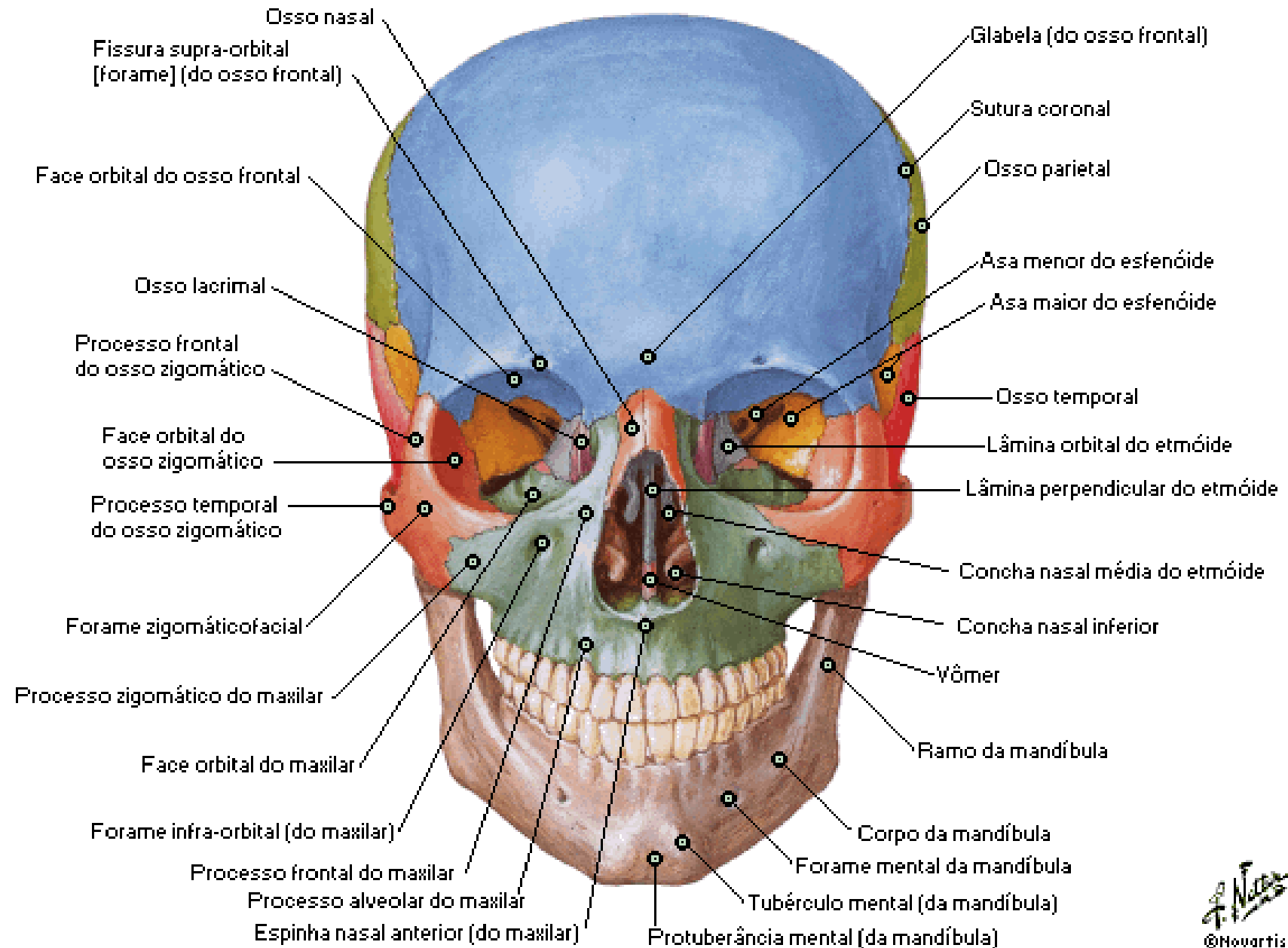


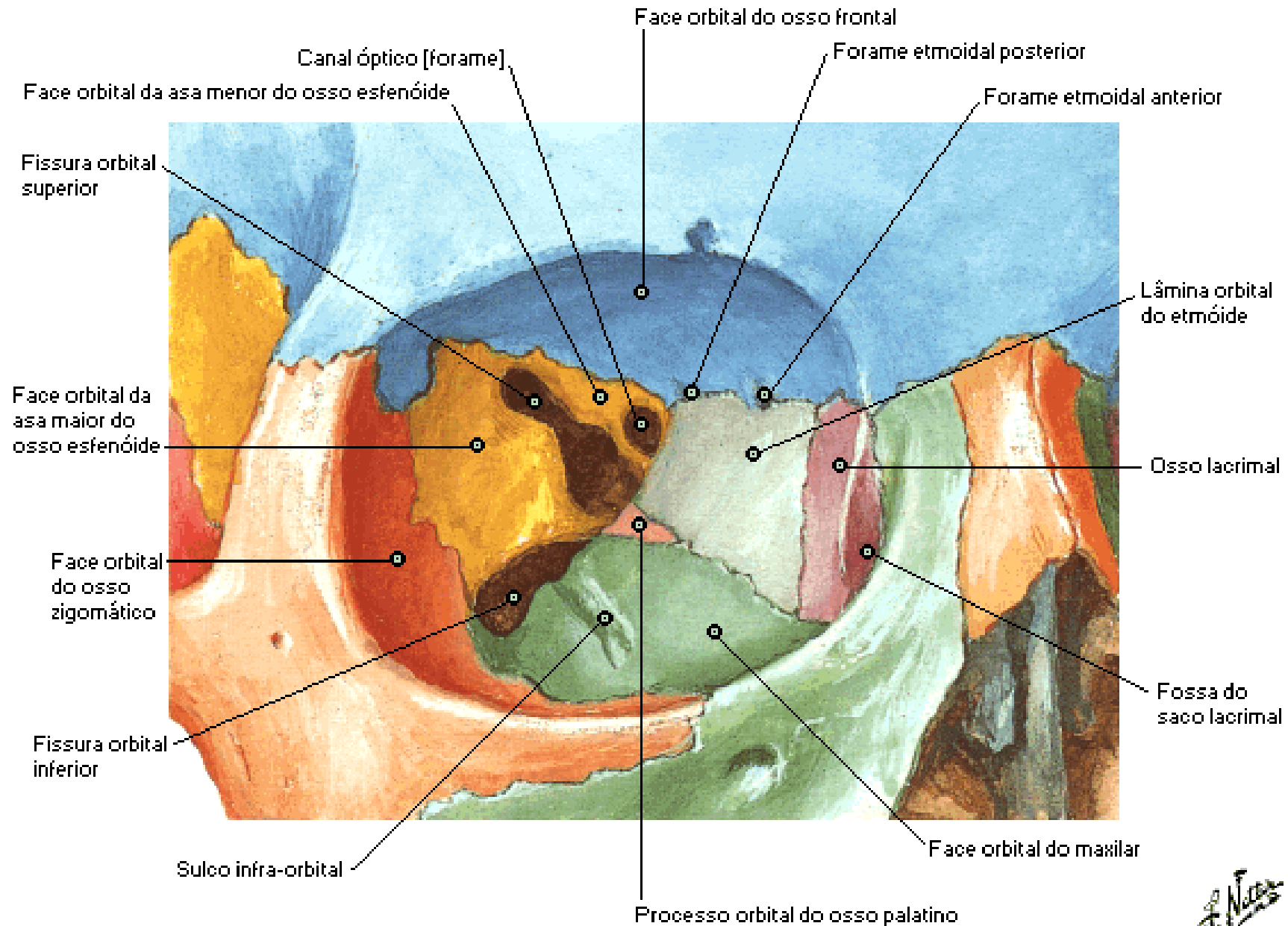
Crânio

Vista Anterior



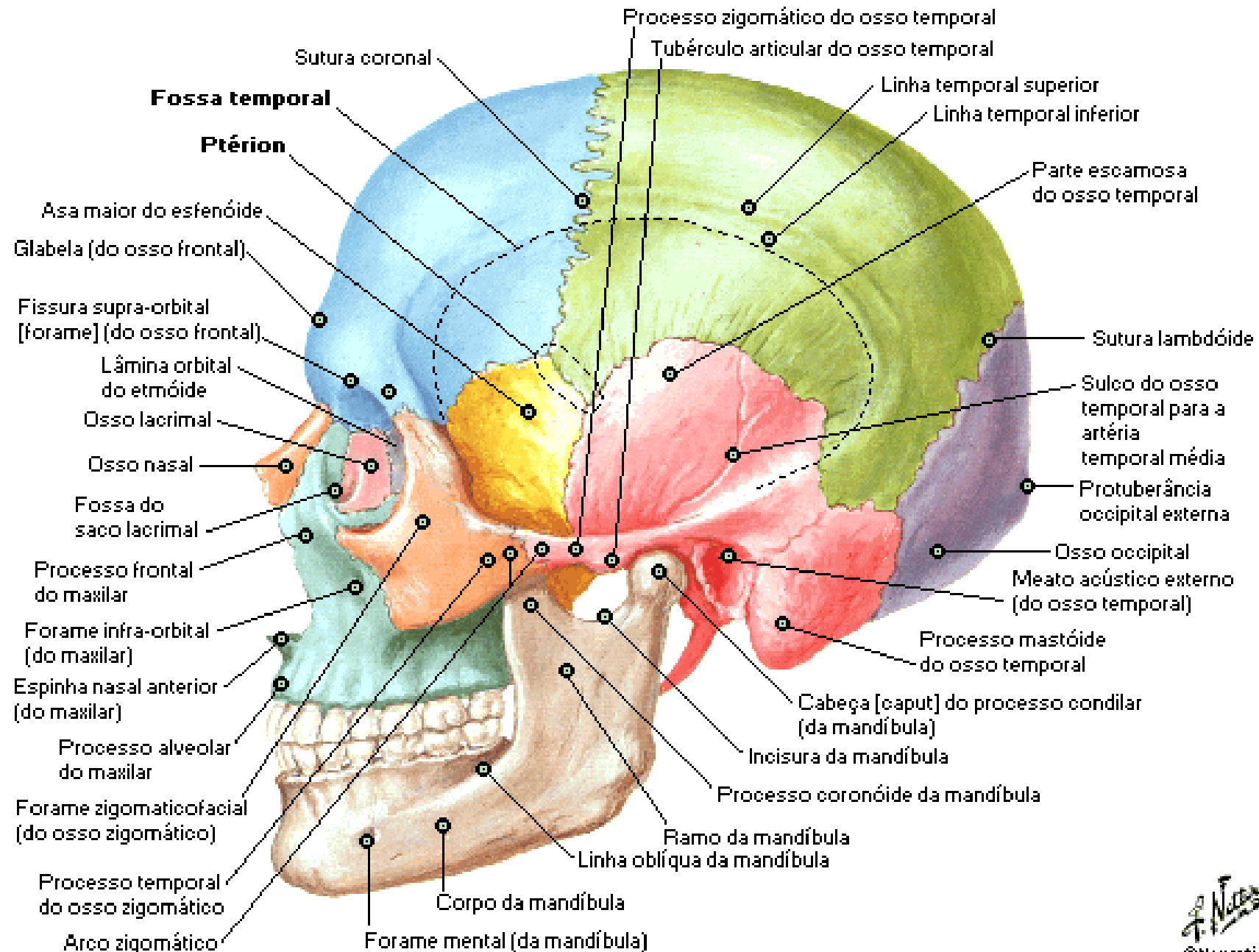
Órbita Direita

Vista Frontal e Levemente Lateral



Crânio

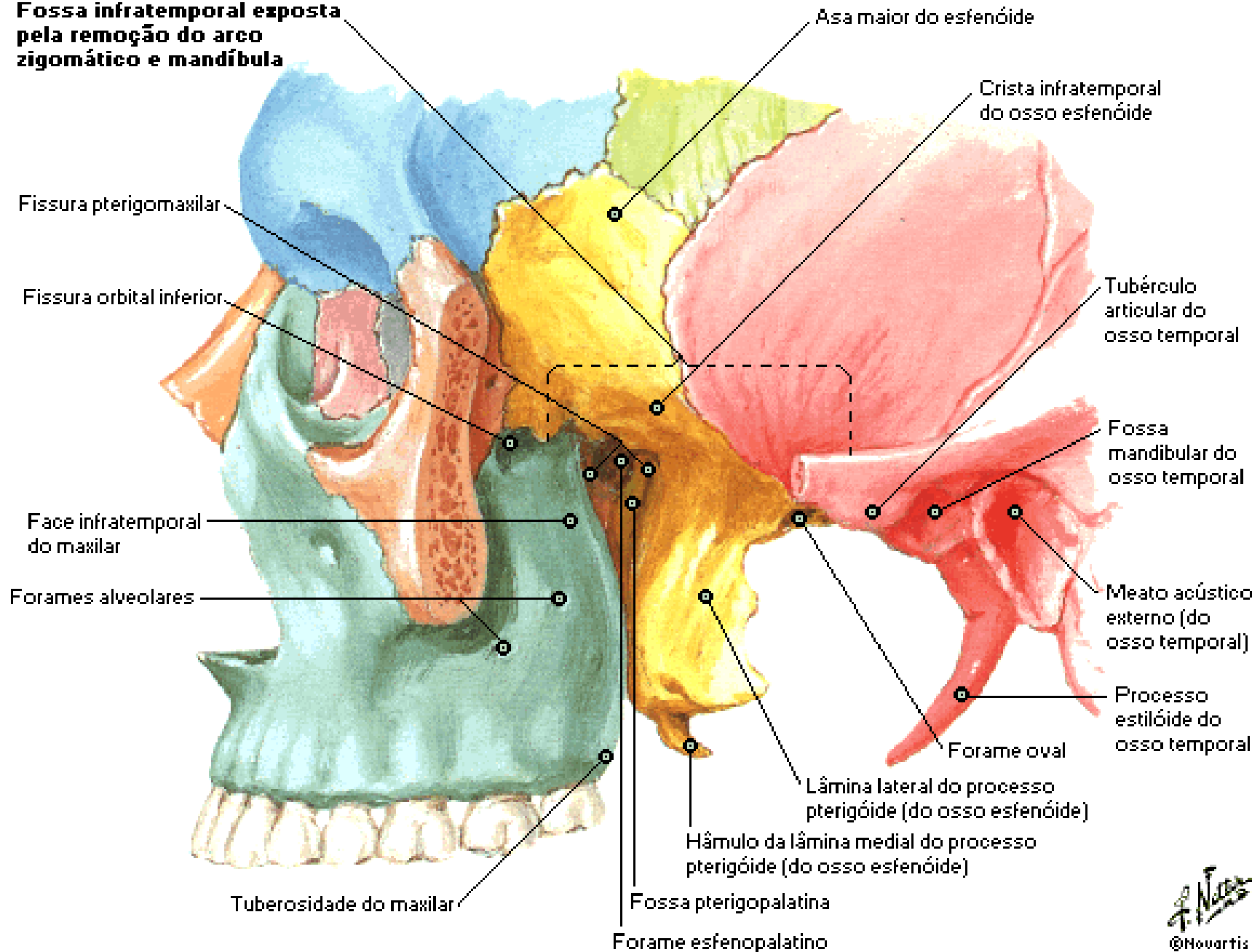
Vista Lateral



Crânio - Fossa Infratemporal Exposta

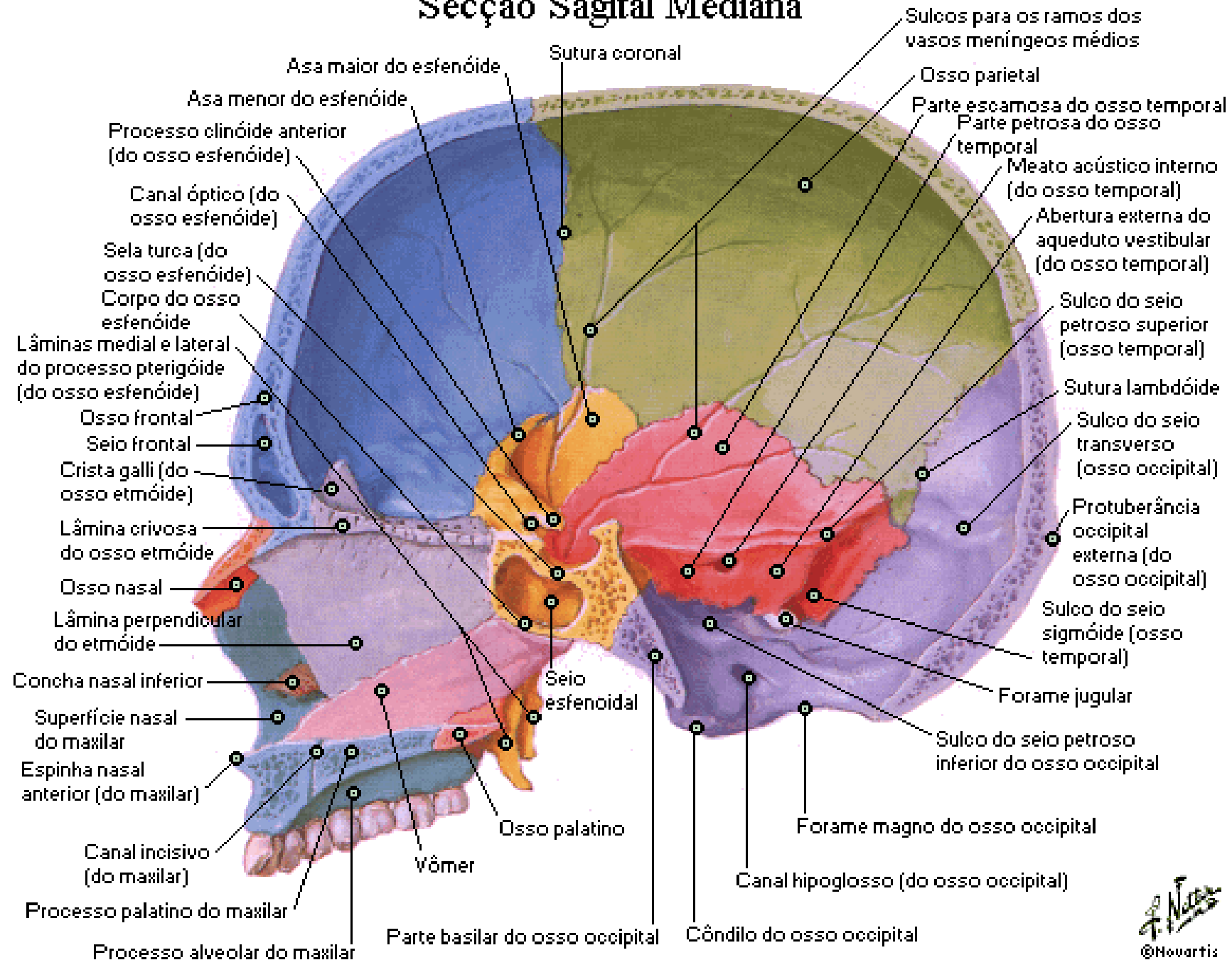
Vista Lateral

Fossa infratemporal exposta pela remoção do arco zigomático e mandíbula



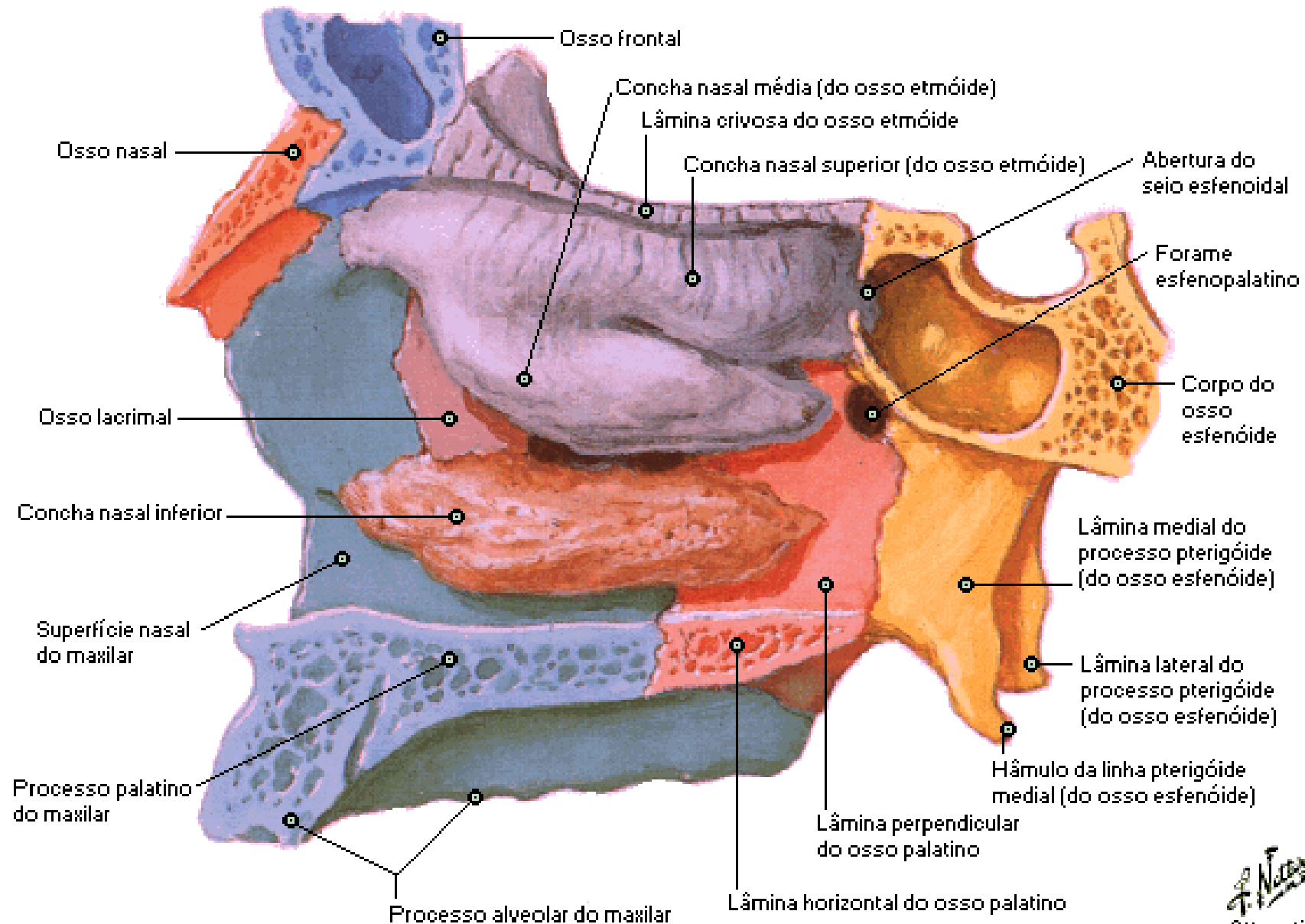
Crânio

Secção Sagital Mediana



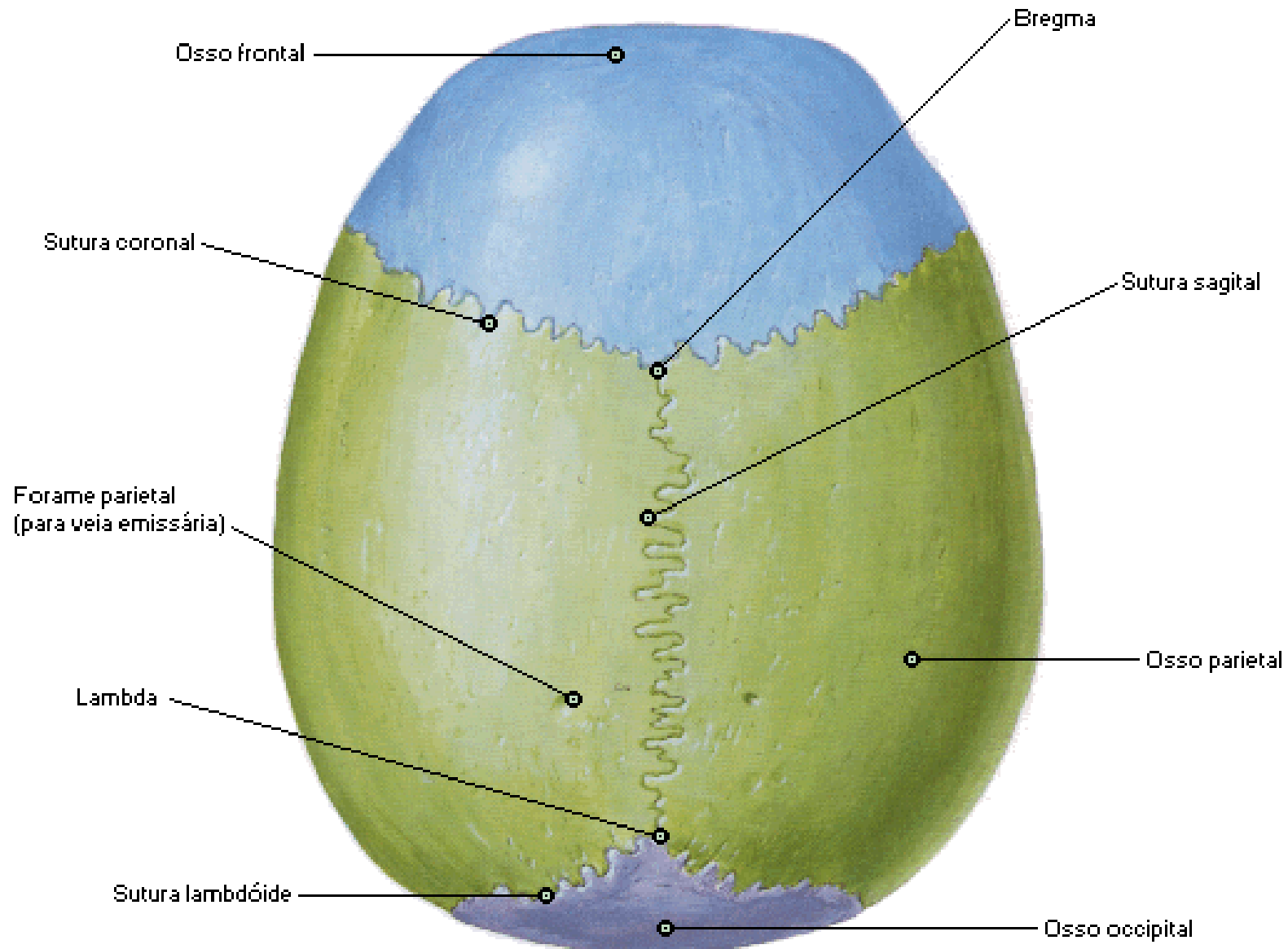
Crânio - Concha Nasal Exposta

Secção Sagital



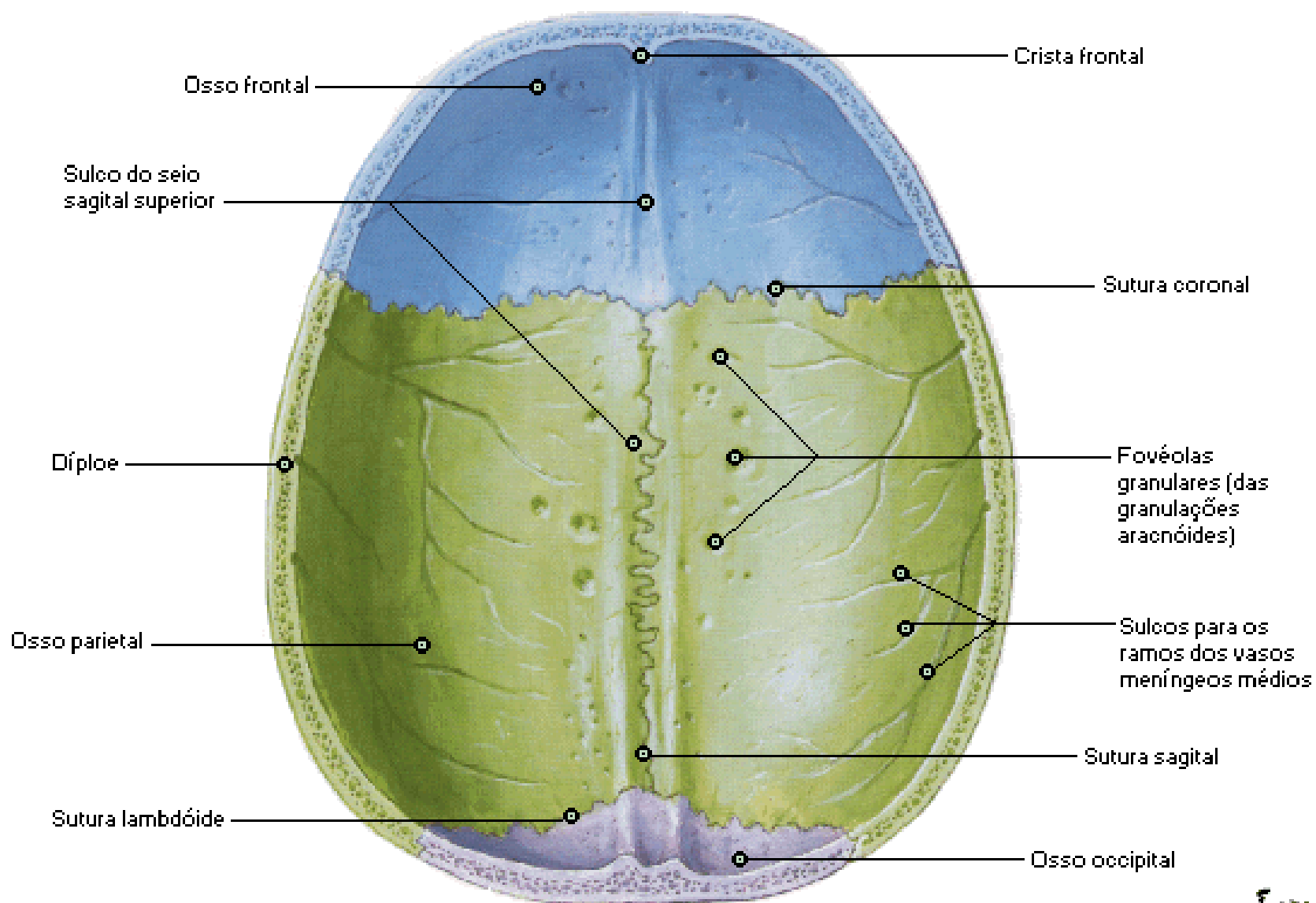
Calota Craniana

Vista Superior



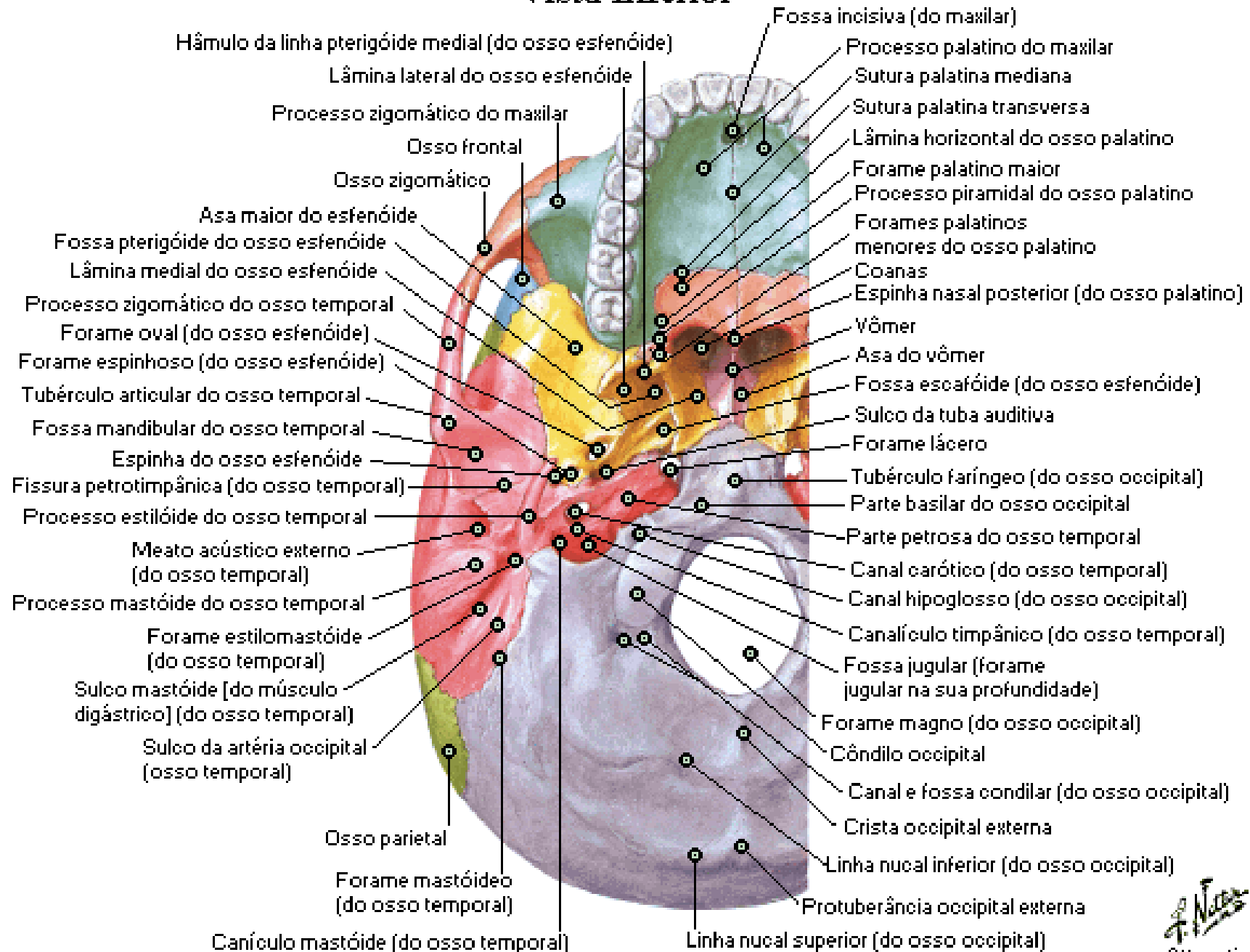
Calota Craniana

Vista Interna



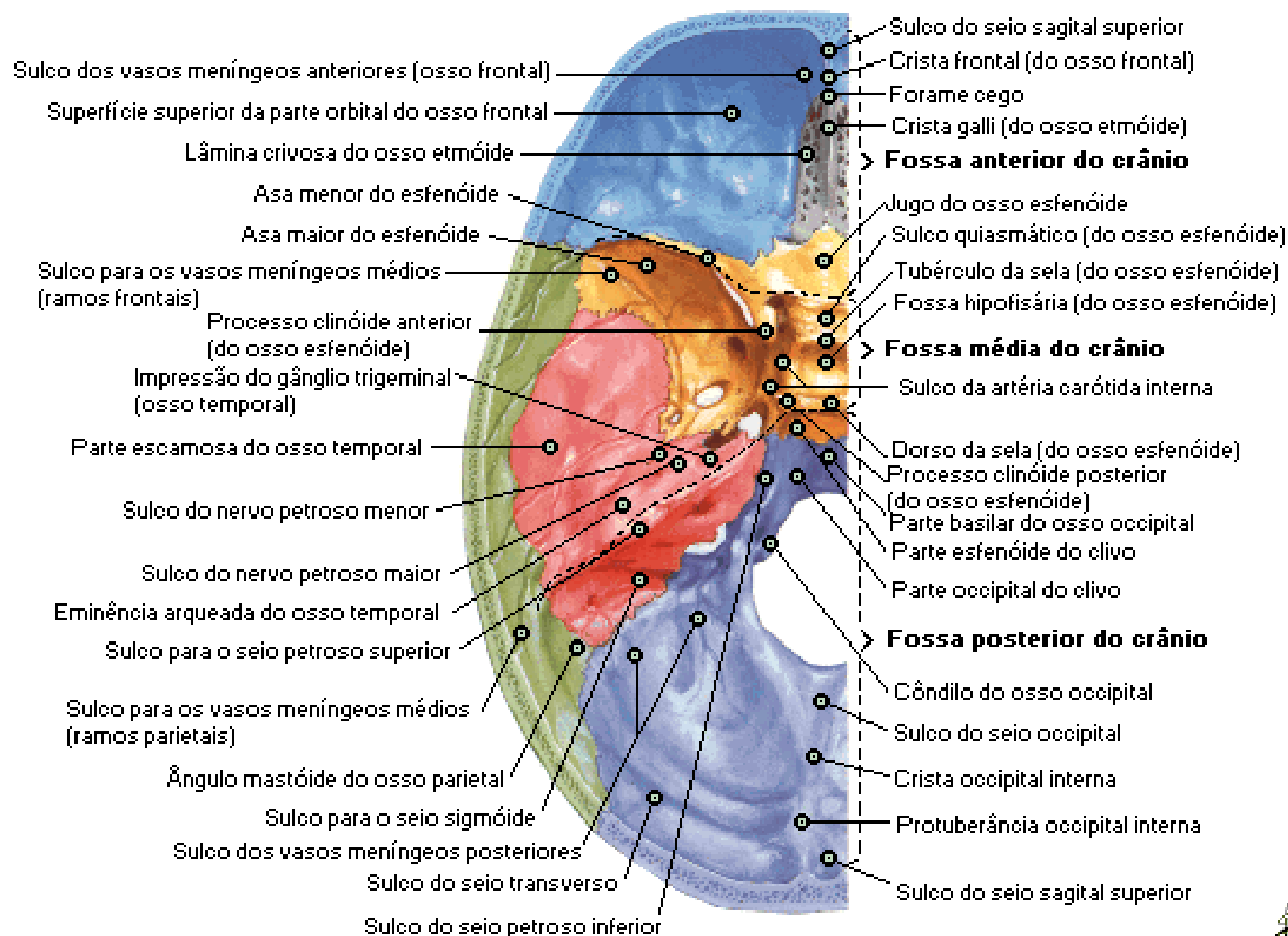
Base do Crânio

Vista Inferior



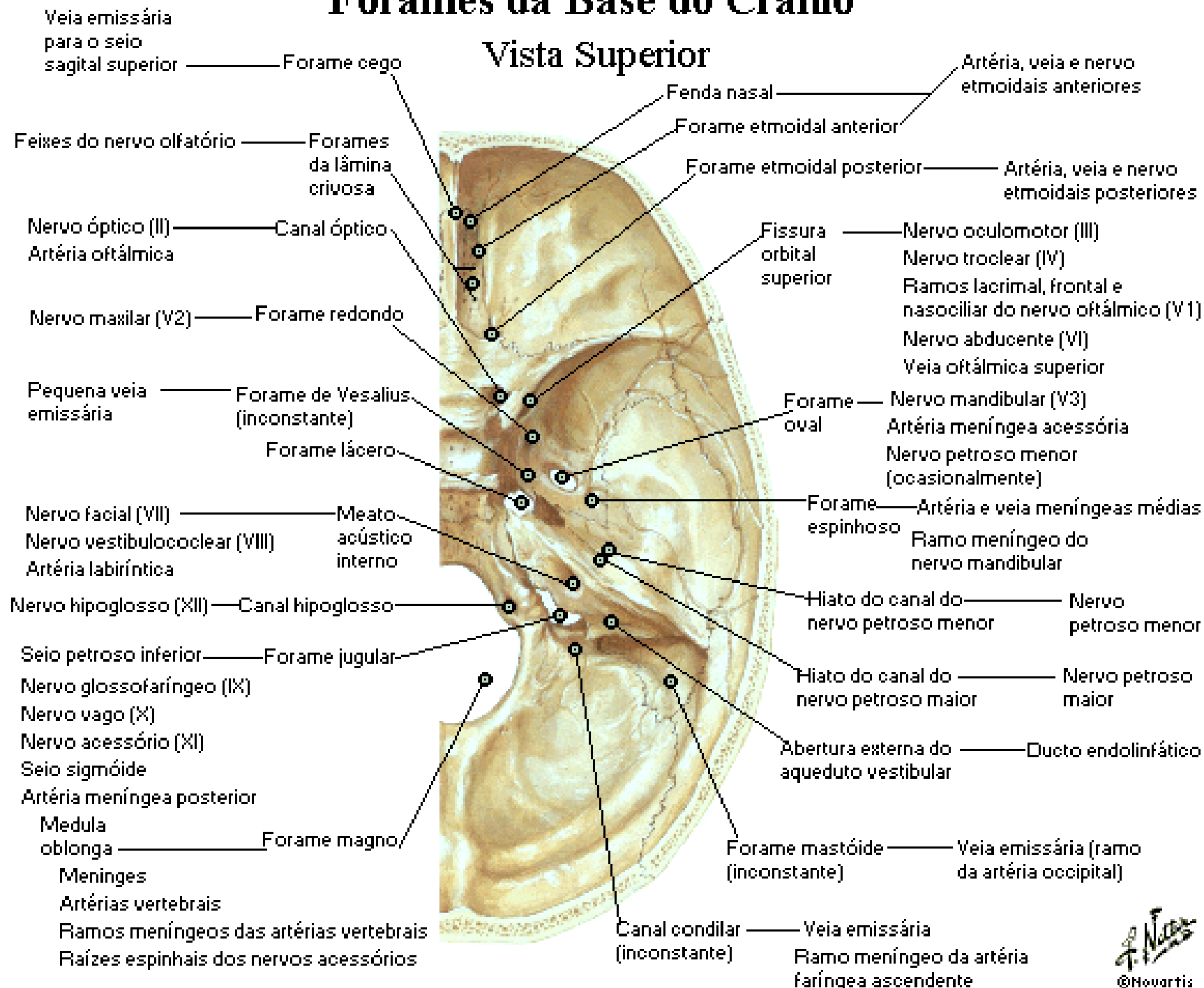
Ossos da Base do Crânio

Vista Superior



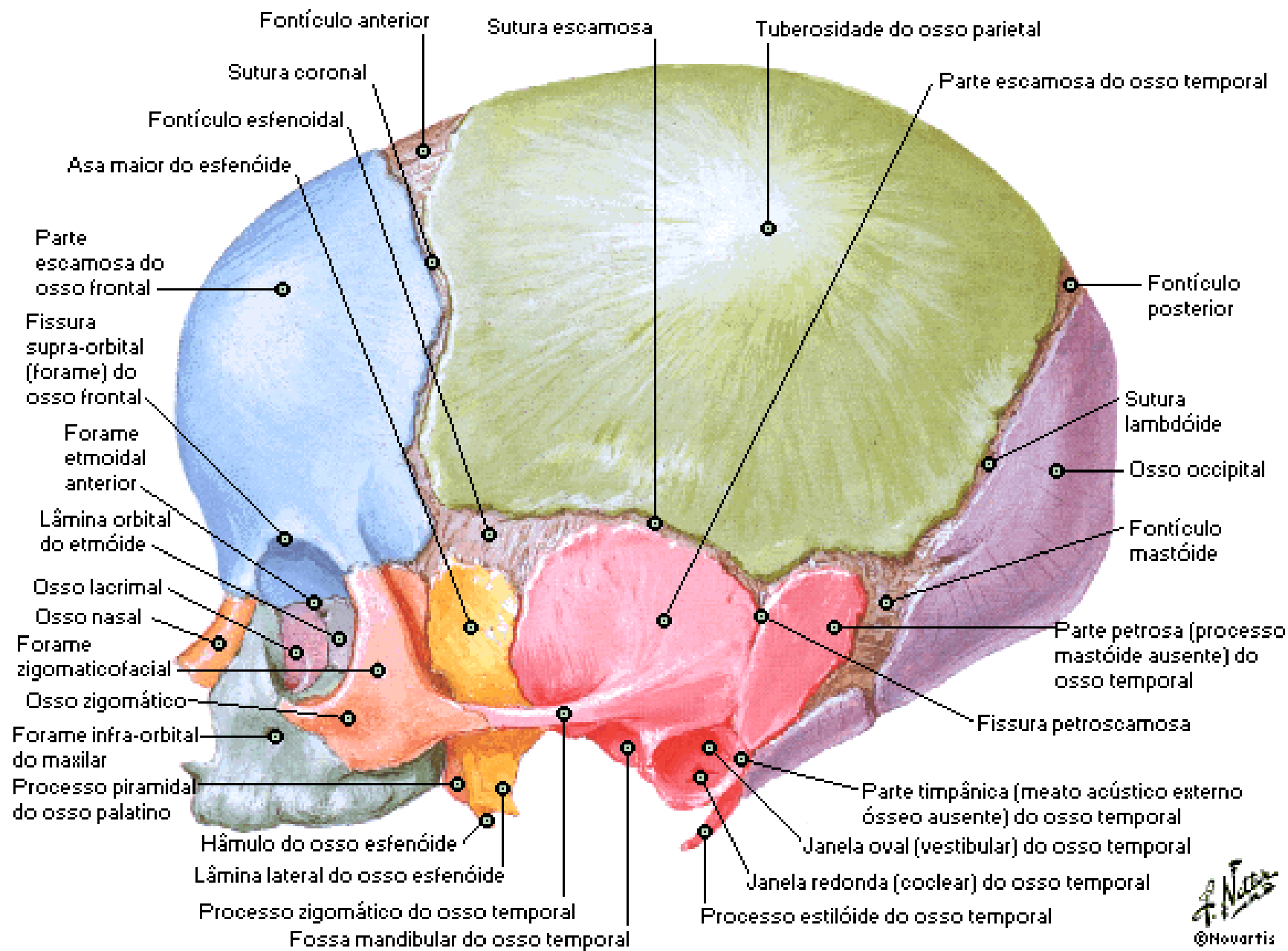
Forames da Base do Crânio

Vista Superior



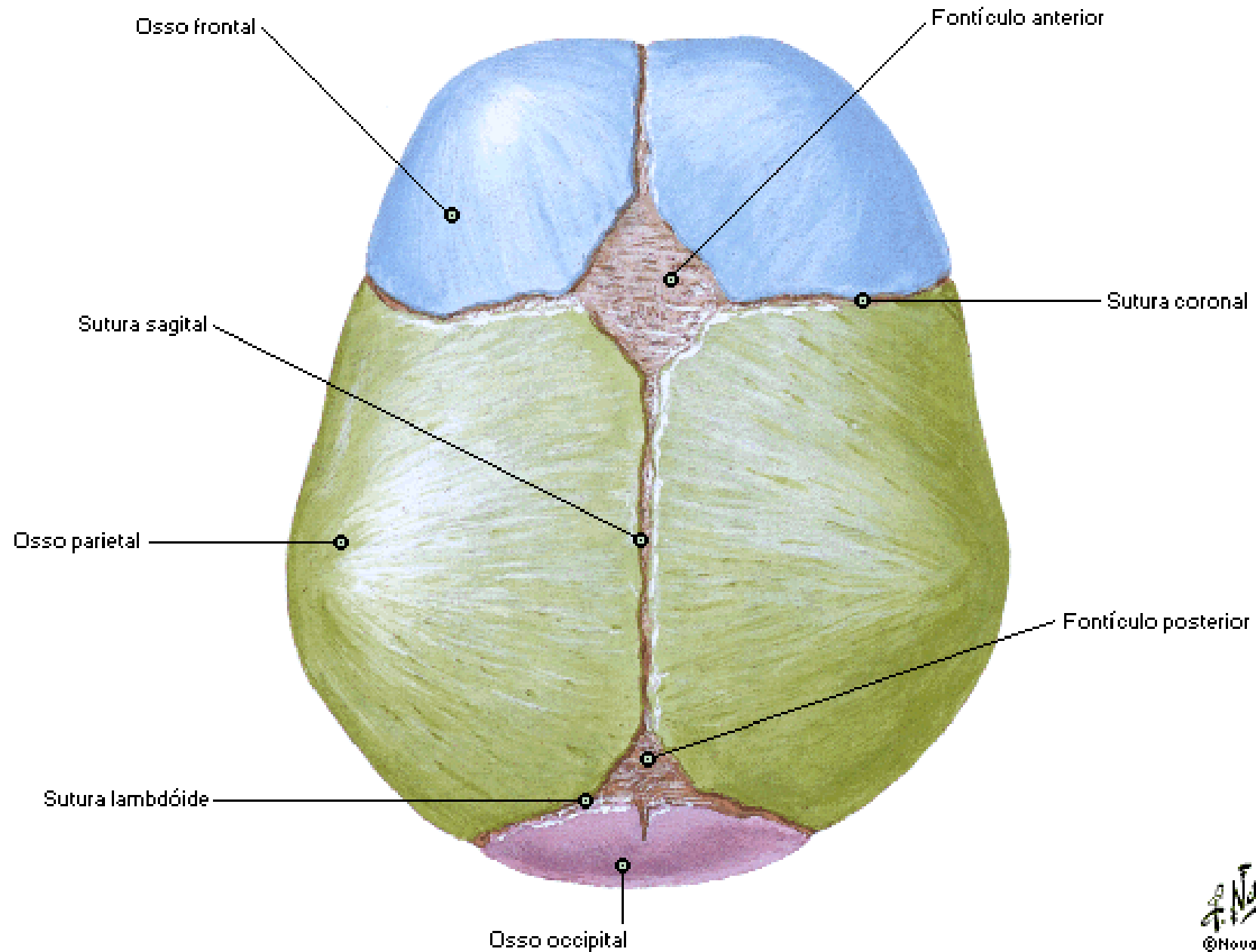
Crânio de um Recém-nascido

Vista Lateral



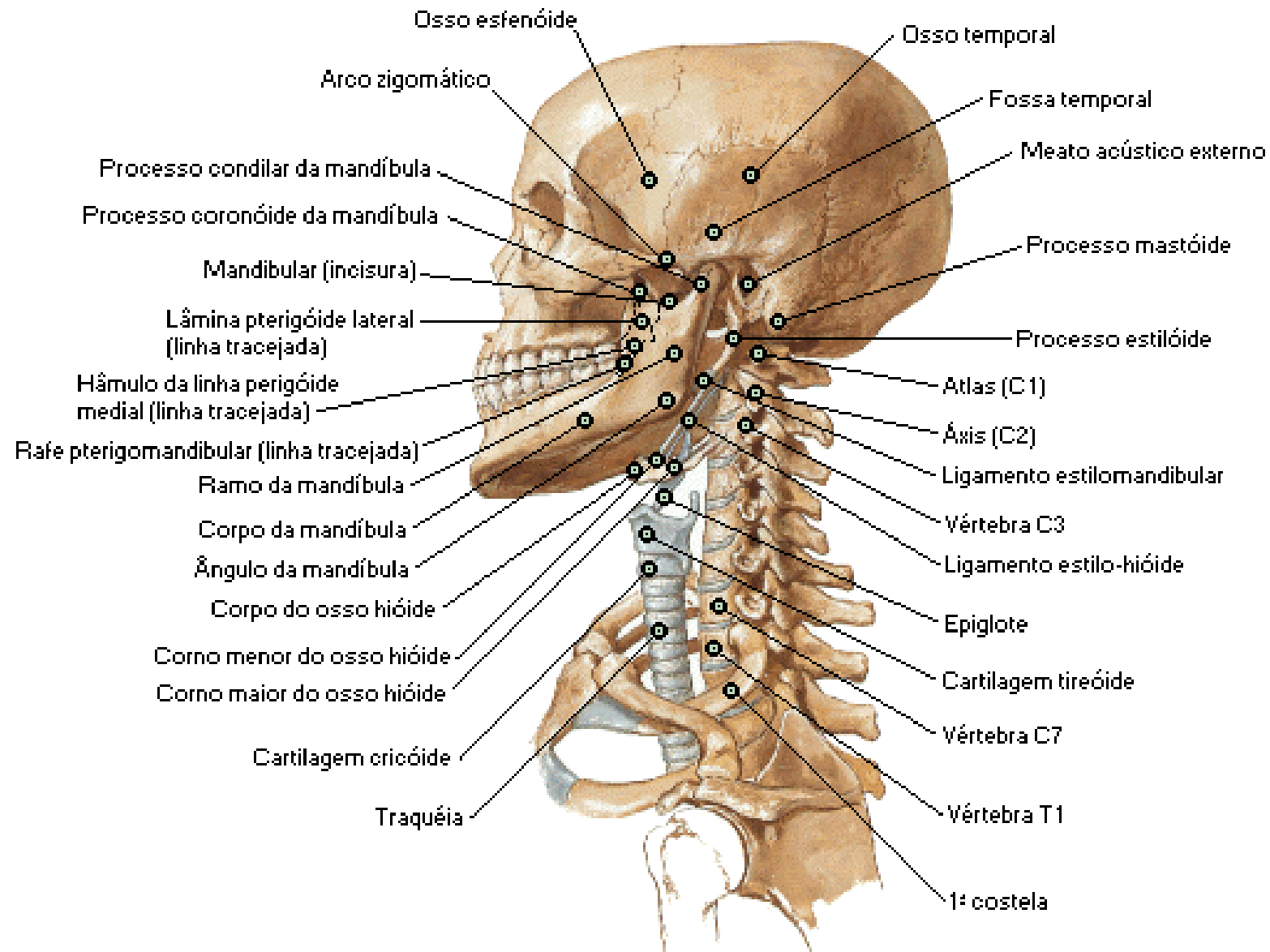
Crânio de um Recém-nascido

Vista Superior



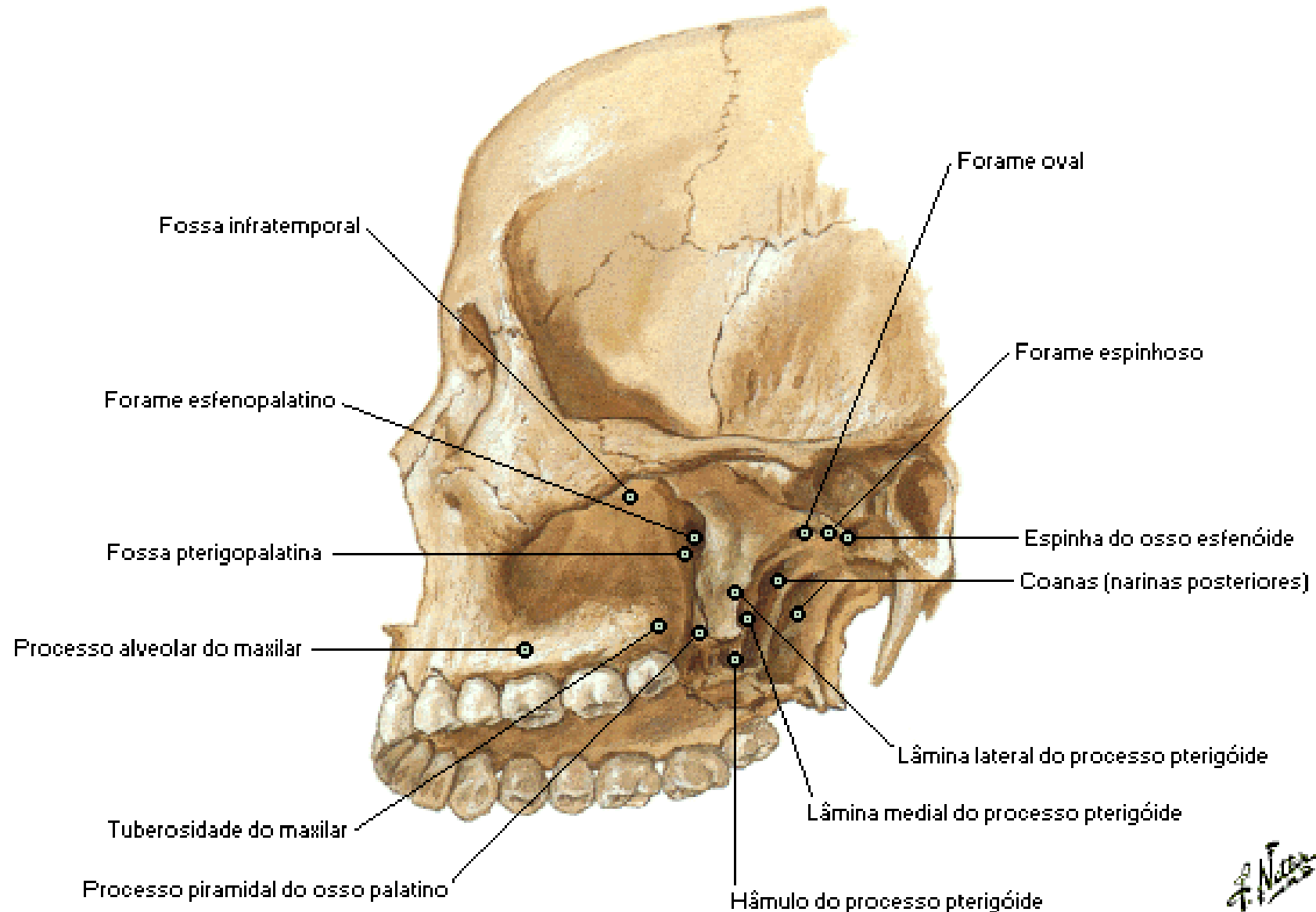
Arcabouço Ósseo da Cabeça e Pescoço

Vista Lateral



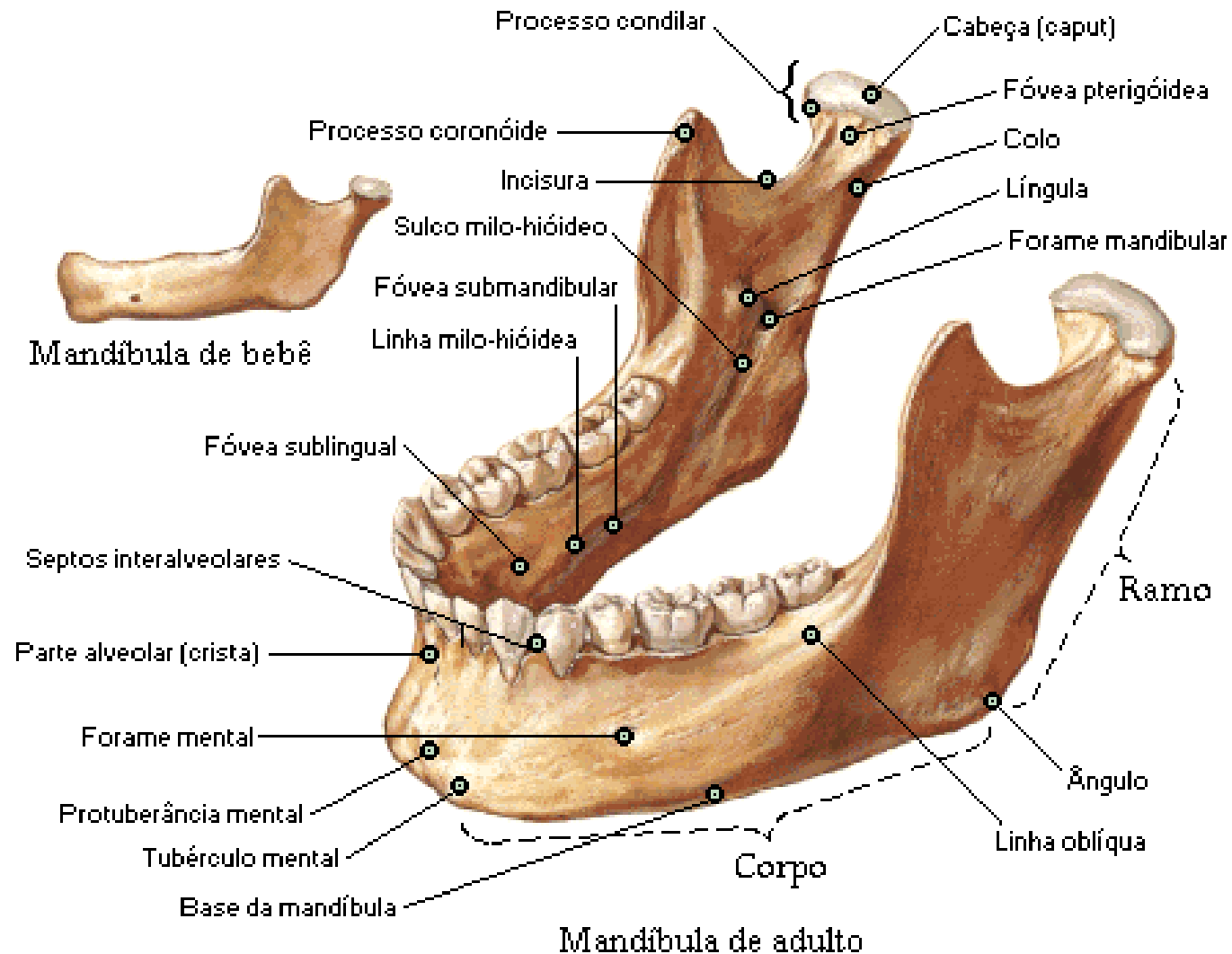
Arcabouço Ósseo da Cabeça - Mandíbula Removida

Vista Lateral



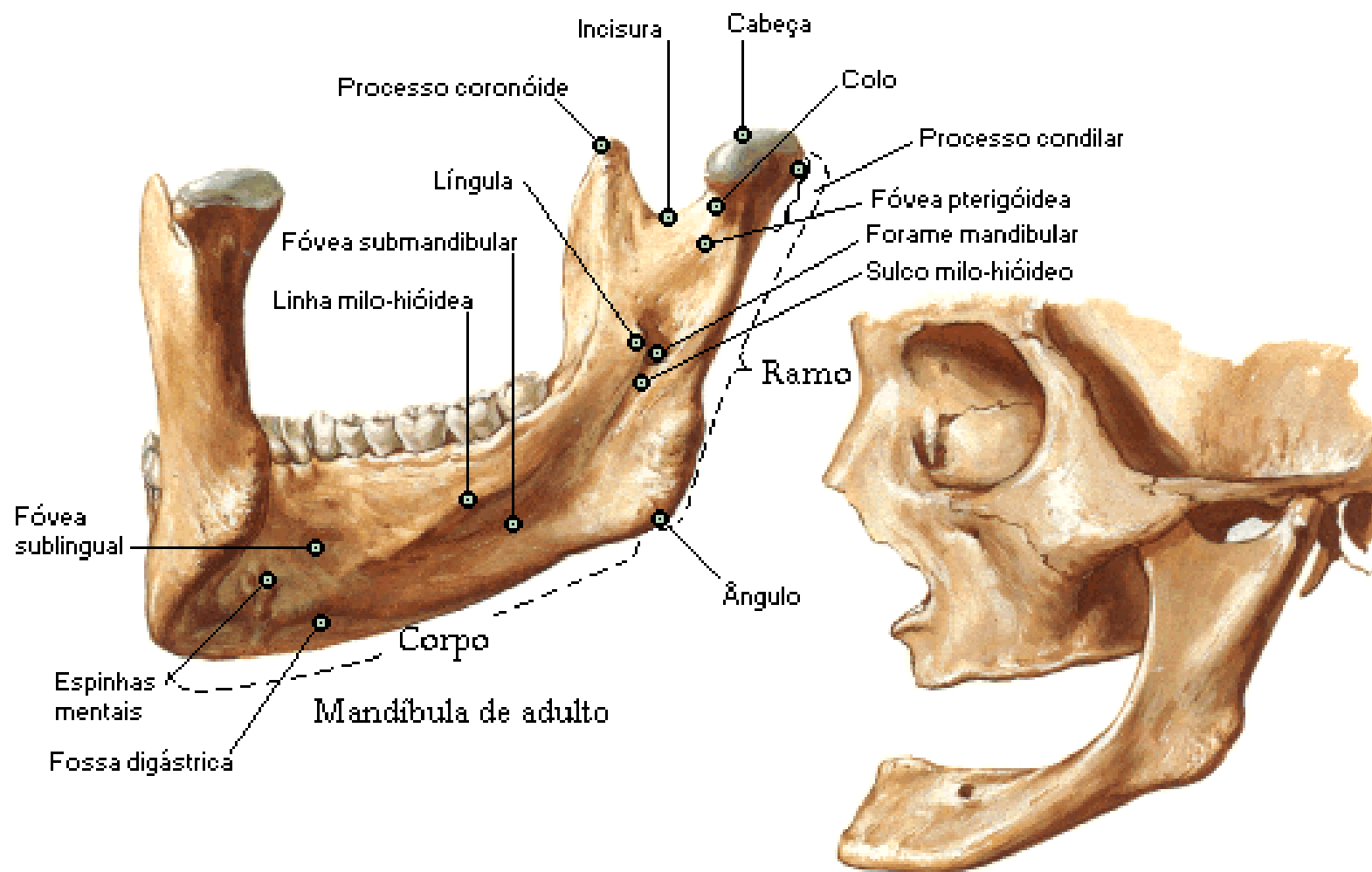
Mandíbula

Vista Superior e Ântero-lateral



Mandíbula

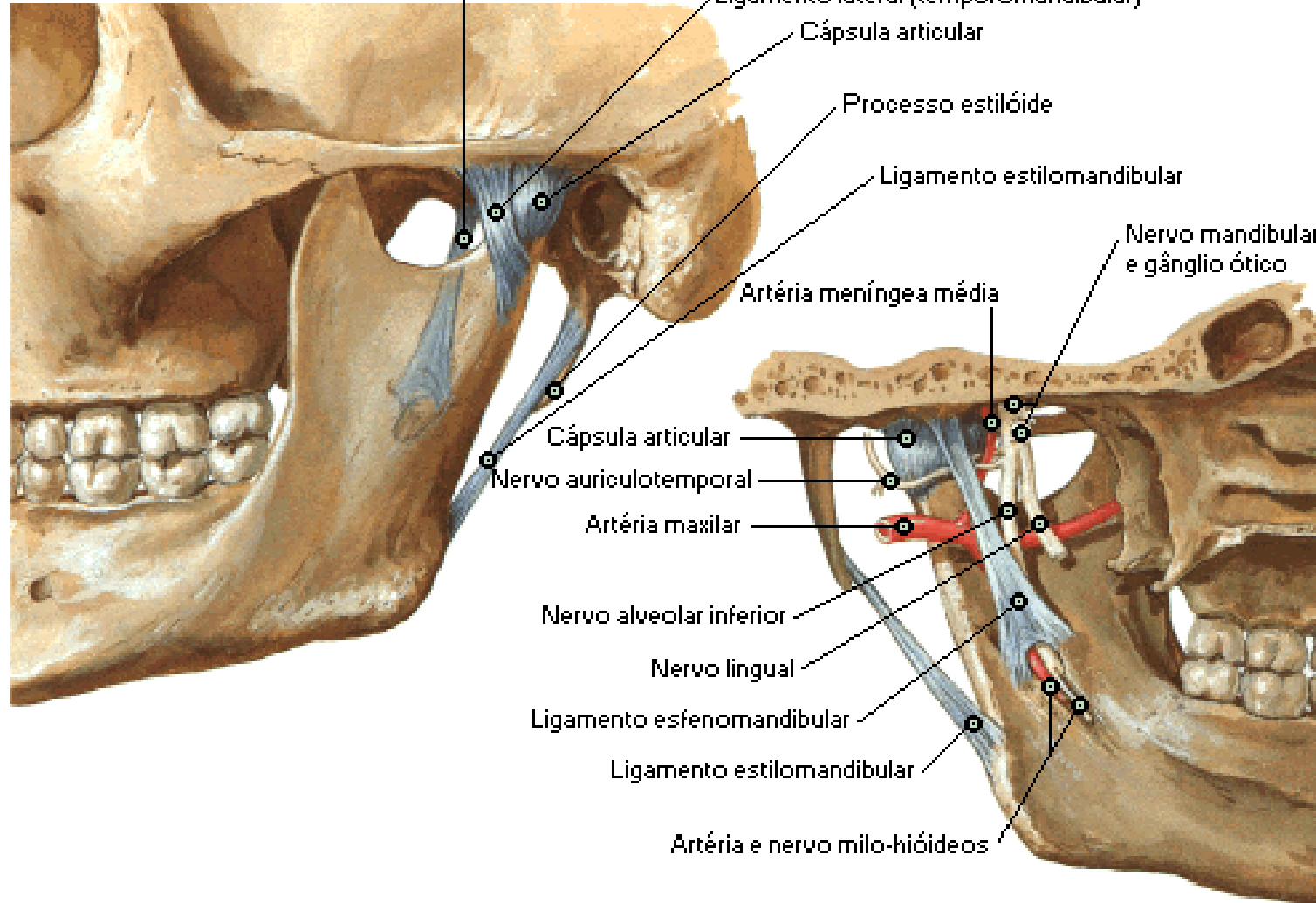
Vista Posterior e Esquerda



Articulação Temporomandibular

Vistas Lateral e Medial

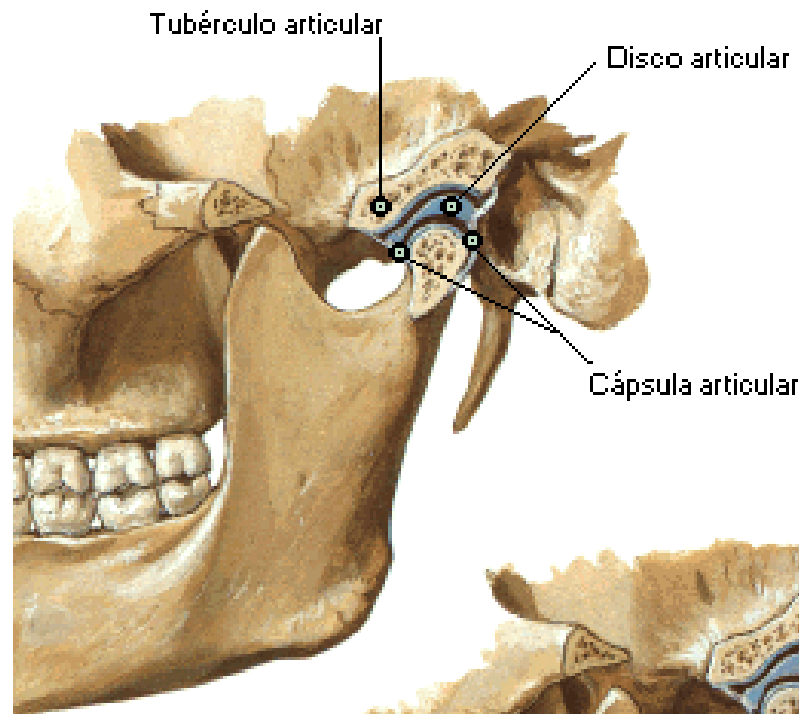
Vista lateral



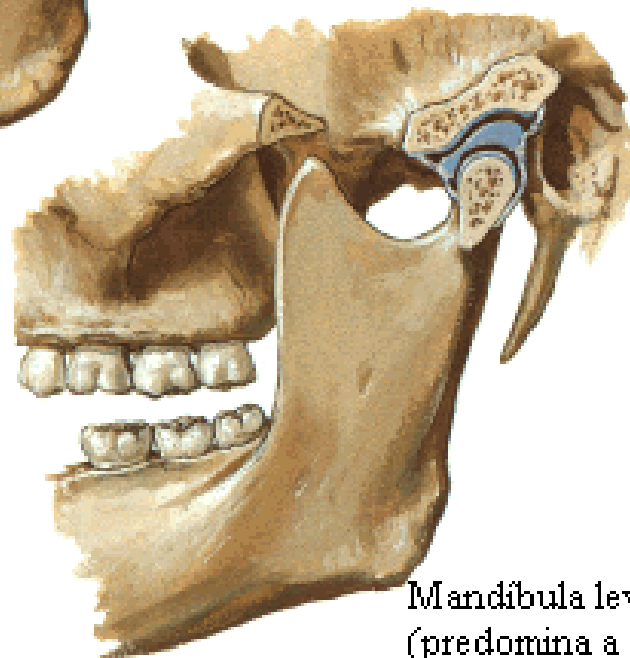
Vista medial

Articulação Temporomandibular

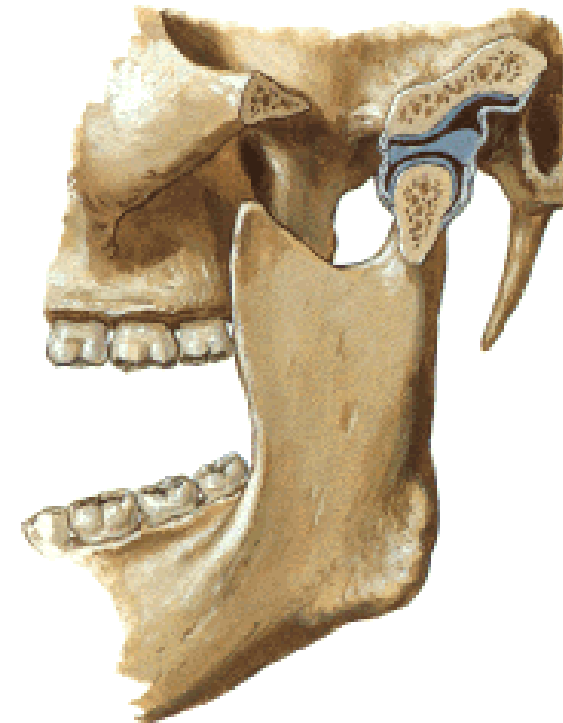
Ação Articular



Mandíbula fechada



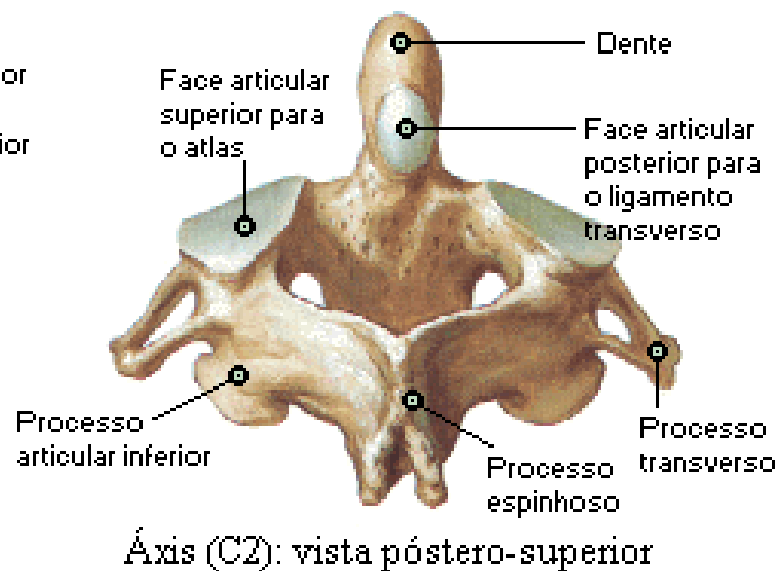
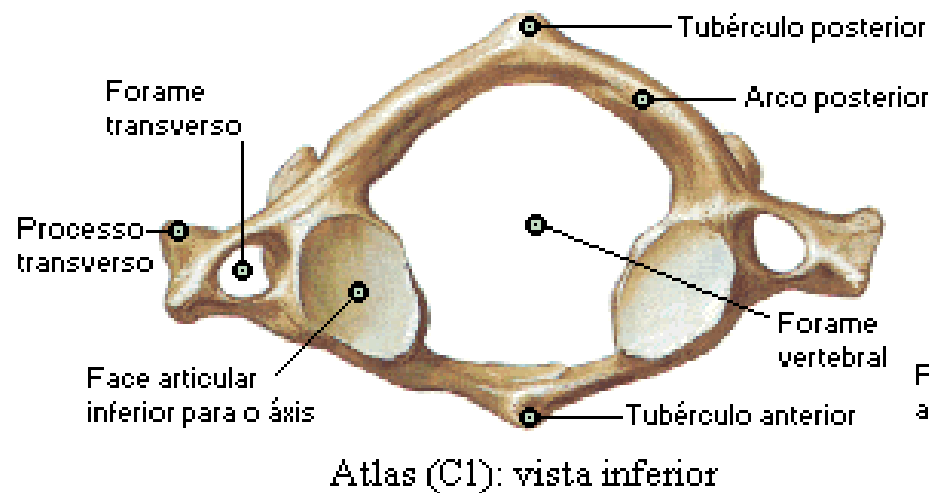
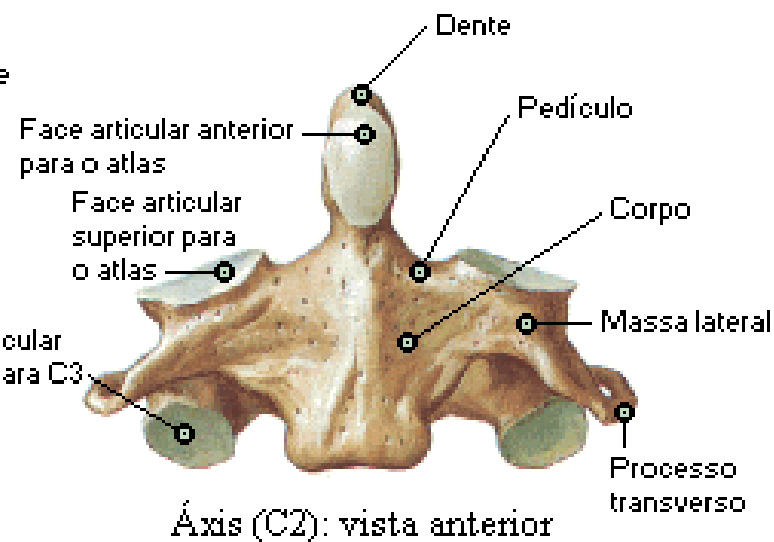
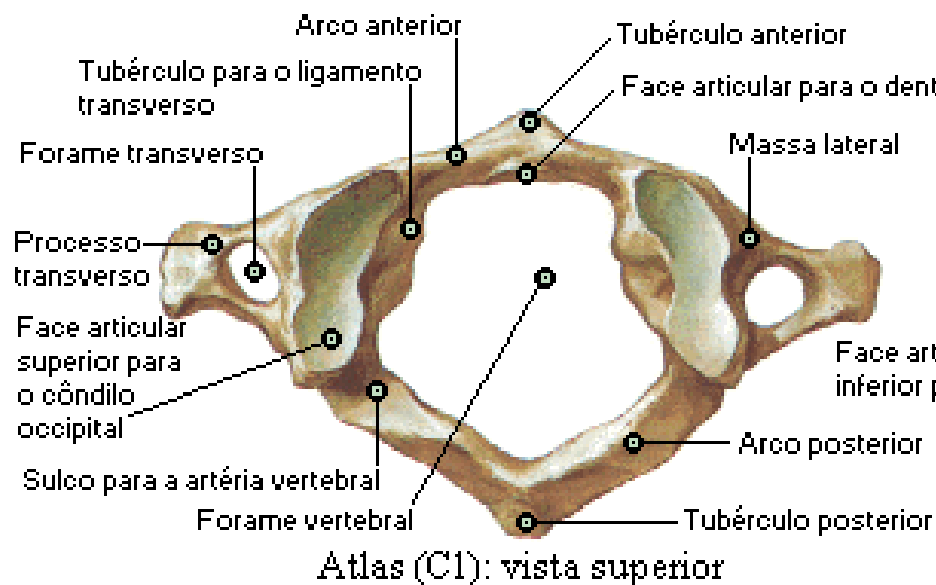
Mandíbula levemente aberta
(predomina a ação de pivô)



Mandíbula amplamente aberta
(combinação das ações de
pivô e deslizamento)

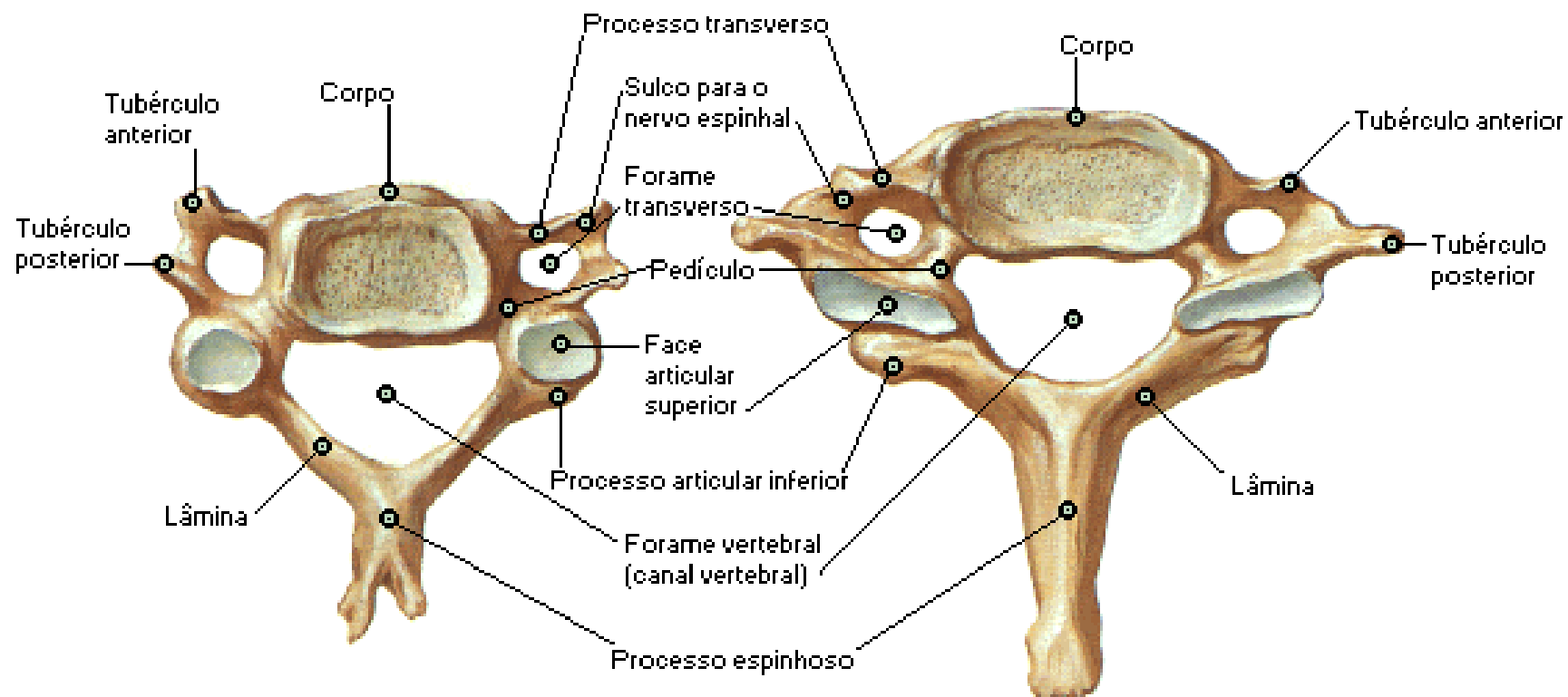
Vértebras Cervicais

Atlas e Áxis



Vértebras Cervicais [C4 e C7]

Vistas Superiores

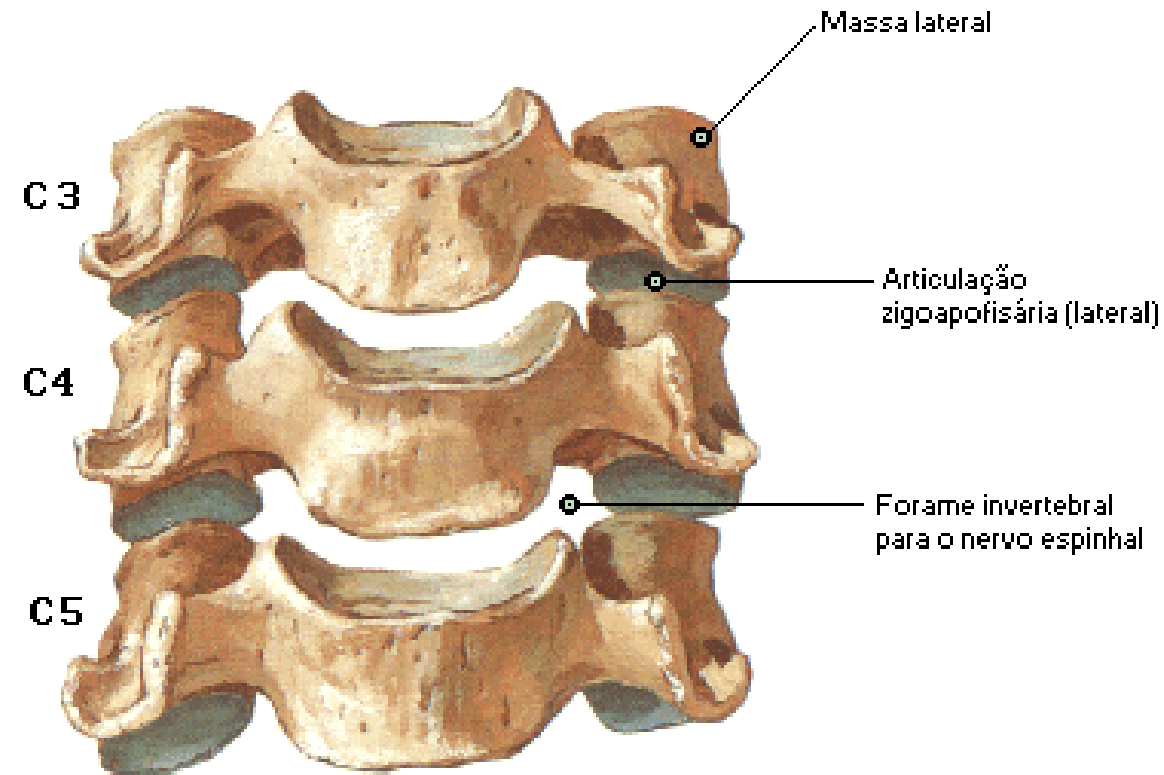


4ª vértebra cervical: vista superior

7ª vértebra cervical: vista superior

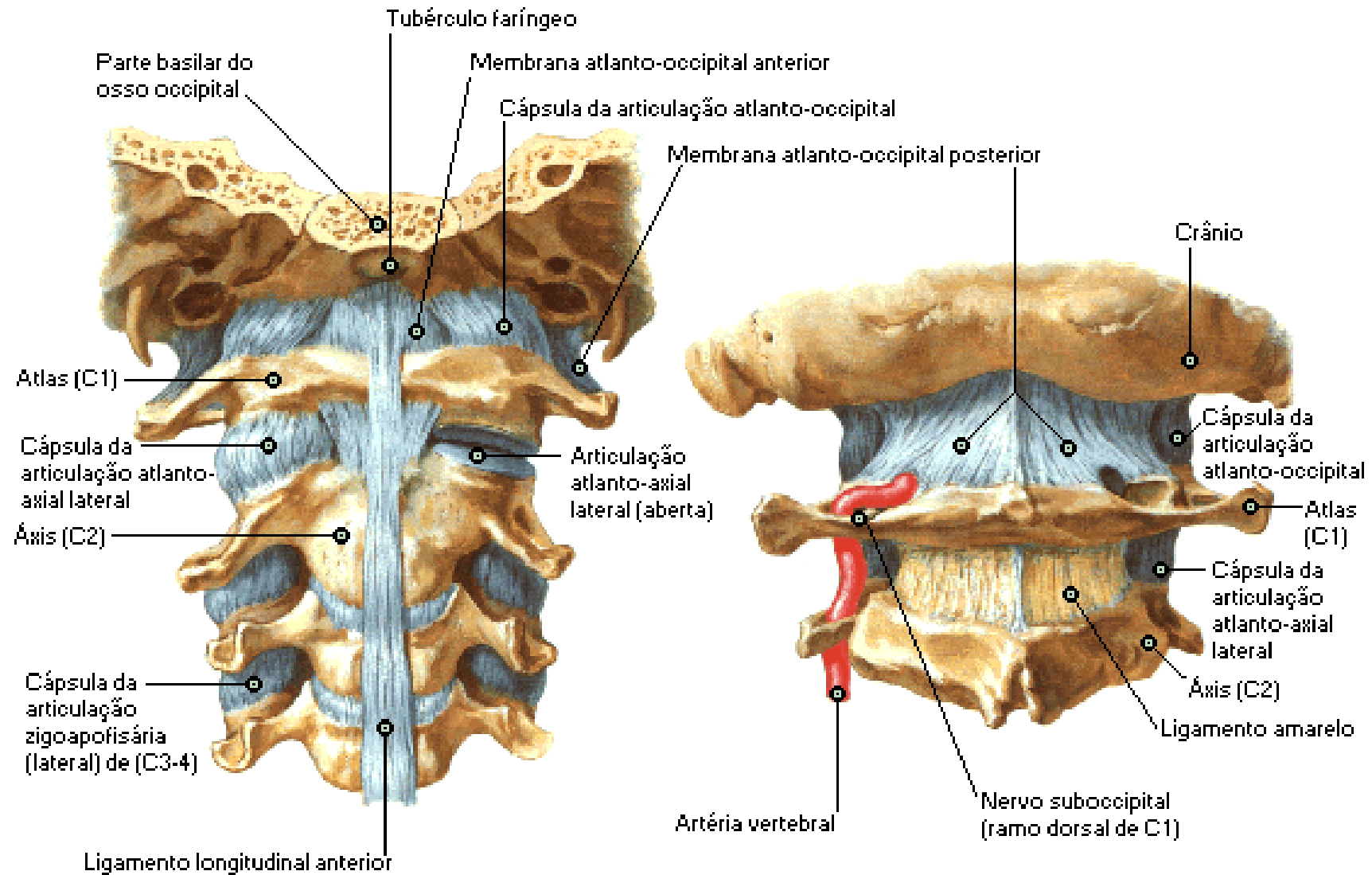
Vértebras Cervicais [C3-C5], Agrupadas

Vista Anterior



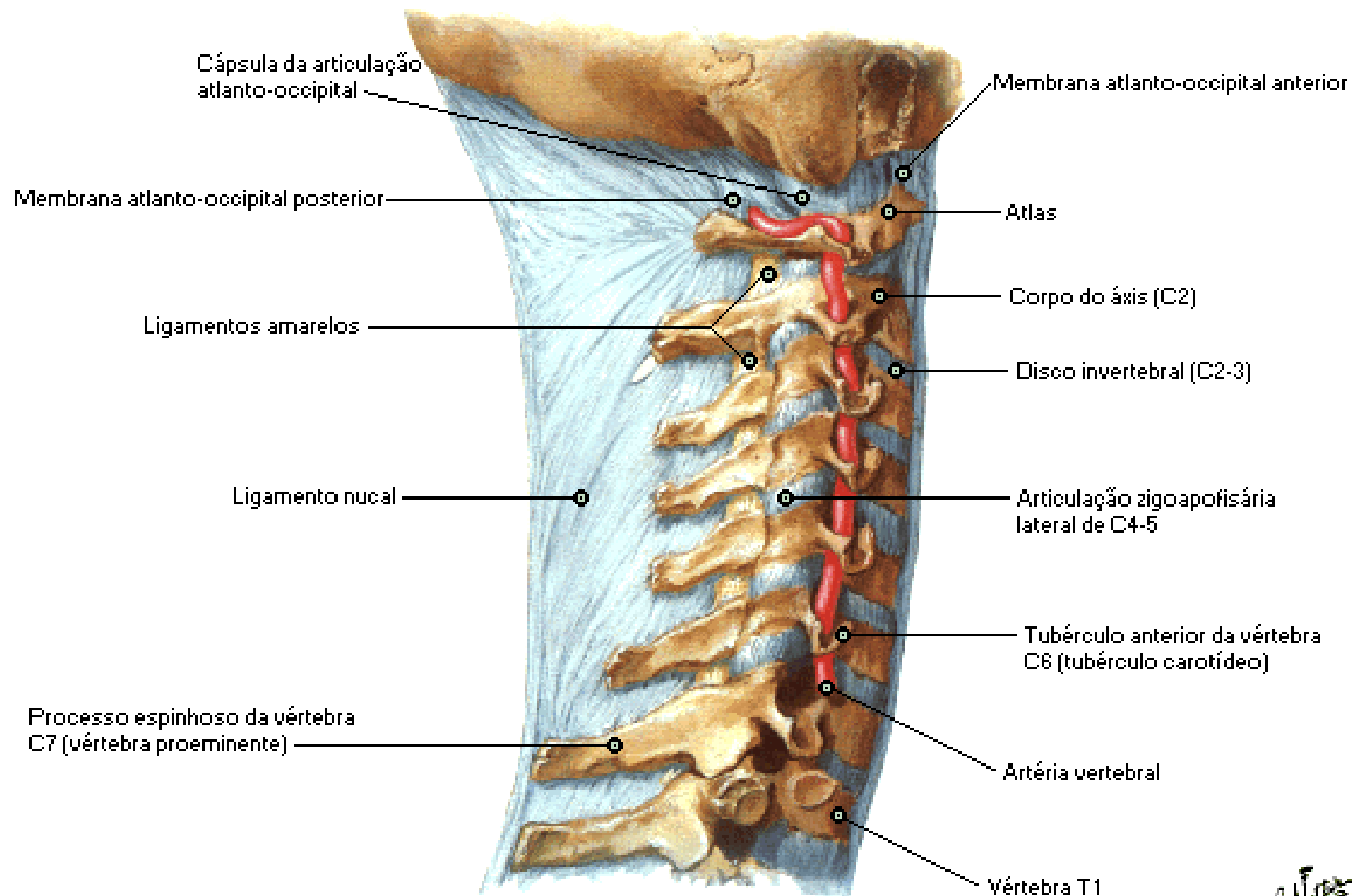
Ligamentos Craniocervicais Externos

Vistas Anterior e Posterior



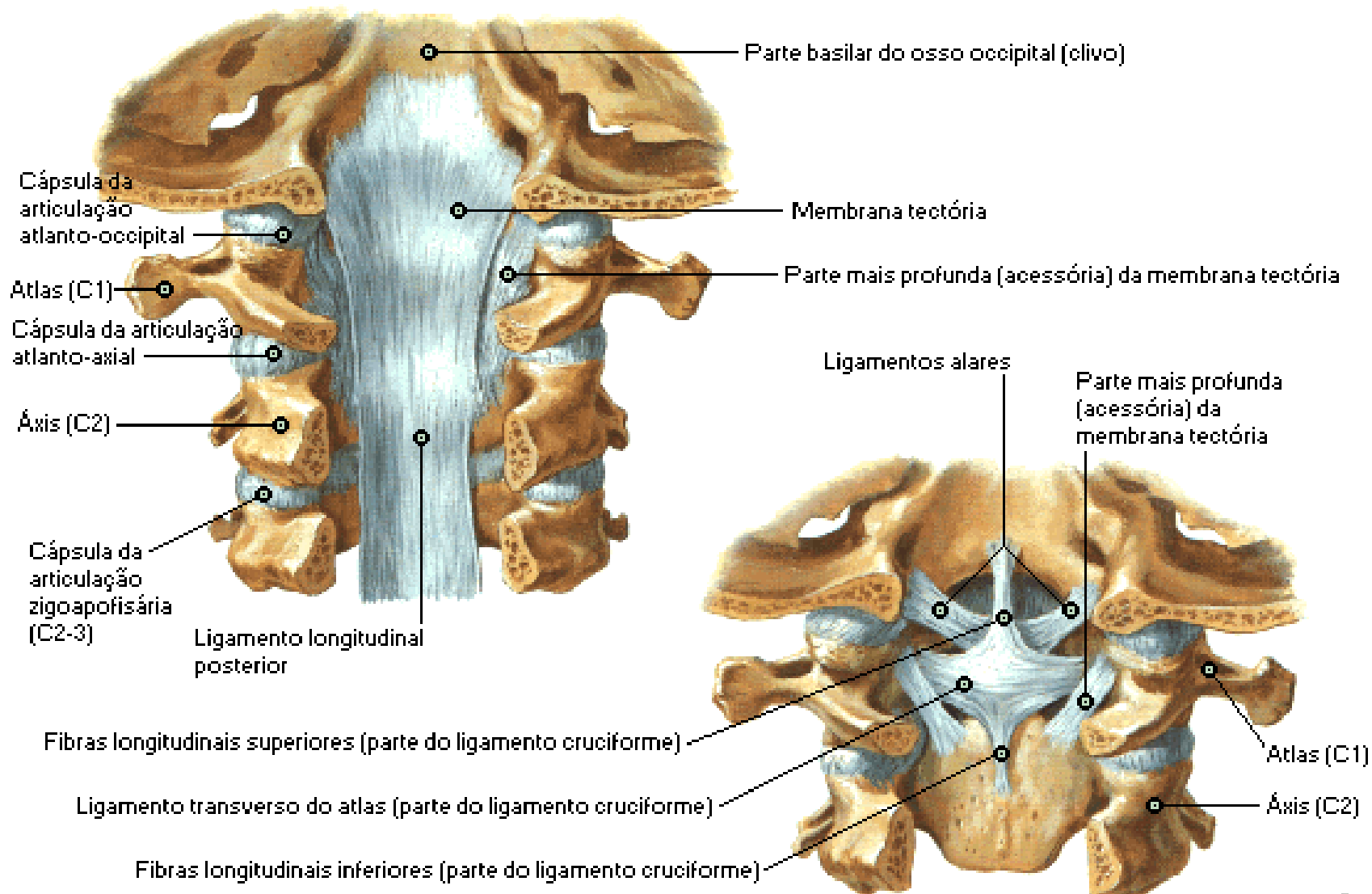
Ligamentos Craniocervicais Externos

Vista Lateral Direita



Ligamentos Craniocervicais Internos

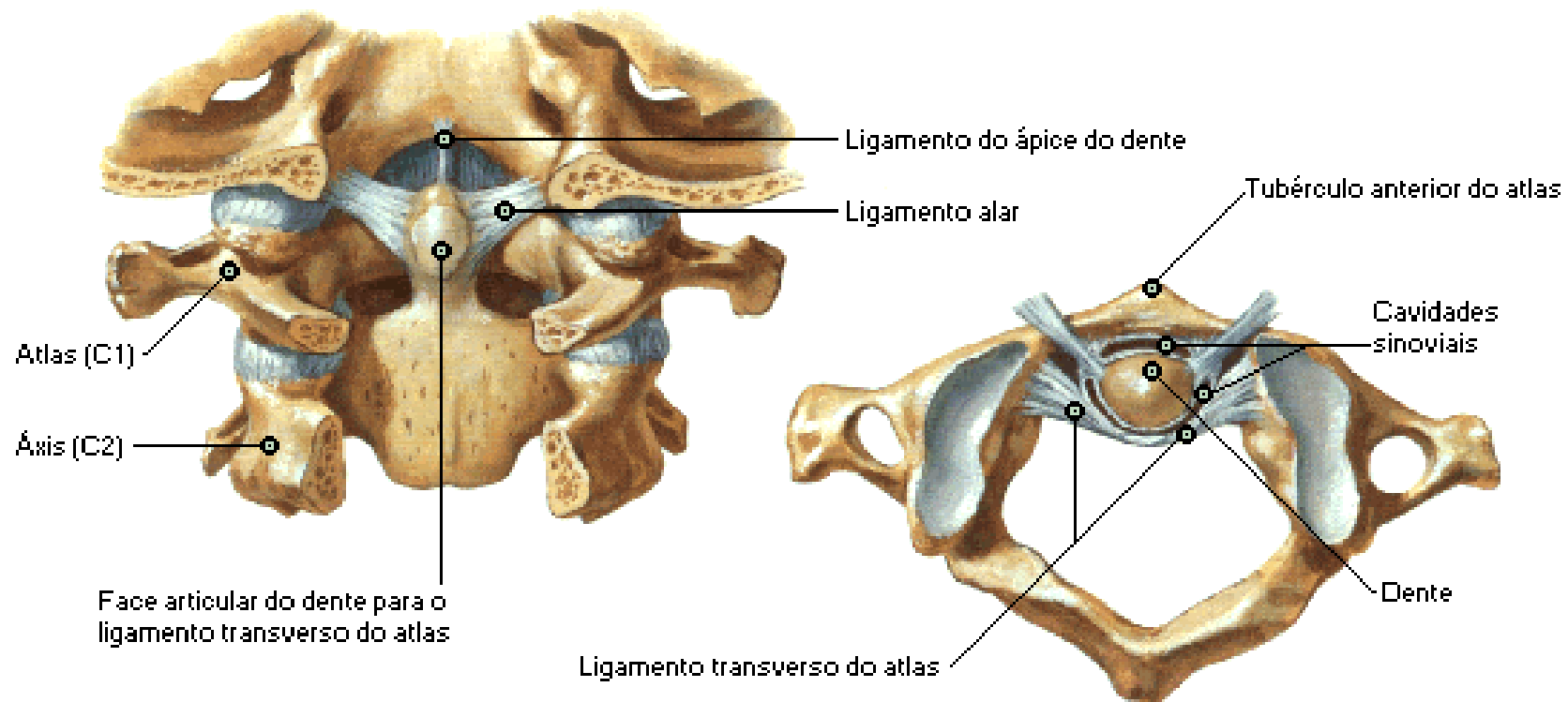
Parte superior do canal vertebral com a remoção dos processos espinhosos e partes dos arcos vertebrais para expor os ligamentos dos corpos vertebrais posteriores: vista posterior



Parte principal da membrana tectória removida, expondo os ligamentos profundos: vista posterior

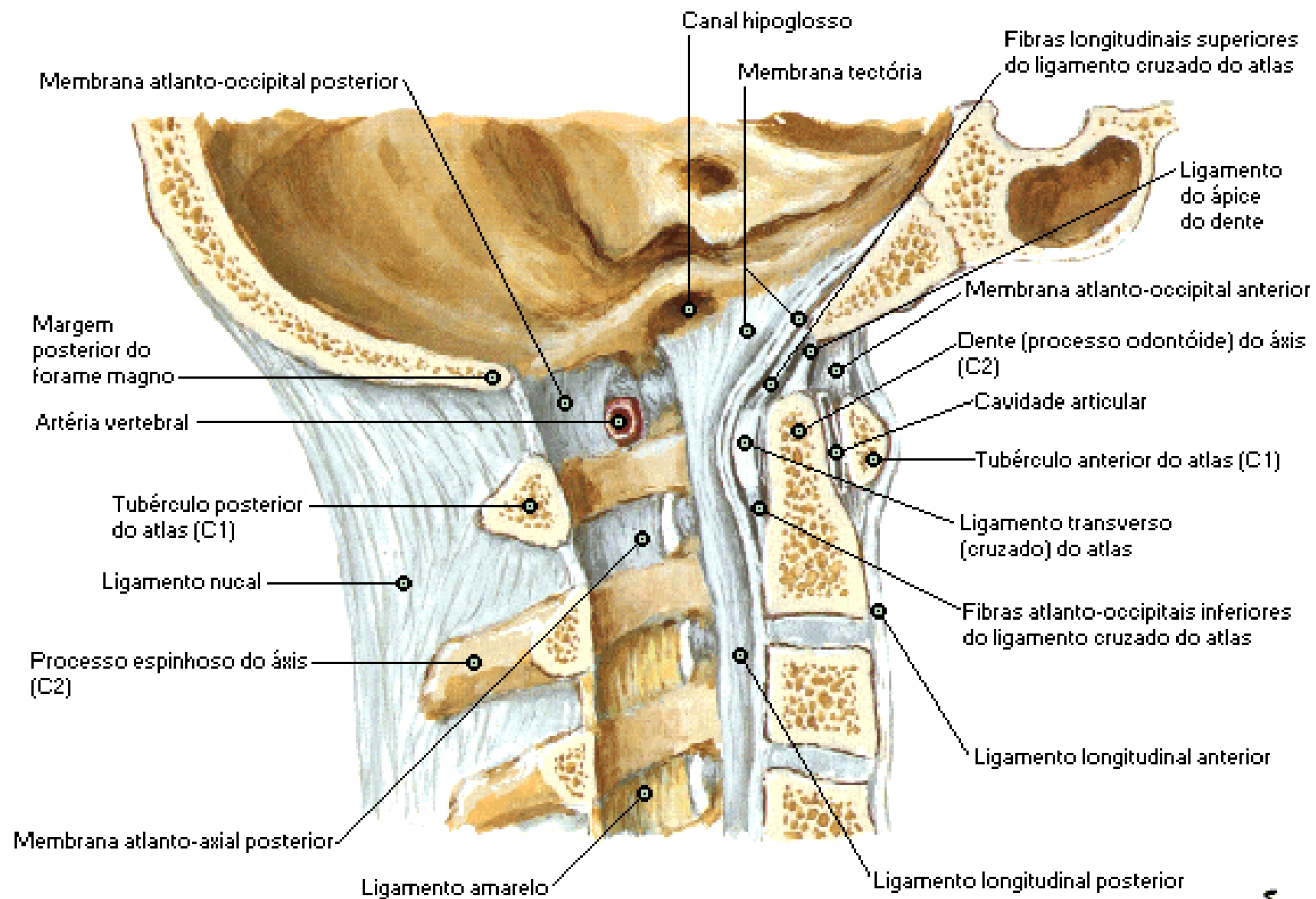
Ligamentos Craniocervicais Internos

Ligamento cruciforme removido, mostrando os ligamentos mais profundos: vista posterior



Articulação atlanto-axial mediana: vista superior

Articulação Atlanto-occipital

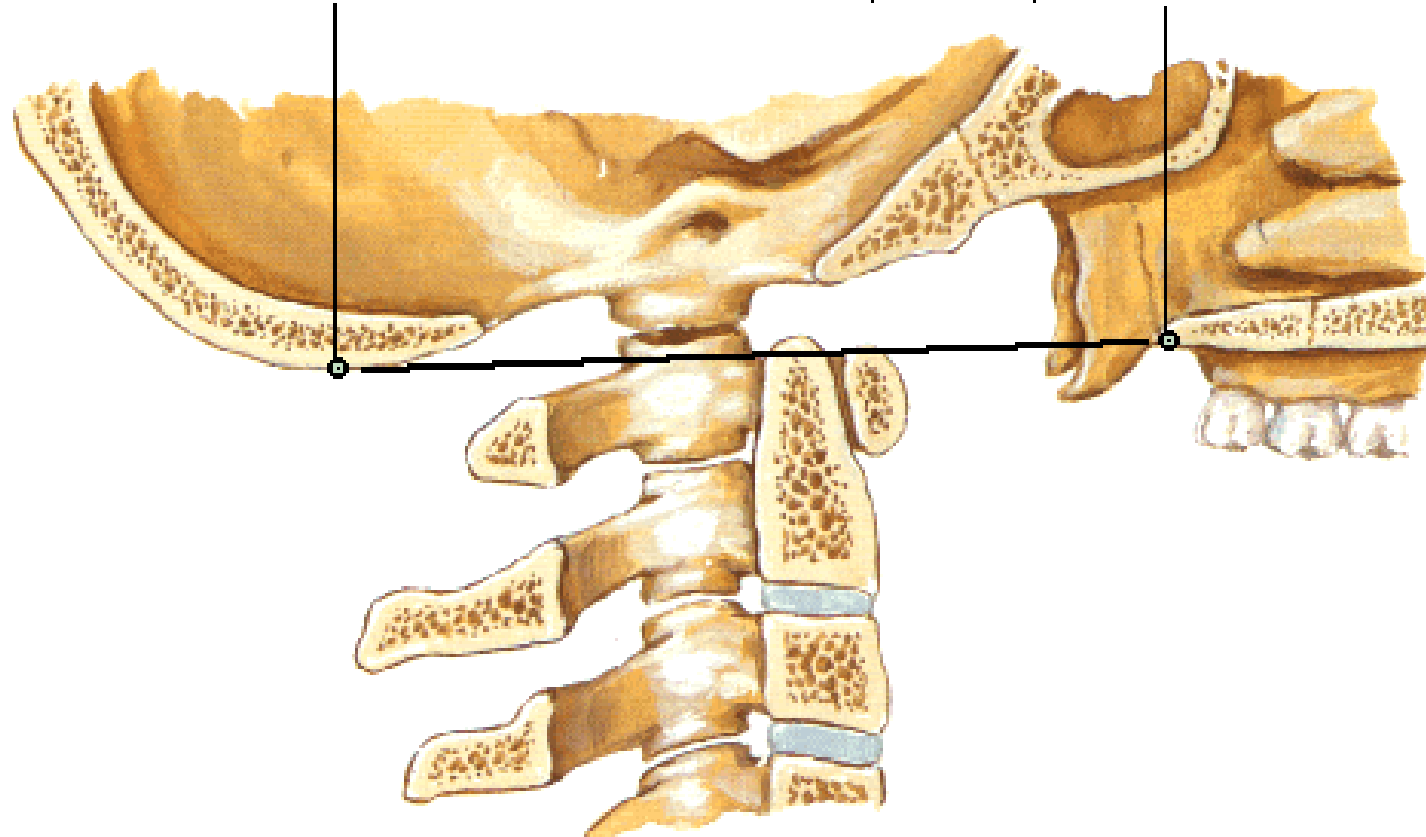


Articulação Atlanto-occipital

Linha de McGregor

Nível mais inferior do osso occipital

Extremidade posterior do palato duro

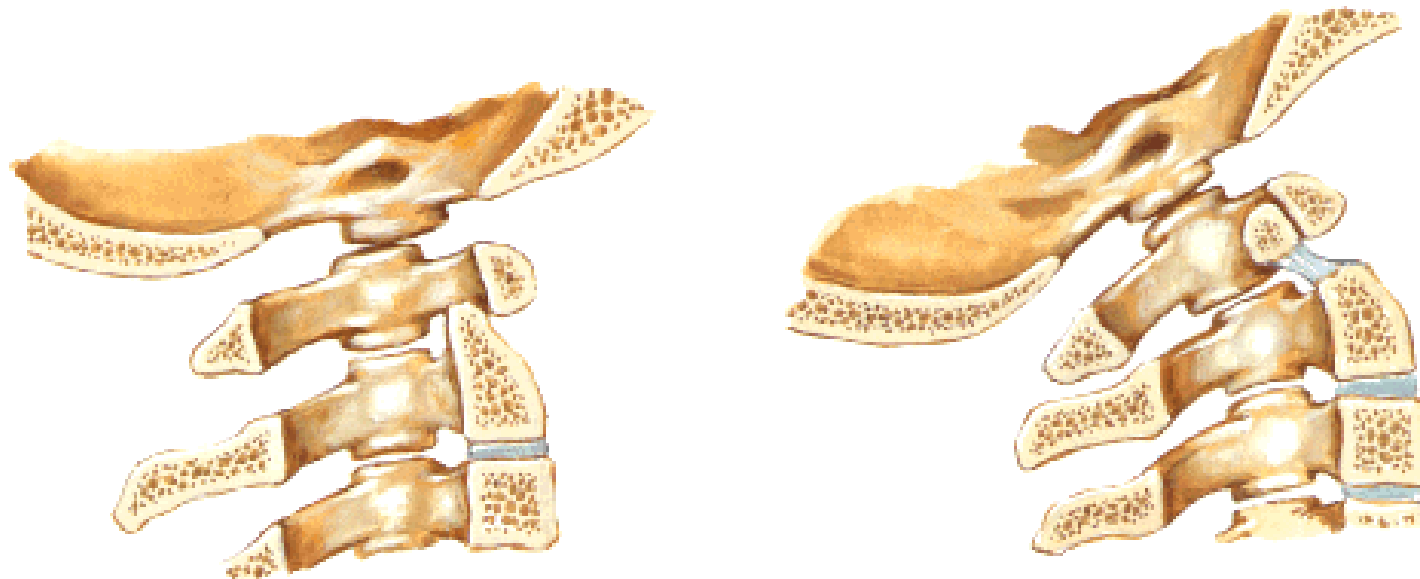


A linha de McGregor, vai da extremidade posterior do palato duro até o ponto inferior do osso occipital. A posição normal mediana da ponta do odontóide é de 1,32 mm acima desta linha, com desvio-padrão de + ou - 2,6 mm, medidos em uma radiografia comum em incidência lateral. A ponta $> 4,5$ mm, acima da linha, é considerada como indicadora de impressão basilar.

Articulação Atlanto-occipital

Anormalidades Odontóides

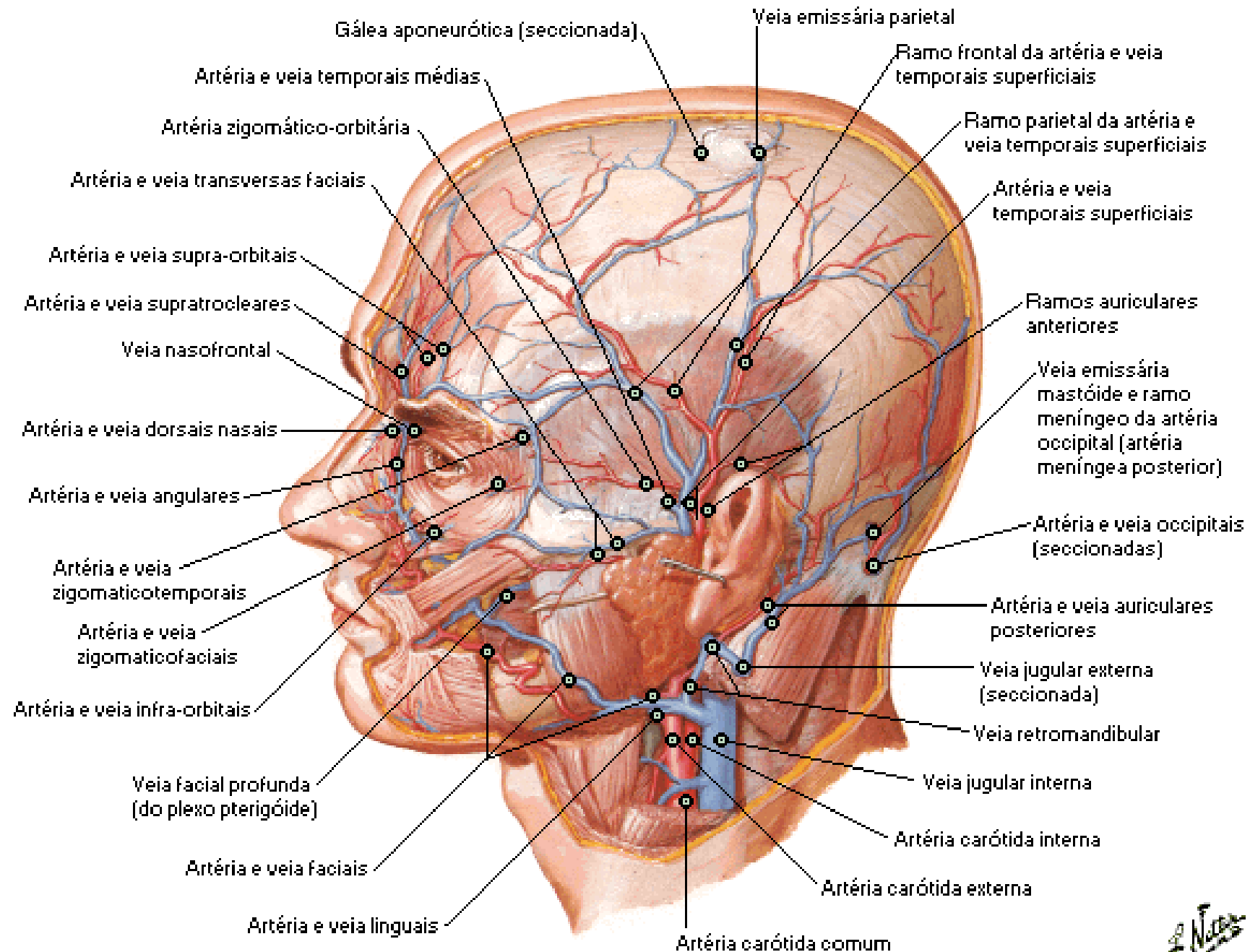
Anormalidades odontóides, mais frequentemente associadas com displasias esqueléticas como as síndromes de Klippel-Feil, de Down ou de Morquio



Dente hipoplásico
(processo odontóide)

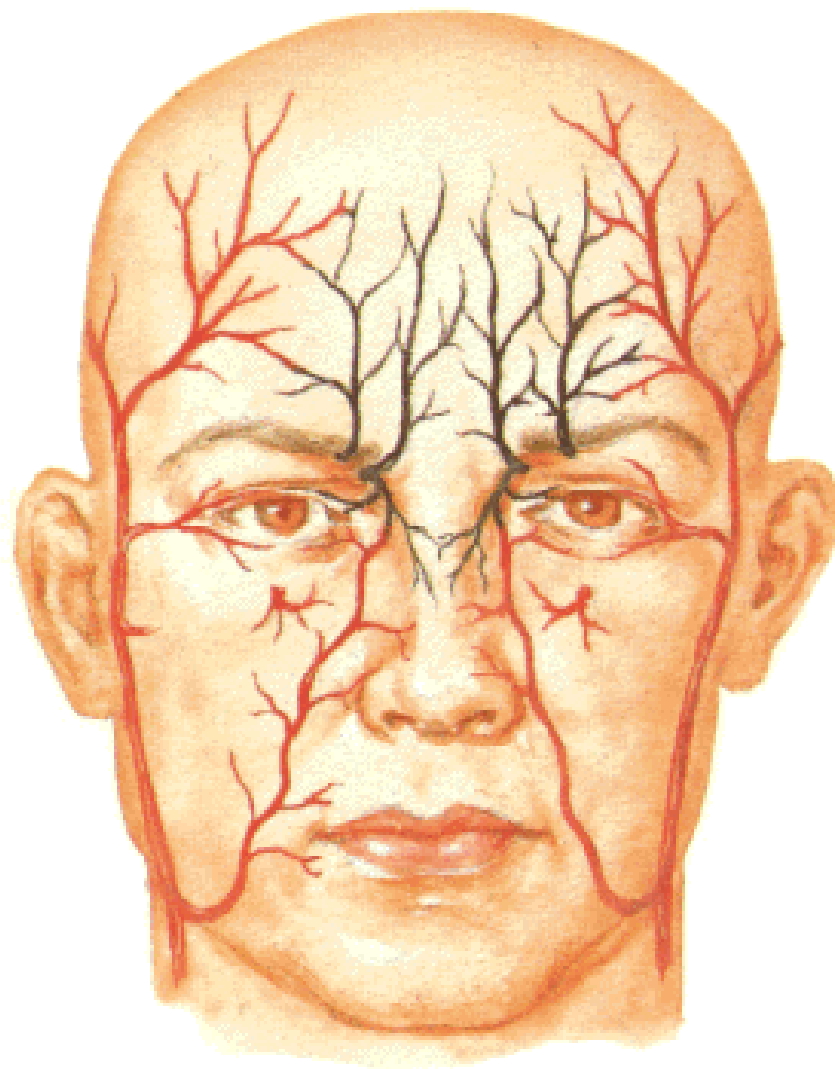
Odontóide com união fibrosa e
estreitamento do canal vertebral
com a cabeça em extensão

Artérias e Veias Superficiais da Face e Couro Cabeludo



Face Superficial

Fontes de Suprimento Arterial



Da artéria carótida interna (via artéria oftálmica) (em preto)

Da artéria carótida externa (em vermelho)

Nervos Cutâneos da Cabeça e Pescoço

Da divisão oftálmica do nervo trigêmeo (V1)

Nervo supra-orbital

Nervo supratroclear

Ramo palpebral do nervo lacrimal

Nervo infratroclear

Ramo nasal externo do nervo etmoidal anterior

Da divisão maxilar do nervo trigêmeo (V2)

Nervo zigomaticotemporal

Nervo infra-orbital

Nervo zigomaticofacial

Da divisão mandibular do nervo trigêmeo (V3)

Nervo mental

Nervo bucal

Nervo auriculotemporal

Ramo auricular do nervo vago (X)

Ramos mediais dos ramos dorsais de nervos espinhais cervicais

Nervo occipital maior (C2)

3º nervo occipital (C3)

4º, 5º, 6º, 7º e 8º nervos sucessivamente inferiores

Ramos do plexo cervical

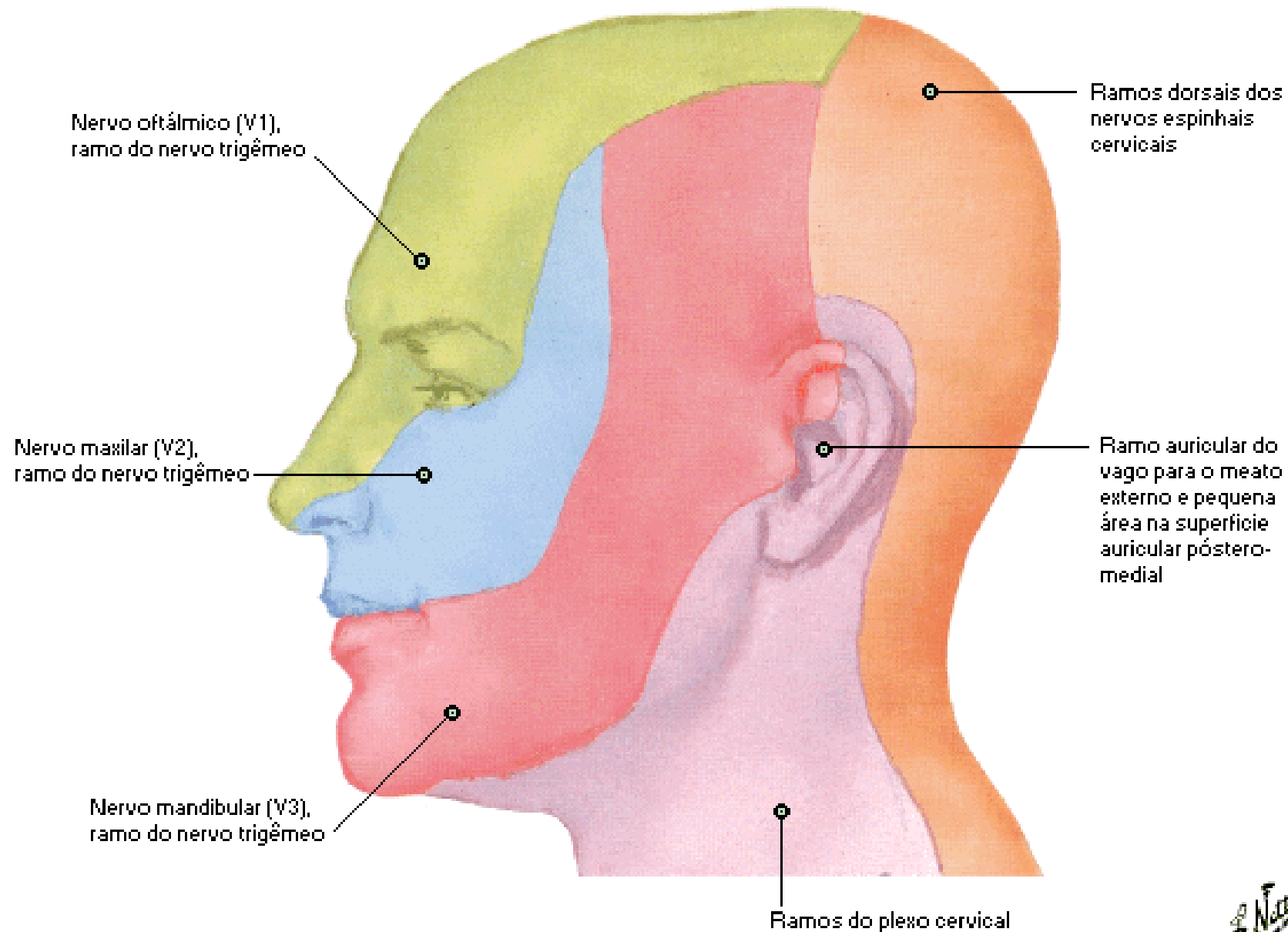
Nervo occipital menor (C2, 3)

Nervo auricular magno (C2, 3)

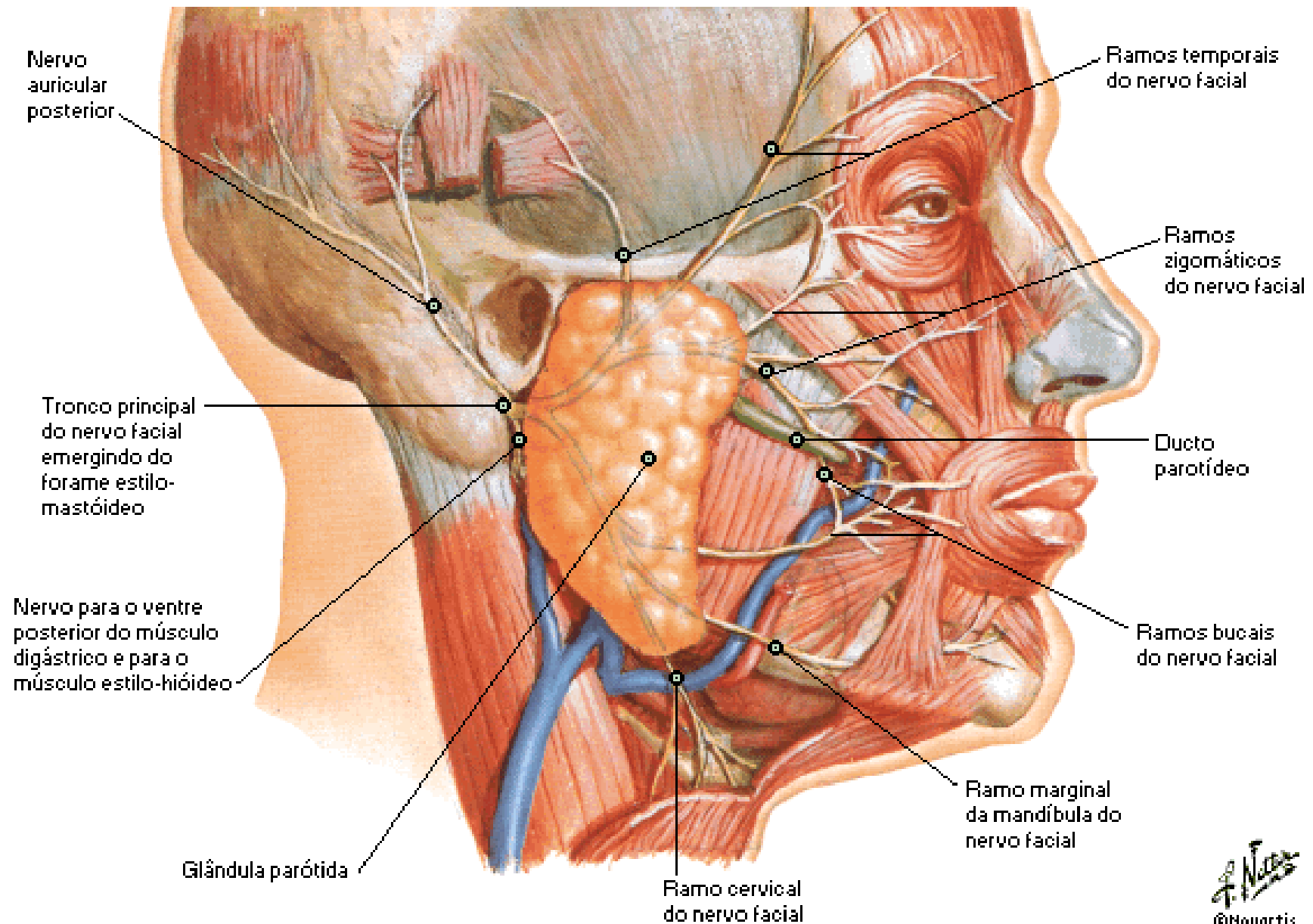
Nervos supraclaviculares (C3, 4)

Nervo cervical transverso (C2, 3)

Dermátomos da Cabeça e do Pescoço

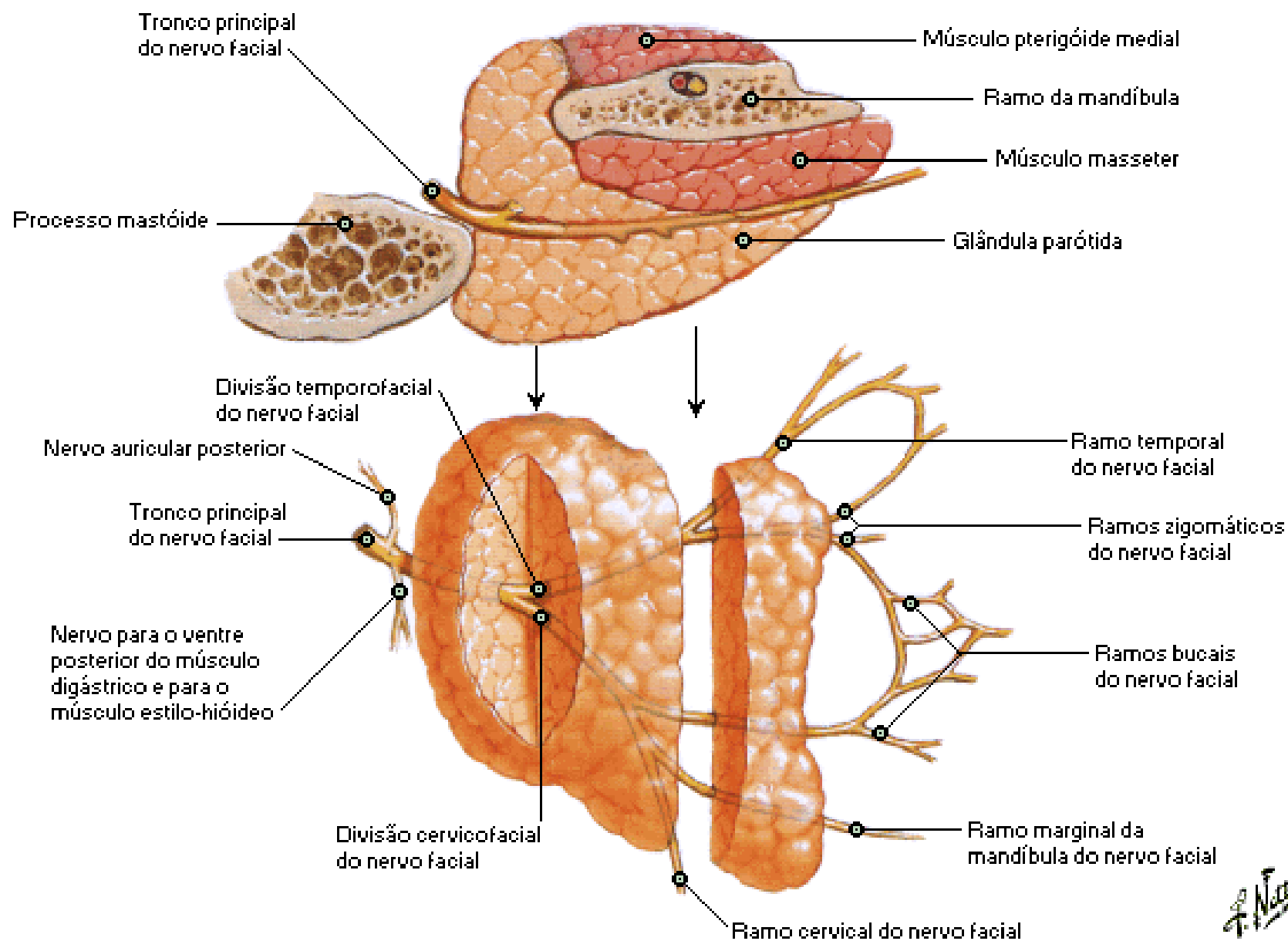


Ramos do Nervo Facial e Glândula Parótida



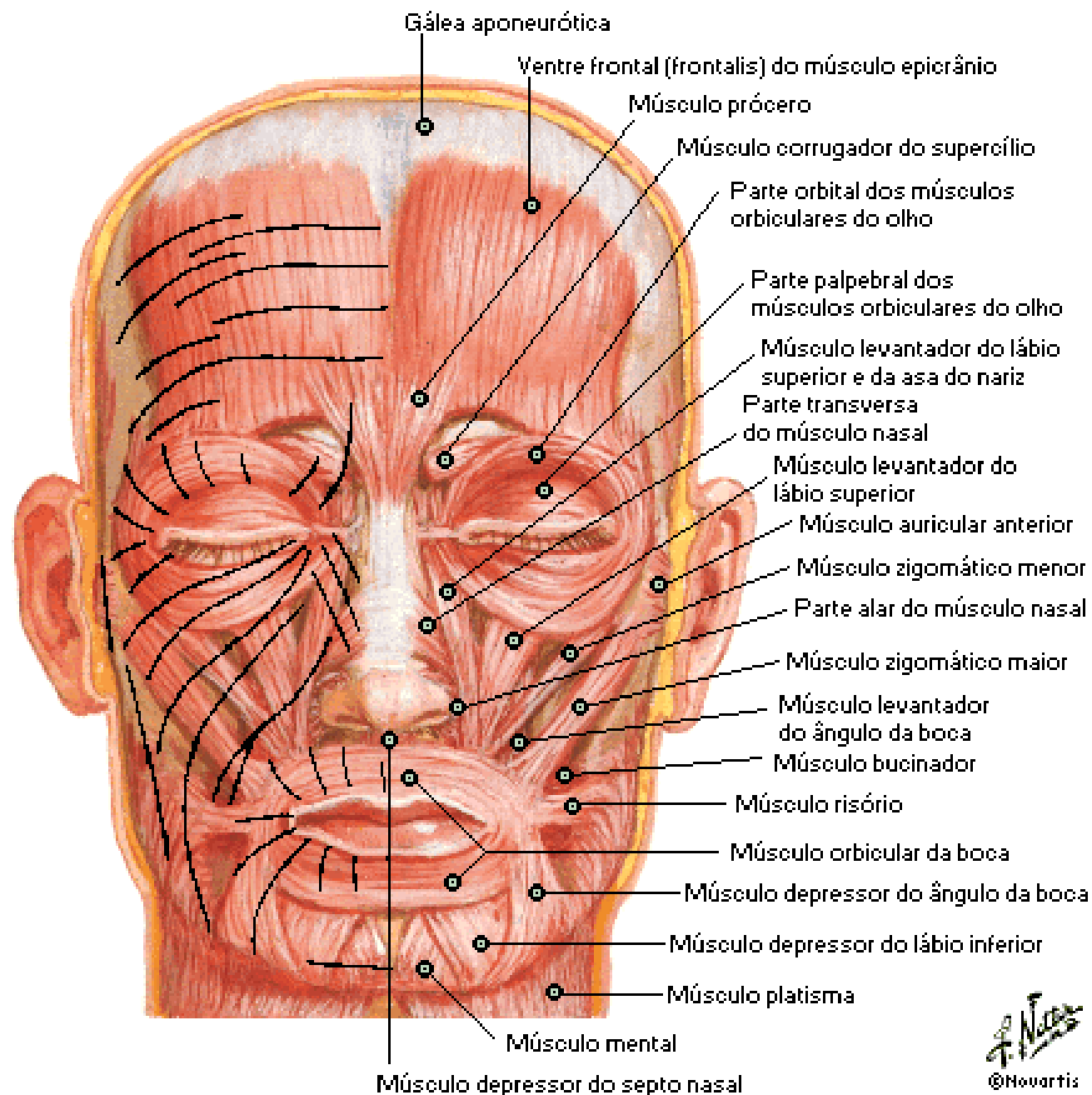
Ramos do Nervo Facial e Glândulas Parótida

Seccionados



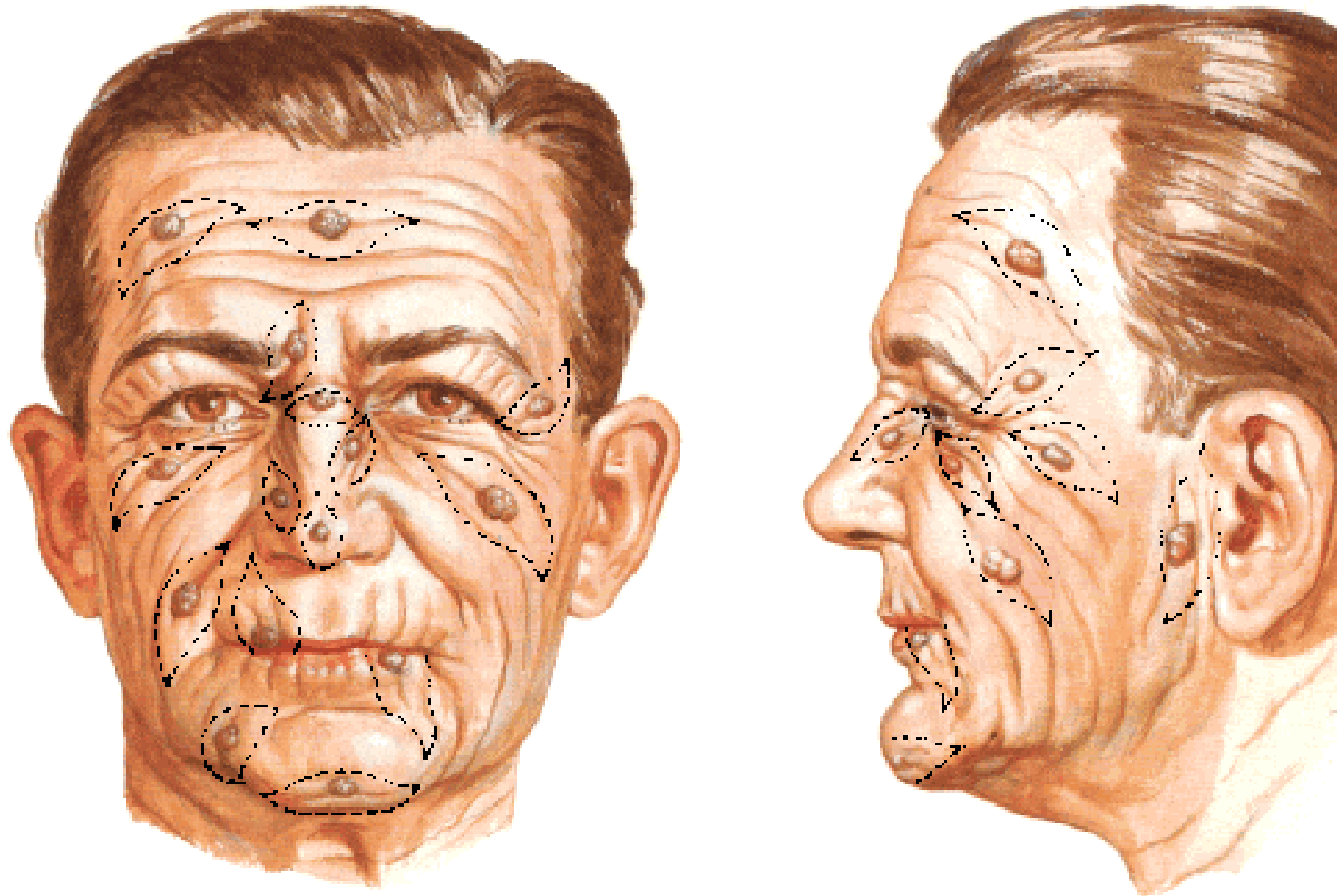
Músculos da Expressão Facial

Vista Anterior



Face Superficial

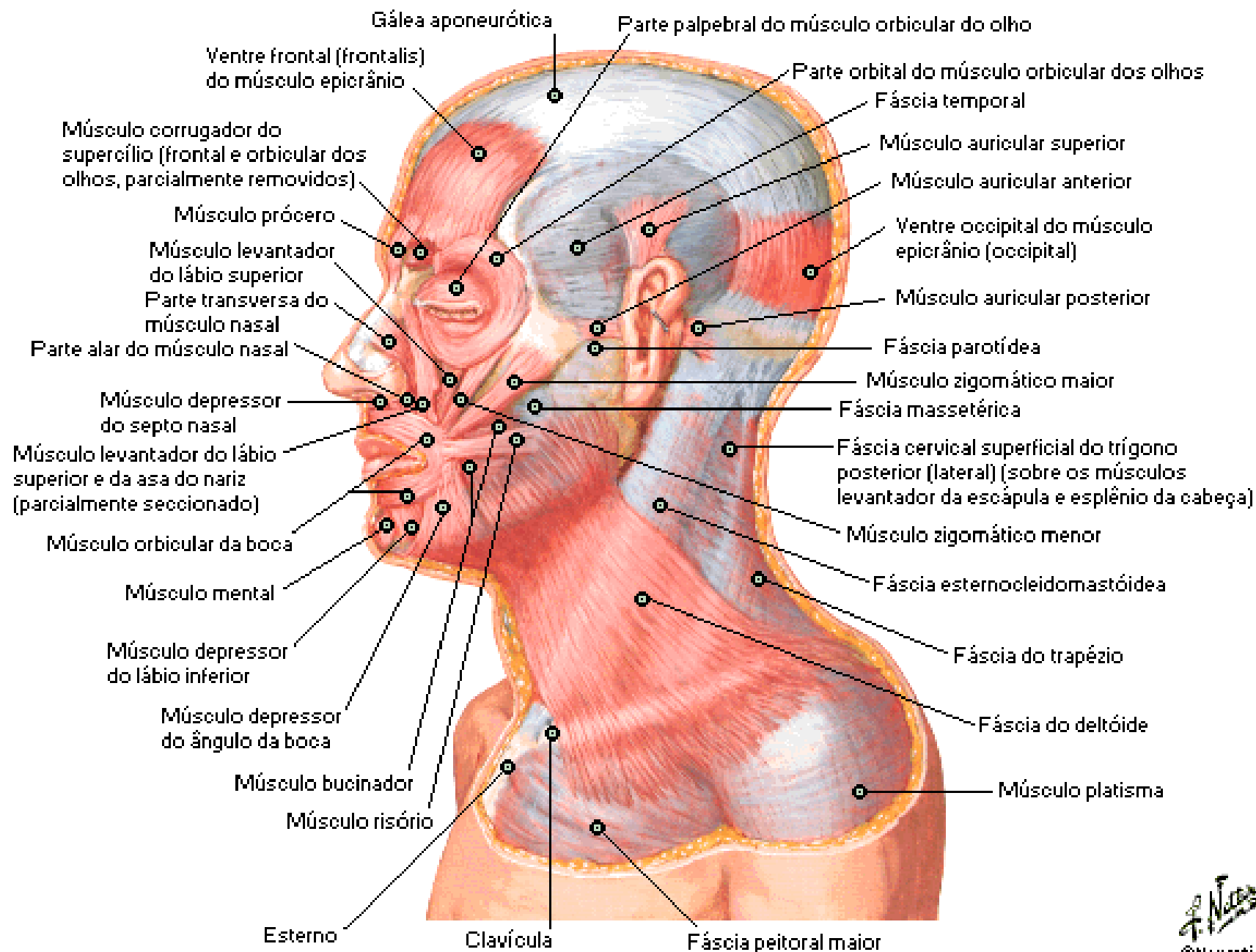
Trajeto das Linhas de Força Faciais



O trajeto das linhas de força faciais é transversal à direção das fibras dos músculos faciais. As incisões elípticas para remoção de tumores cutâneos devem ser conforme a direção das linhas de força

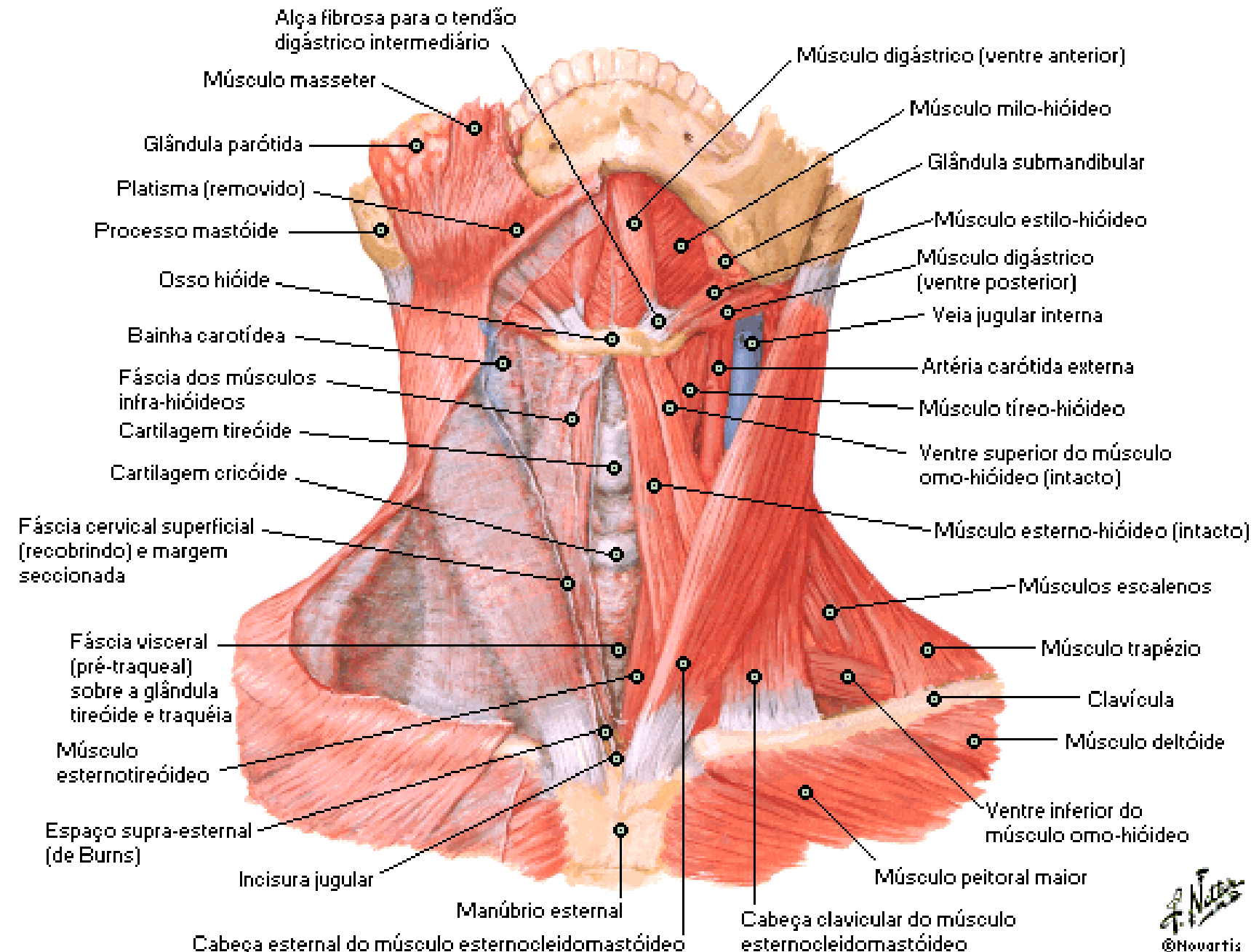
Músculos da Expressão Facial

Vista Lateral

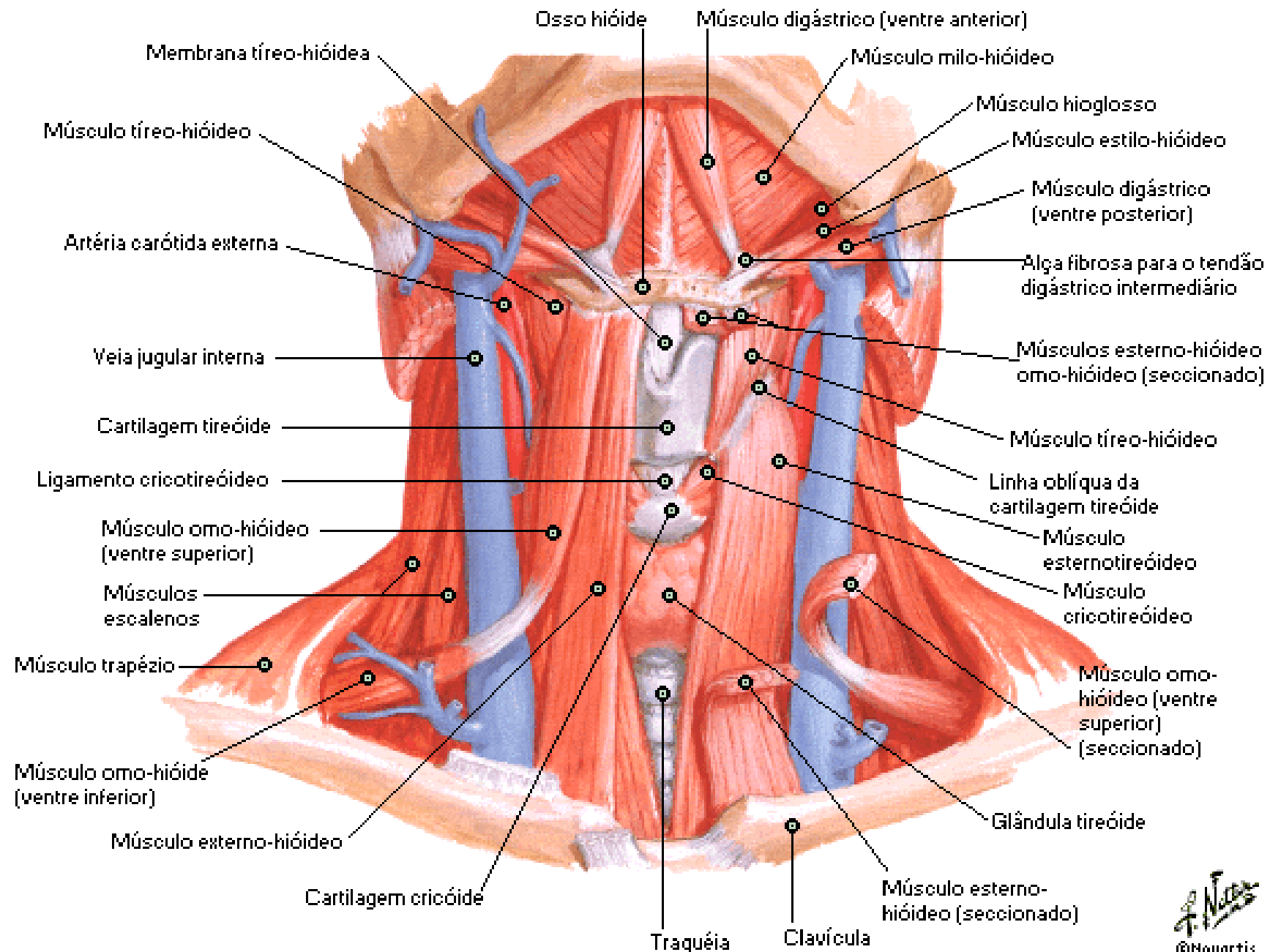


Músculos do Pescoço

Vista Anterior

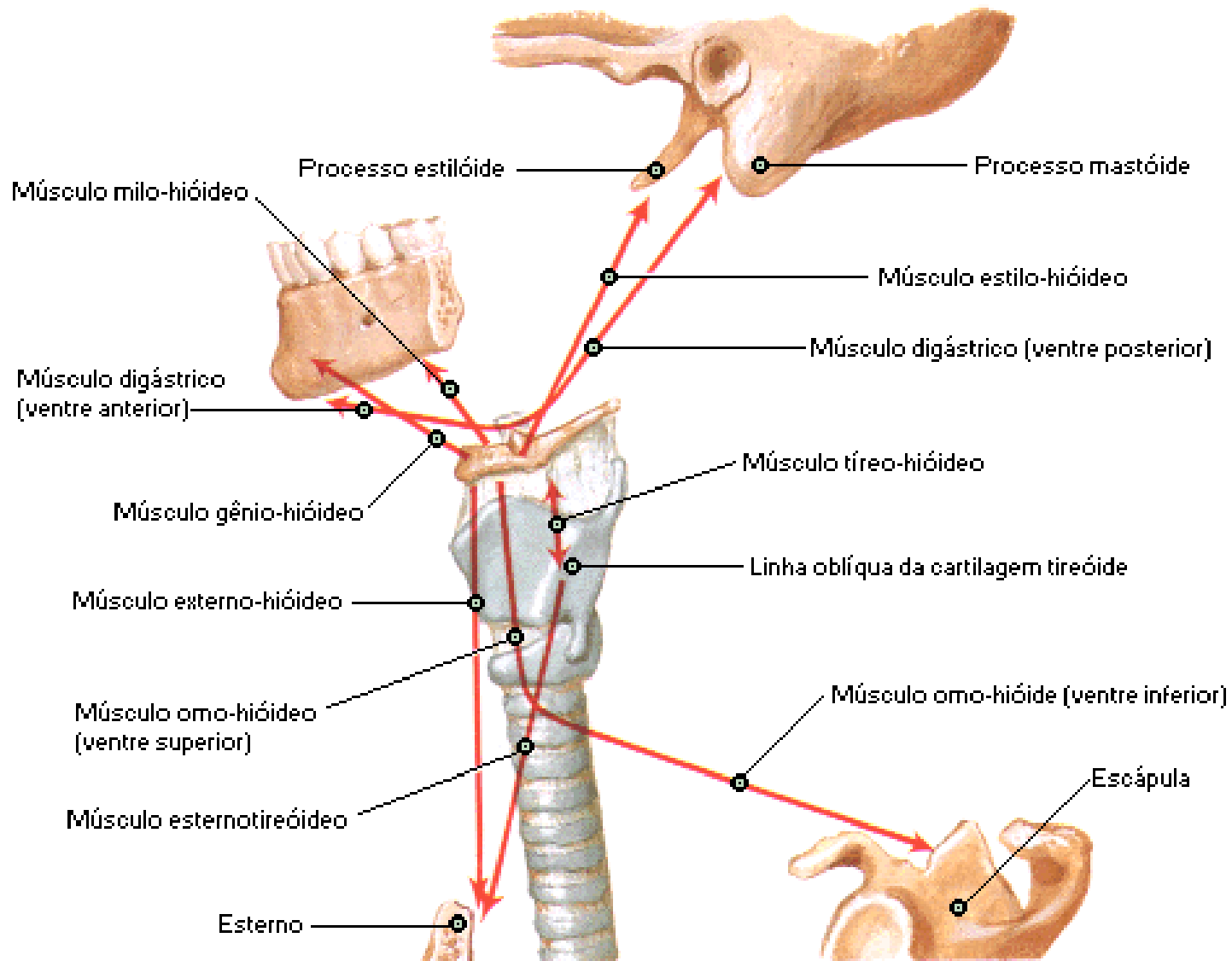


Músculos Infra-hióideos e Supra-hióideos

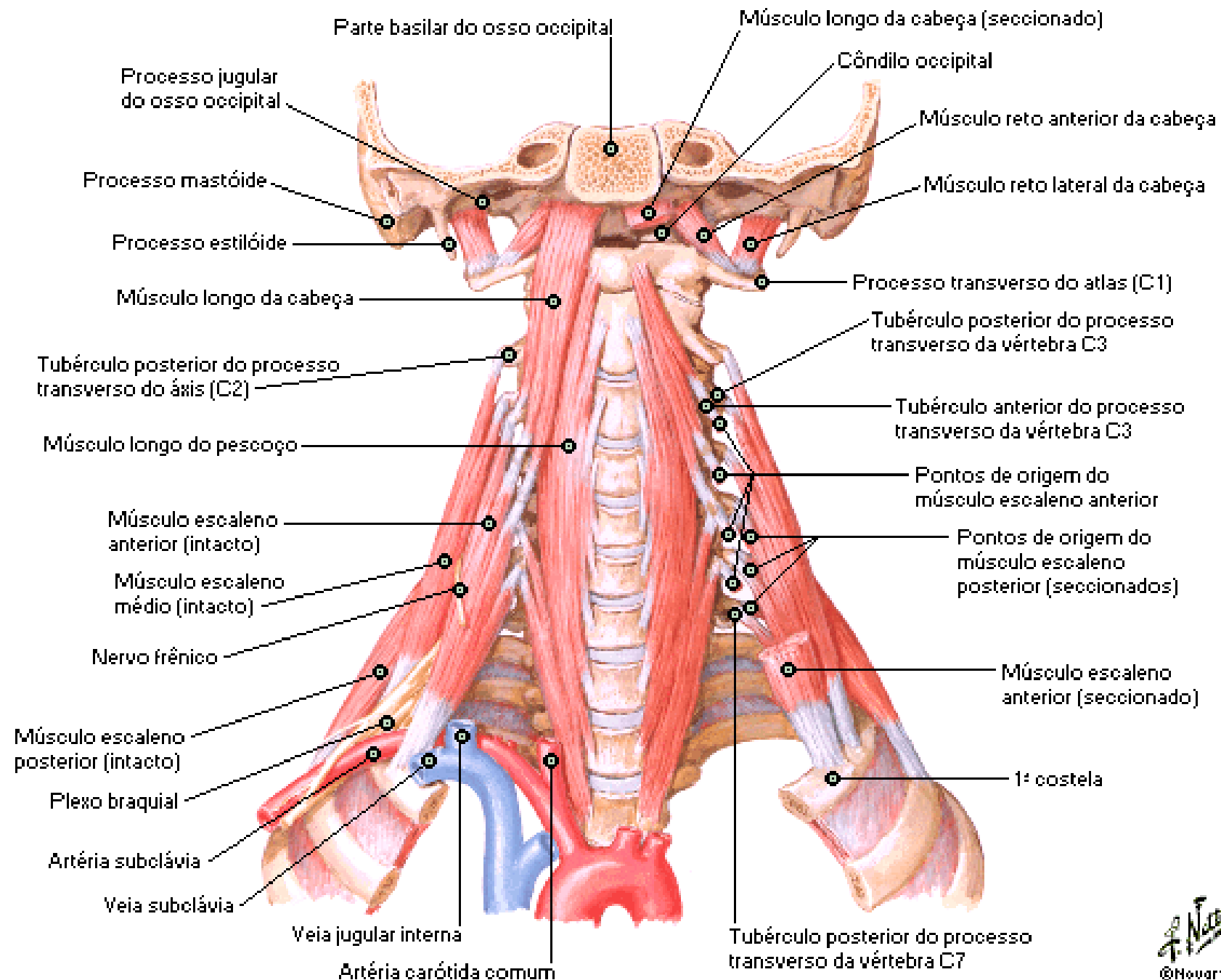


Músculos Infra-hióideos e Supra-hióideos, Ações

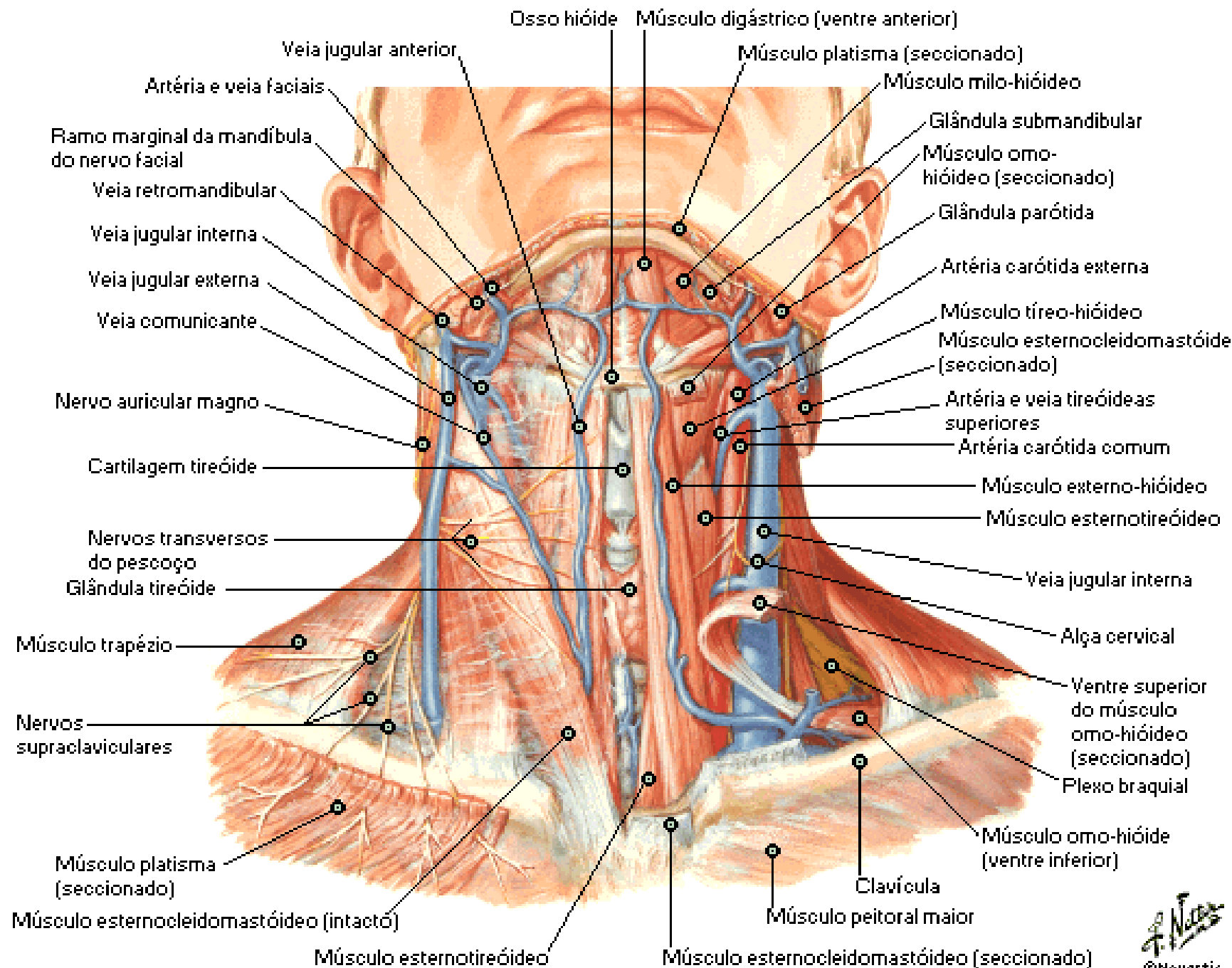
Esquema



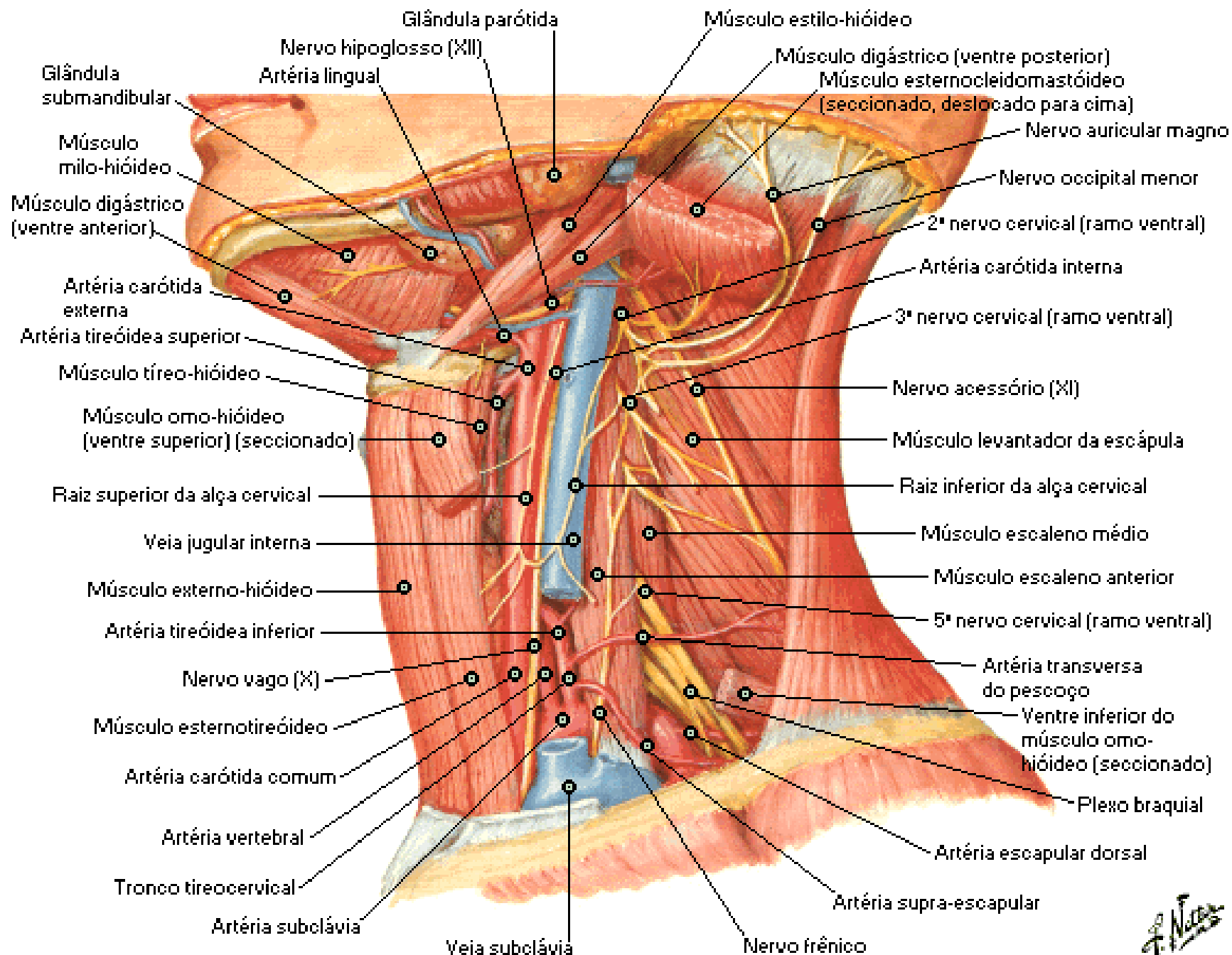
Músculos Escalenos e Pré-vertebrais



Veias Superficiais e Nervos Cutâneos do Pescoço



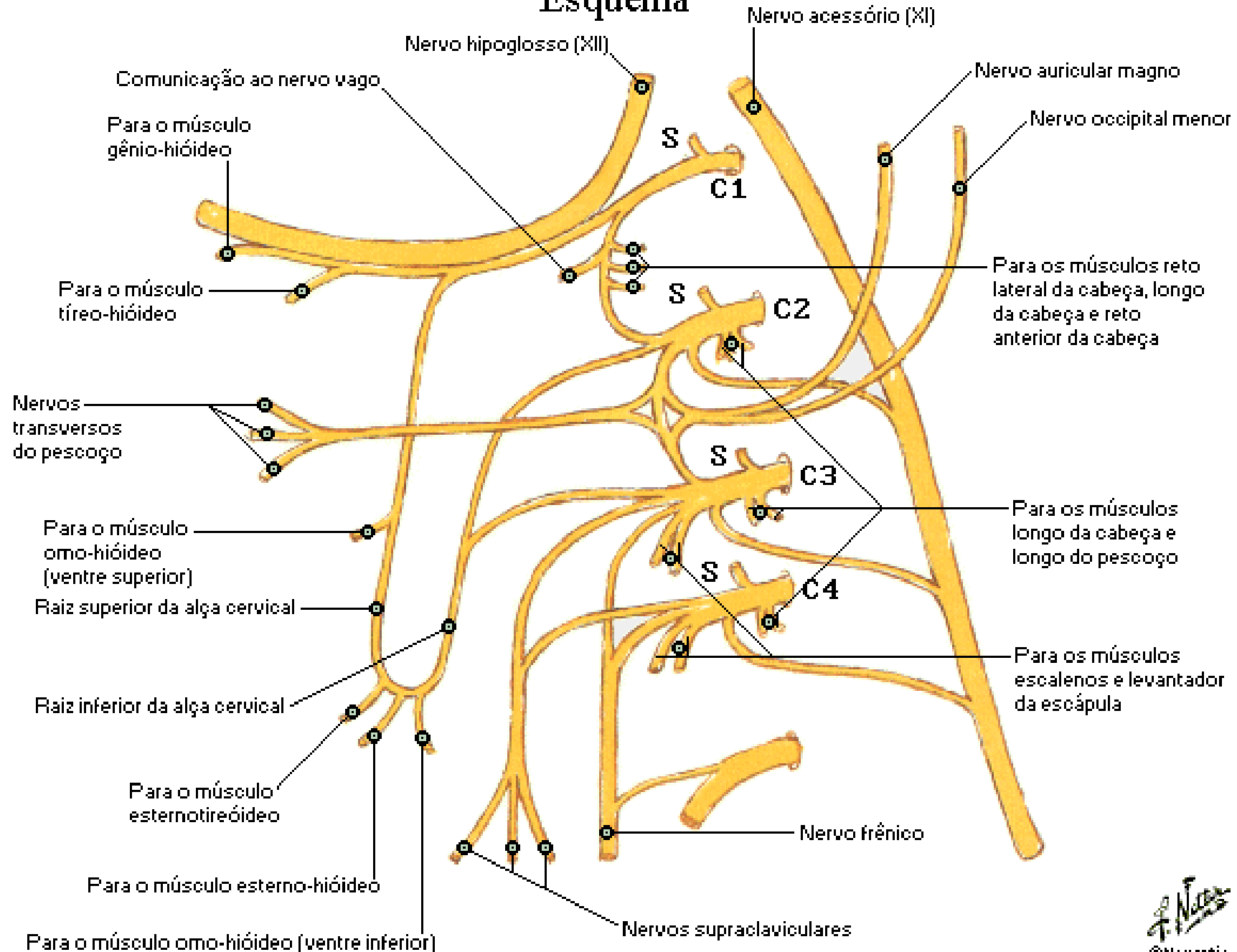
Plexo Cervical



S = ramo cinzento para o gânglio simpático superior

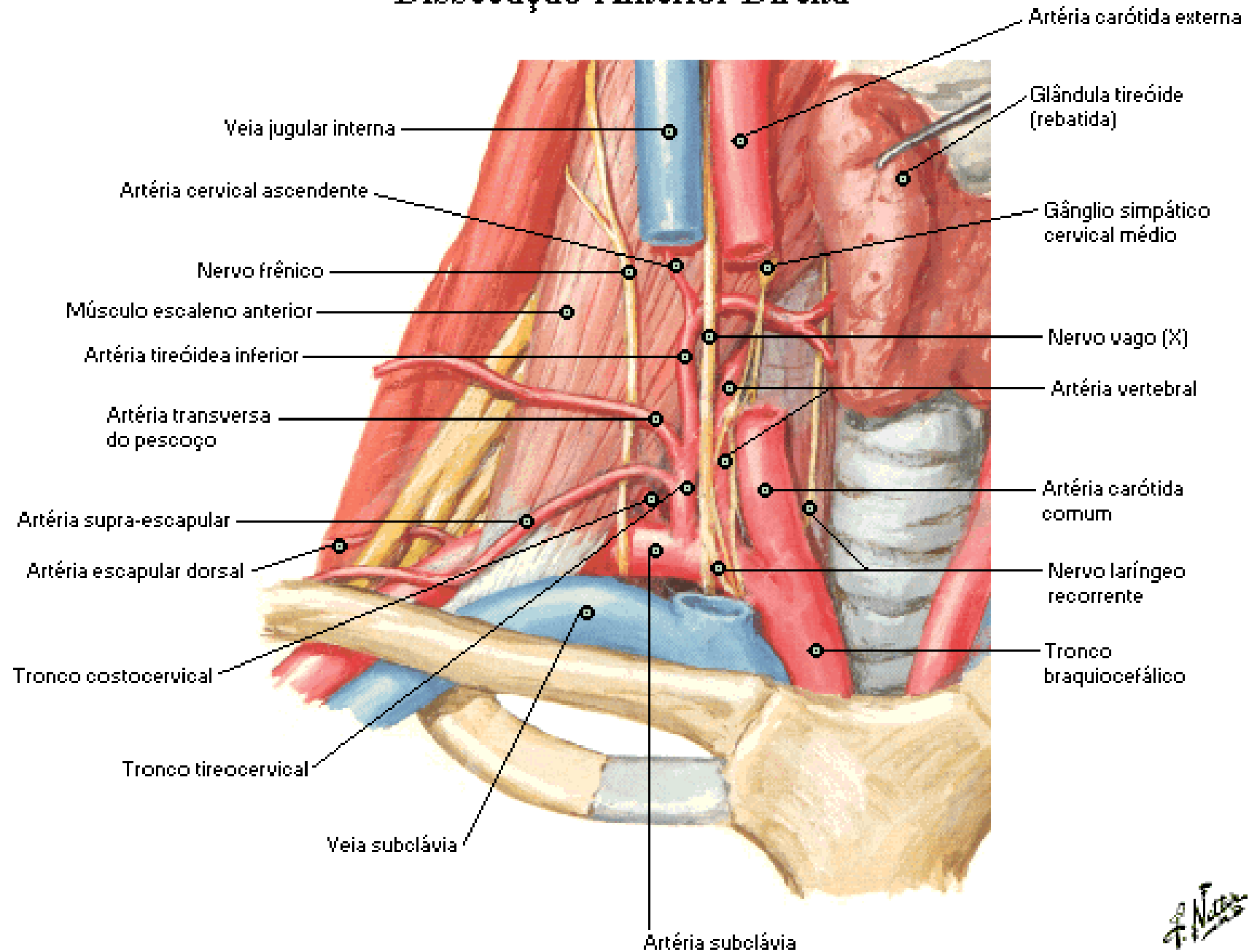
Plexo Cervical

Esquema



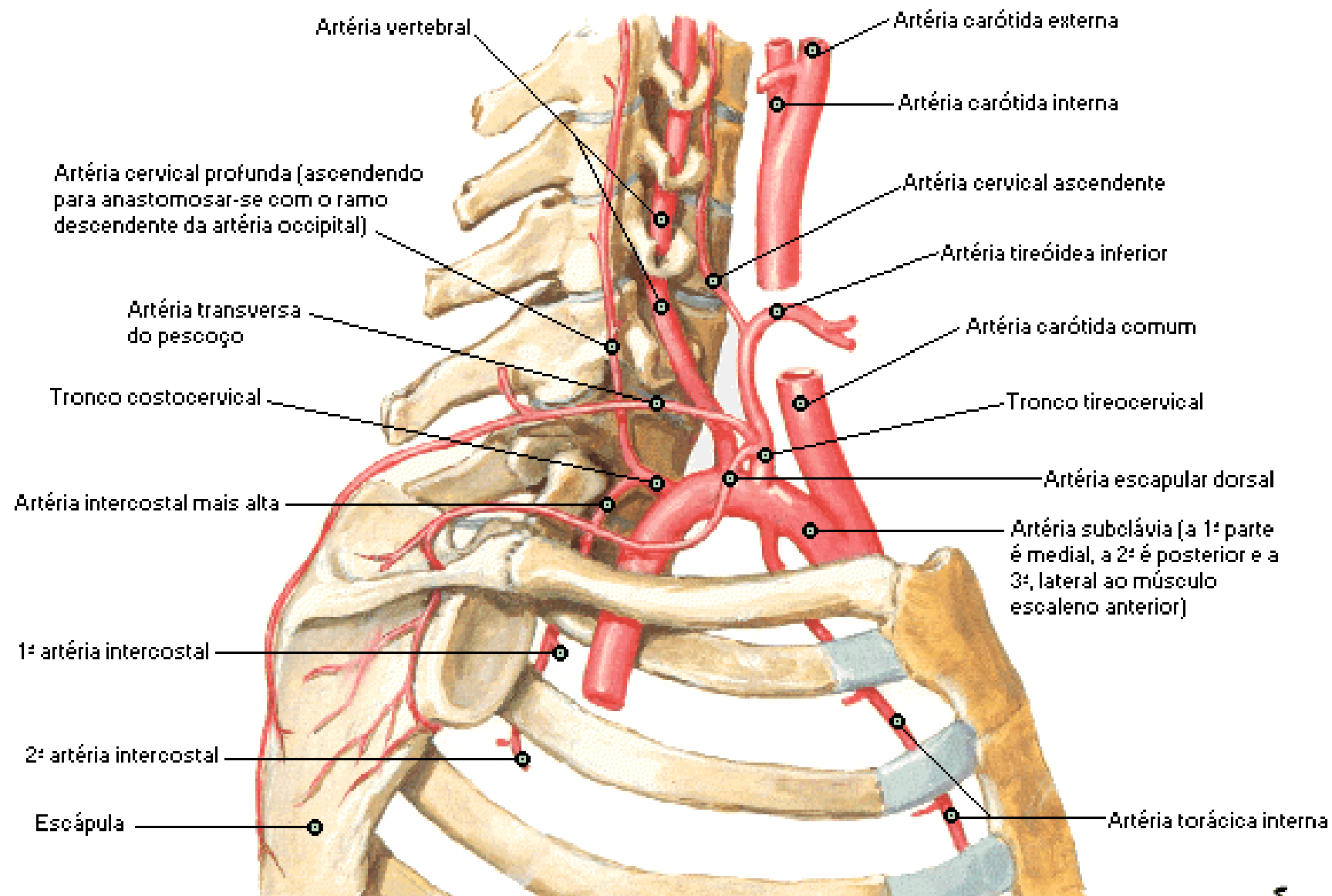
Artéria Subclávia

Dissecação Anterior Direita



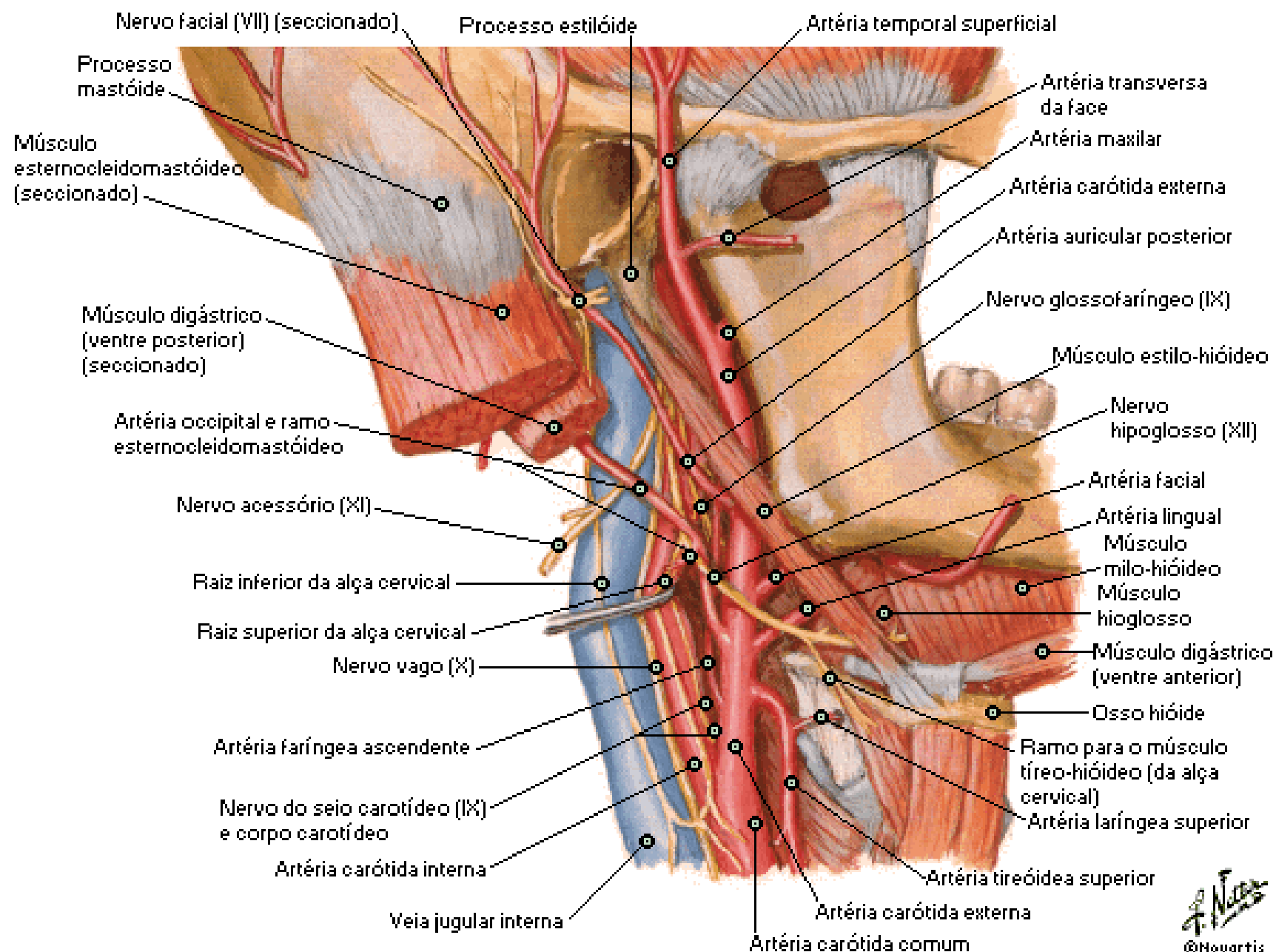
Artéria Subclávia

Vista Esquemática Lateral Direita



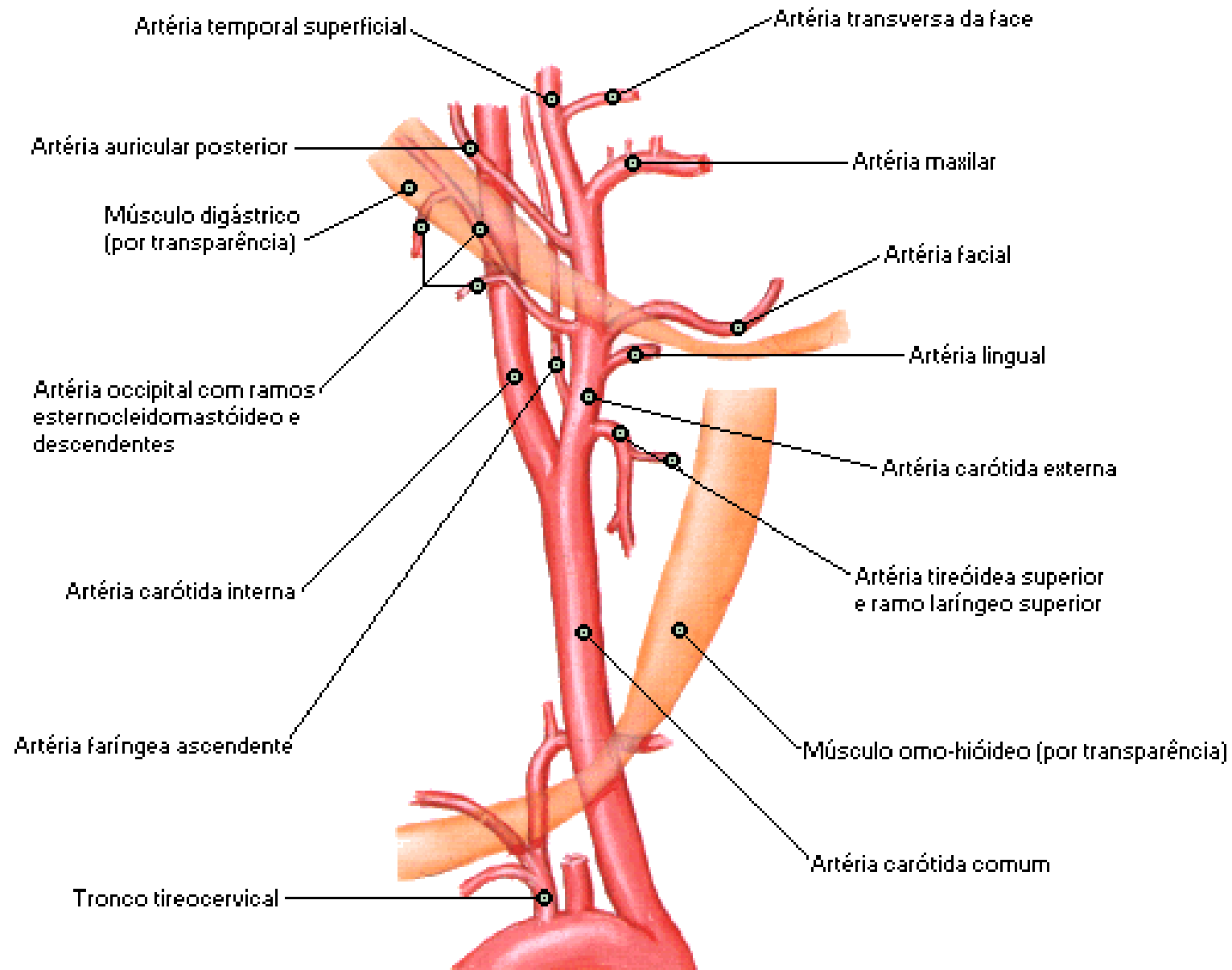
Artérias Carótidas - Fossa Parotídea

Dissecação Lateral Direita



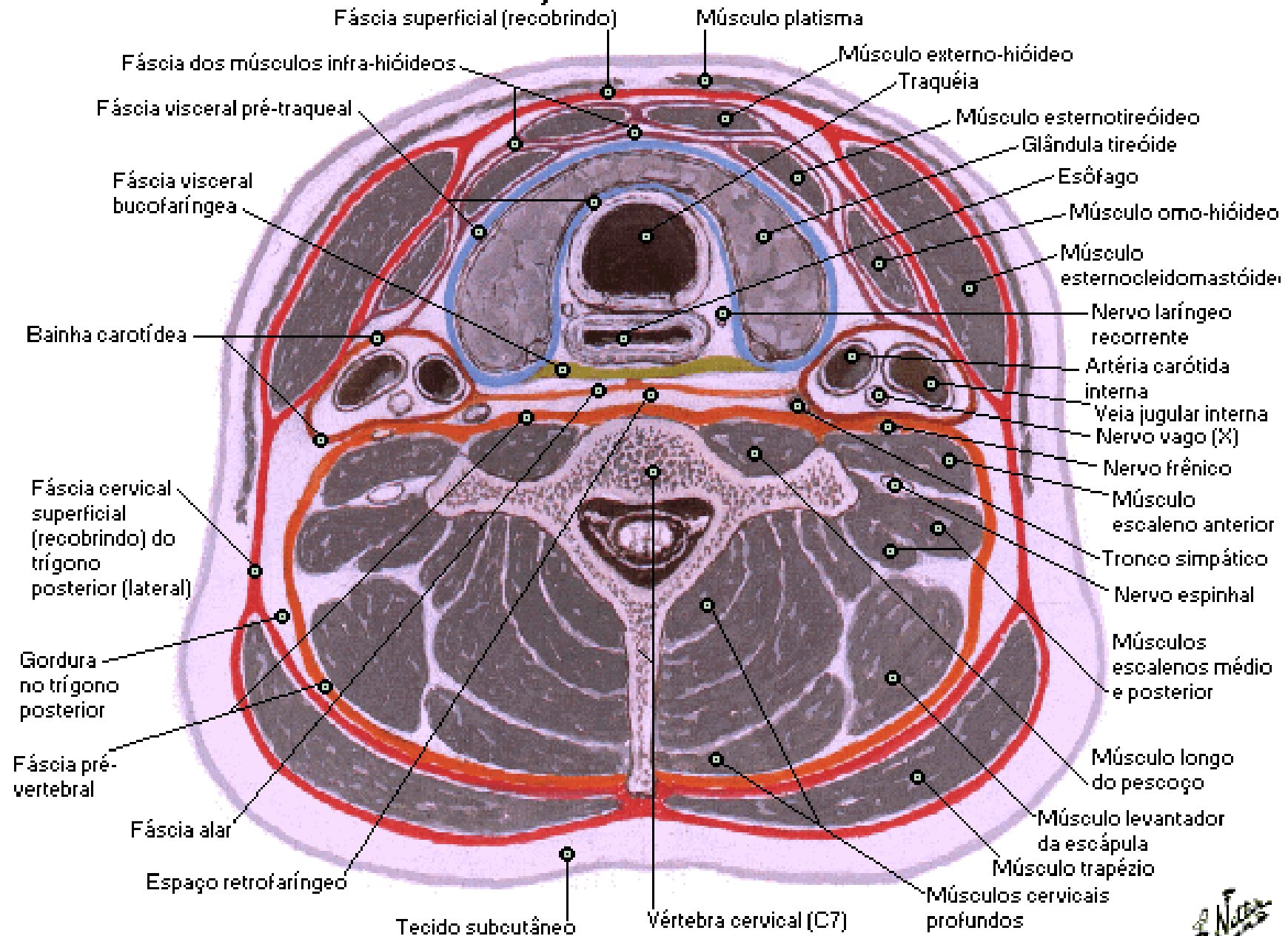
Artéria Carótida Externa e Ramos

Esquema



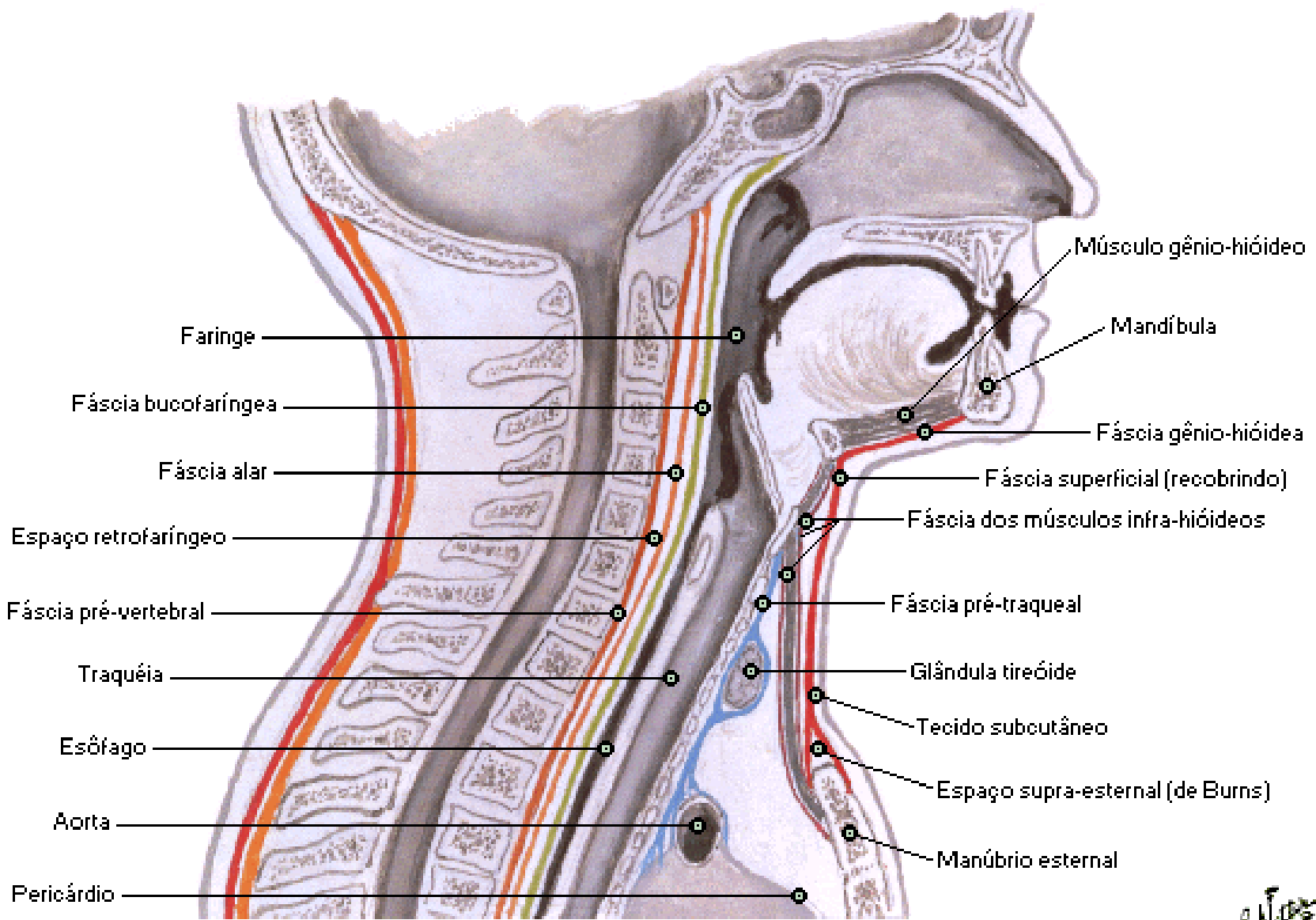
Fáscias do Pescoço

Secção Transversal



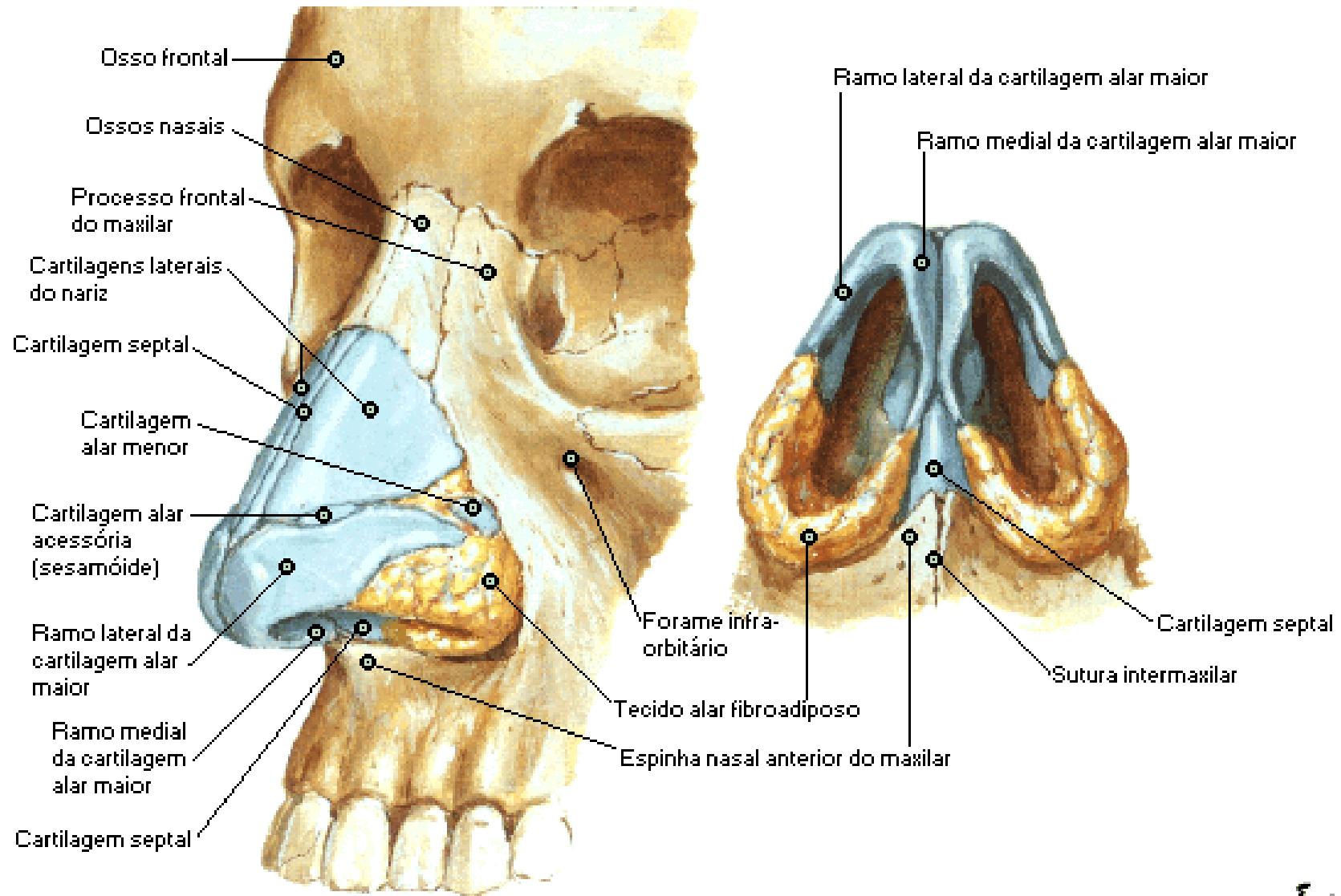
Fáscia do Pescoço

Secção Sagital



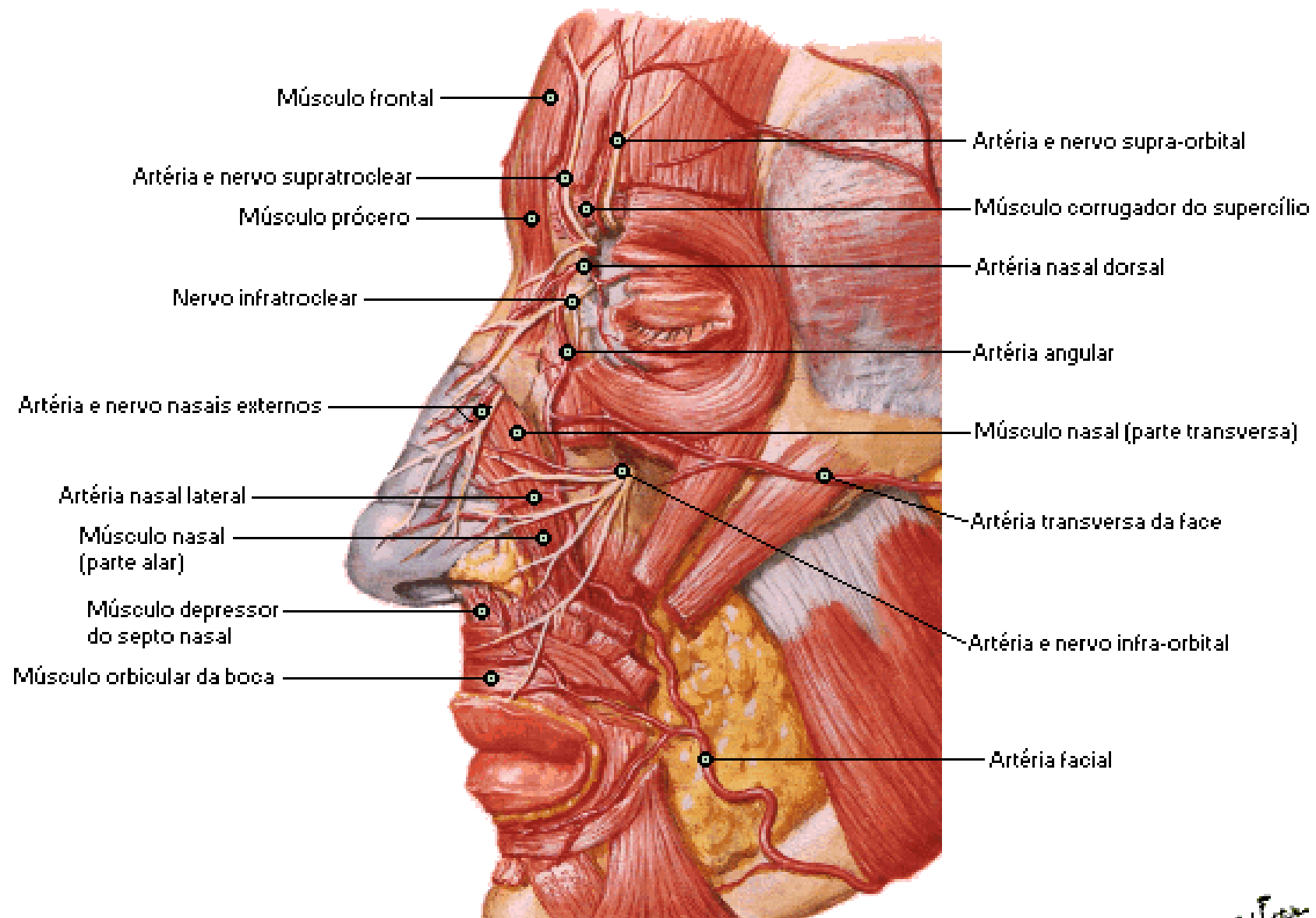
Nariz [Esqueleto]

Vistas Ântero-lateral e Inferior

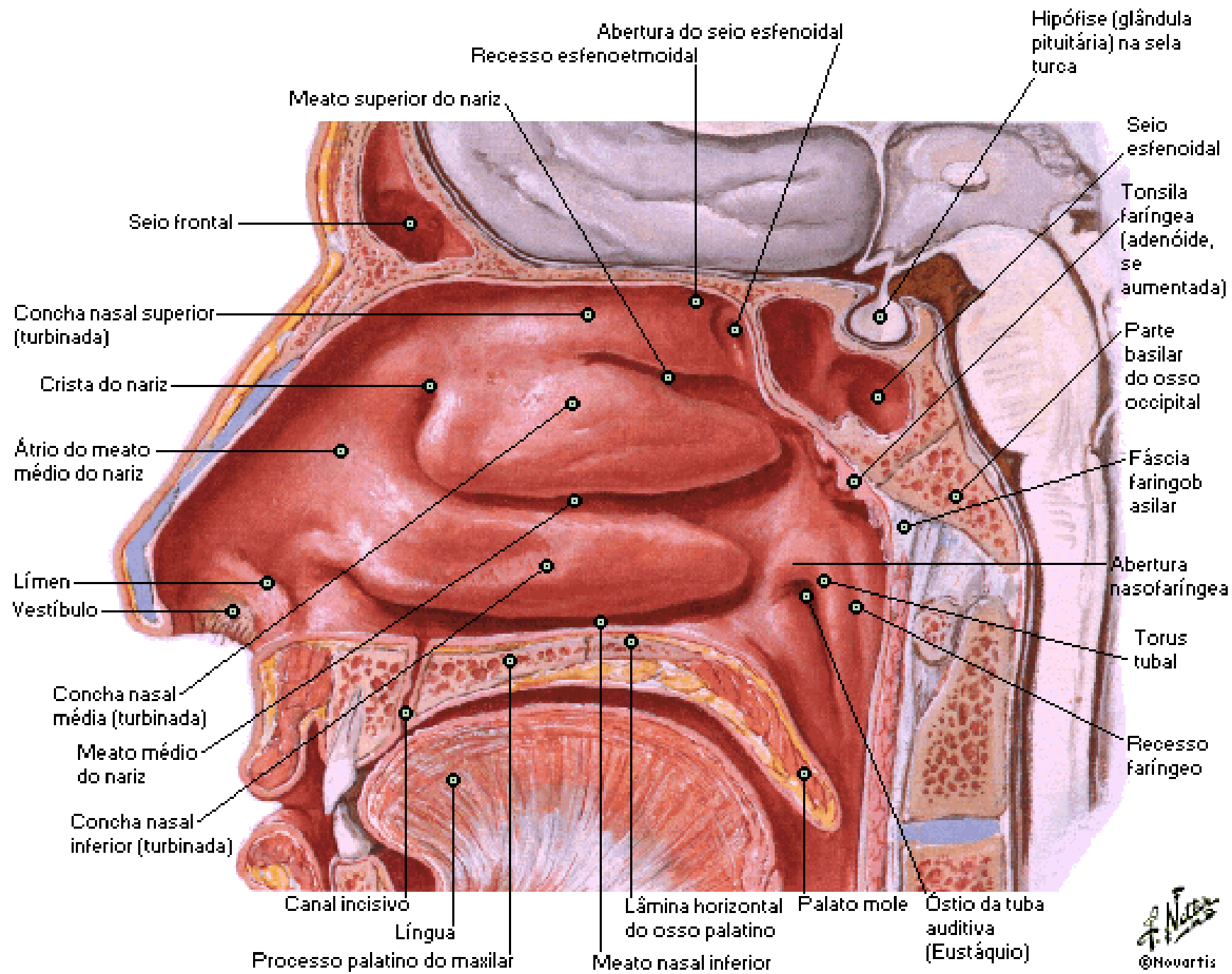


Nariz [Esqueleto] in Situ

Vista Lateral

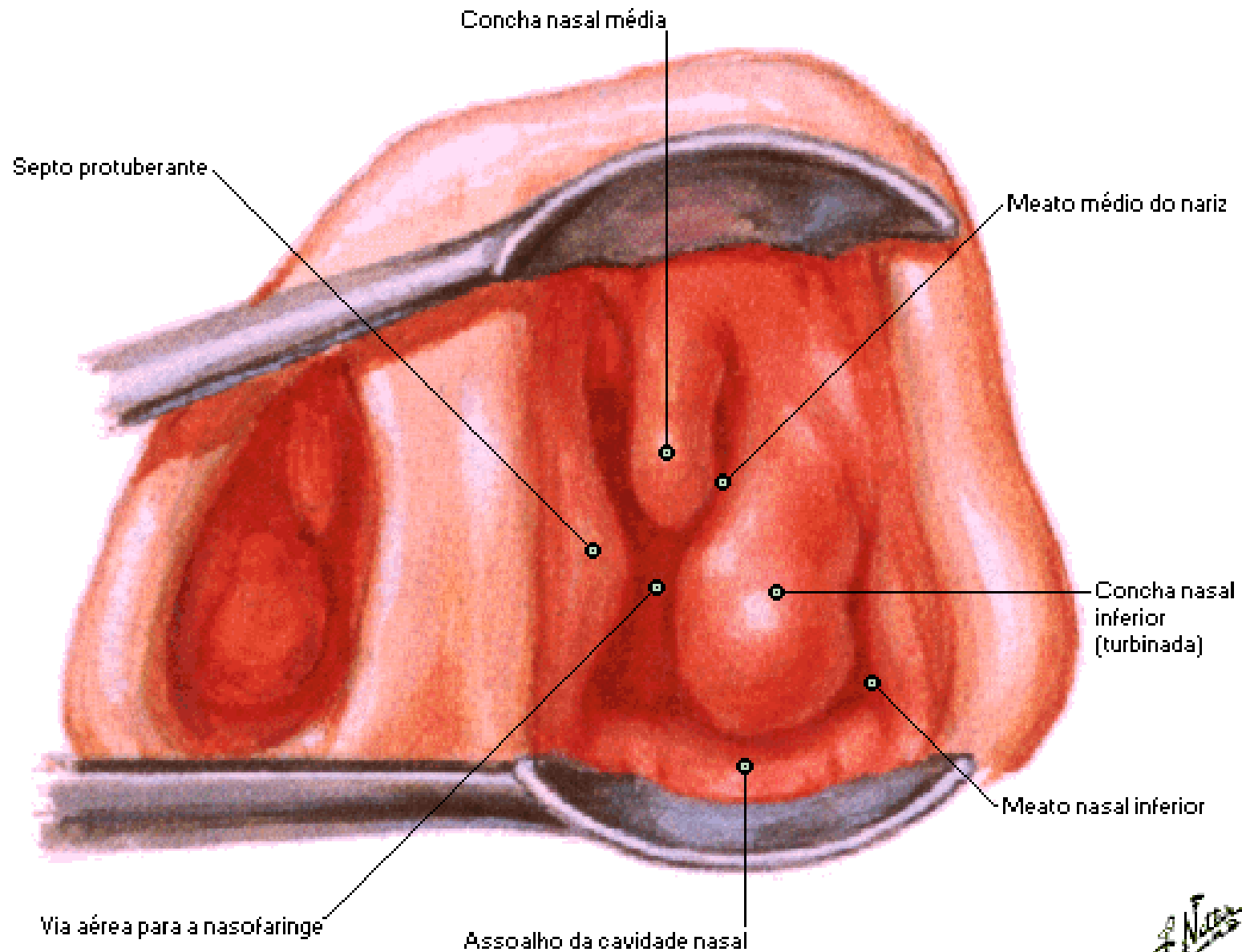


Cavidade Nasal - Parede Lateral

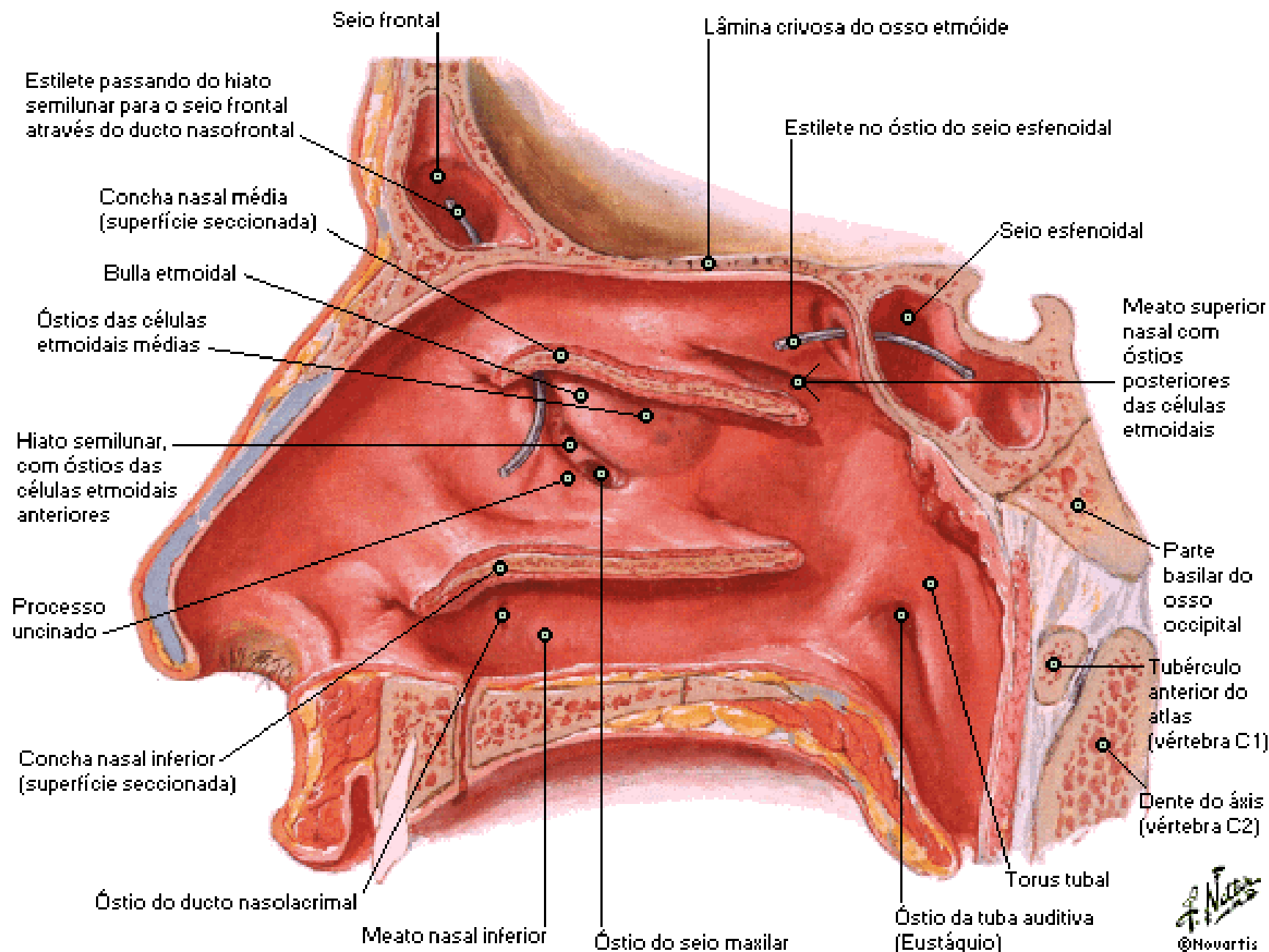


Cavidade Nasal

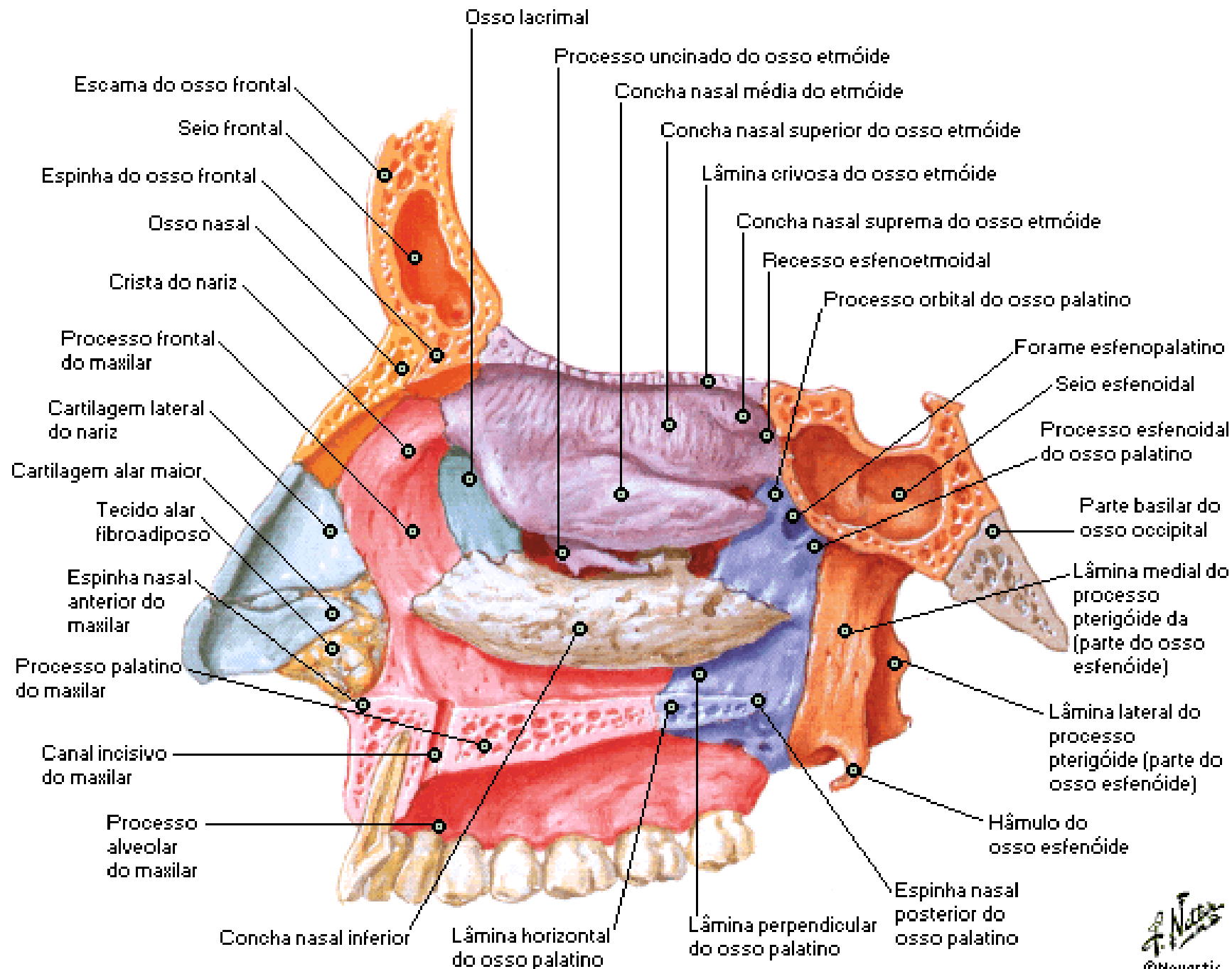
Vista Especular



Parede Lateral do Nariz - Concha Nasal Removida

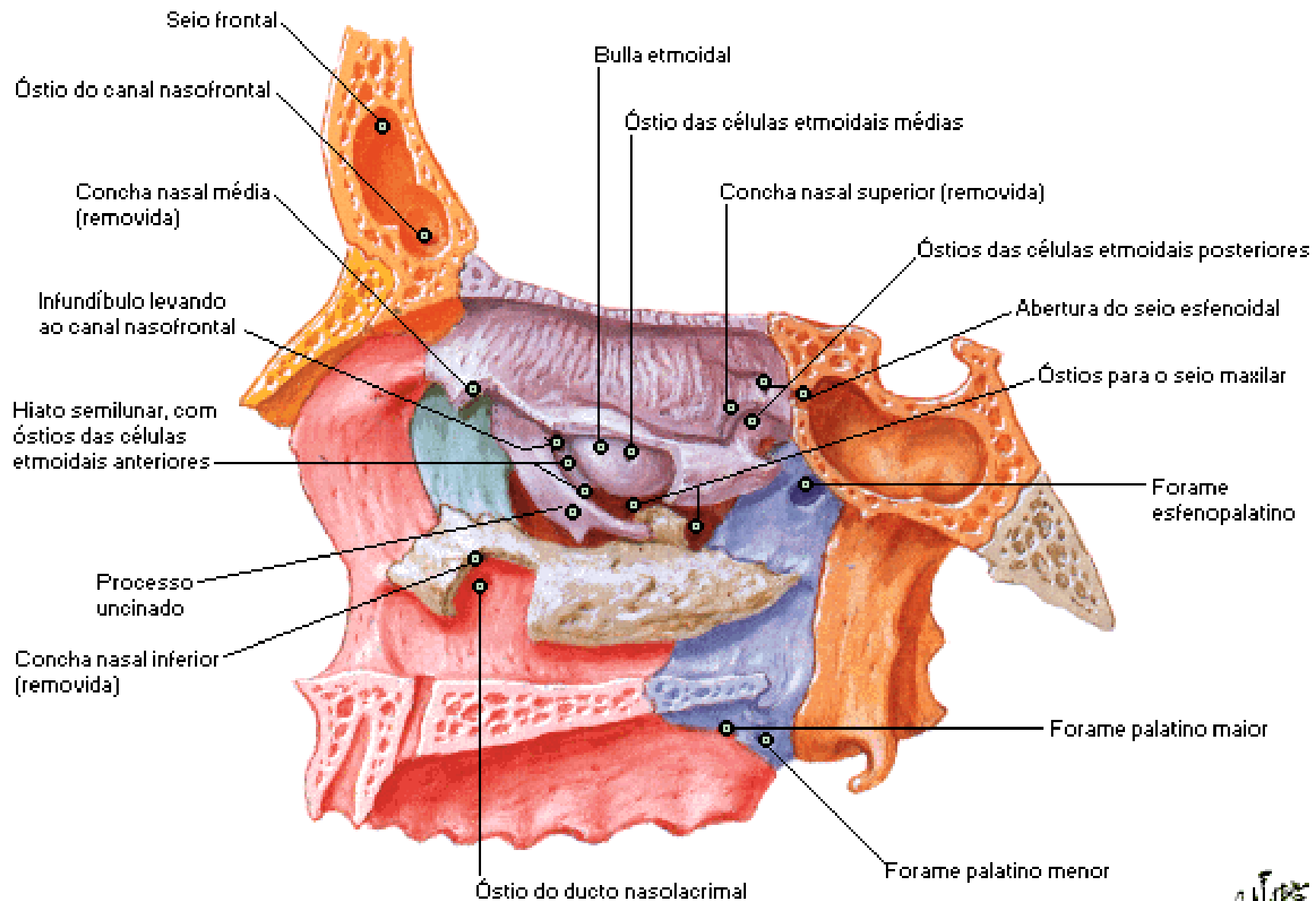


Parede Lateral do Nariz - Estrutura Óssea

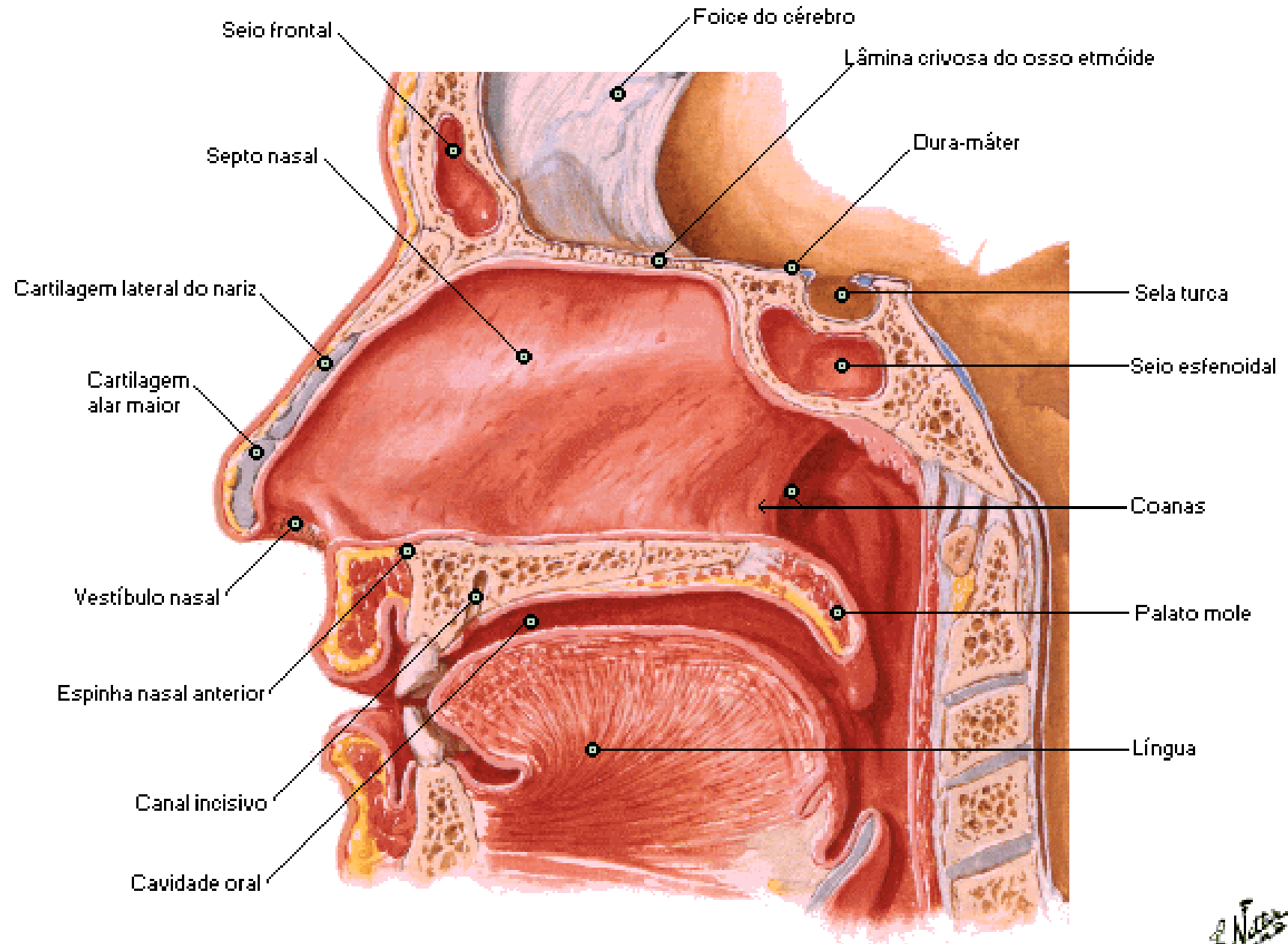


Parede Lateral do Nariz - Estrutura Óssea

Concha Nasal Parcialmente Removida

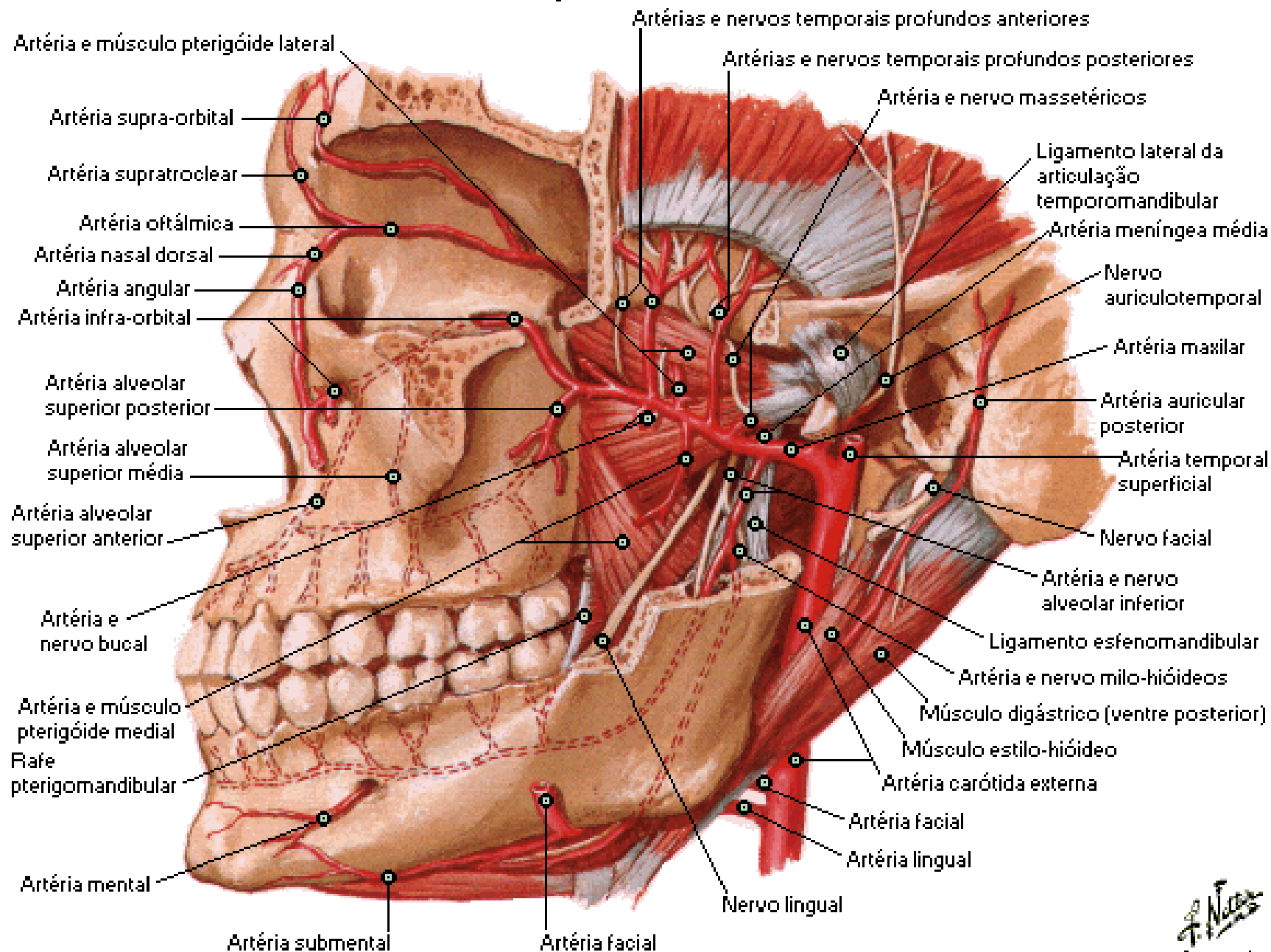


Parede Medial do Nariz [Septo]



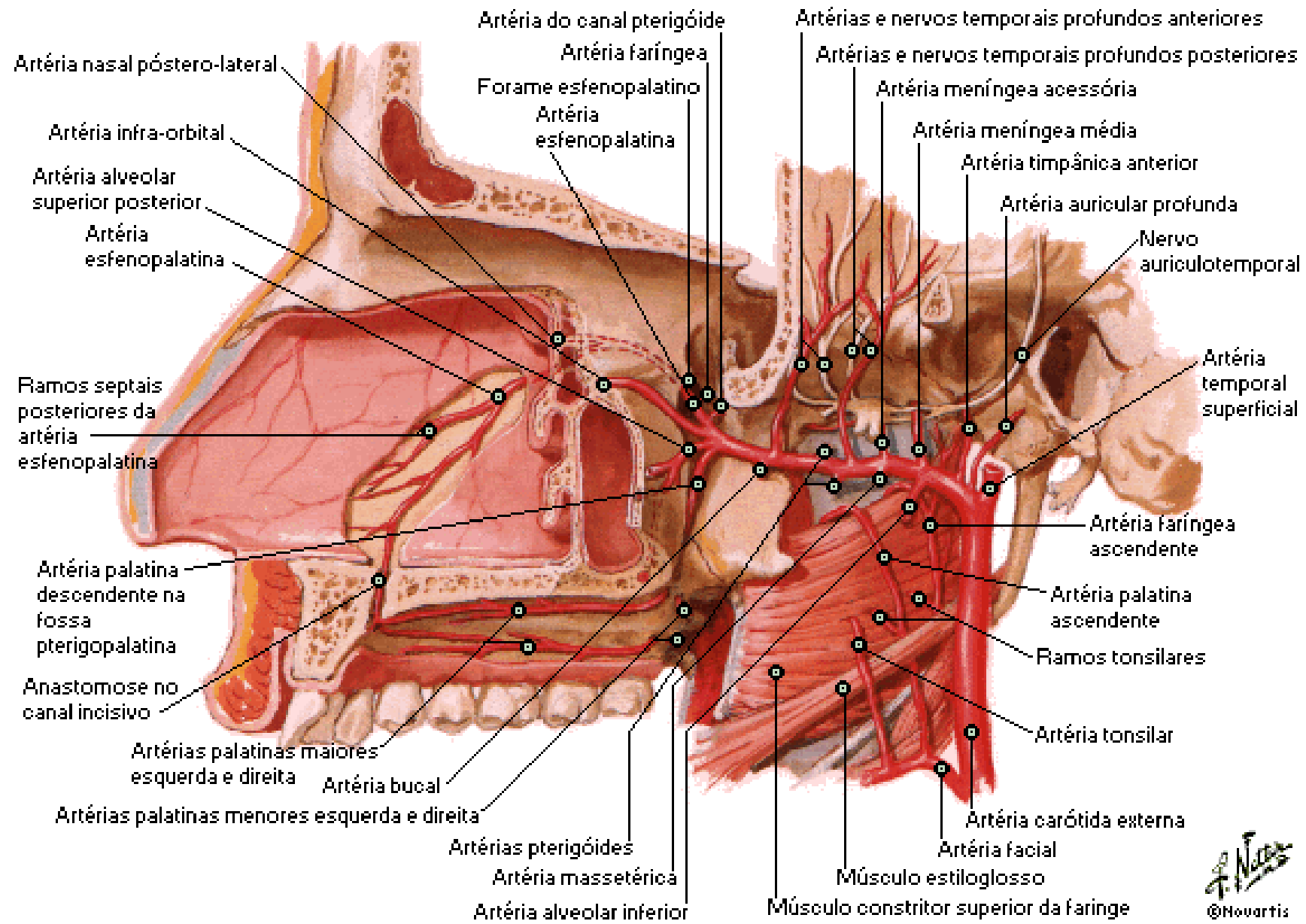
Artéria Maxilar

Distribuição Orbitomaxilar



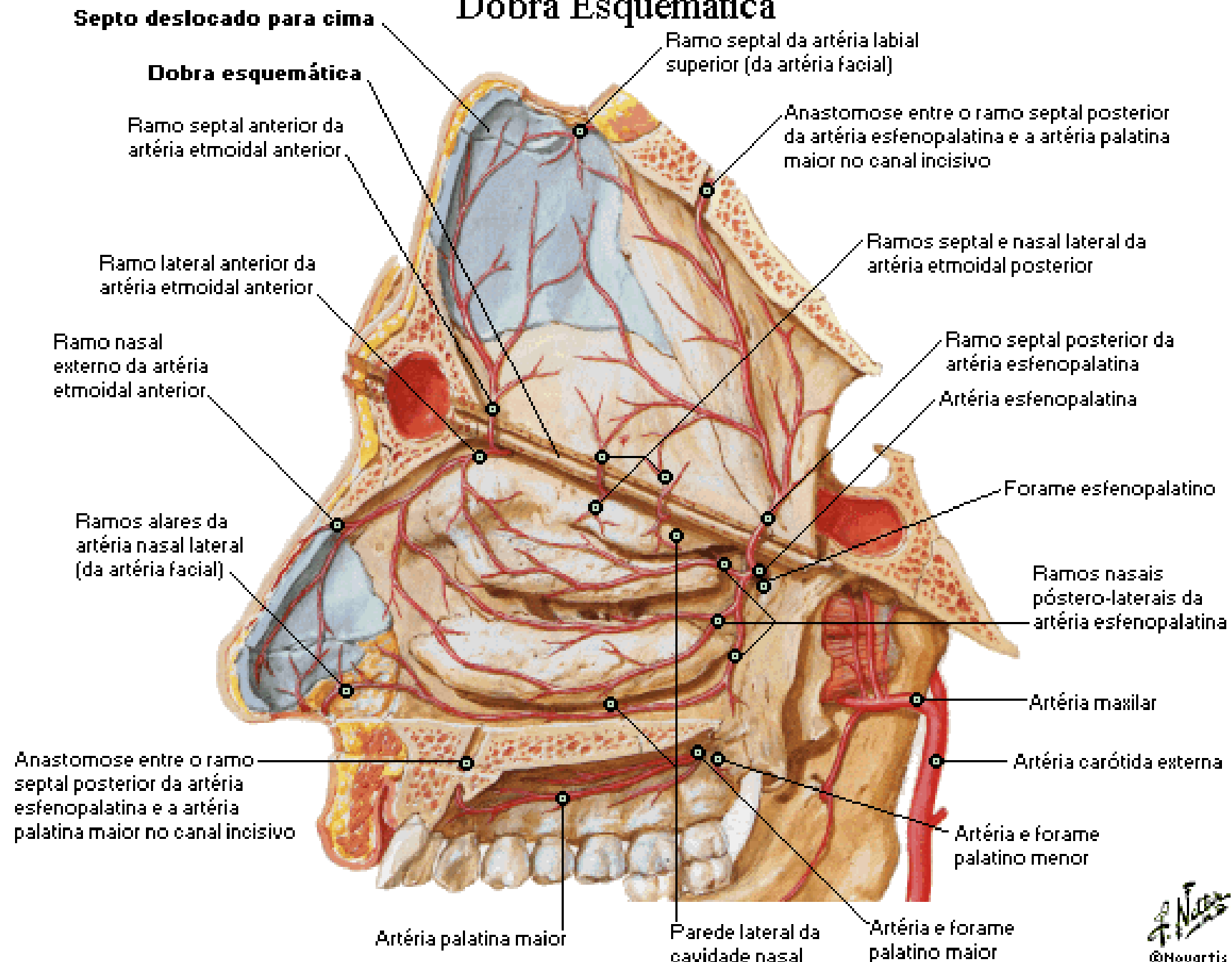
Artéria Maxilar

Distribuição Nasopalatina



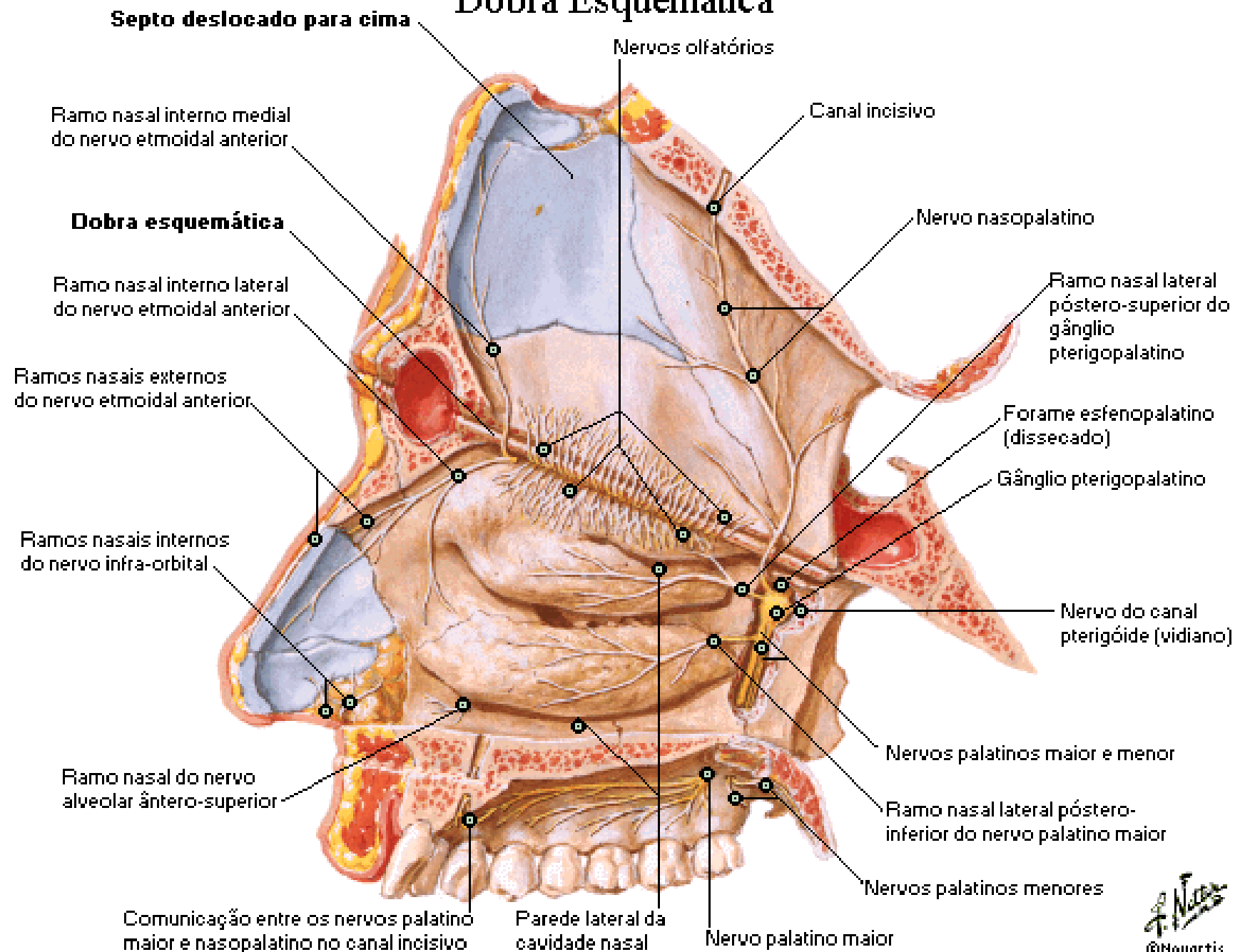
Artérias da Cavidade Nasal

Dobra Esquemática



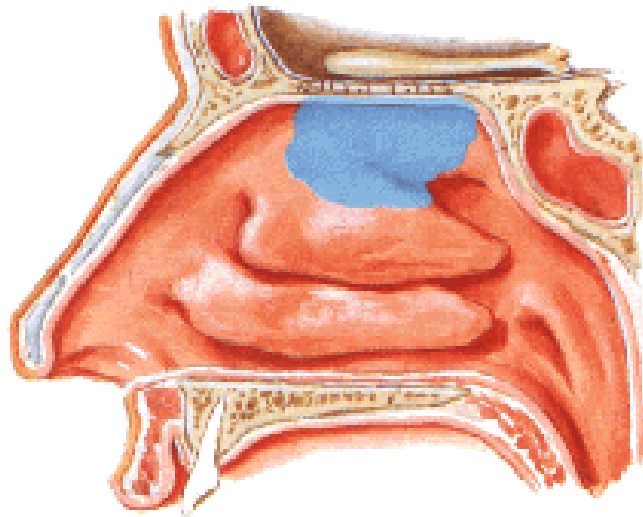
Nervos da Cavidade Nasal

Dobra Esquemática

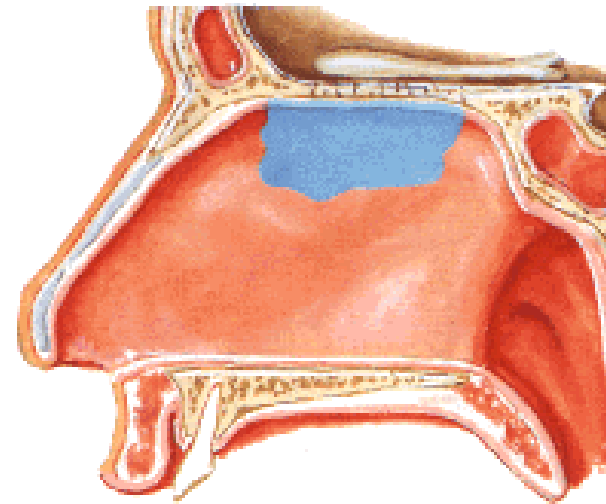


Nervos da Cavidade Nasal

Distribuição da Mucosa Olfatória



Parede lateral da cavidade nasal

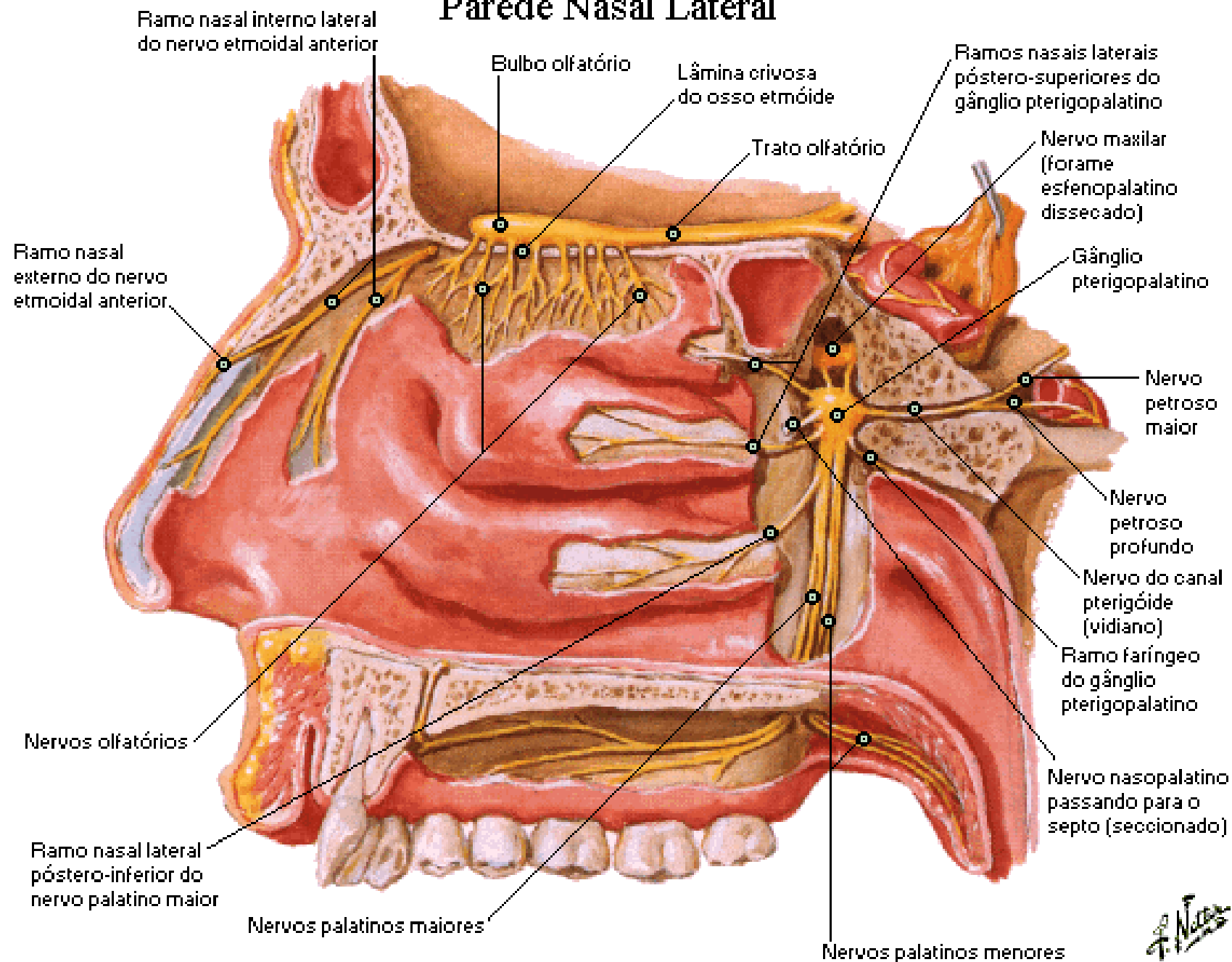


Septo nasal

Nota: A distribuição da mucosa olfatória está sombreada de azul

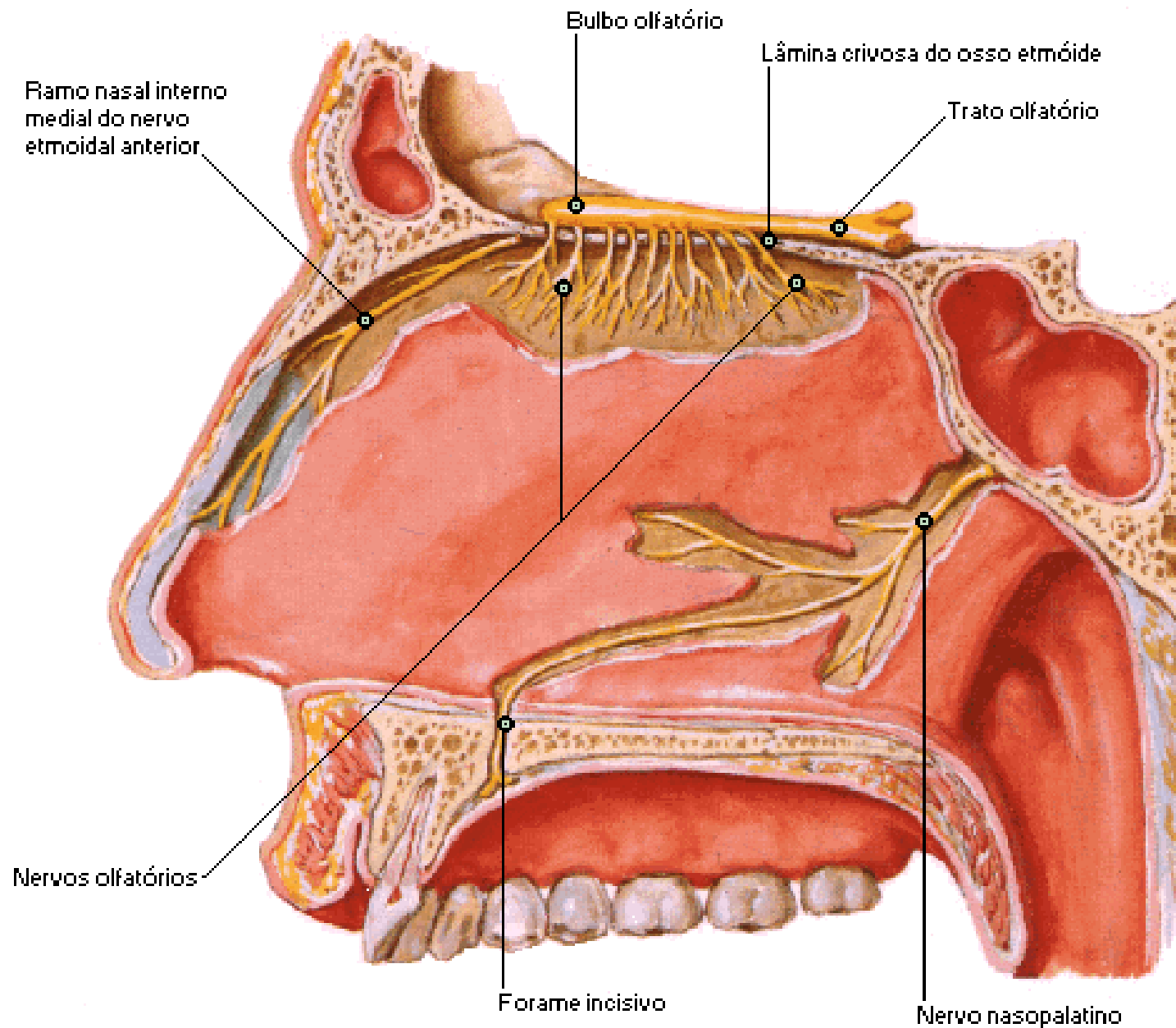
Nervos da Cavidade Nasal

Parede Nasal Lateral

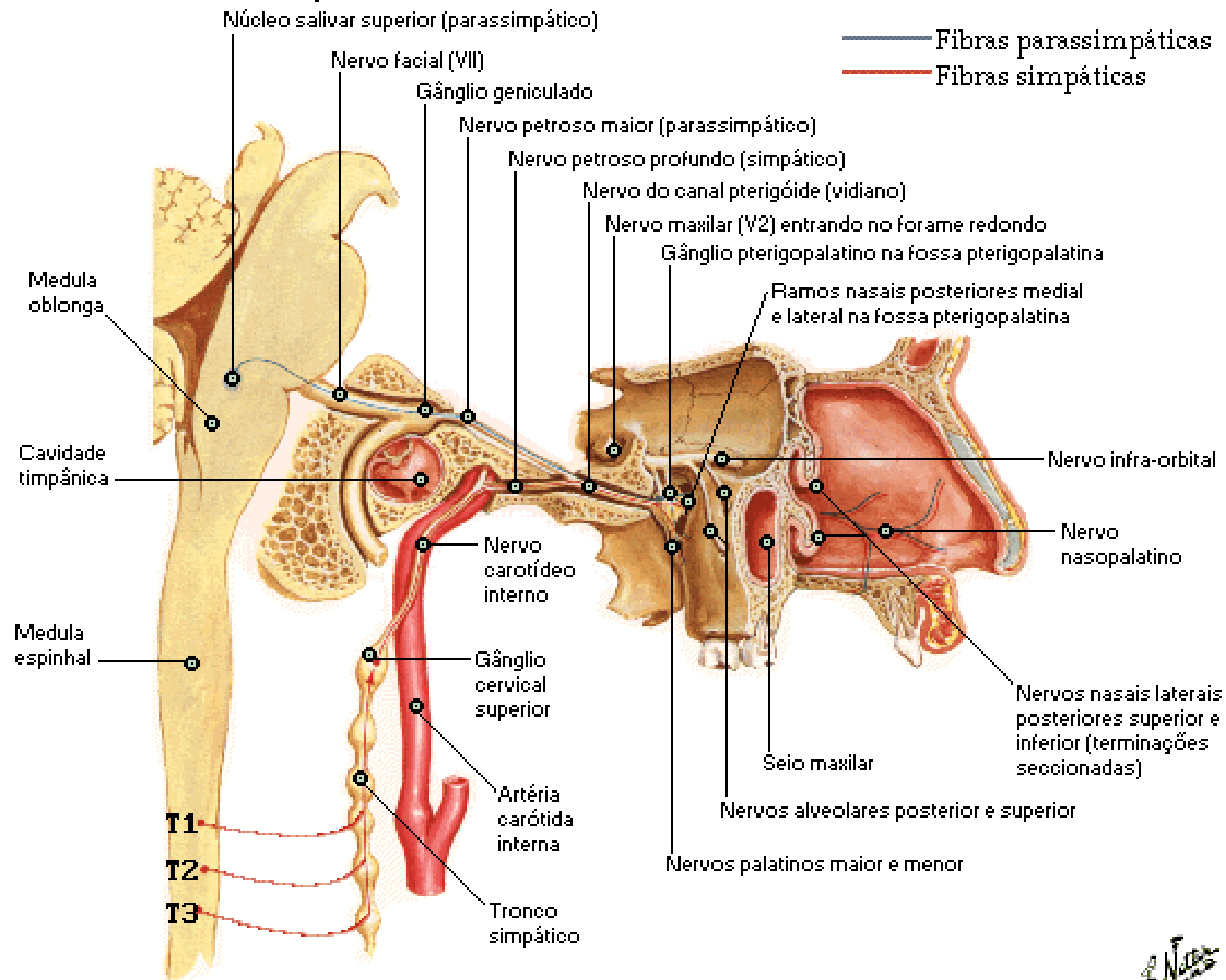


Nervos da Cavidade Nasal

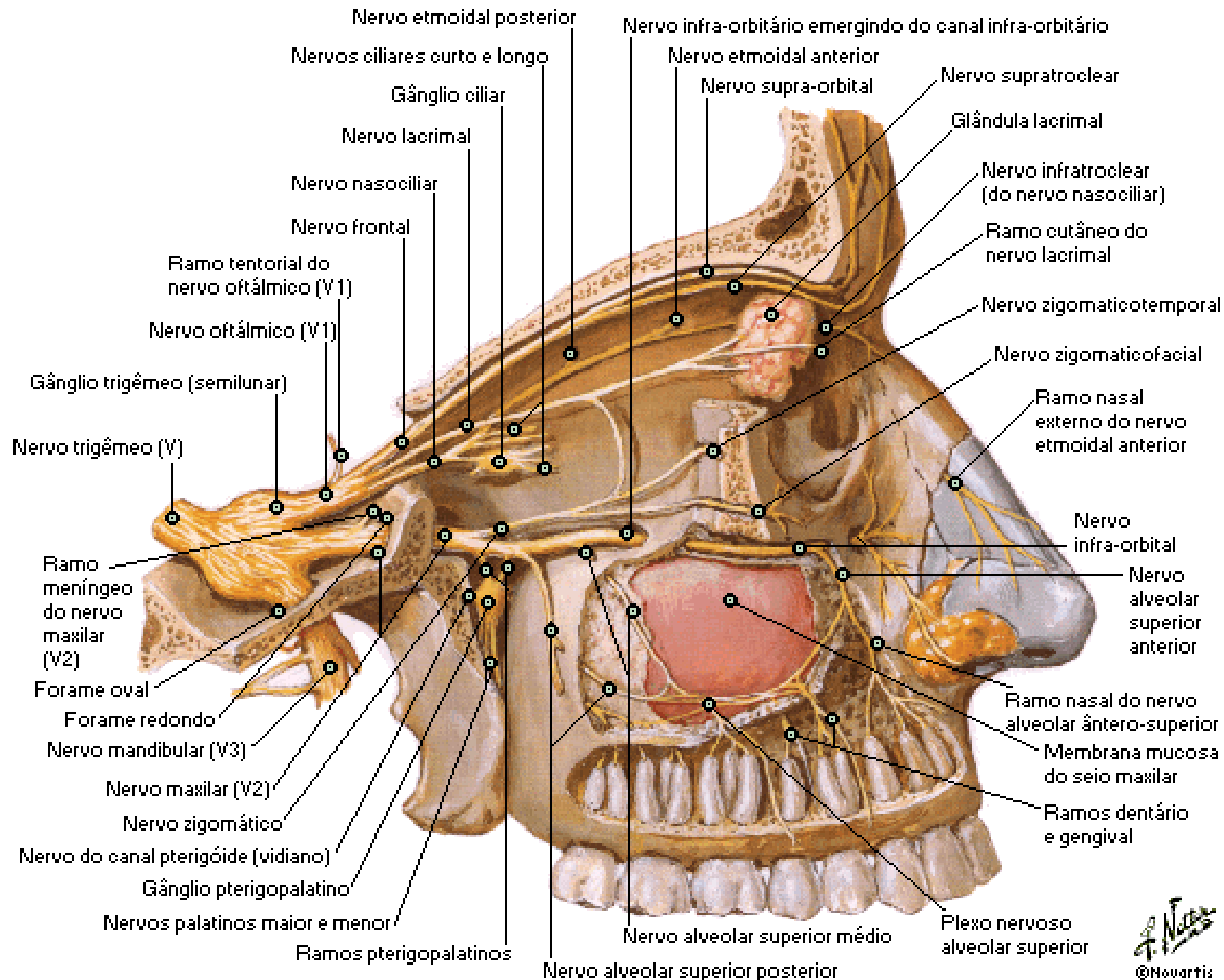
Septo Nasal



Inervação Autônoma da Cavidade Nasal

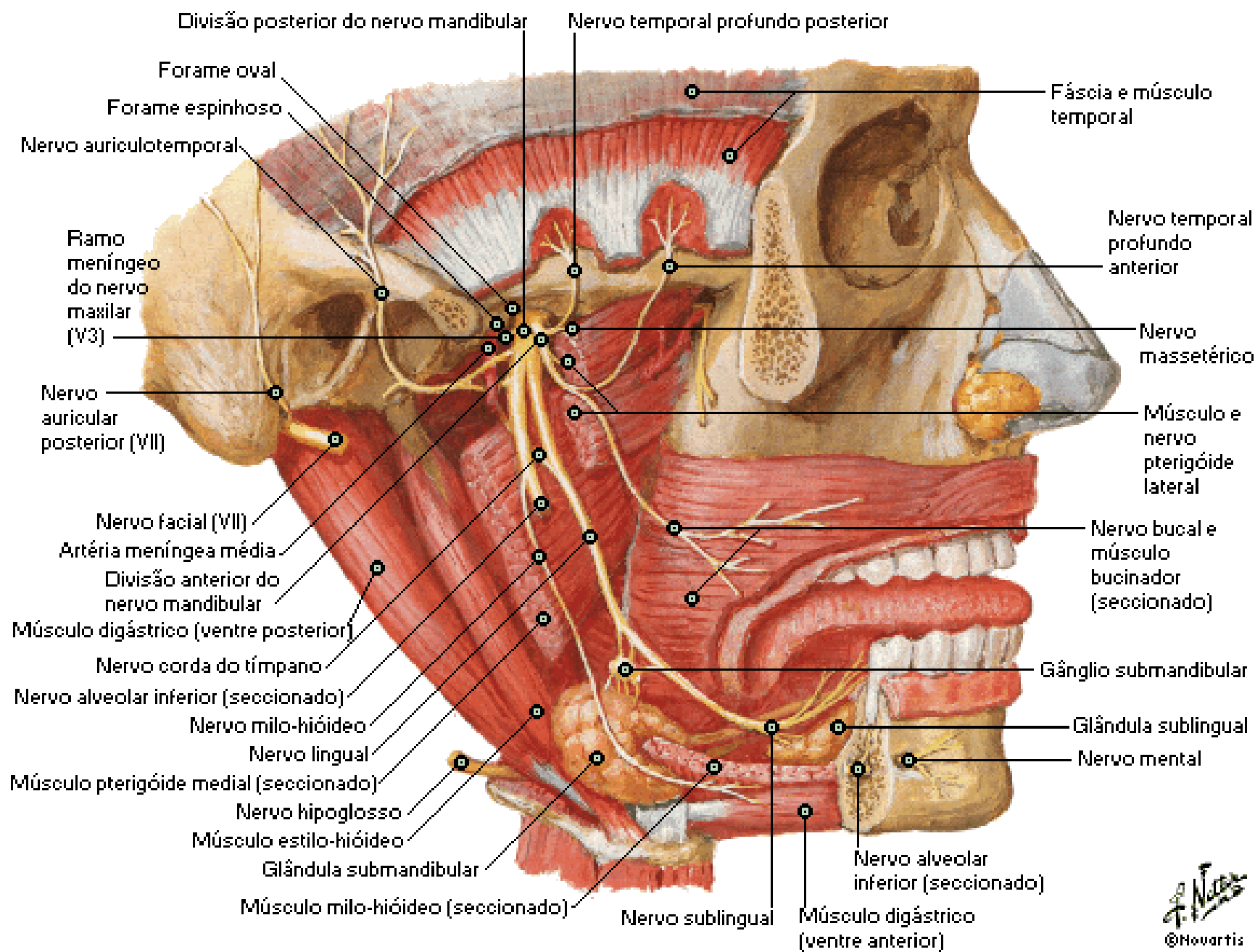


Nervos Oftálmico e Maxilar



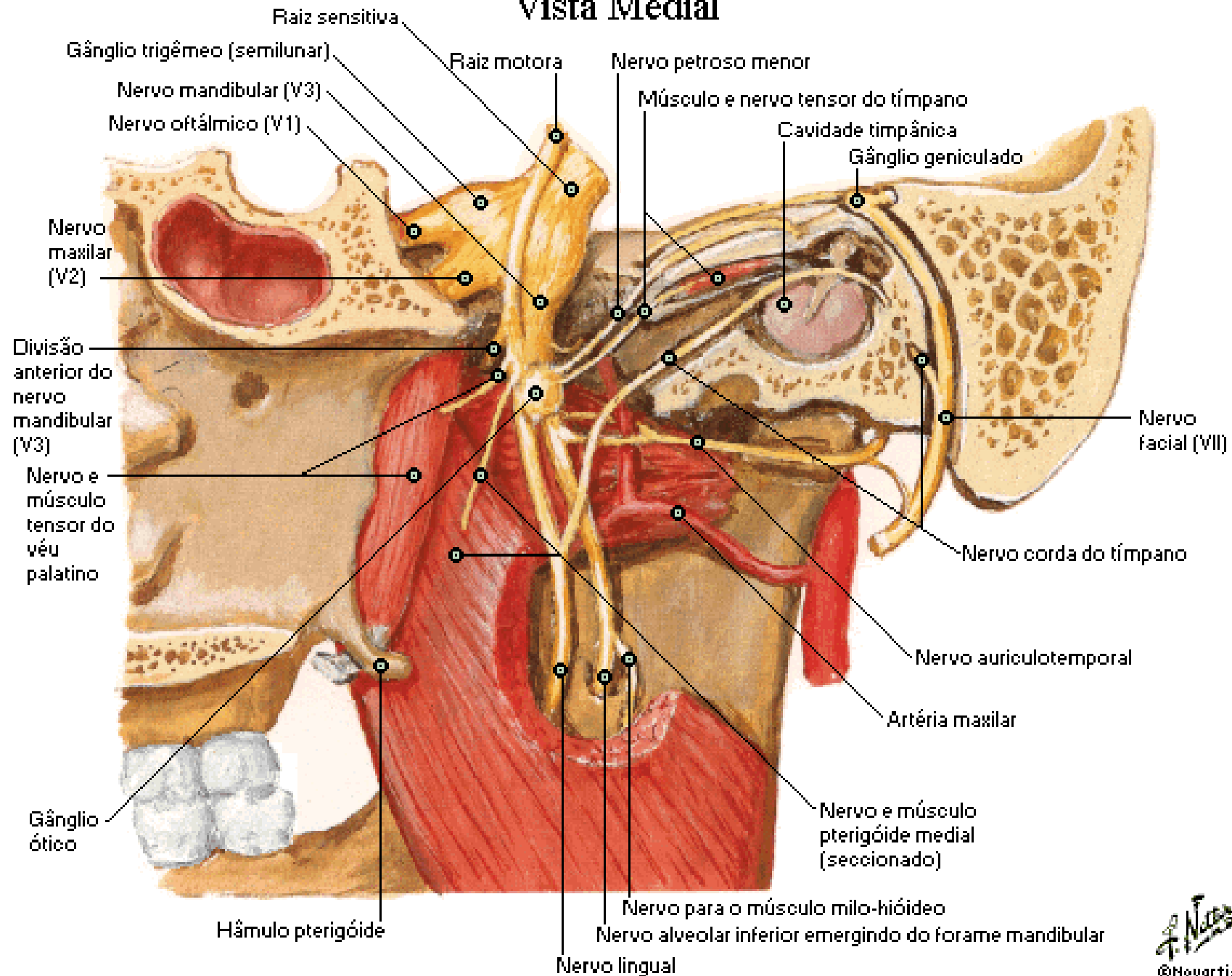
Nervo Mandibular [V3]

Vista Lateral



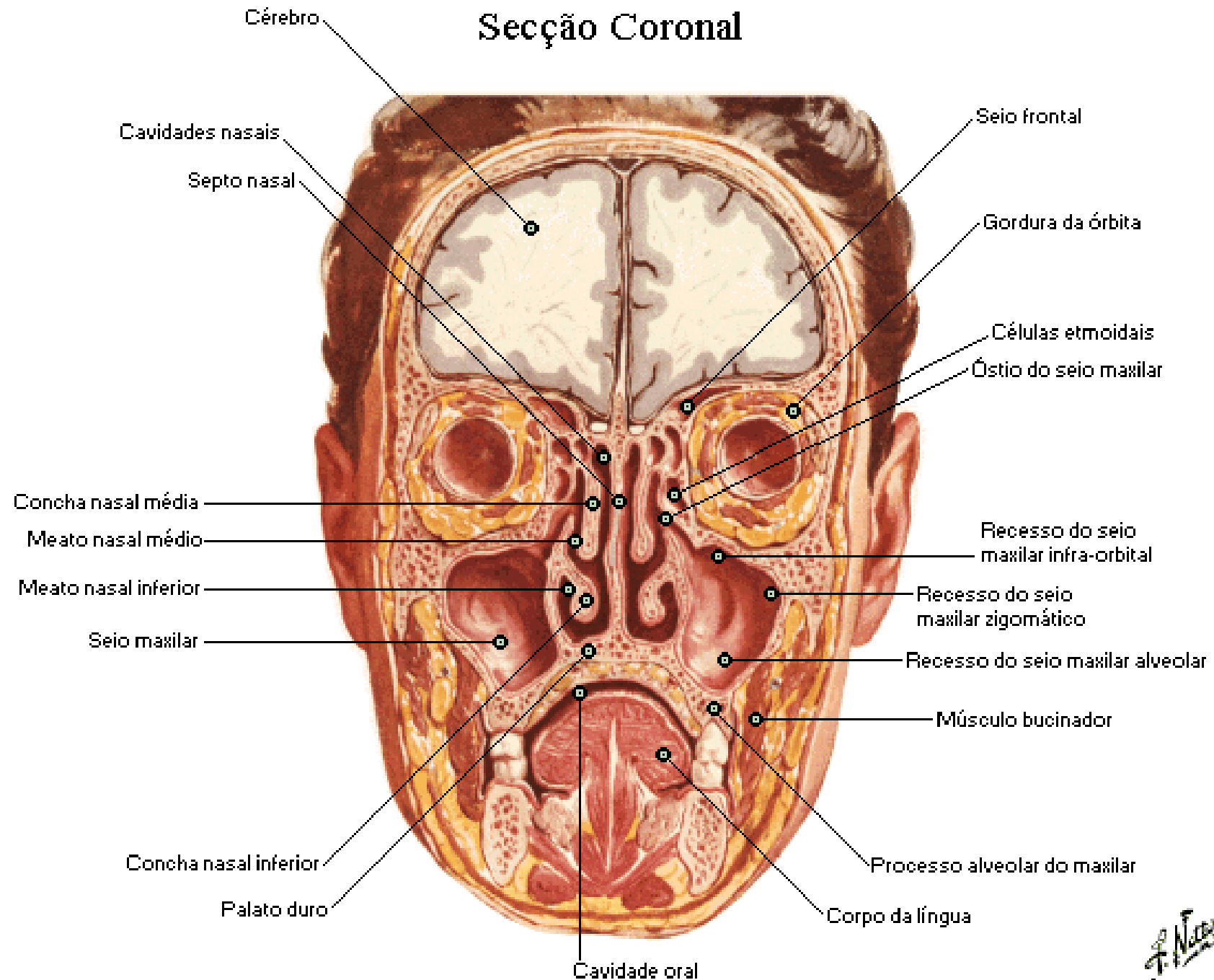
Nervo Mandibular [V3]

Vista Medial



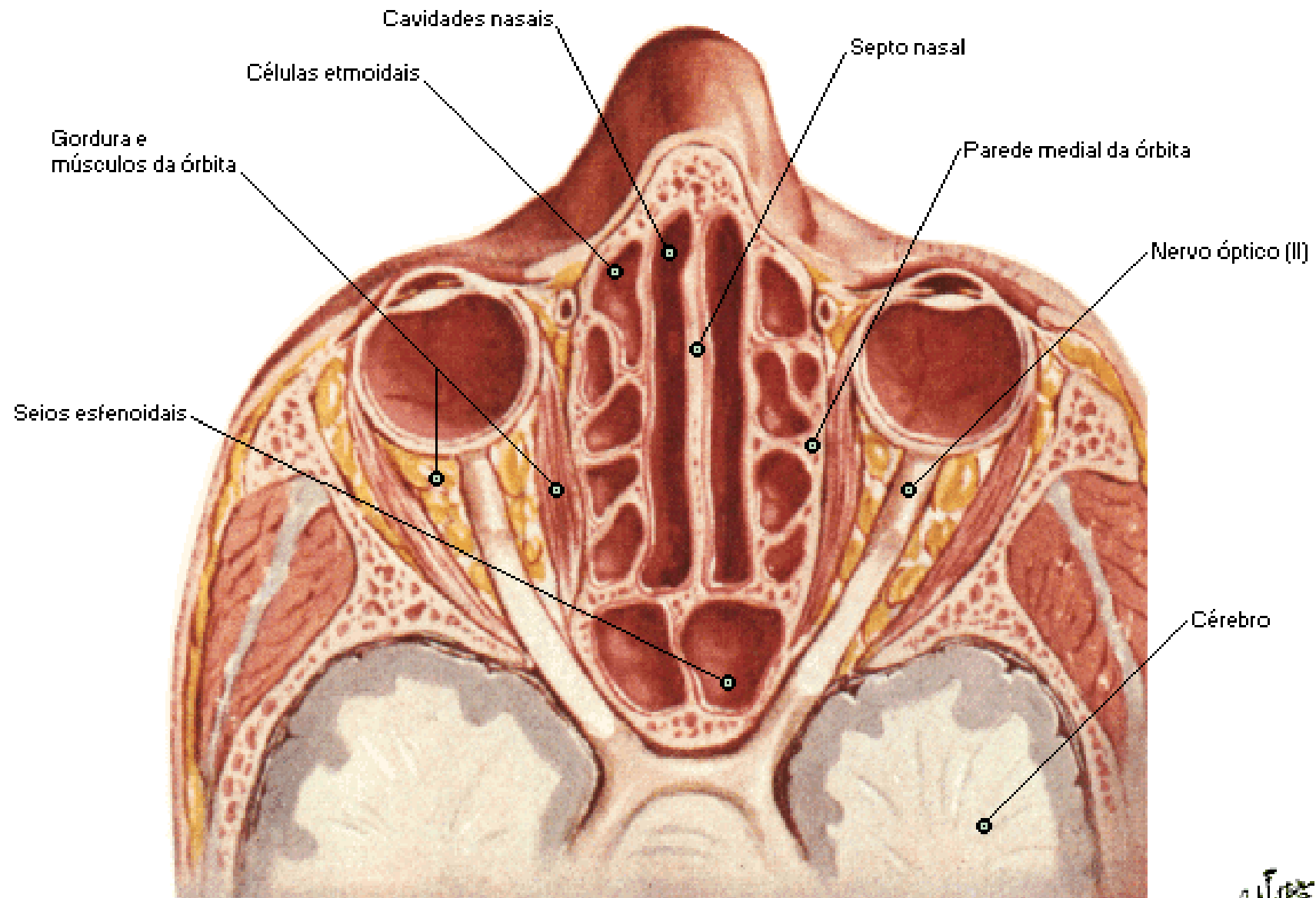
Seios Paranasais

Secção Coronal



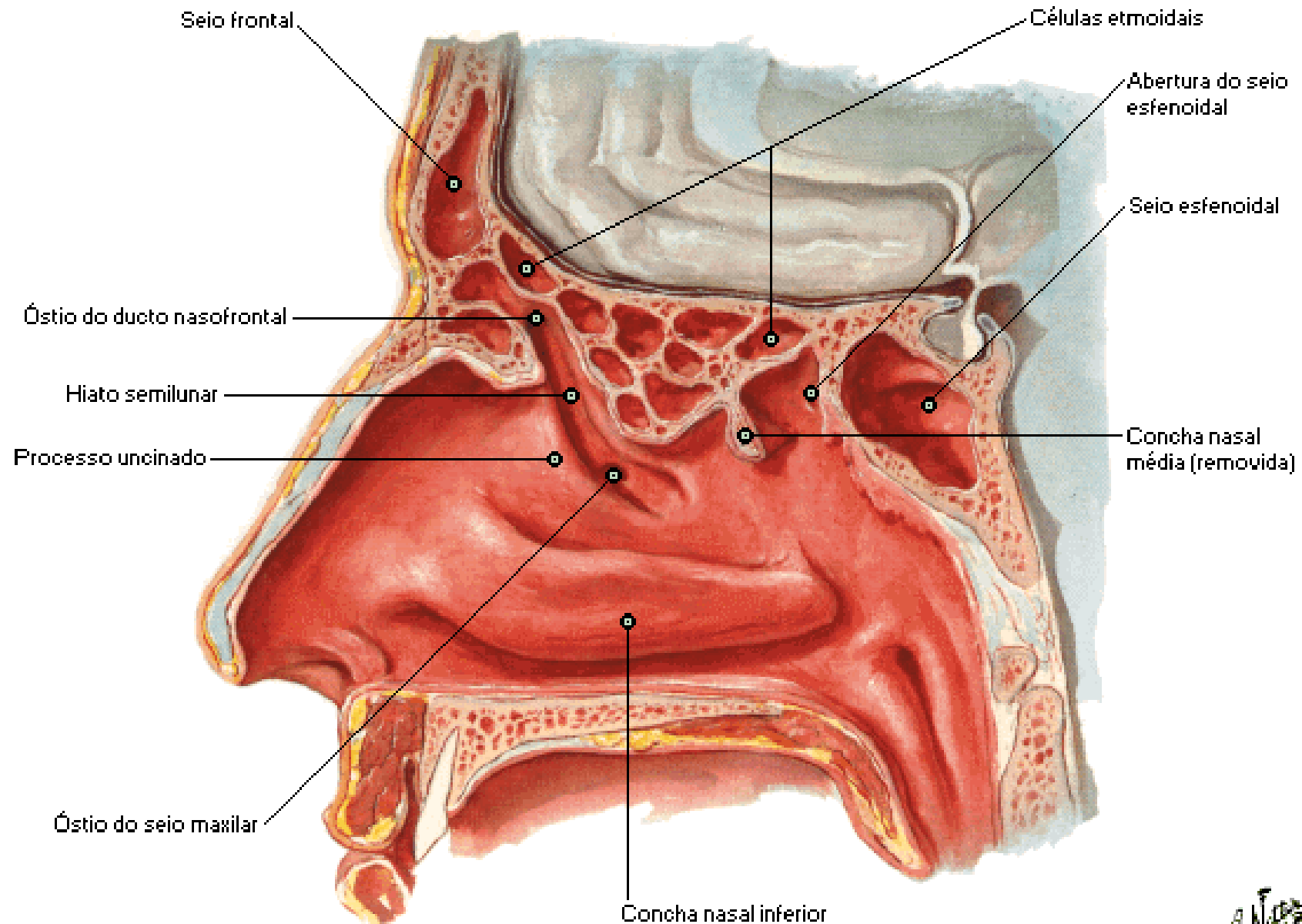
Seios Paranasais

Secção Horizontal



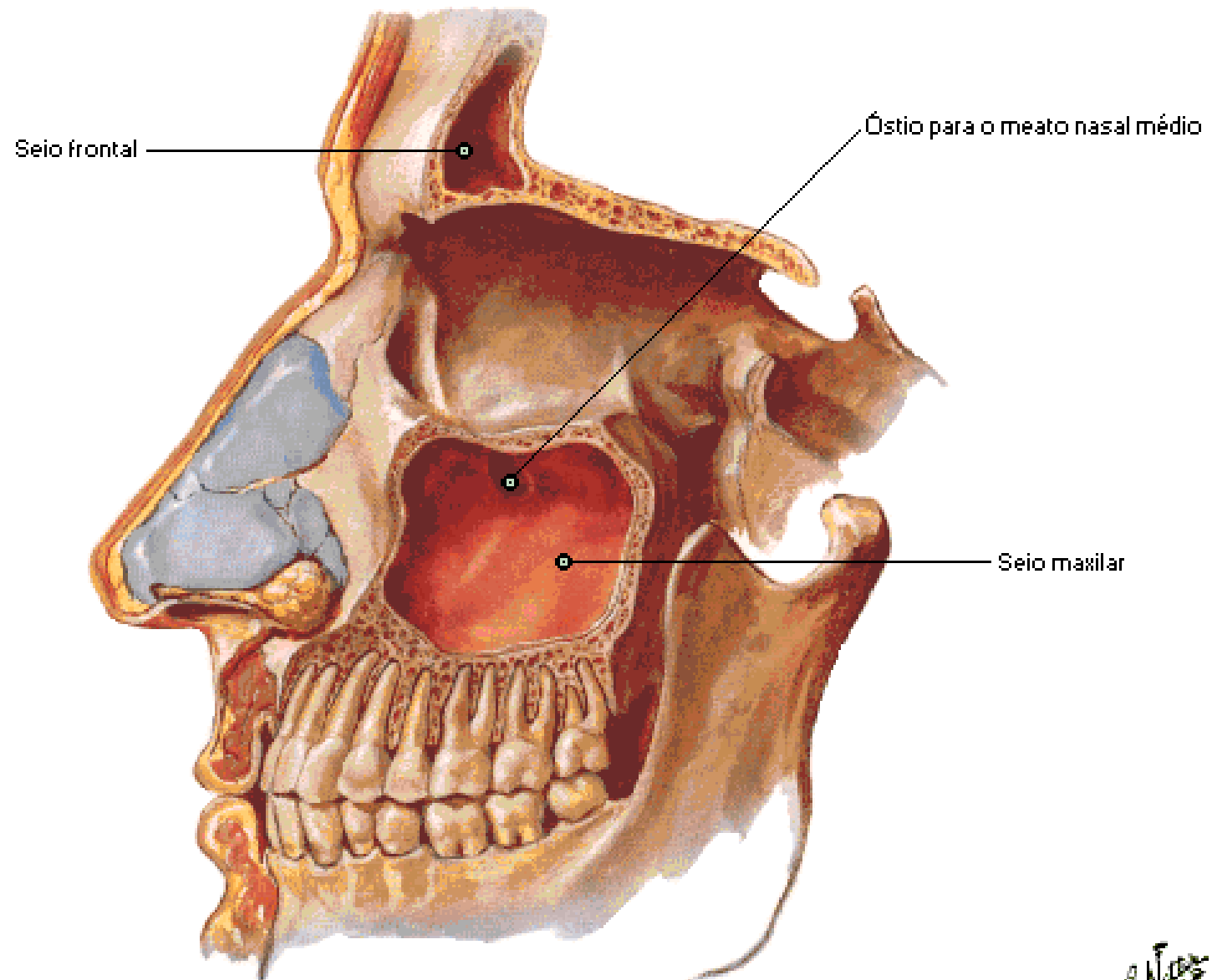
Seios Paranasais

Secção Sagital



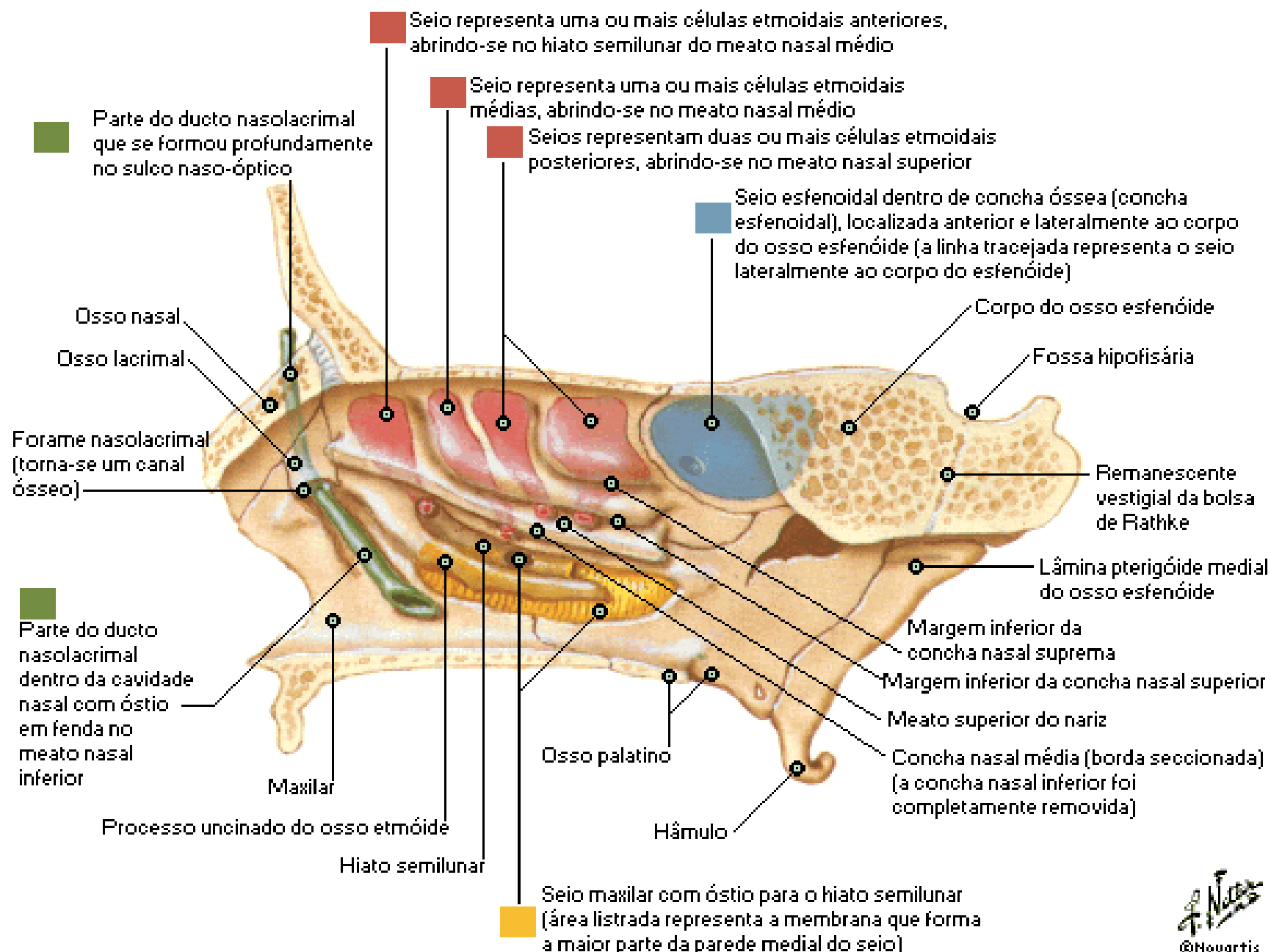
Seios Paranasais

Dissecação Lateral



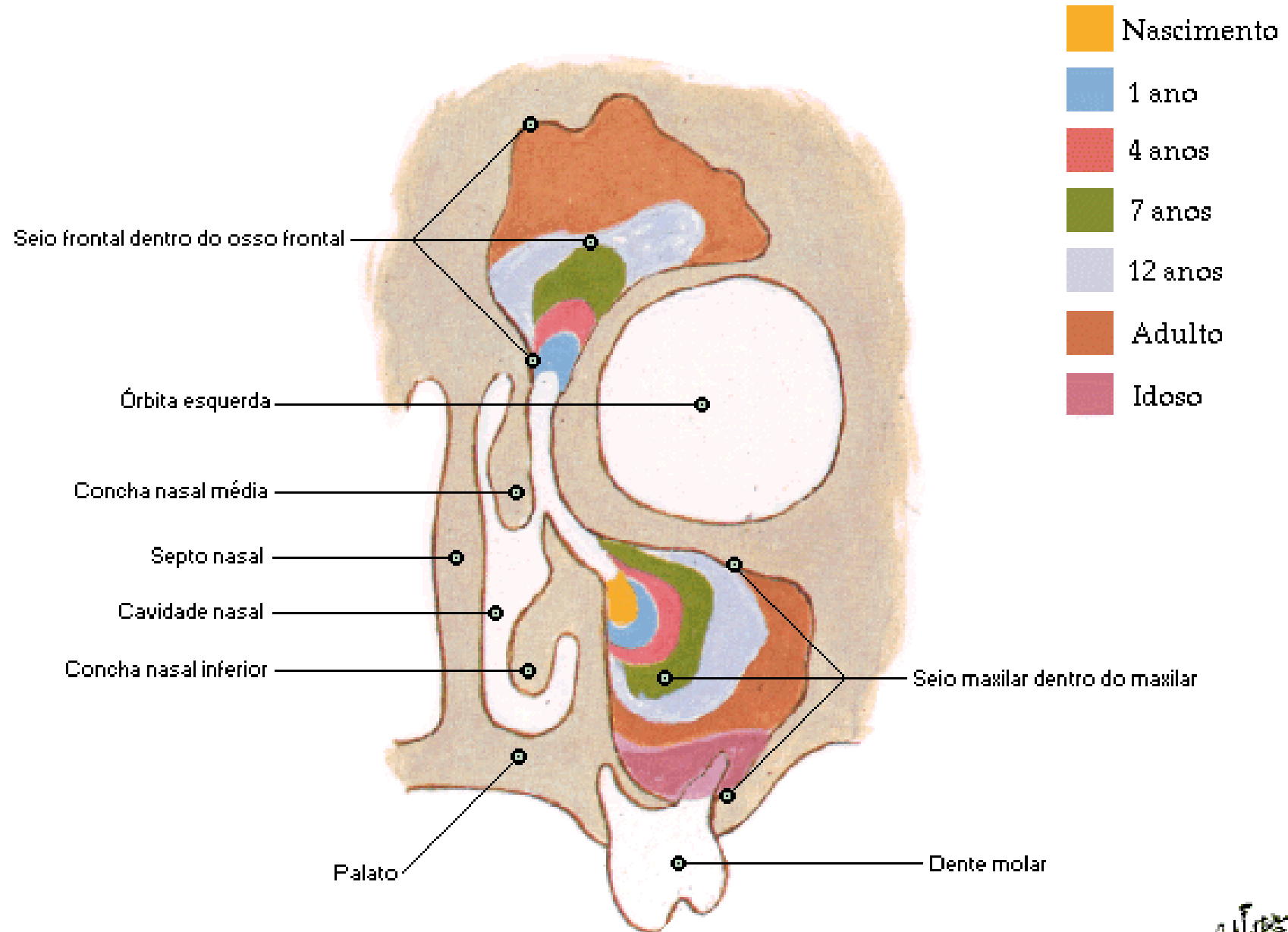
Seios Paranasais

Ao Nascimento



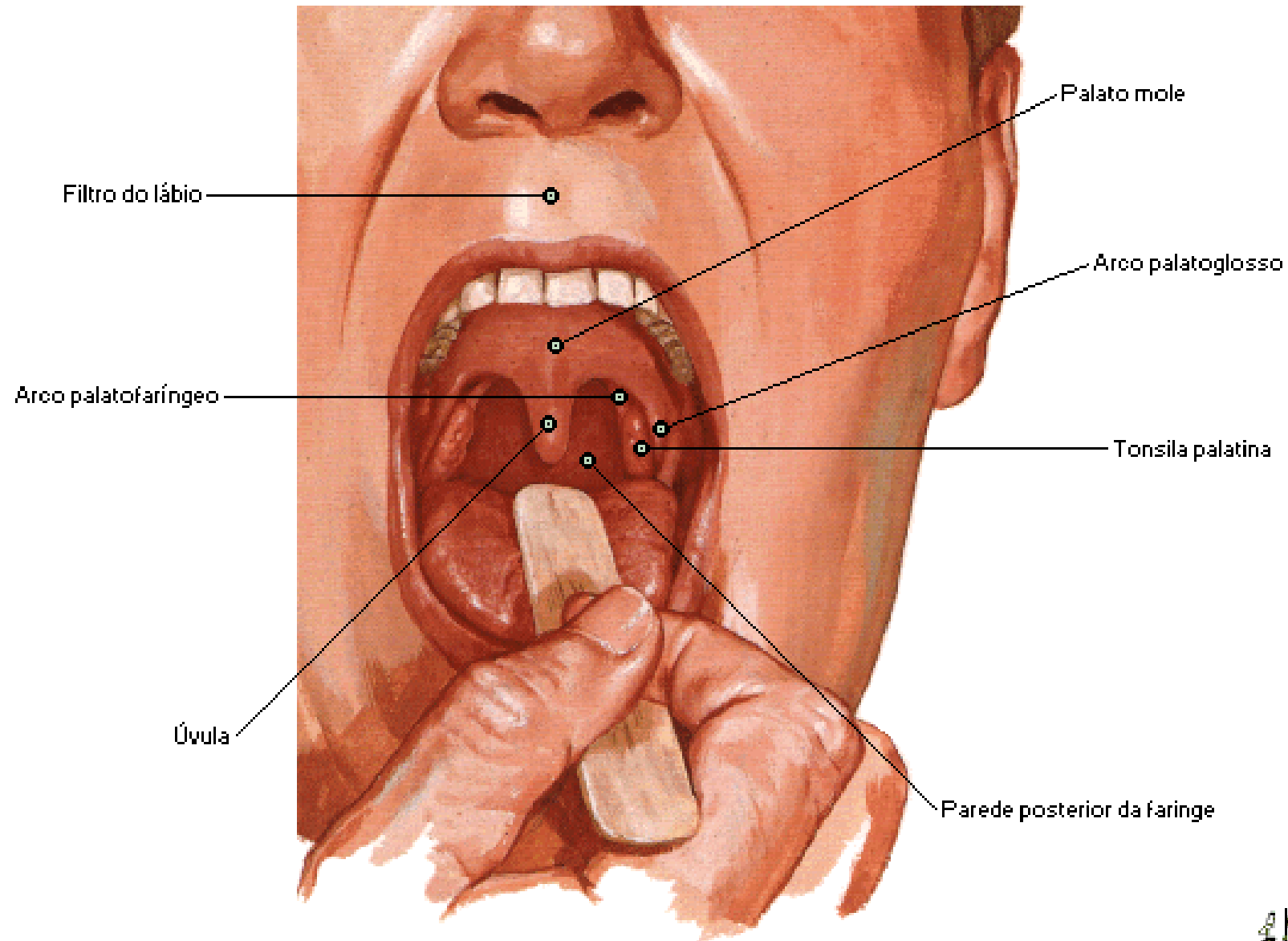
Seios Paranasais

Crescimento Durante a Vida



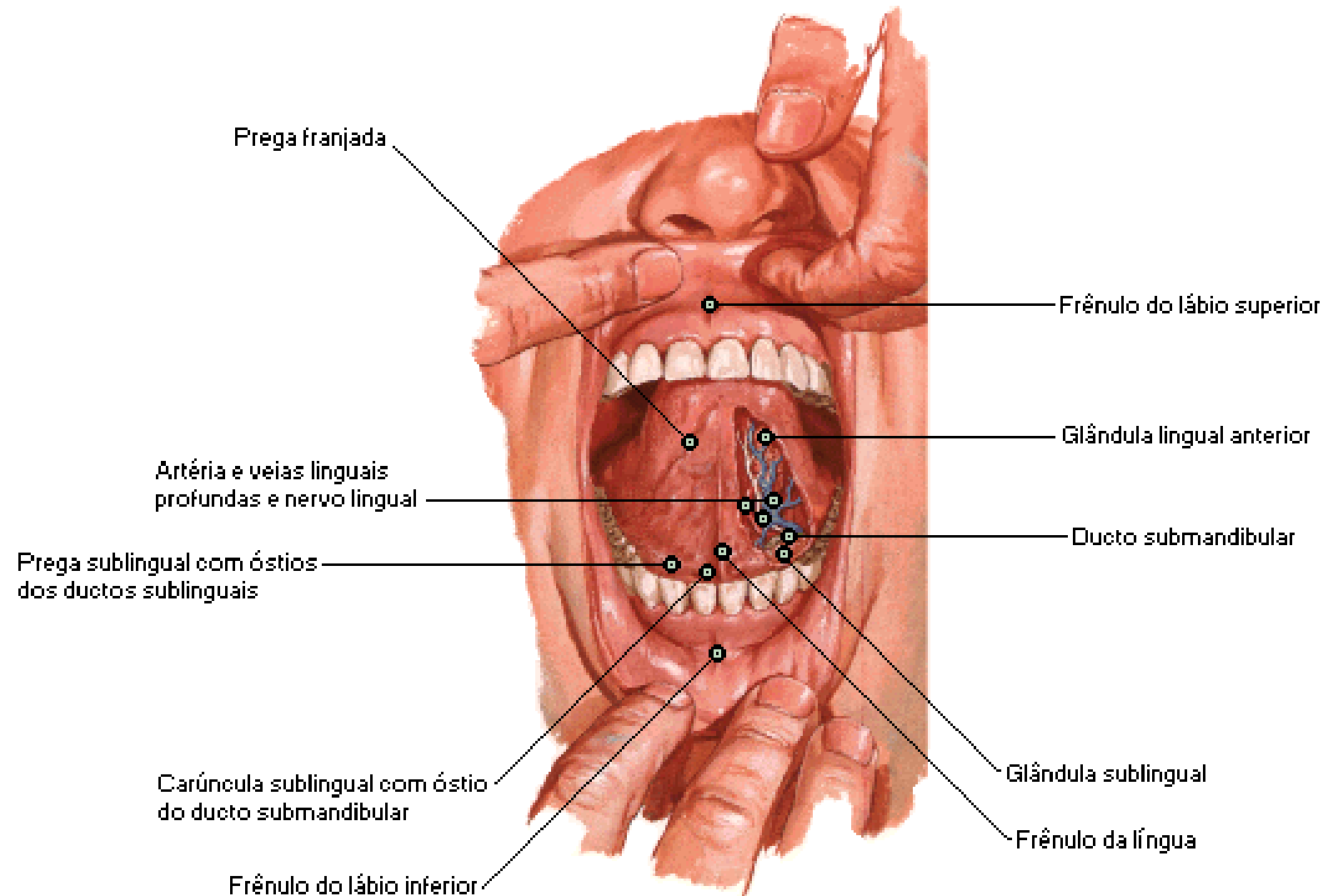
Inspeção da Cavidade Oral

Dorso da Língua e do Palato



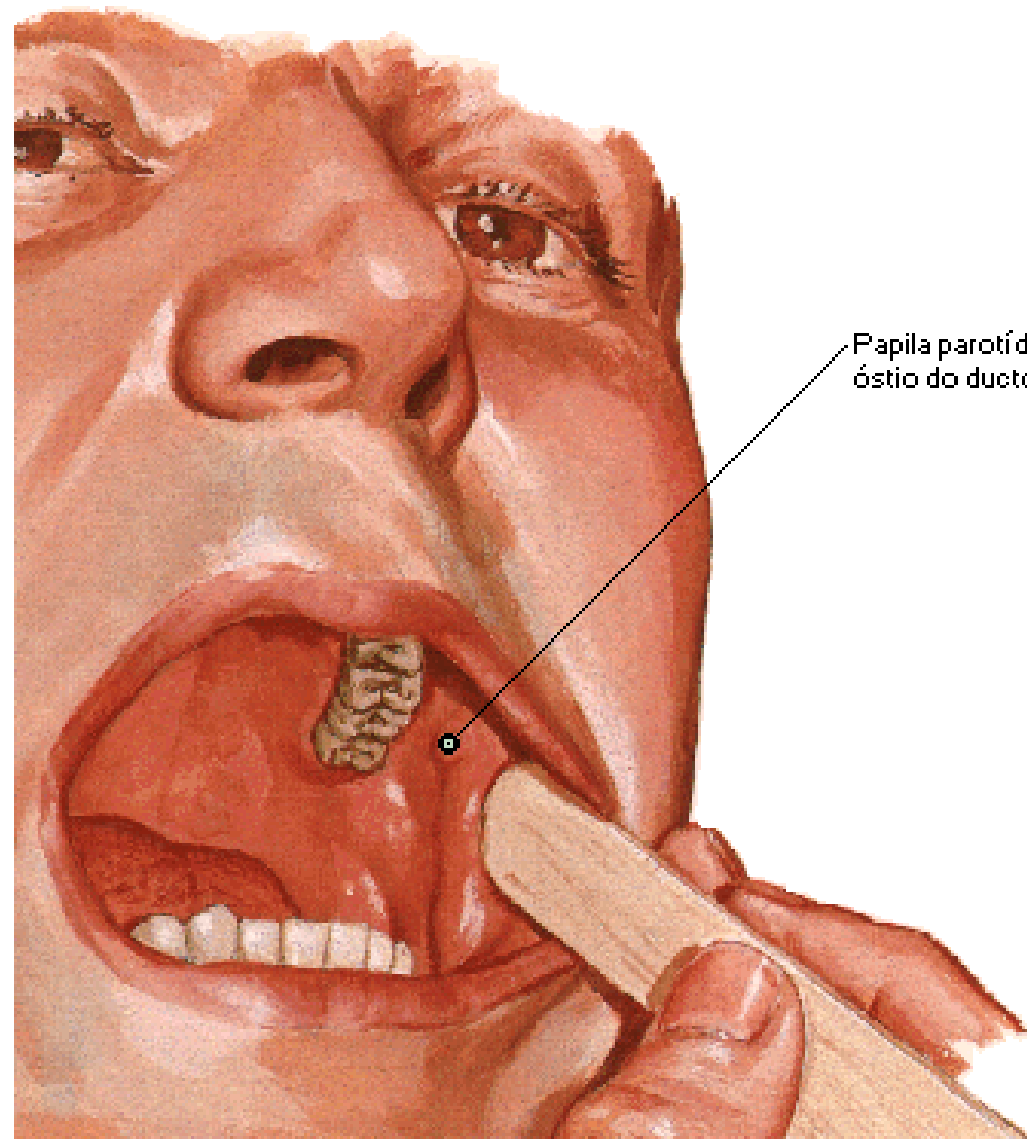
Inspeção da Cavidade Oral

Região Sublingual - Vestíbulo Anterior



Inspeção da Cavidade Oral

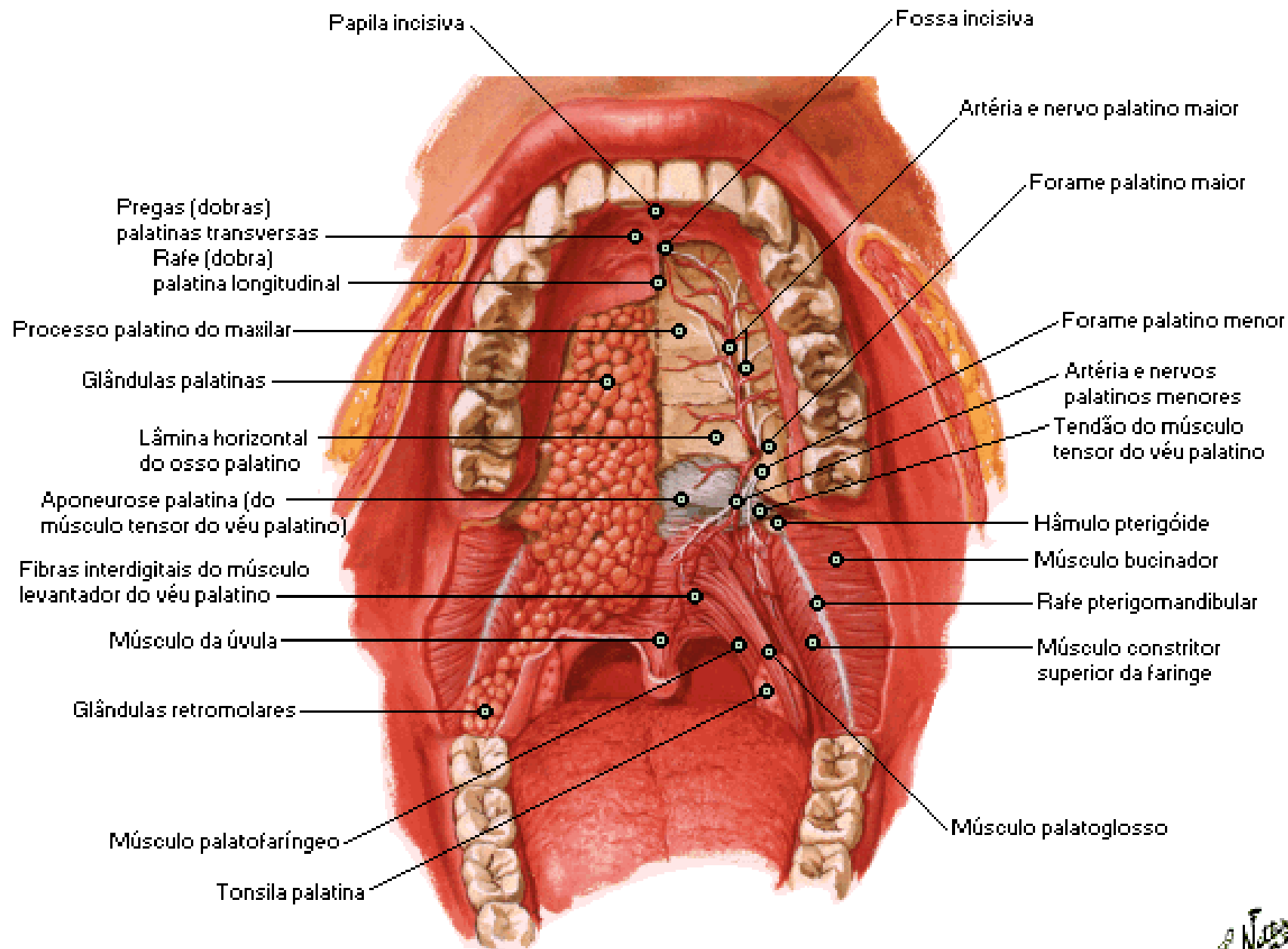
Vestíbulo Oral Lateral



Papila parotídea com
óstio do ducto parotídeo

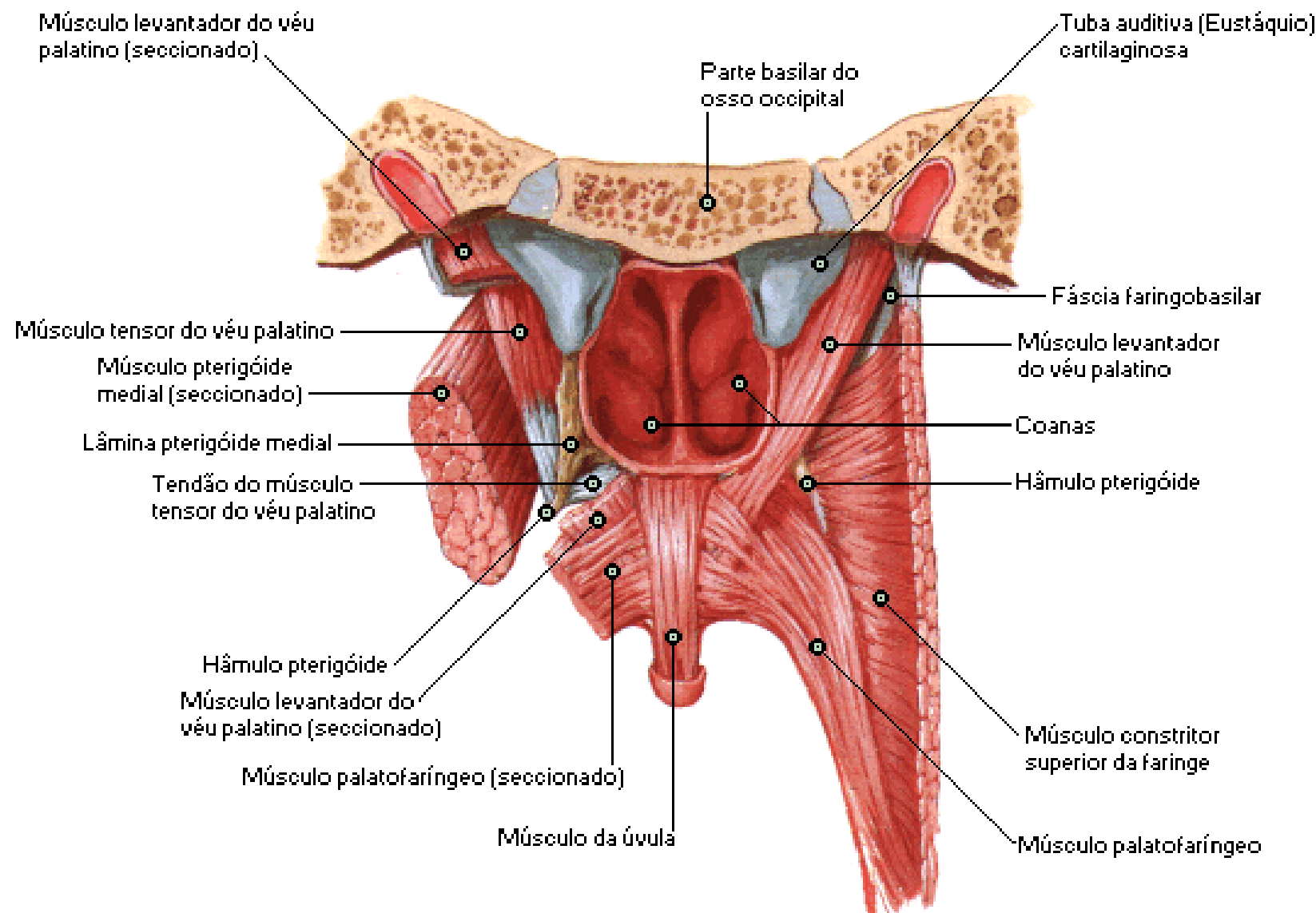
Teto da Cavidade Oral - Palatos Duro e Mole

Vista Anterior



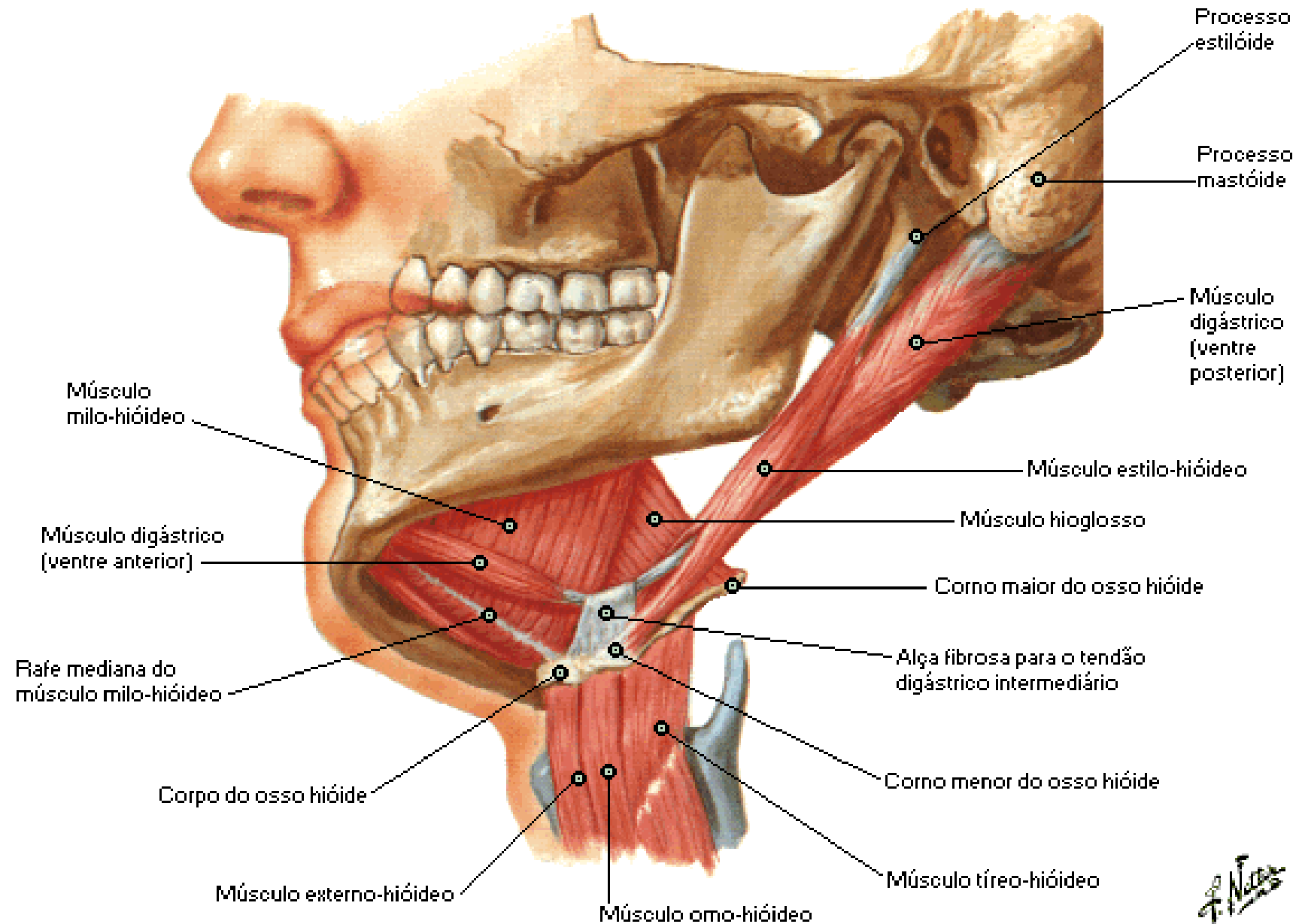
Teto da Cavidade Oral - Plato Mole

Vista Posterior



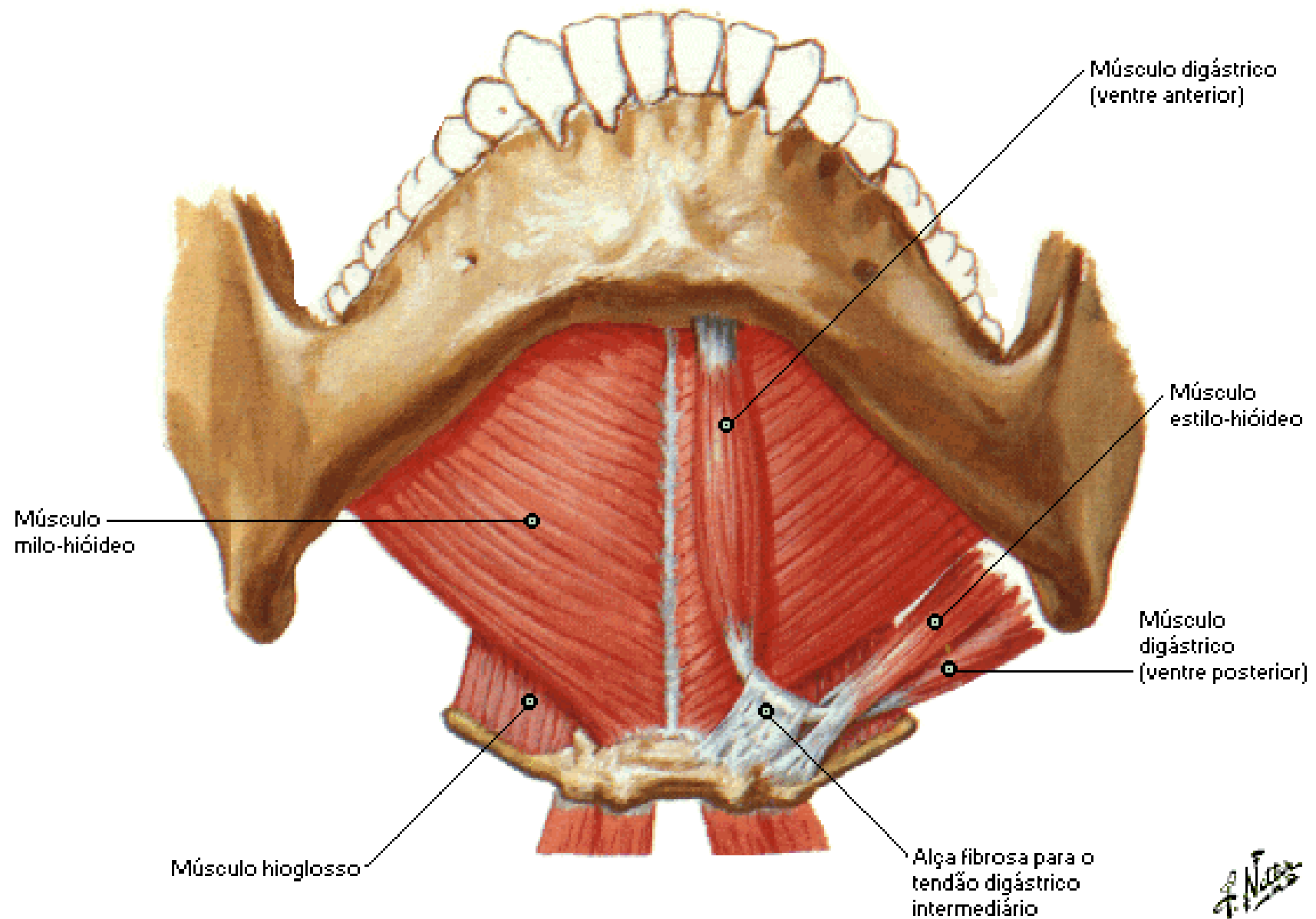
Assoalho da Cavidade Oral

Vista Inferior e Levemente Lateral



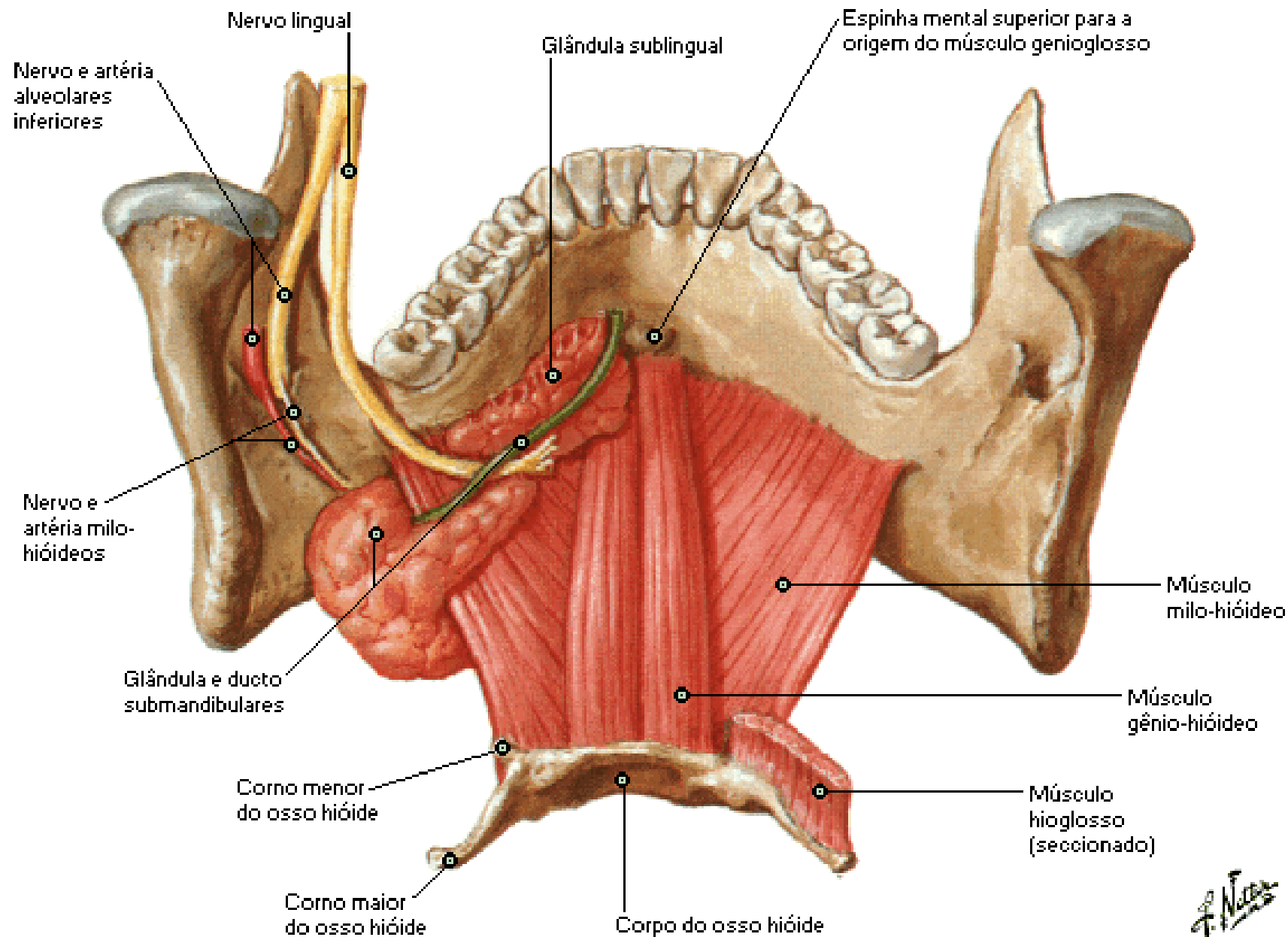
Assoalho da Cavidade Oral

Vista Ântero-inferior



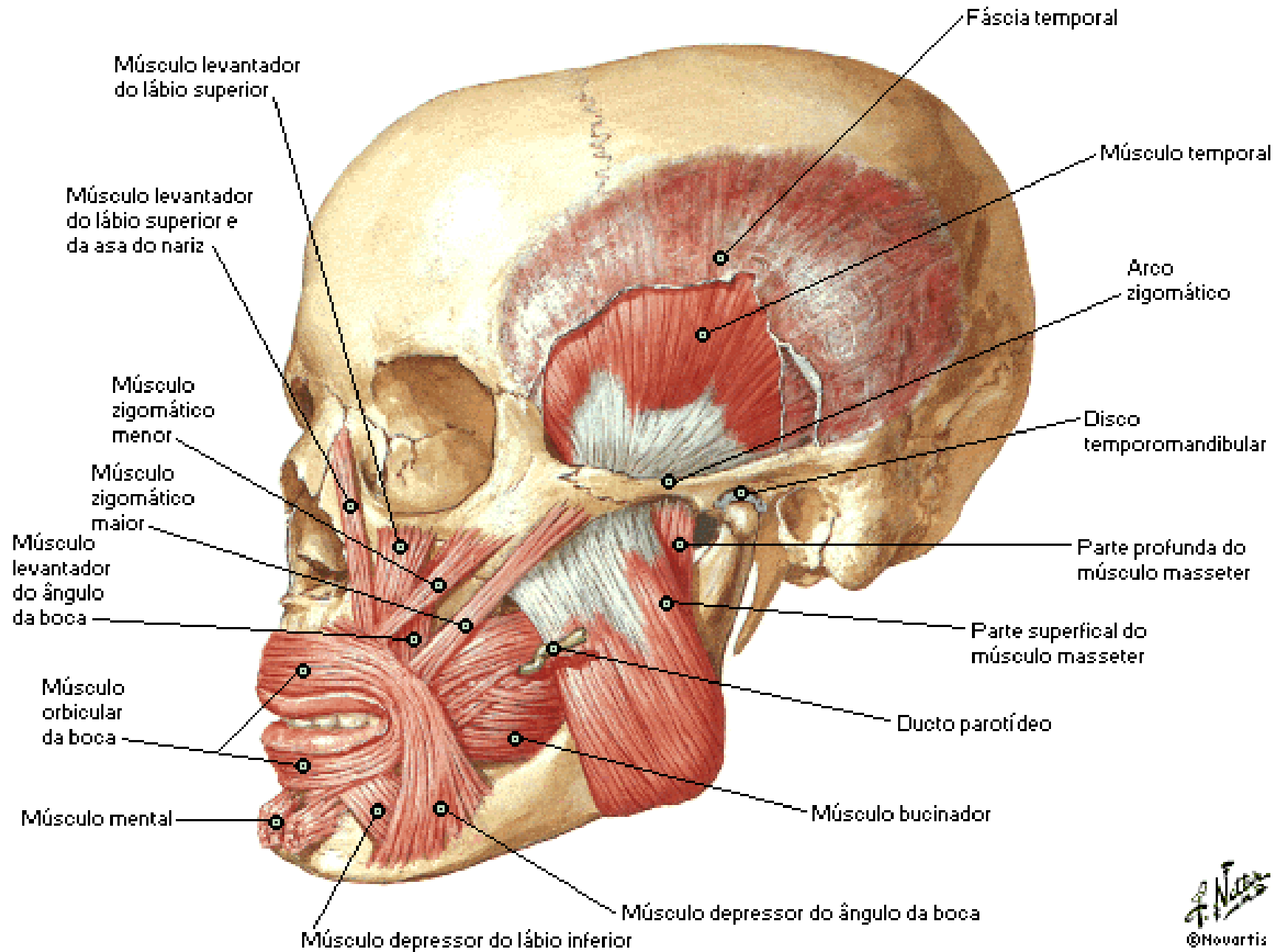
Assoalho da Cavidade Oral

Vista Pósterio-superior



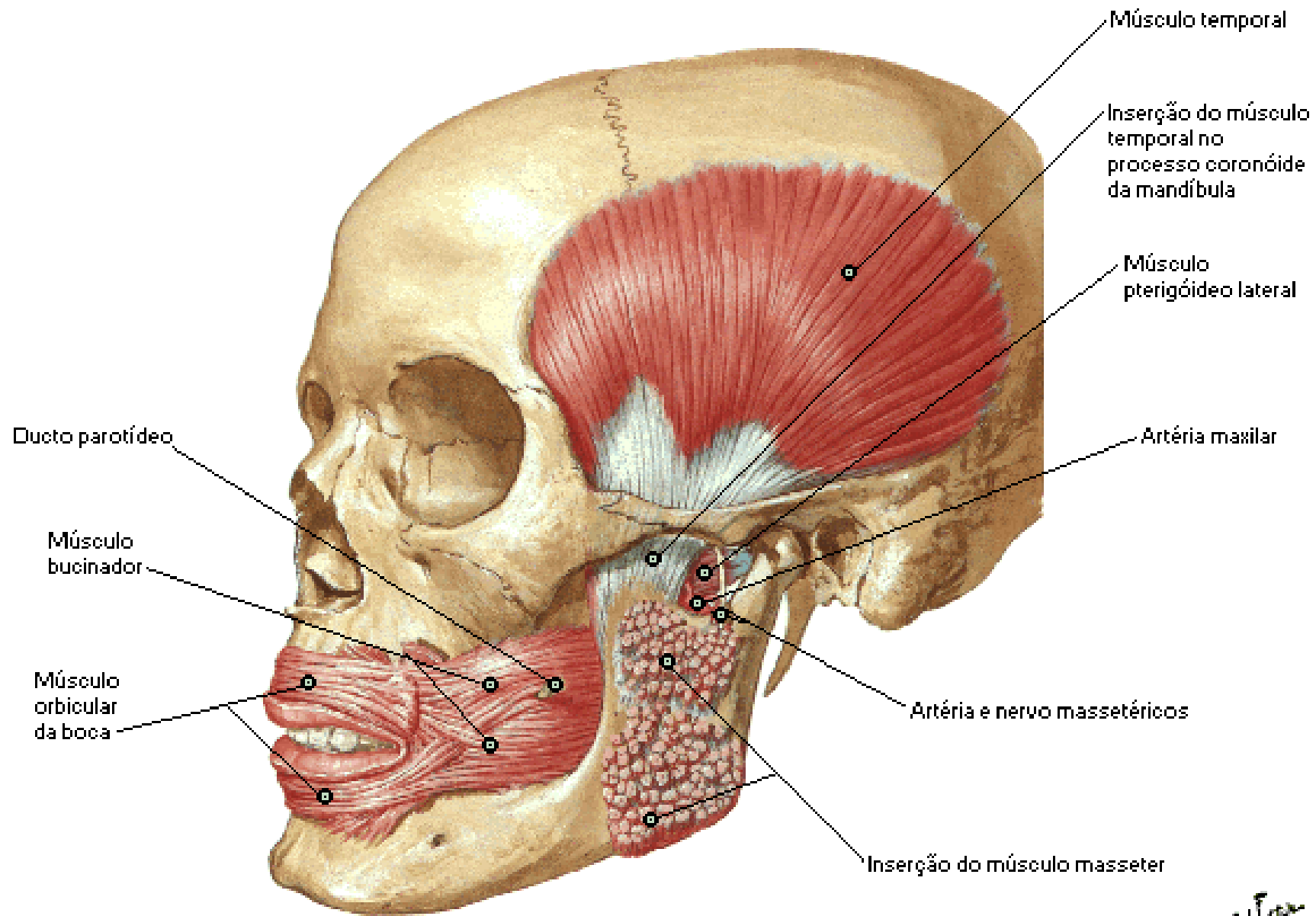
Músculos Envolvidos na Mastigação

Vista Lateral



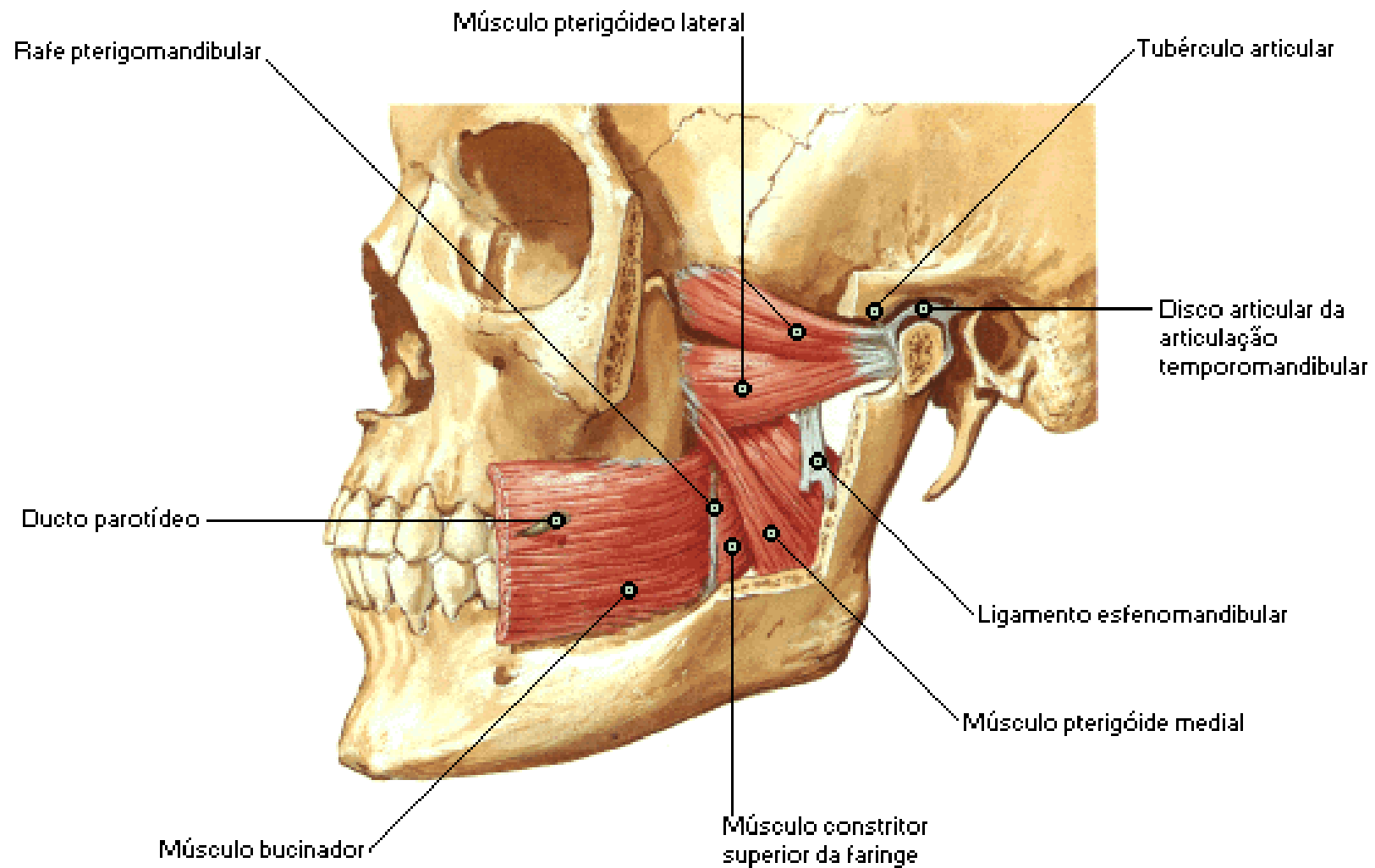
Músculos Envolvidos na Mastigação - Masseter Removido

Vista Lateral



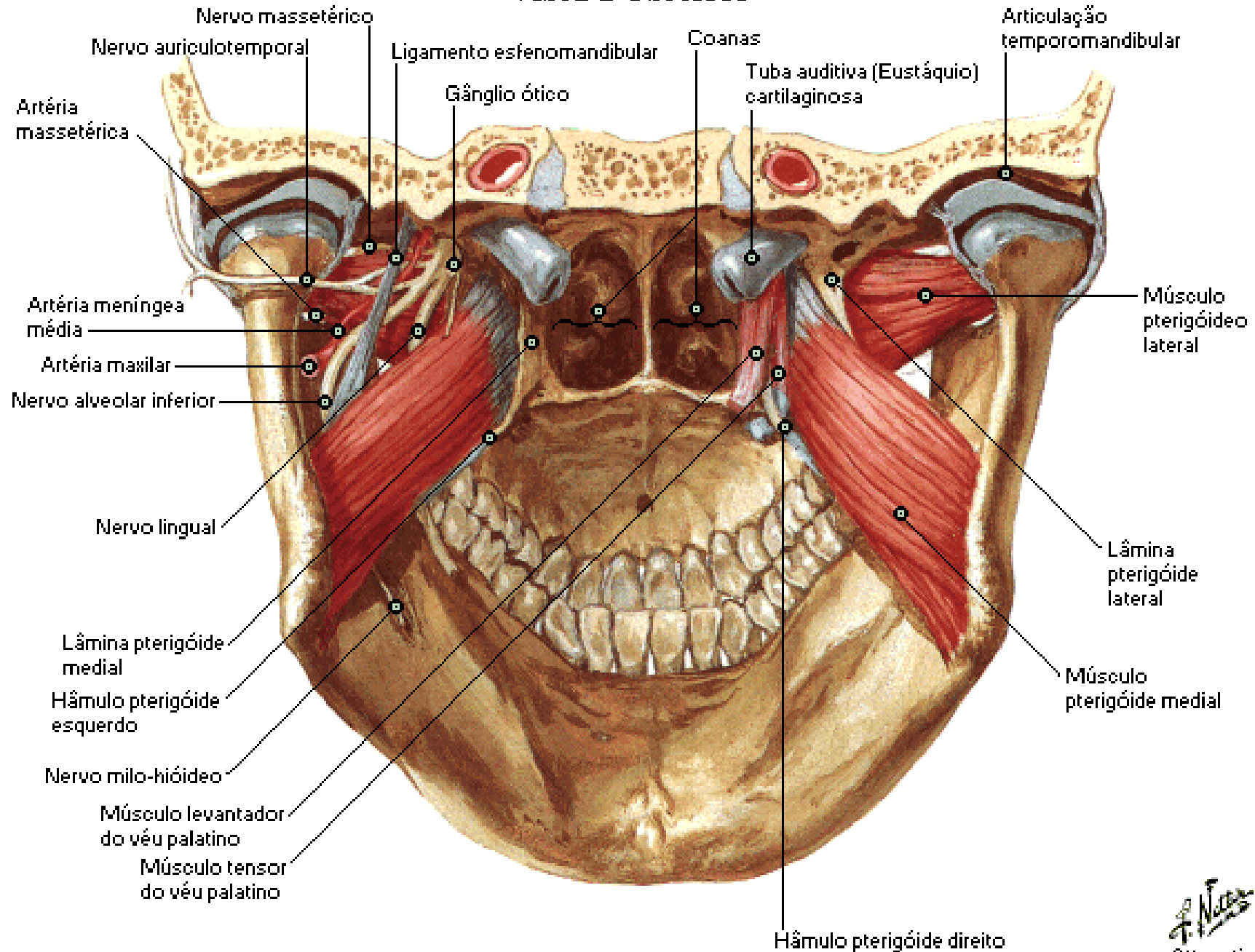
Músculos Envolvidos na Mastigação

Vista Lateral



Músculos Envolvidos na Mastigação

Vista Posterior

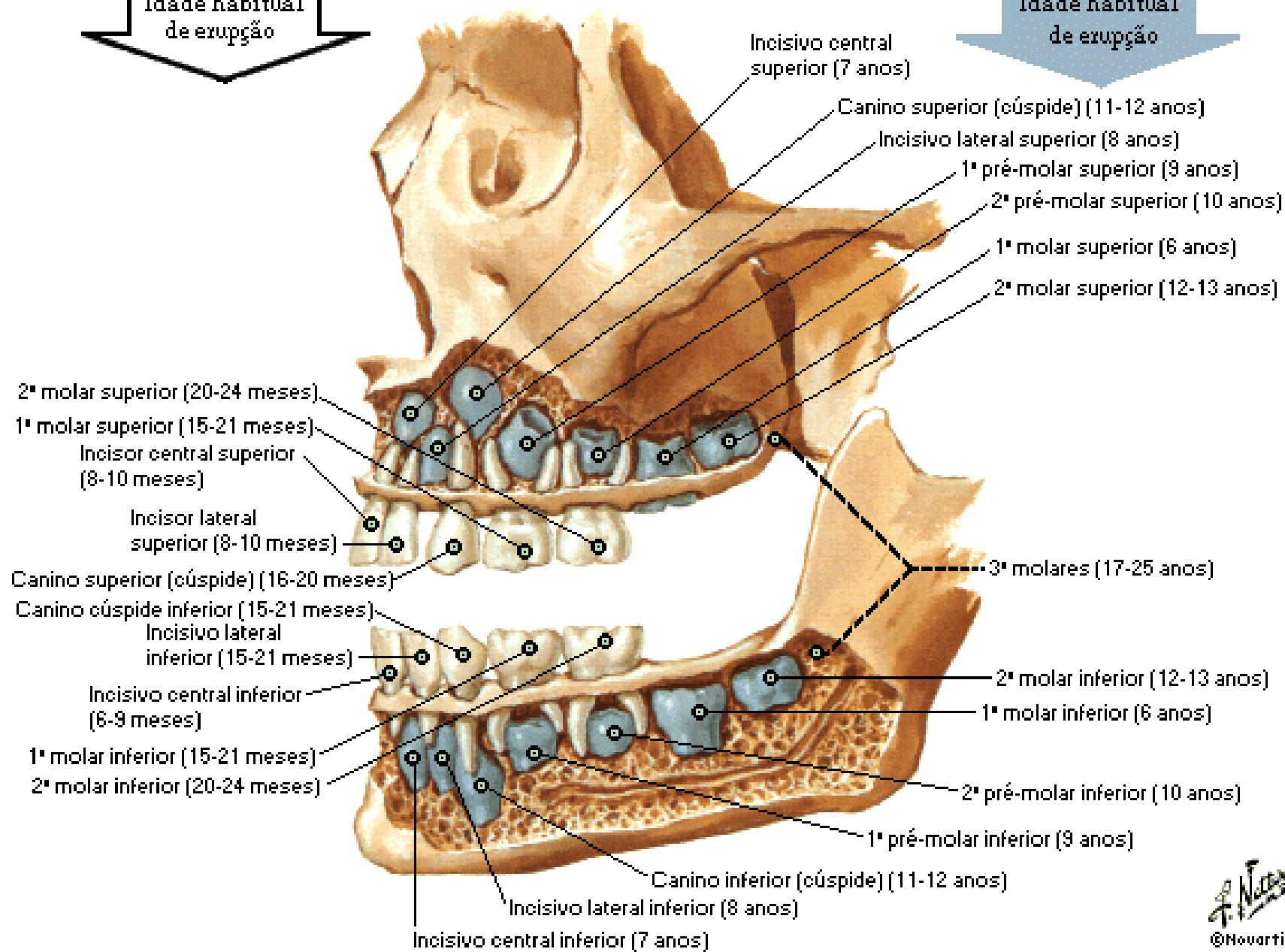


Dentes - Decíduos e Permanentes

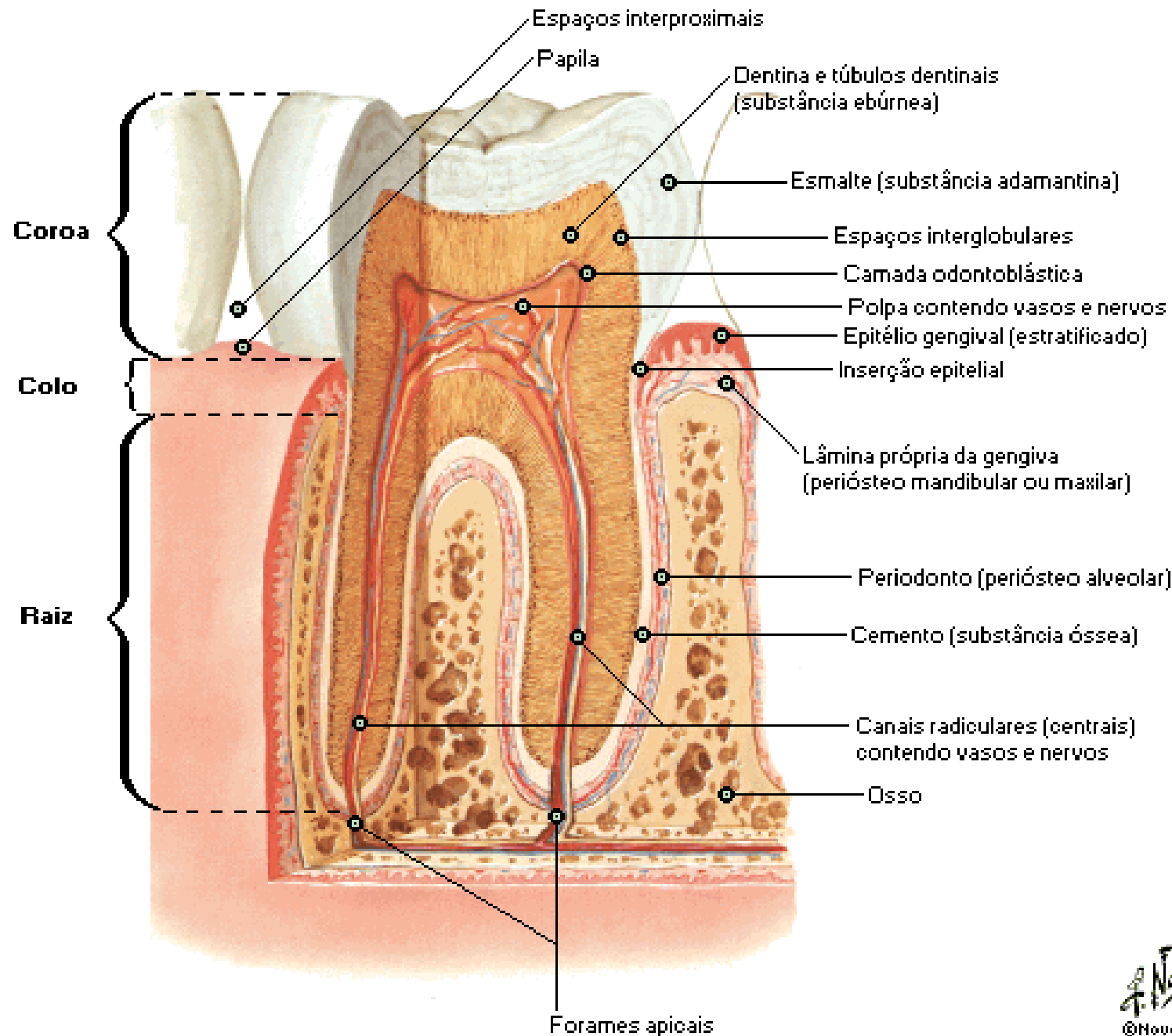
Decíduos
(primários)
Idade habitual
de erupção

Idade de Erupção

Permanentes
(coloridos de azul)
Idade habitual
de erupção

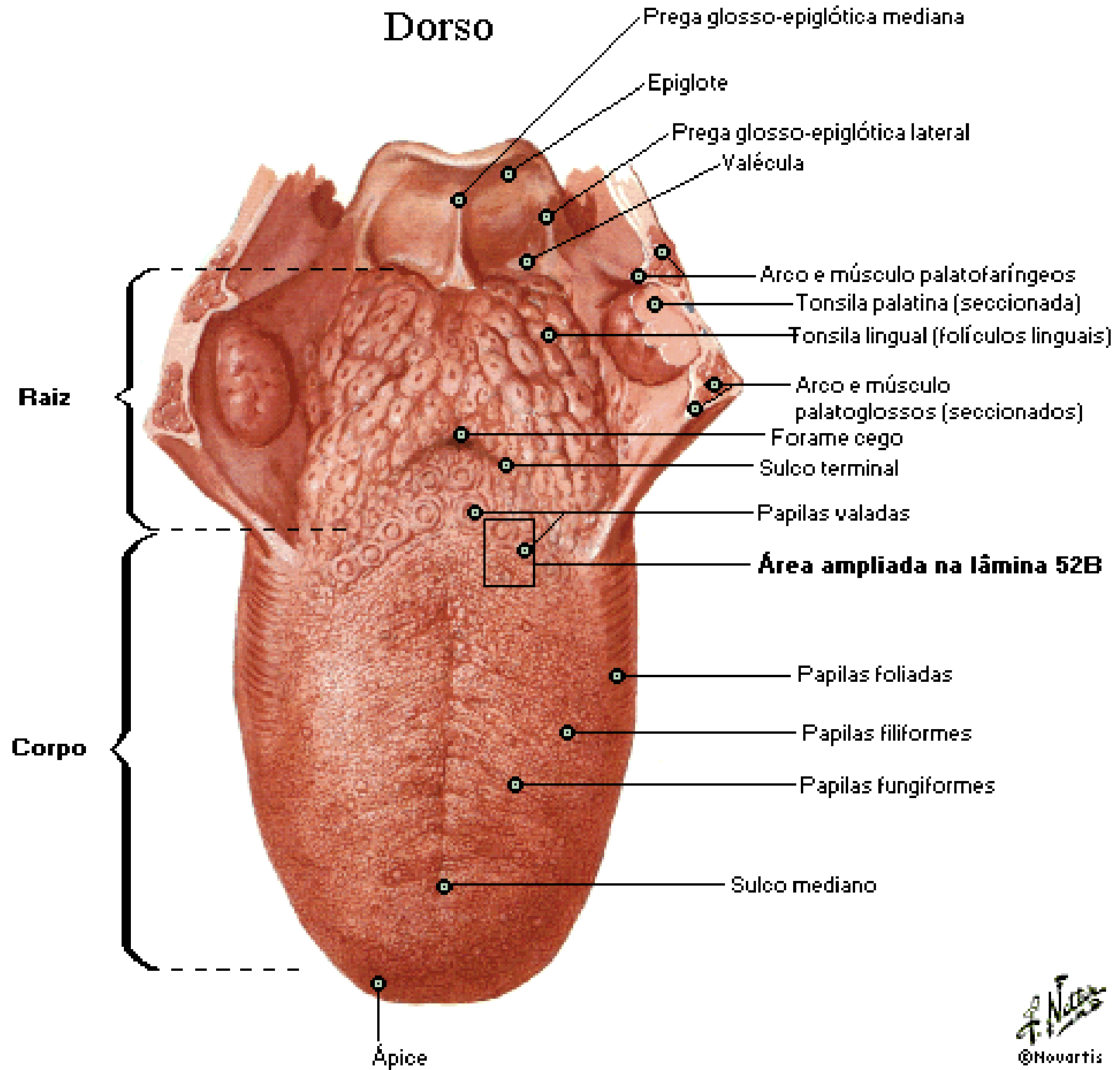


Anatomia de um Dente



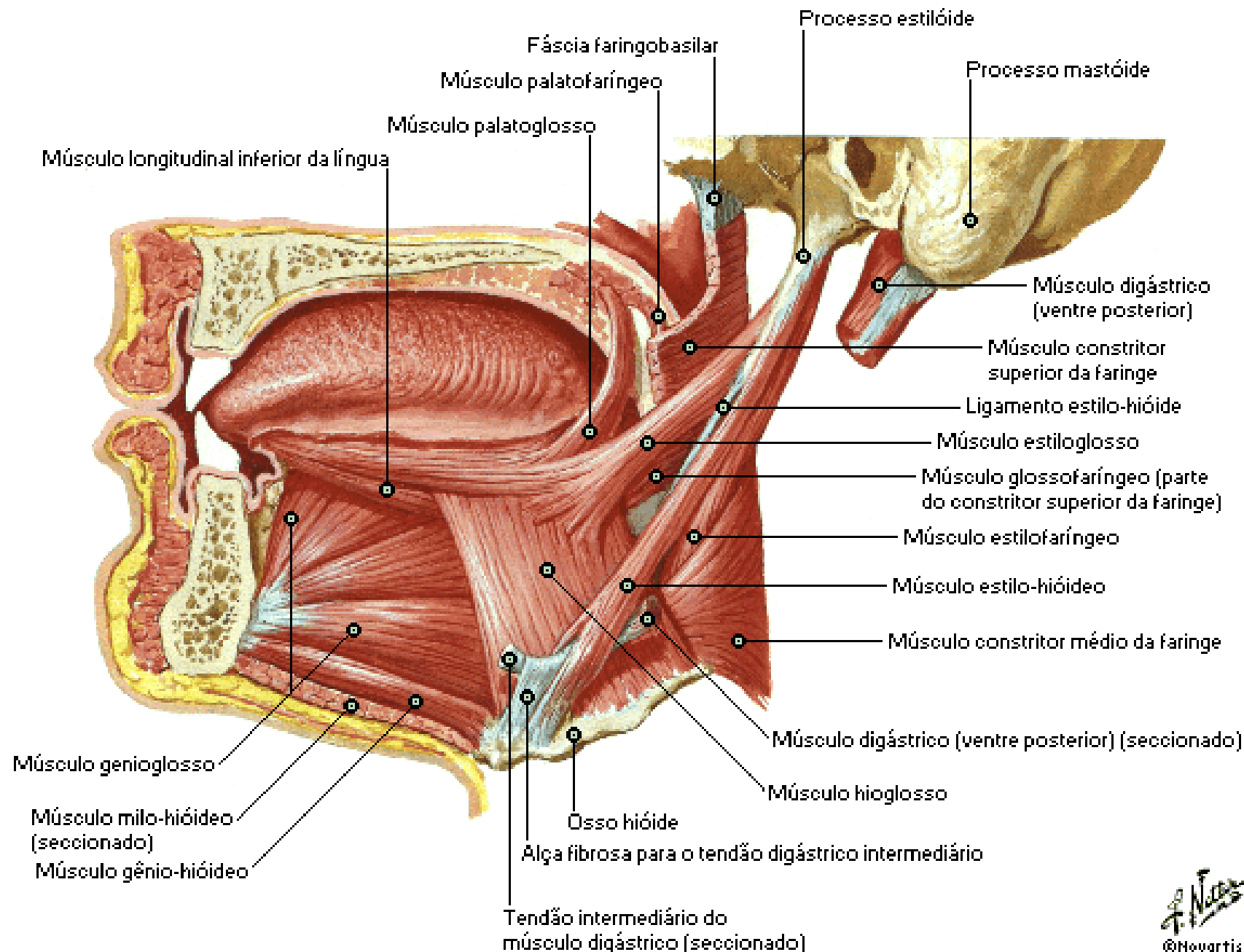
Língua

Dorso



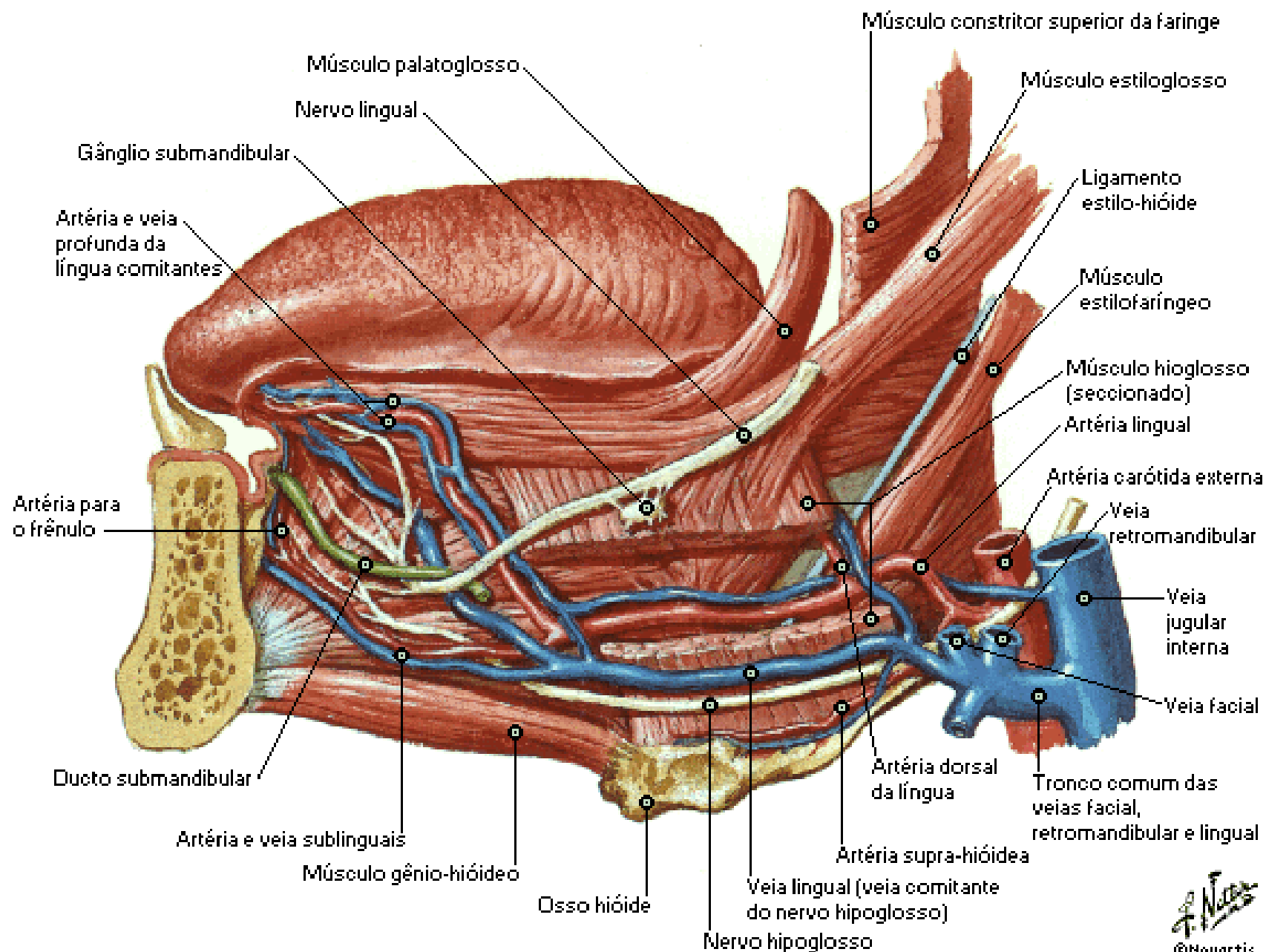
Músculos da Língua

Secção Sagital



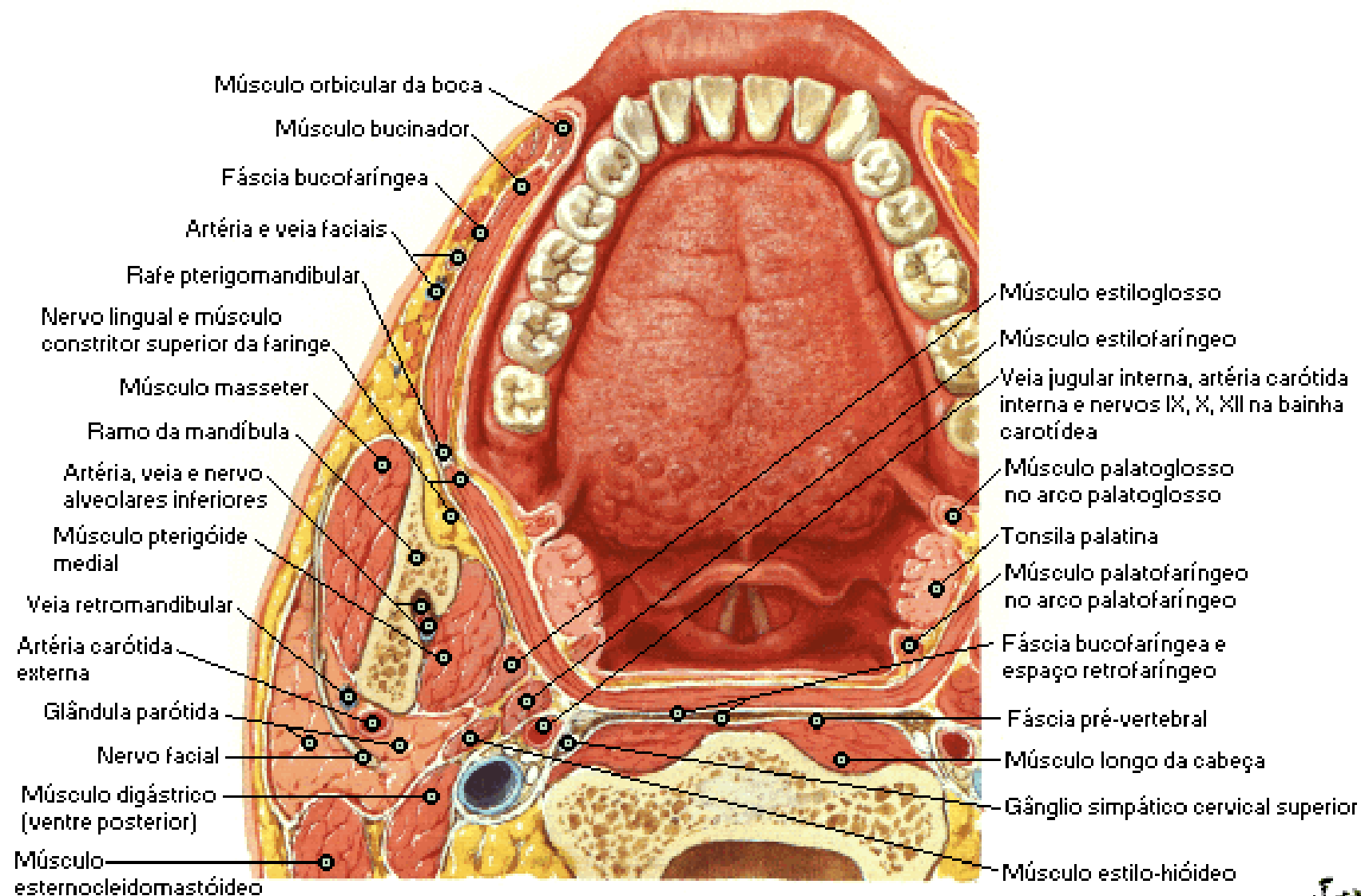
Língua e Estruturas Relacionadas

Secção Sagital



Língua e Boca

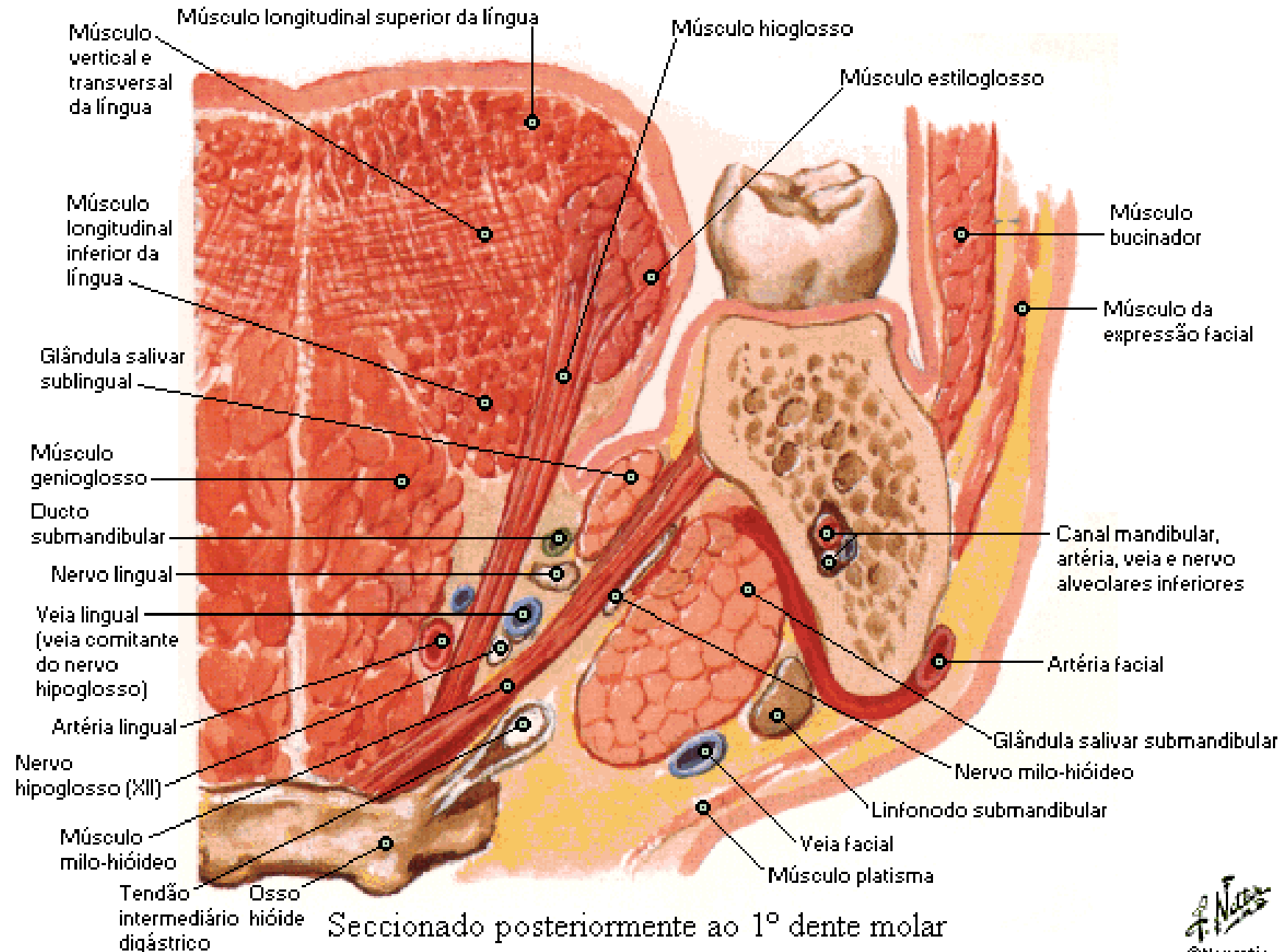
Secção Horizontal - Vista Posterior



Seccionado abaixo da língua da mandíbula

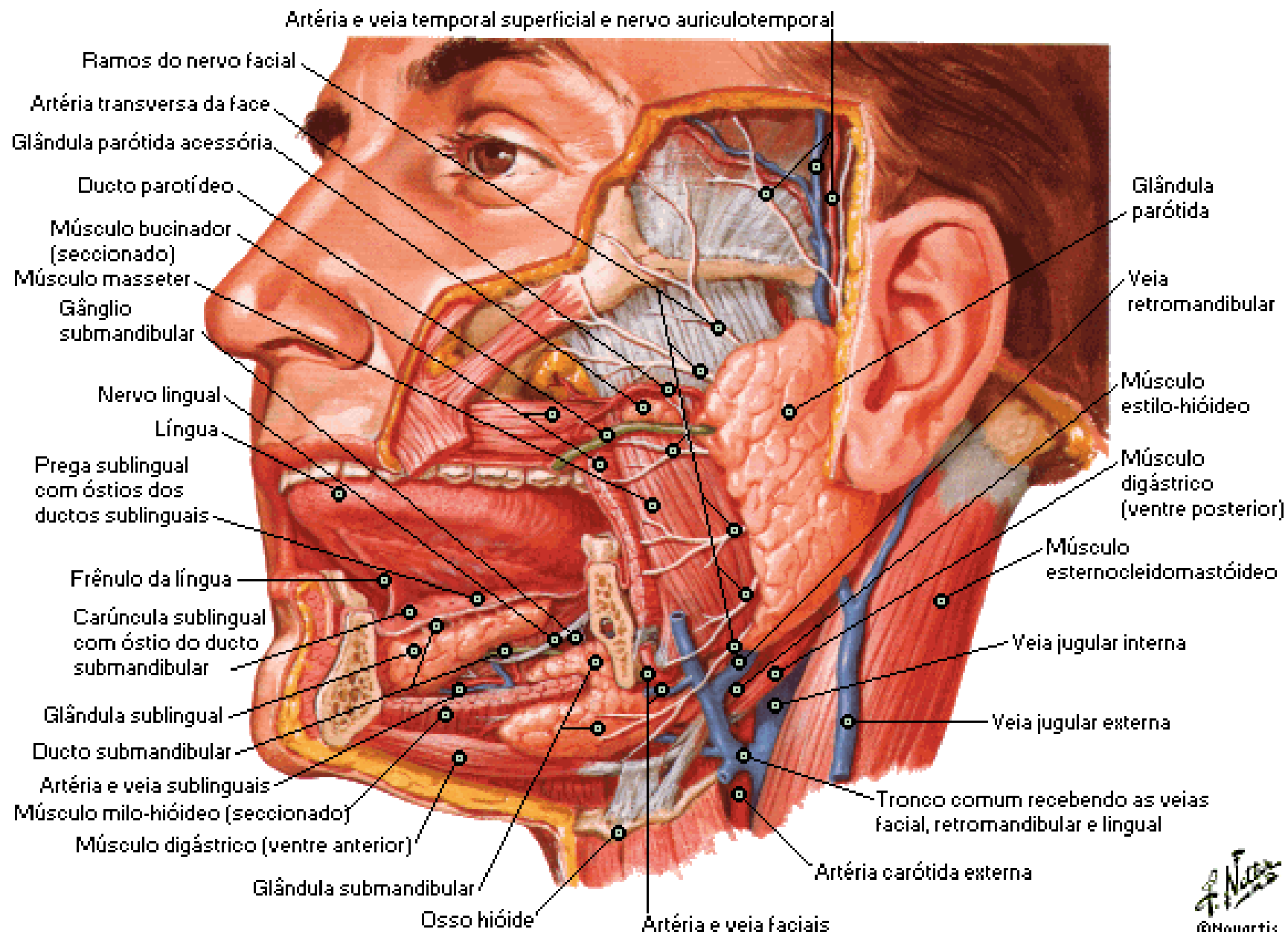
Língua e Boca

Secção Frontal - Vista Anterior



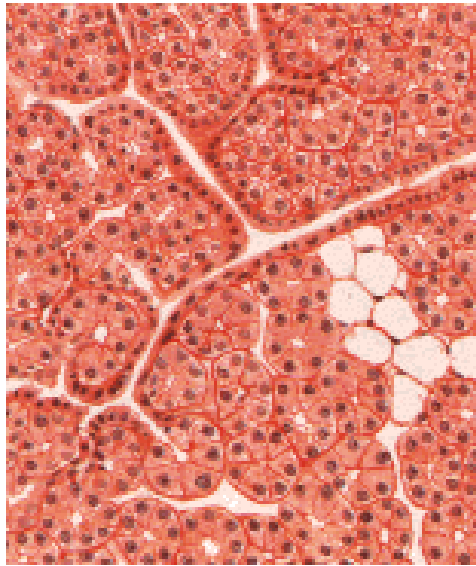
Glândulas Salivares

Dissecação

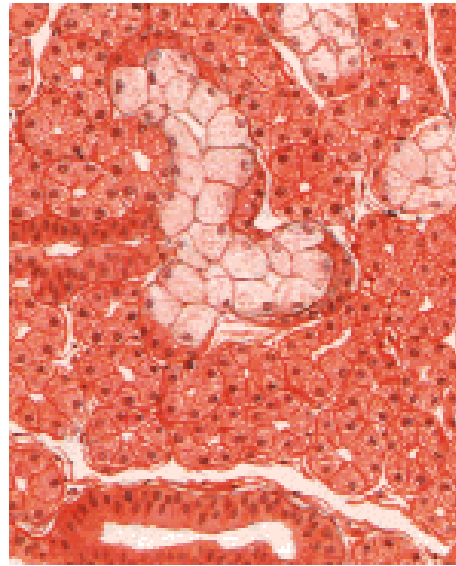


Glândulas Salivares

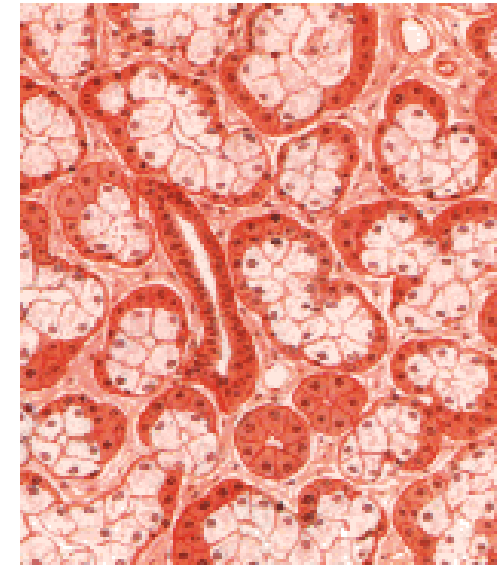
Histologia



Glândula parótida: totalmente serosa



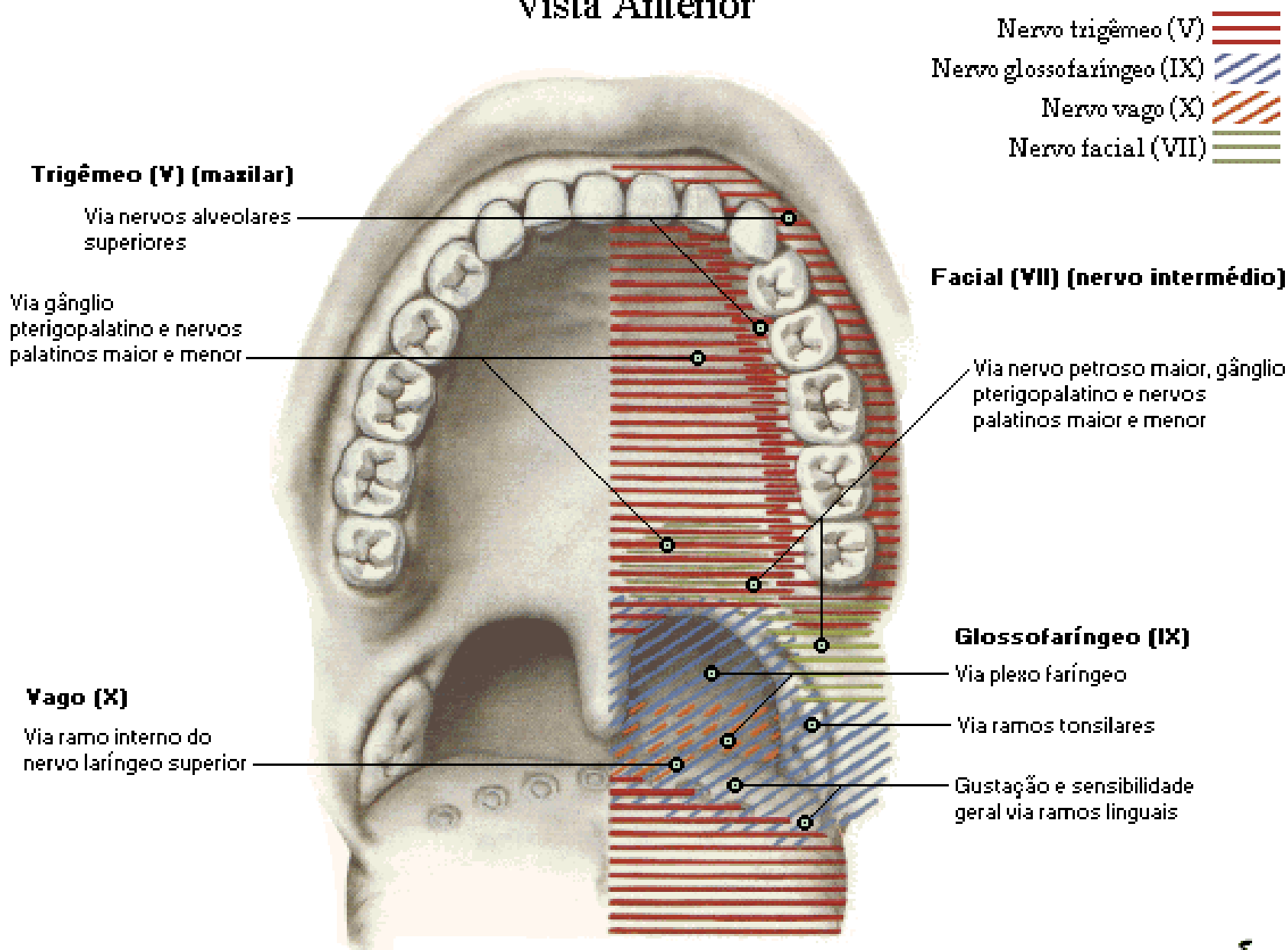
Glândula submandibular:
principalmente serosa,
parcialmente mucosa



Glândula sublingual: quase
completamente mucosa

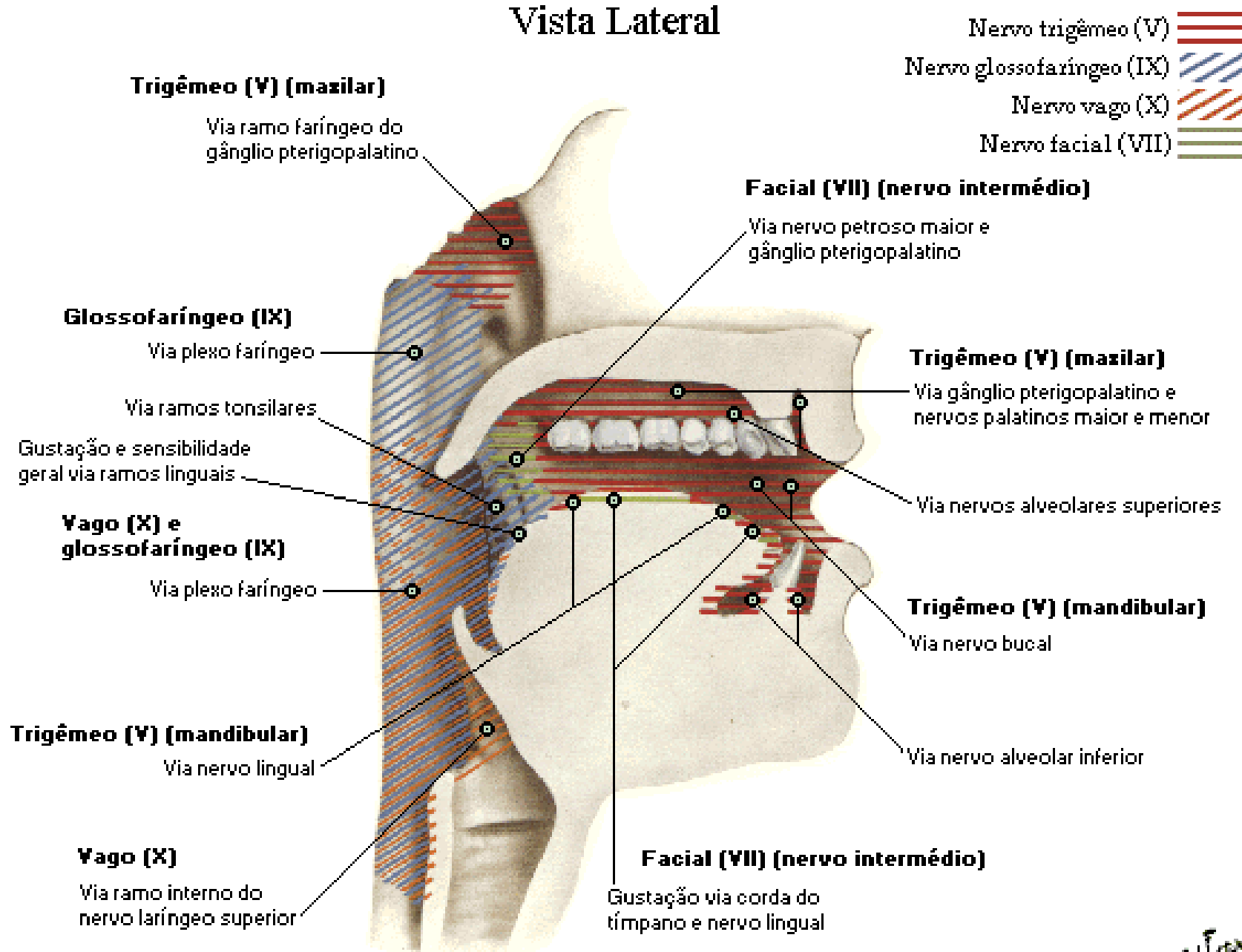
Inervação Aferente da Cavidade da Boca e Faringe

Vista Anterior



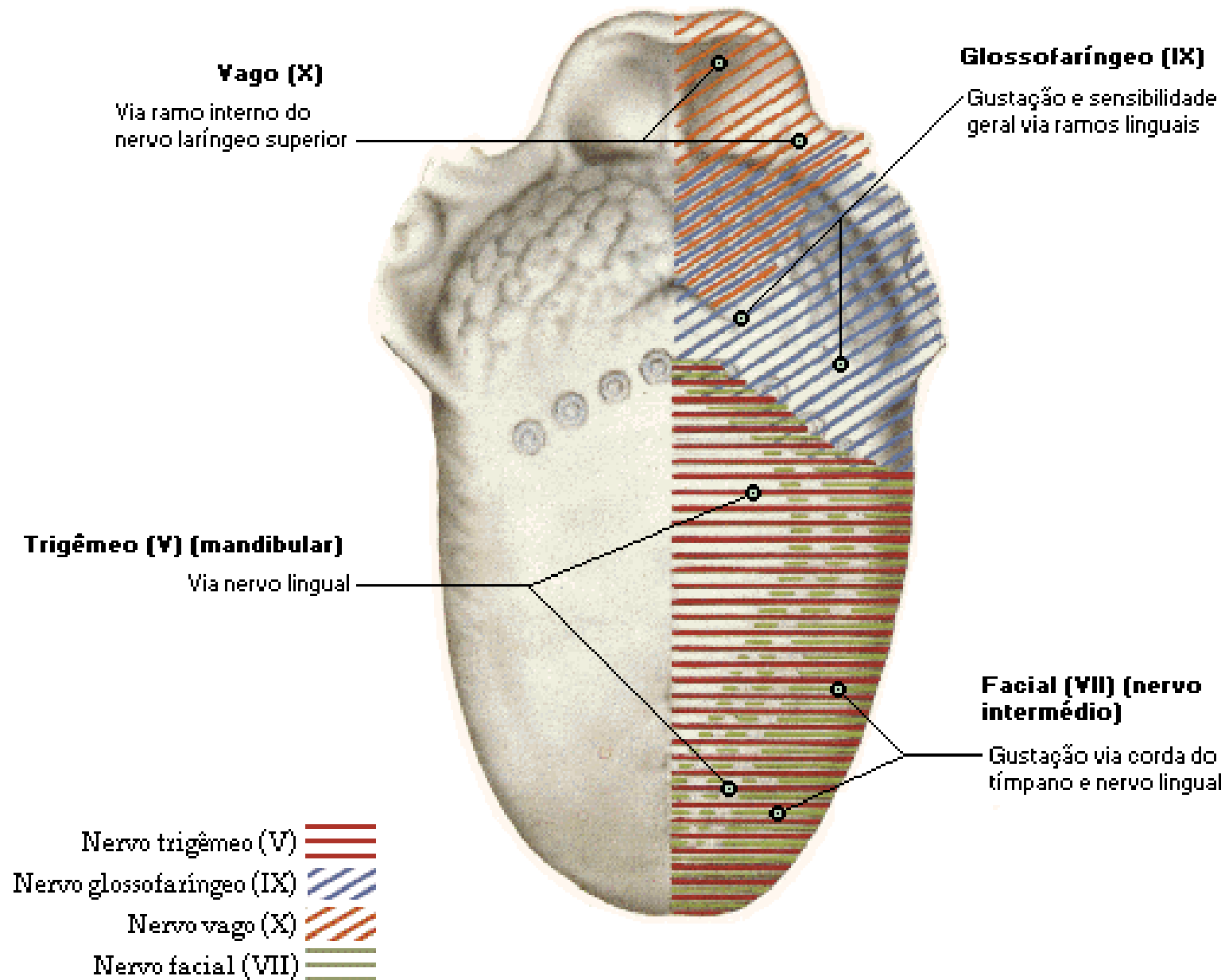
Inervação Aferente da Cavidade da Boca e Faringe

Vista Lateral



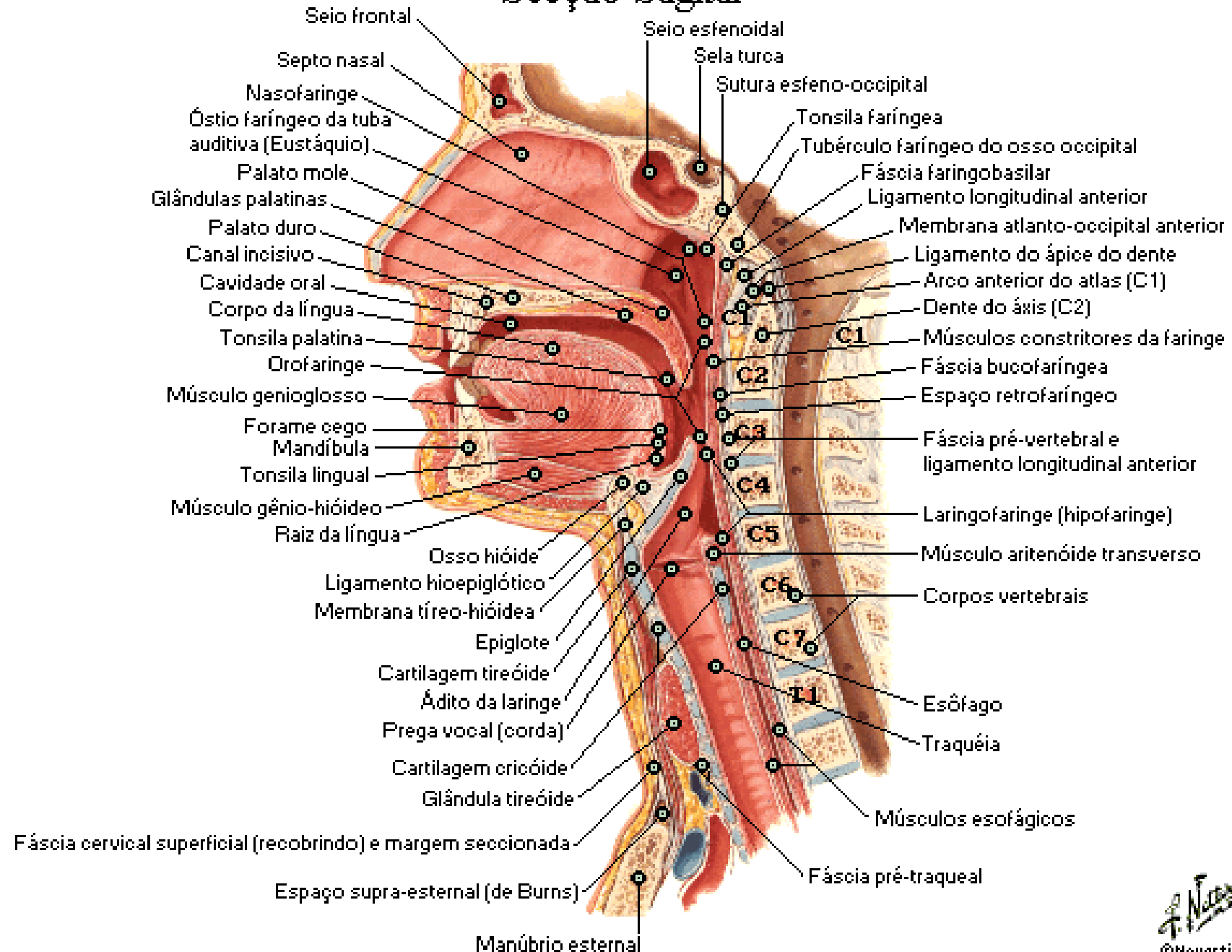
Inervação Aferente da Cavidade da Boca e Faringe

Dorso da Língua



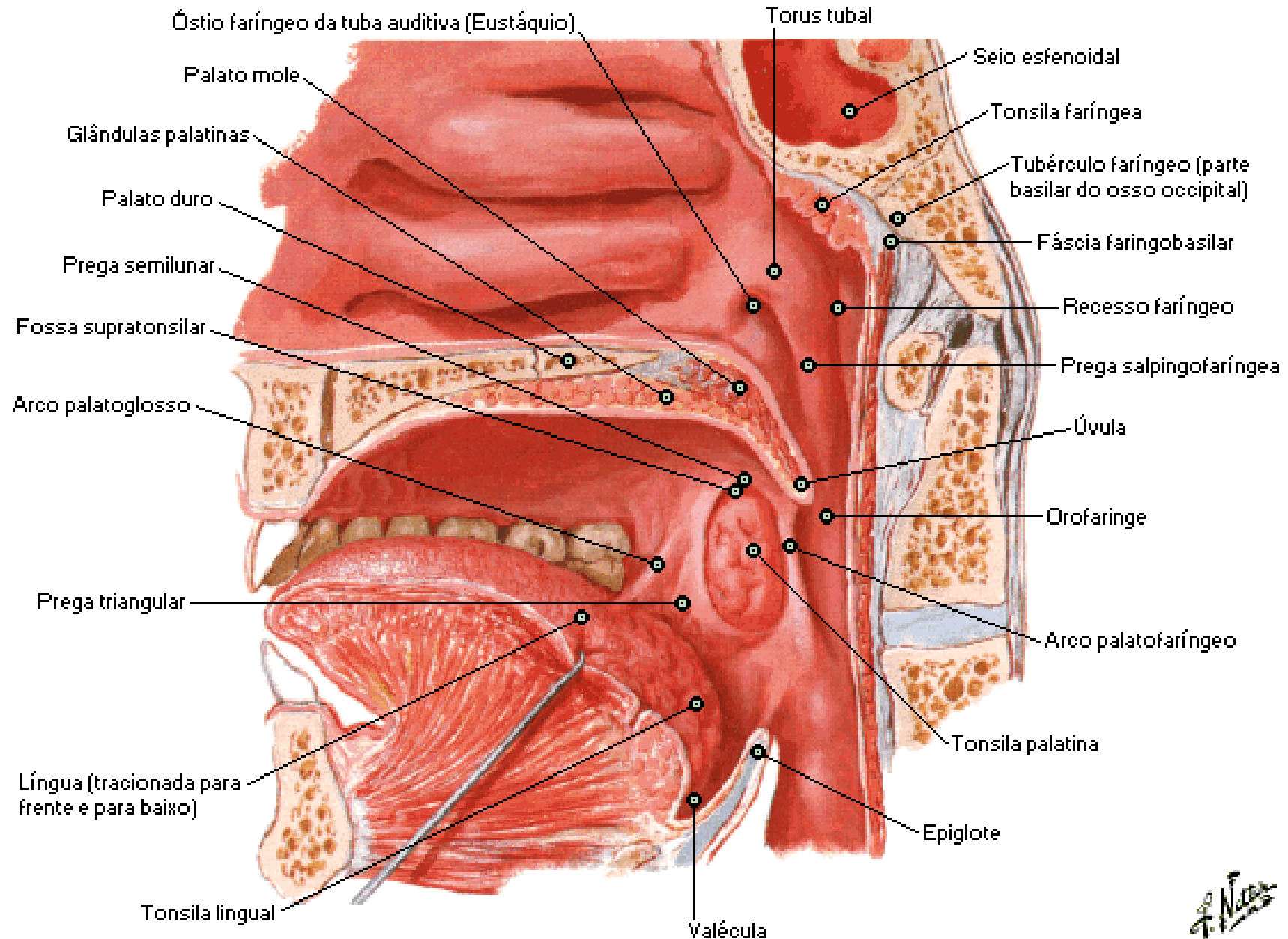
Faringe

Secção Sagital



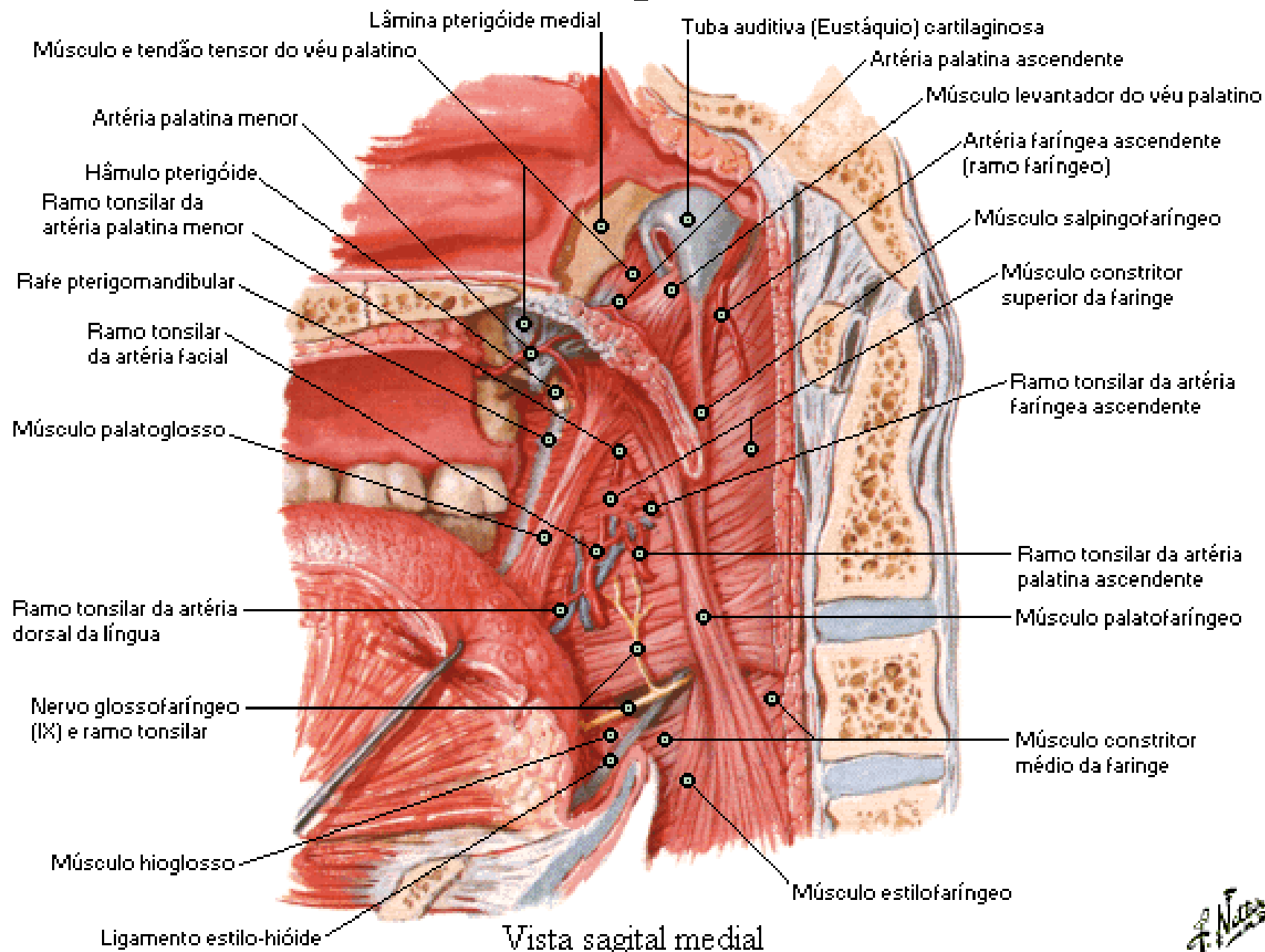
Fauces

Vista Sagital Medial



Fauces

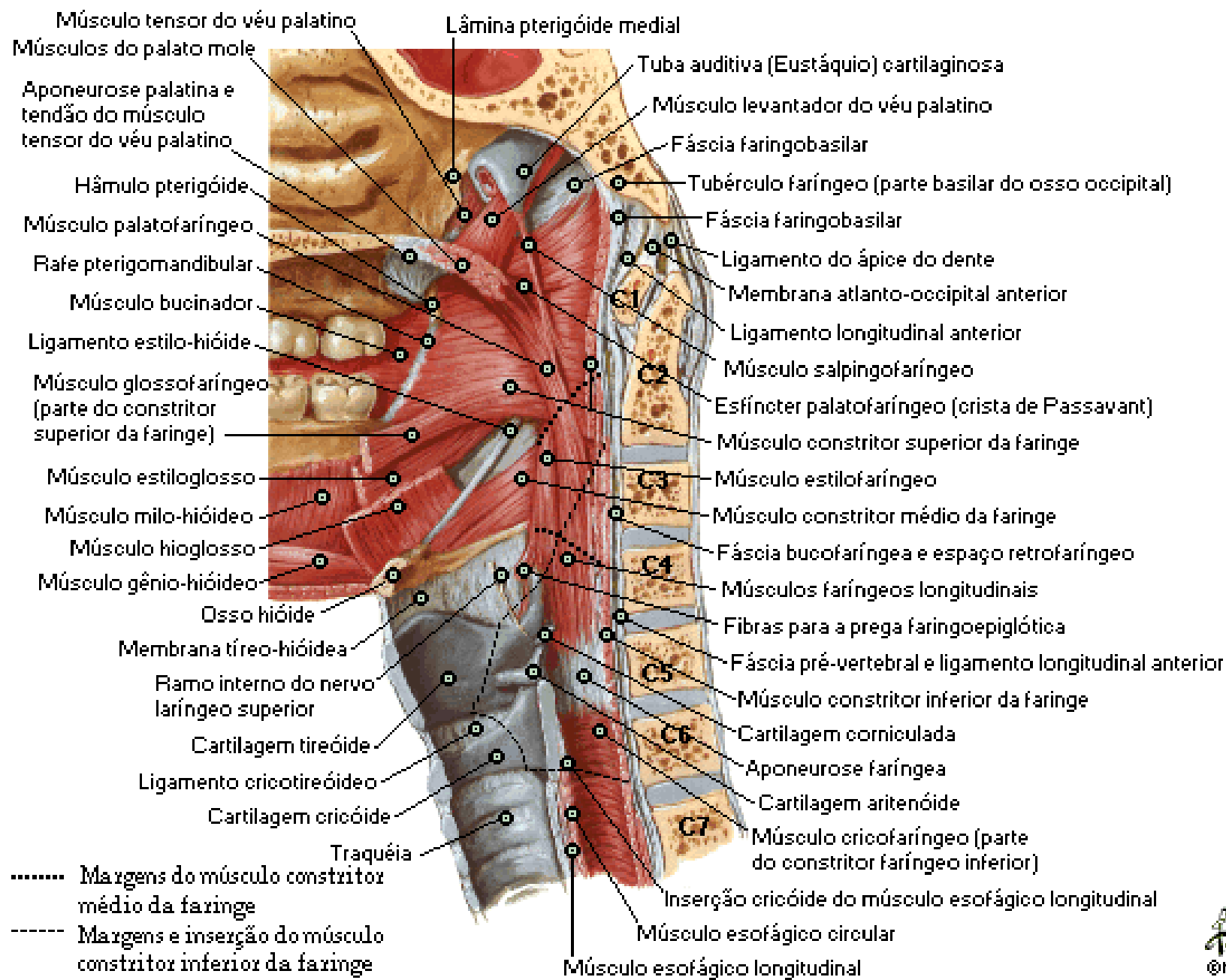
Mucosa Faríngea Removida



Vista sagital medial

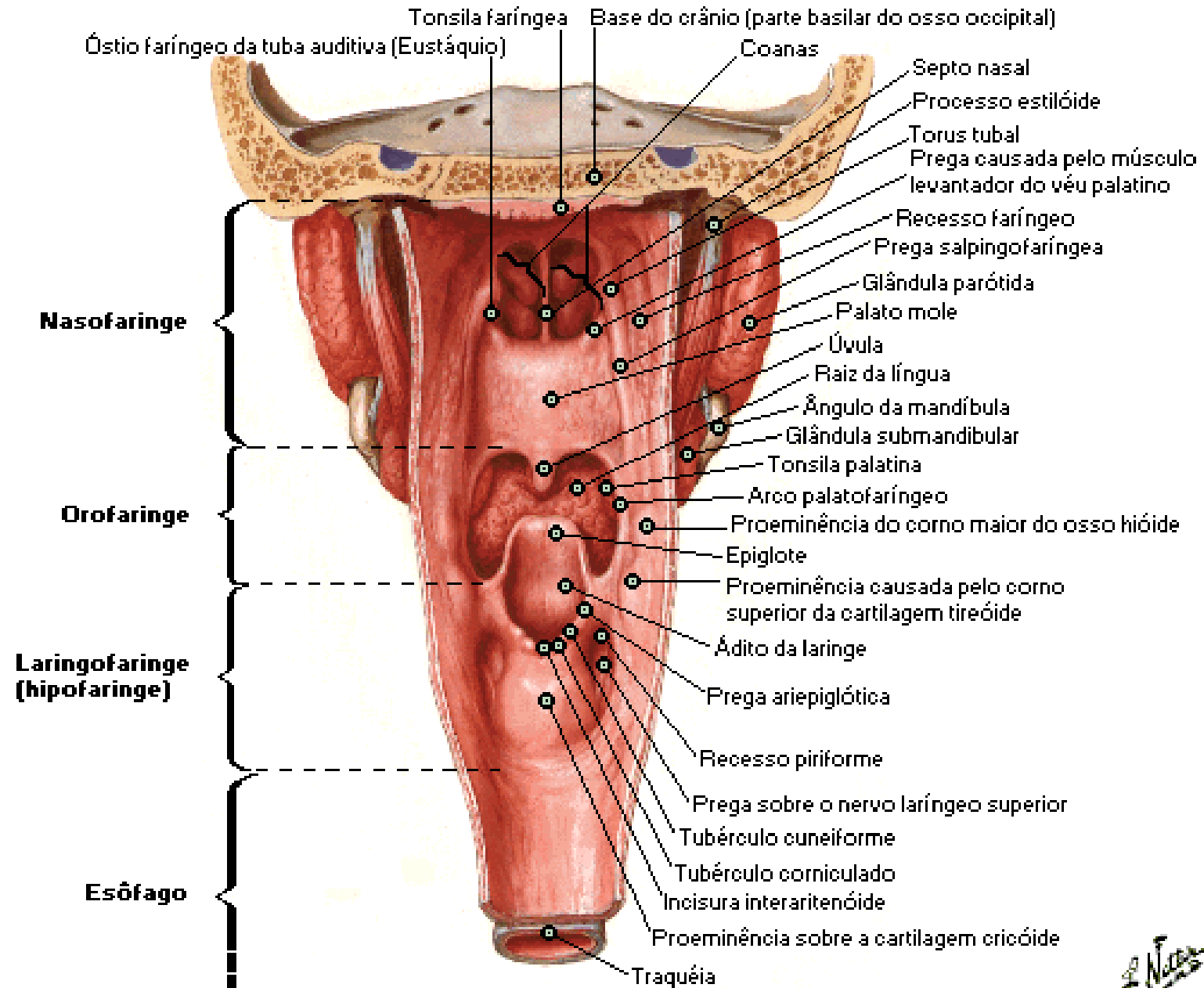
Músculos da Faringe

Secção Sagital



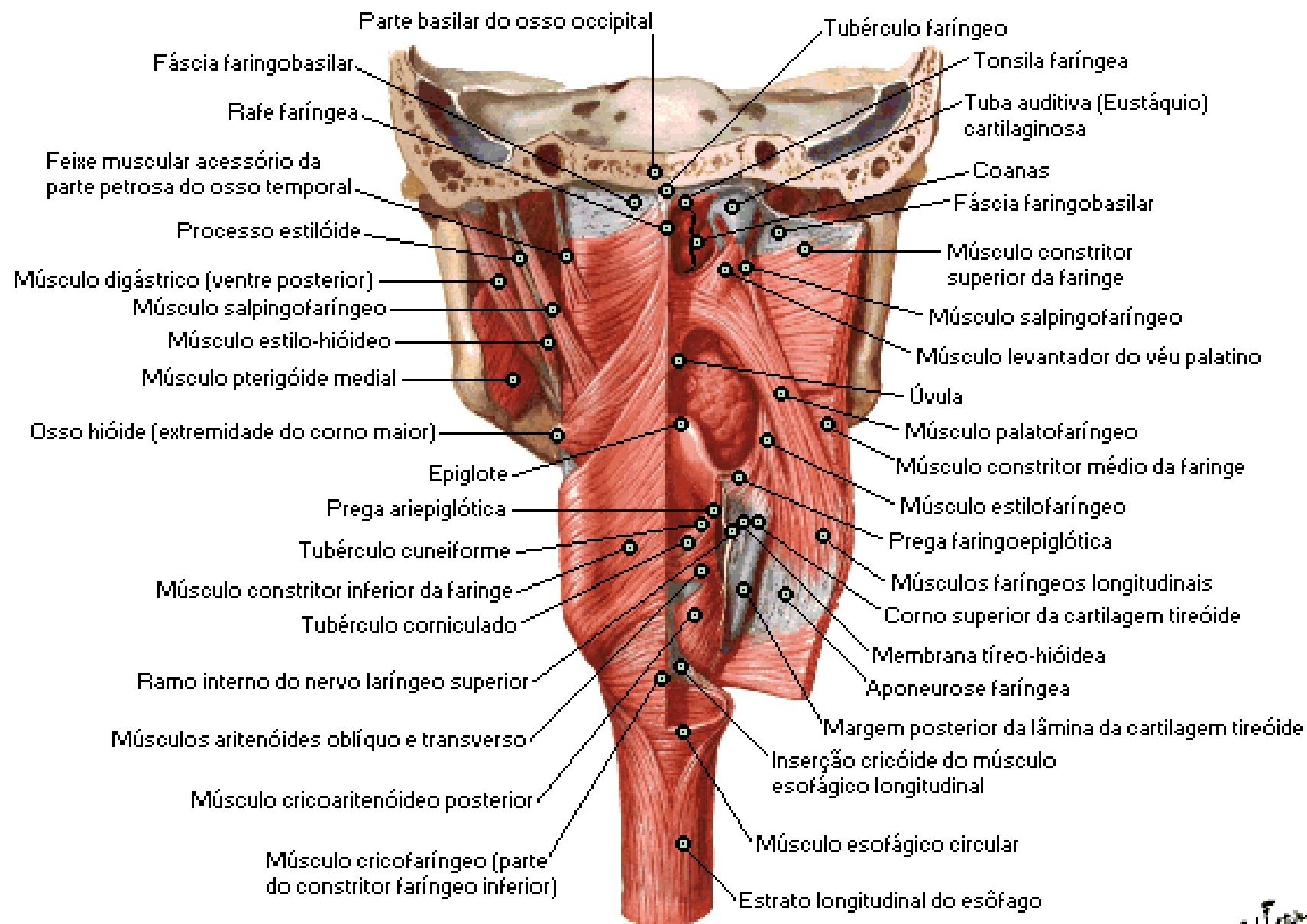
Faringe

Vista Posterior Seccionada



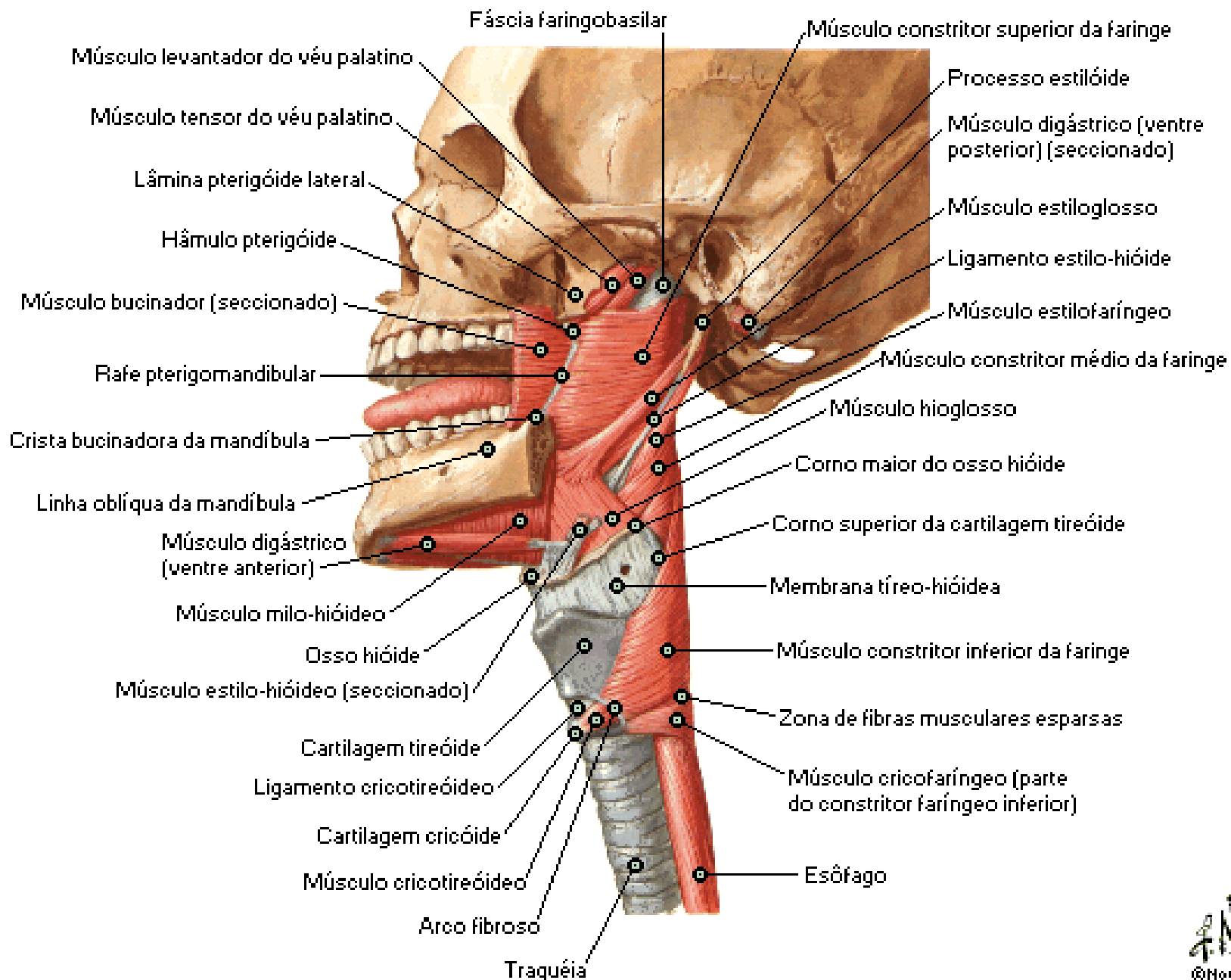
Músculos da Faringe

Vista Posterior Parcialmente Seccionada

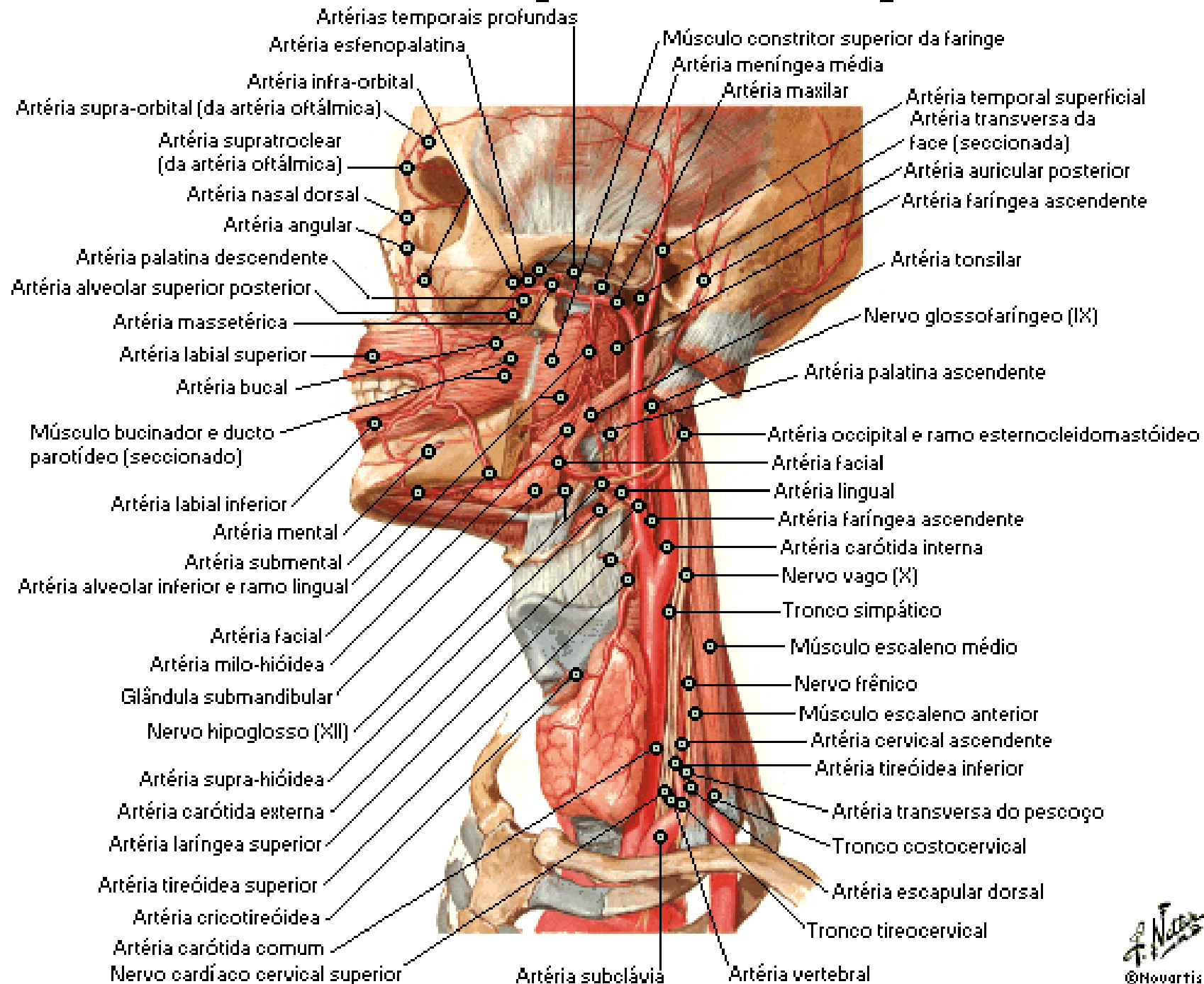


Músculos da Faringe

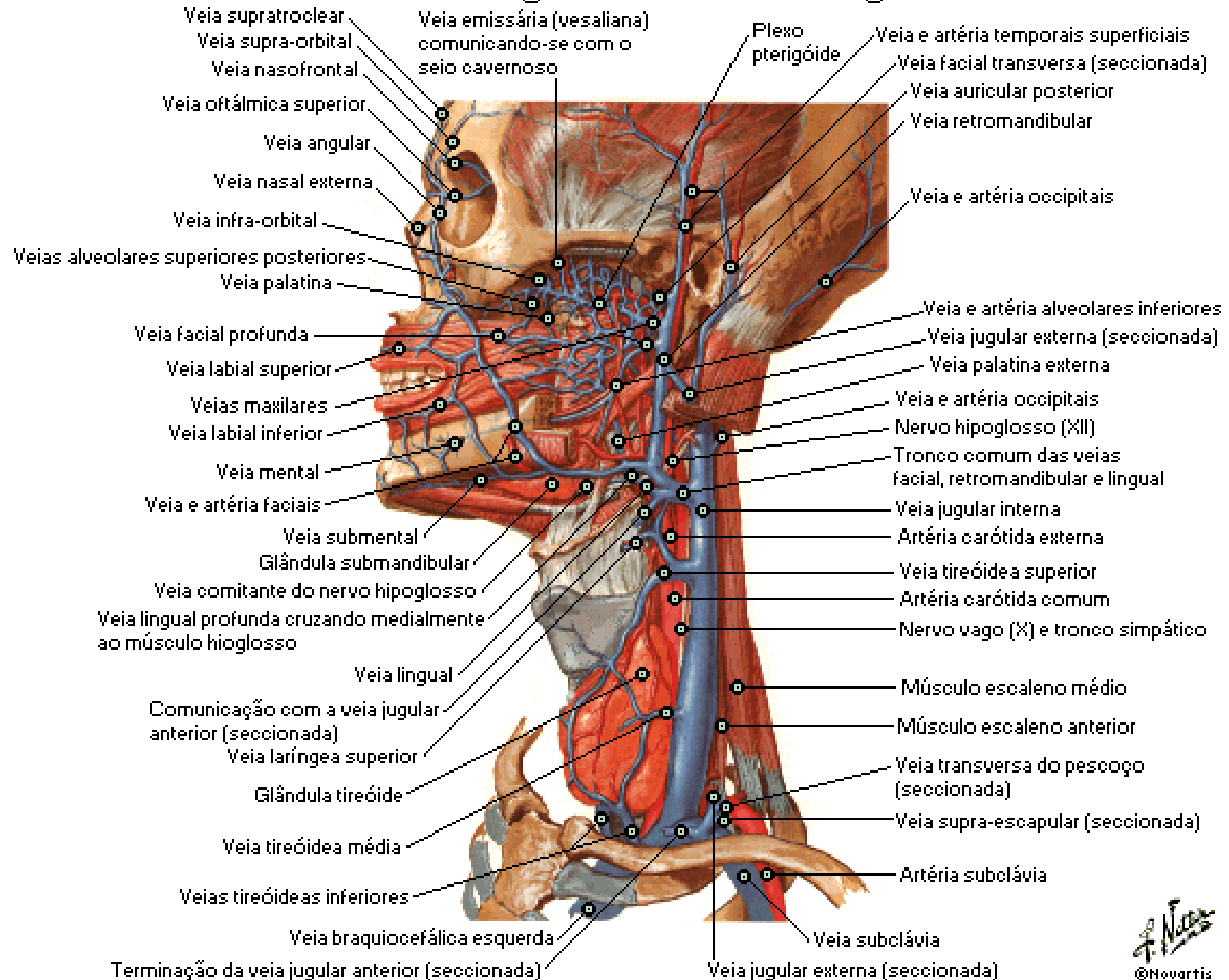
Vista Lateral



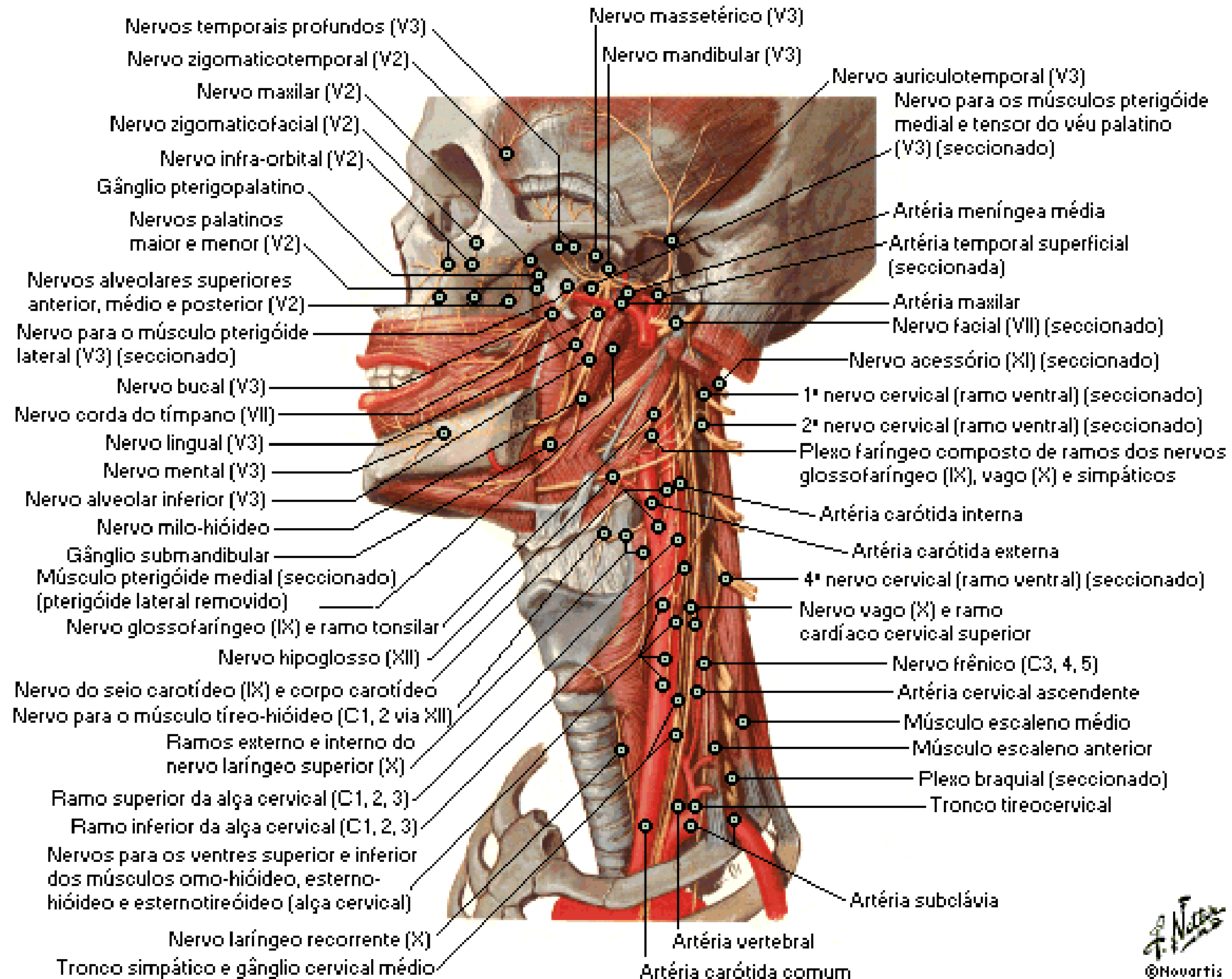
Artérias das Regiões Oral e Faríngea



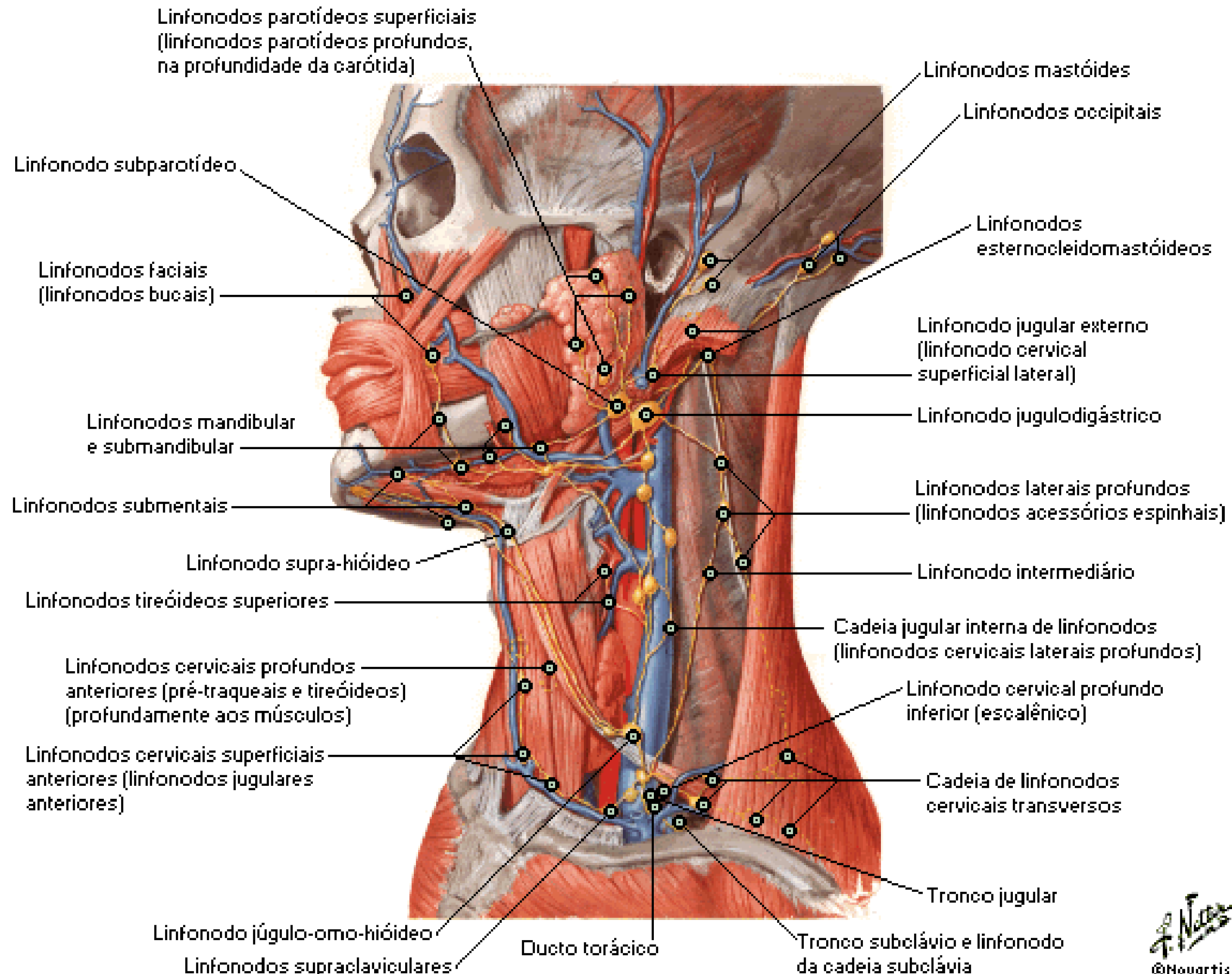
Veias das Regiões Oral e Faríngea



Nervos das Regiões Oral e Faríngea

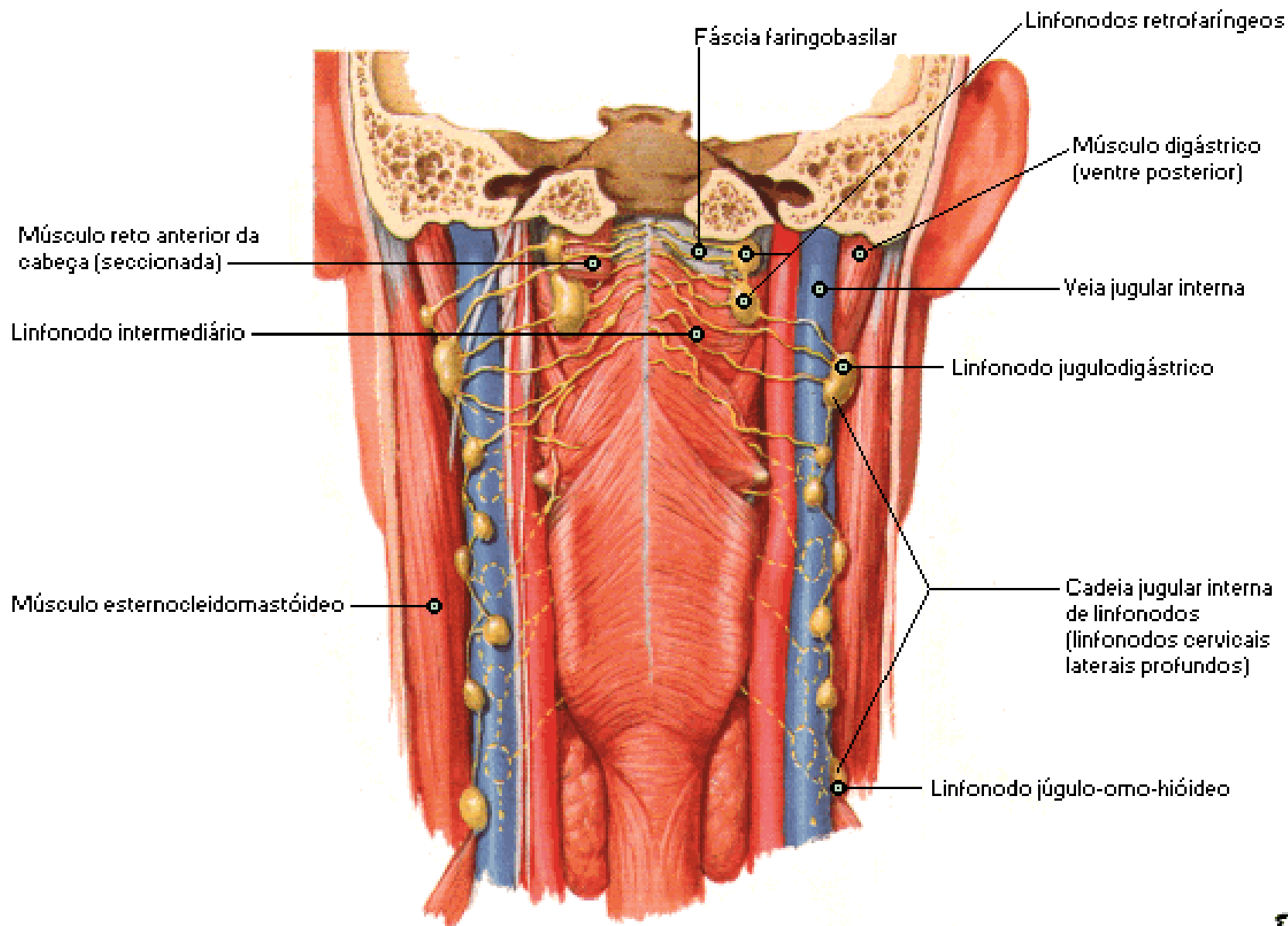


Vasos Linfáticos e Linfonodos das Regiões Oral e Faríngea



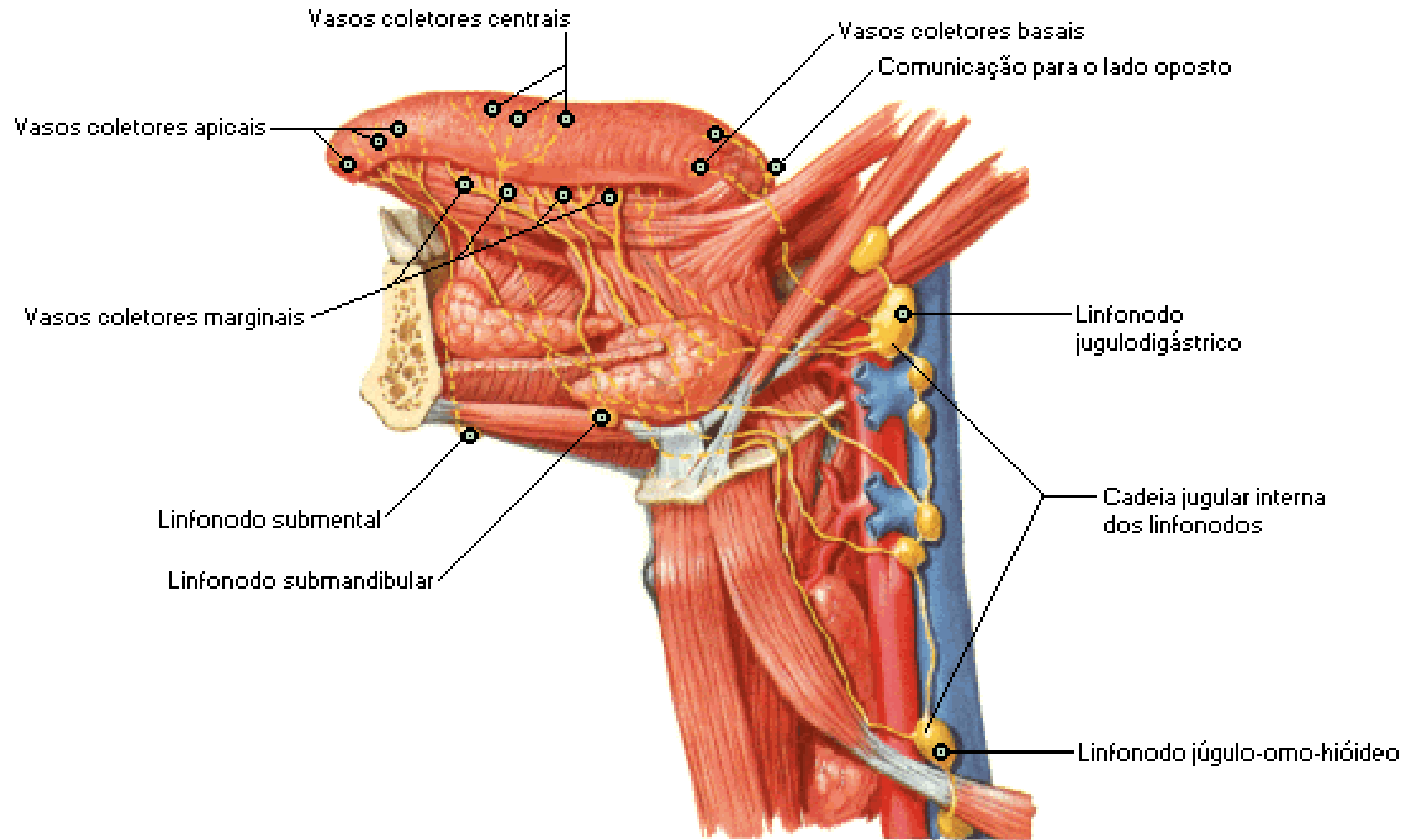
Drenagem Linfática da Laringe

Vista Posterior



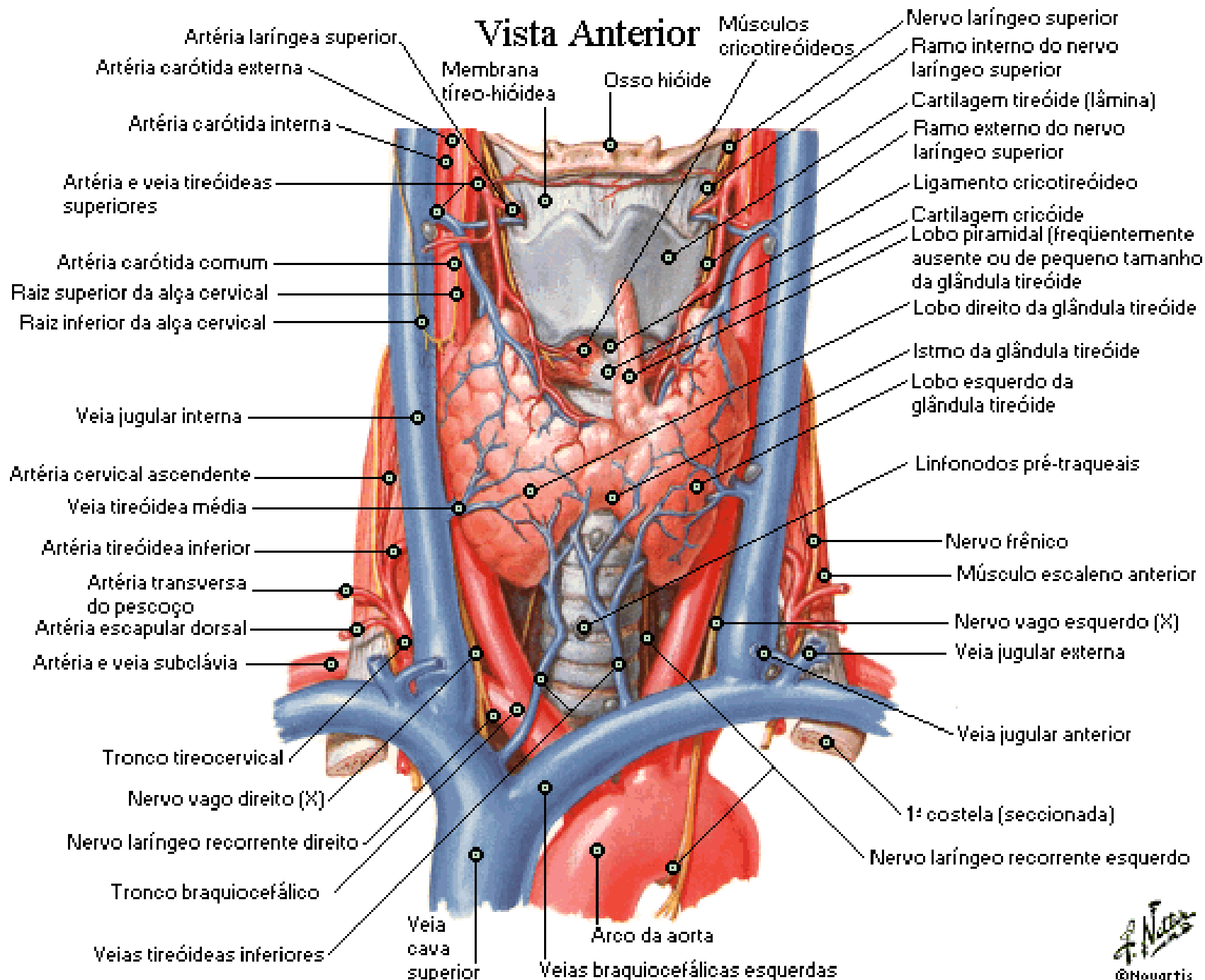
Drenagem Linfática da Língua

Vista Lateral



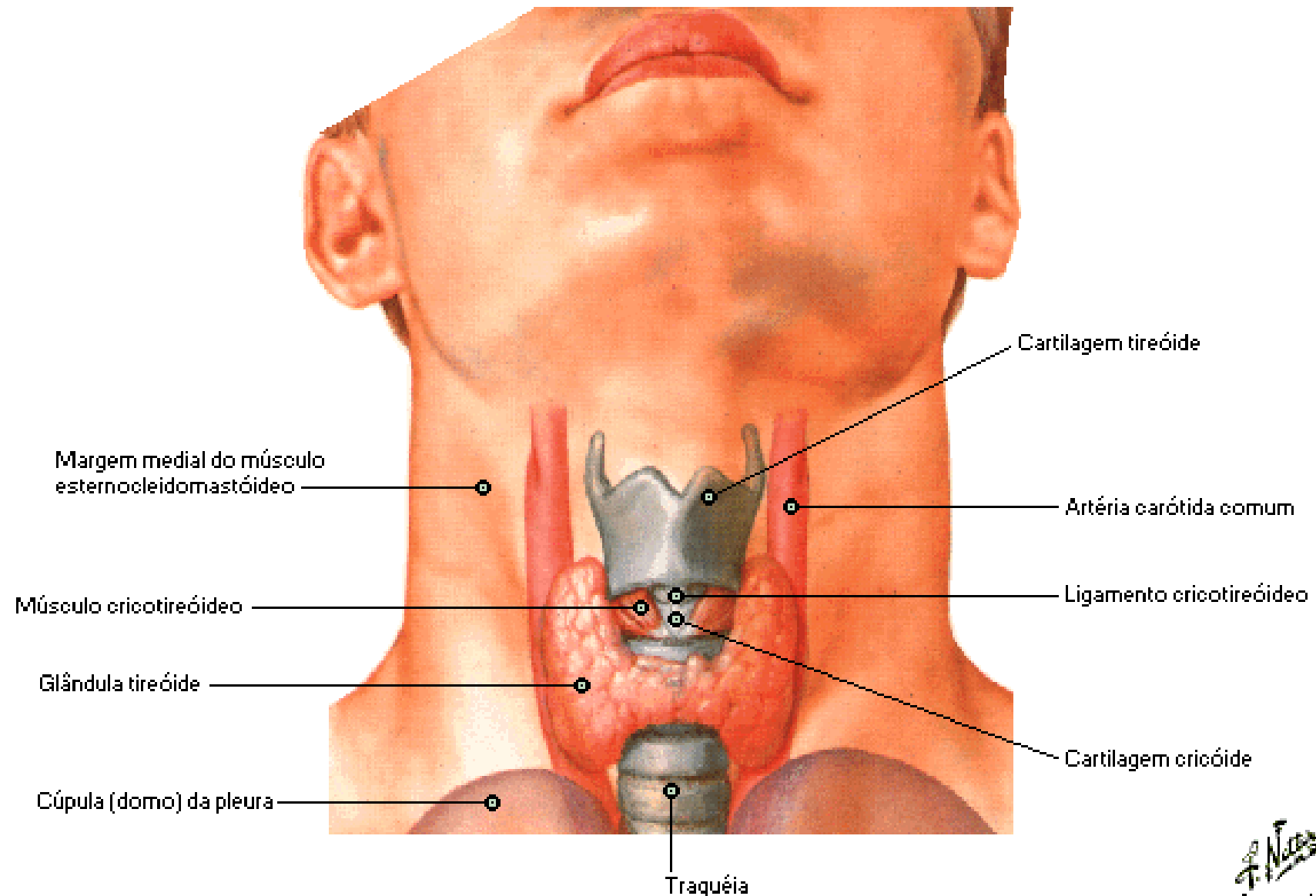
Glândula Tireóide

Vista Anterior



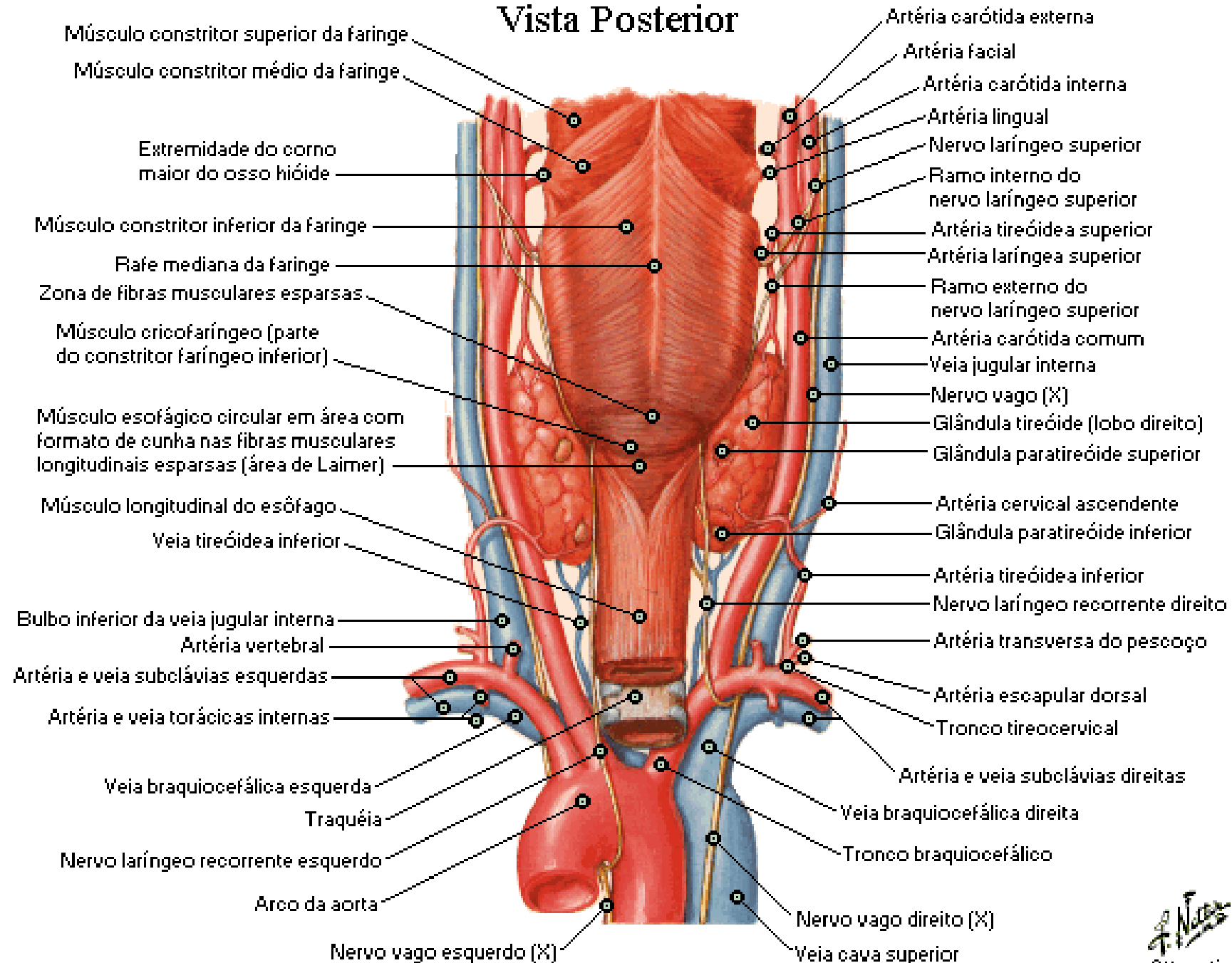
Glândula Tireóide in Situ

Vista Anterior



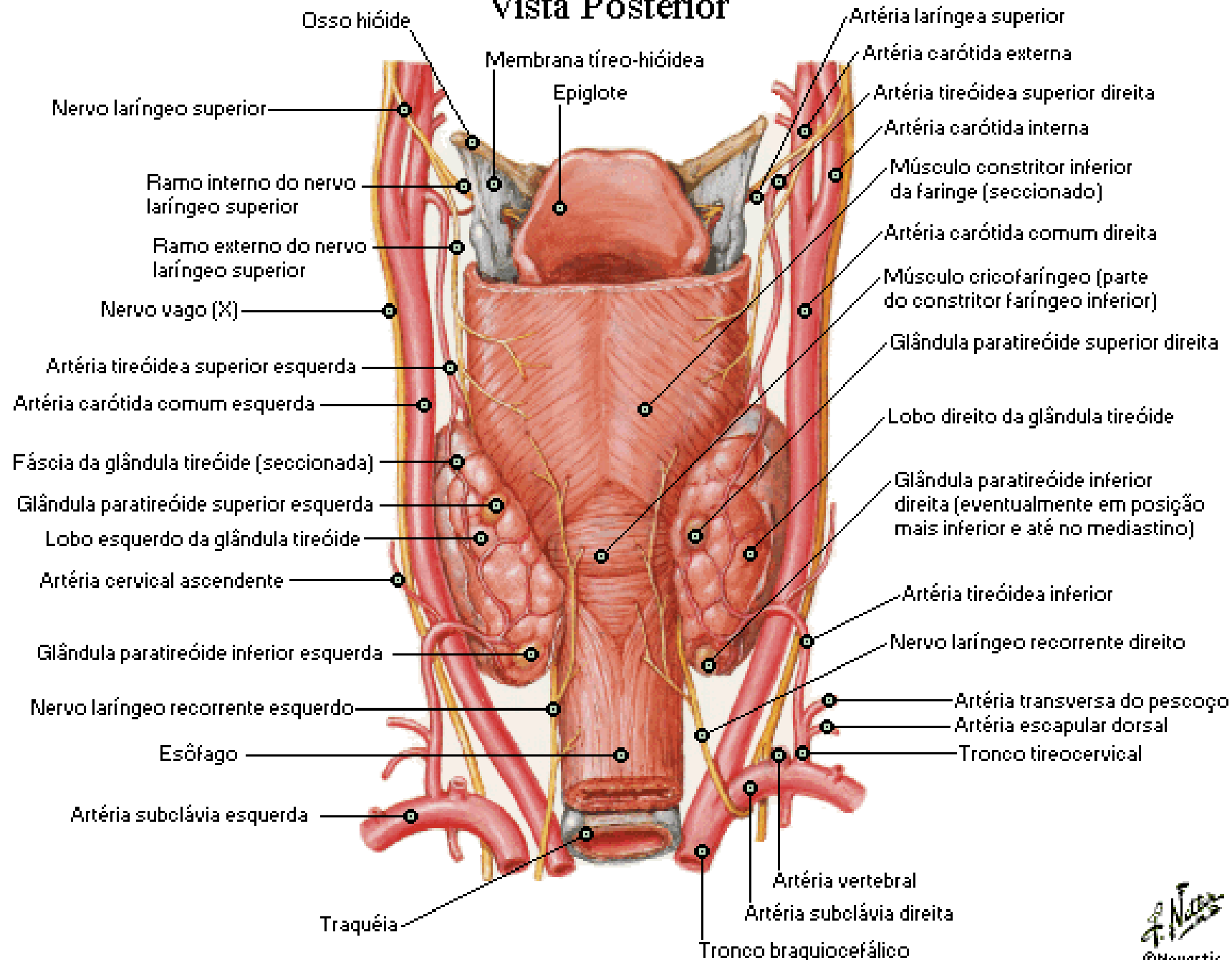
Glândula Tireóide e Faringe

Vista Posterior



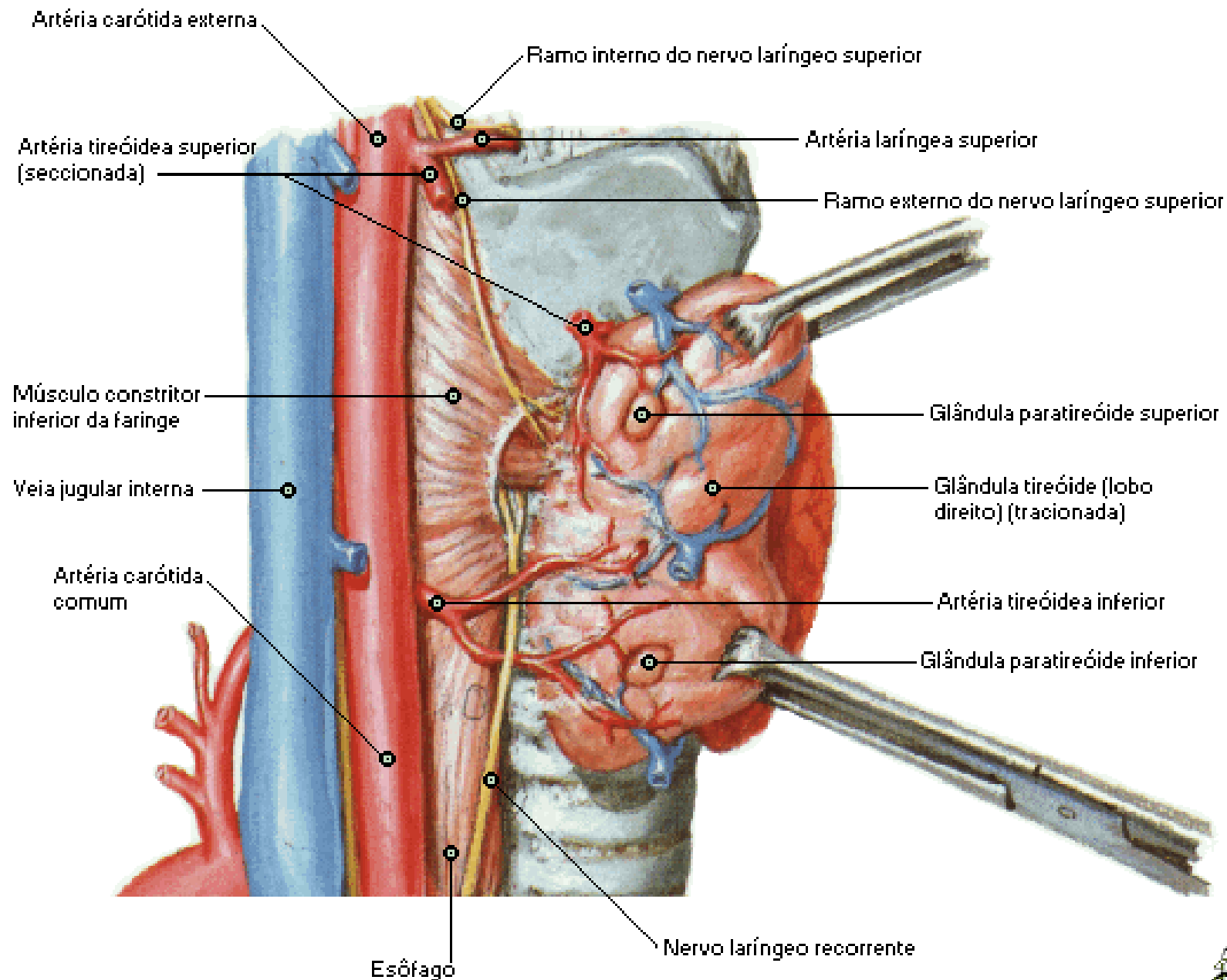
Glândulas Paratireóides

Vista Posterior



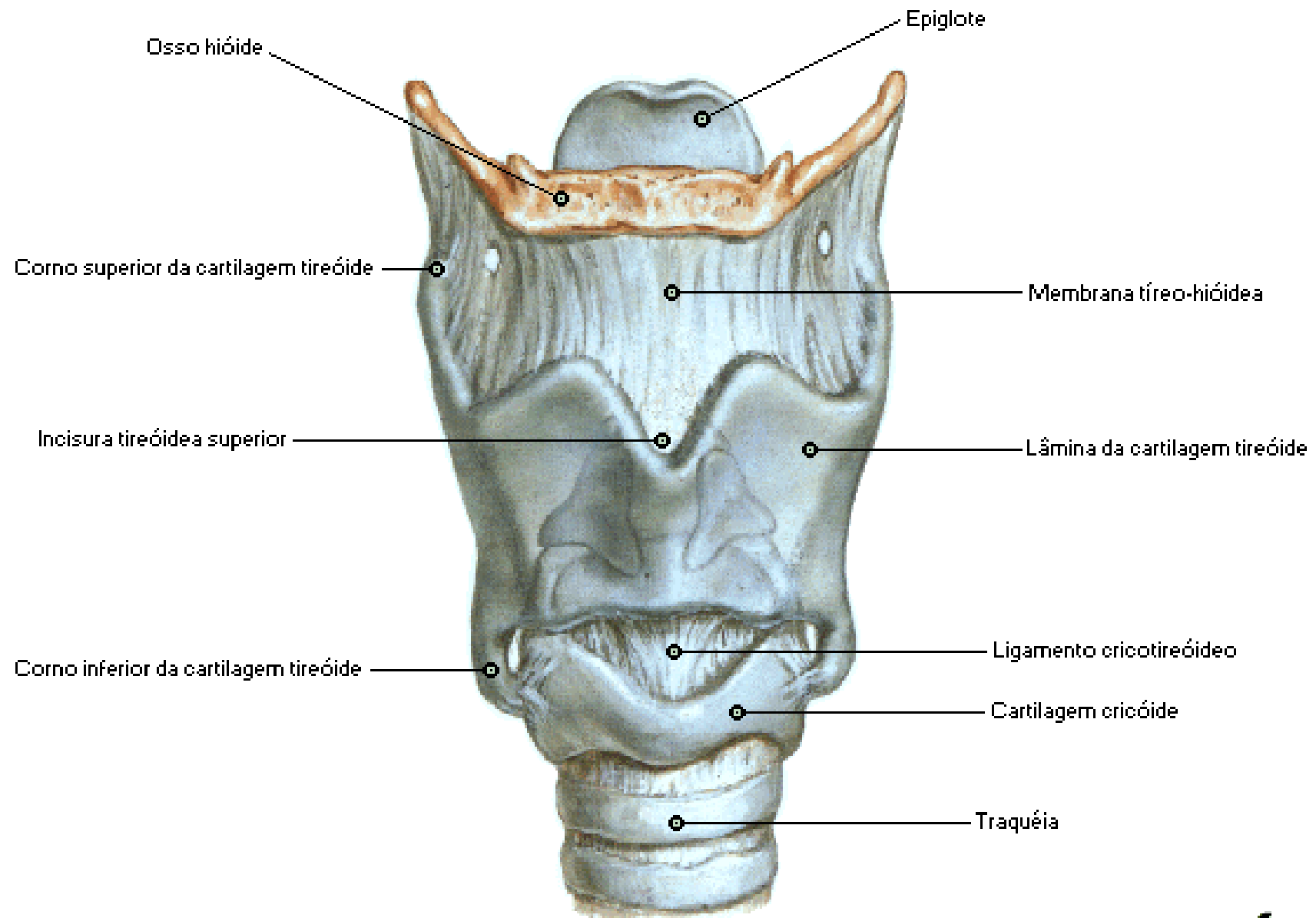
Glândulas Paratireóides

Vista Lateral Direita



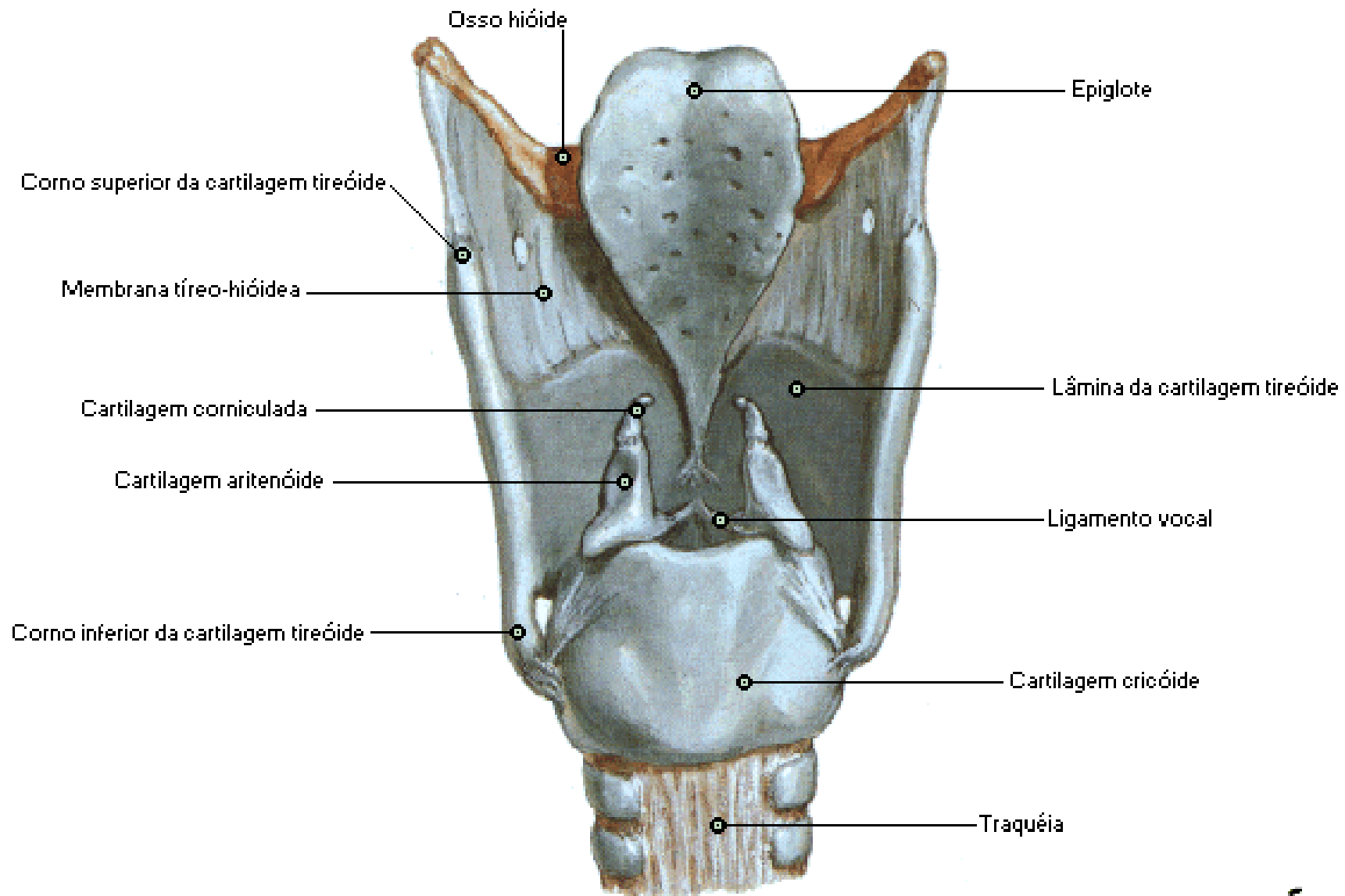
Cartilagens da Laringe

Vista Anterior



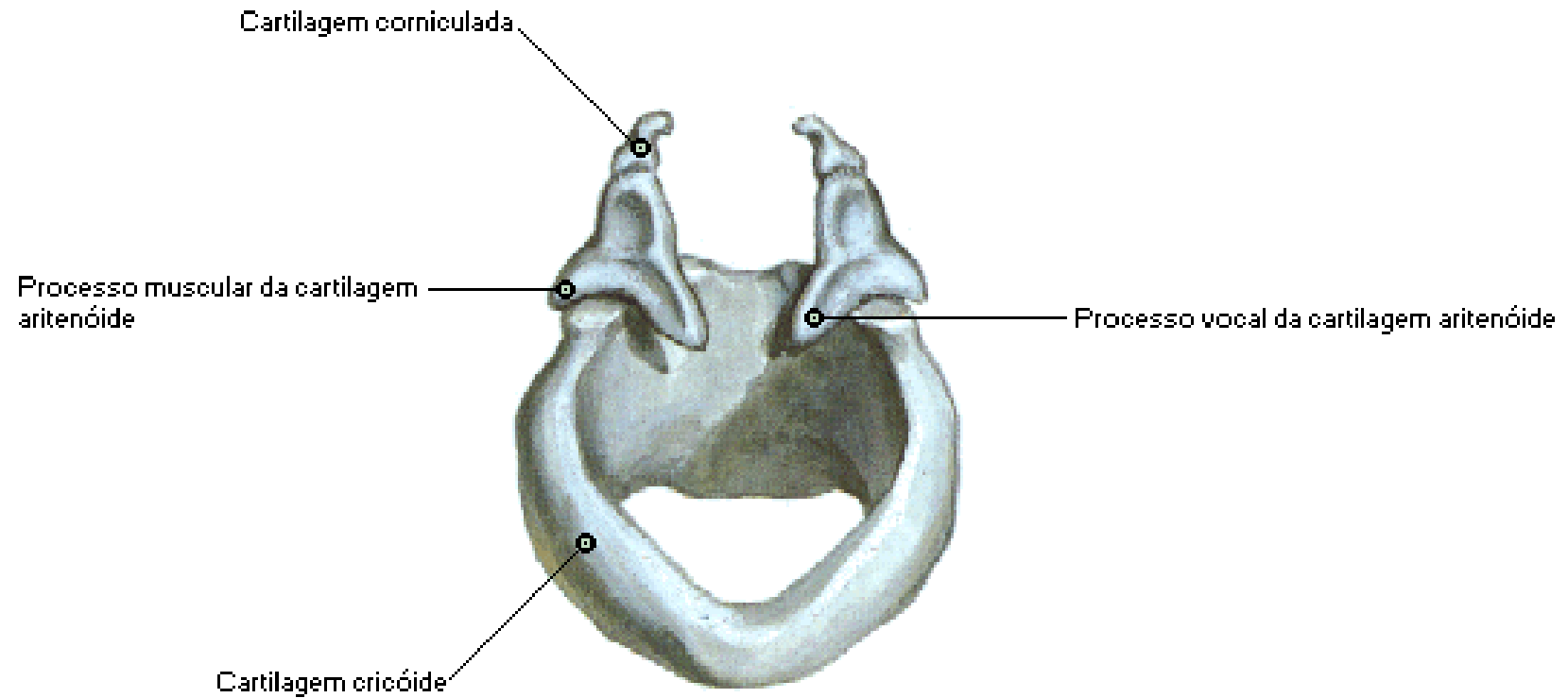
Cartilagens da Laringe

Vista Posterior



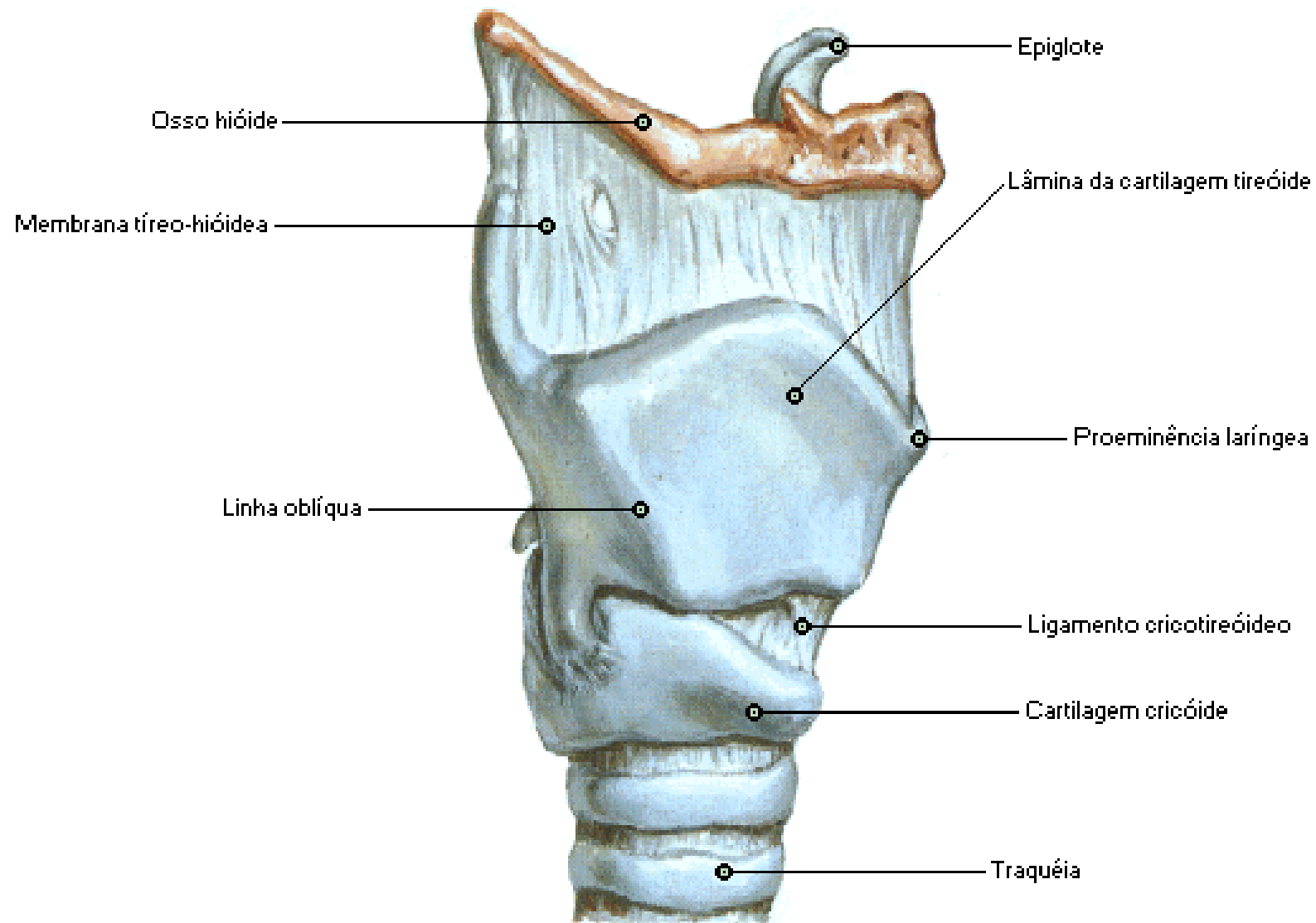
Cartilagens da Laringe

Vista Ântero-superior



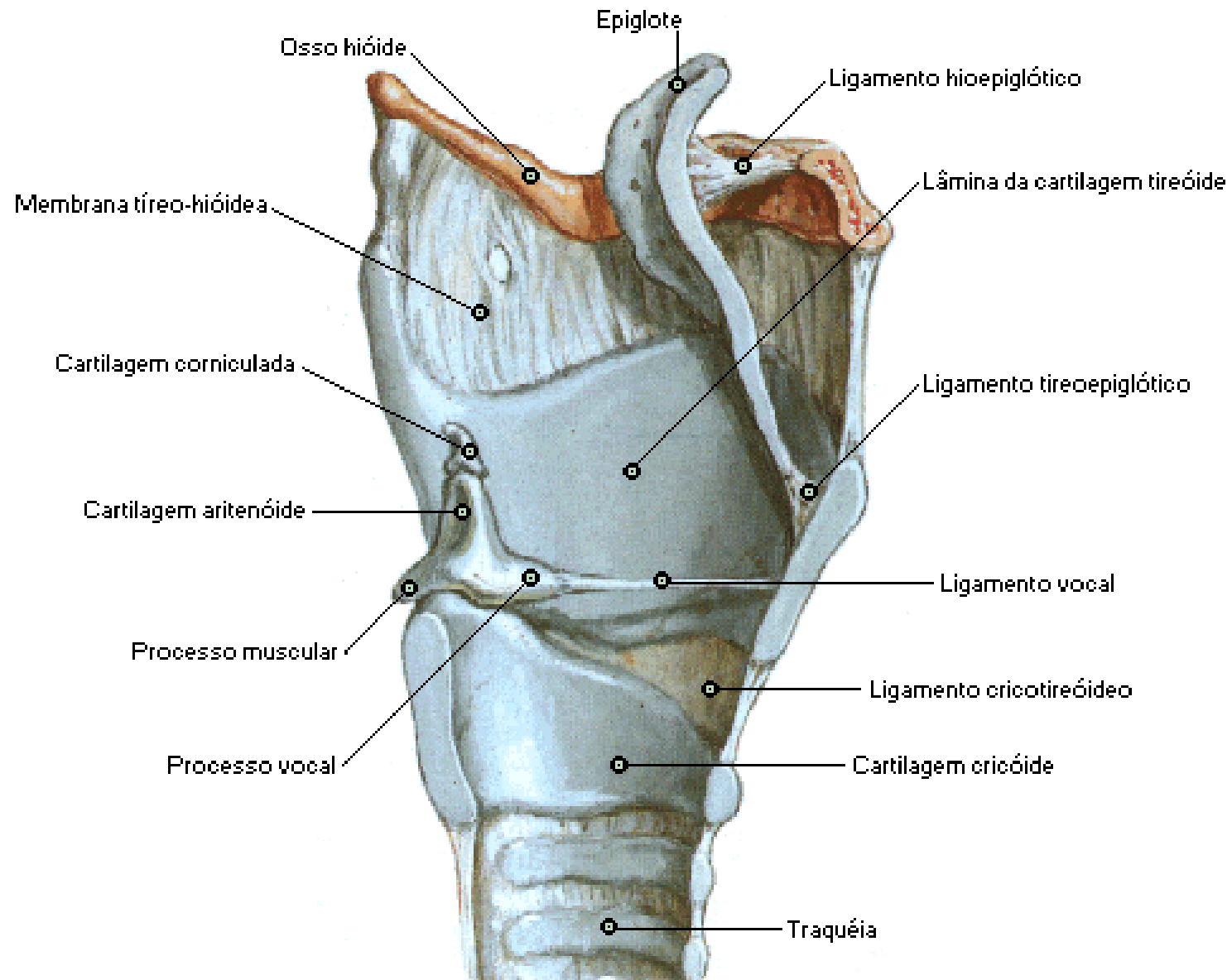
Cartilagens da Laringe

Vista Lateral Direita



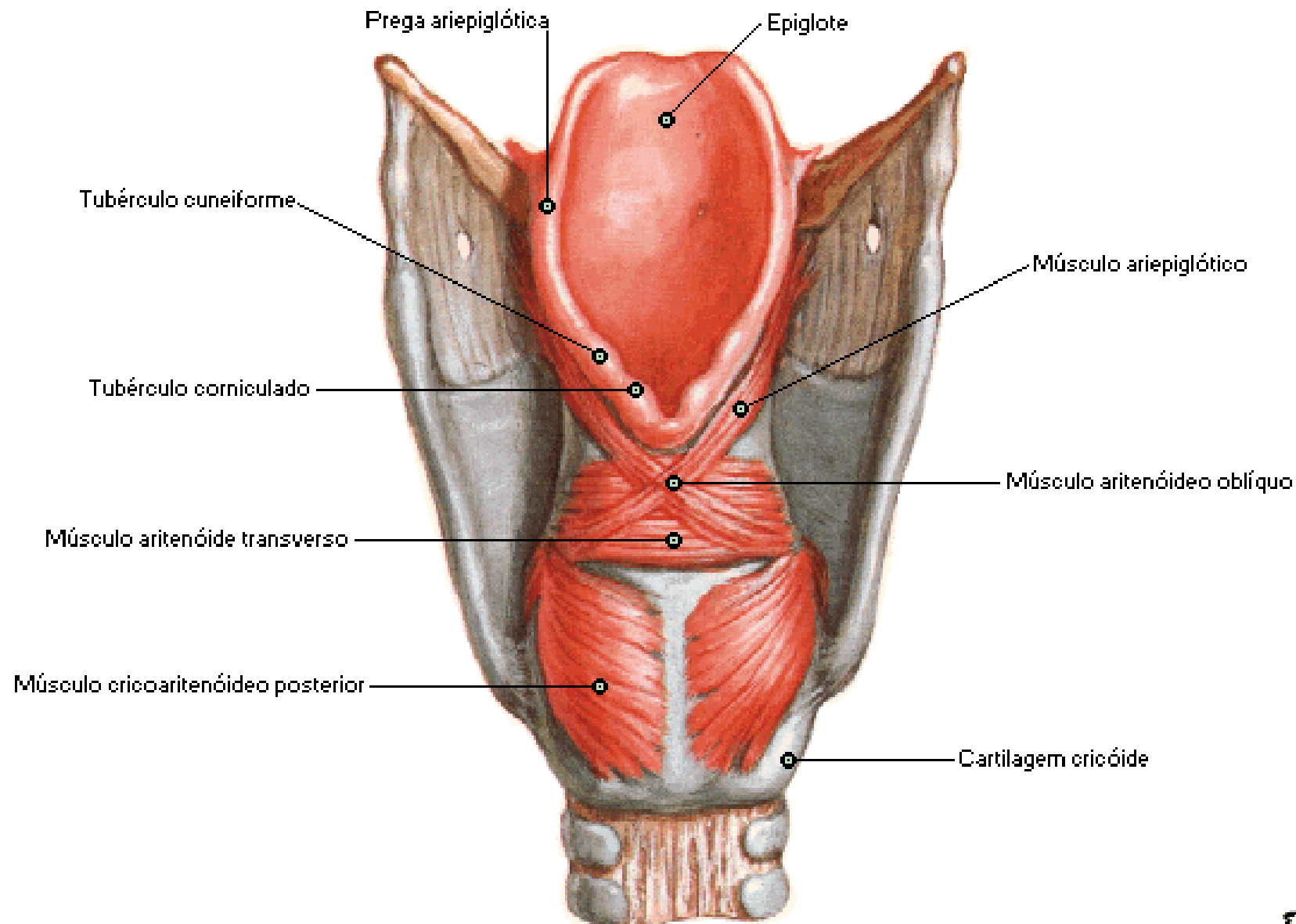
Cartilagens da Laringe

Secção Sagital



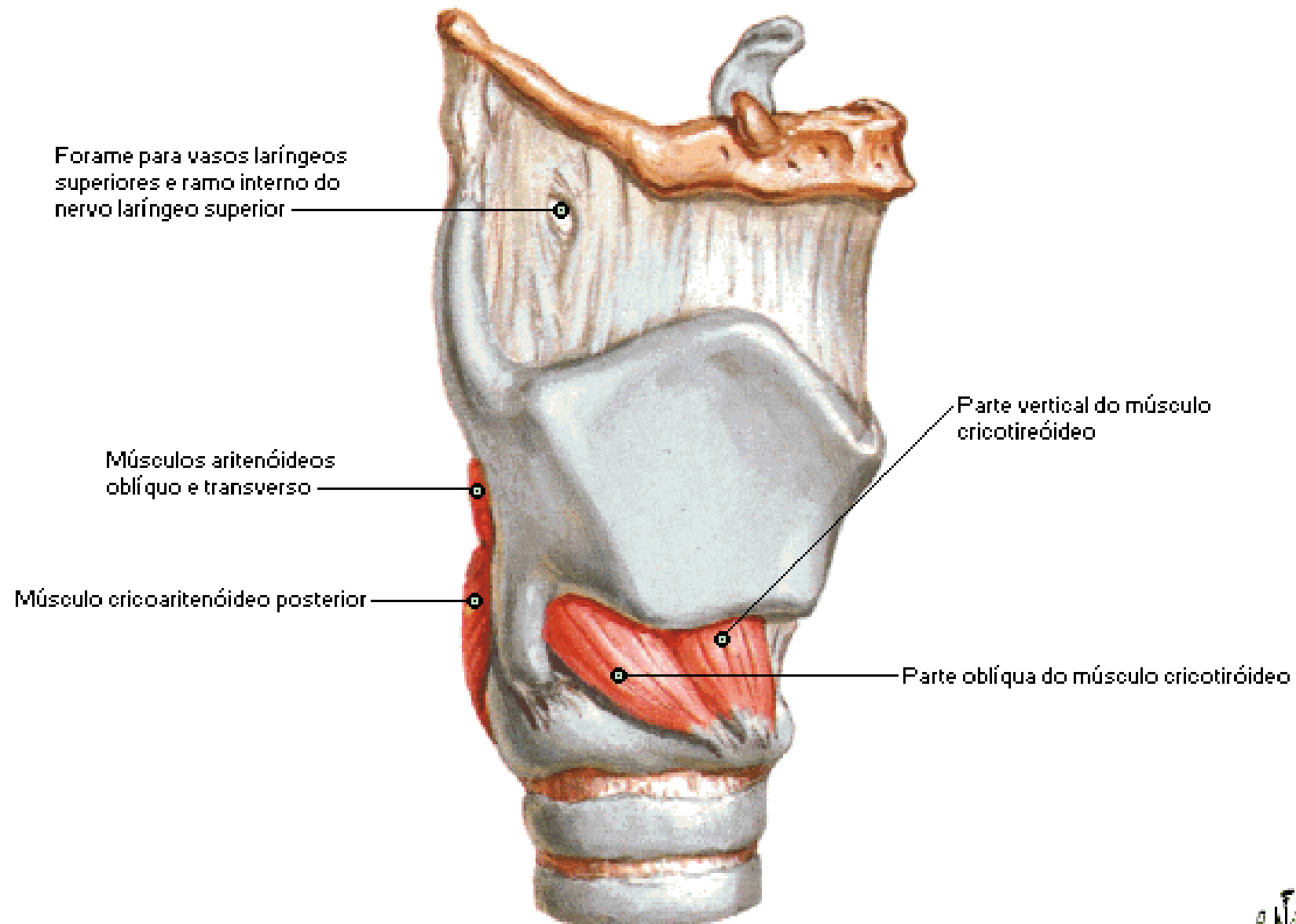
Músculos Intrínsecos da Laringe

Vista Posterior



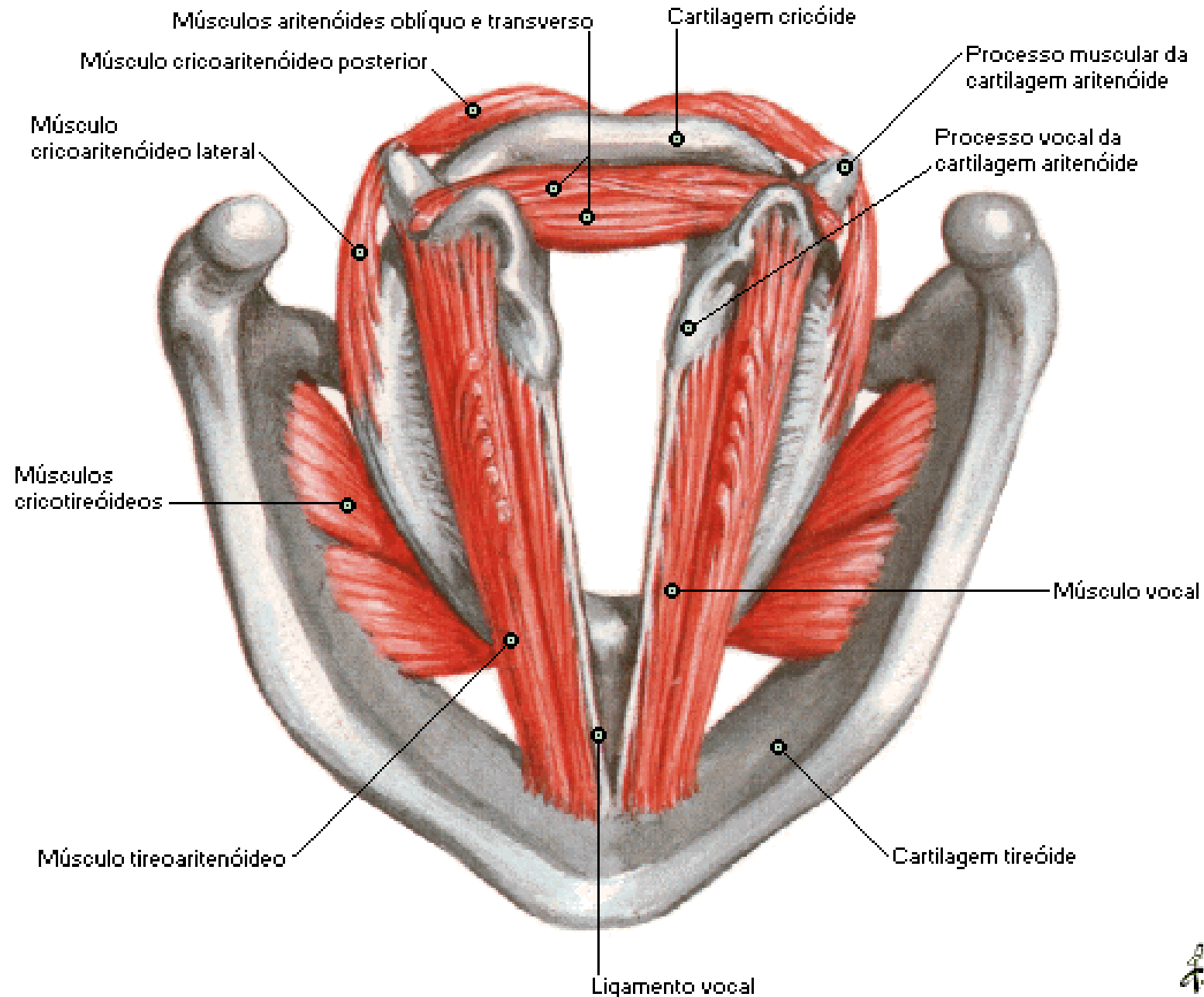
Músculos Intrínsecos da Laringe

Vista Lateral Direita



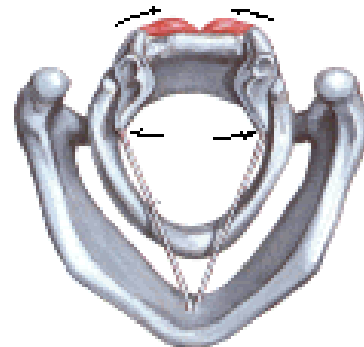
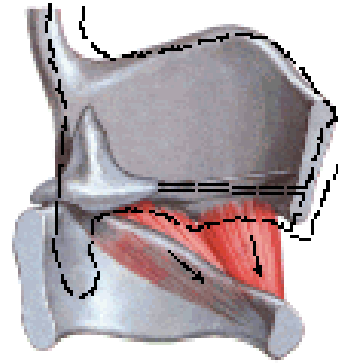
Músculos Intrínsecos da Laringe

Vista Superior

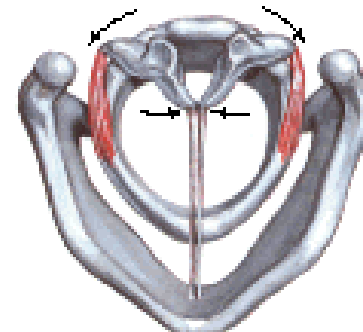


Ação dos Músculos Intrínsecos da Laringe

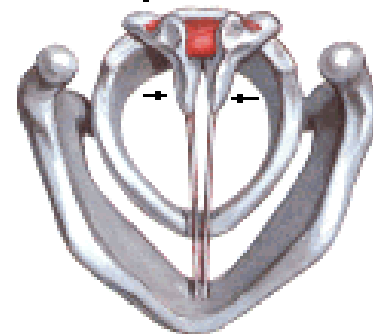
Ação dos músculos cricotireóideos:
alongamento (tensão) das cordas vocais



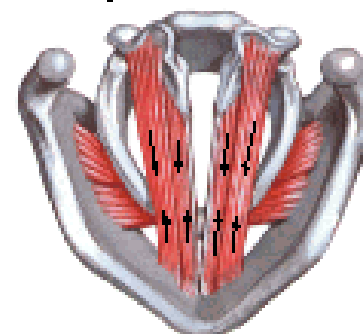Ação dos músculos cricoaritenóideos
posteriores: abdução das cordas vocais



Ação dos músculos cricoaritenóideos
laterais: adução das cordas vocais



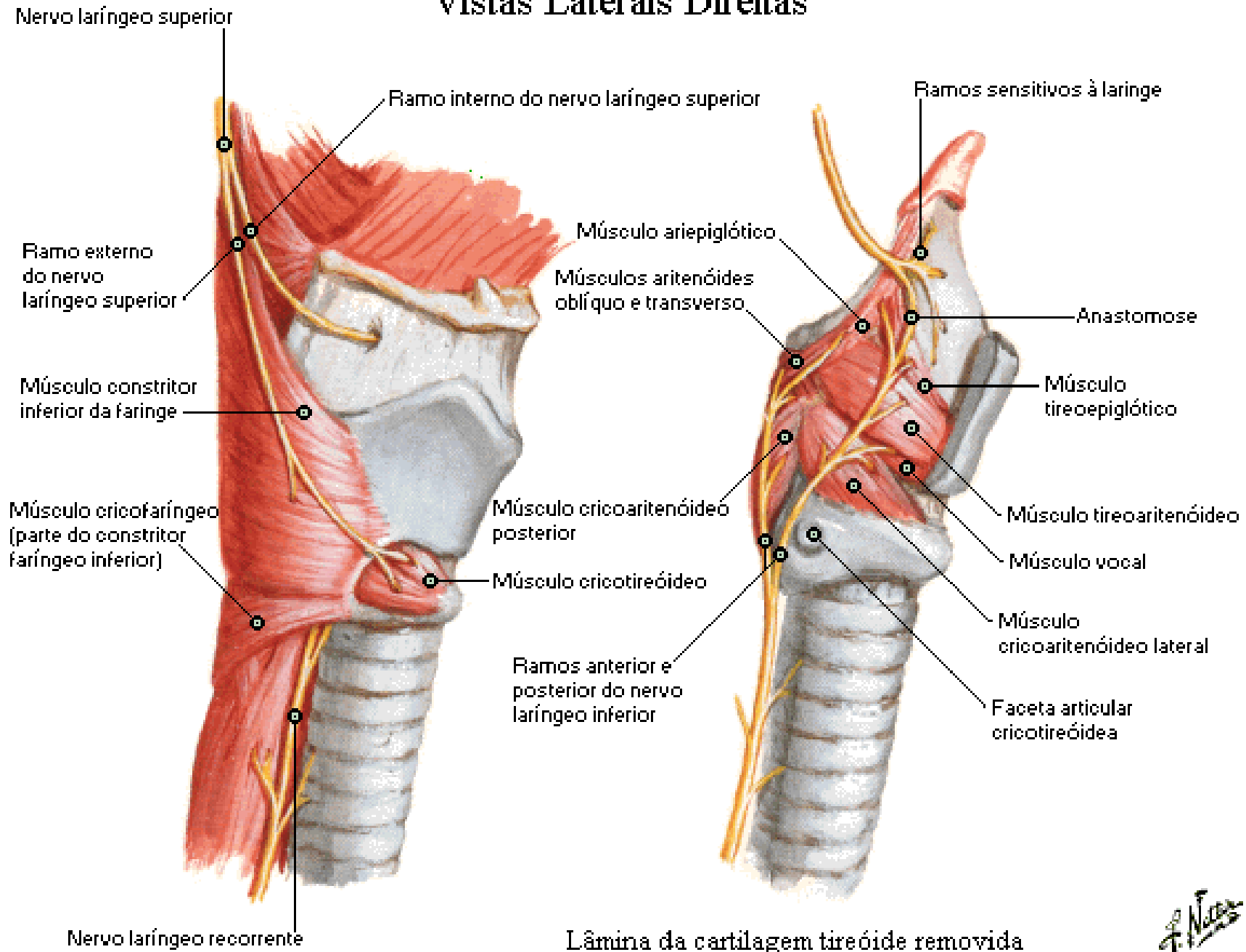
Ação do músculo aritenóideo:
adução das cordas vocais



Ação dos músculos vocal e tireoaritenóideo:
encurtamento (relaxamento) das cordas vocais

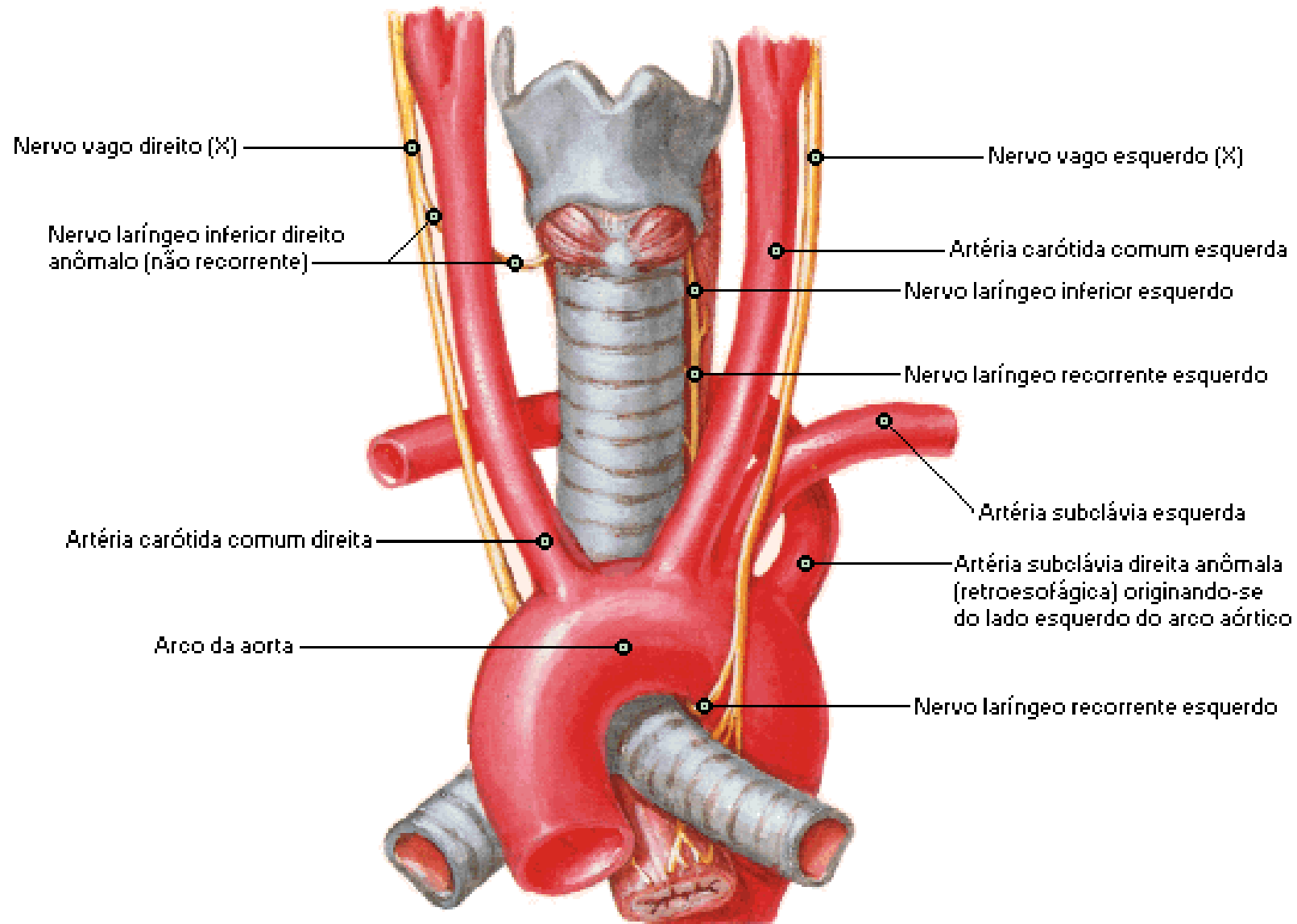
Nervos da Laringe

Vistas Laterais Direitas



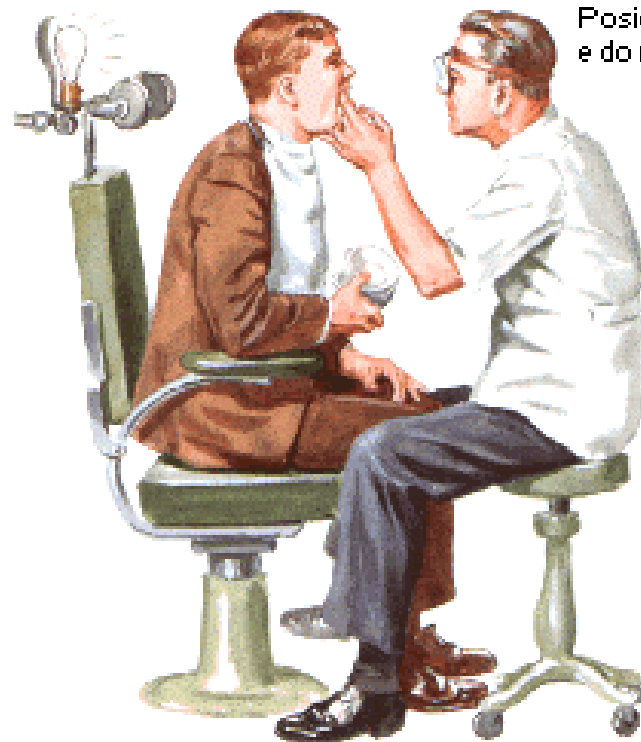
Nervos da Laringe

Vista Anterior



Inspeção da Laringe

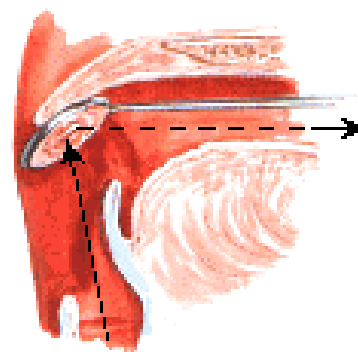
Técnica



Posição do paciente e do médico



Espelho aquecido em chama para prevenir embaçamento e testado no dorso da mão do médico



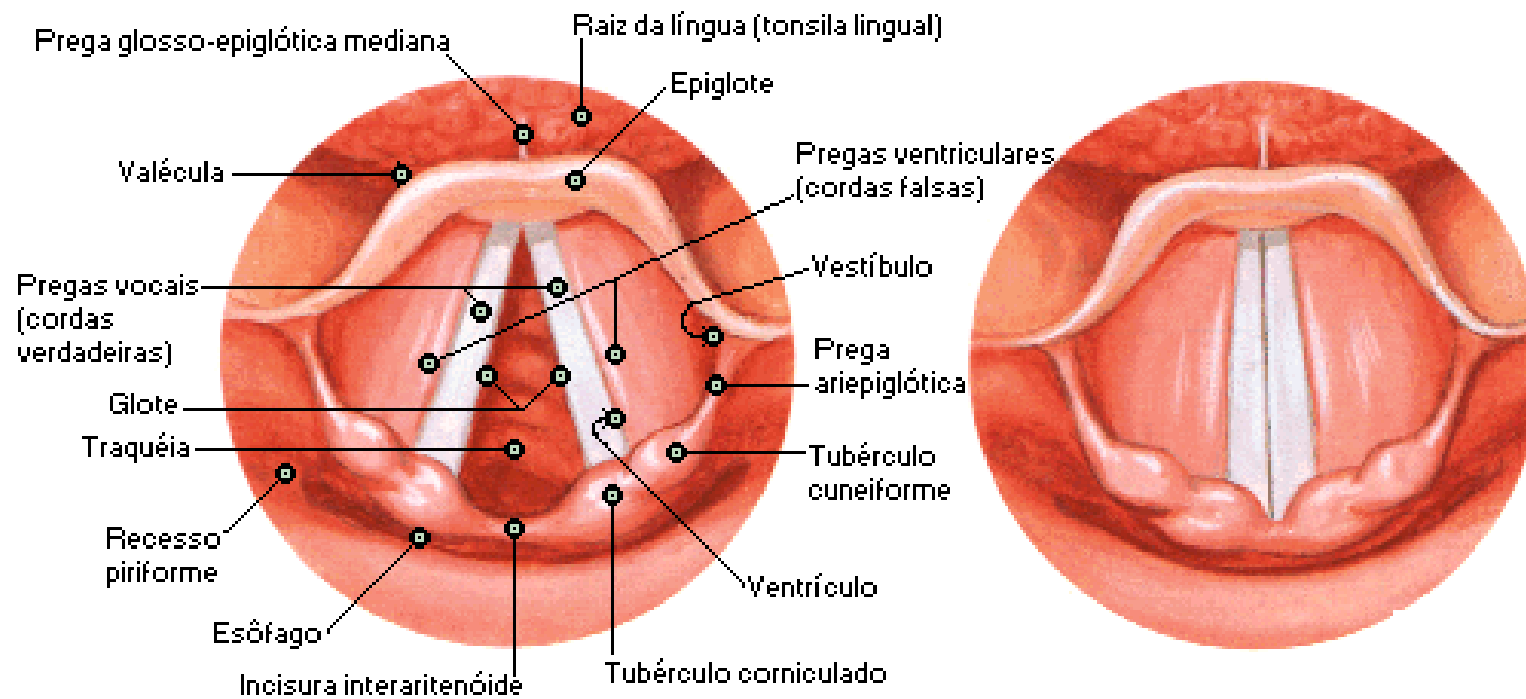
Espelho eleva a úvula



Técnica

Inspeção da Laringe

Vistas Durante a Inspiração e a Formação



Laringe normal: inspiração

Laringe normal: fonação

Pálpebras

Vista Anterior

Conjuntiva palpebral superior: glândulas tarsais (de Meibomious) por transparência

Pupila

Papila e ponto lacrimais superiores

Córnea

Prega semilunar

Limbo da córnea

Carúncula lacrimal no lago lacrimal

Conjuntiva bulbar sobre a esclera

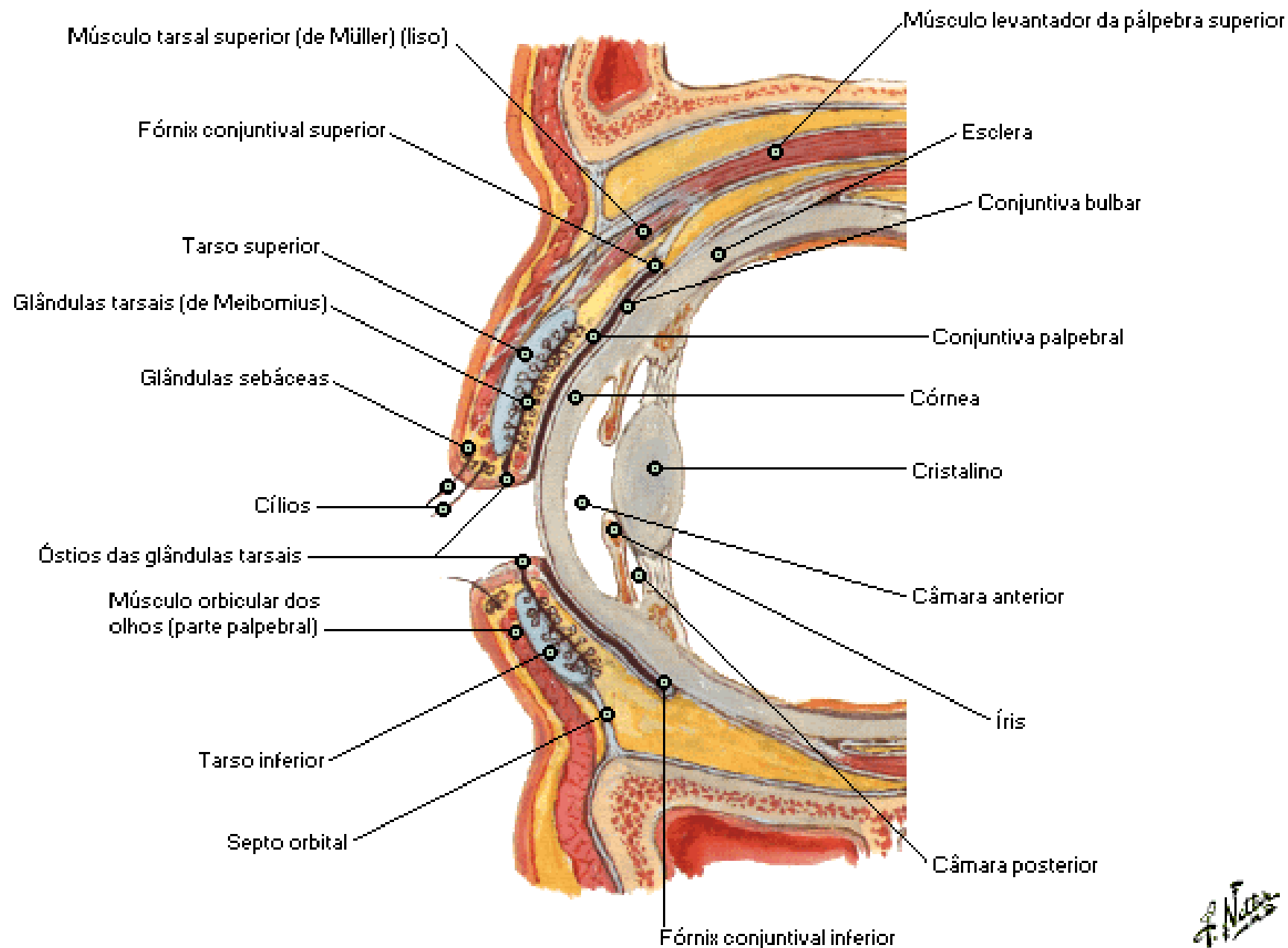
Papila e ponto lacrimais inferiores

Fórnix inferior da conjuntiva

Conjuntiva palpebral inferior: glândulas tarsais por transparência

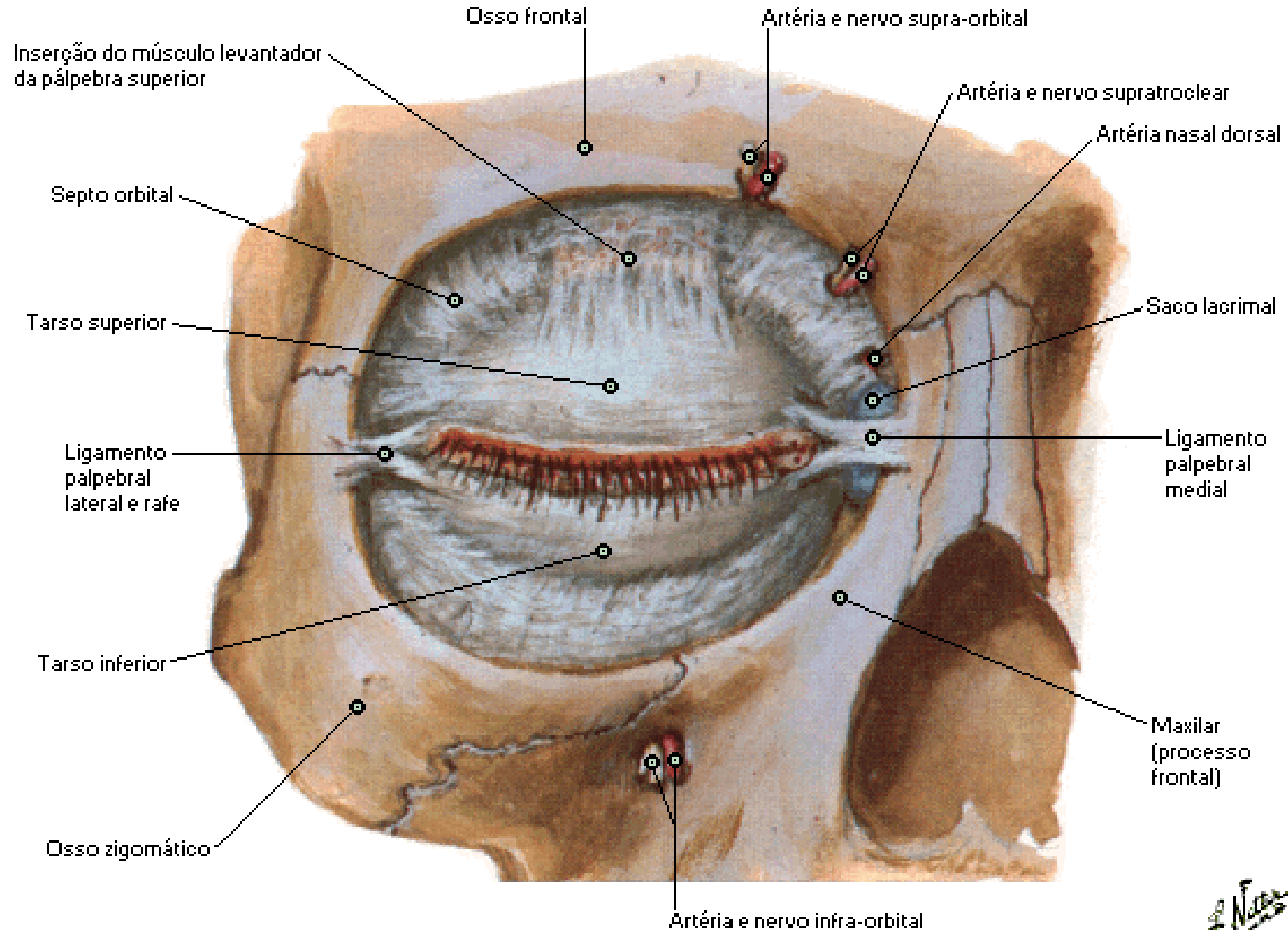
Pálpebras e Estruturas Orbitais Anteriores

Secção Sagital

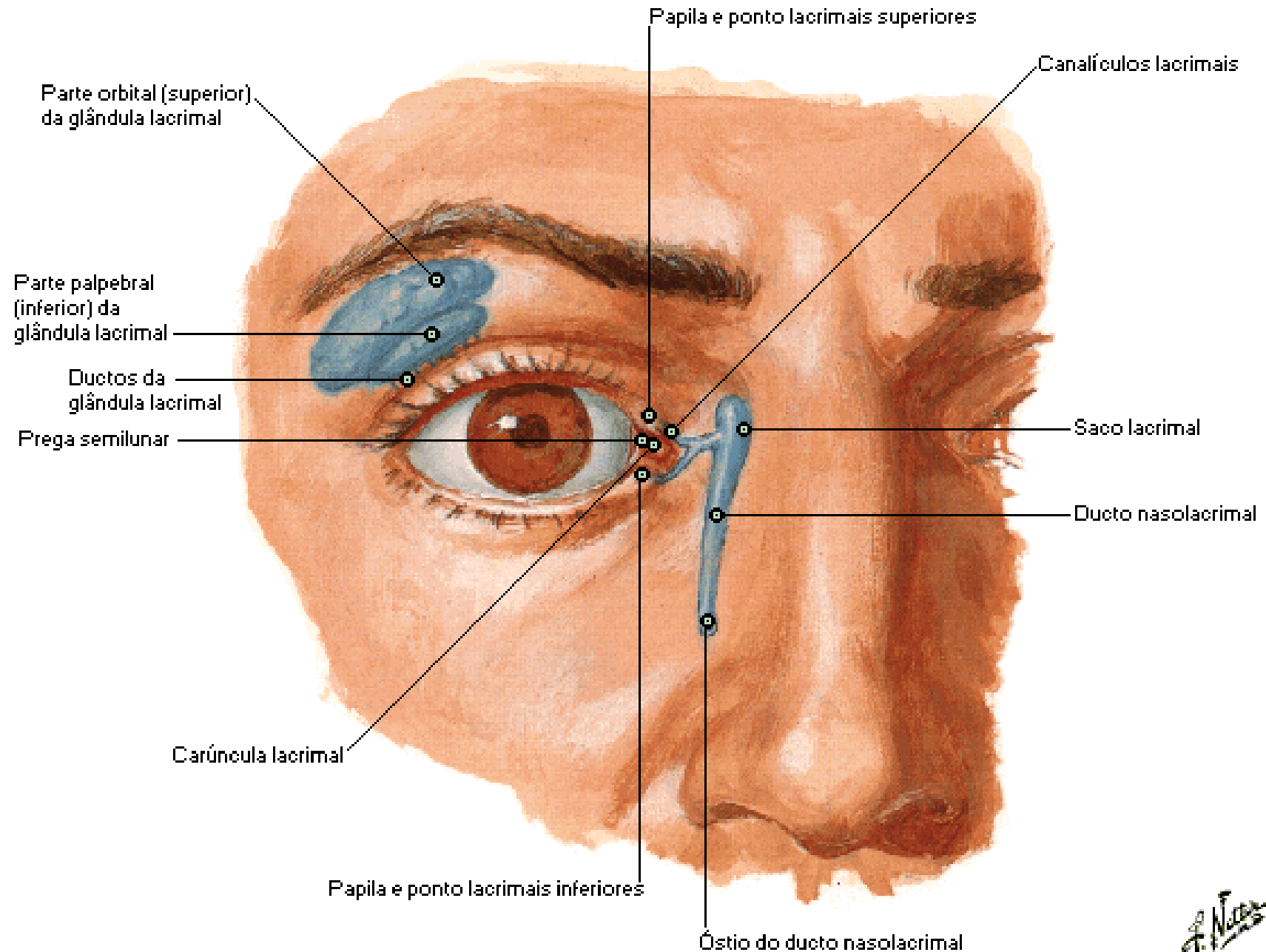


Pálpebras - Dissecação

Vista Anterior

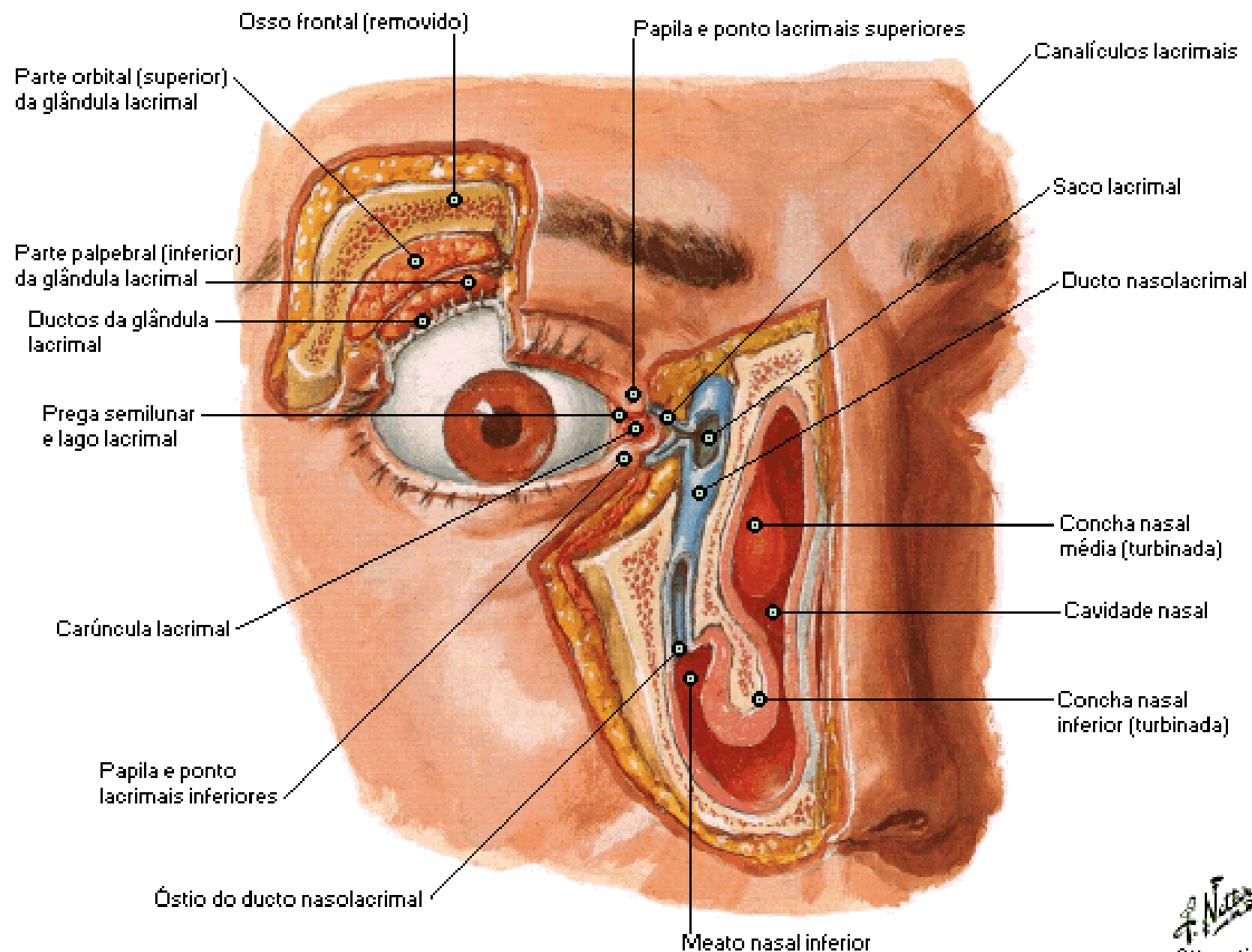


Aparelho Lacrimal



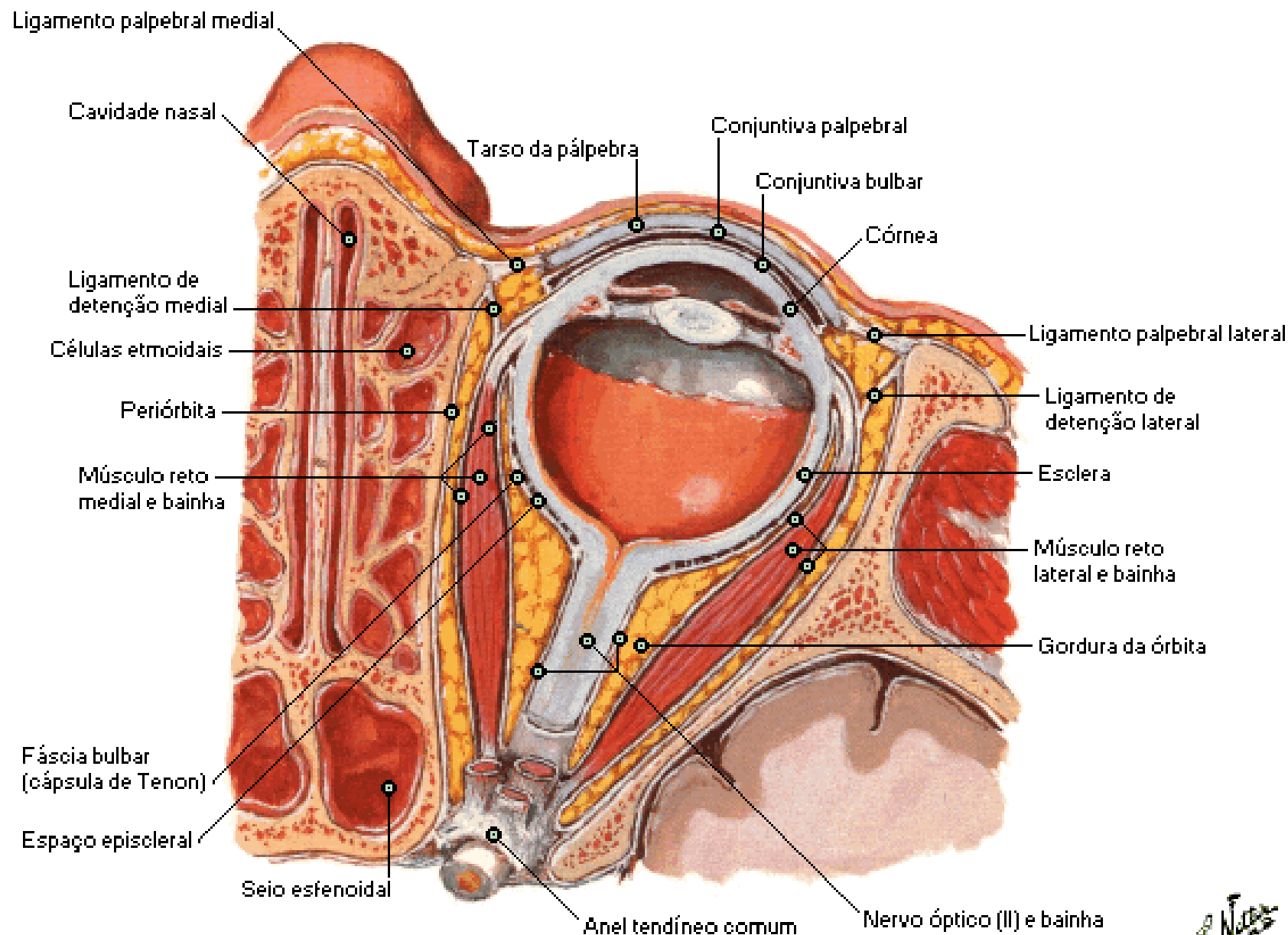
Aparelho Lacrimal

Dissecação



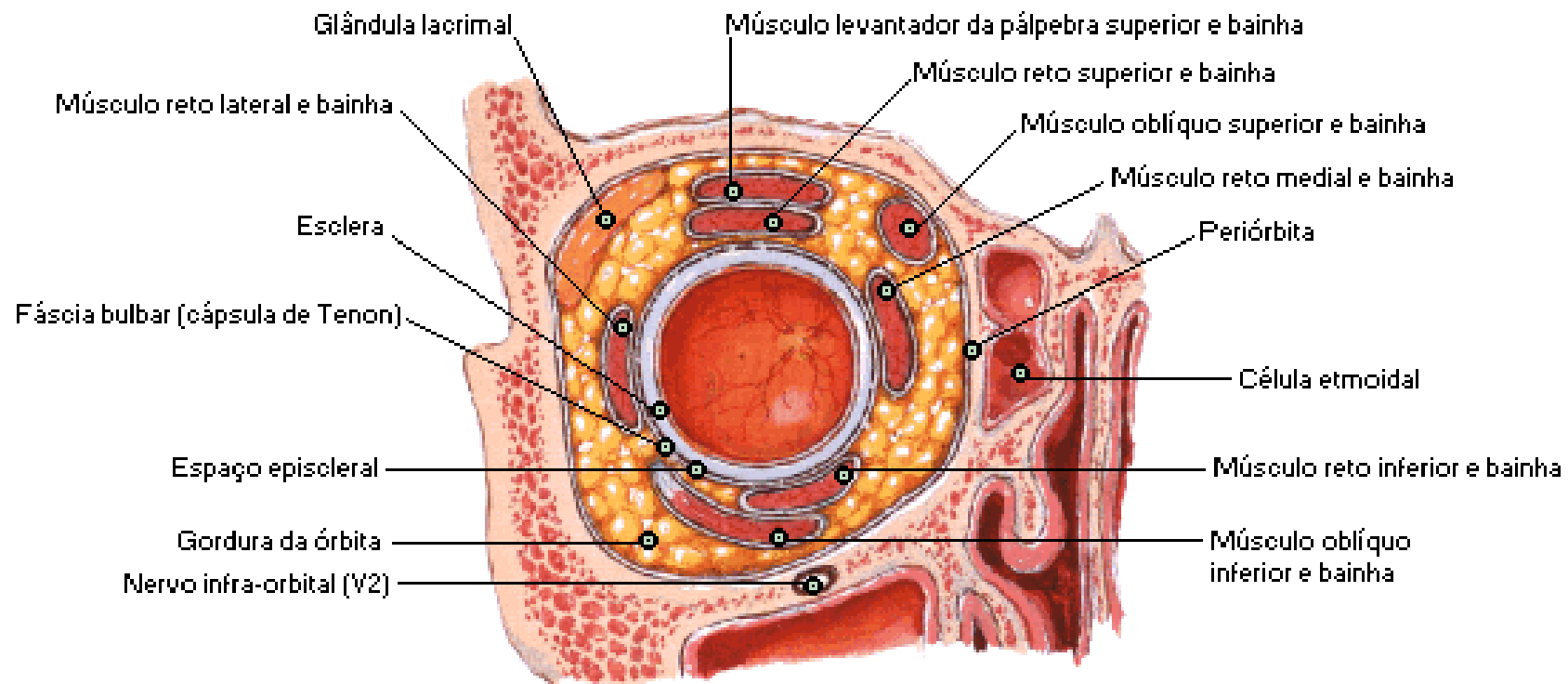
Fáscia da Órbita e Bulbo Ocular

Secção Horizontal

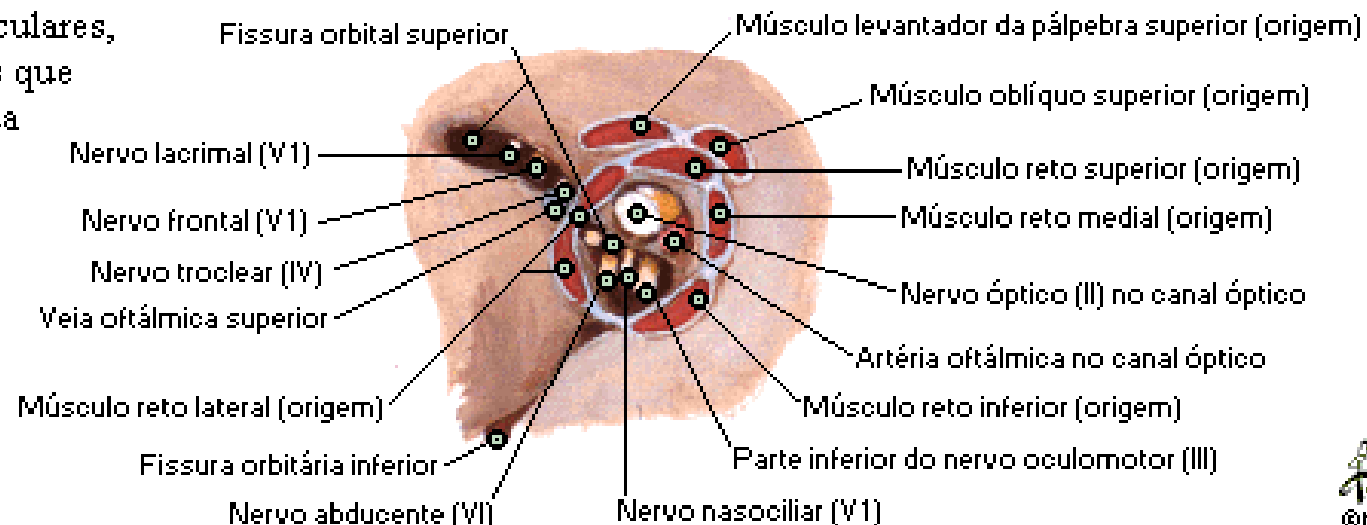


Fáscia da Órbita e Bulbo Ocular

Secção Frontal e Estruturas que Entram na Órbita

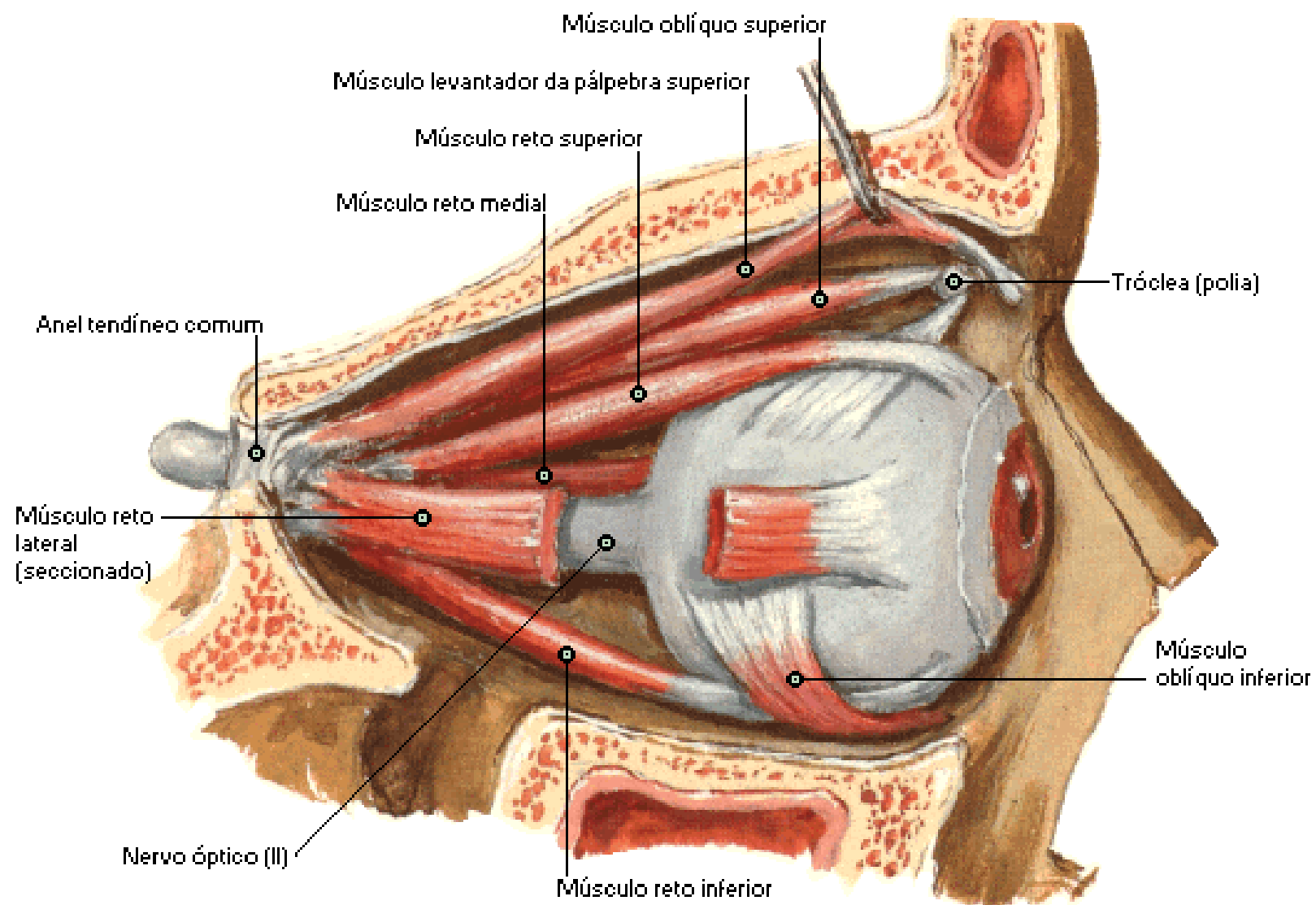


Inserções musculares,
nervos e vasos que
entram na órbita



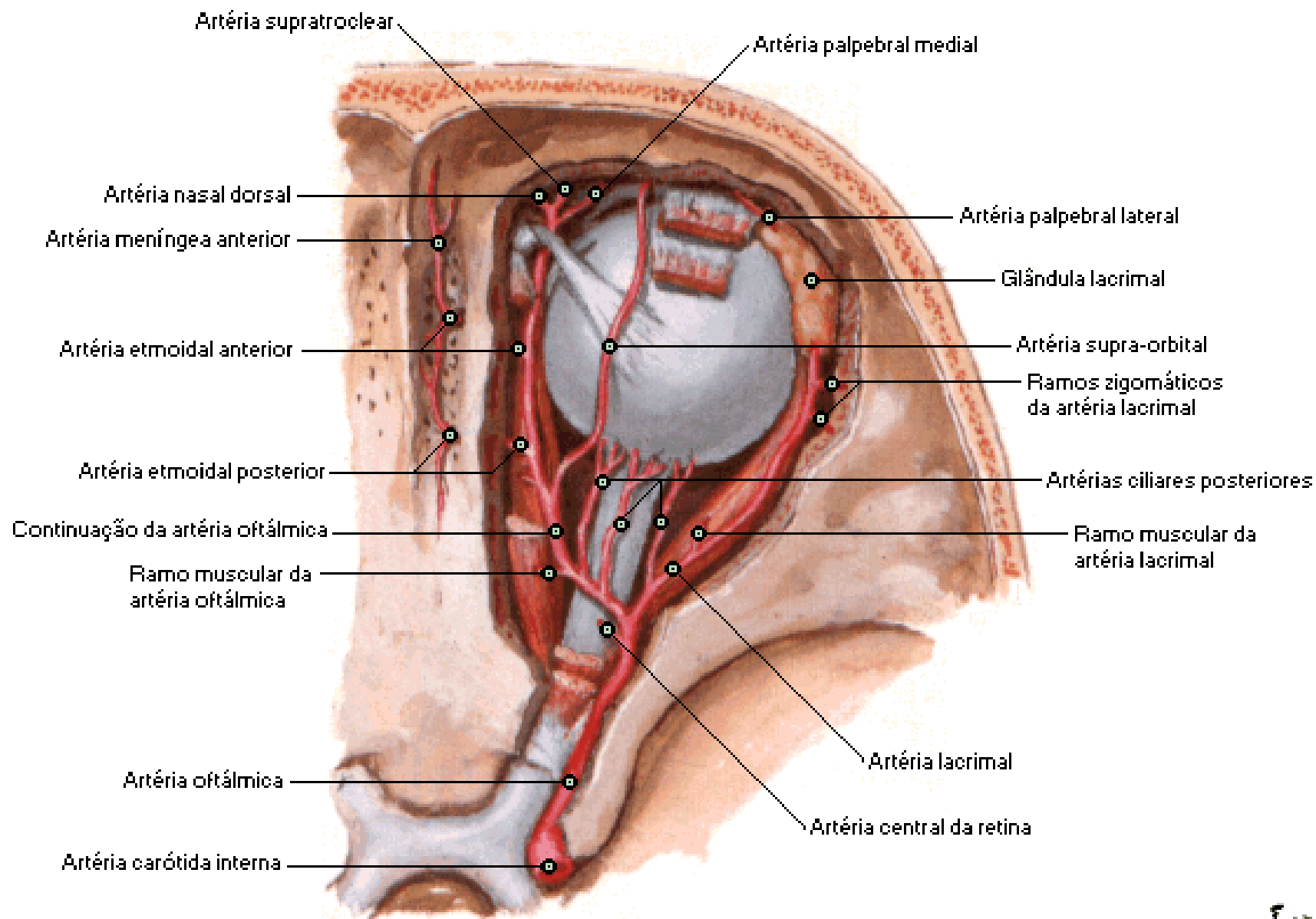
Músculos Extrínsecos do Bulbo Ocular

Vista Lateral Direita



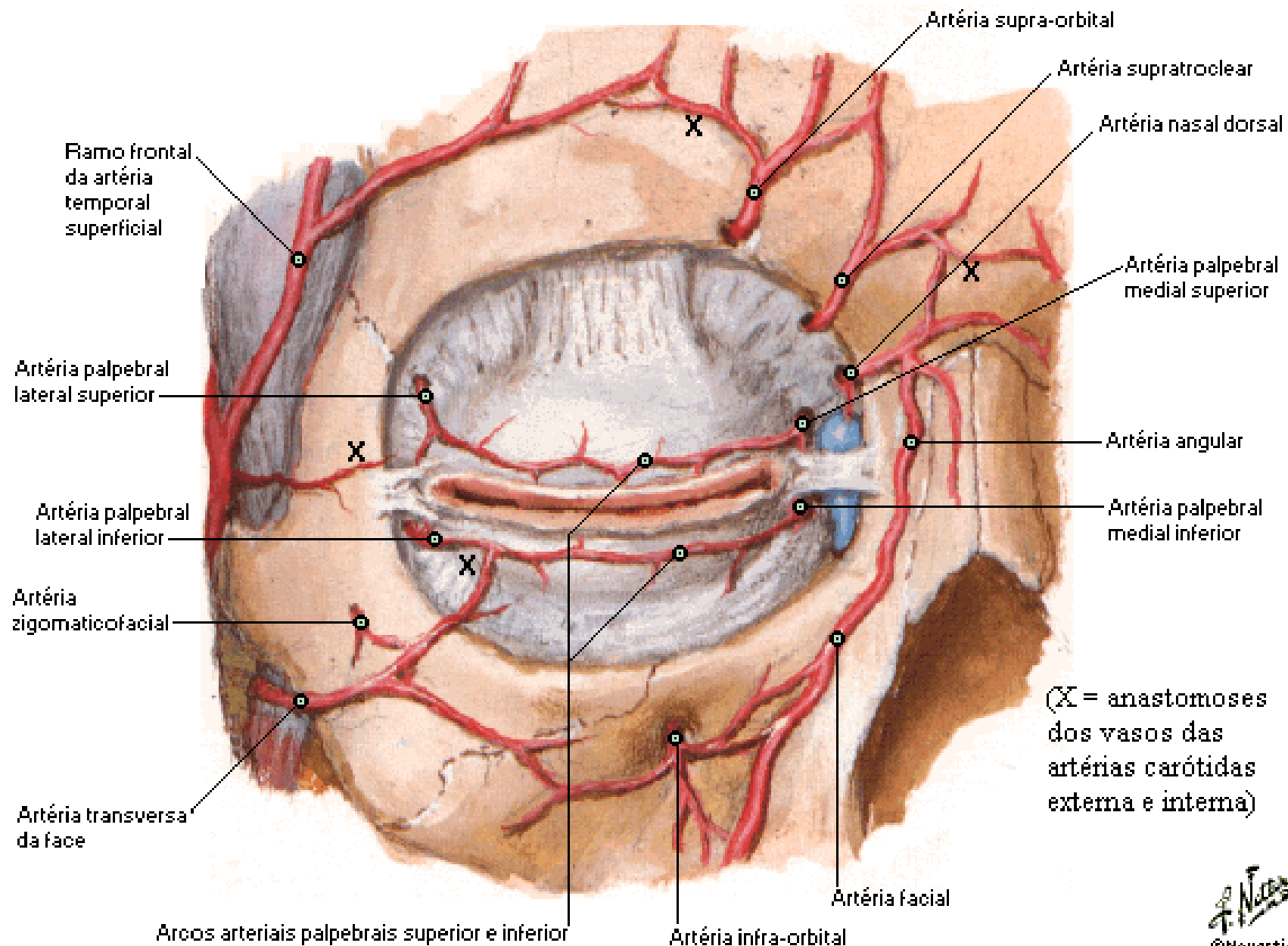
Artérias e Veias da Órbita e Pálpebras

Vista Superior



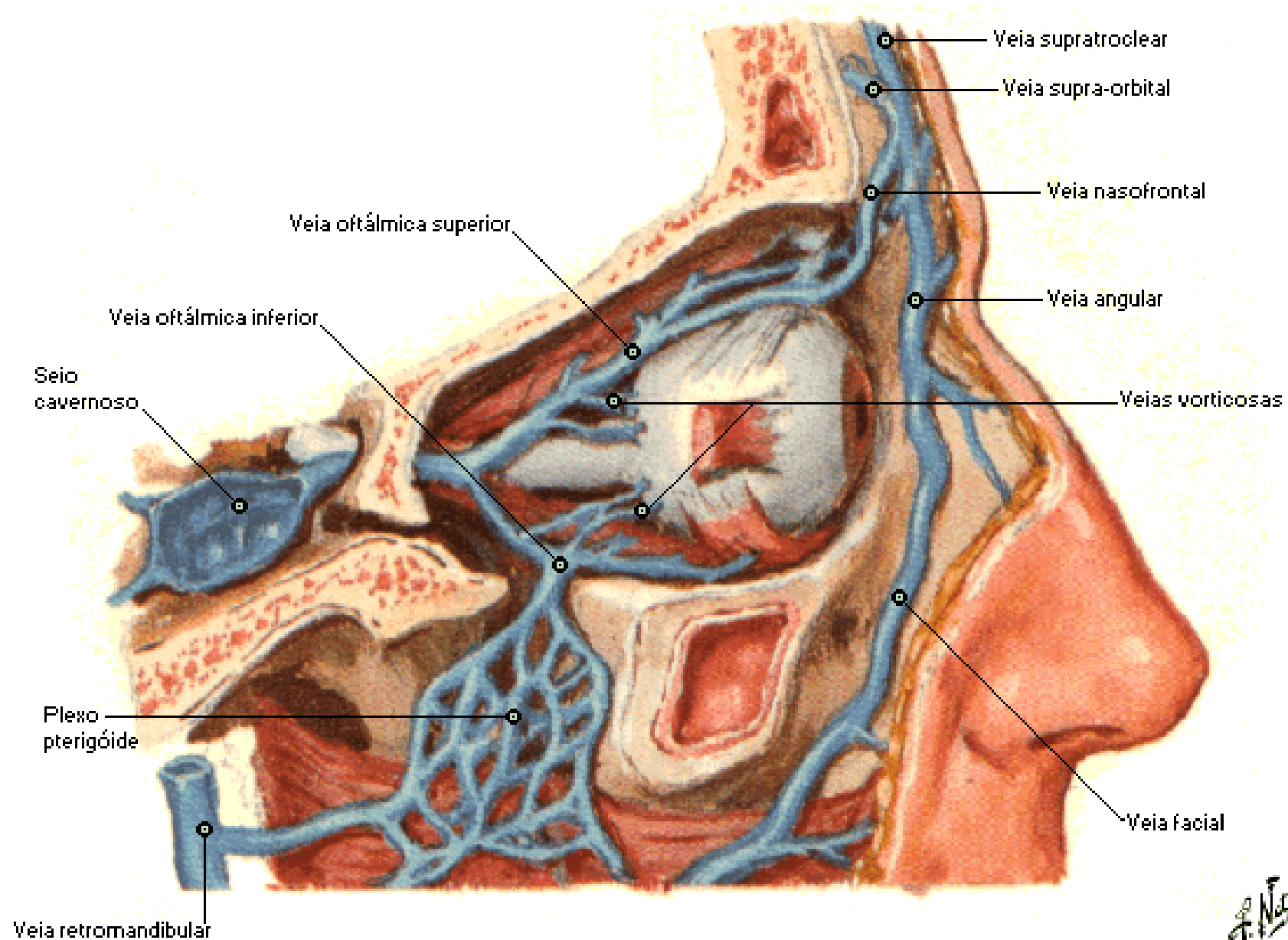
Artérias e Veias da Órbita e Pálpebras

Vista Anterior



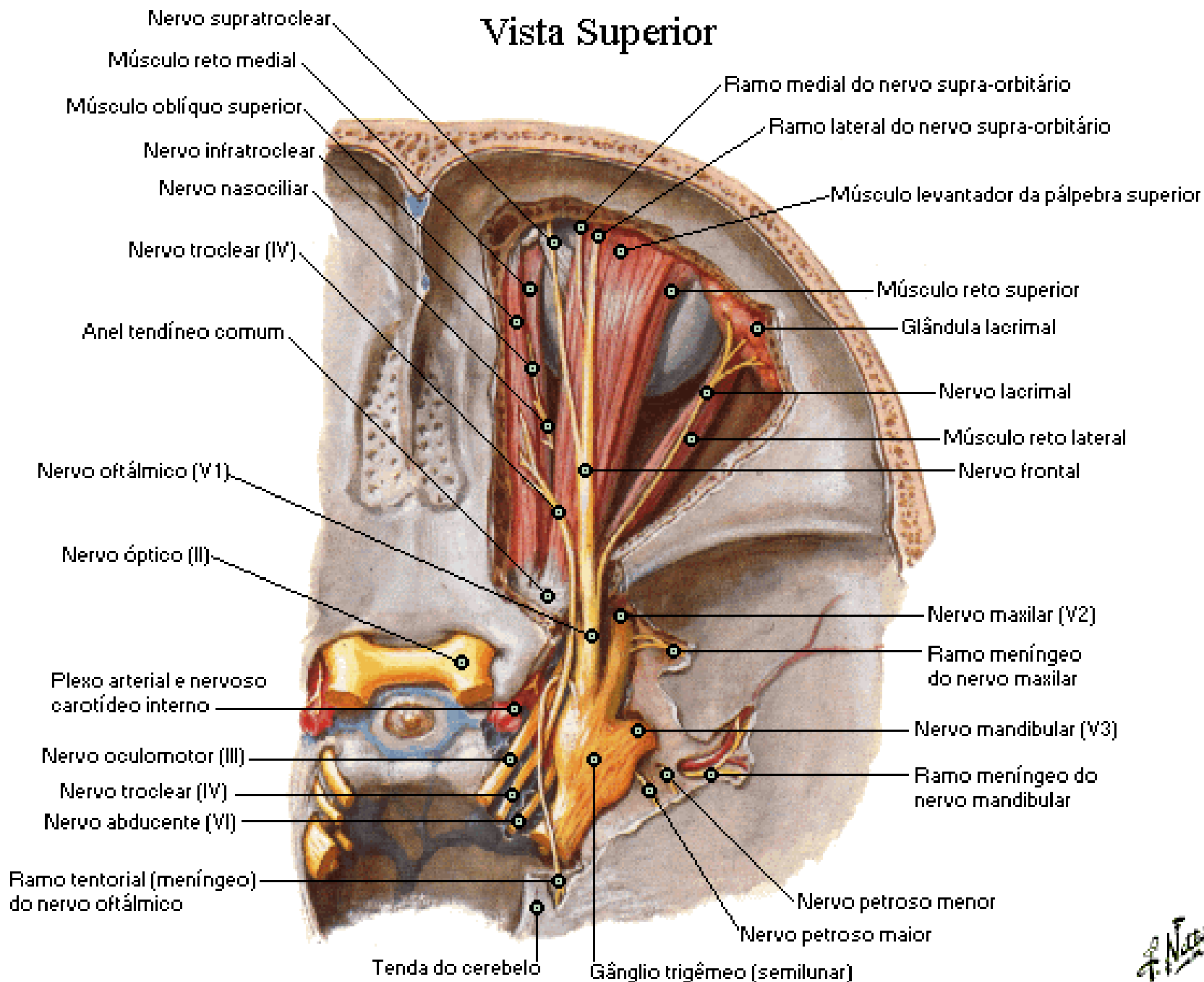
Artérias e Veias da Órbita e Pálpebras

Vista Lateral



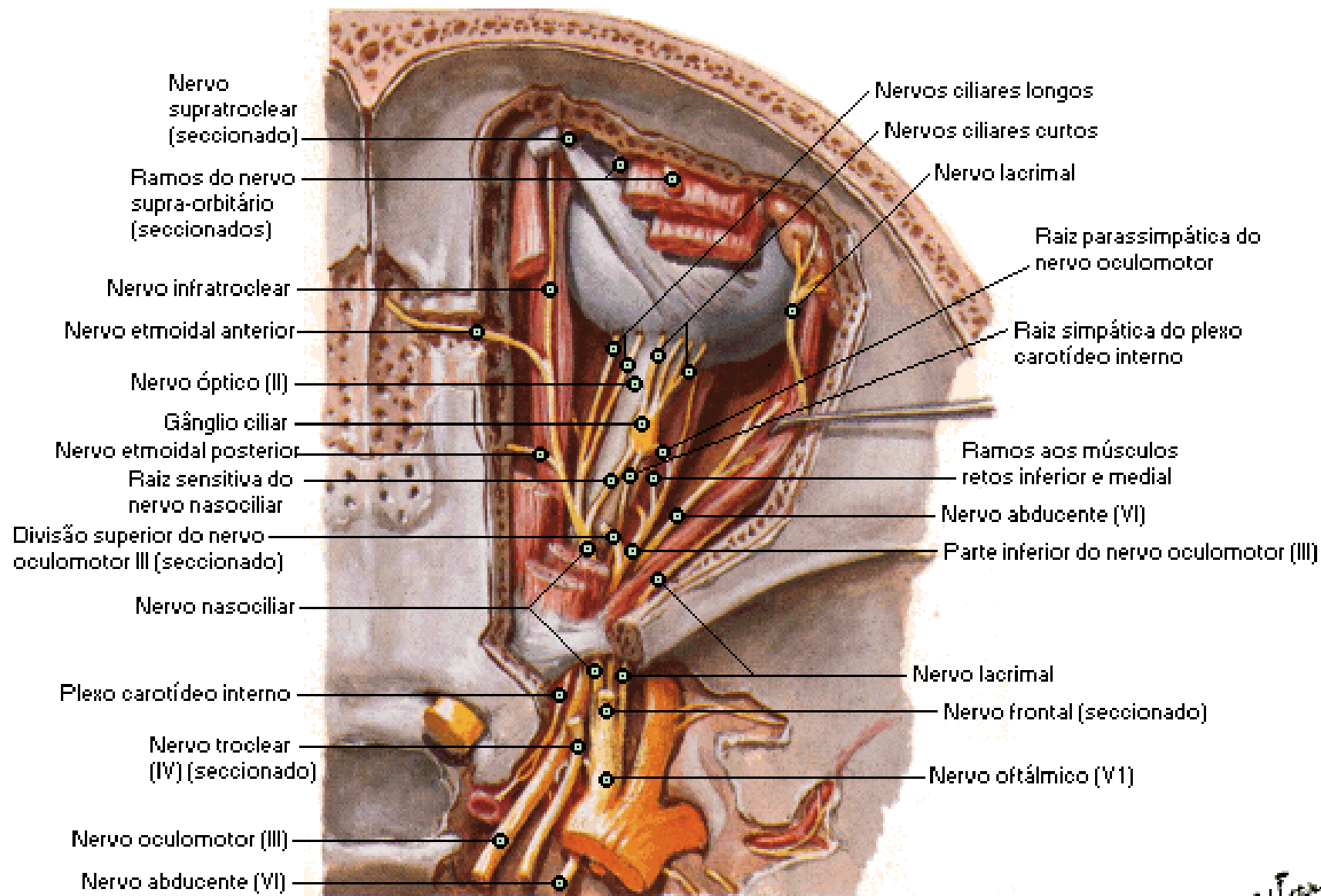
Nervos da Órbita

Vista Superior



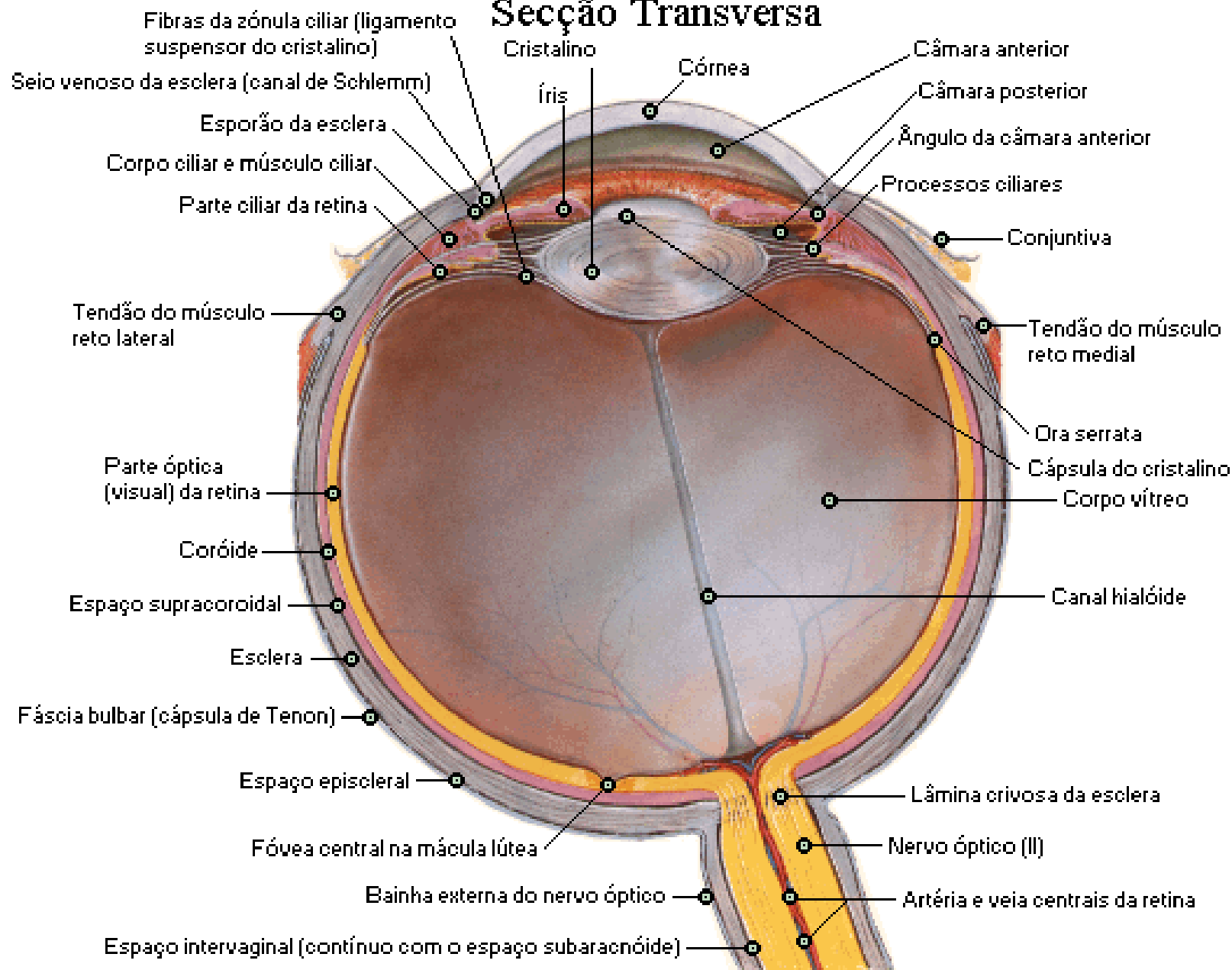
Nervos da Órbita - Músculos Parcialmente Seccionados

Vista Superior



Bulbo Ocular

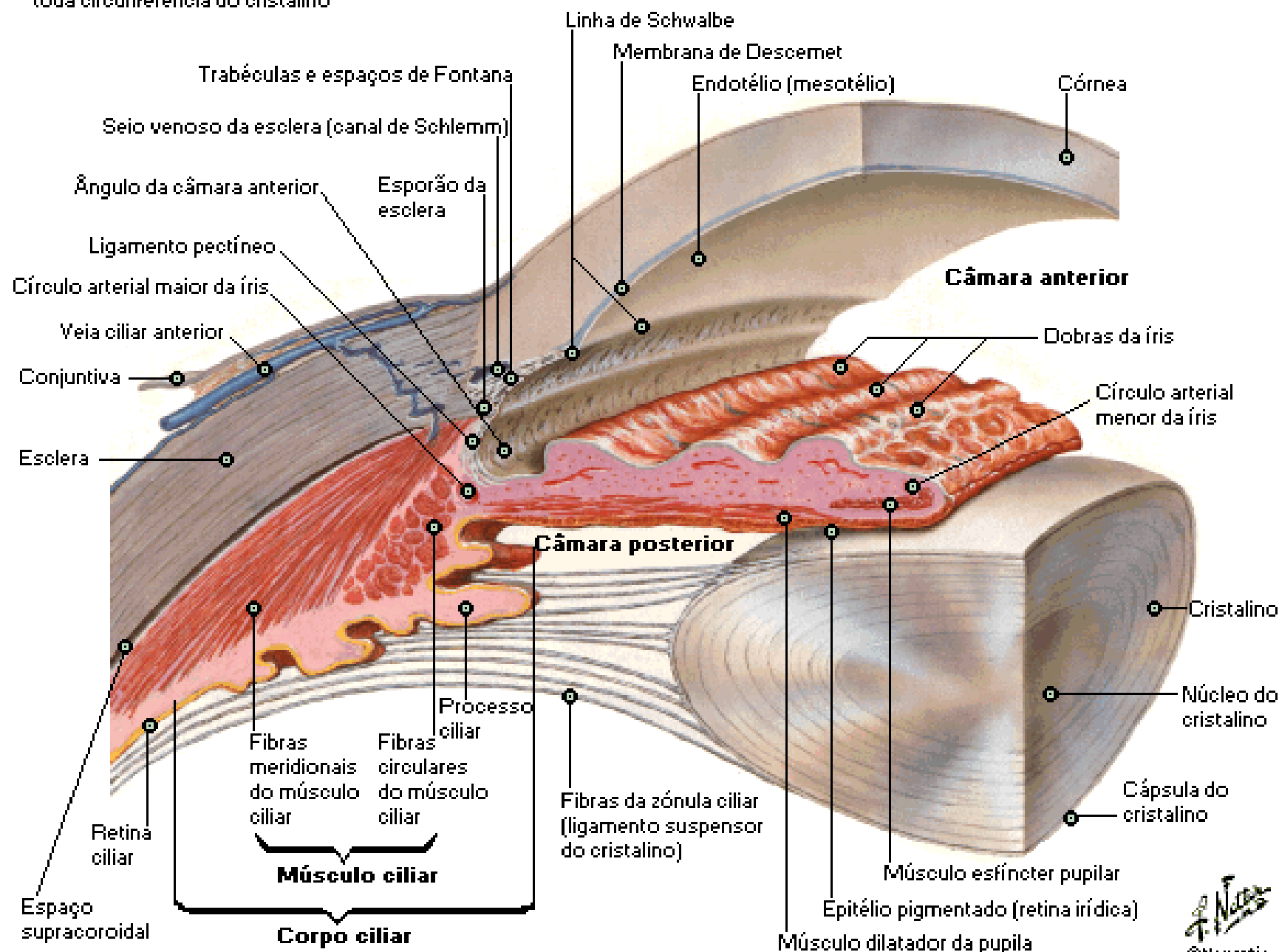
Secção Transversa



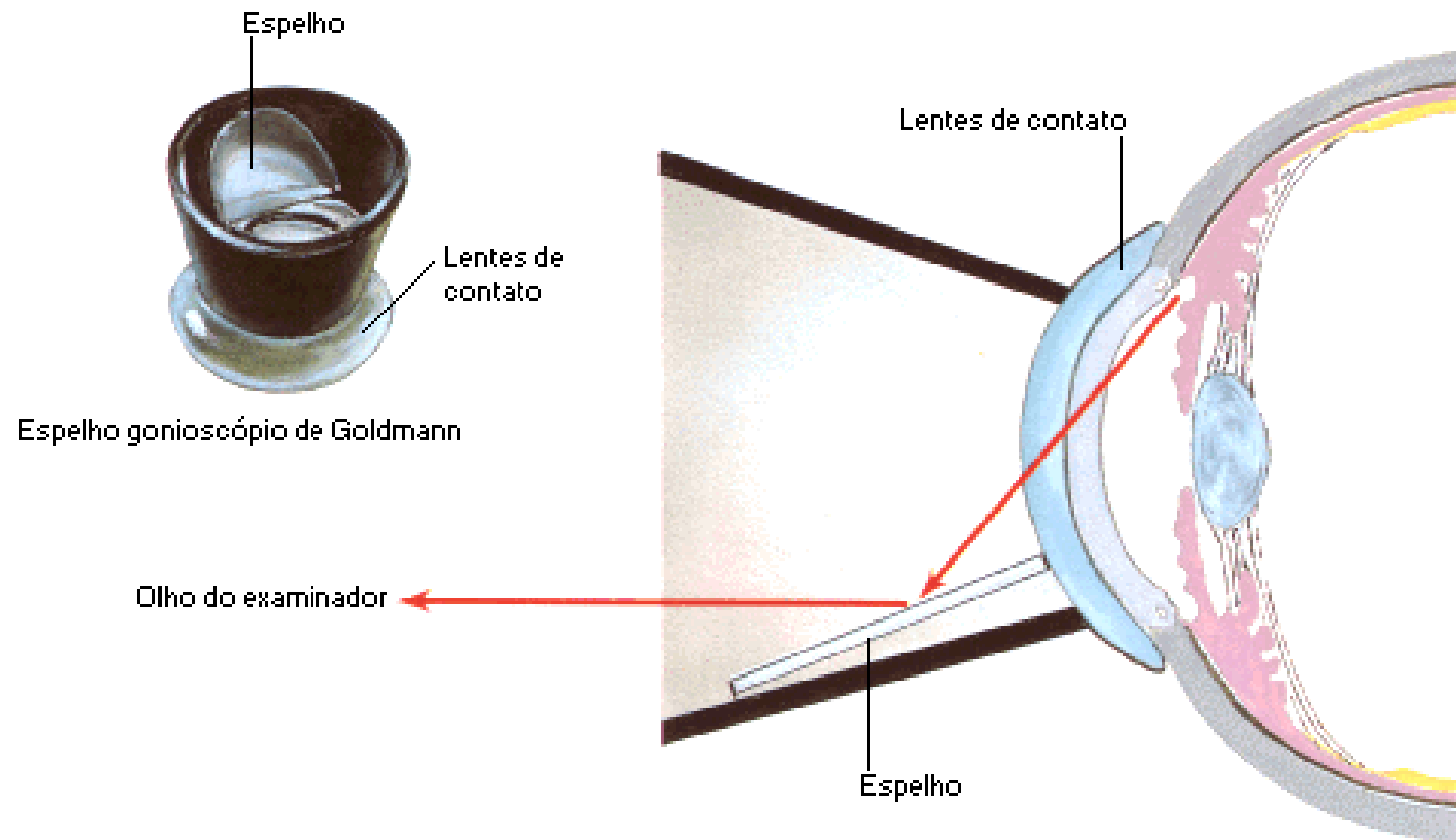
Secção horizontal

Câmaras Anterior e Posterior do Bulbo Ocular

Nota: por clareza, é mostrado somente um plano das fibras da zônula; na realidade, essas fibras circundam toda circunferência do cristalino



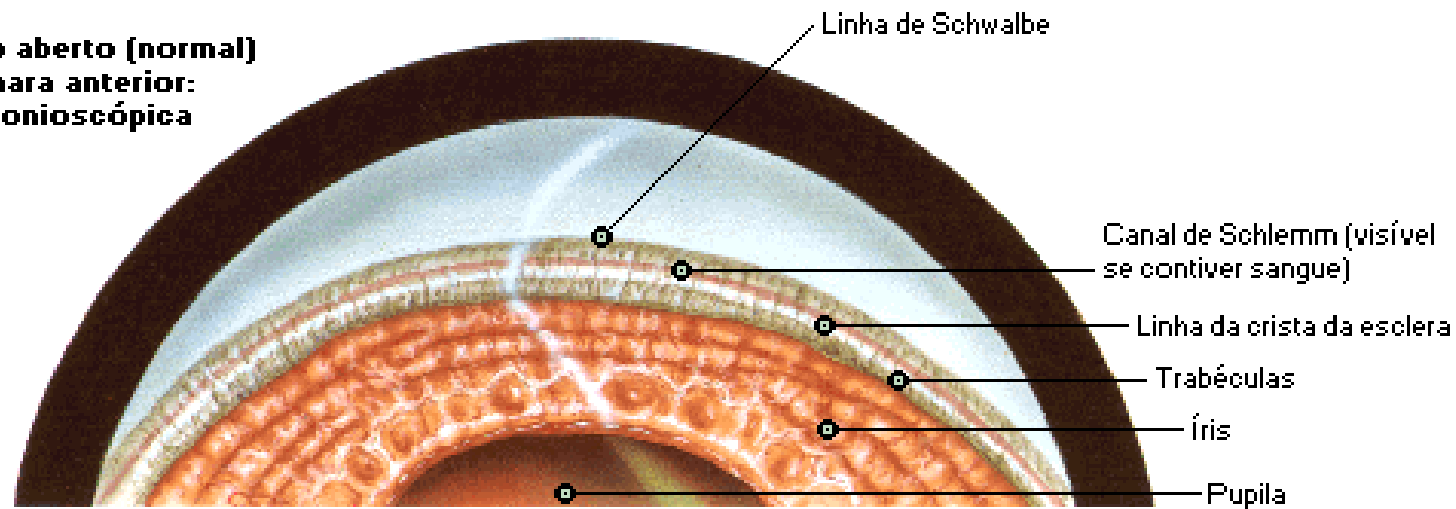
Câmara Anterior do Bulbo Ocular



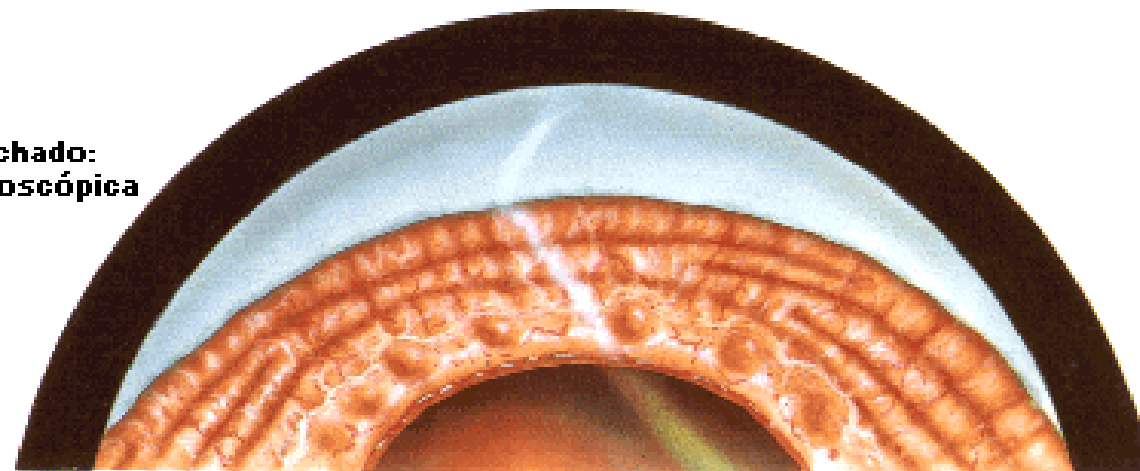
Câmara Anterior do Bulbo Ocular

Vistas Gonioscópicas

**Ângulo aberto (normal)
da câmara anterior:
vista gonioscópica**



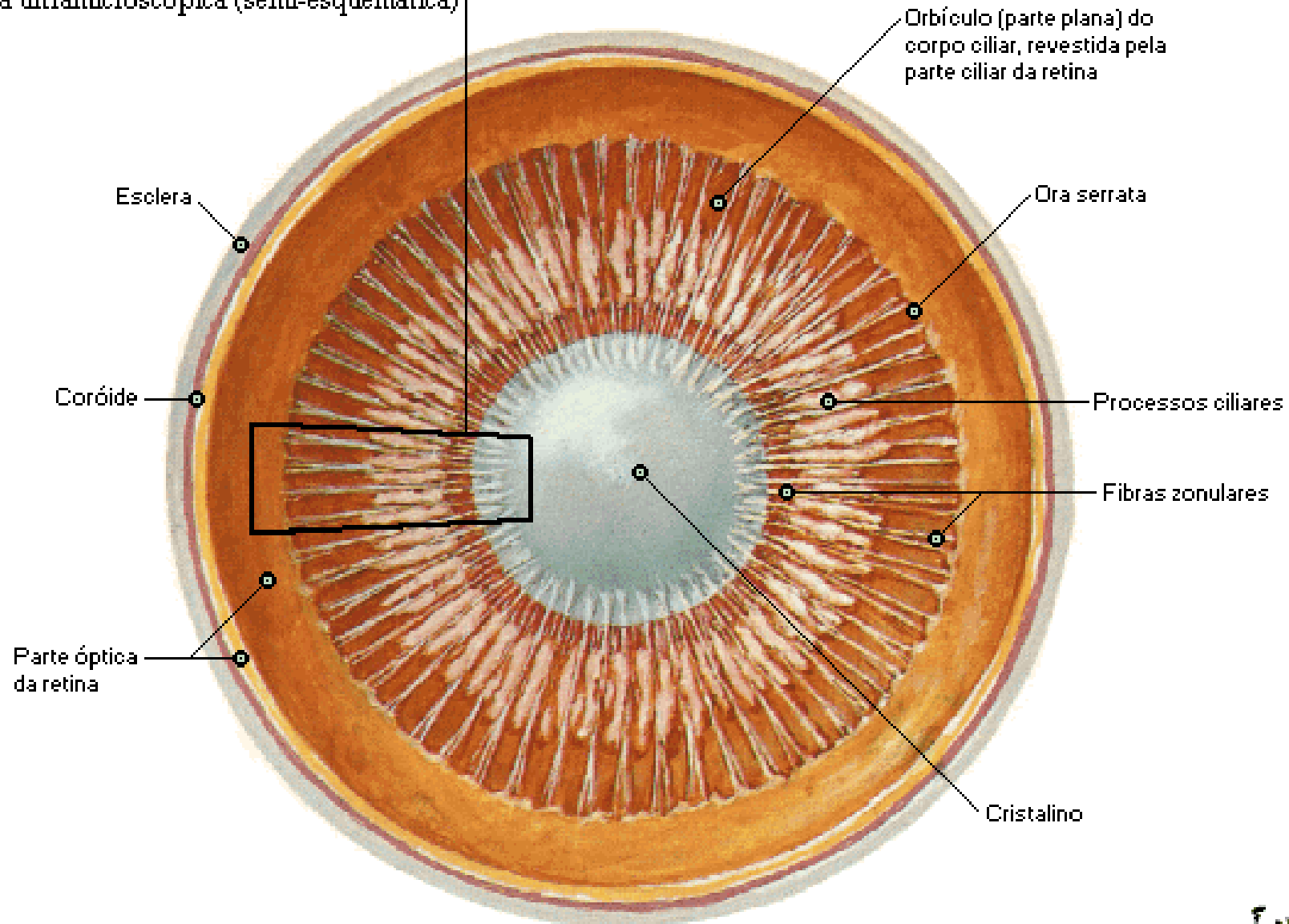
**Ângulo fechado:
vista gonioscópica**



Cristalino e Estruturas de Sustentação

Secção no Plano Frontal

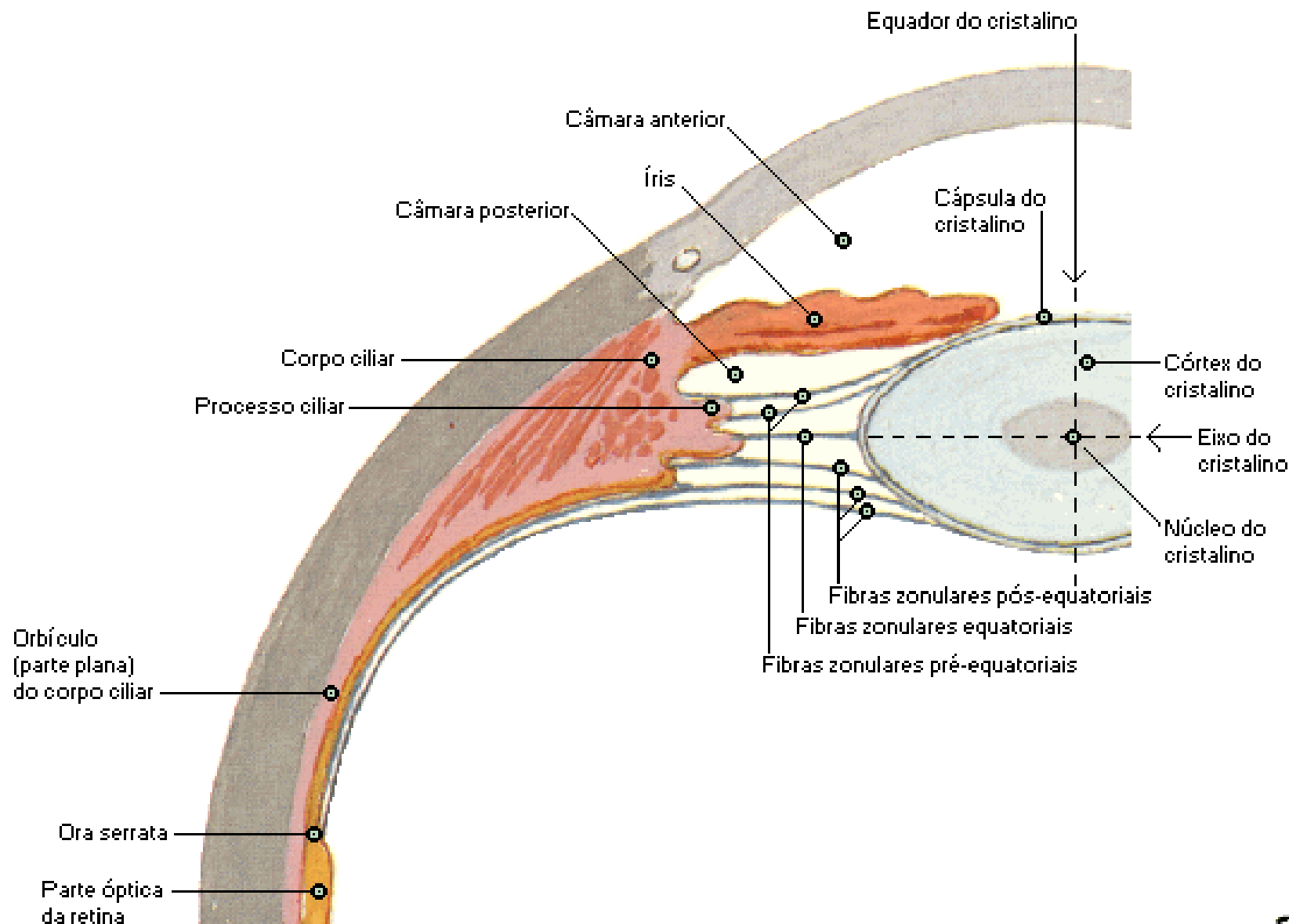
Segmento delineado na ilustração de cima, magnificado a uma escala ultramicroscópica (semi-esquemática)



Bulbo ocular: segmento anterior visto por trás

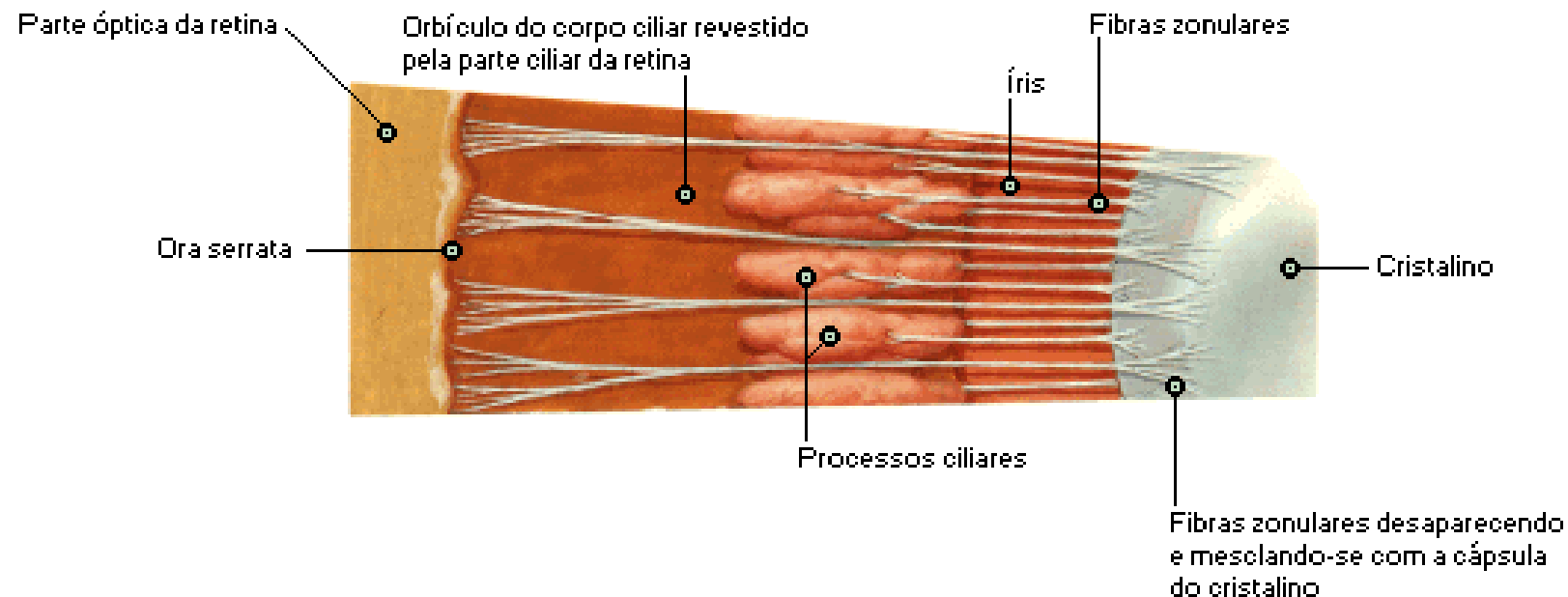
Cristalino e Estruturas de Sustentação

Secção Horizontal



Cristalino e Estruturas de Sustentação

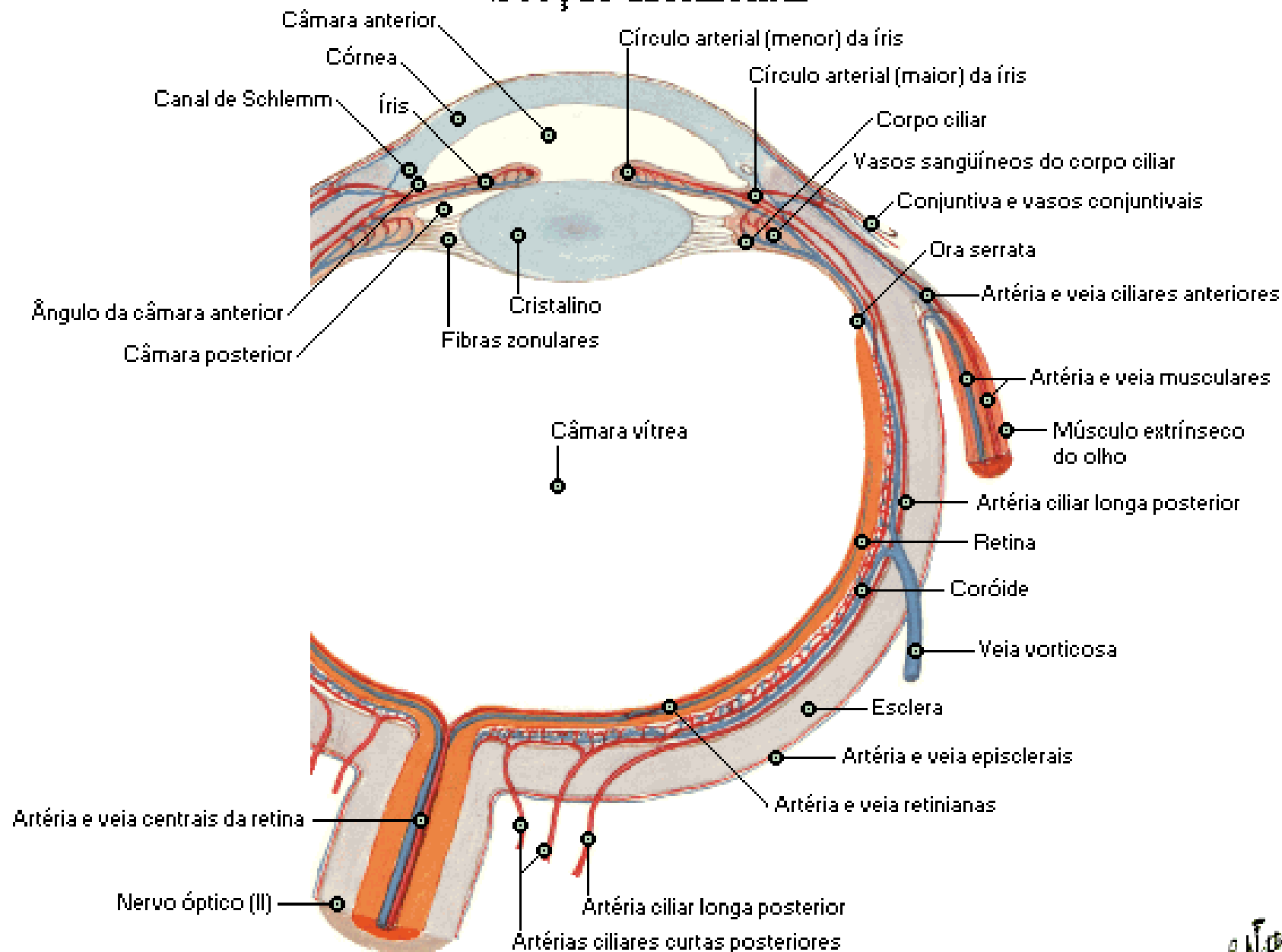
Segmento Delineado na Lâmina 85A



Magnificado a uma escala ultramicroscópica [semi-esquemática]

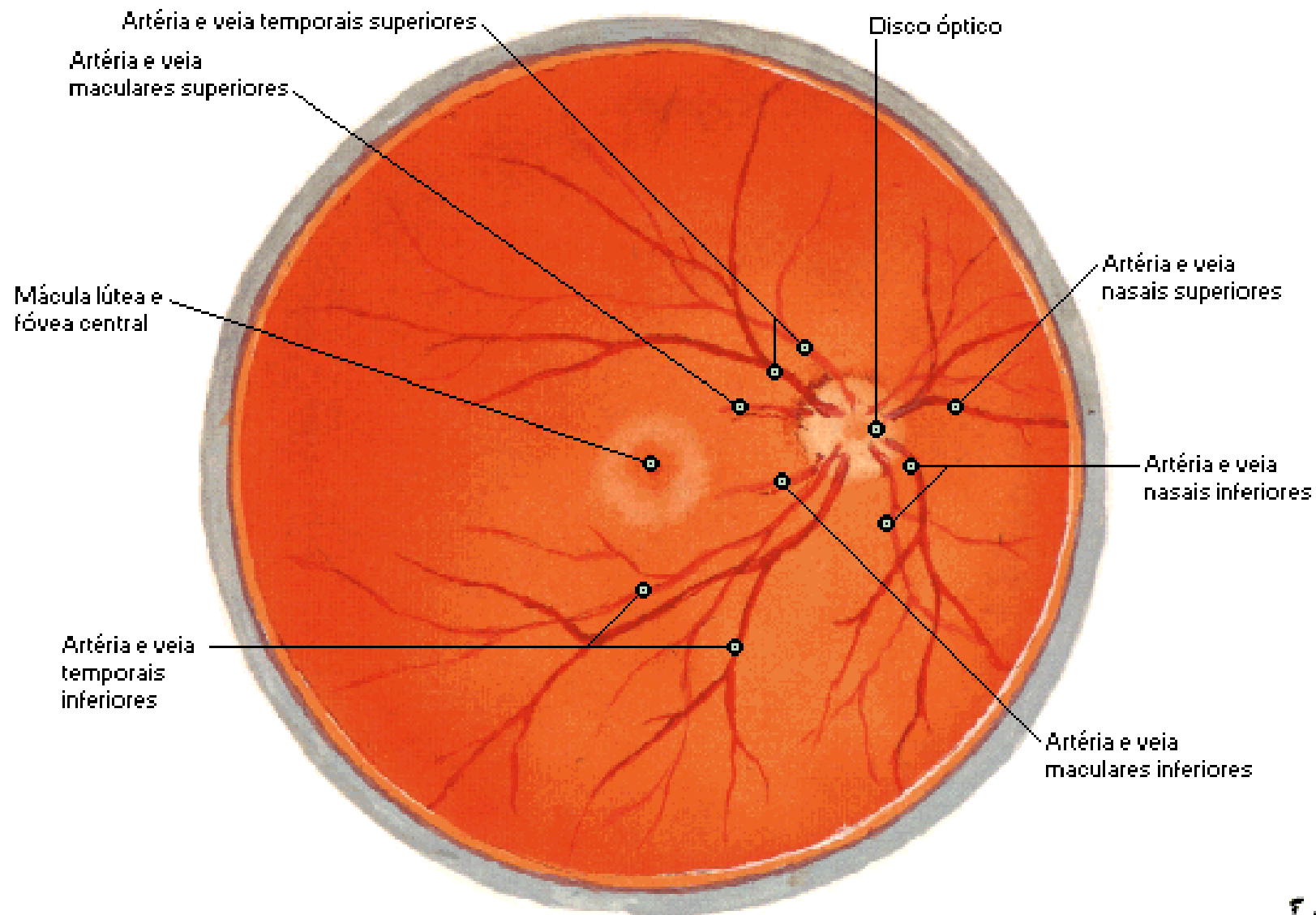
Artérias e Veias Intrínsecas do Bulbo Ocular

Secção Horizontal



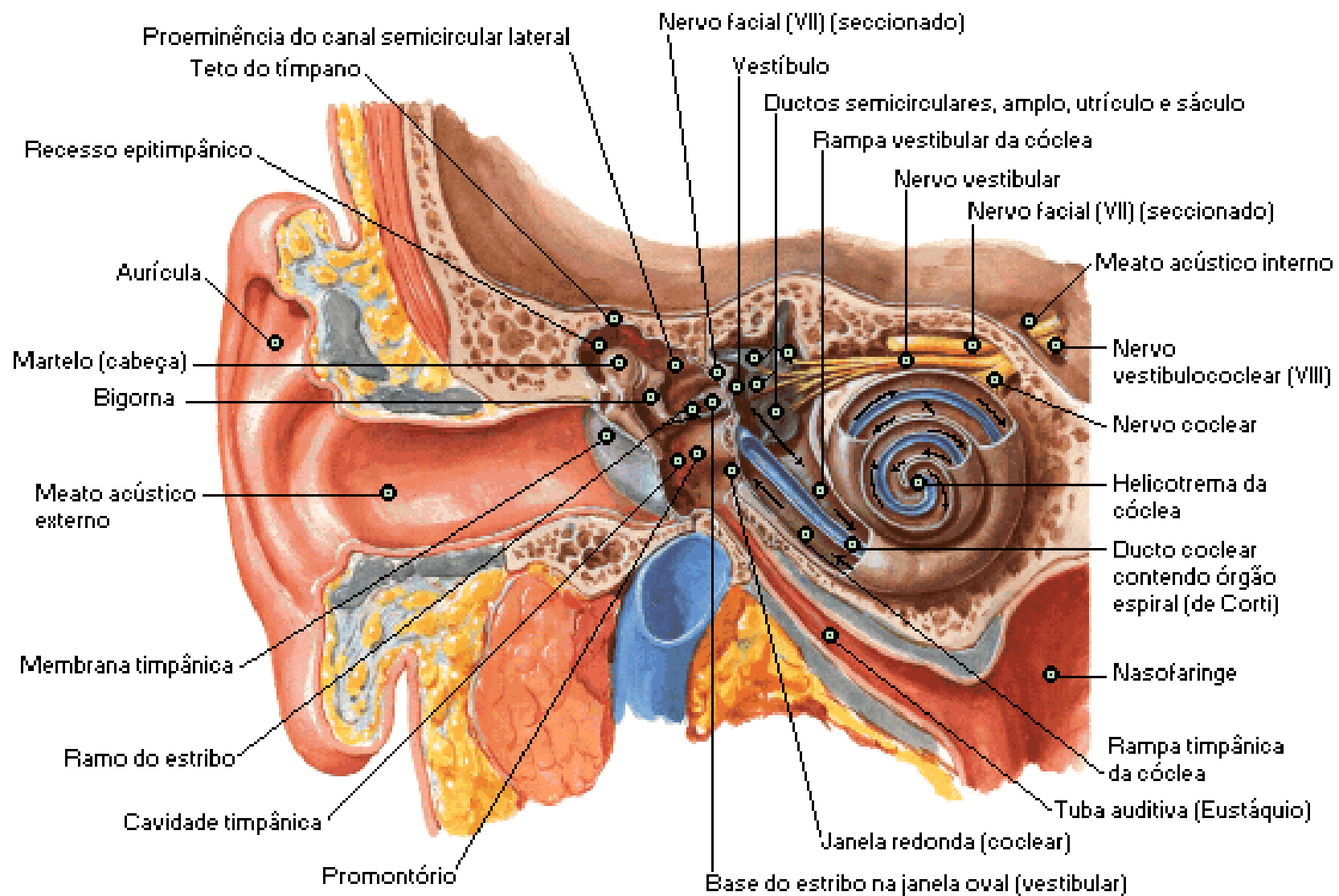
Artérias e Veias Intrínsecas do Bulbo Ocular

Vista Oftalmoscópica



Vasos retinianos direitos

Via da Recepção Sonora

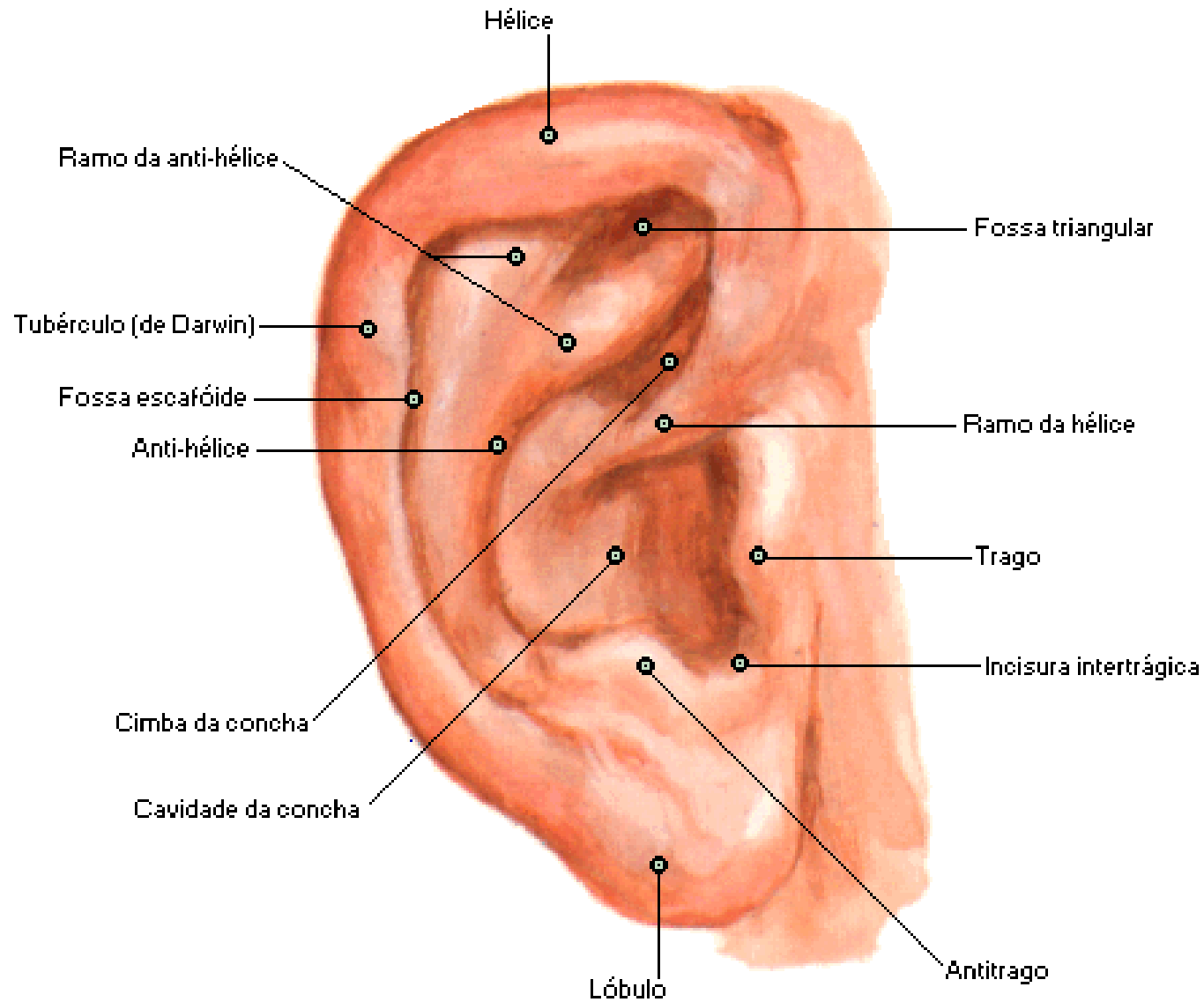


Nota: as setas indicam o trajeto das ondas sonoras

Secção frontal esquematizada

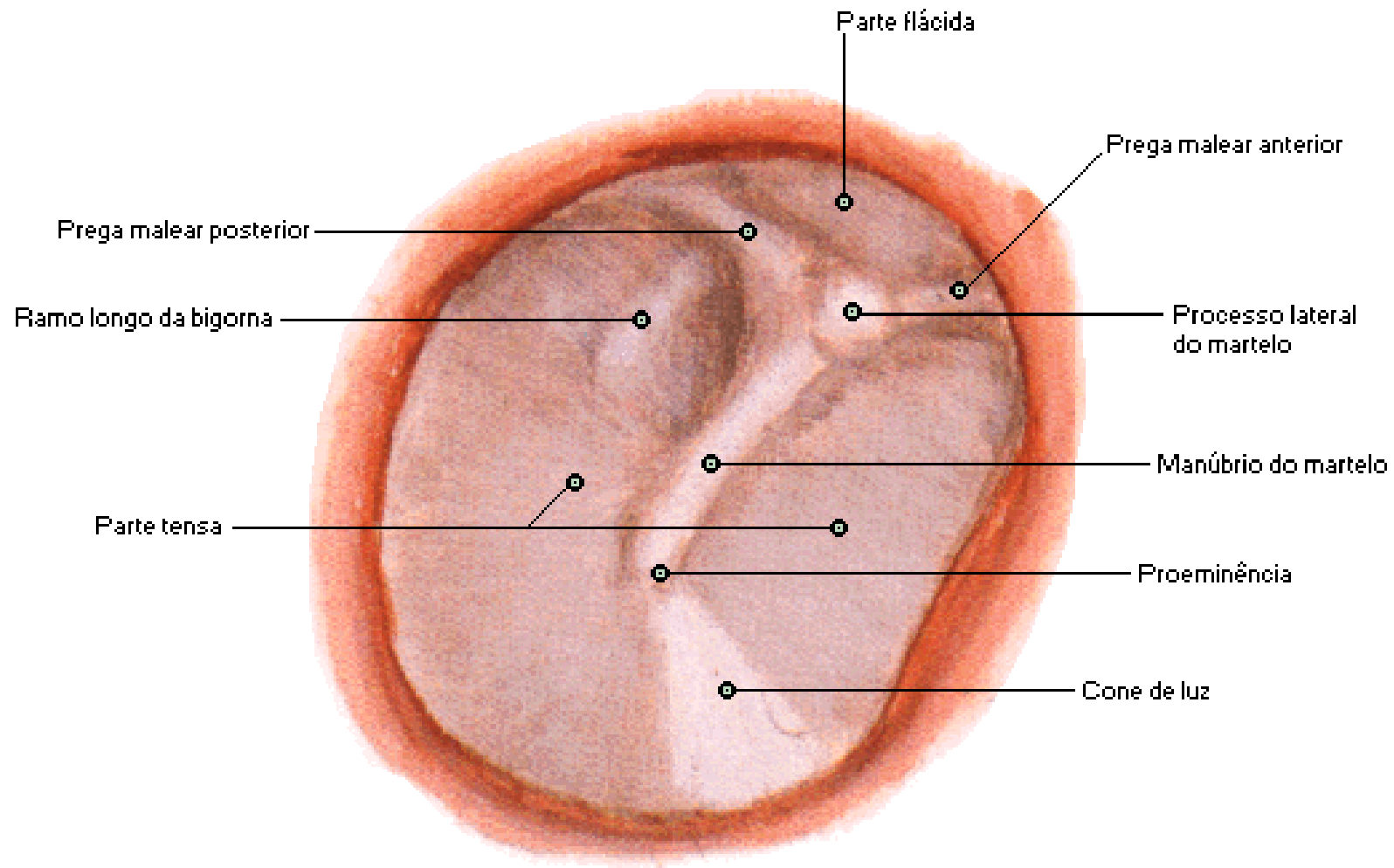
Orelha Externa

Pavilhão Auricular Direito



Orelha Externa

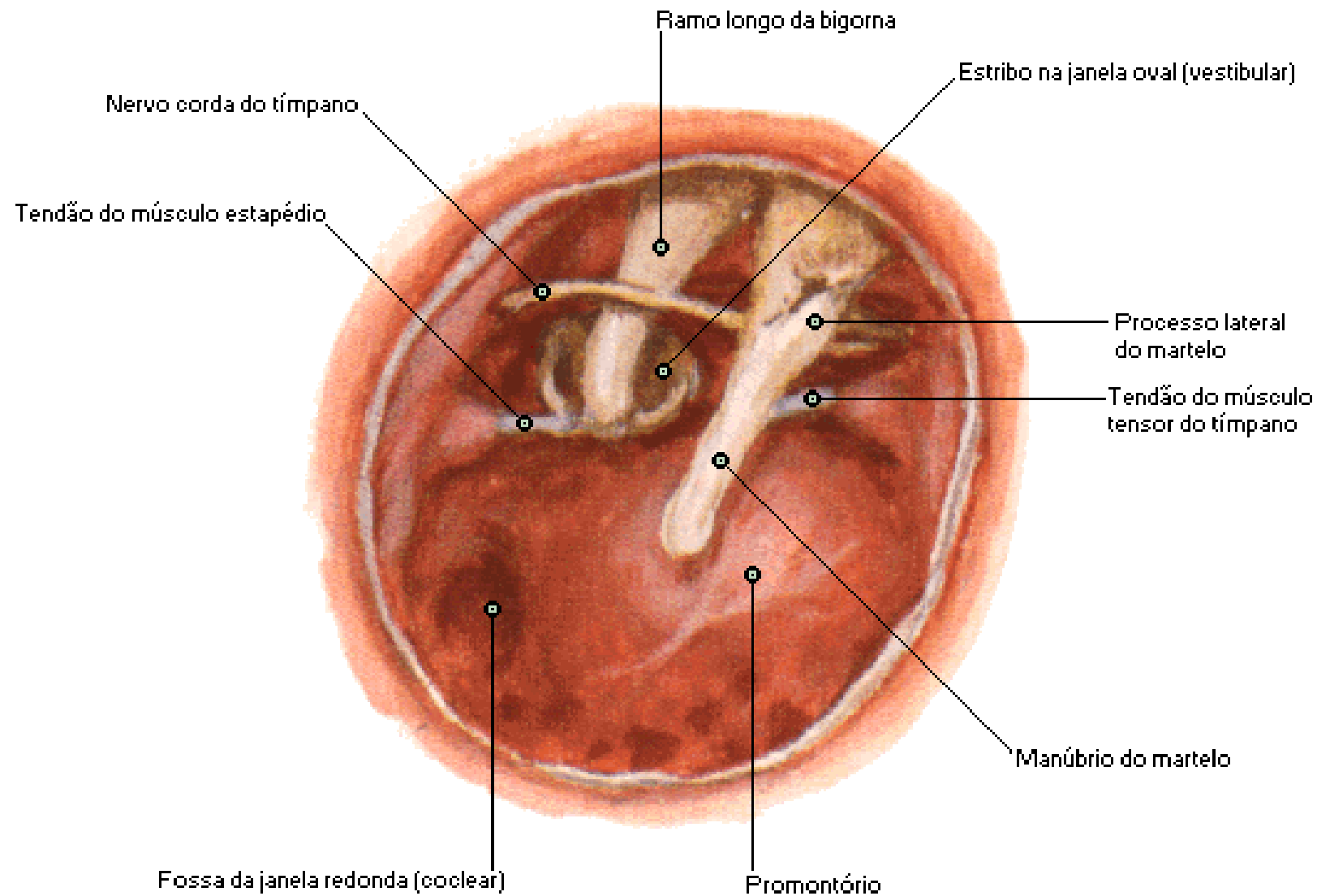
Membrana Timpânica Direita



Vista através do espéculo

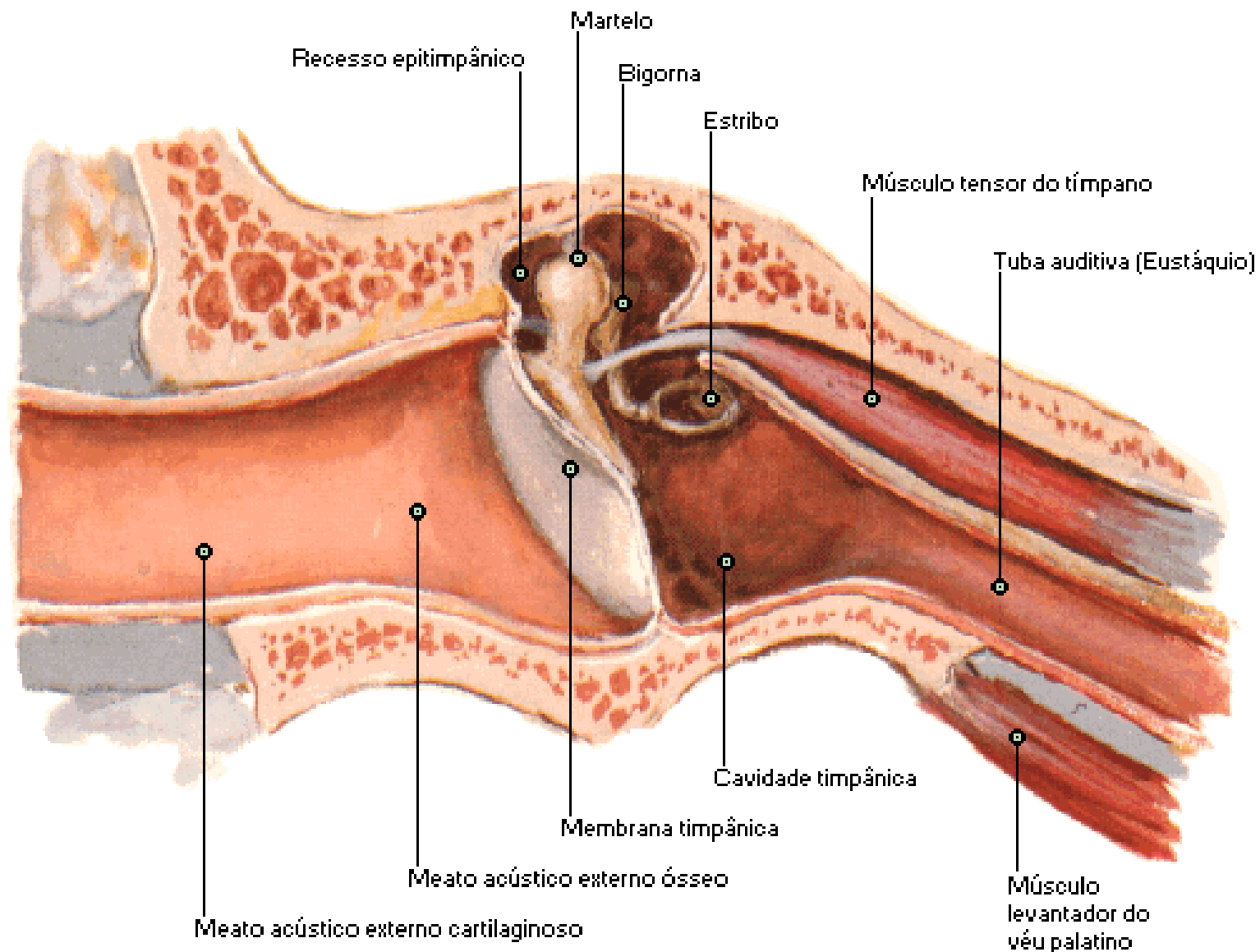
Cavidade Timpânica

Vista a Partir do Meato Acústico Externo



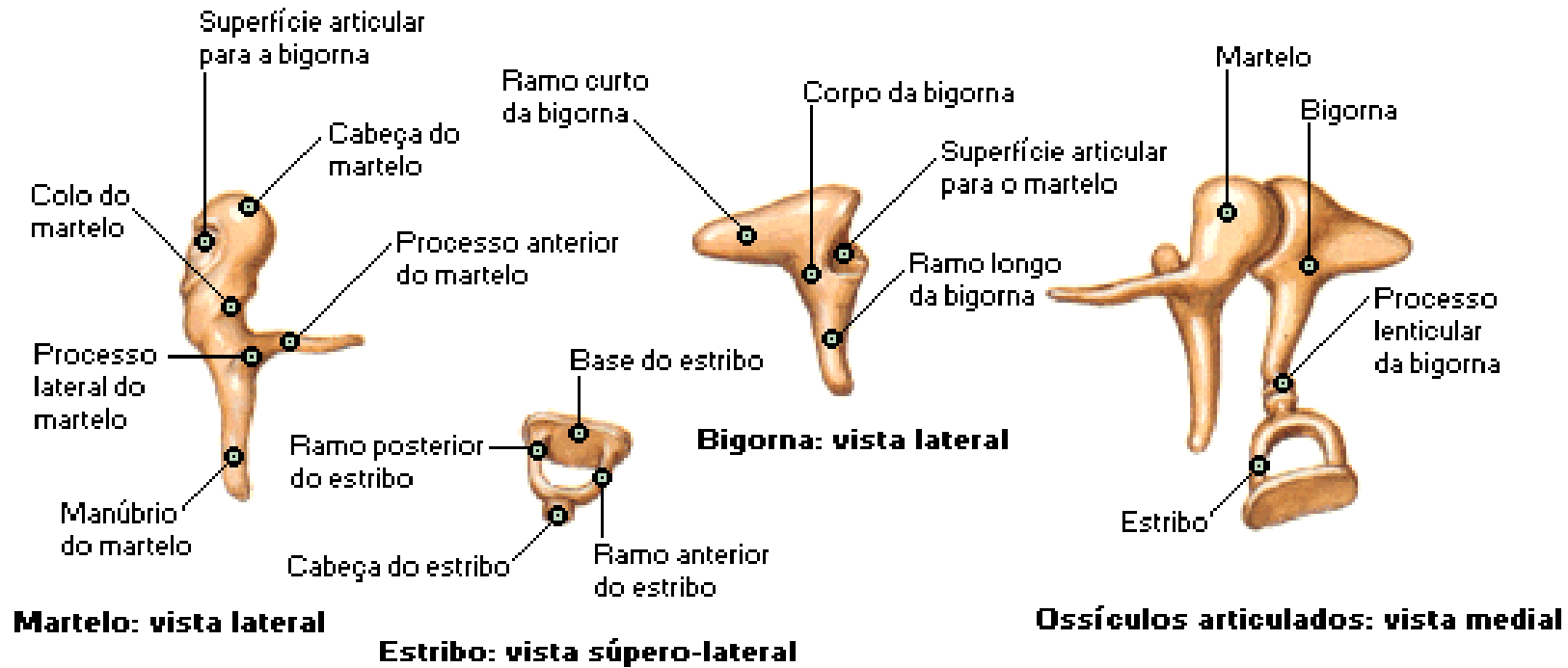
Orelha Externa e Cavidade Timpânica

Secção Obliqua Coronal



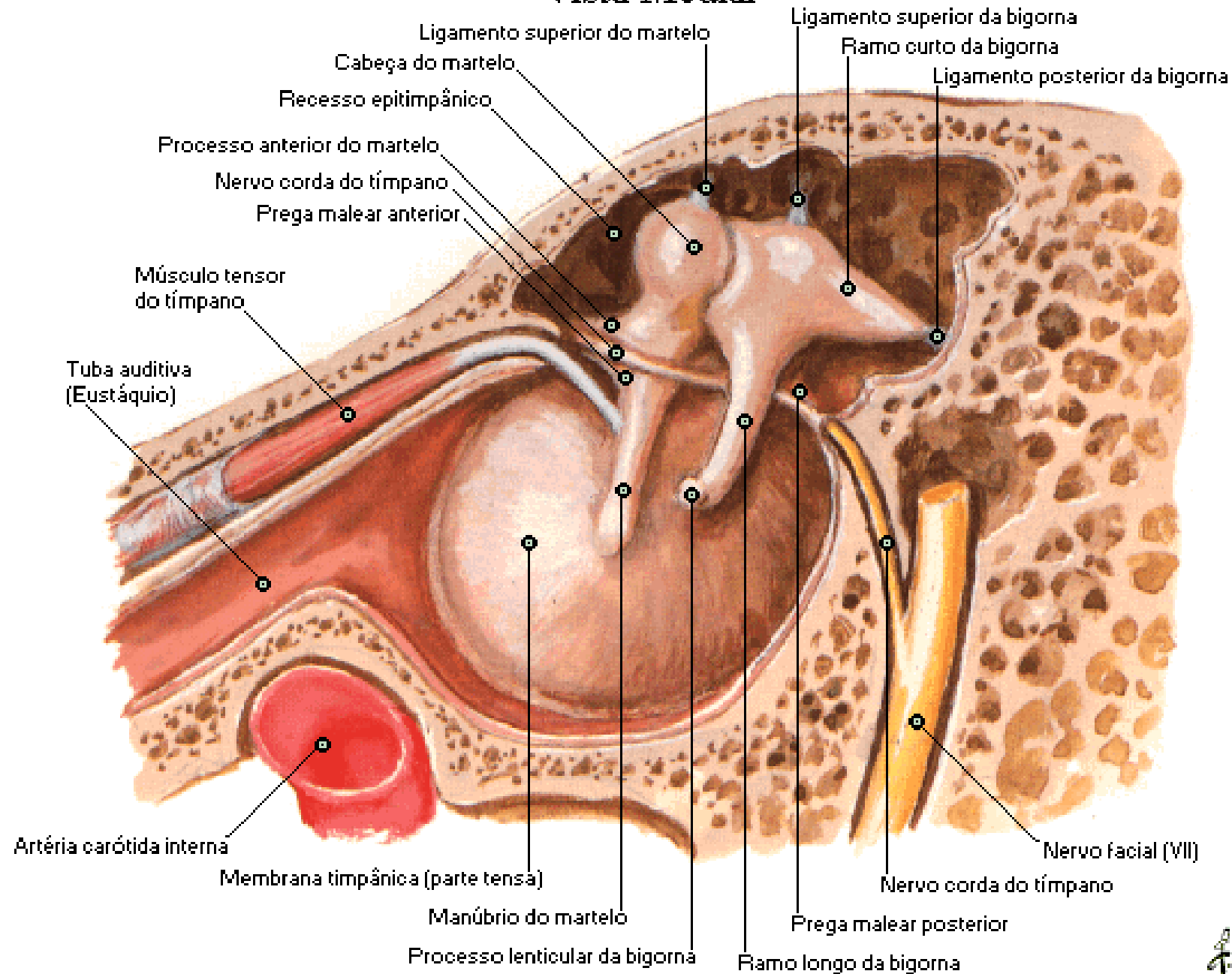
Cavidade Timpânica

Ossículos Auditivos



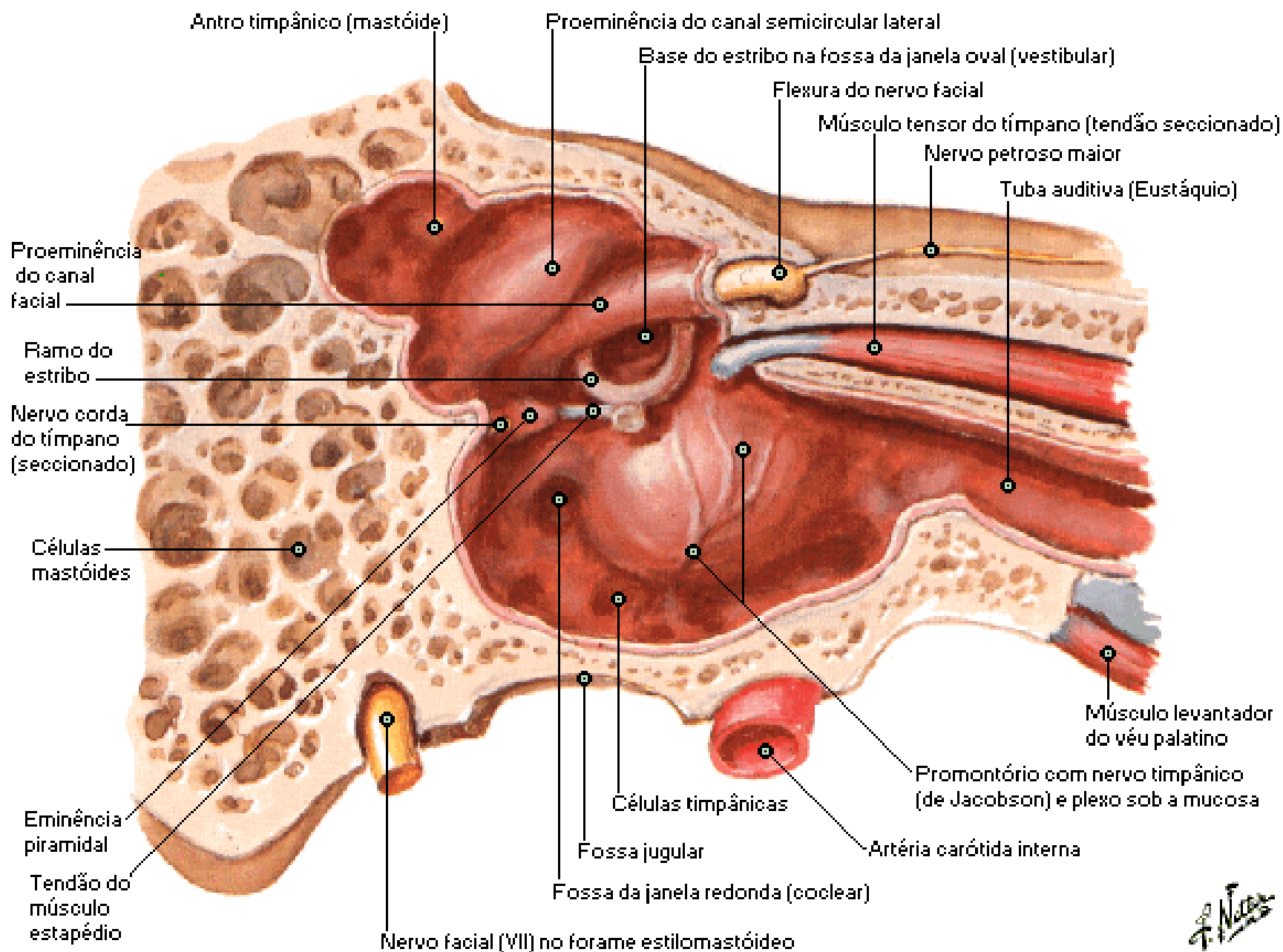
Cavidade Timpânica - Parede Lateral

Vista Medial



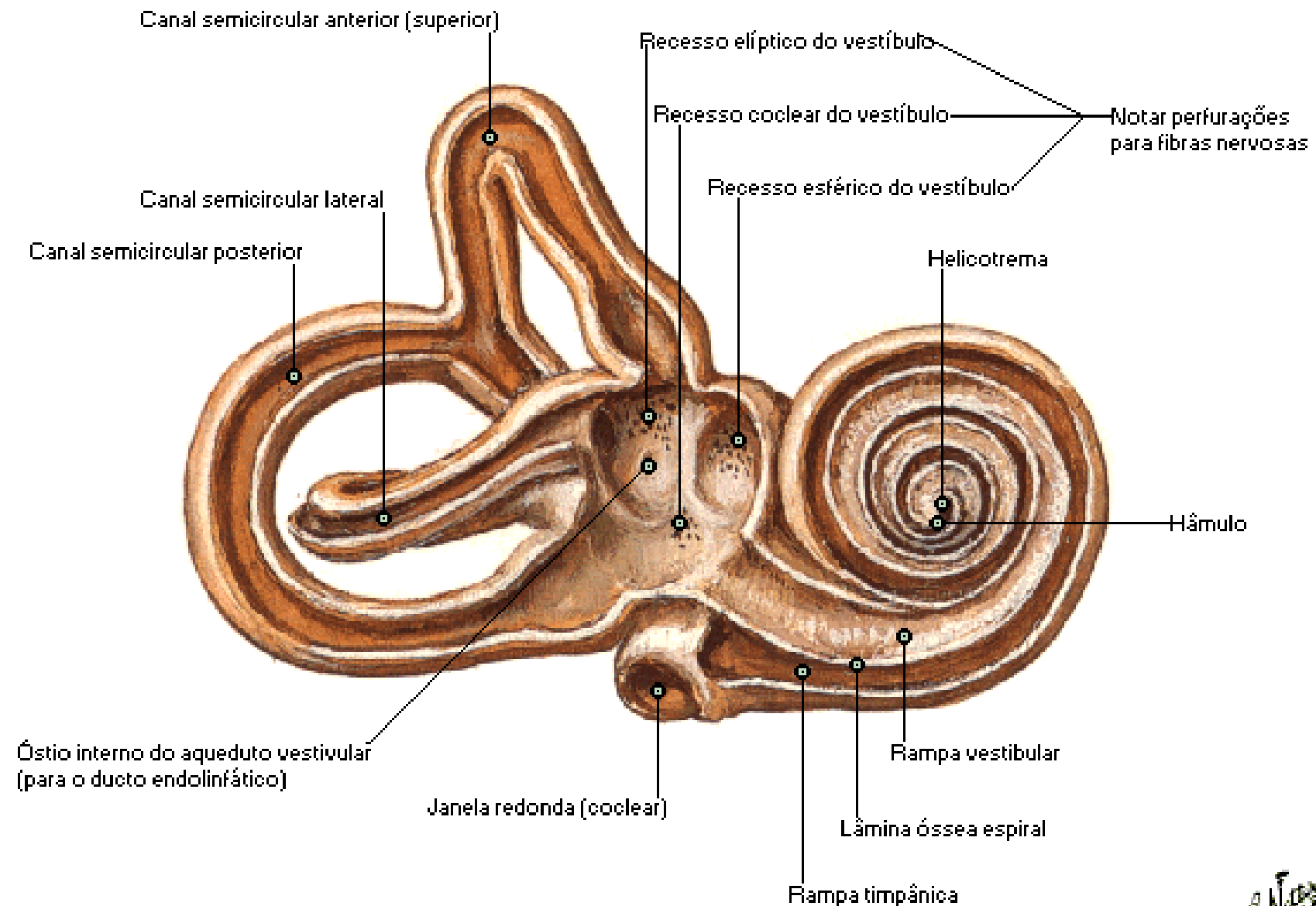
Parede Medial da Cavidade Timpânica

Vista Lateral



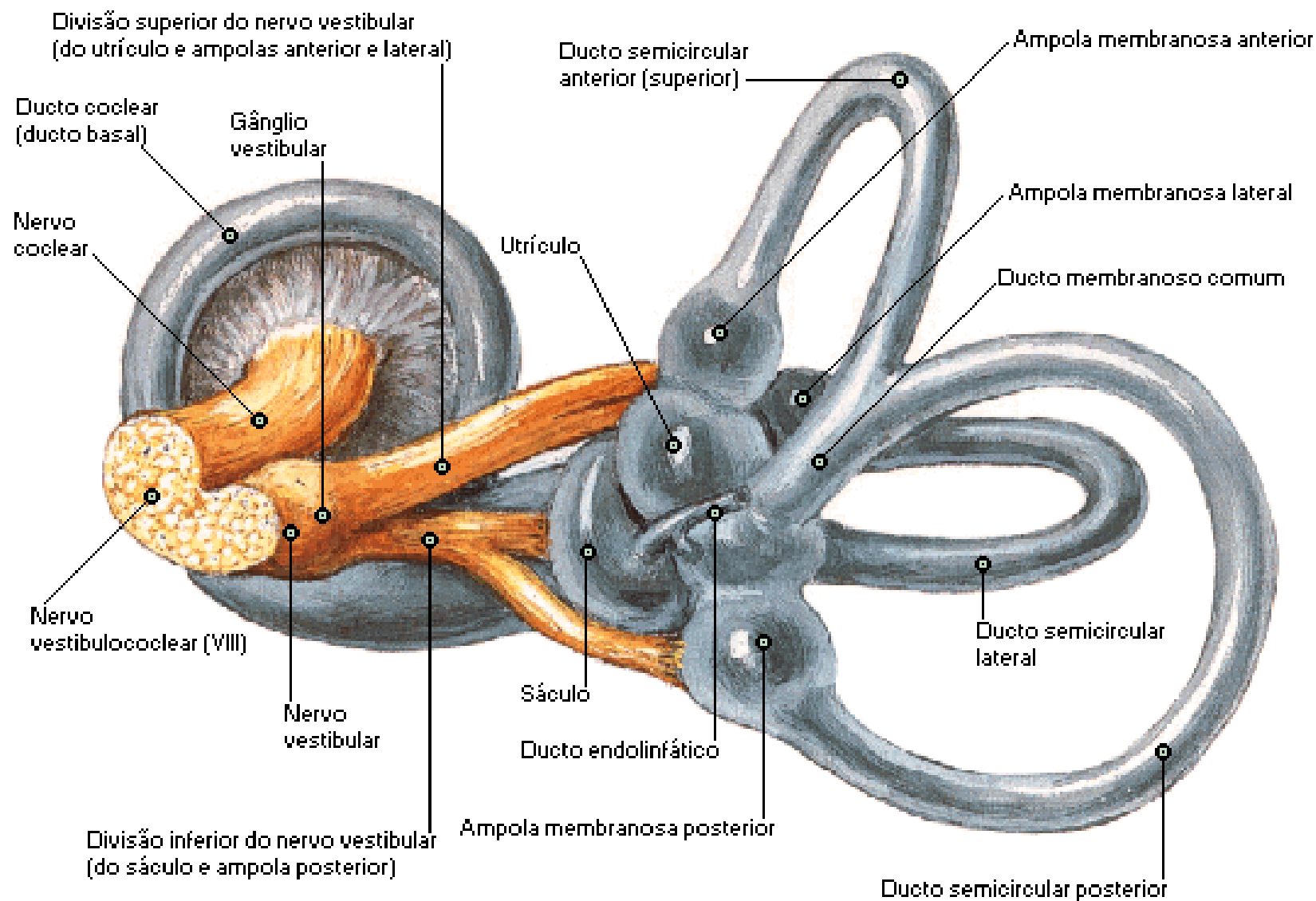
Labirinto Ósseo Direito Dissecado

Labirinto Membranoso Removido



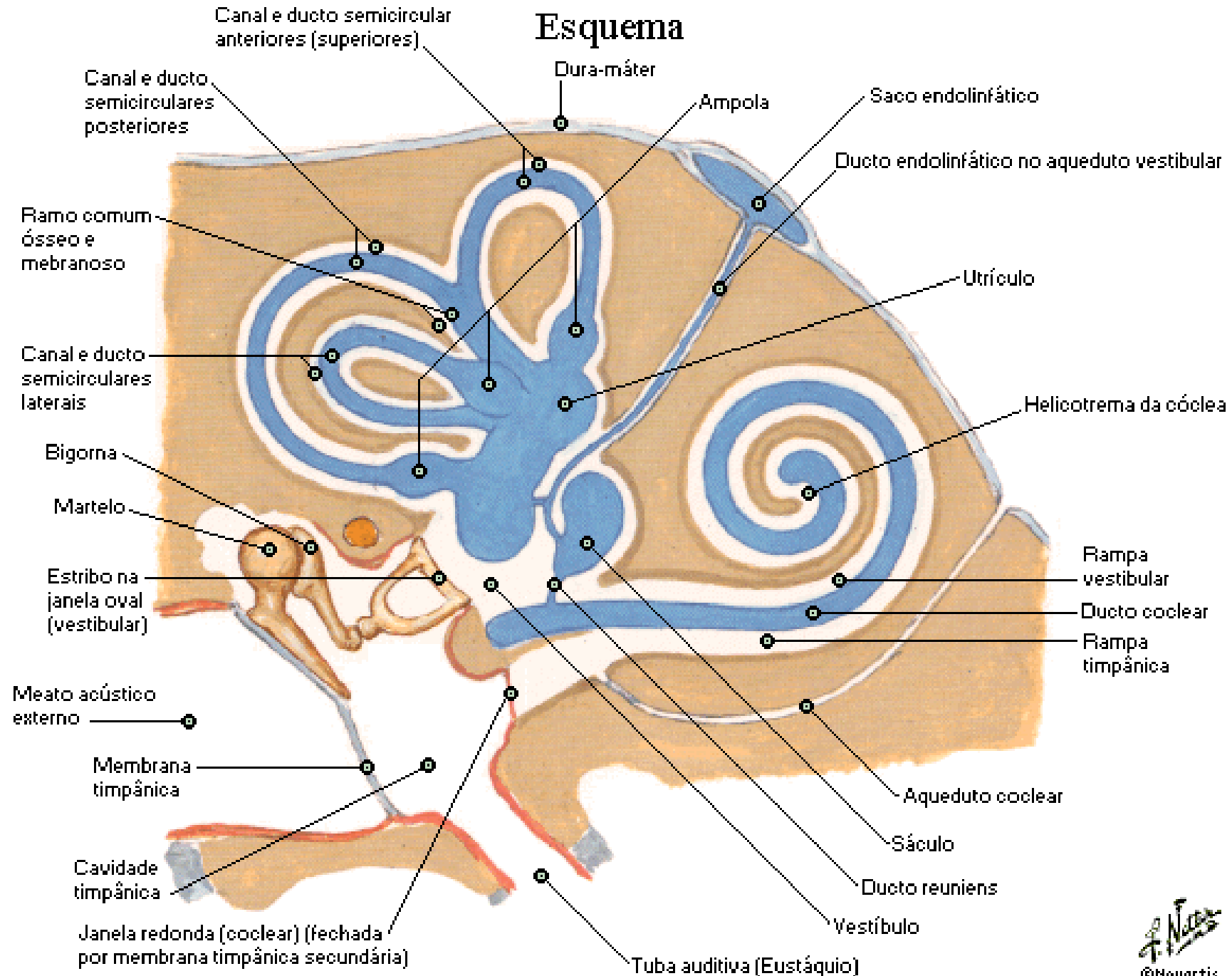
Labirinto Membranoso Direito com Nervos

Vista Pósterio-medial



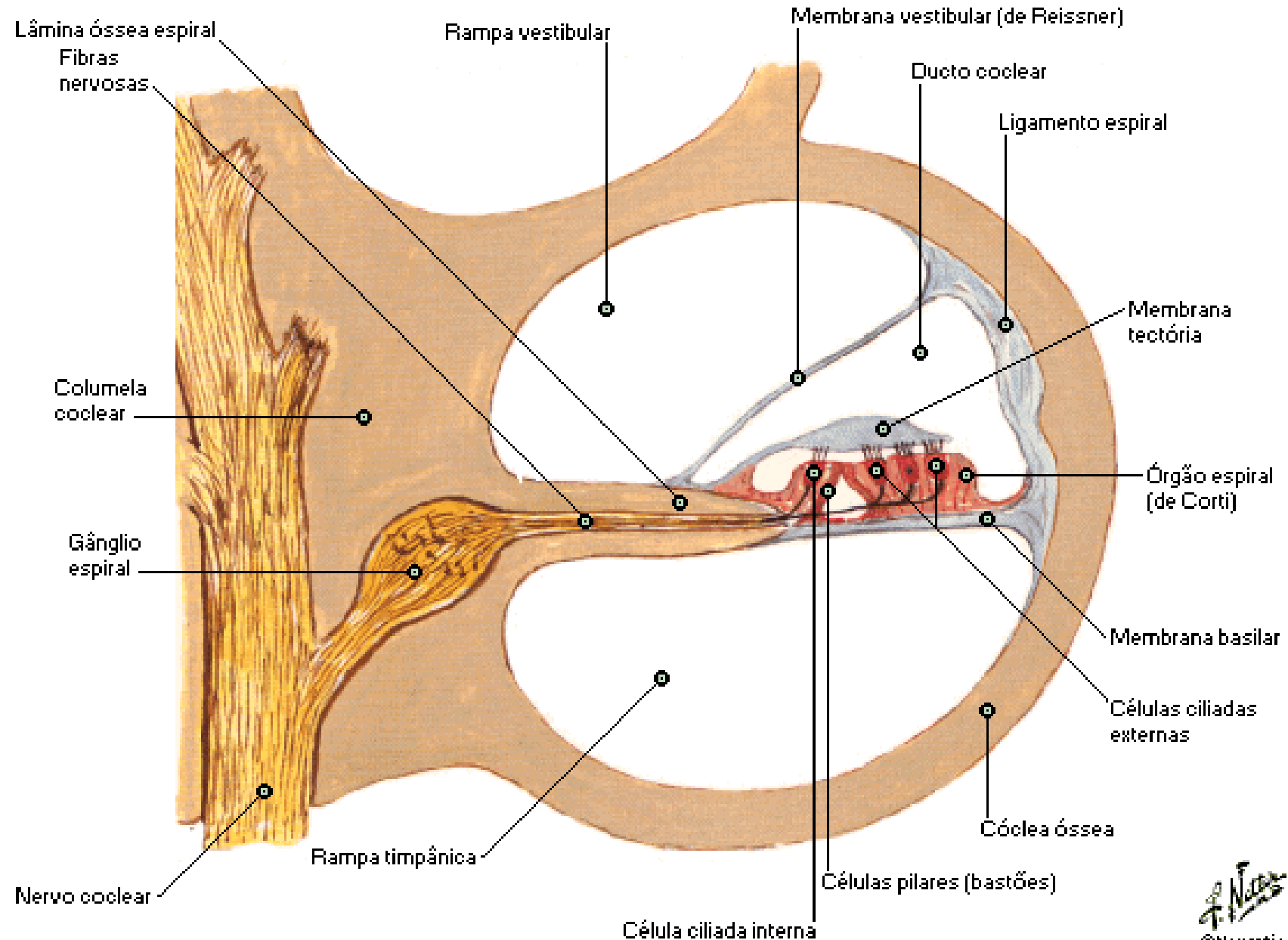
Labirinto Ósseo e Membranoso

Esquema



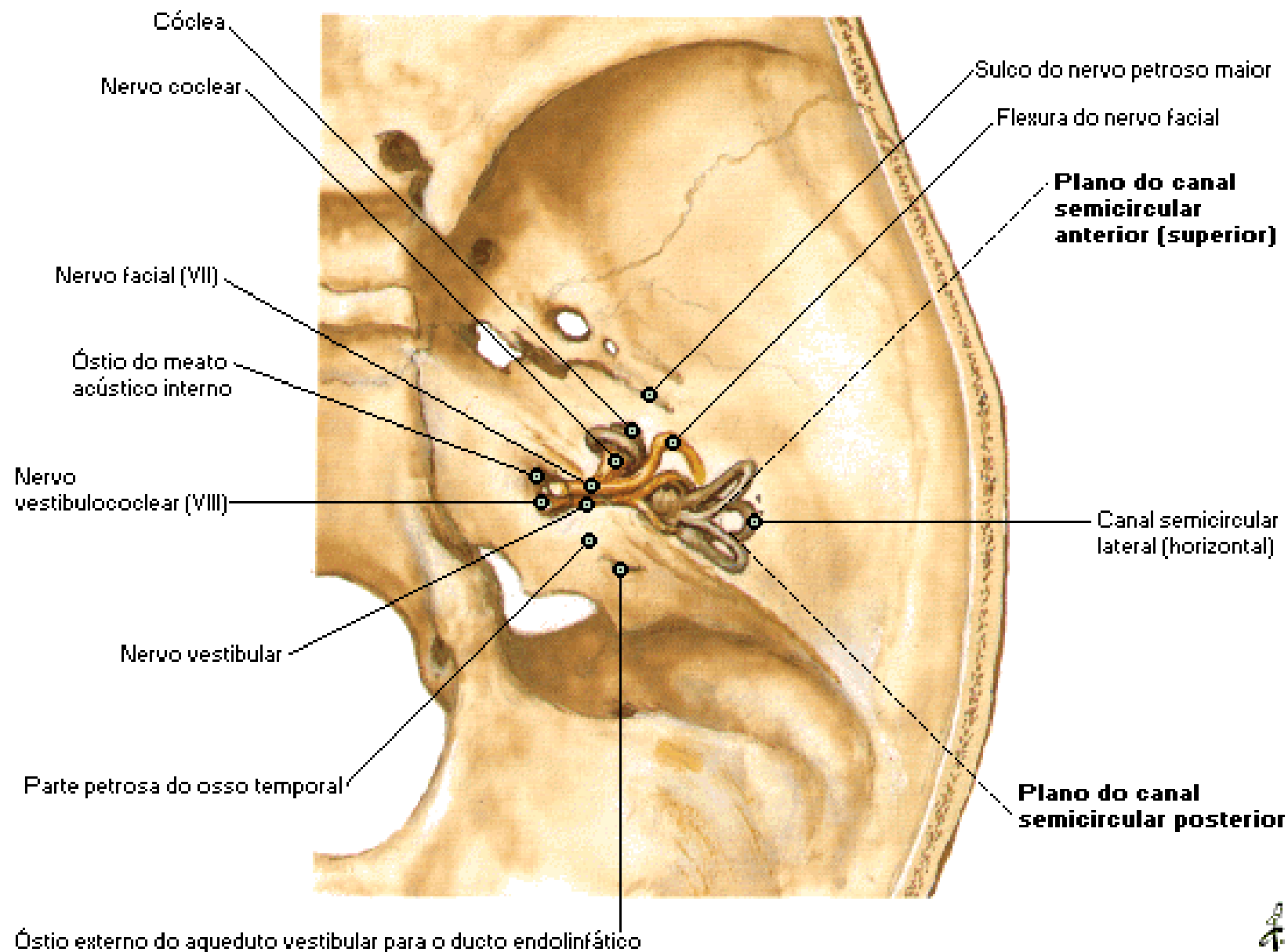
Labirintos Ósseo e Membranoso

Secção Através do Ducto Coclear



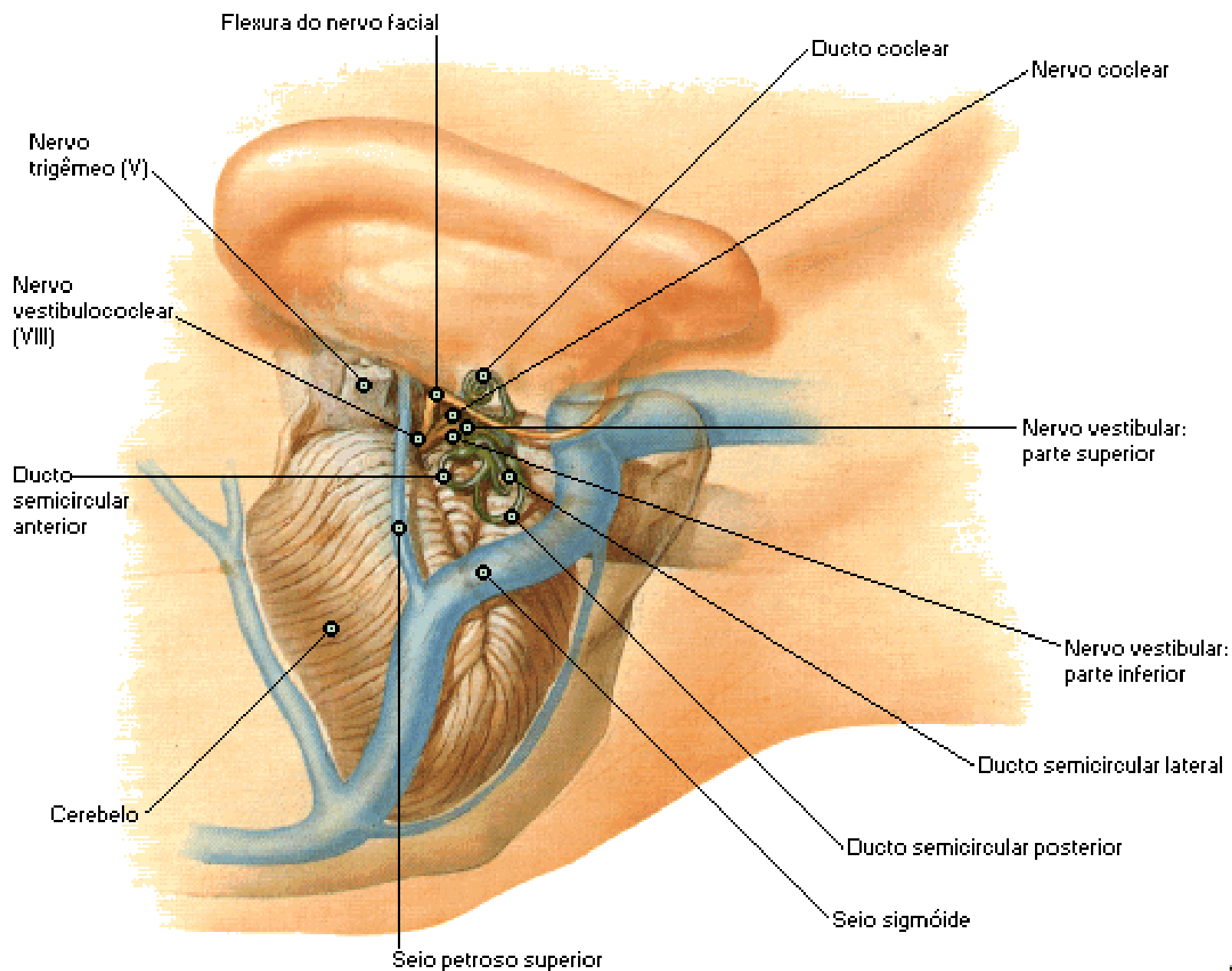
Orientação do Labirinto no Crânio

Projeção Superior



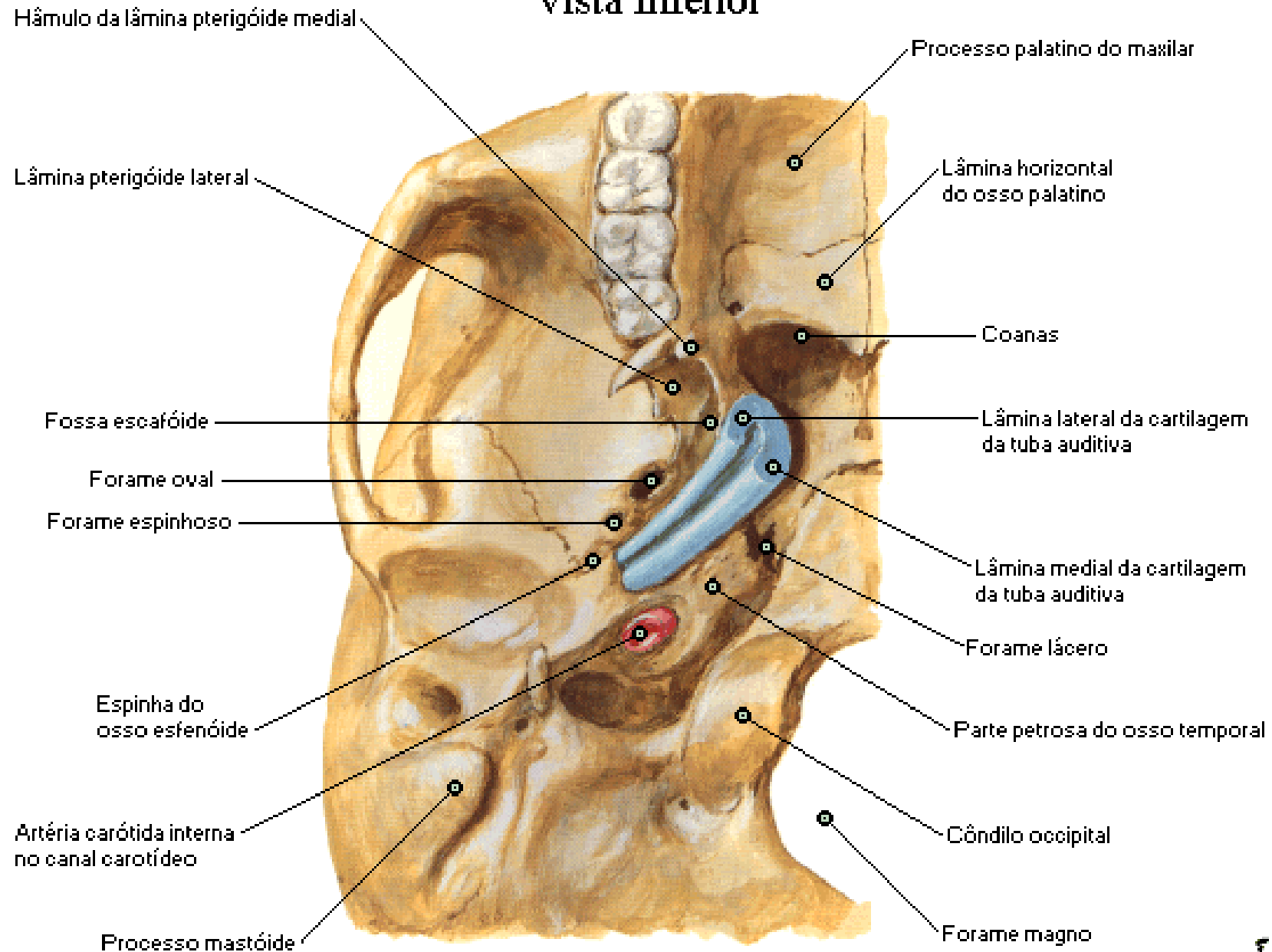
Orientação do Labirinto no Crânio

Projeção Lateral



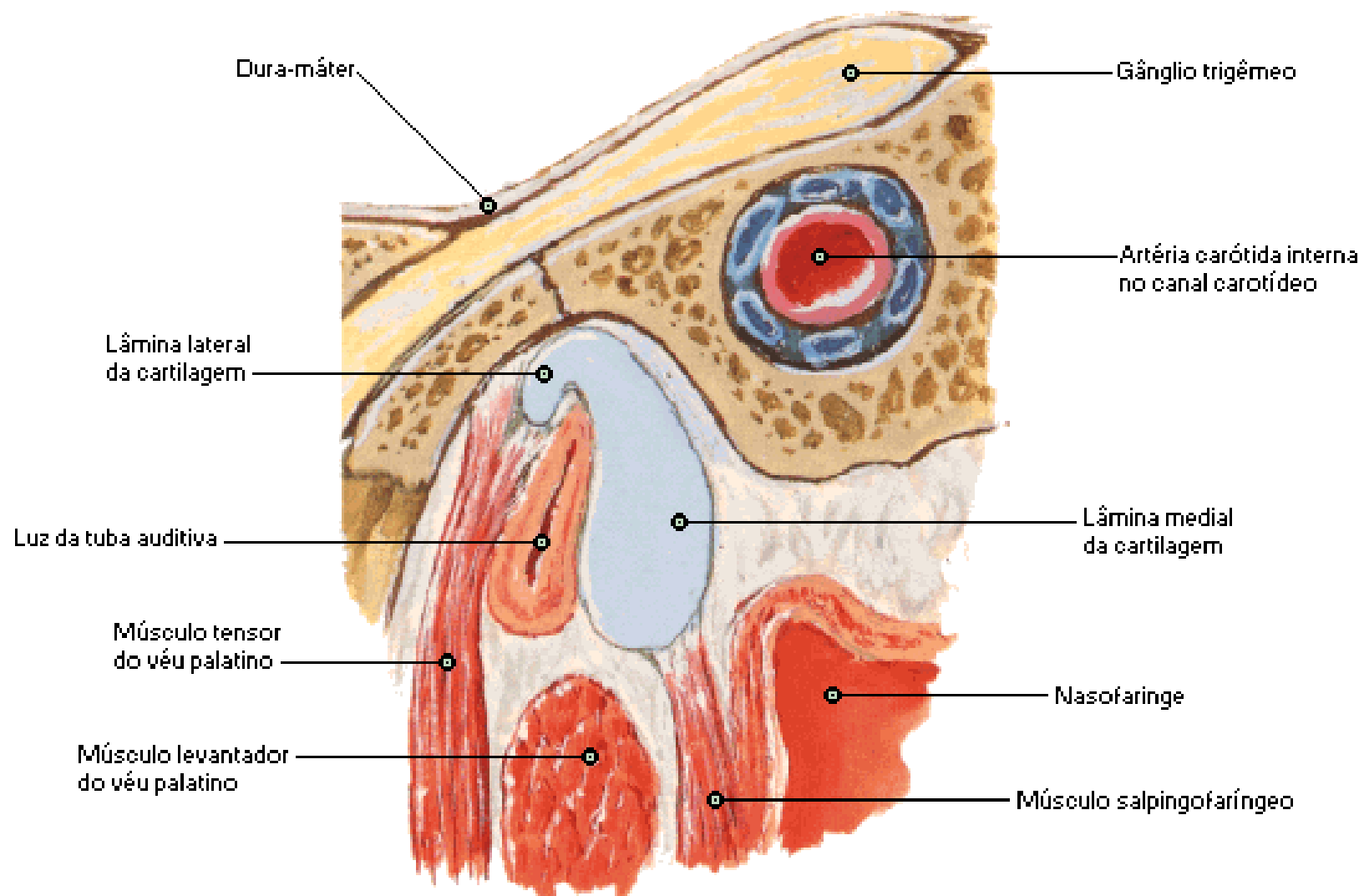
Cartilagem da Tuba Auditiva na Base do Crânio

Vista Inferior



Tuba Auditiva - Secção Através da Cartilagem

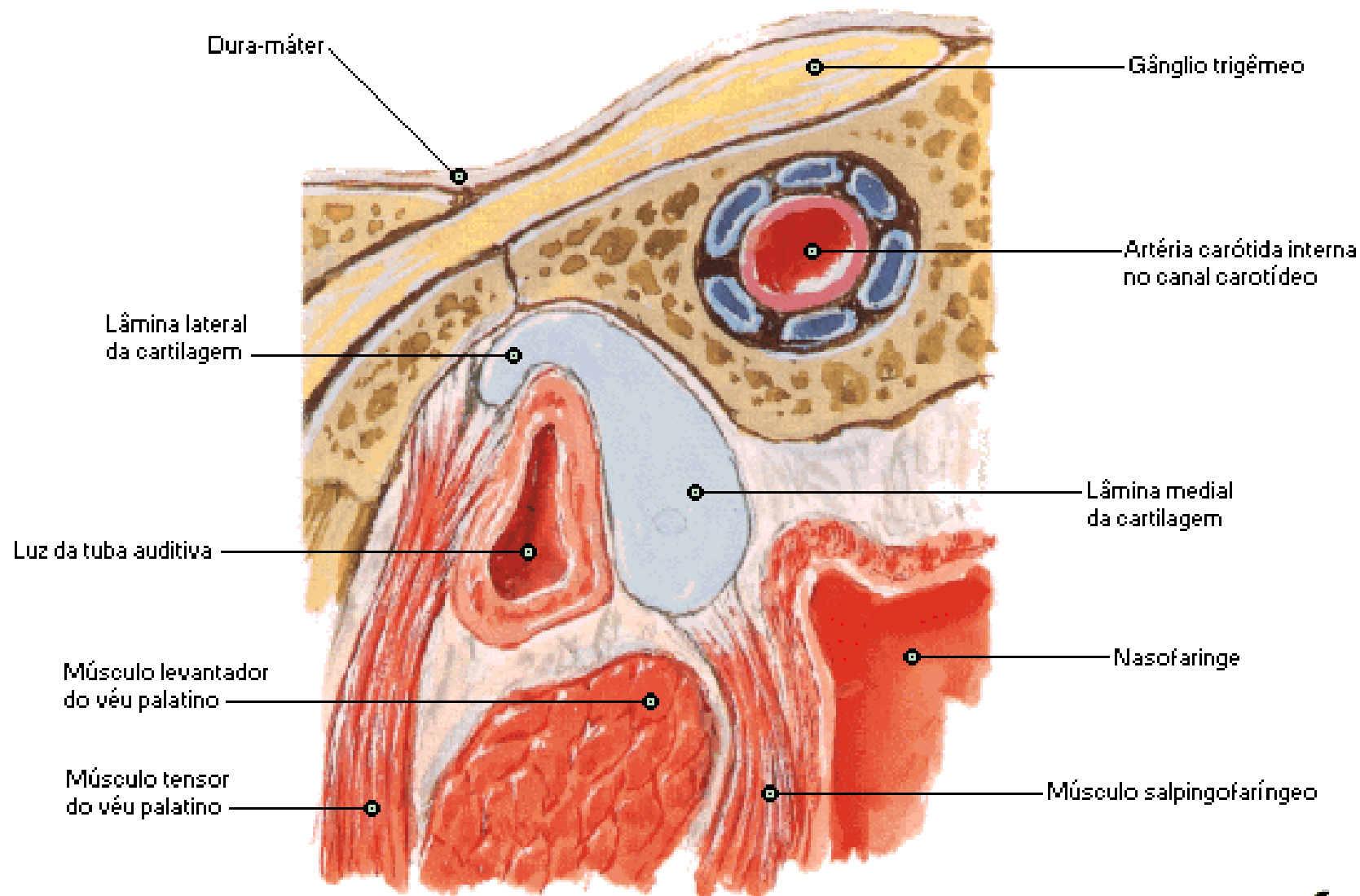
Tuba Auditiva Ocluída



Tuba auditiva fechada por recuo da cartilagem, turgidez tecidual e tensão dos músculos salpingofaríngeos

Tuba Auditiva - Secção Através da Cartilagem

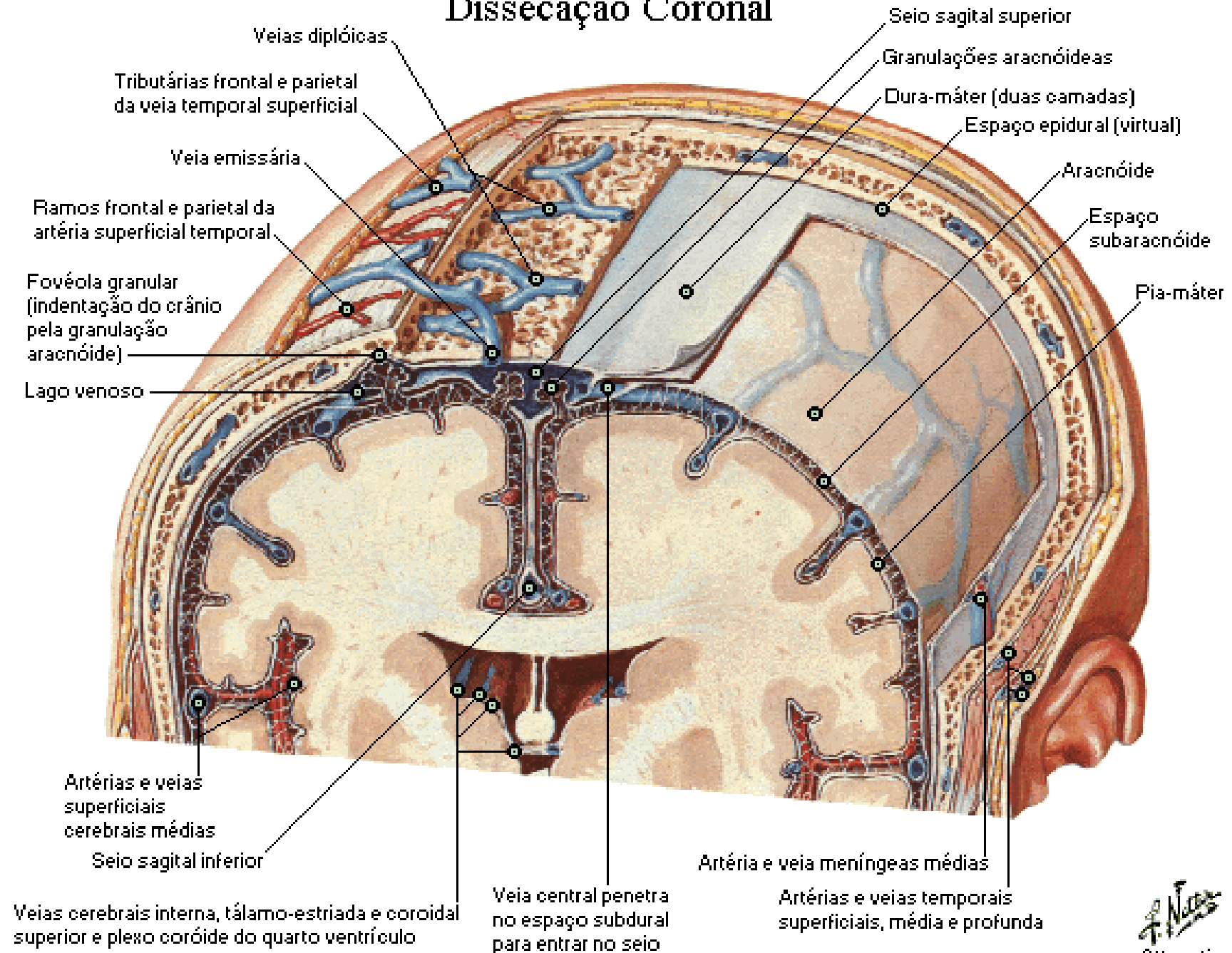
Tuba Auditiva Aberta



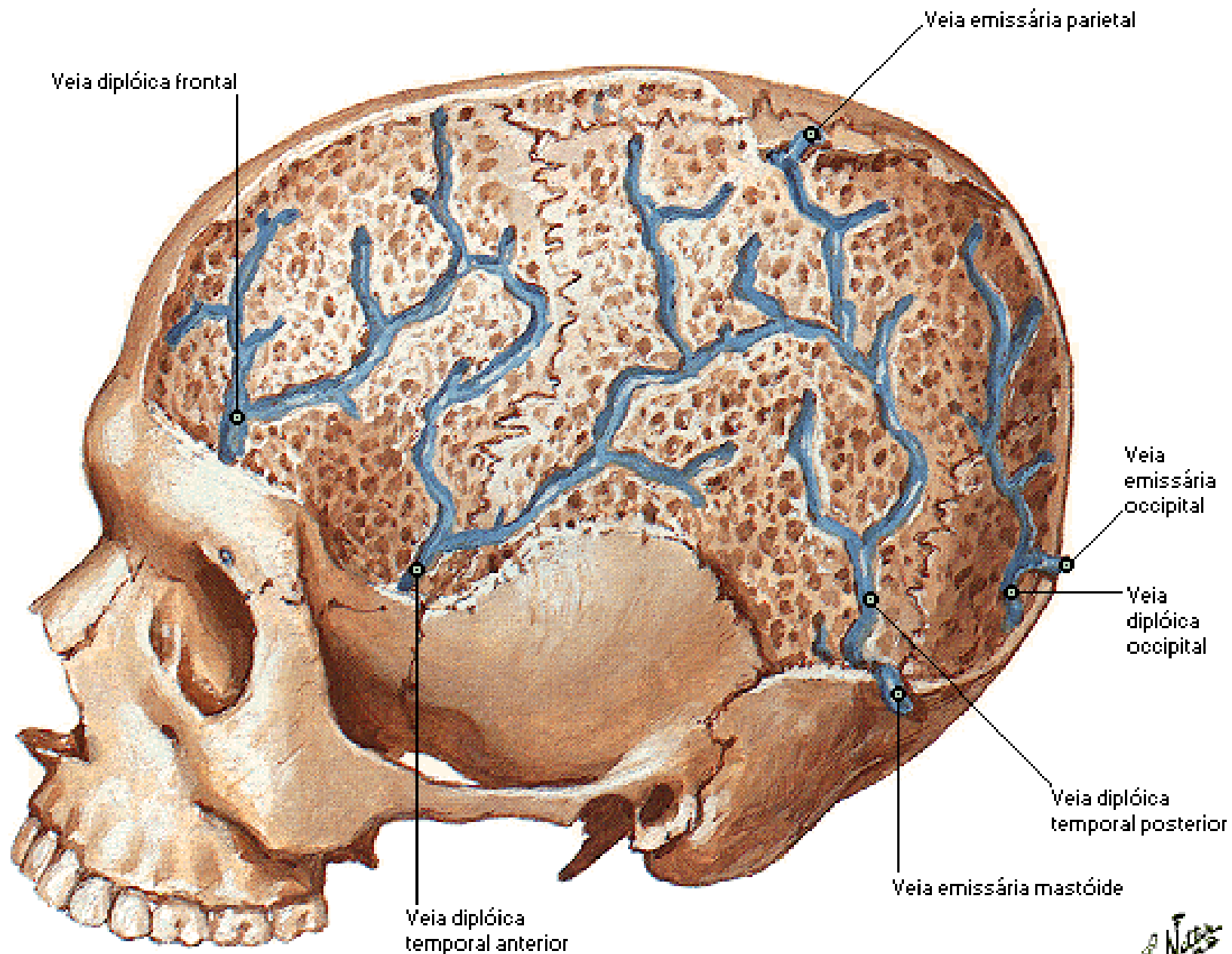
○ lúmen abre-se principalmente quando a ação do tensor do músculo do véu palatino puxa a parede do tubo lateralmente durante o ato de engolir

Meninges e Veias Diplóicas

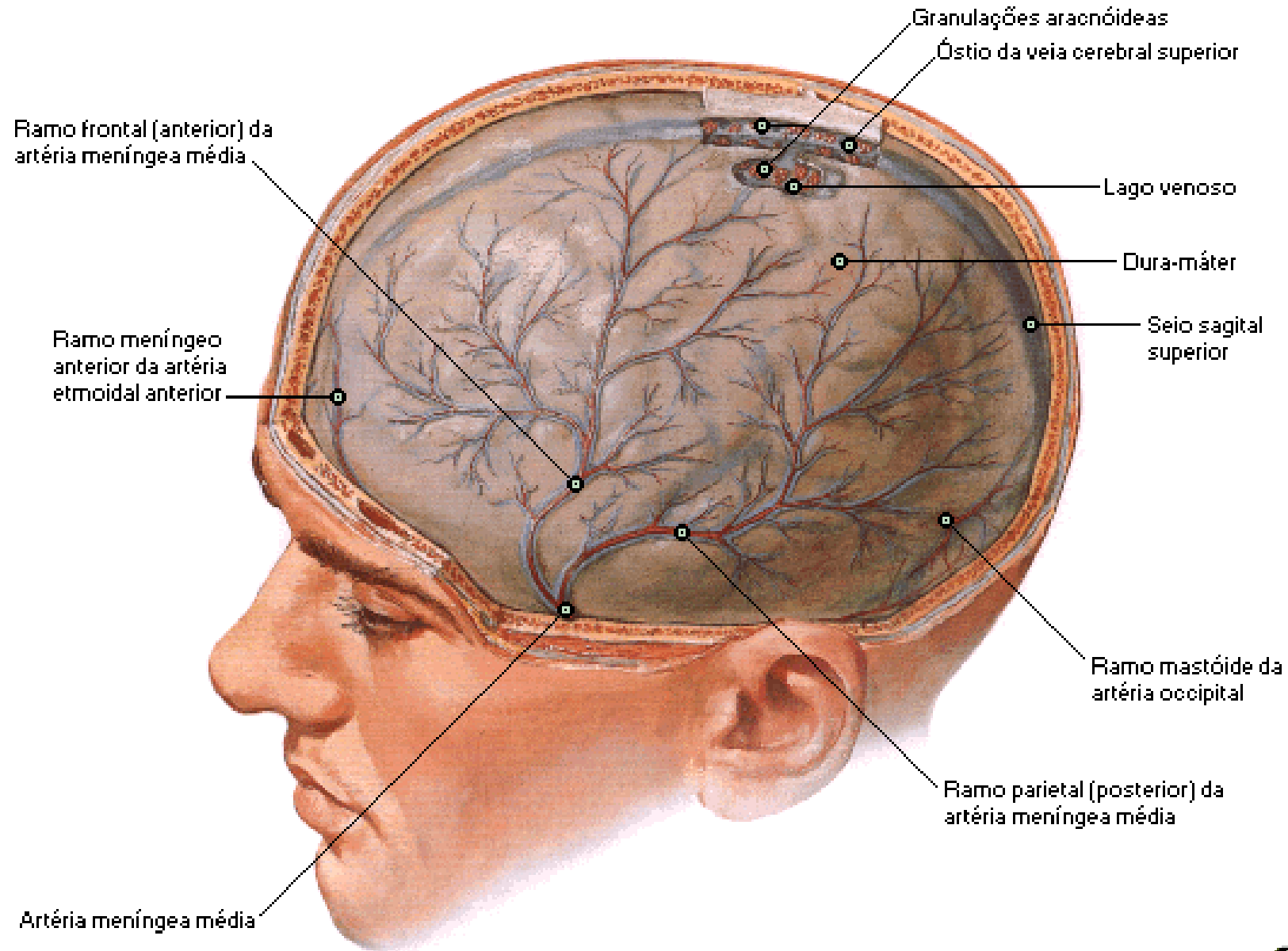
Dissecação Coronal



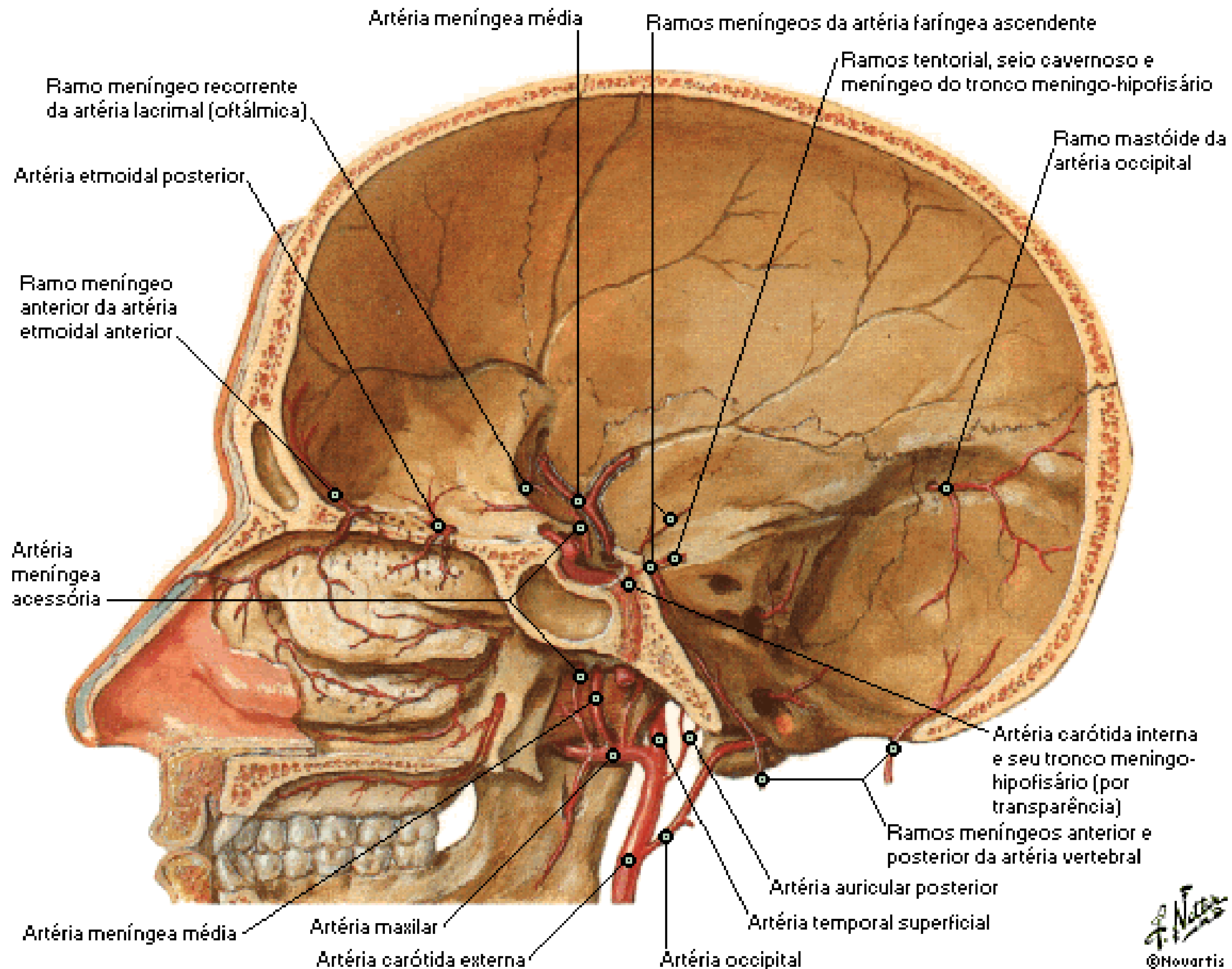
Veias Diplóicas e Emissárias do Crânio



Artérias Meníngeas

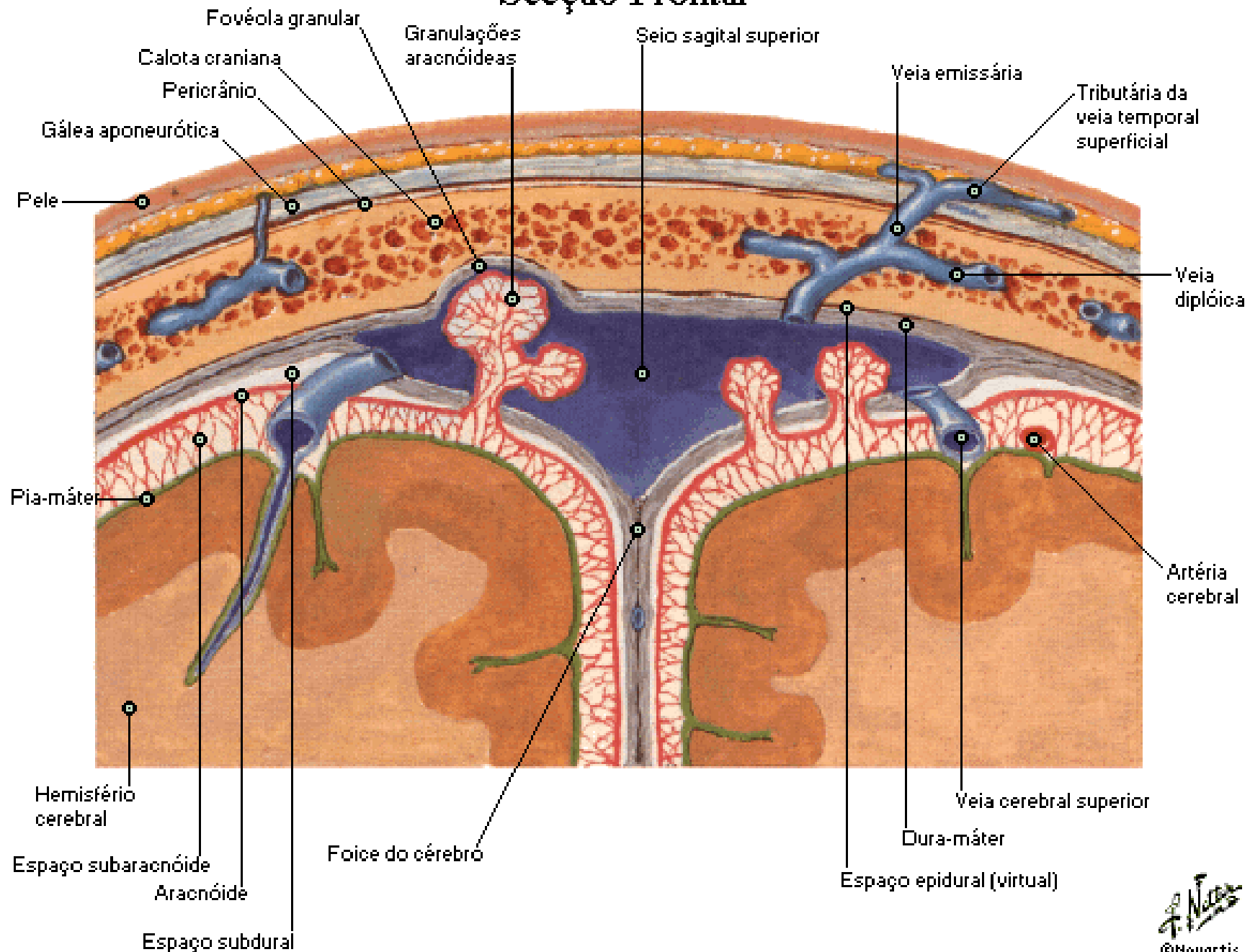


Artérias Meníngeas [Continuação]



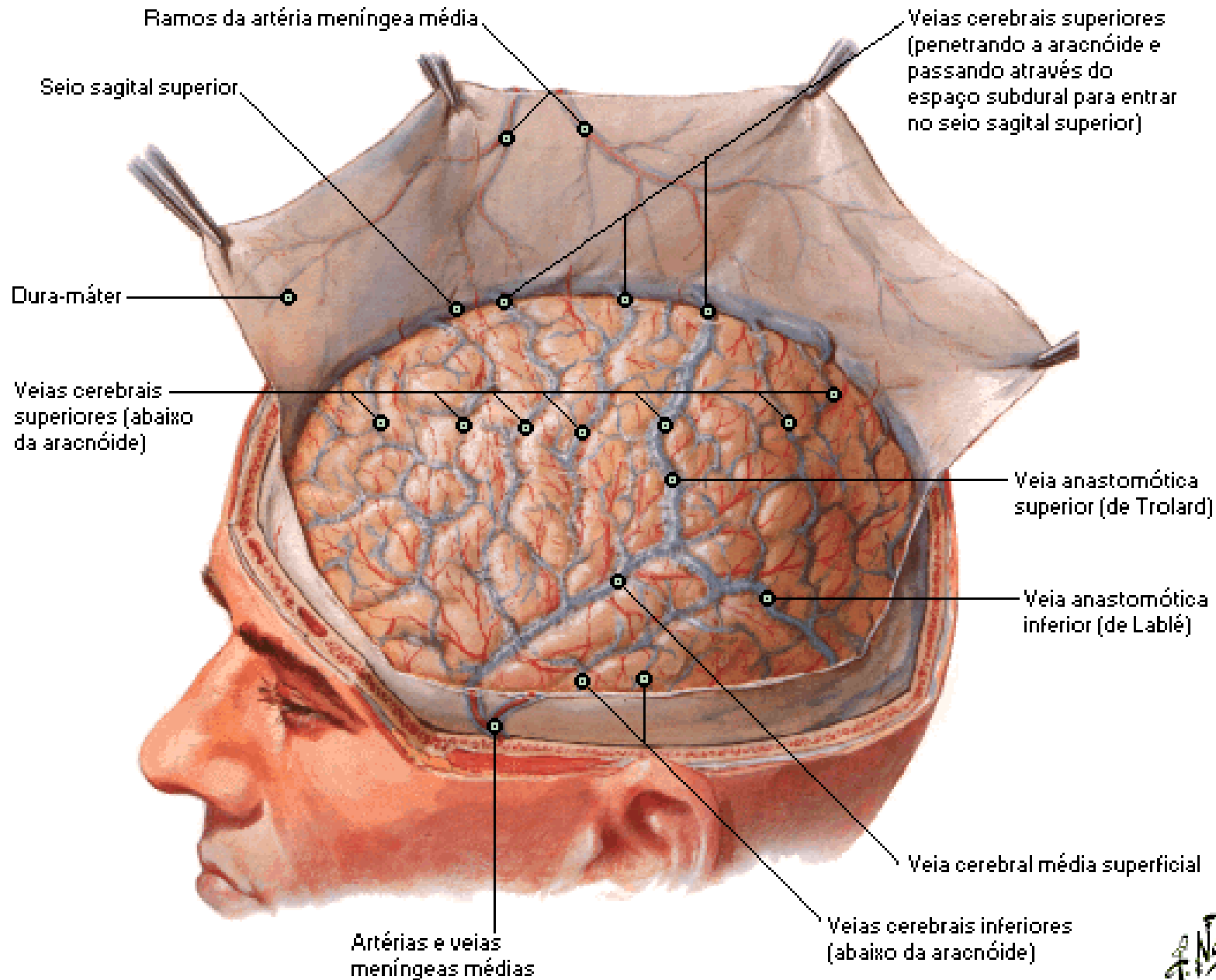
Meninges e Veias Cerebrais Superficiais

Secção Frontal



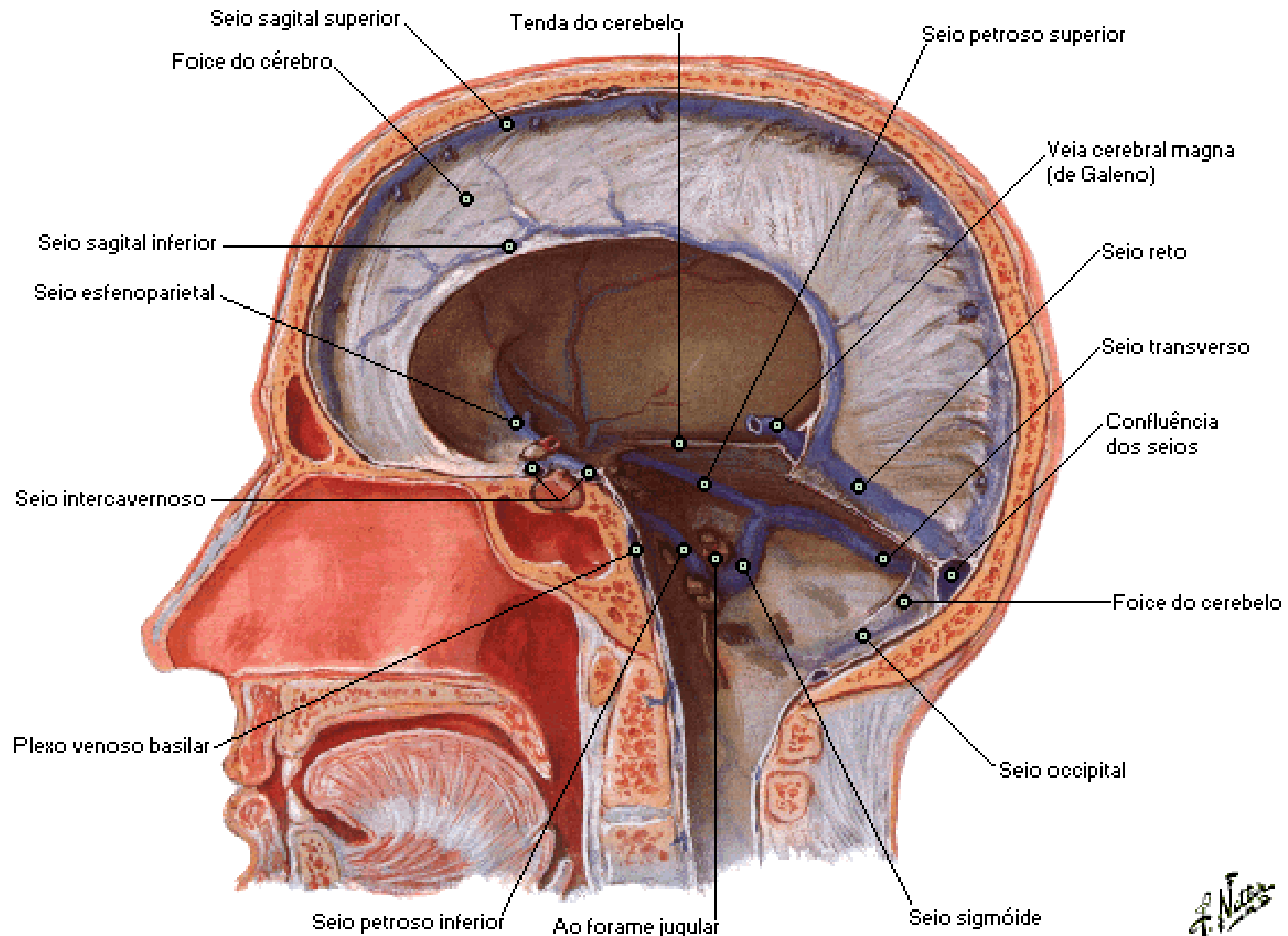
Meninges e Veias Cerebrais Superficiais

Dura-máter em Destaque



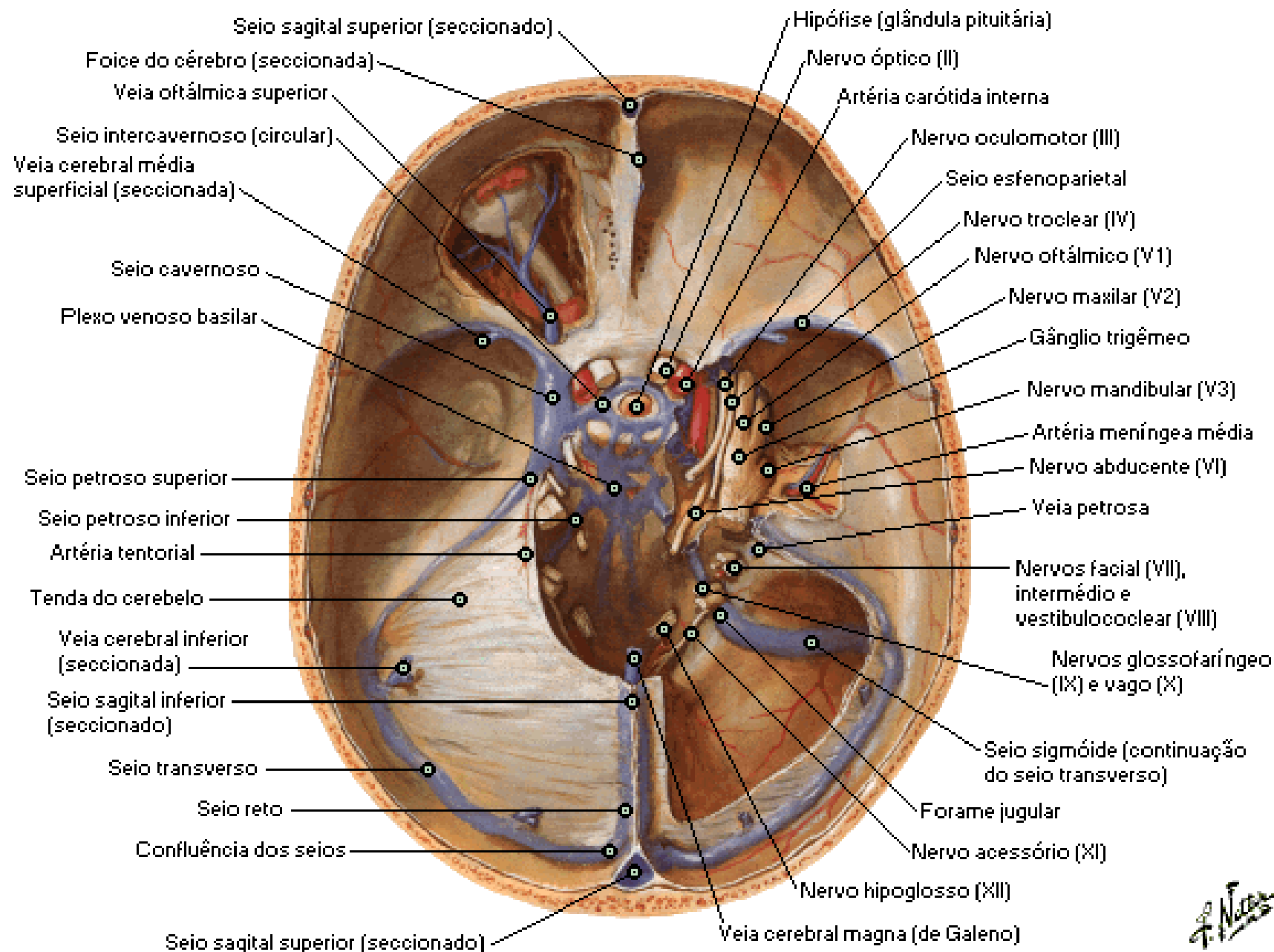
Seios Venosos da Dura-máter

Secção Sagital



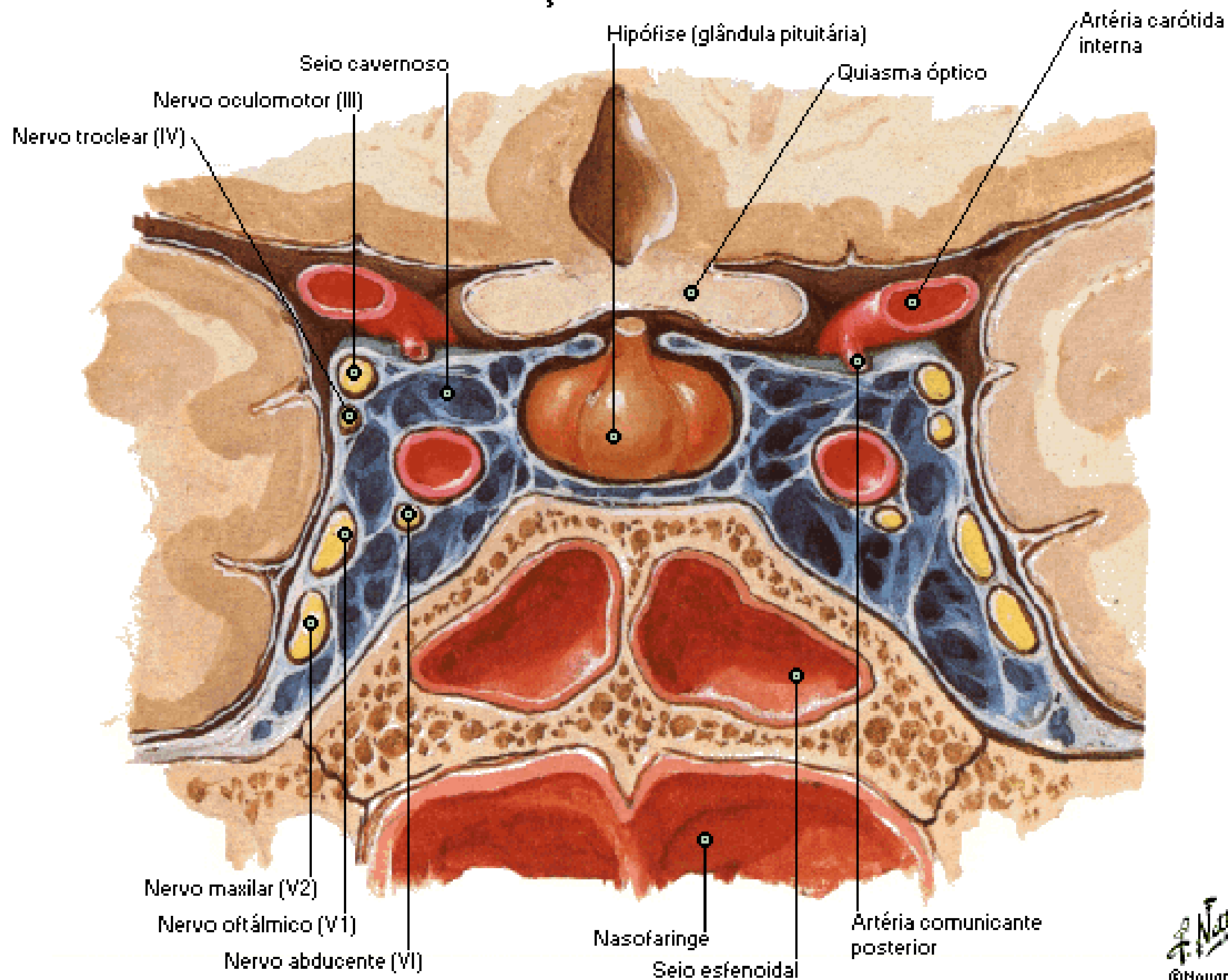
Seios Venosos da Dura-máter

Crânio - Vista Superior



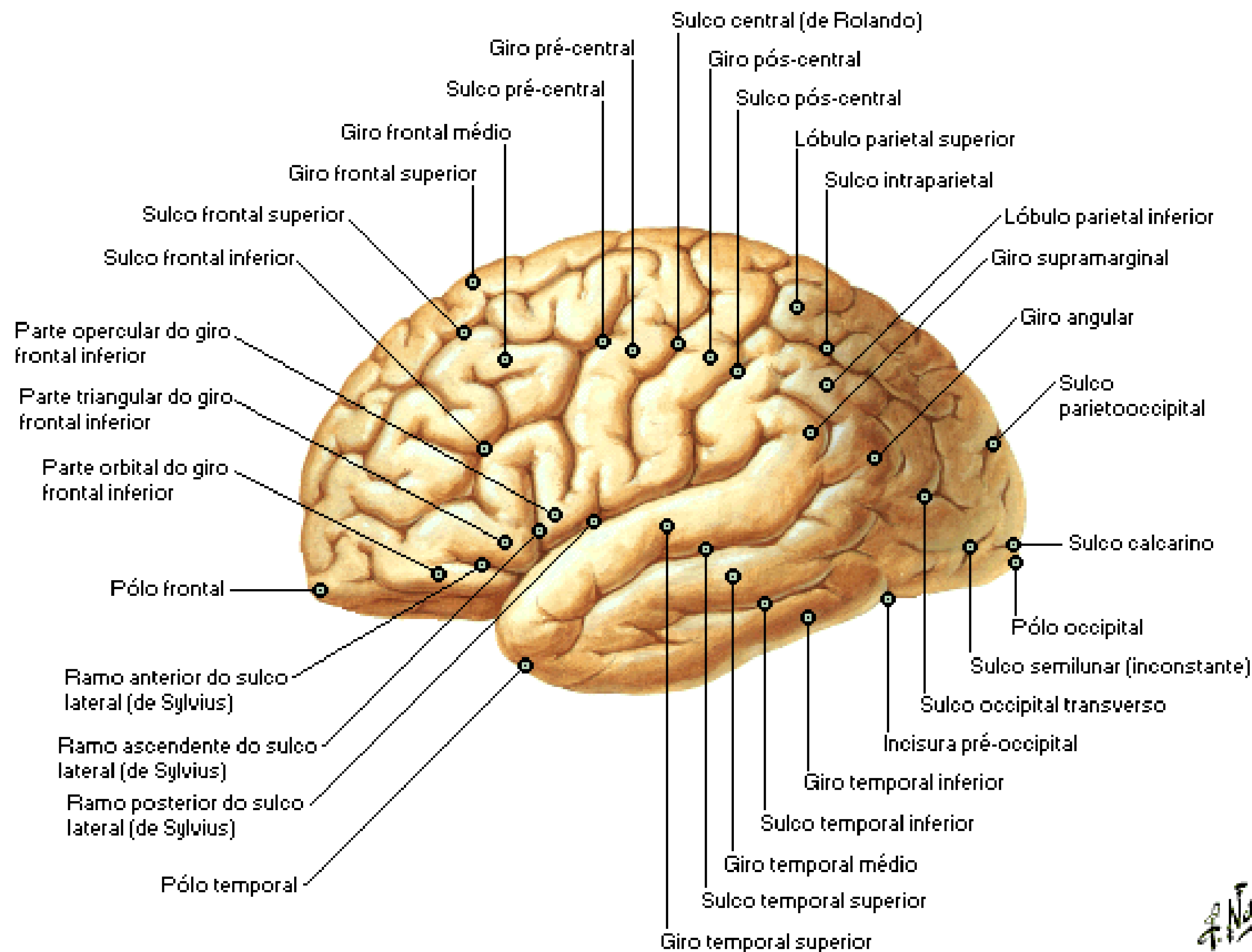
Seio Cavernoso

Secção Coronal



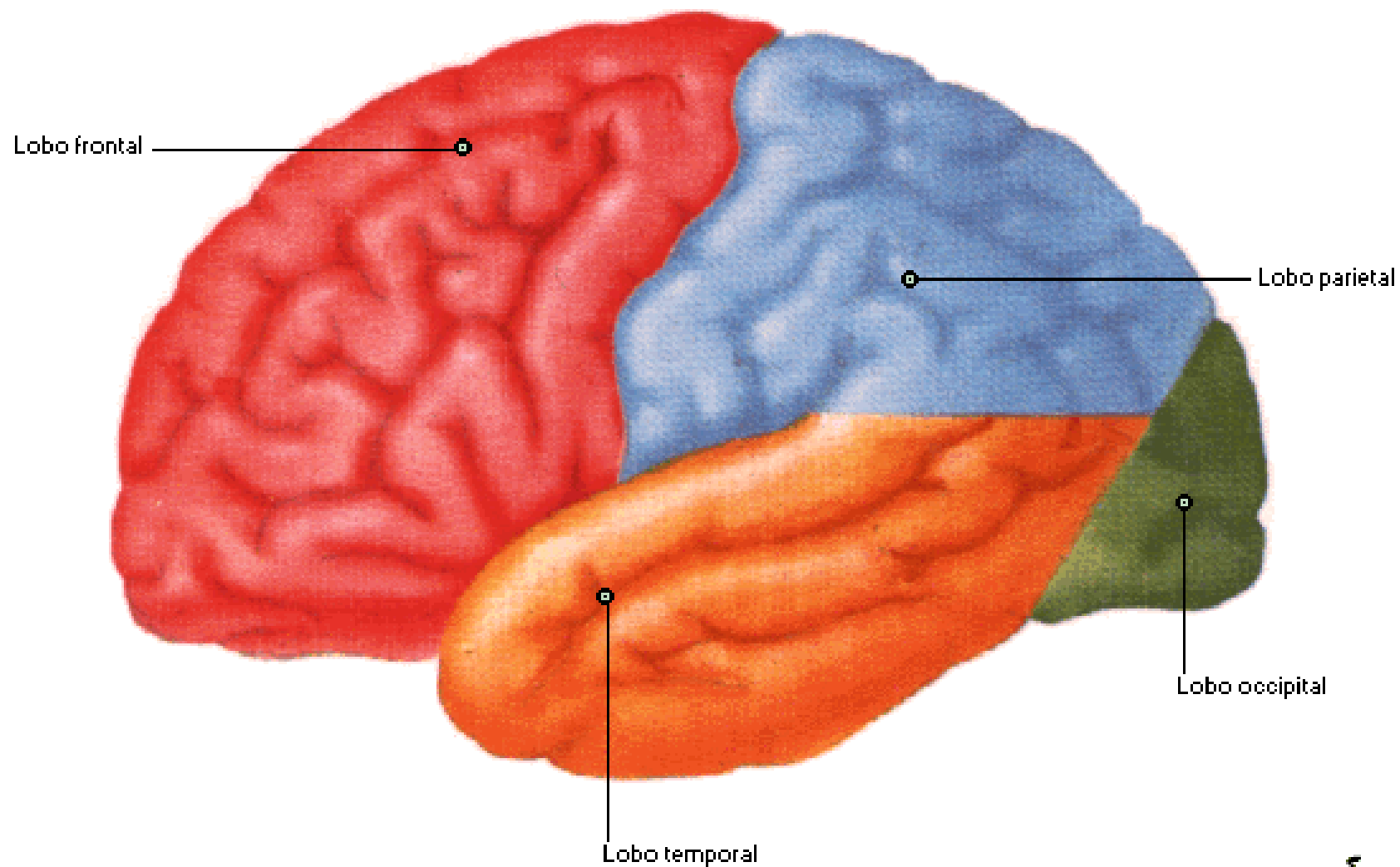
Cérebro

Vista Lateral



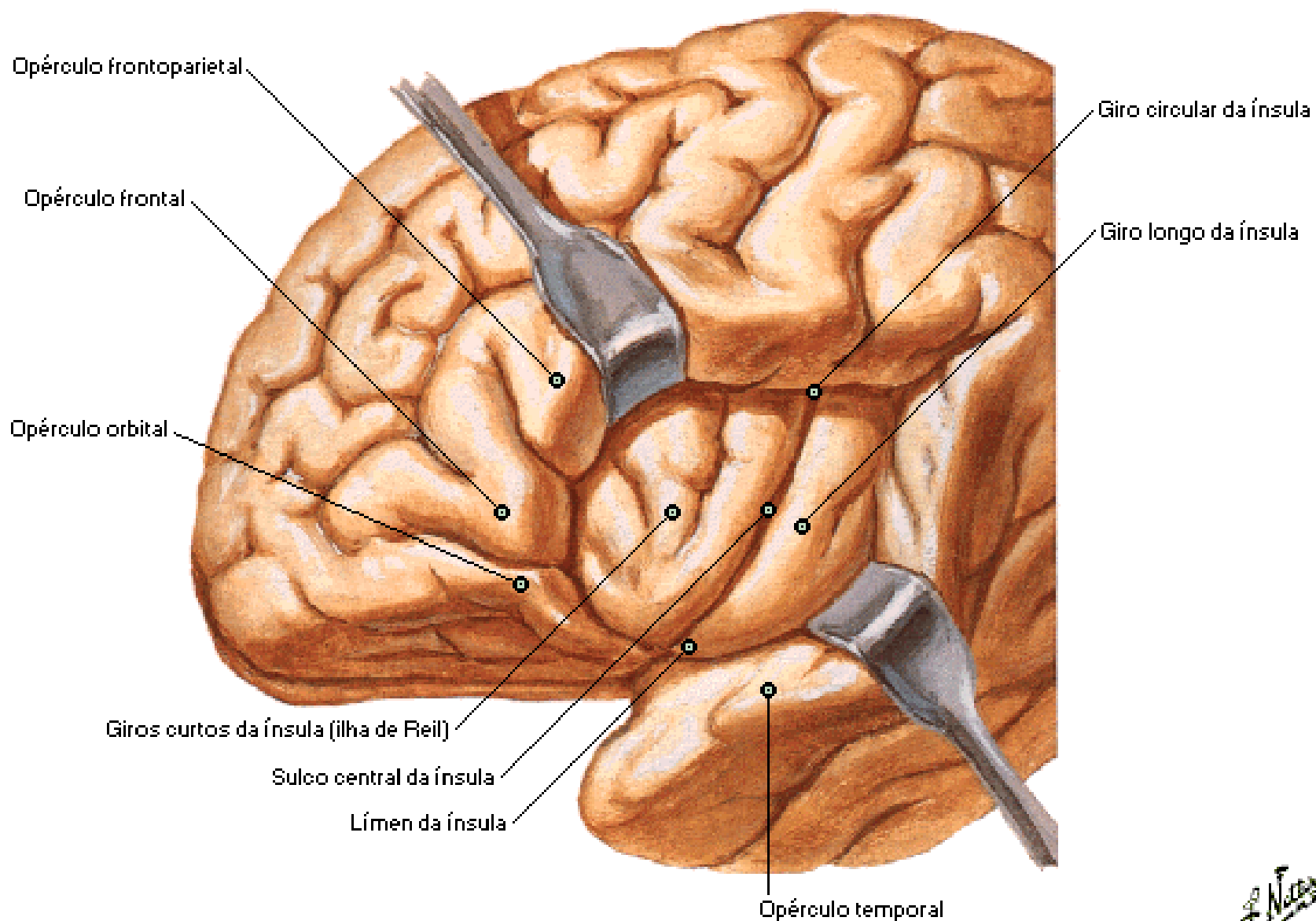
Cérebros - Lobos

Vista Lateral



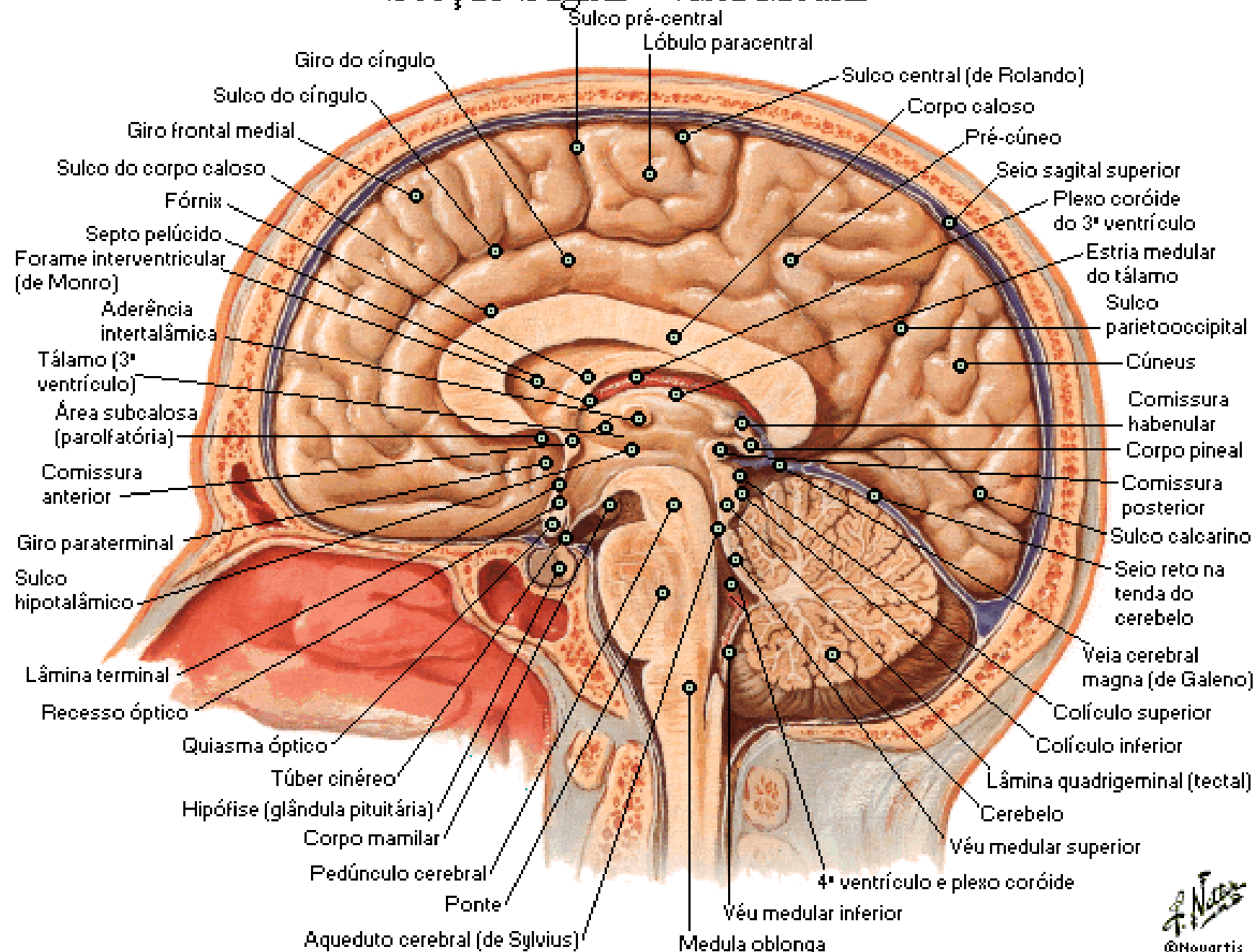
Cérebro - Ínsula [Ilha de Reil]

Vista Lateral



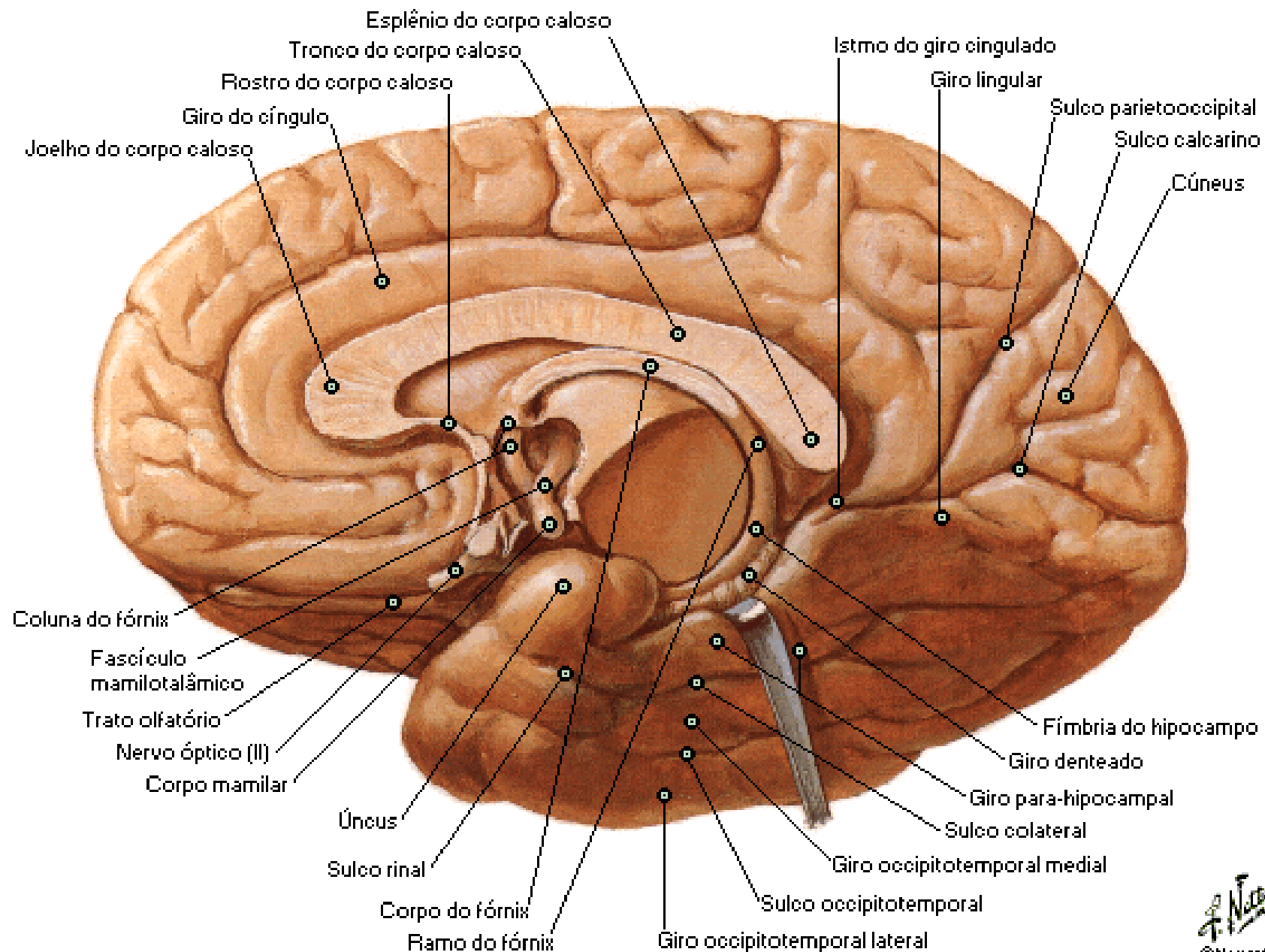
Cérebro - Cérebro in Situ

Secção Sagital - Vista Medial



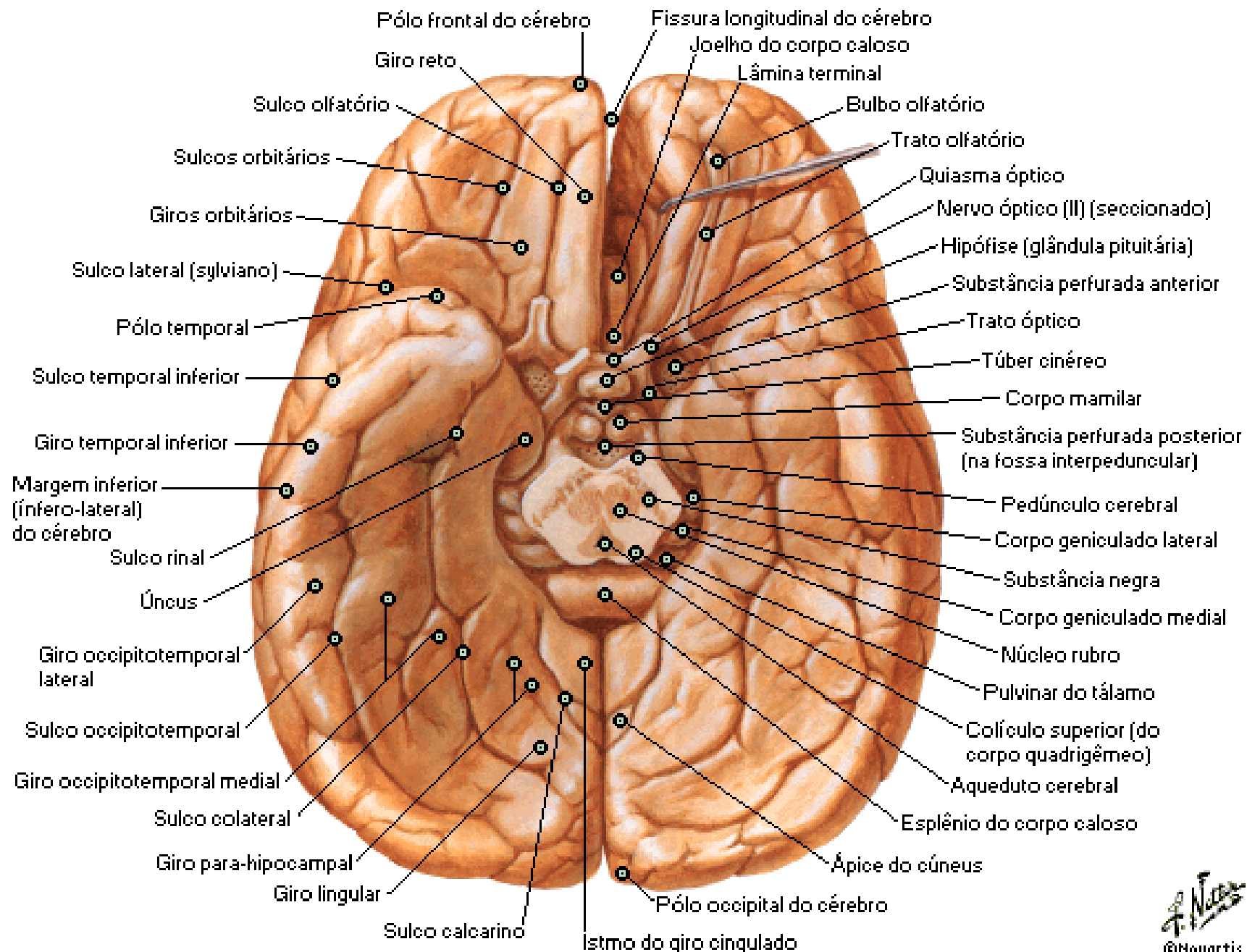
Cérebro - Hemisfério com Tronco Cerebral Removido

Vista Medial



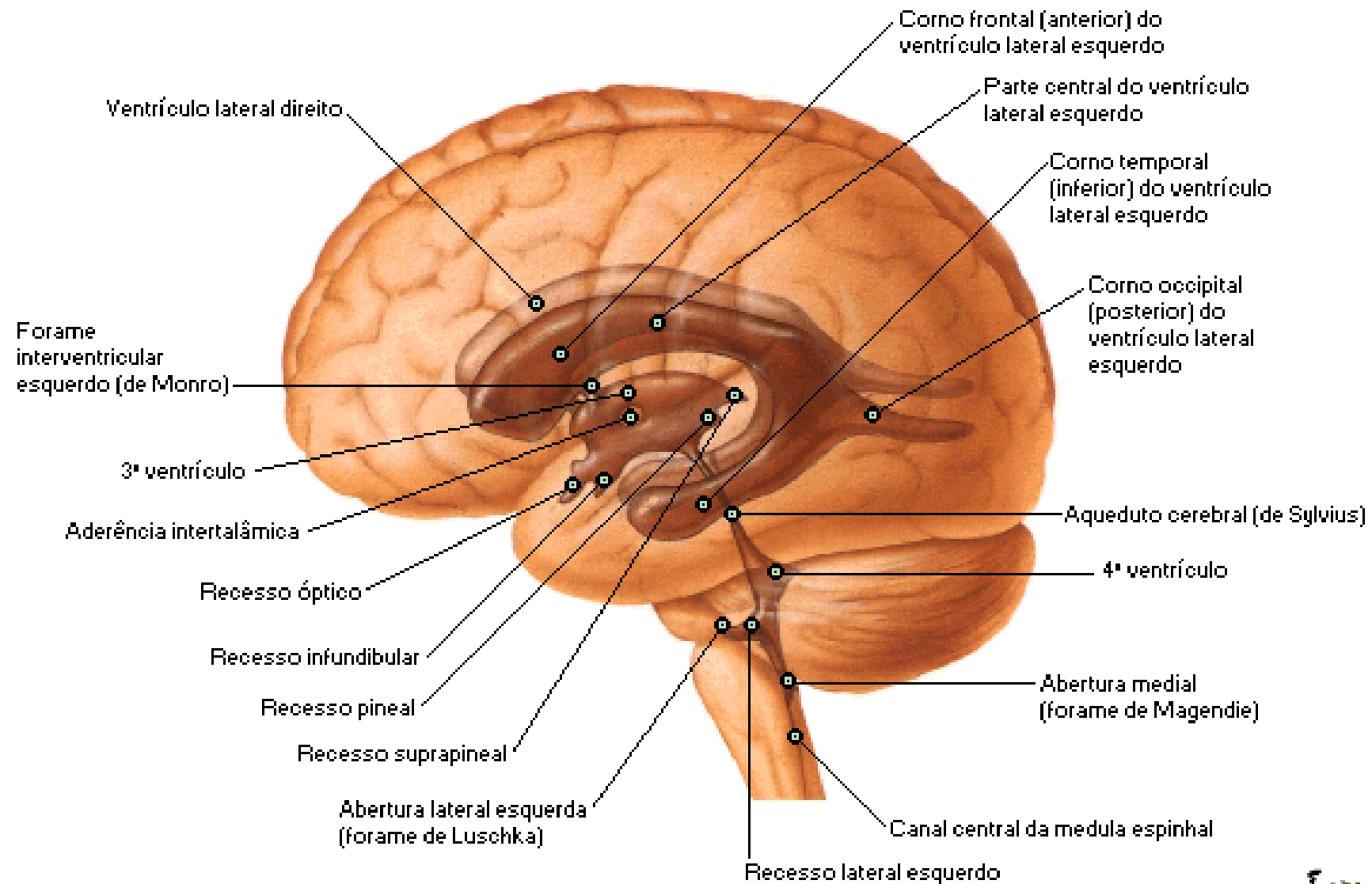
Cérebro

Vista Inferior



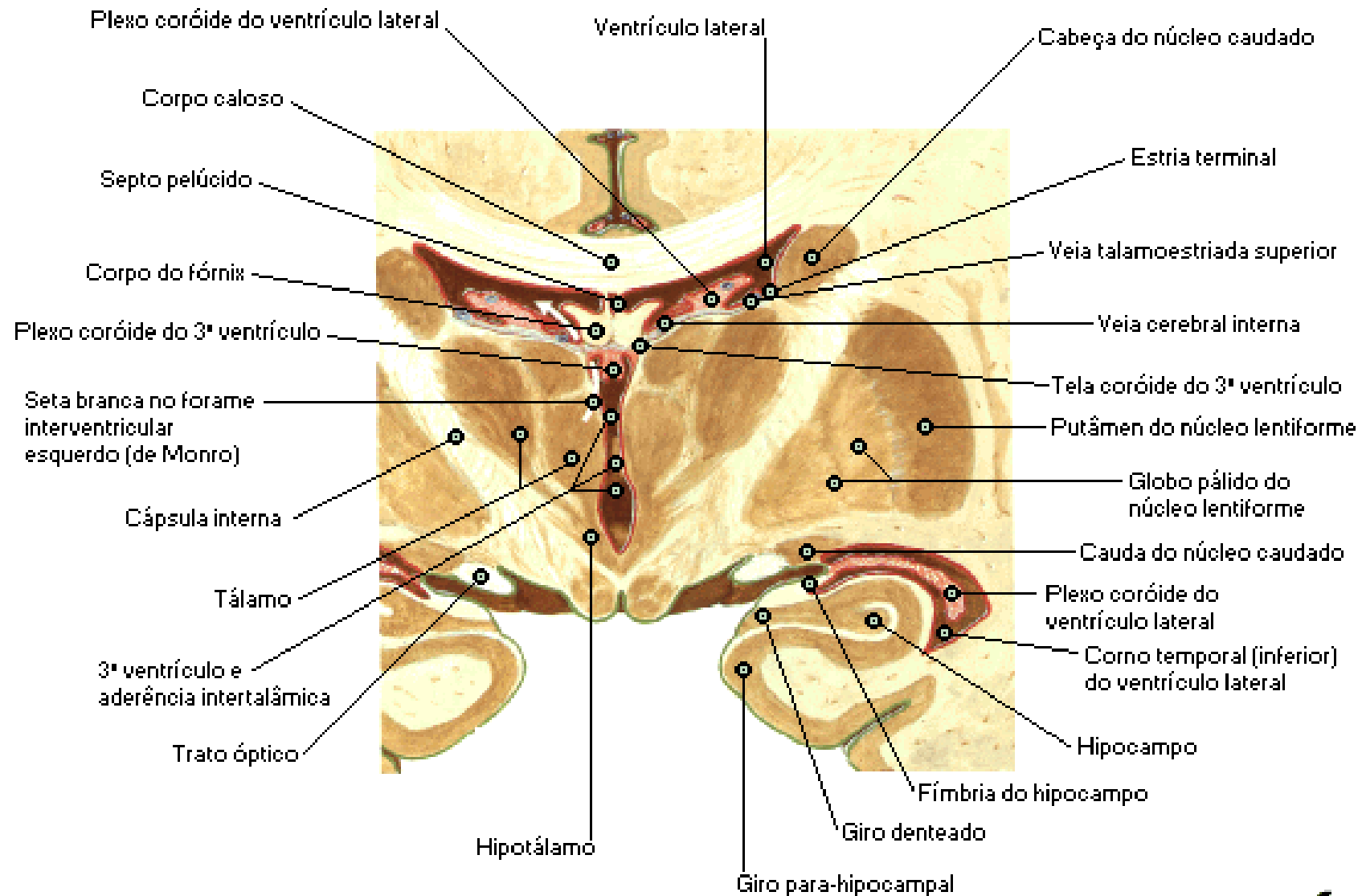
Ventrículos do Cérebro

Vista Lateral Esquerda por Transparência

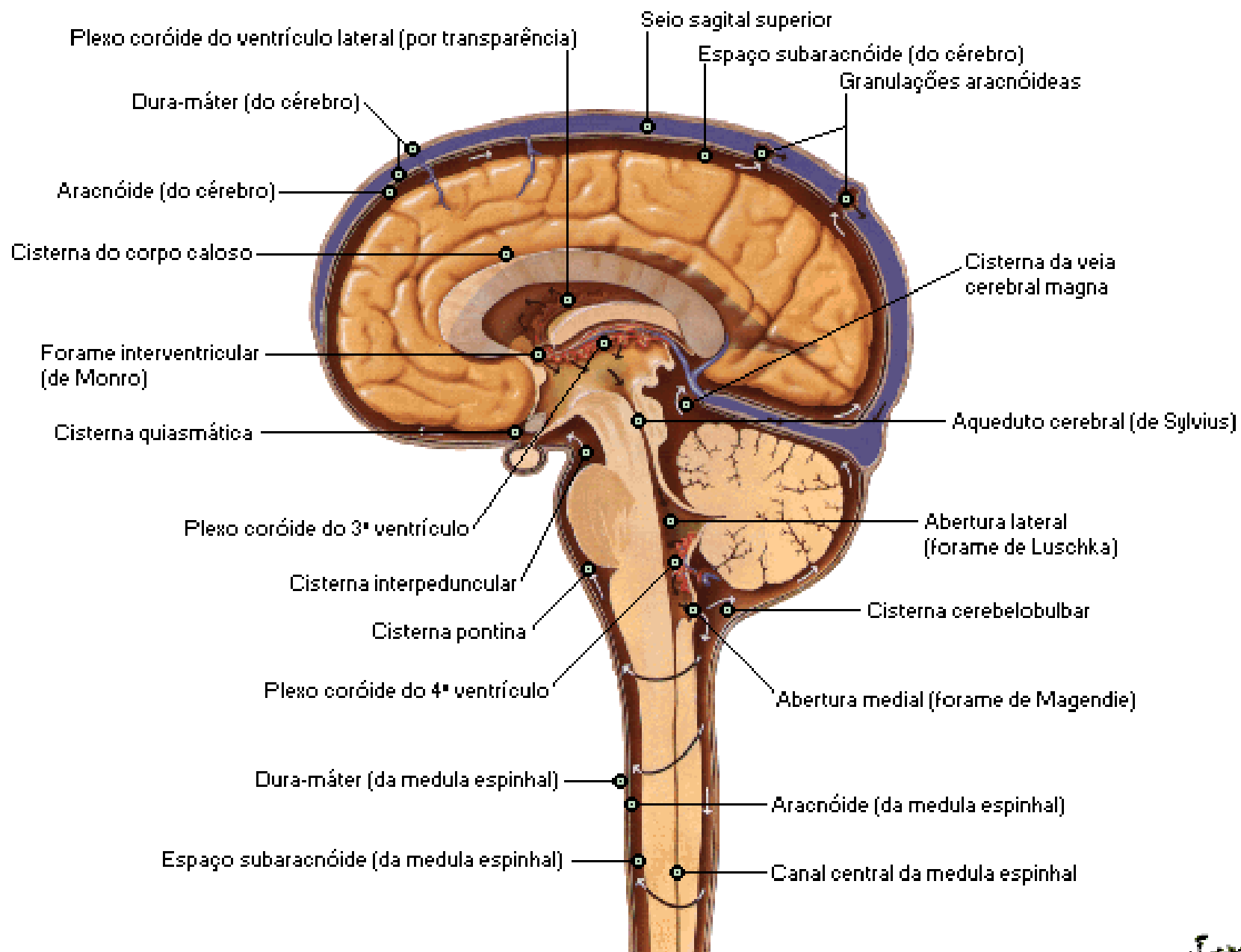


Ventrículos do Cérebro

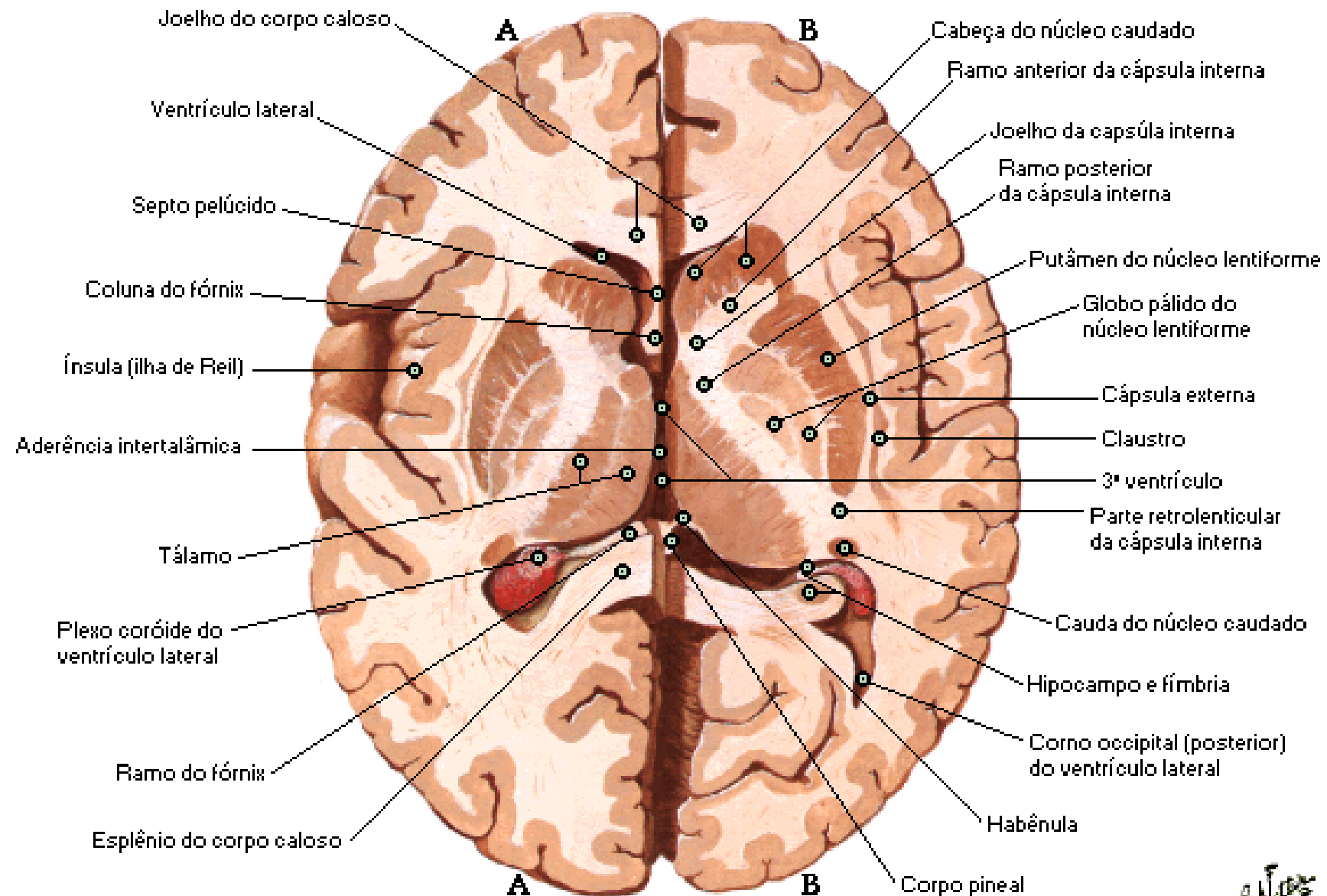
Secção Coronal do Cérebro - Vista Posterior



Circulação do Líquido Cerebroespinal

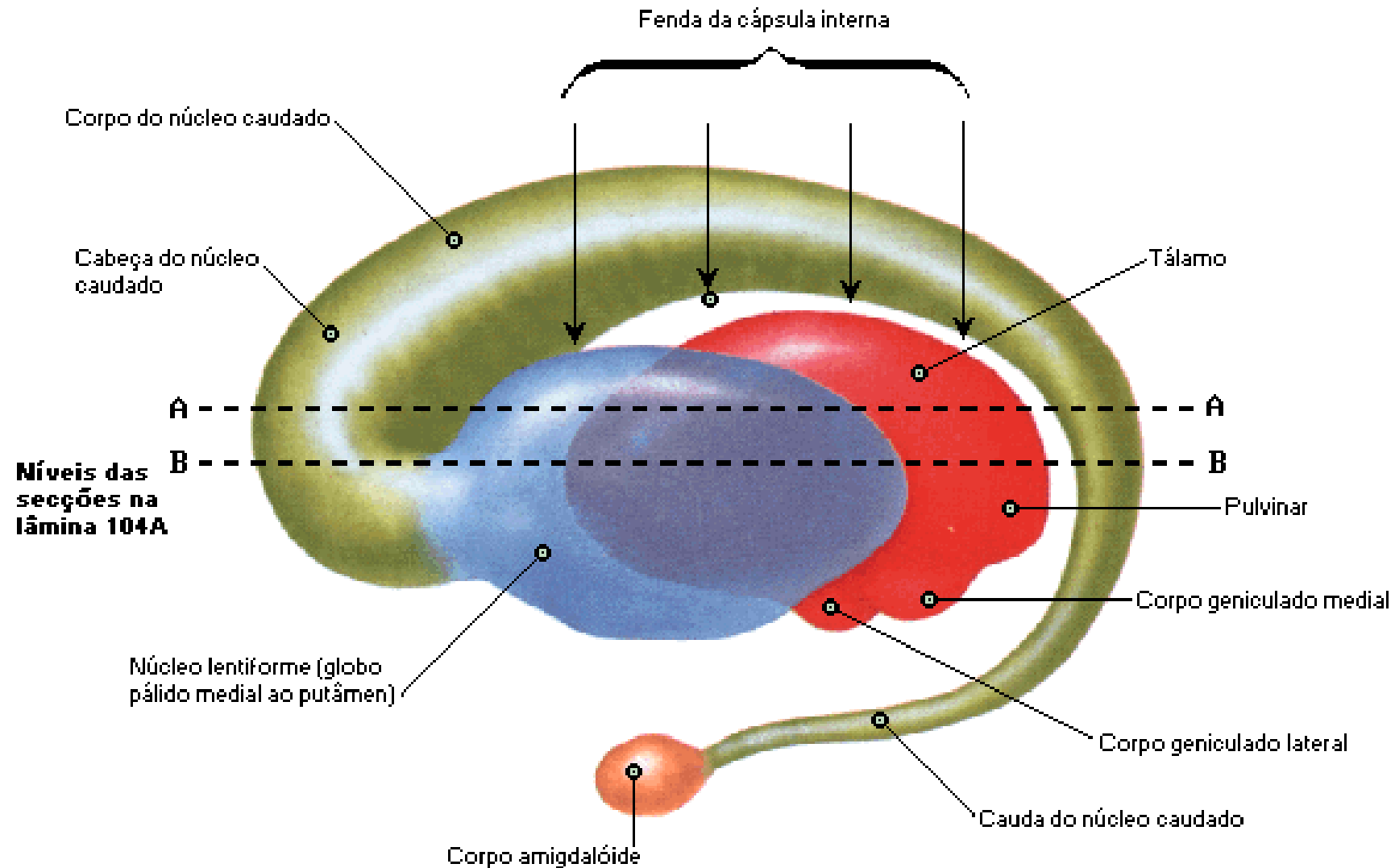


Secções Horizontais Através do Cérebro



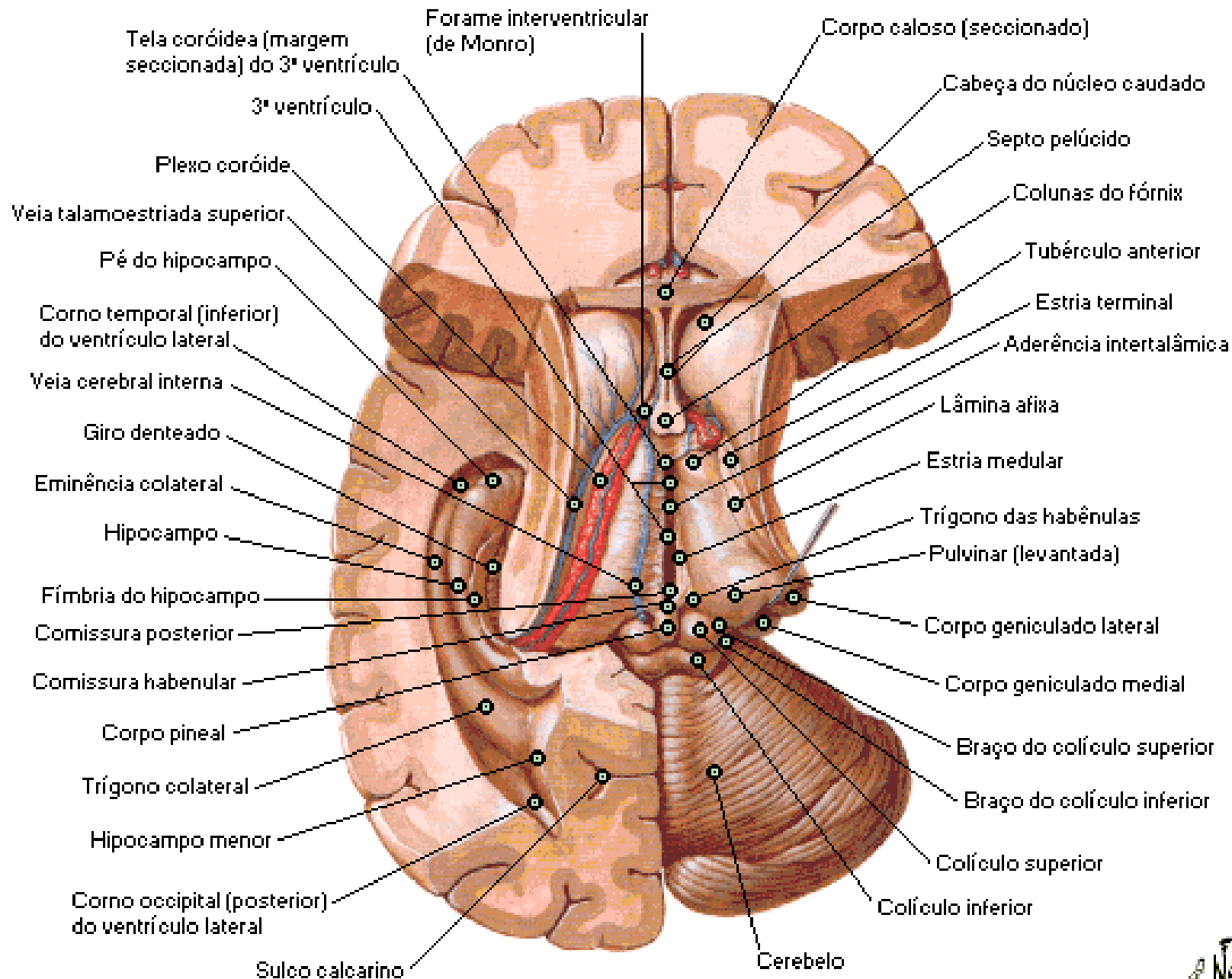
Gânglio Basal - Esquema

Vista Lateral Esquerda



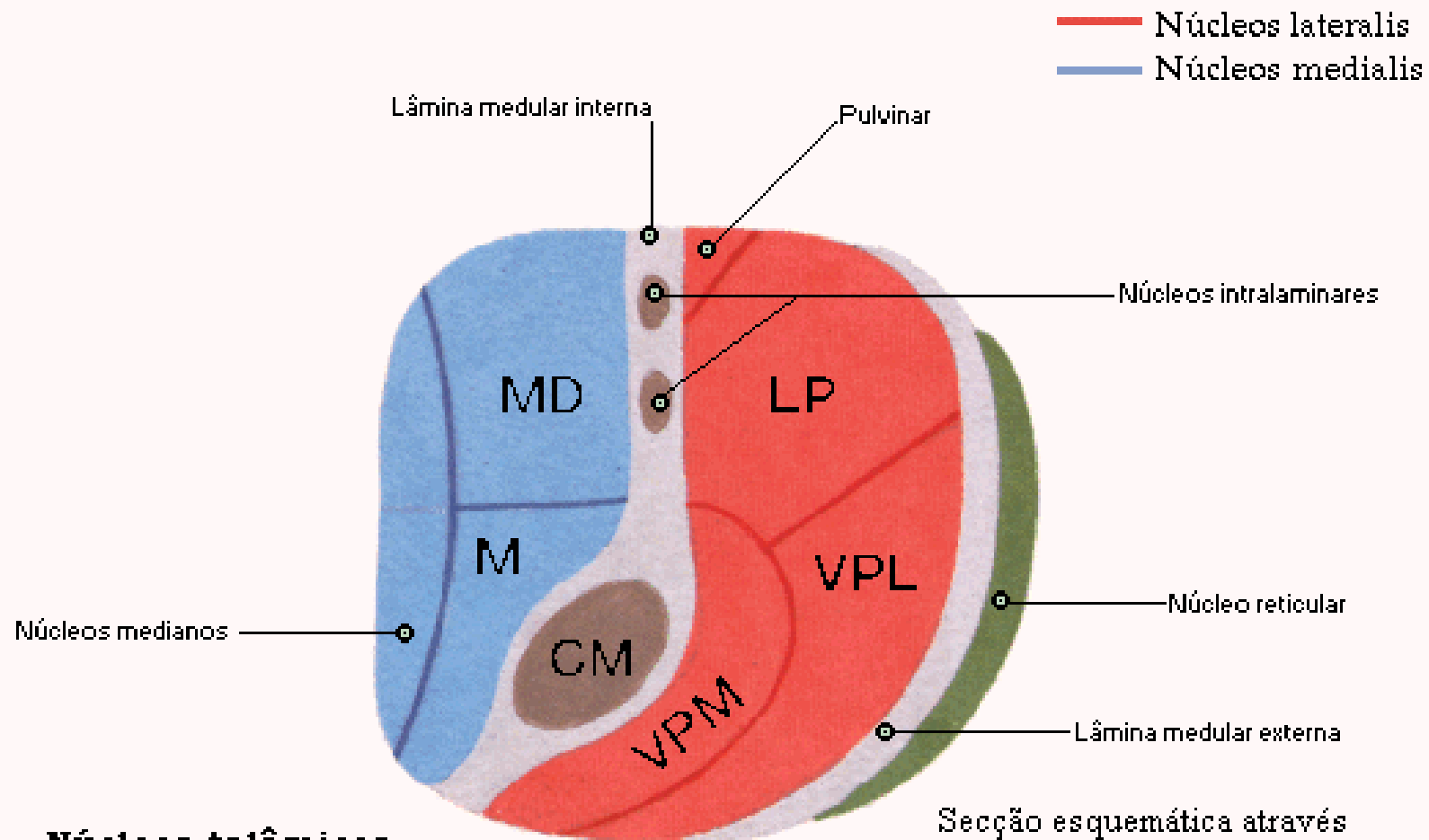
Inter-relação do tálamo, núcleo lentiforme, núcleo caudado e corpo amigdalóide (esquema): vista lateral esquerda

Tálamo



Tálamo

Secção Esquemática



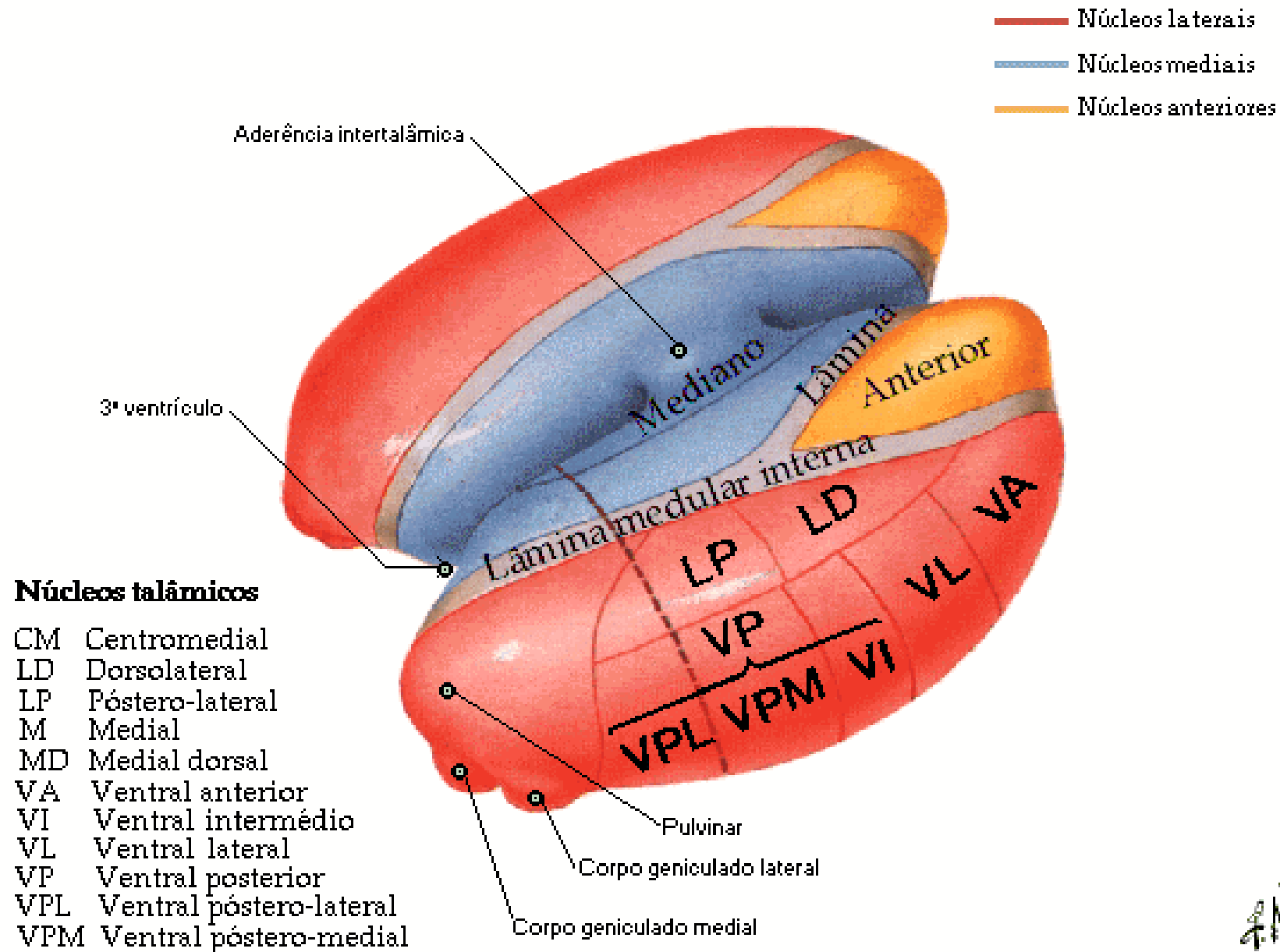
Núcleos talâmicos

CM	Centromedial	VA	Ventral anterior
LD	Dorsolateral	VI	Ventral intermédio
LP	Pósterolateral	VL	Ventral lateral
M	Medial	VP	Ventral posterior
MD	Medial dorsal	VPL	Ventral pósterolateral
		VPM	Ventral pósteromedial

Secção esquemática através do tálamo (ao nível da linha tracejada na lâmina 105C)

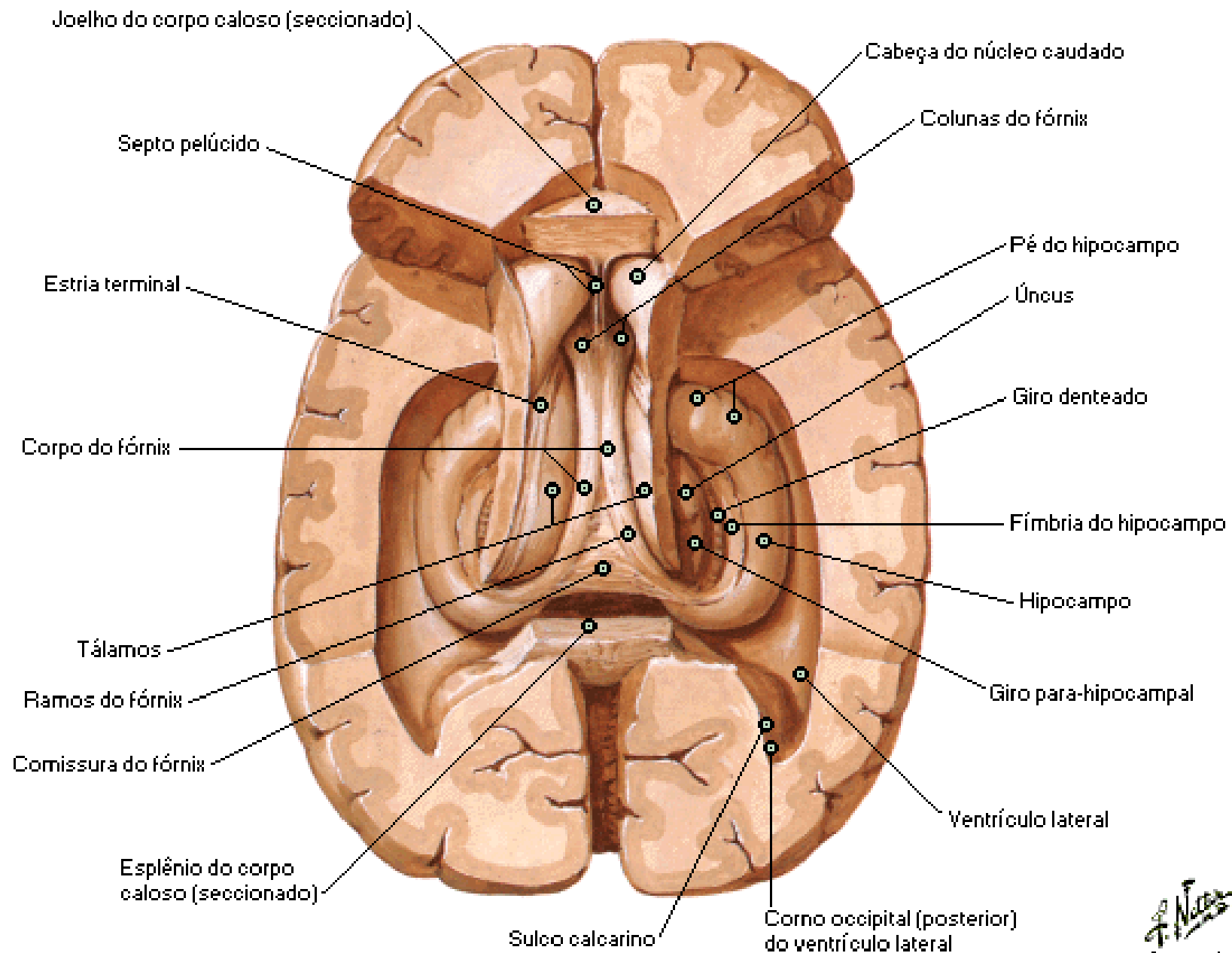
Tálamo

Representação Esquemática do Tálamo



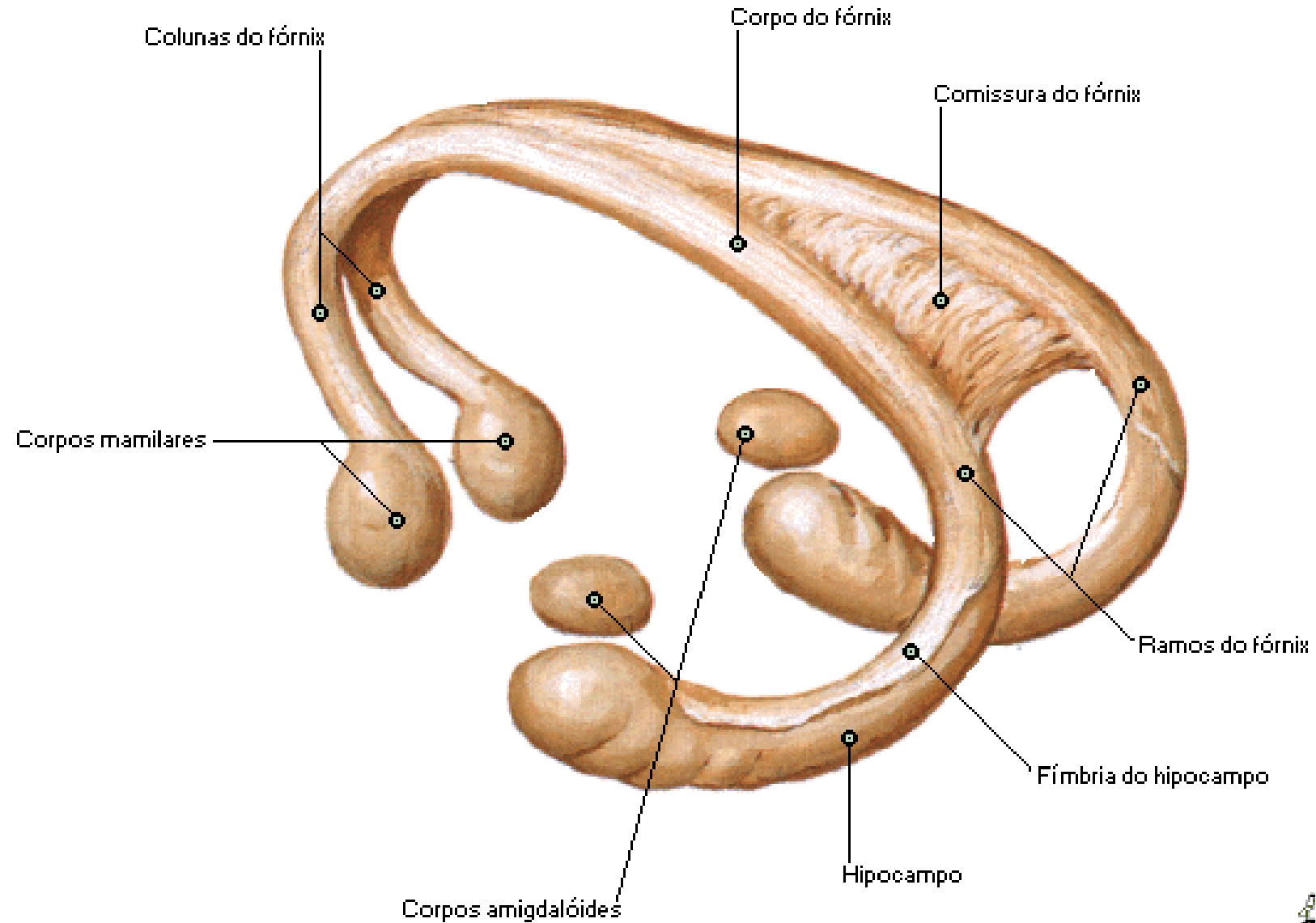
Hipocampo e Fórnix

Dissecação Superior



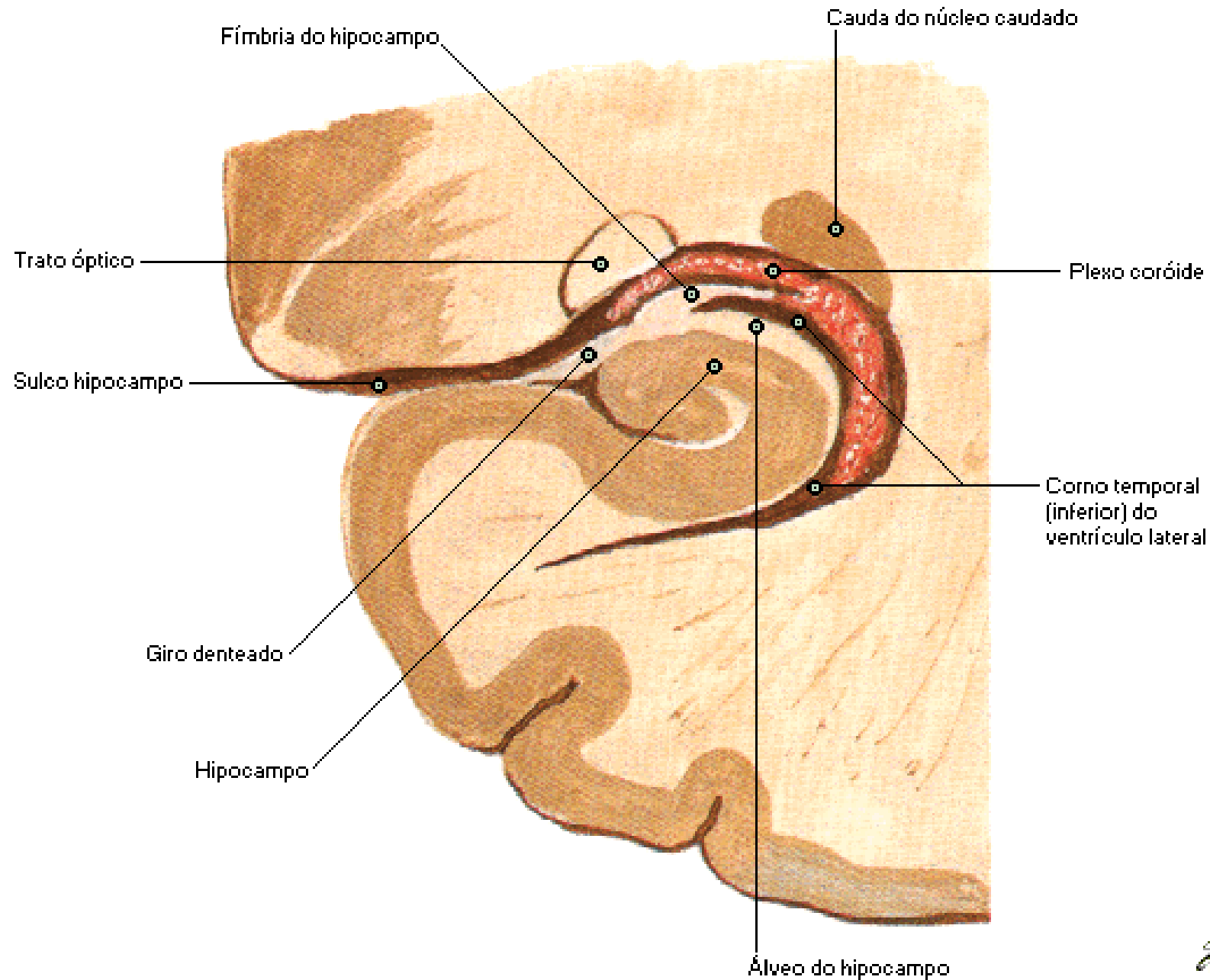
Hipocampo e Fórnix

Fórnix Esquemático



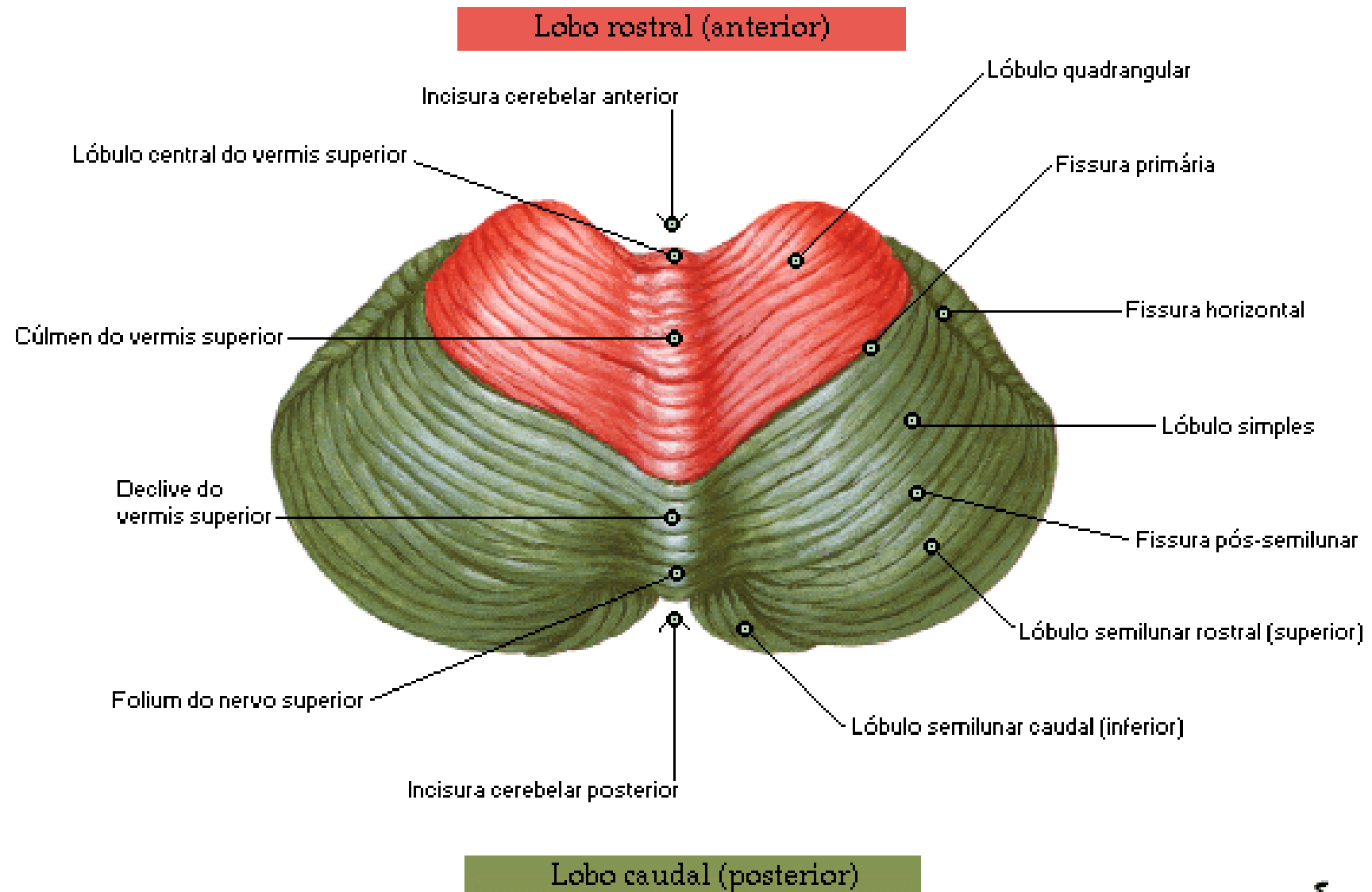
Hipocampo e Fórnix

Secção Coronal - Vista Posterior



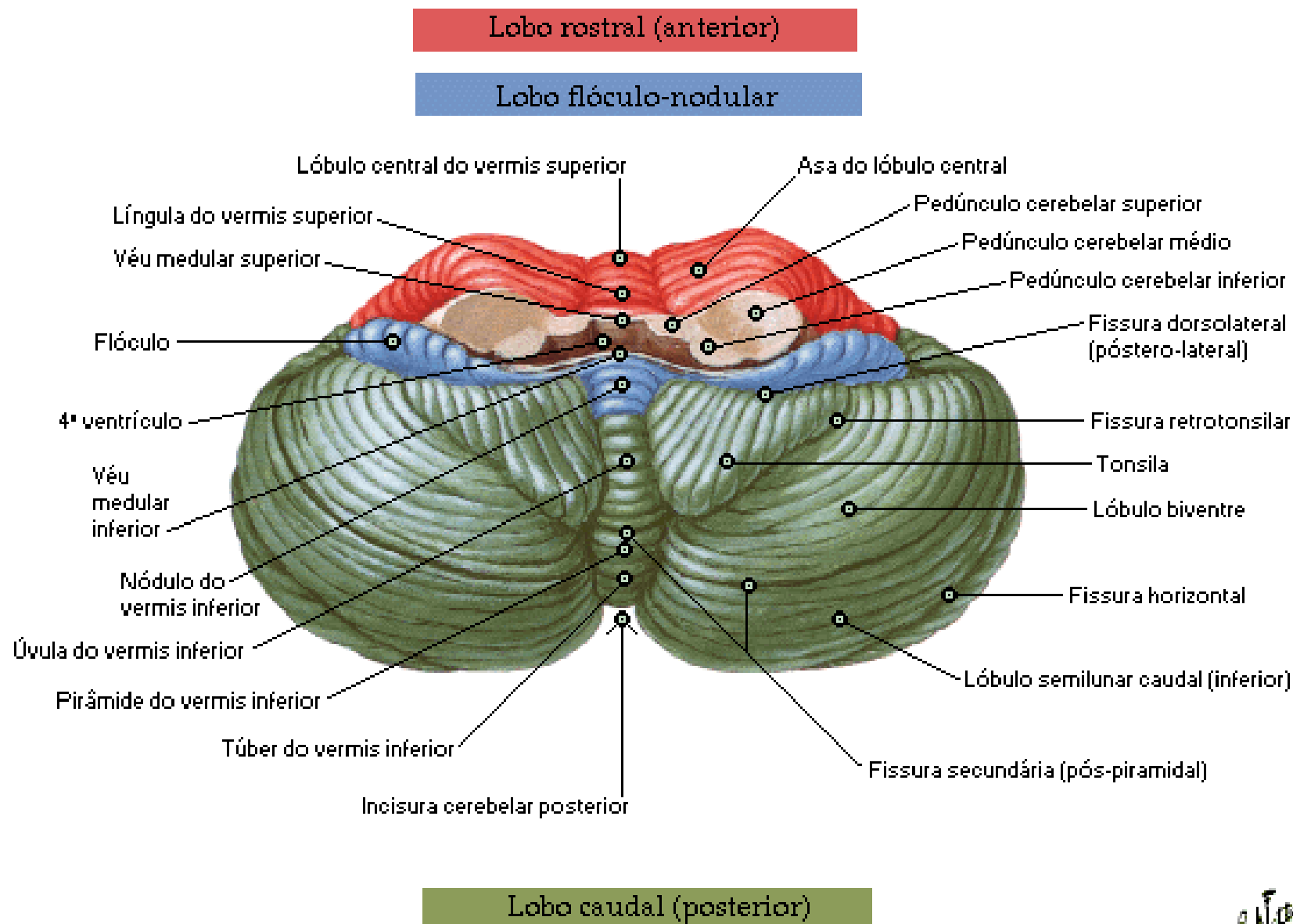
Cerebelo

Superfície Superior



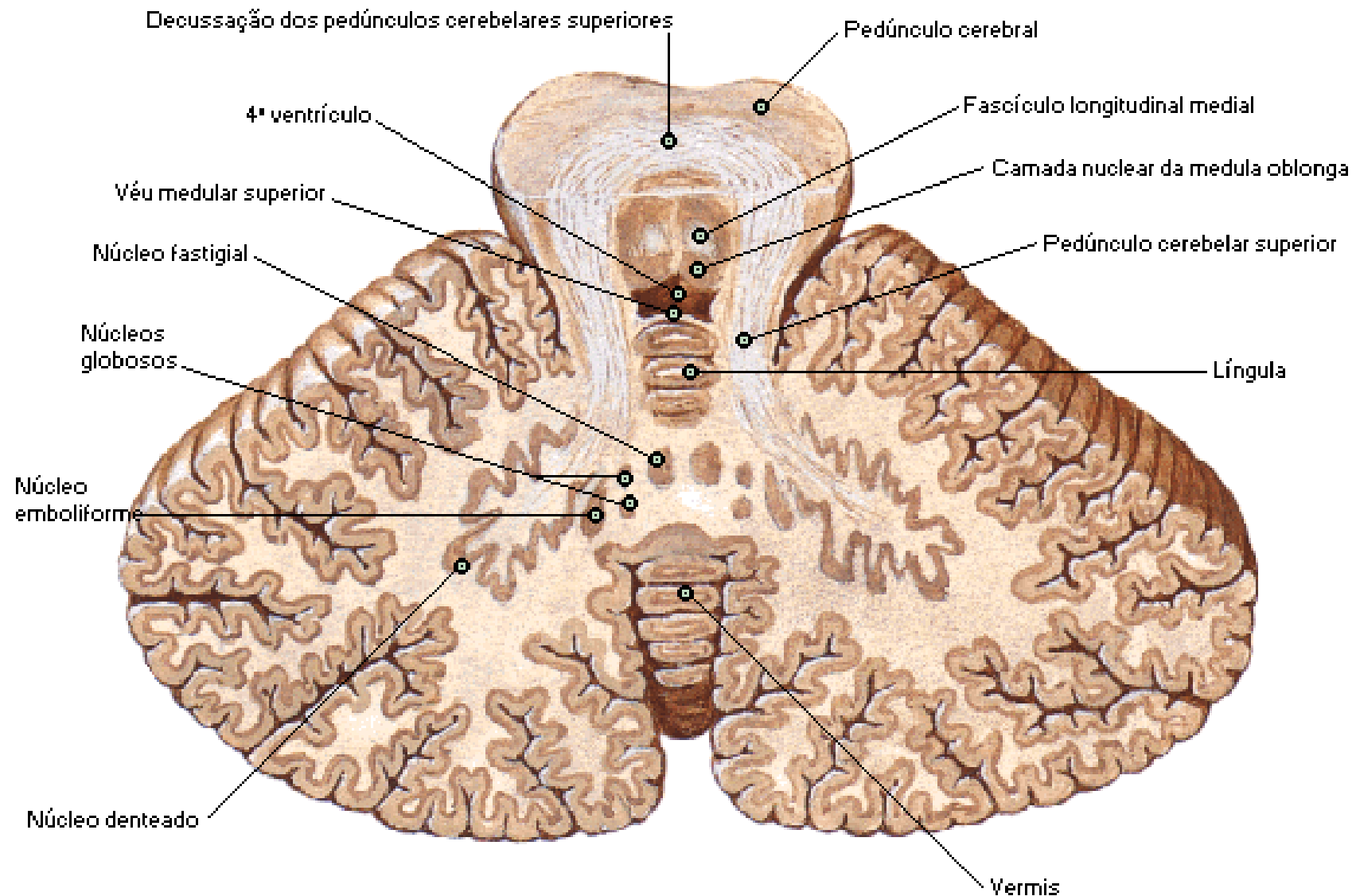
Cerebelo

Superfície Inferior



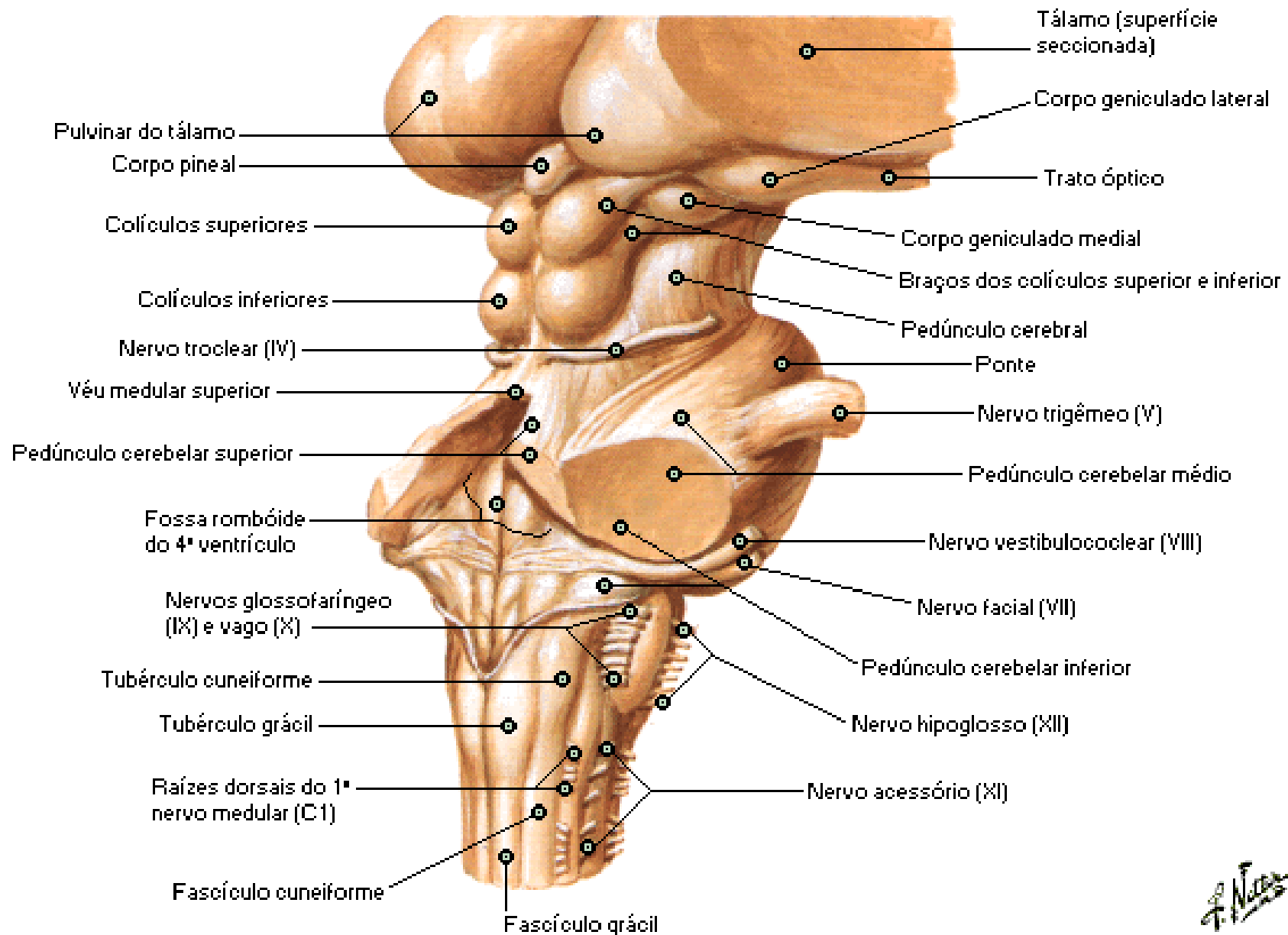
Cerebelo

Secção no Plano do Pedúnculo Cerebelar Superior



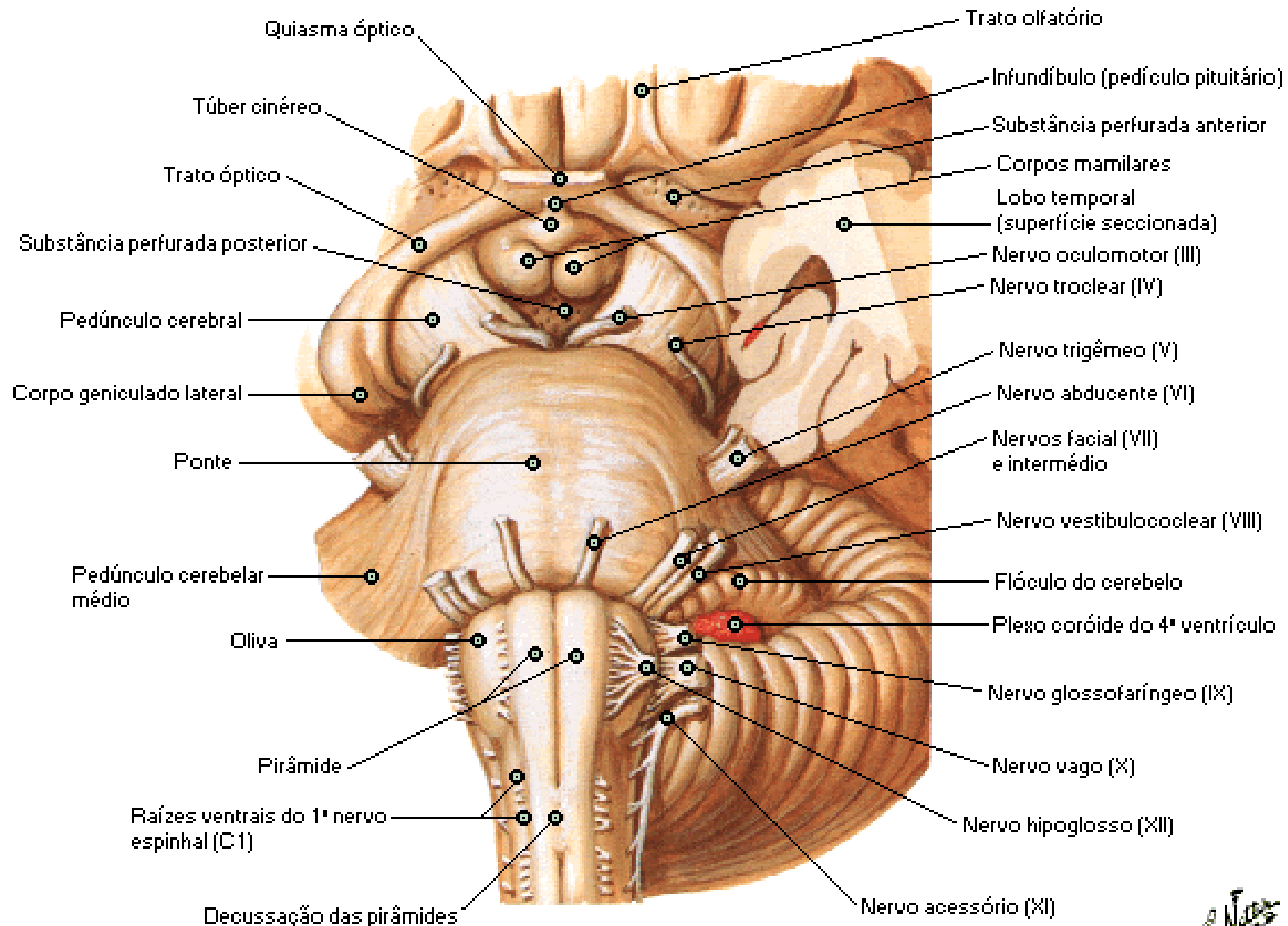
Tronco Cerebral

Vista Pósterio-lateral



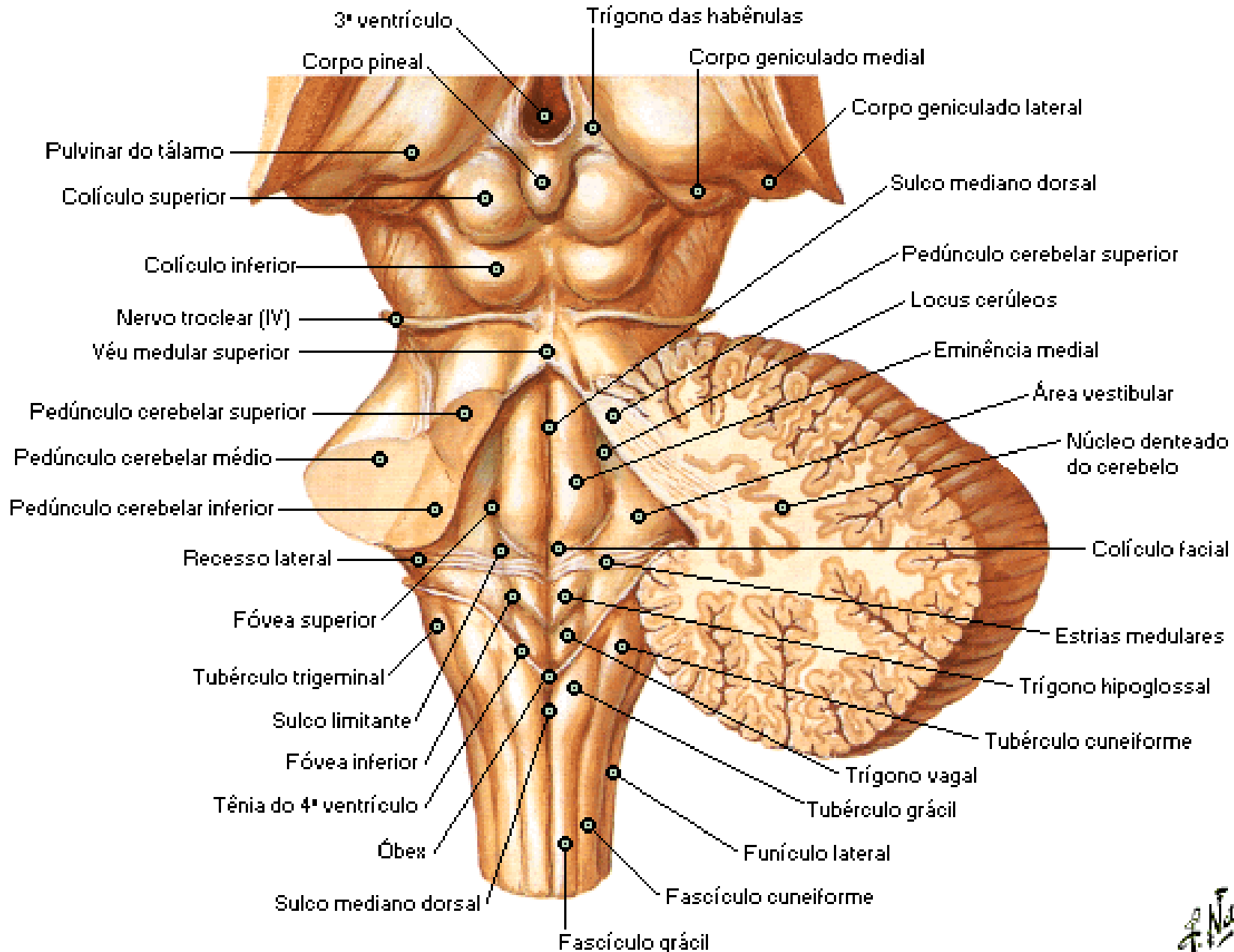
Tronco Cerebral

Vista Ântero-inferior



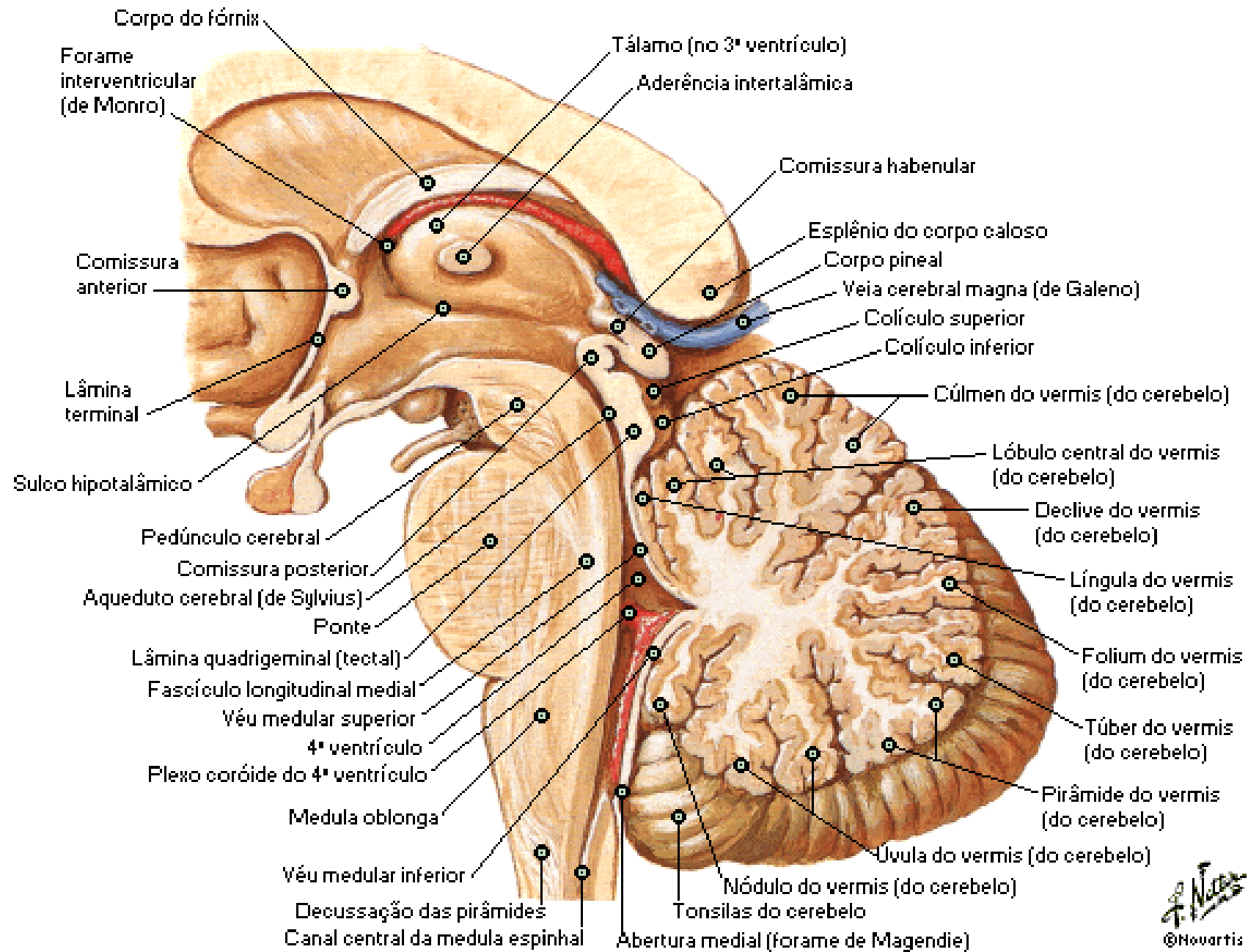
Quarto Ventrículo e Cerebelo

Vista Posterior



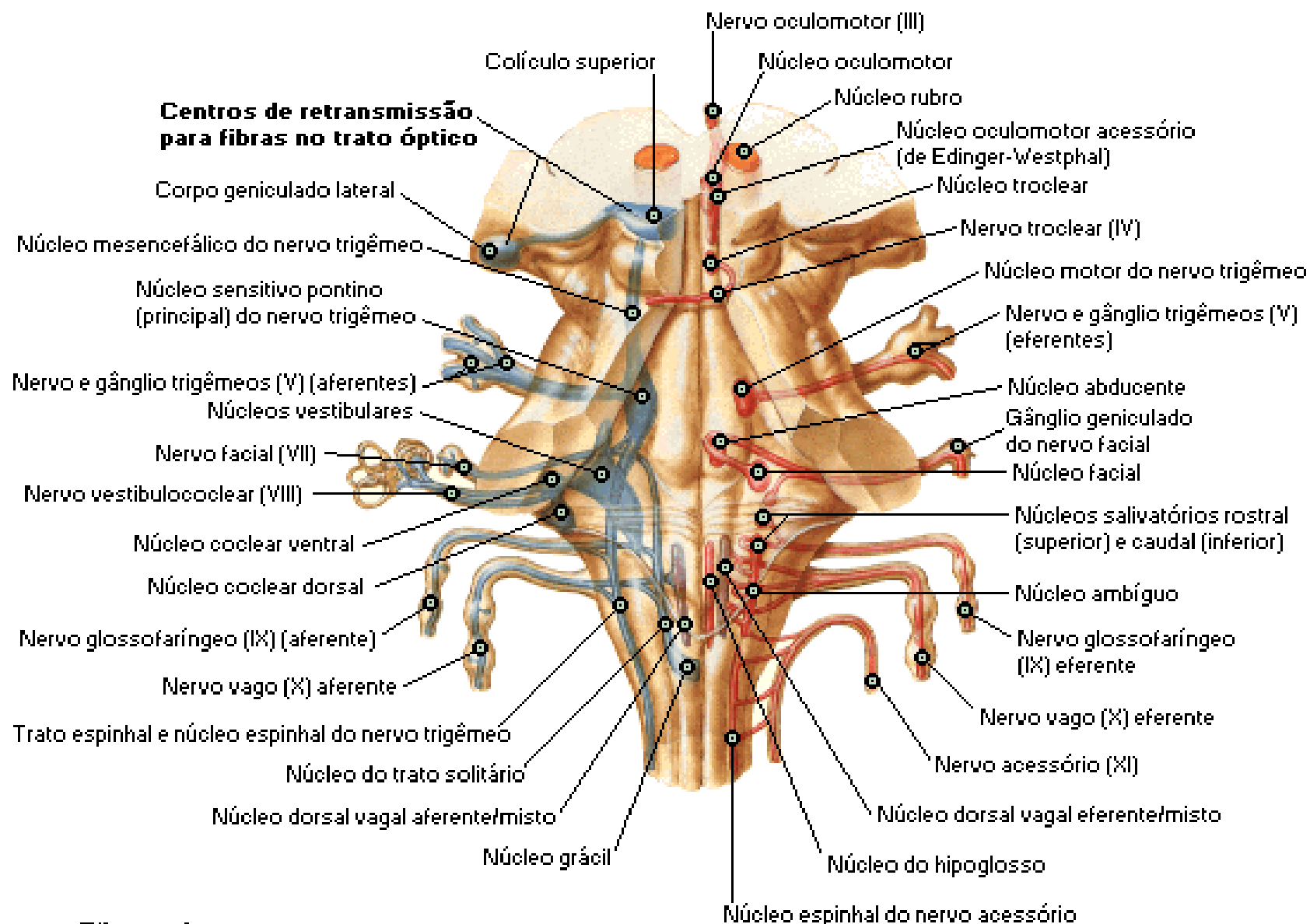
Quarto Ventrículo e Cerebelo

Secção Sagital Mediana



Núcleos dos Nervos Crânicos no Tronco Cerebral

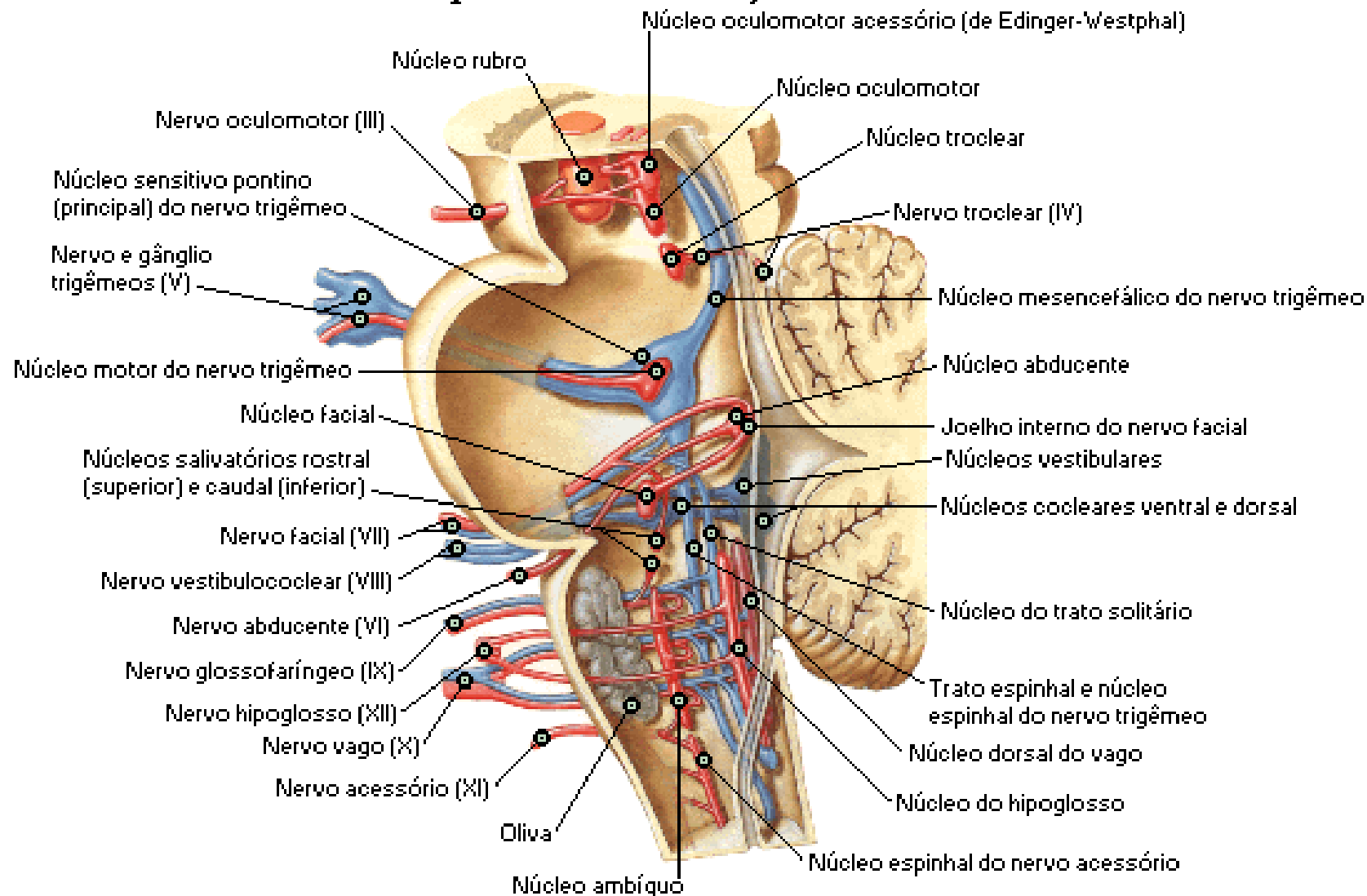
Esquema - Vista Posterior por Transparência



- Fibras eferentes
- Fibras aferentes
- Fibras mistas

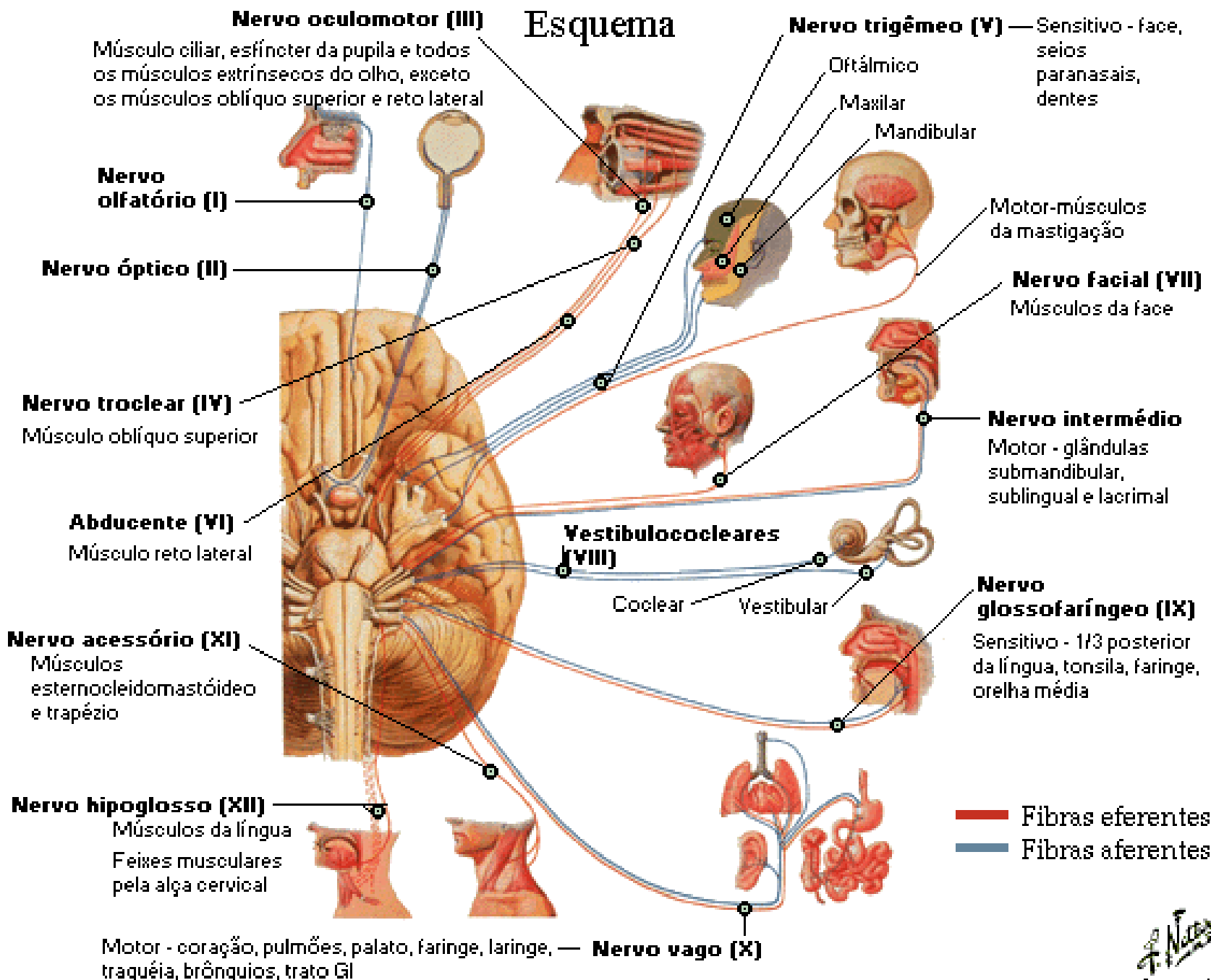
Núcleos dos Nervos Crânicos no Tronco Cerebral

Esquema - Dissecação Medial



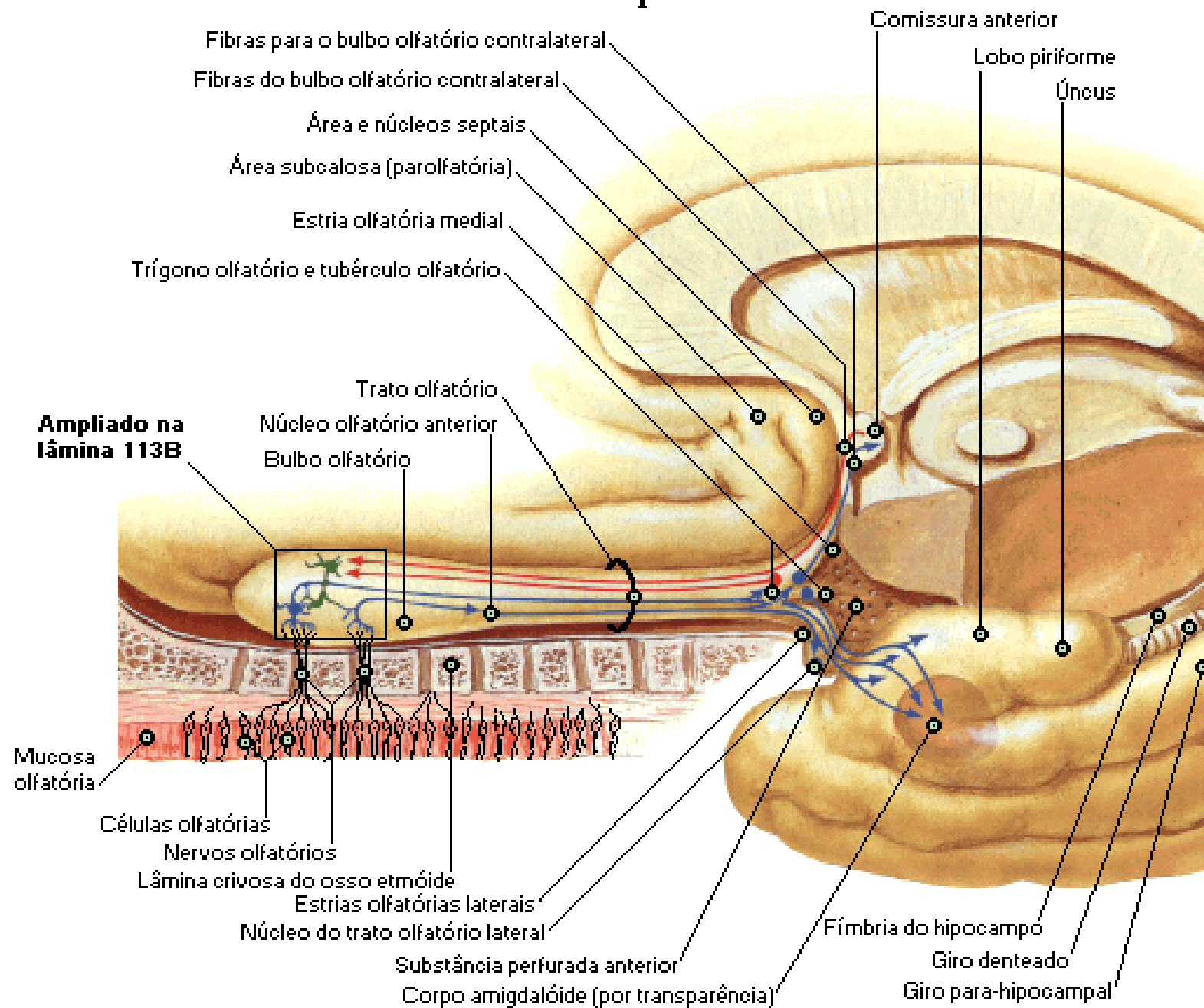
- Fibras eferentes
- Fibras aferentes
- Fibras mistas

Nervos Crânicos [Distribuição Motora e Sensitiva]



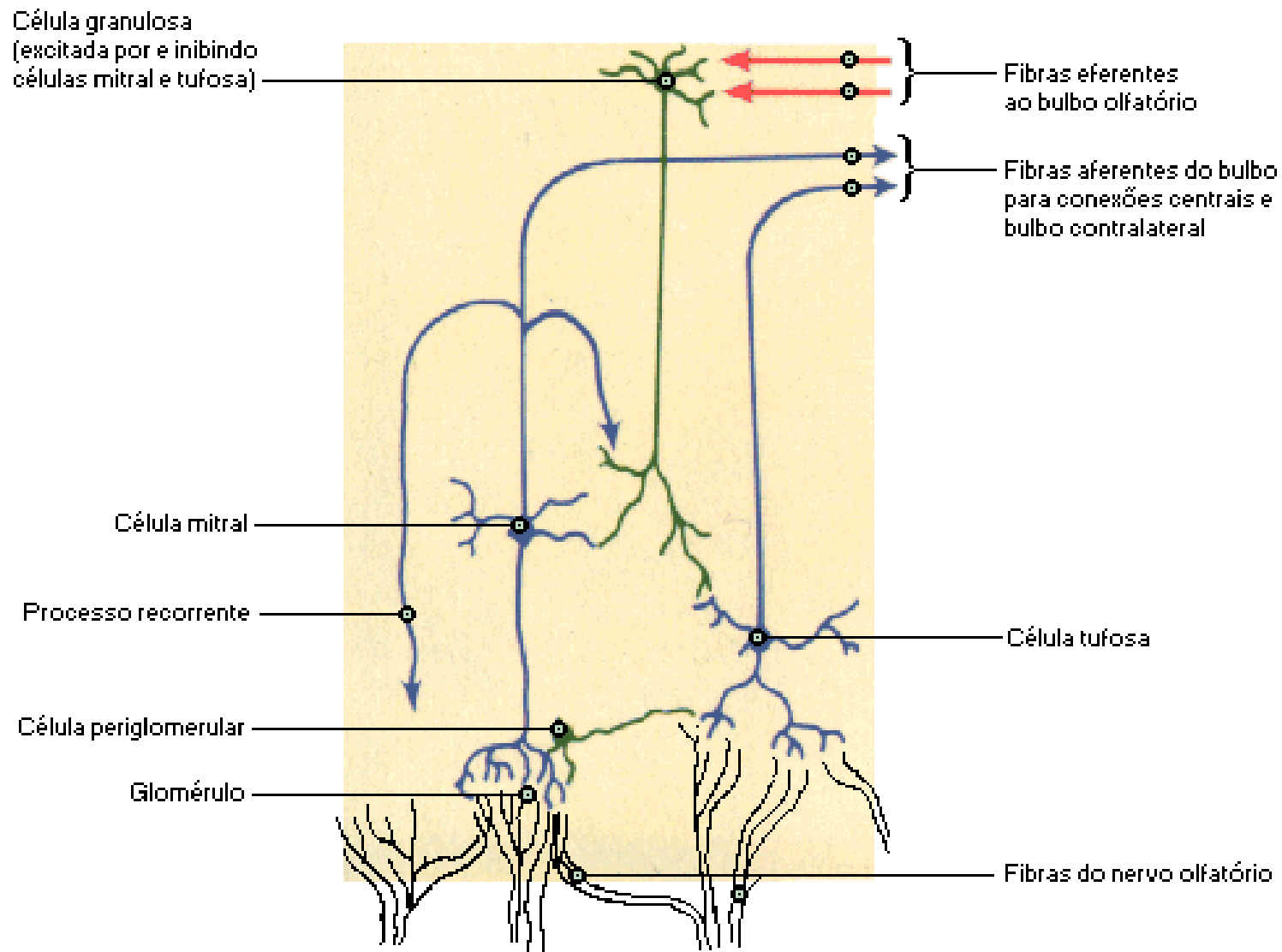
Nervo Olfatório

Esquema



Nervo Olfatório - Células do Bulbo Olfatório

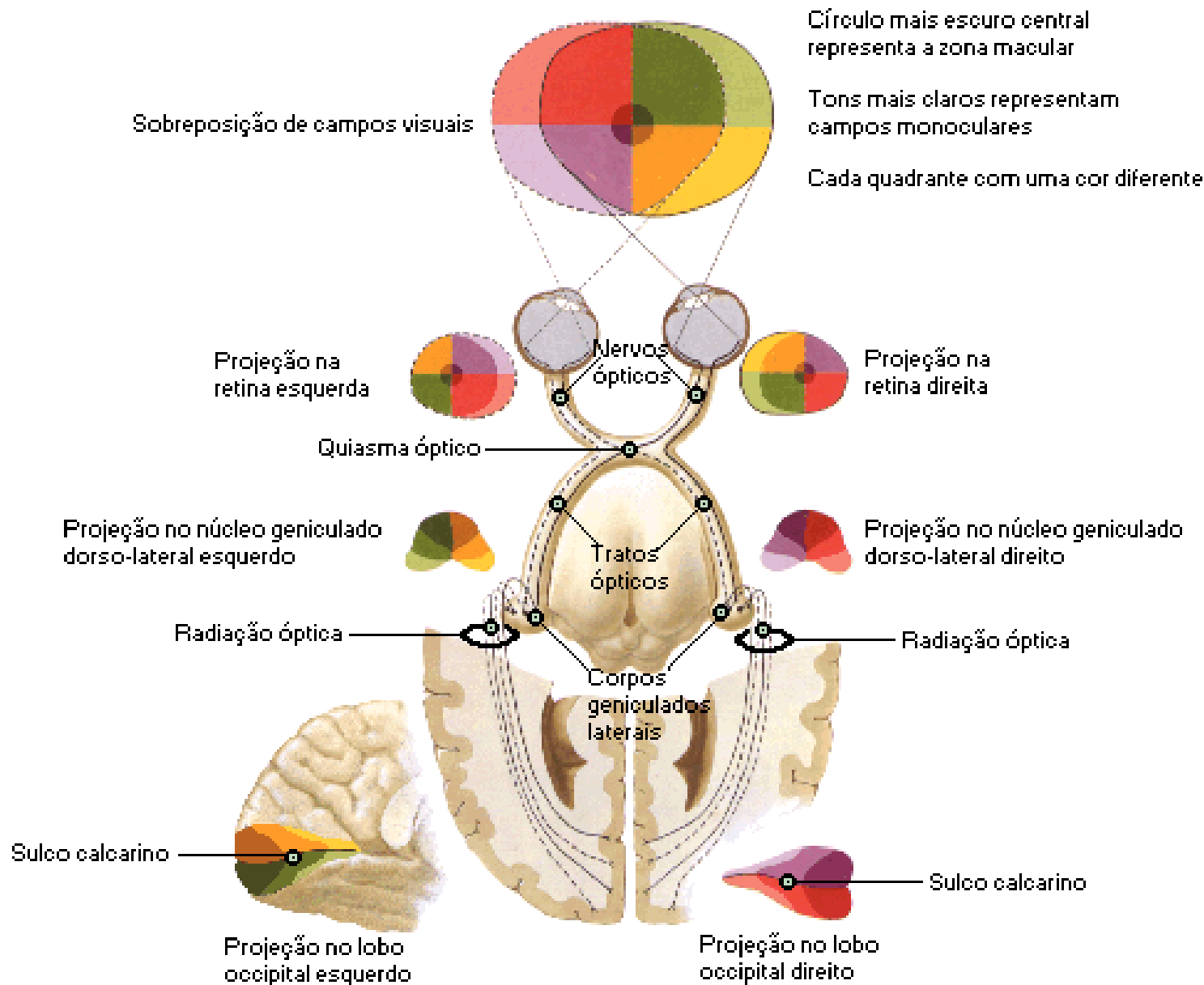
Esquema



Esquema da área delineada na lâmina 113A

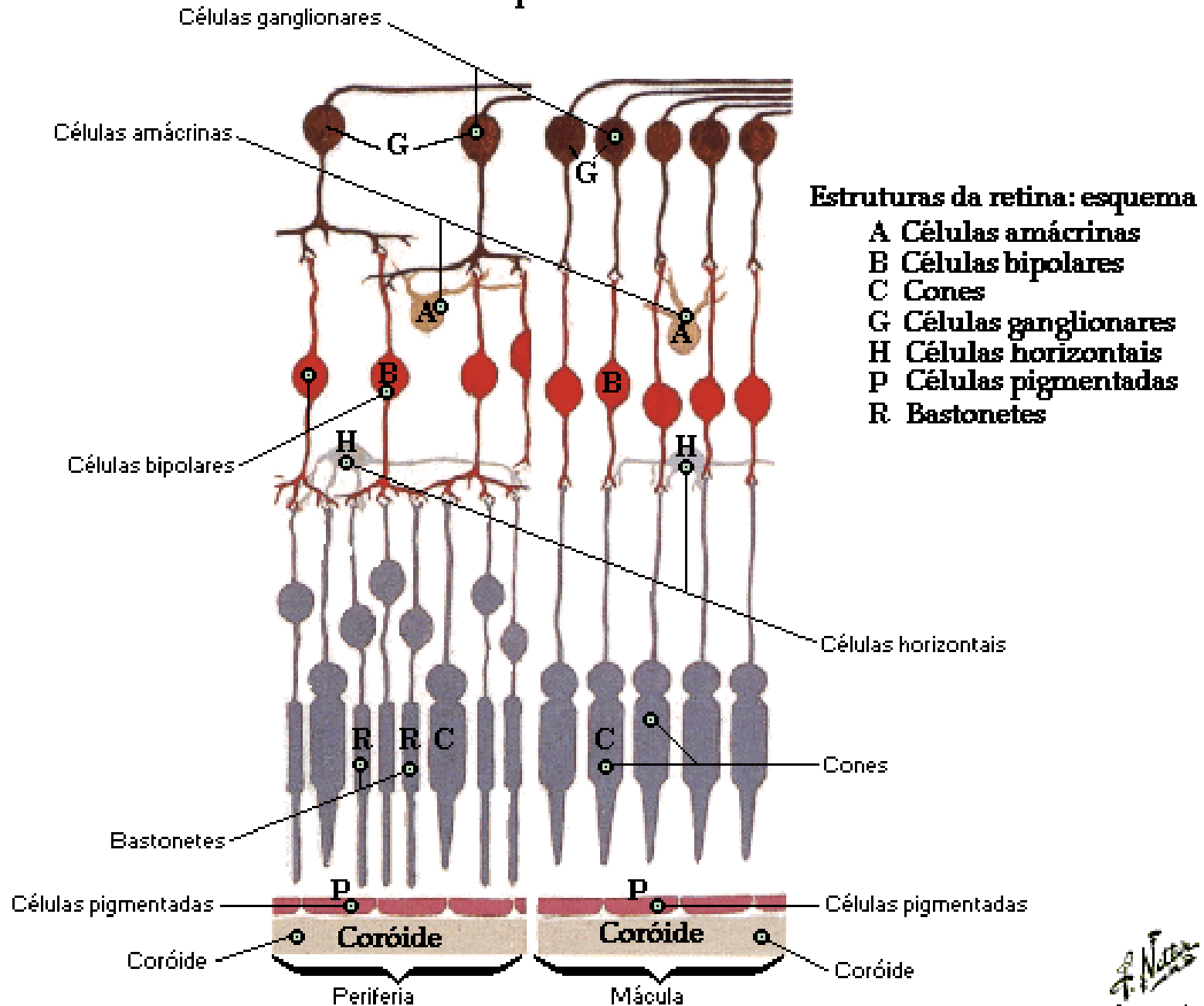
Nervo Óptico [Via Óptica]

Esquema



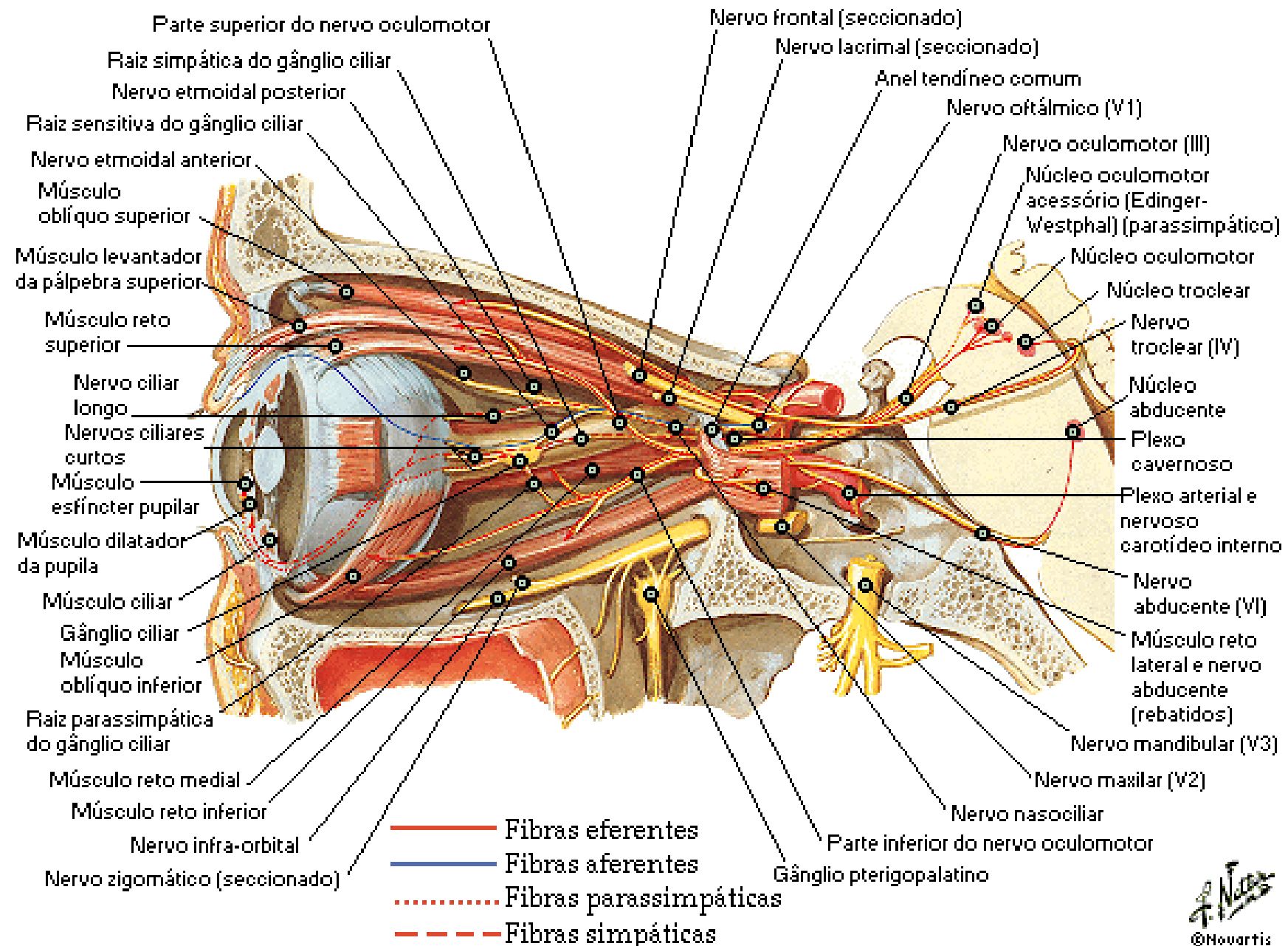
Nervo Óptico [Via Óptica] - Estrutura da Retina

Esquema



Nervos Oculomotor, Troclear e Abducente

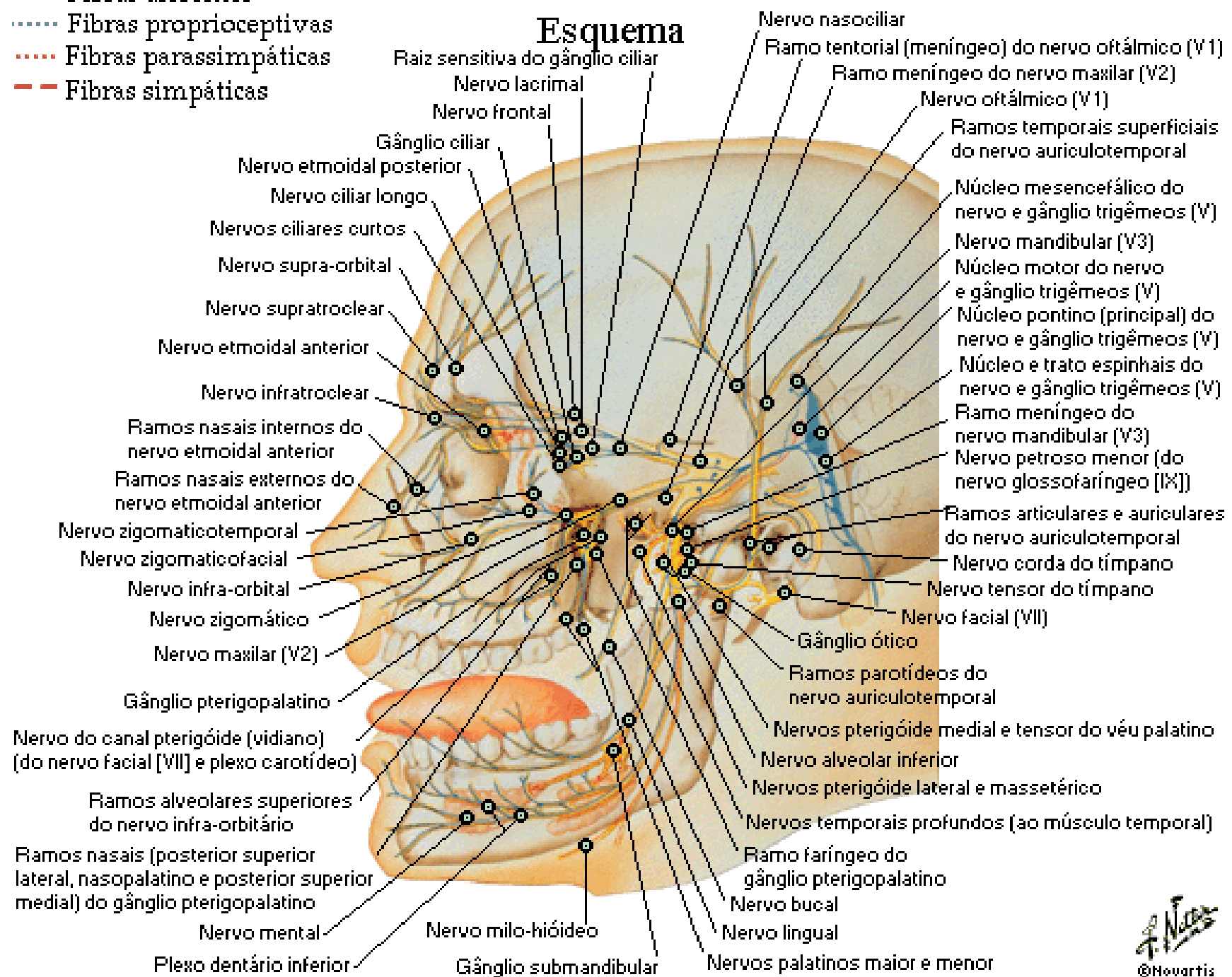
Esquema



Nervo Trigêmeo

- Fibras eferentes
- Fibras aferentes
- Fibras proprioceptivas
- Fibras parassimpáticas
- Fibras simpáticas

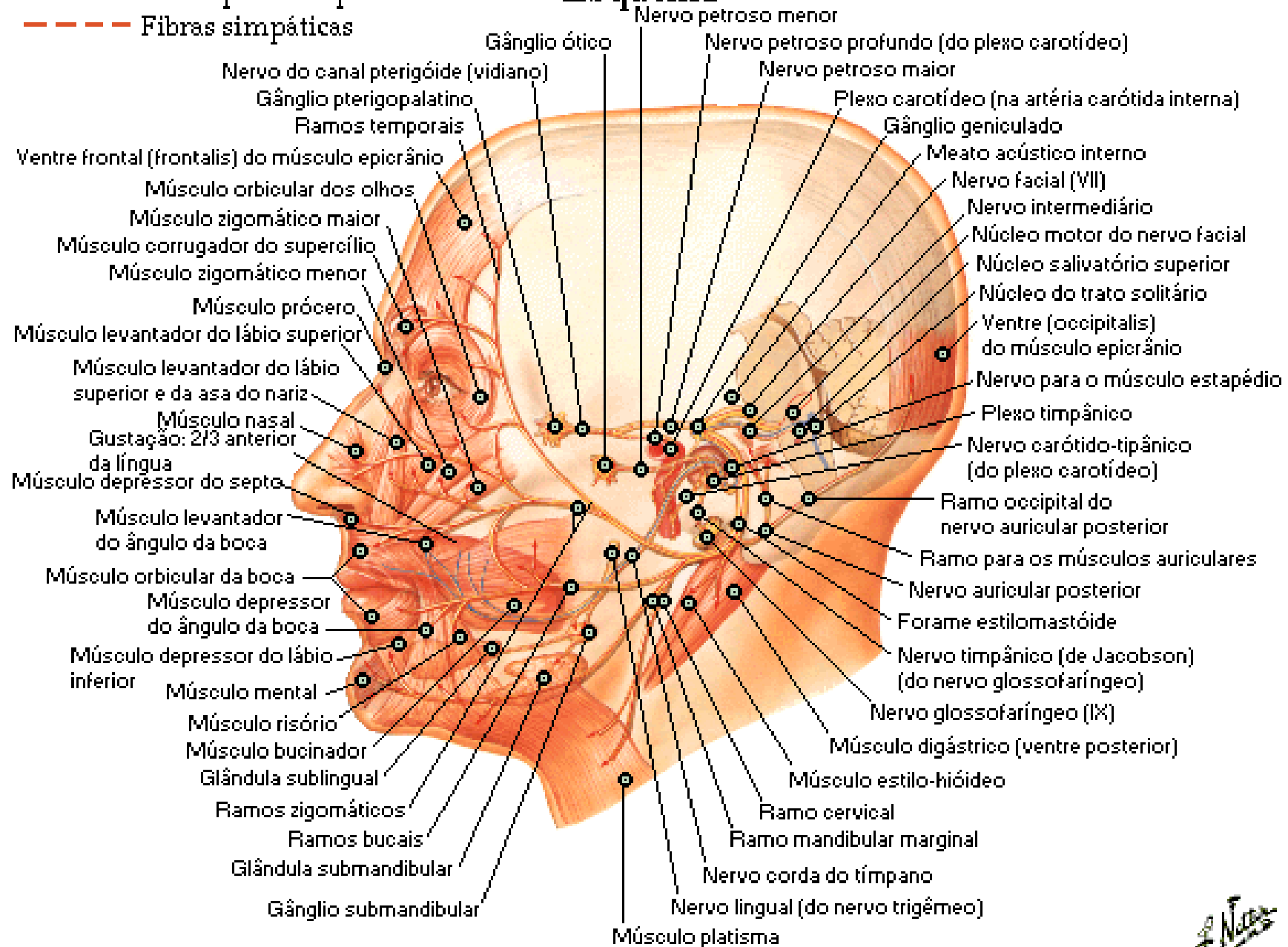
Esquema



Nervo Facial

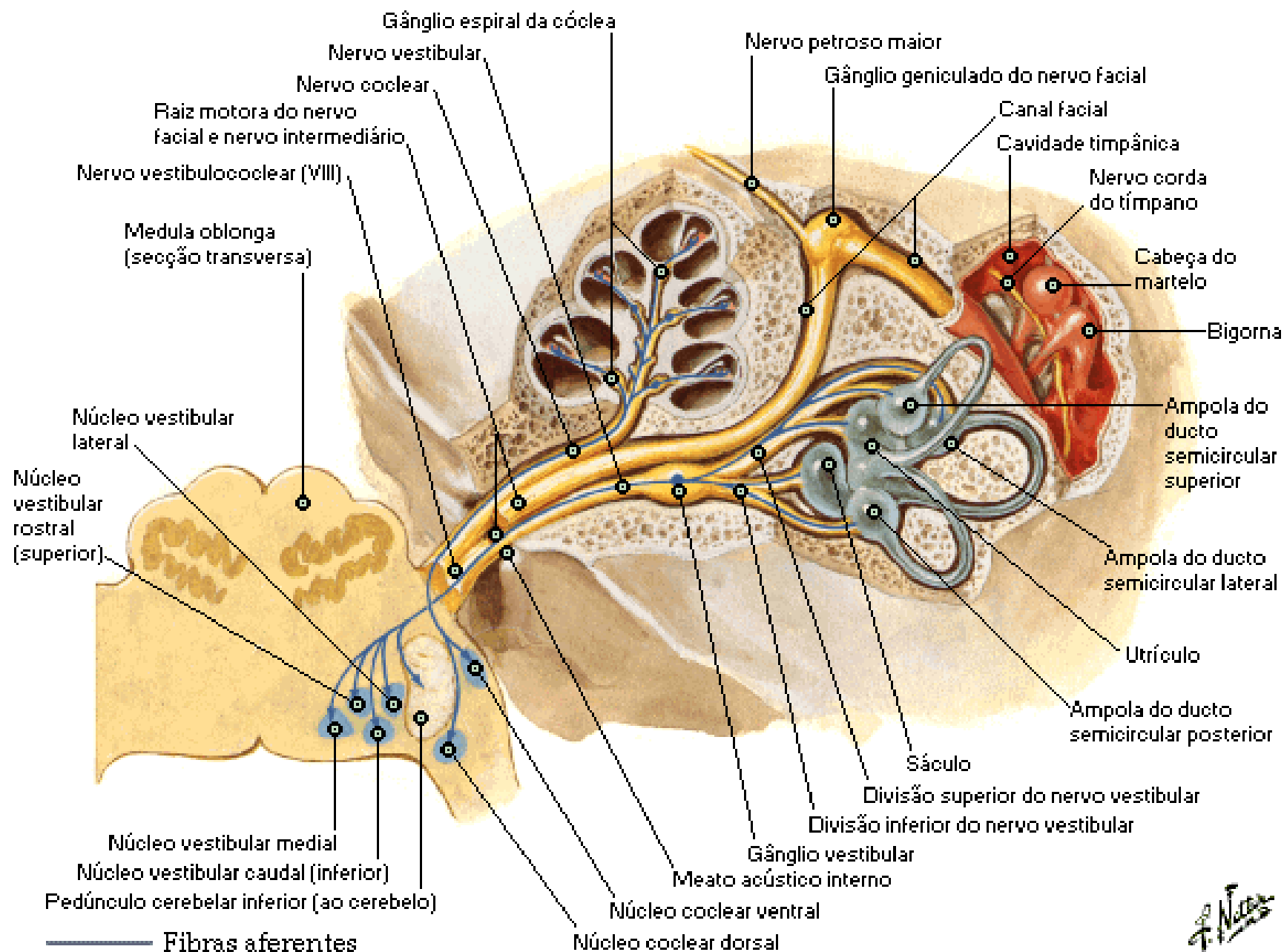
Esquema

- Fibras eferentes
- Fibras aferentes
- Fibras parassimpáticas
- - - Fibras simpáticas



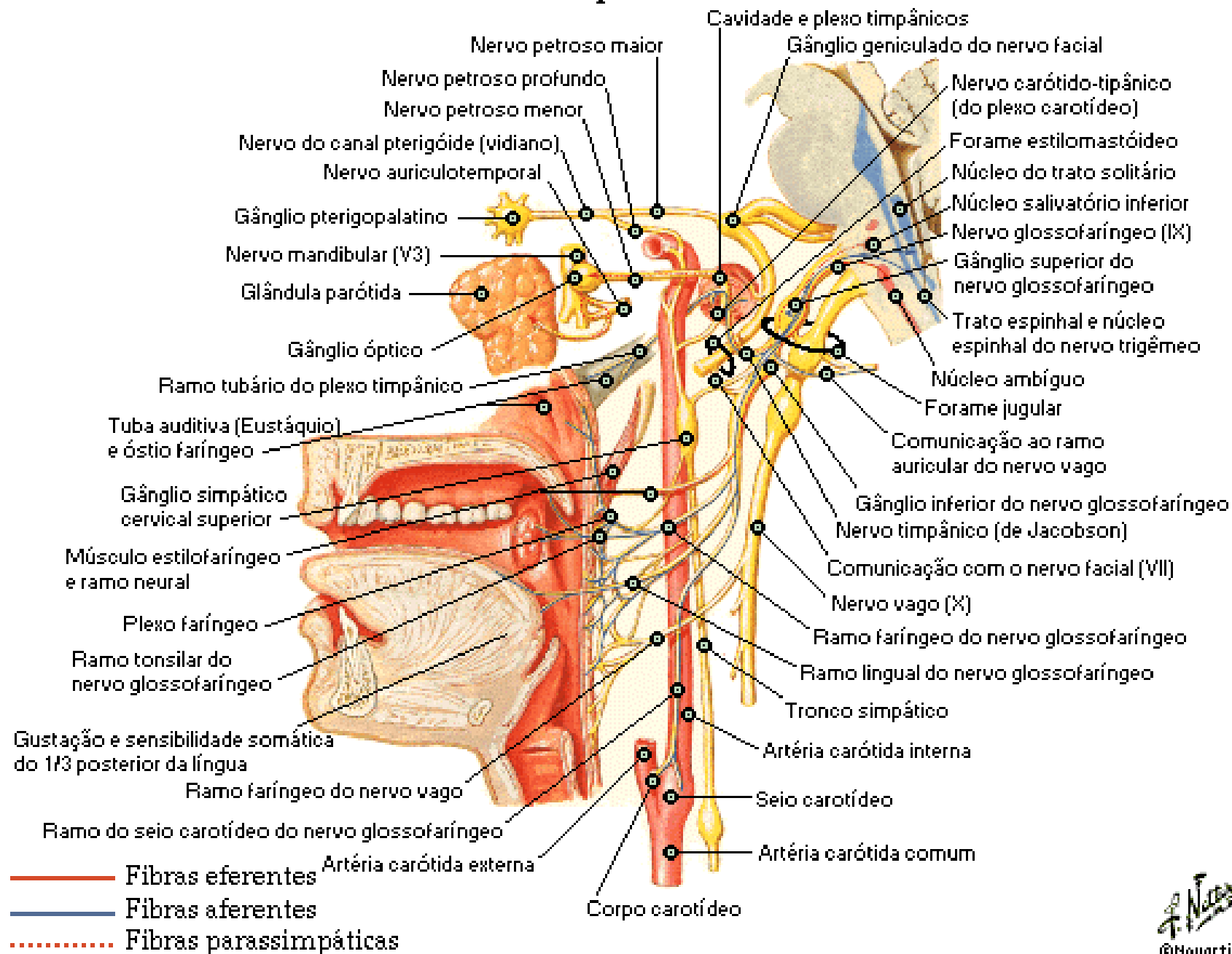
Nervo Vestibulococlear

Esquema



Nervo Glossofaríngeo

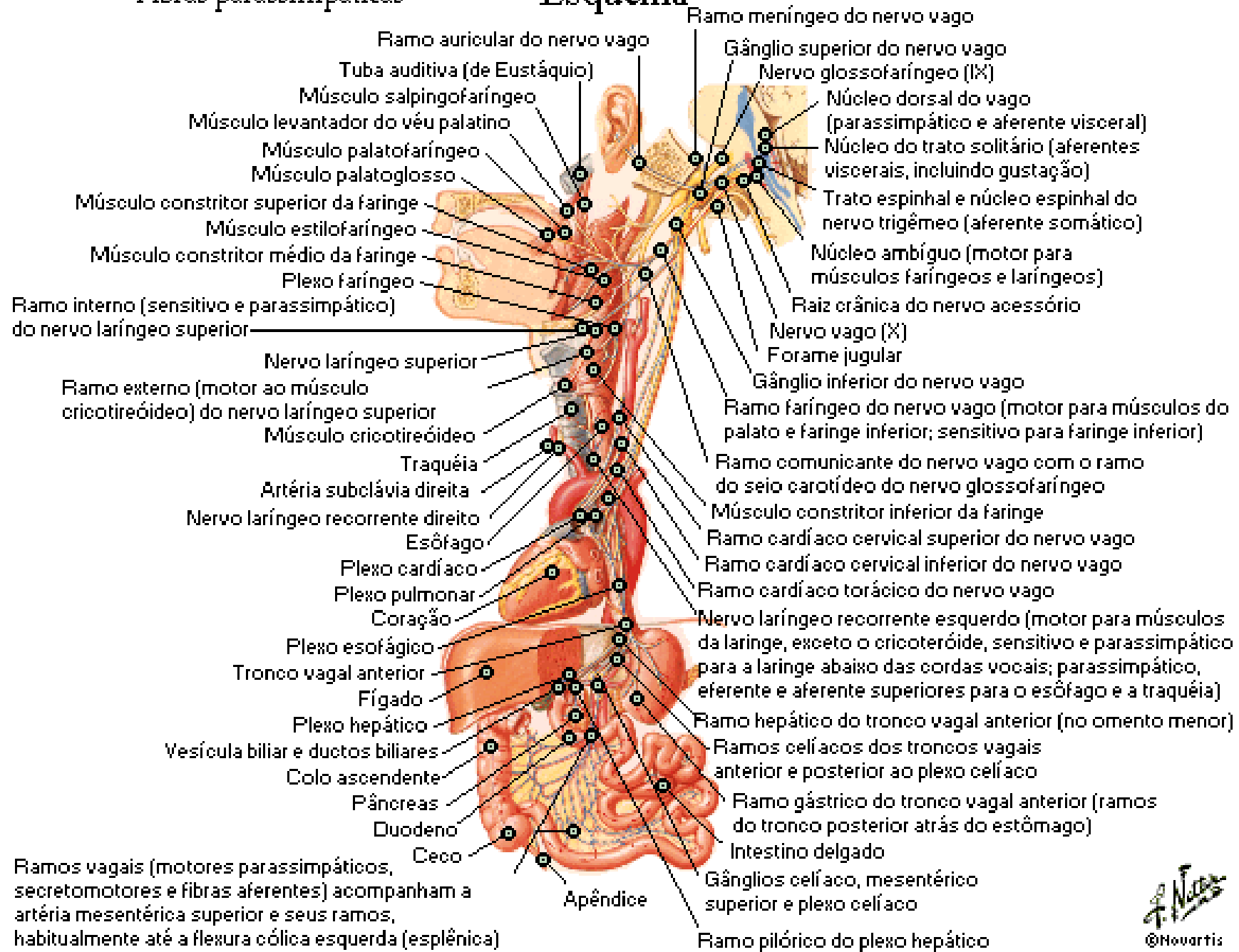
Esquema



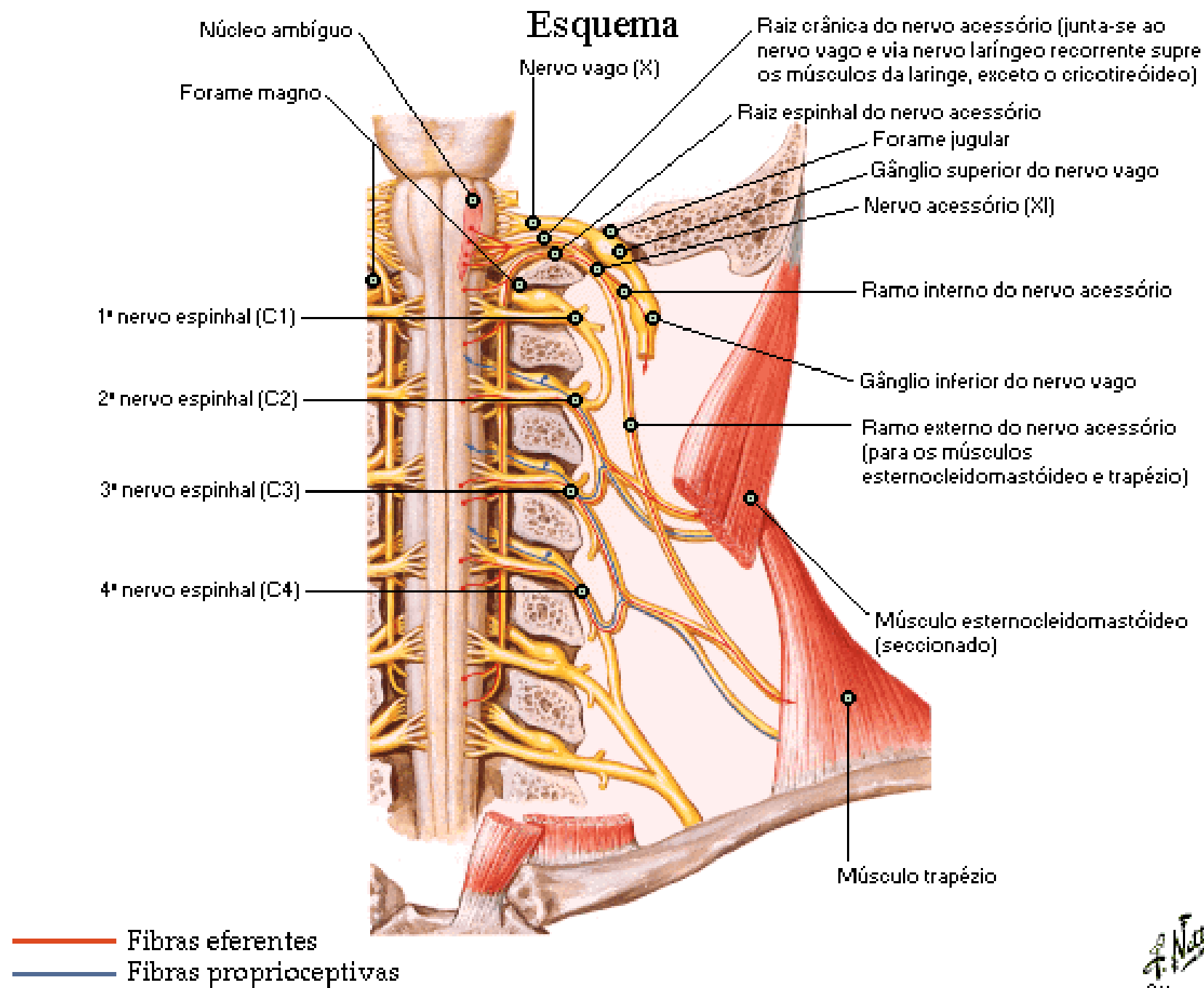
- Fibras eferentes
- Fibras aferentes
- ⋯ Fibras parassimpáticas

Nervo Vago

Esquema

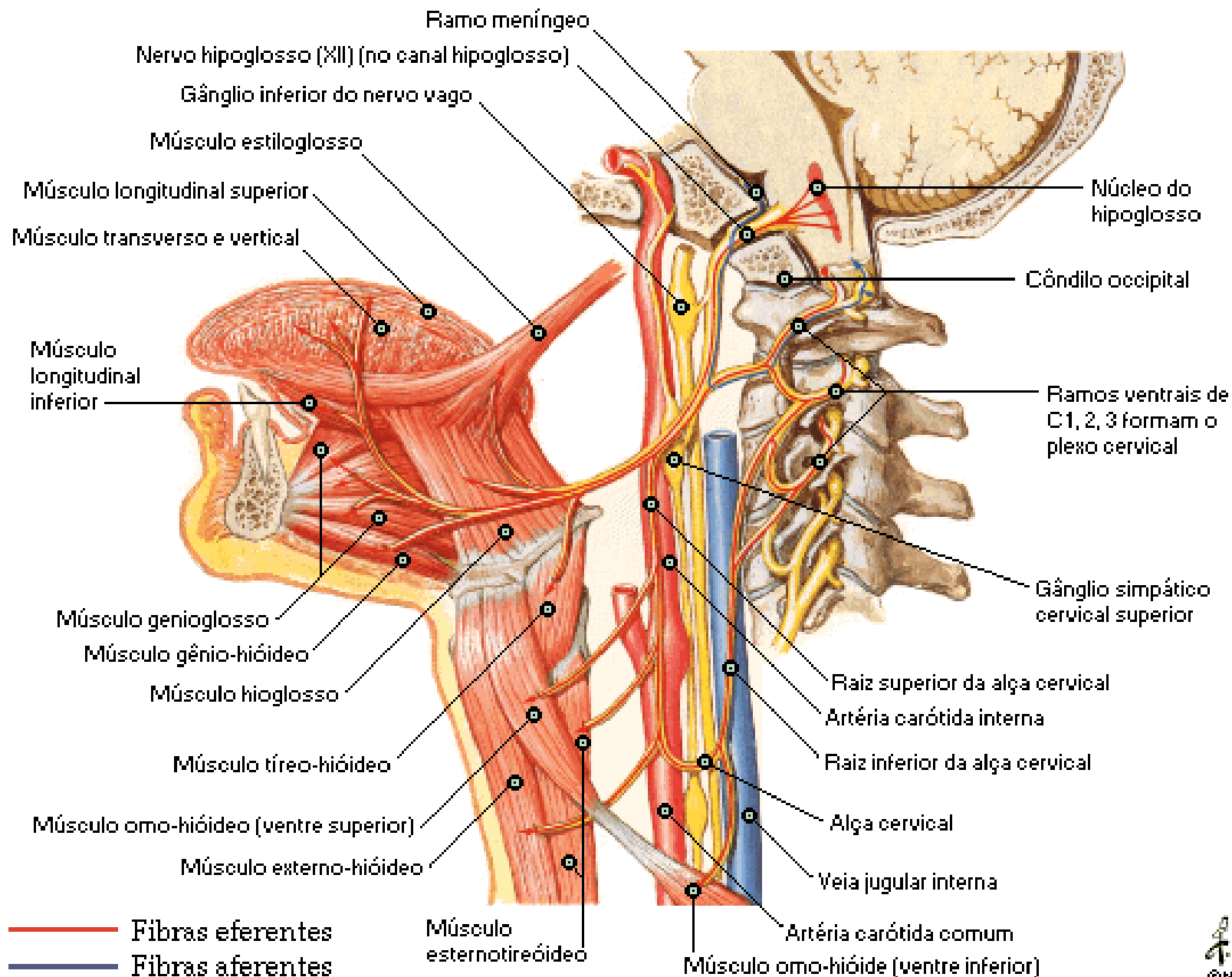


Nervo Acessório



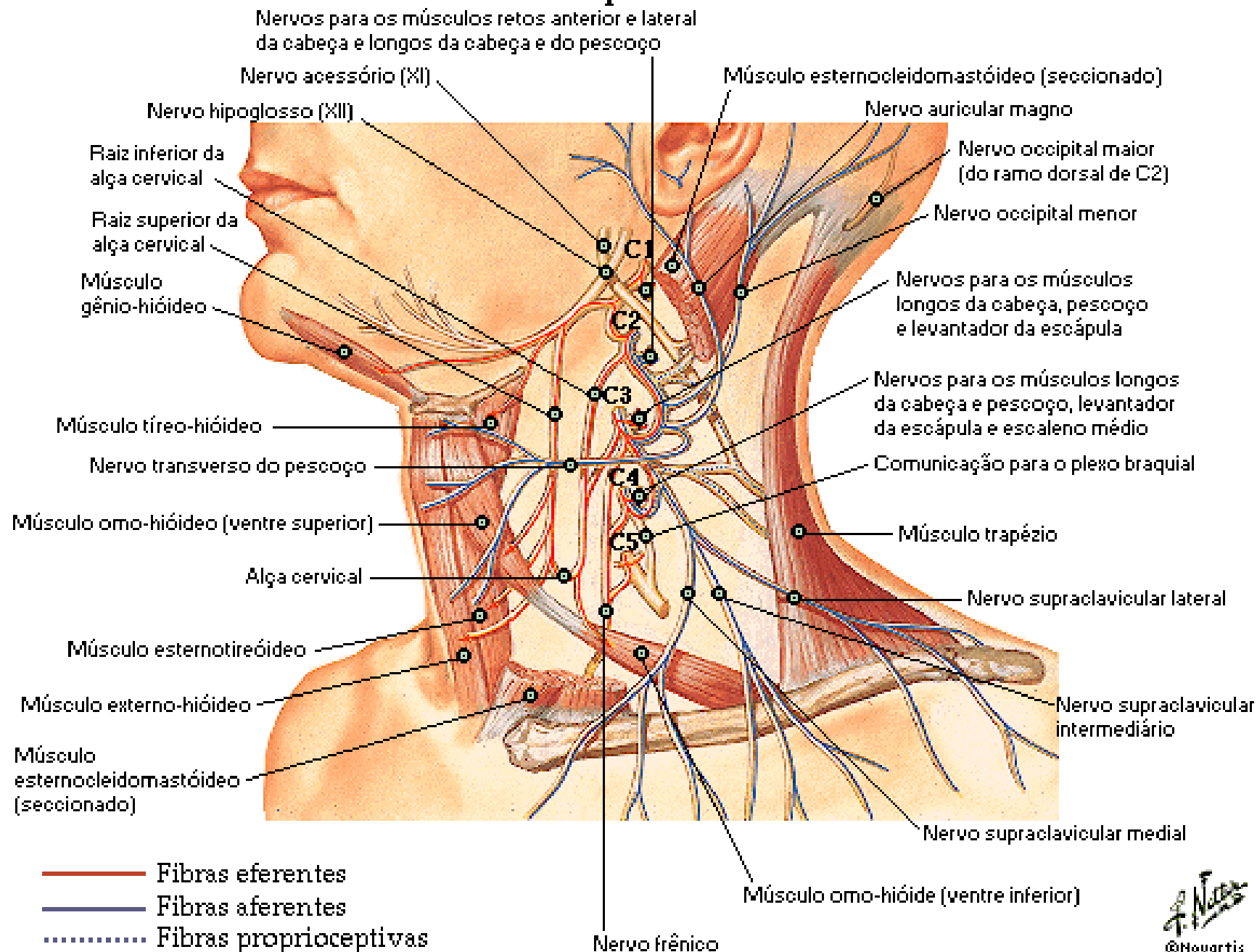
Nervo Hipoglosso

Esquema

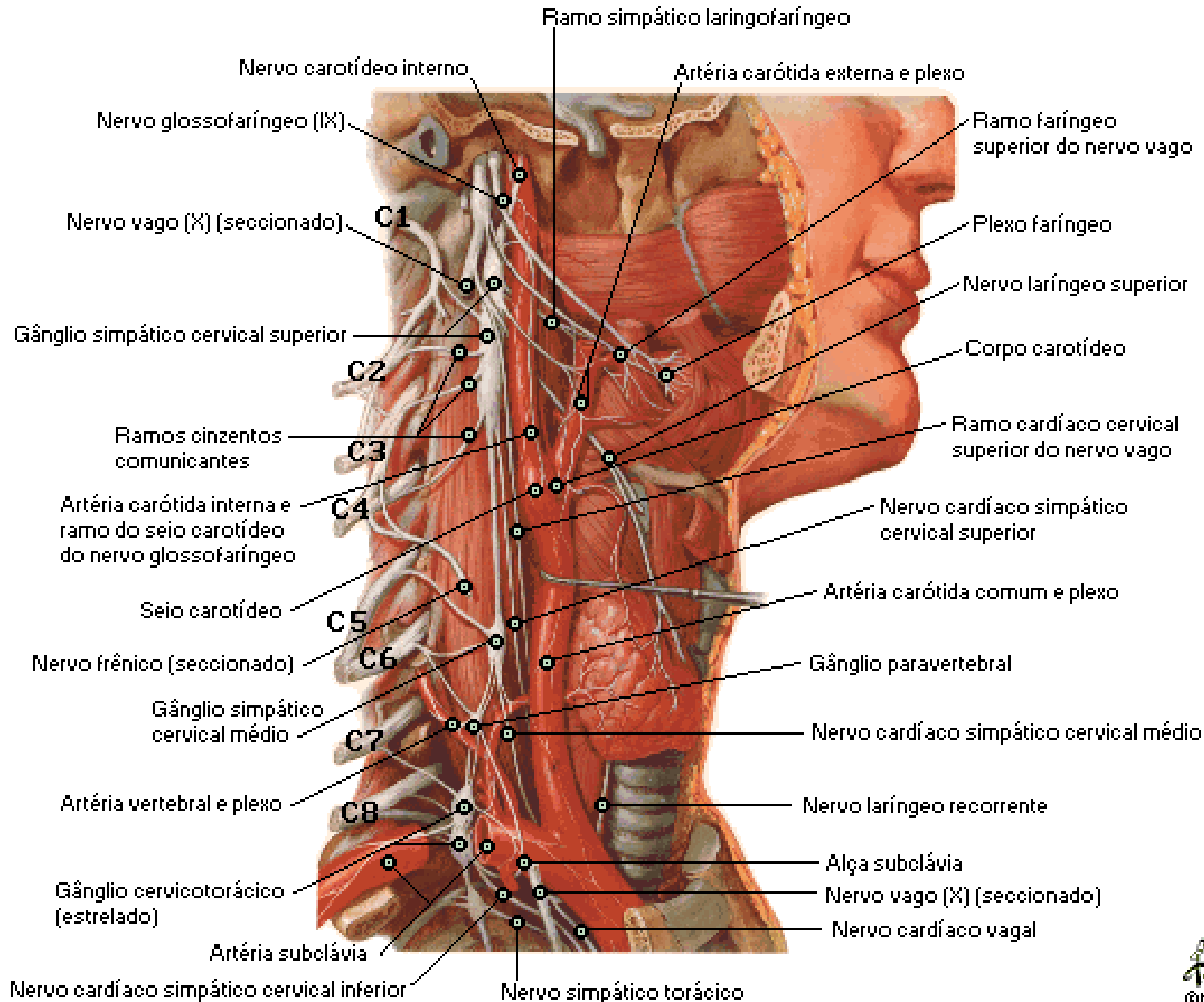


Plexo Cervical

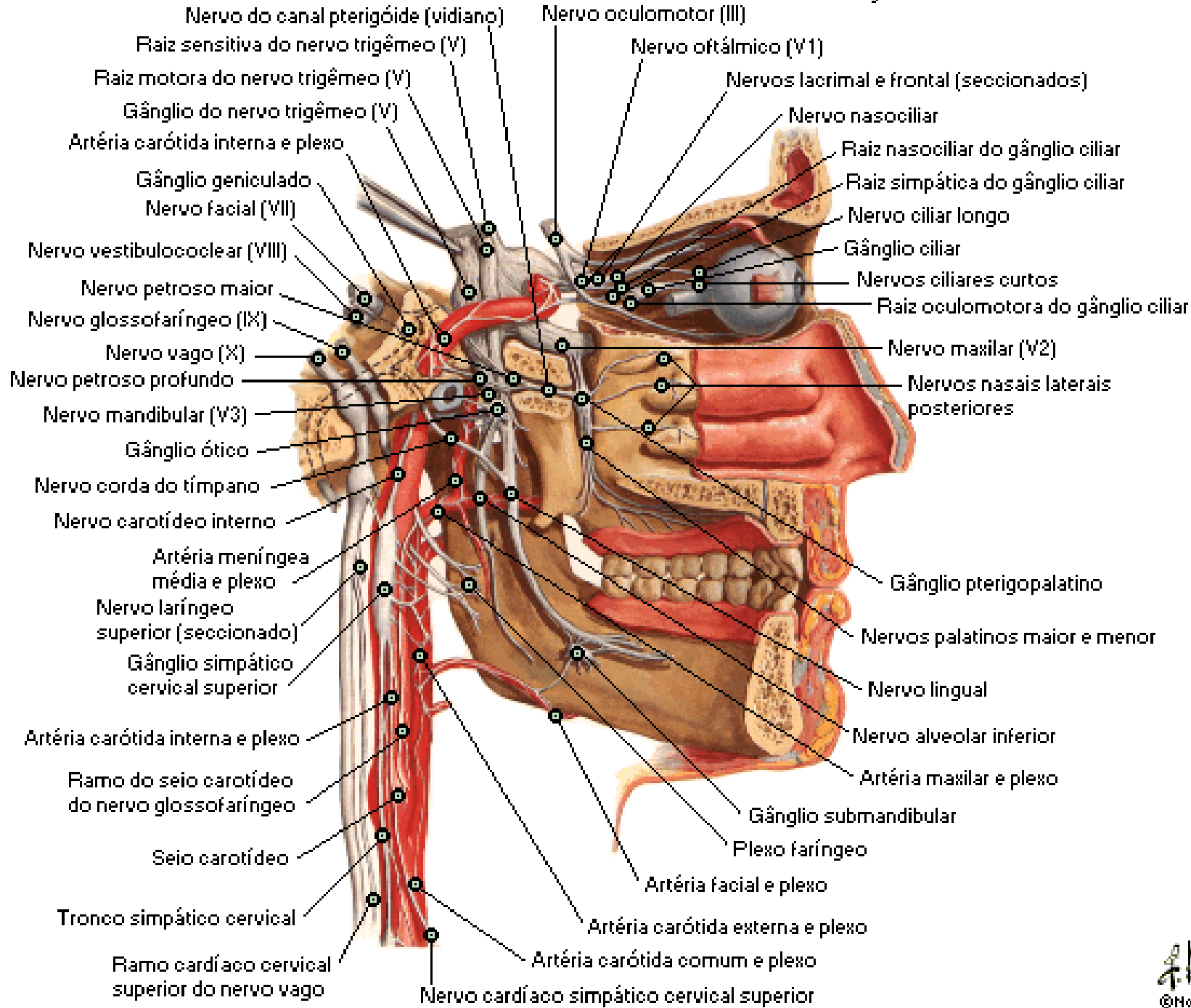
Esquema



Nervos Autônomos do Pescoço

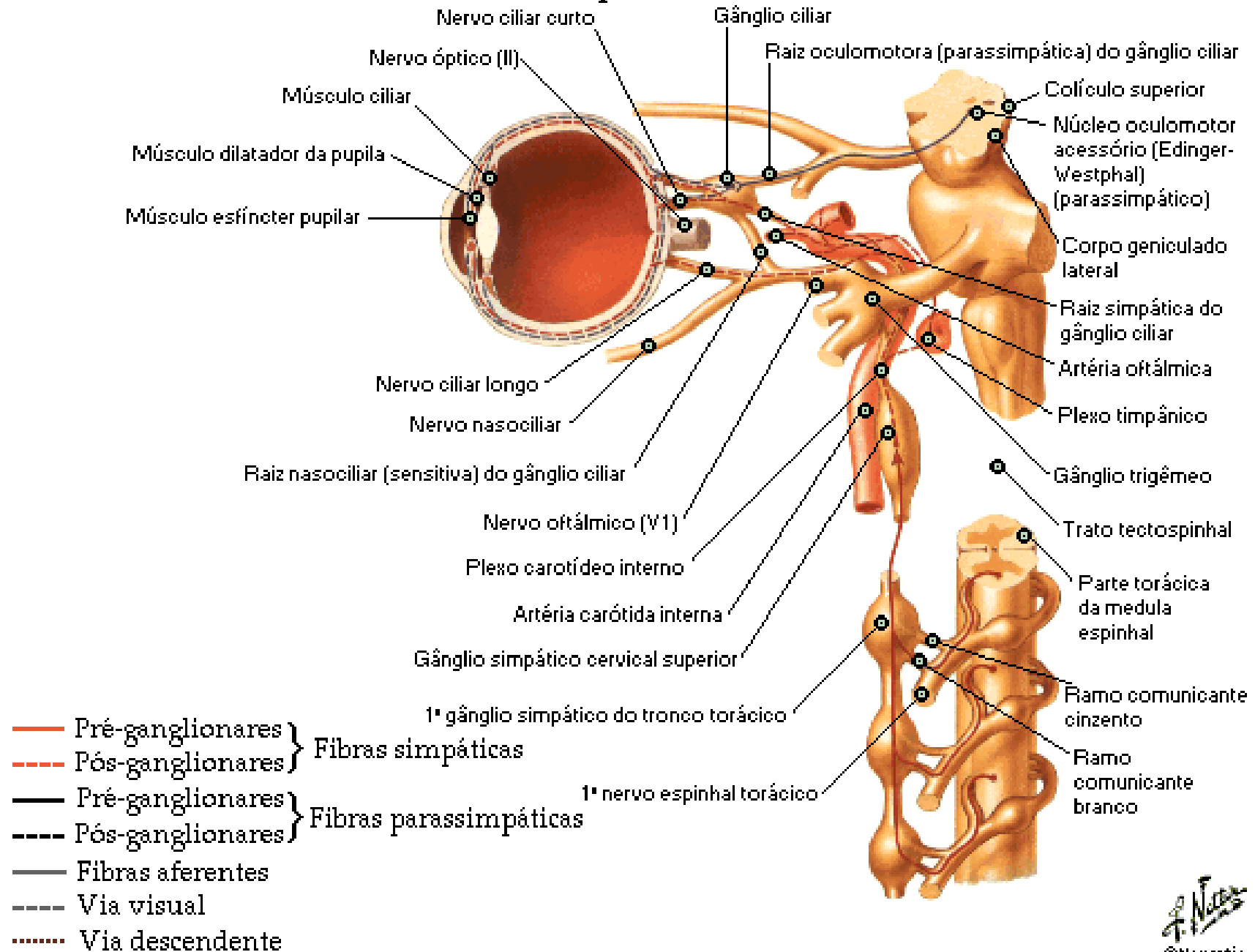


Nervos Autônomos da Cabeça



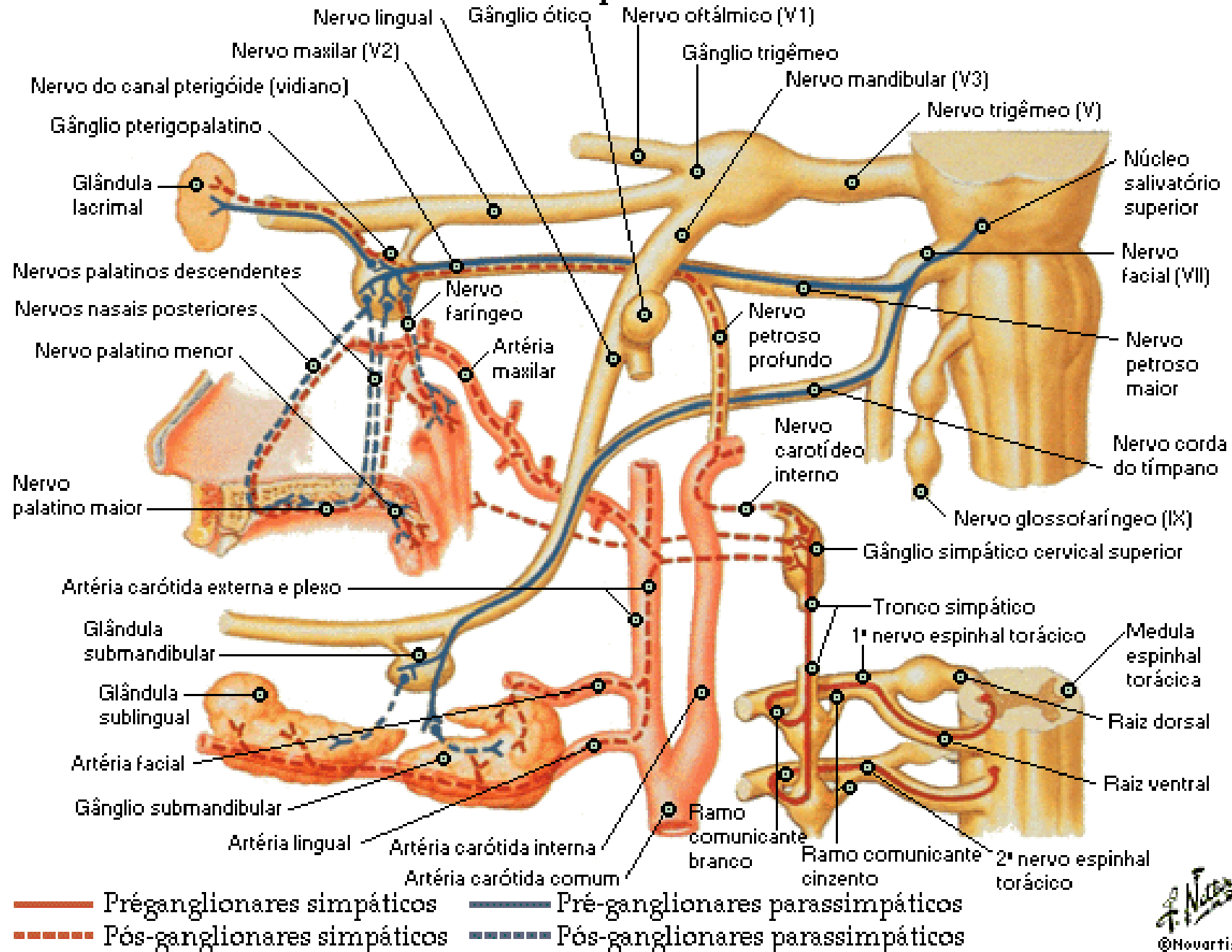
Gânglio Ciliar

Esquema



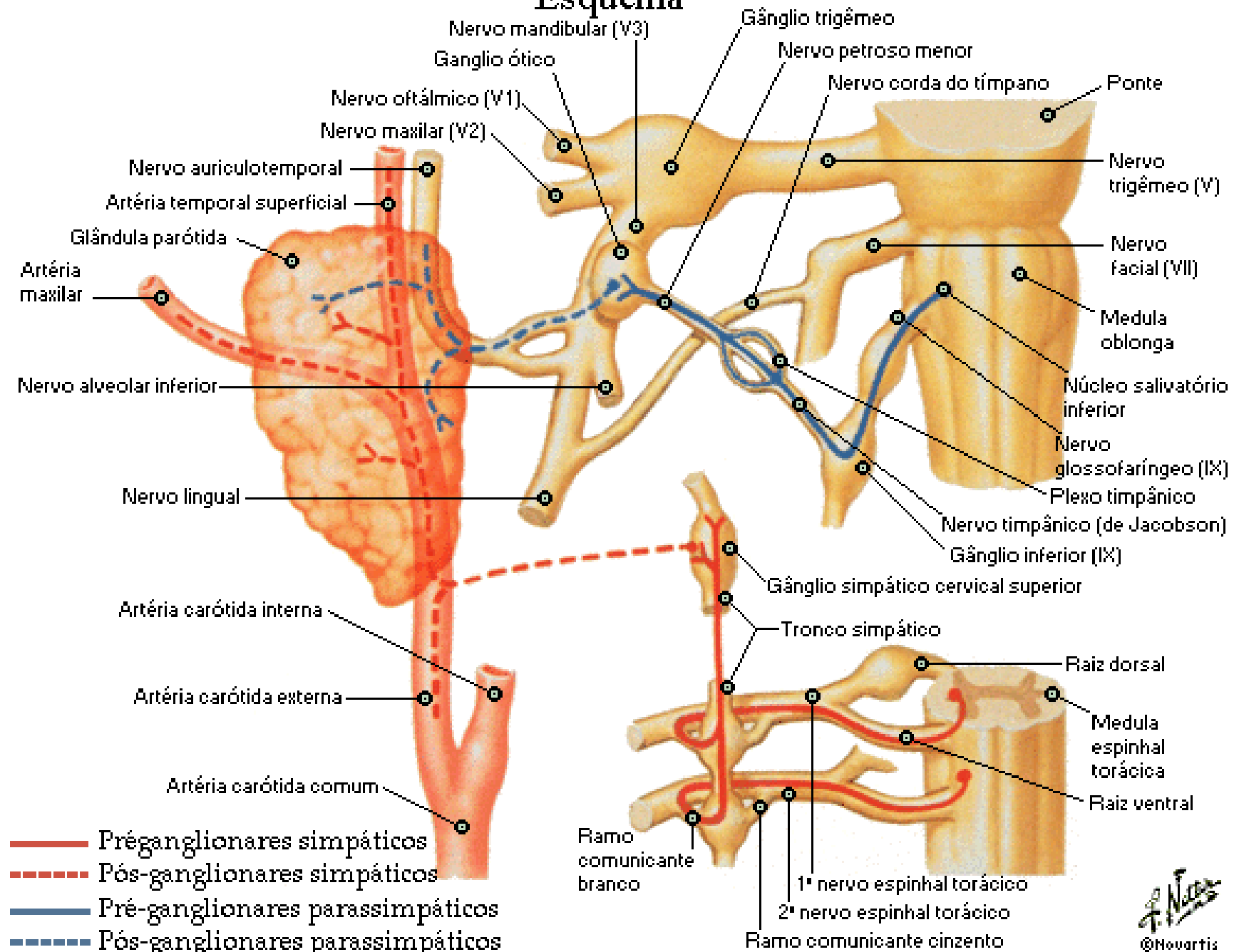
Gânglios Pterigopalatino e Submandibular

Esquema



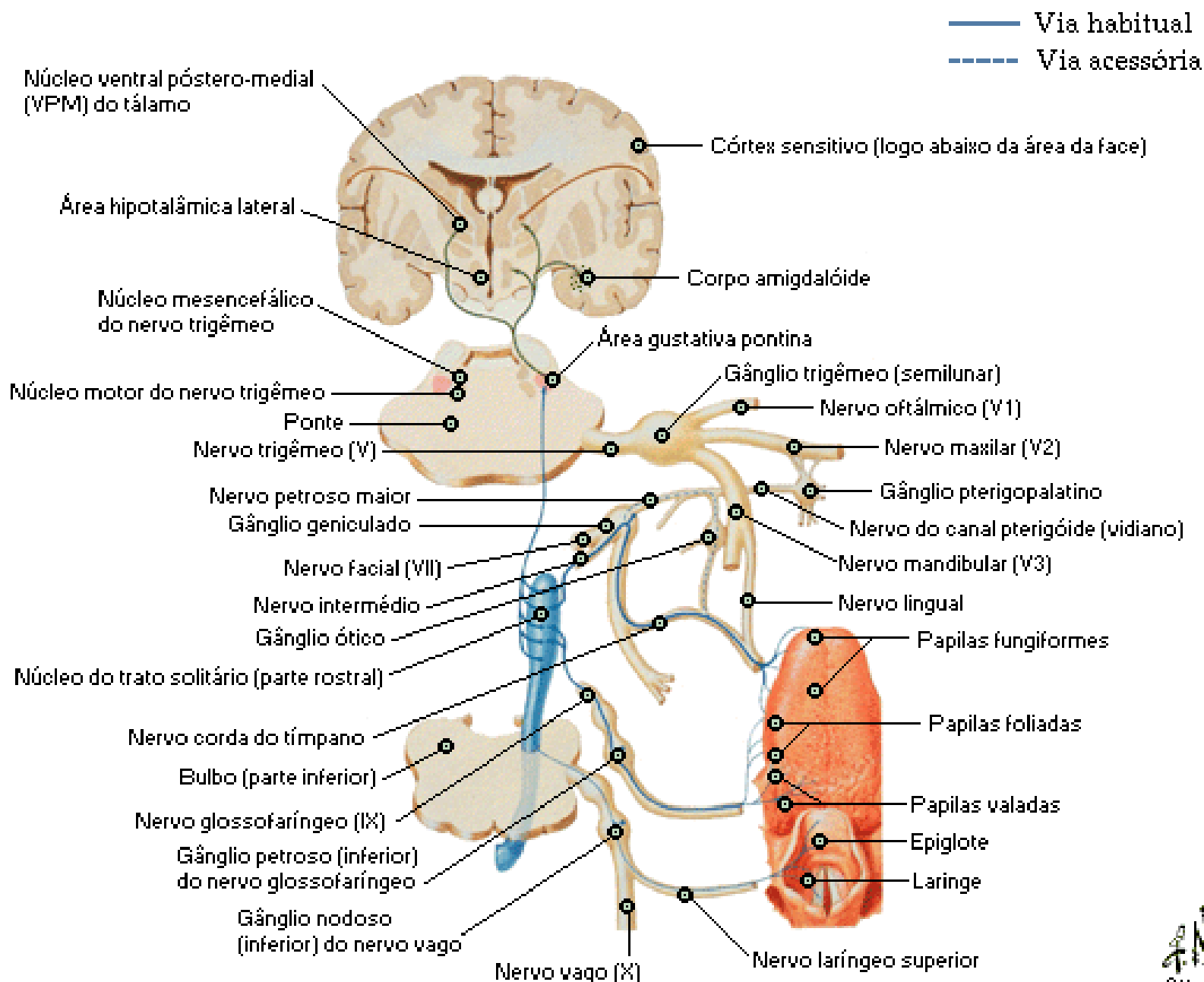
Gânglio Ótico

Esquema

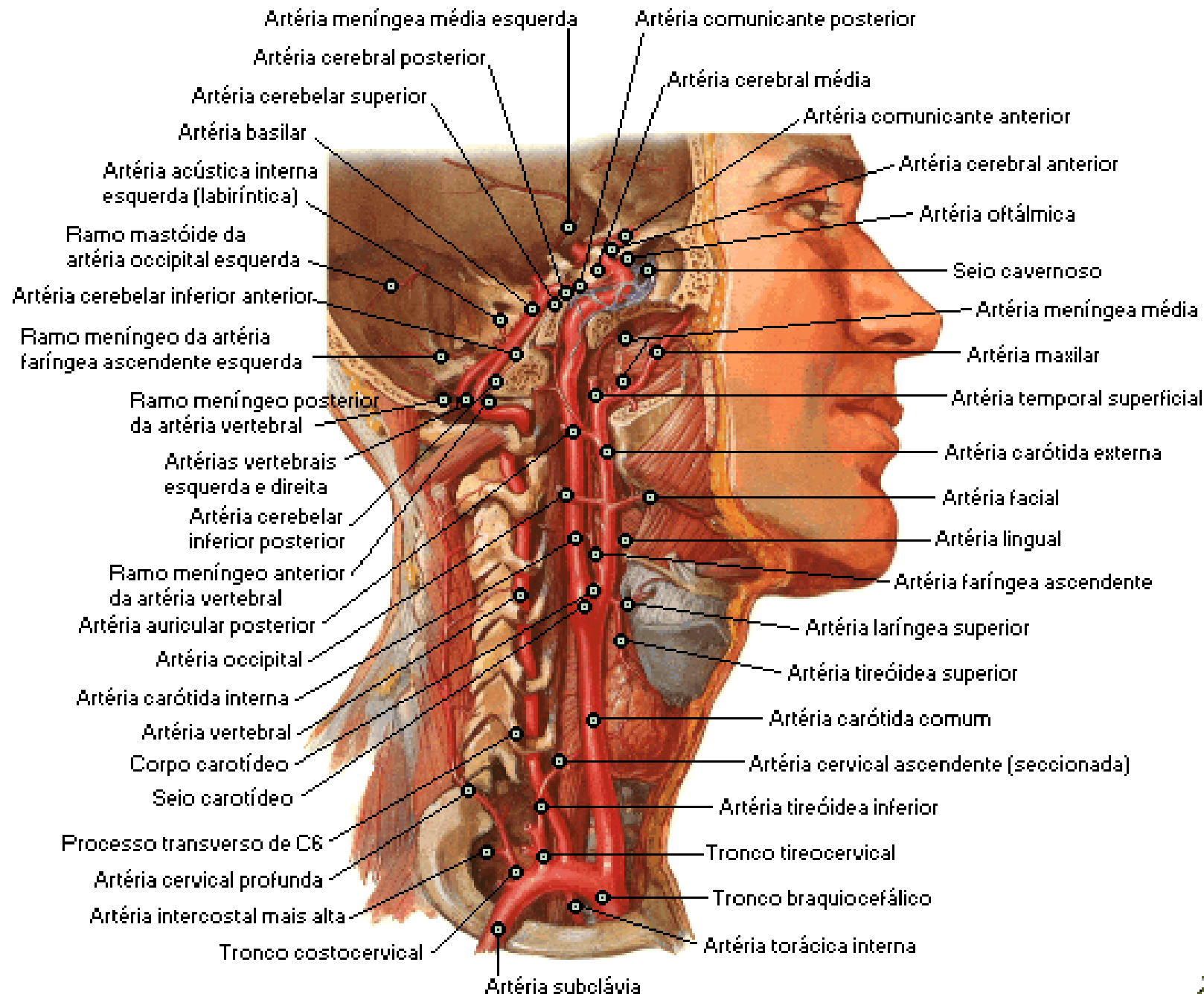


Vias Gustativas

Esquema

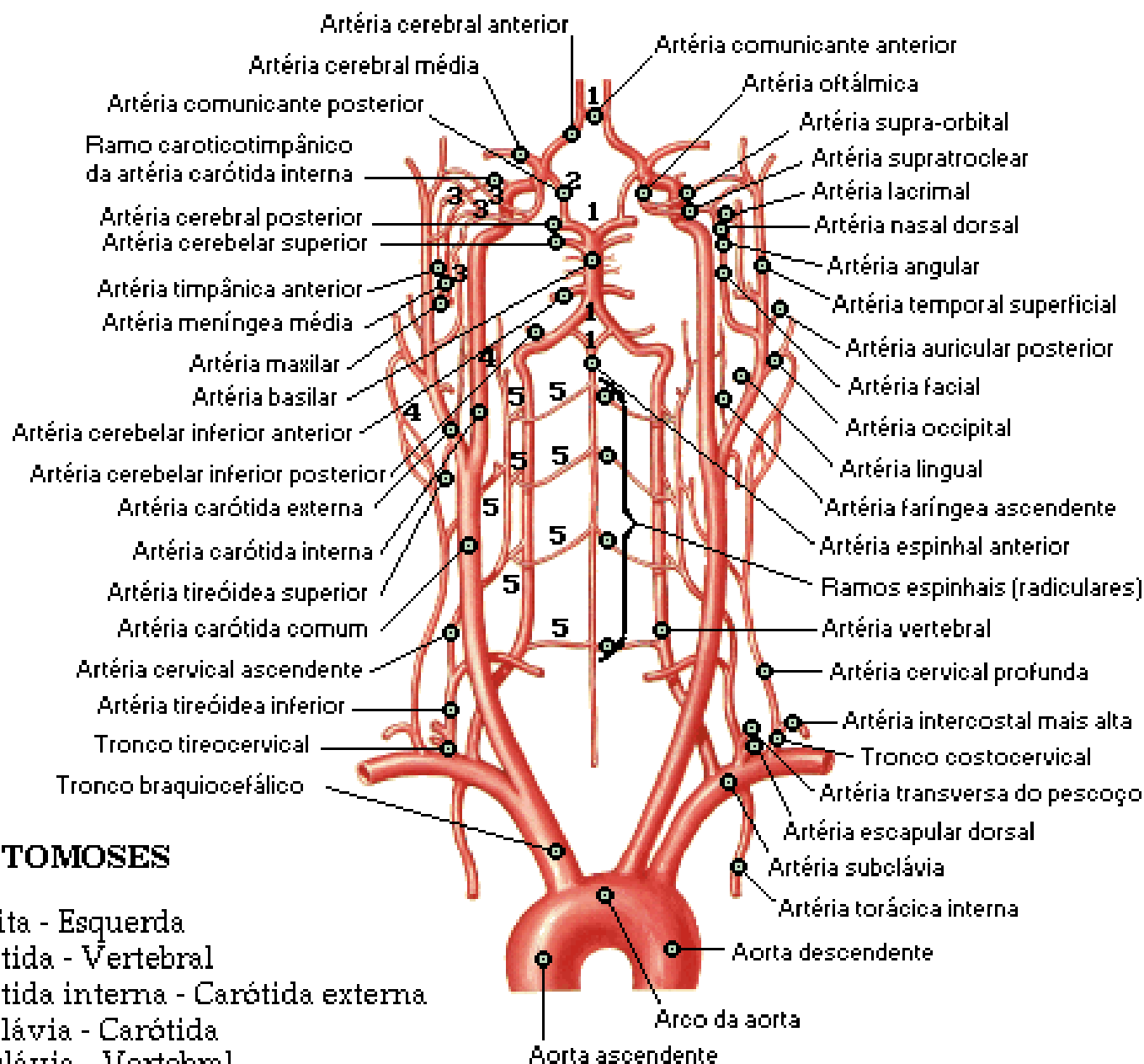


Artérias do Cérebro e Meninges



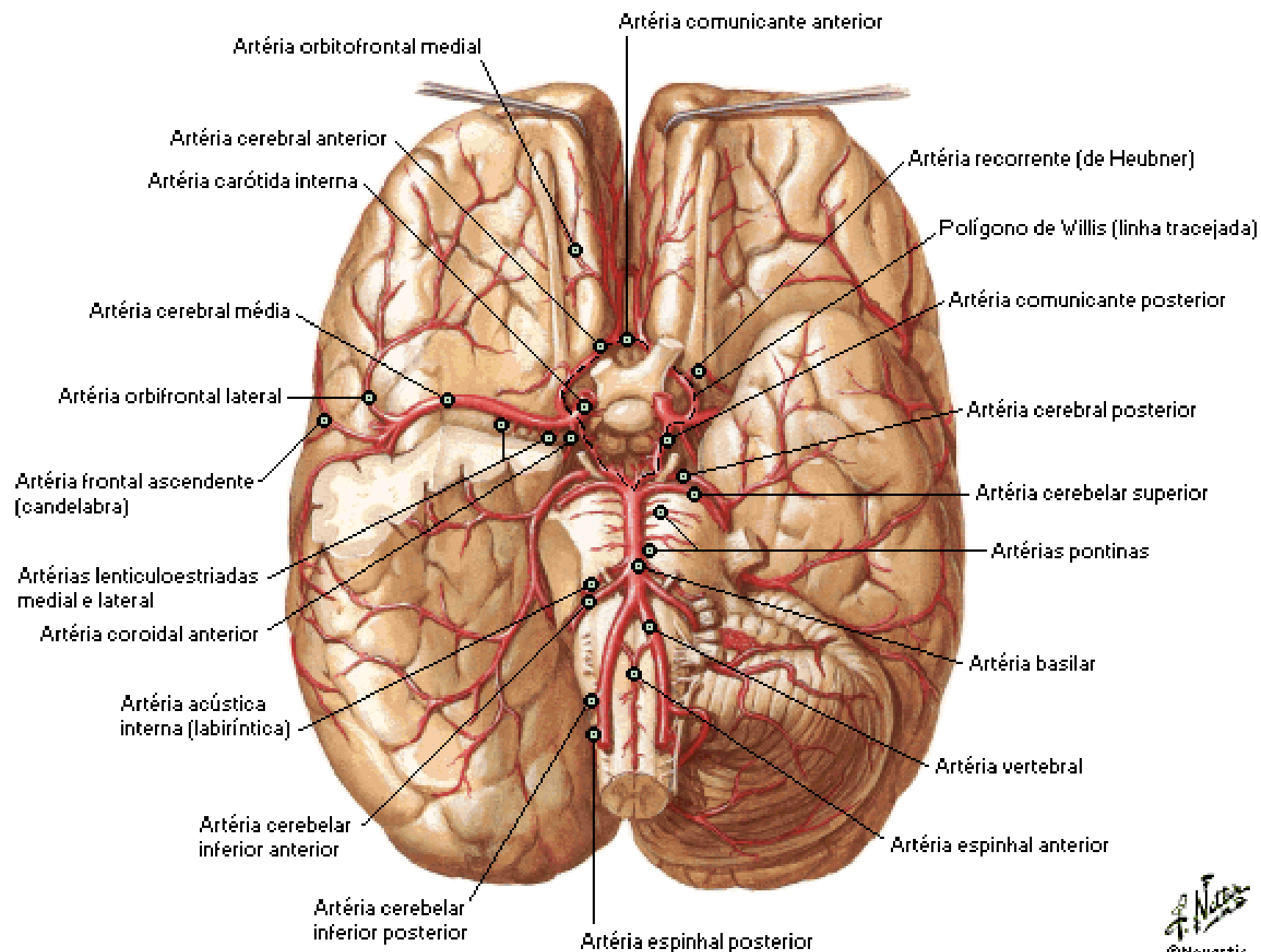
Artérias do Cérebro

Esquema



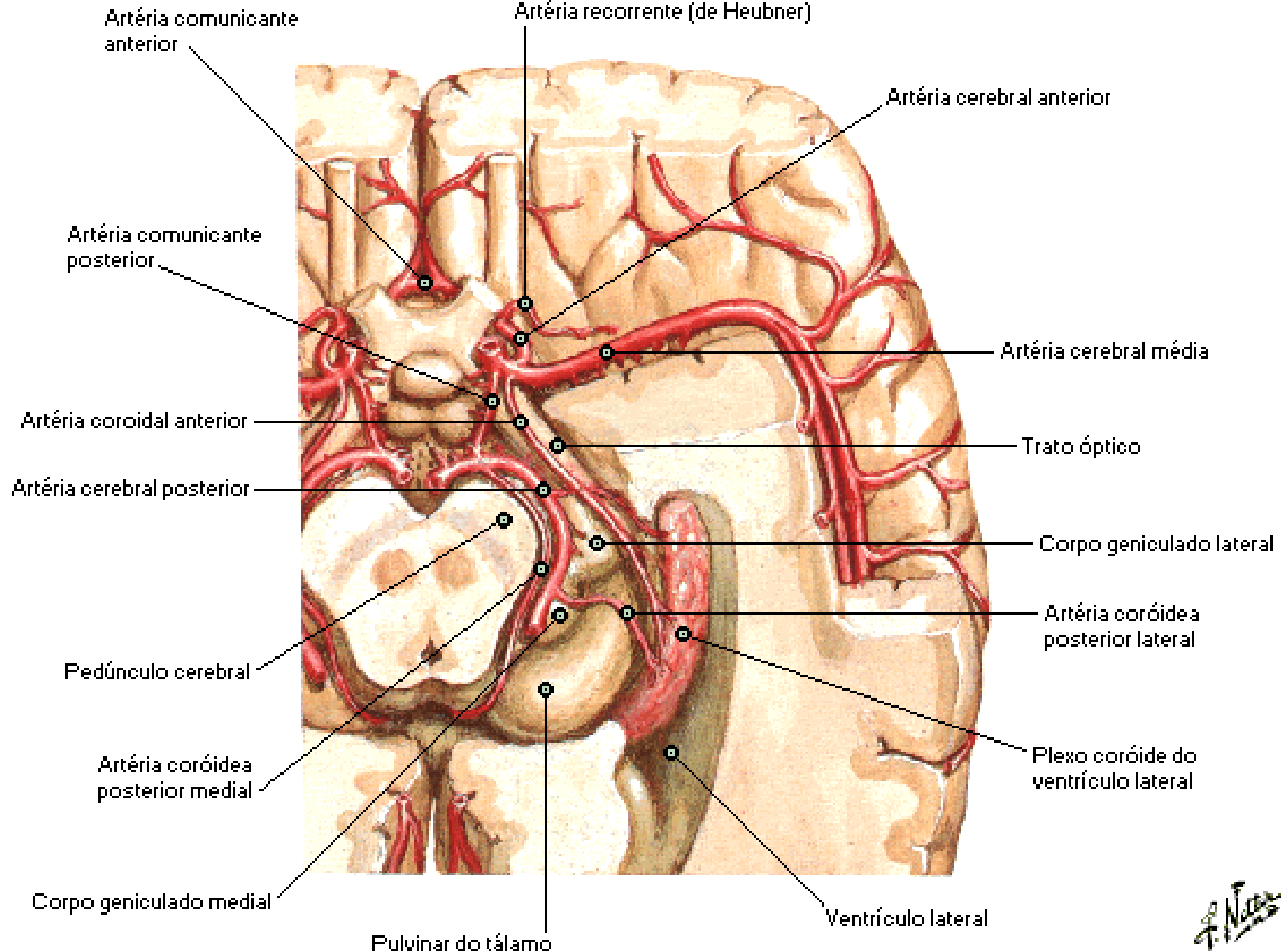
Artérias do Cérebro

Vista Inferior



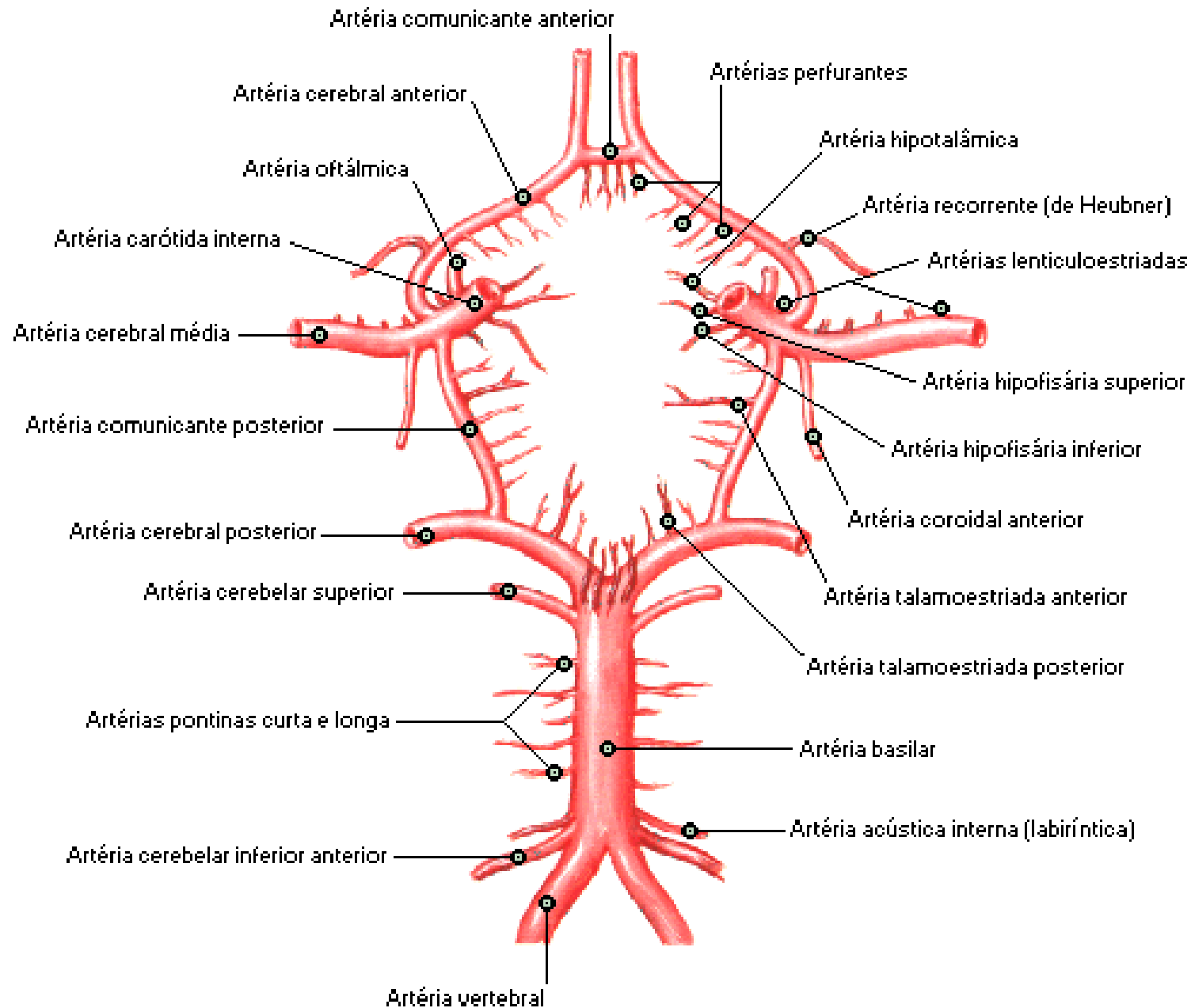
Artérias do Cérebro [Continuação]

Vista Inferior



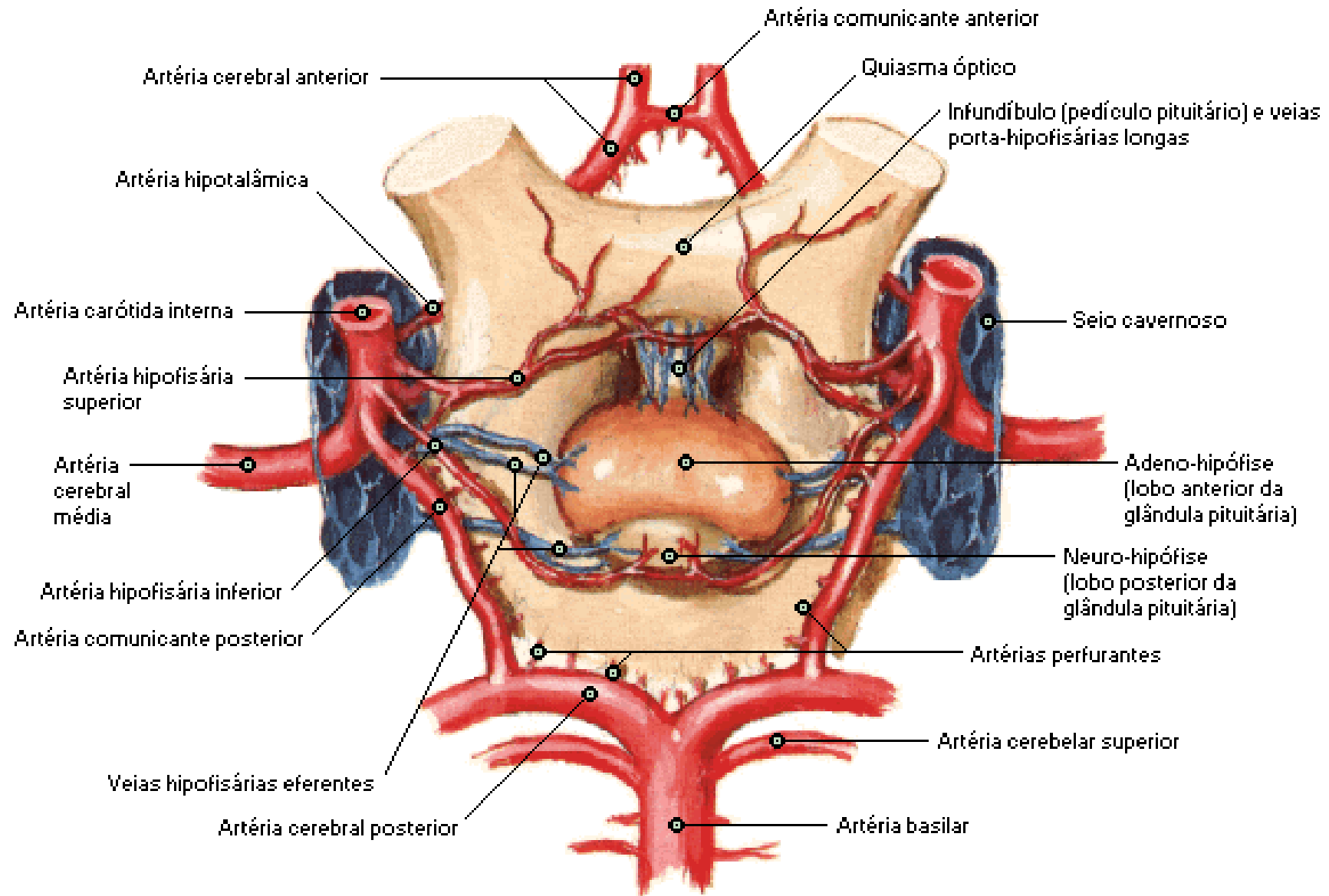
Polígono de Willis - Vasos Dissecados

Vista Inferior



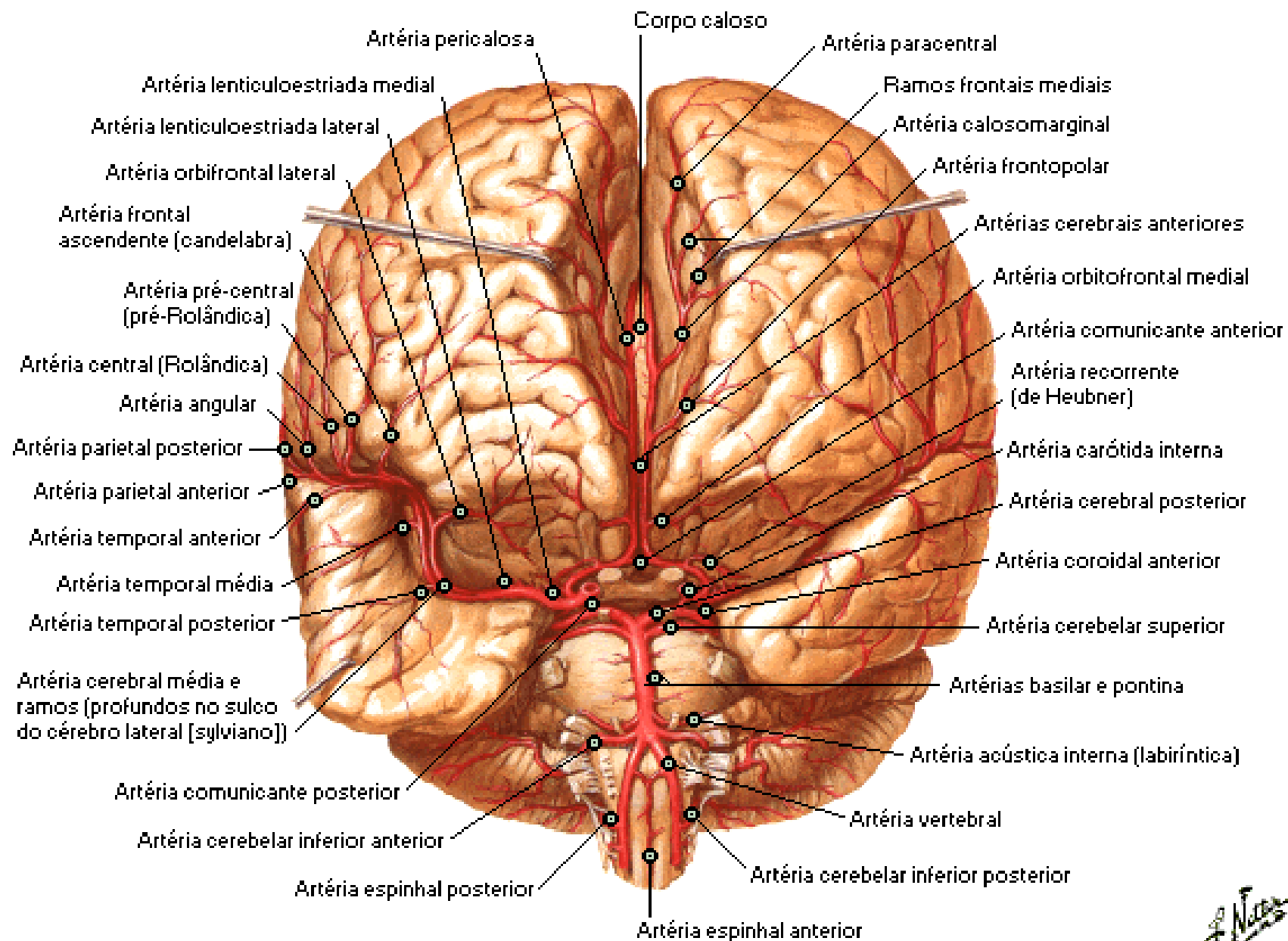
Polígono de Willis - Vasos in Situ

Vista Inferior



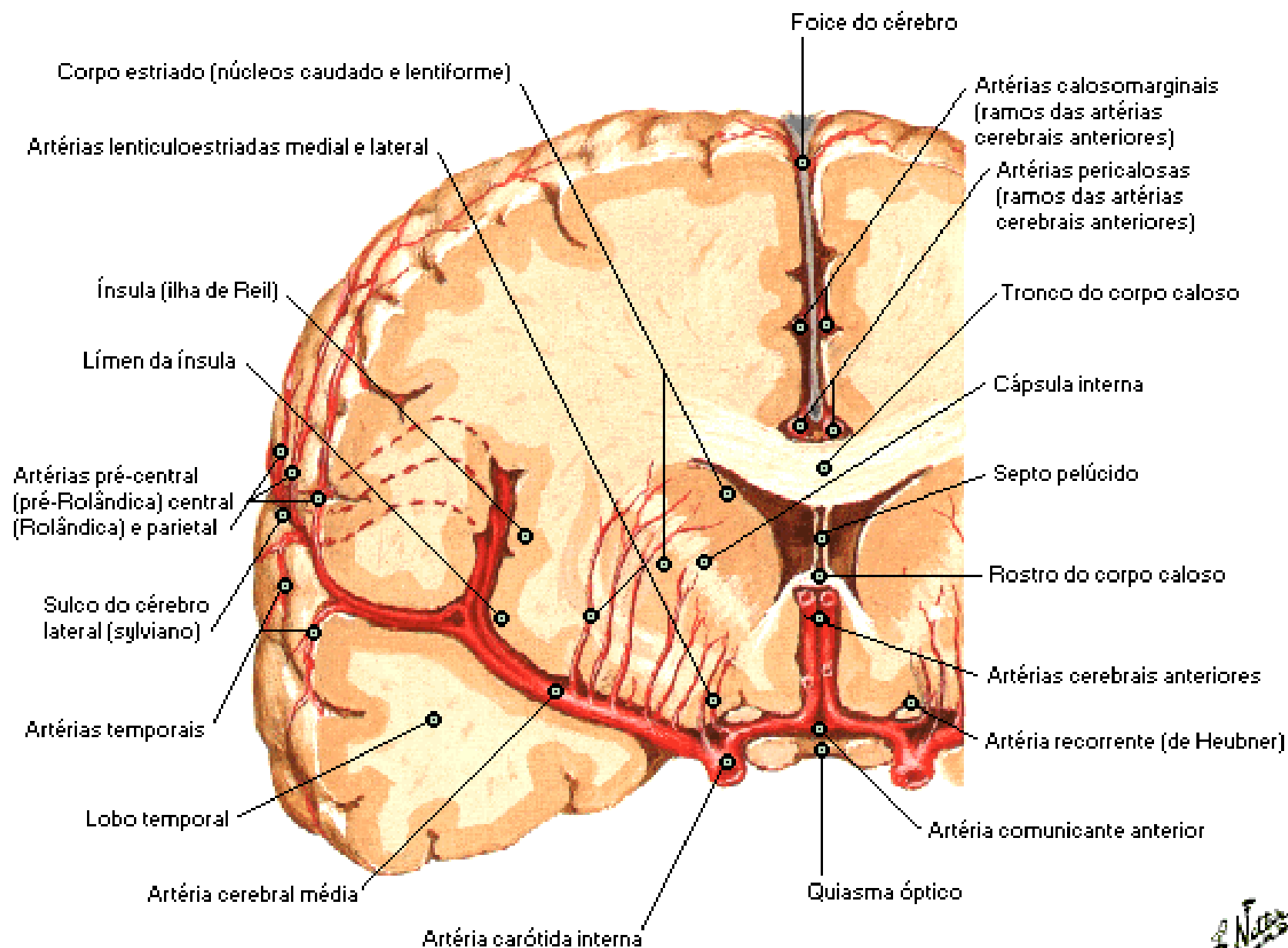
Artérias do Cérebro

Vista Frontal



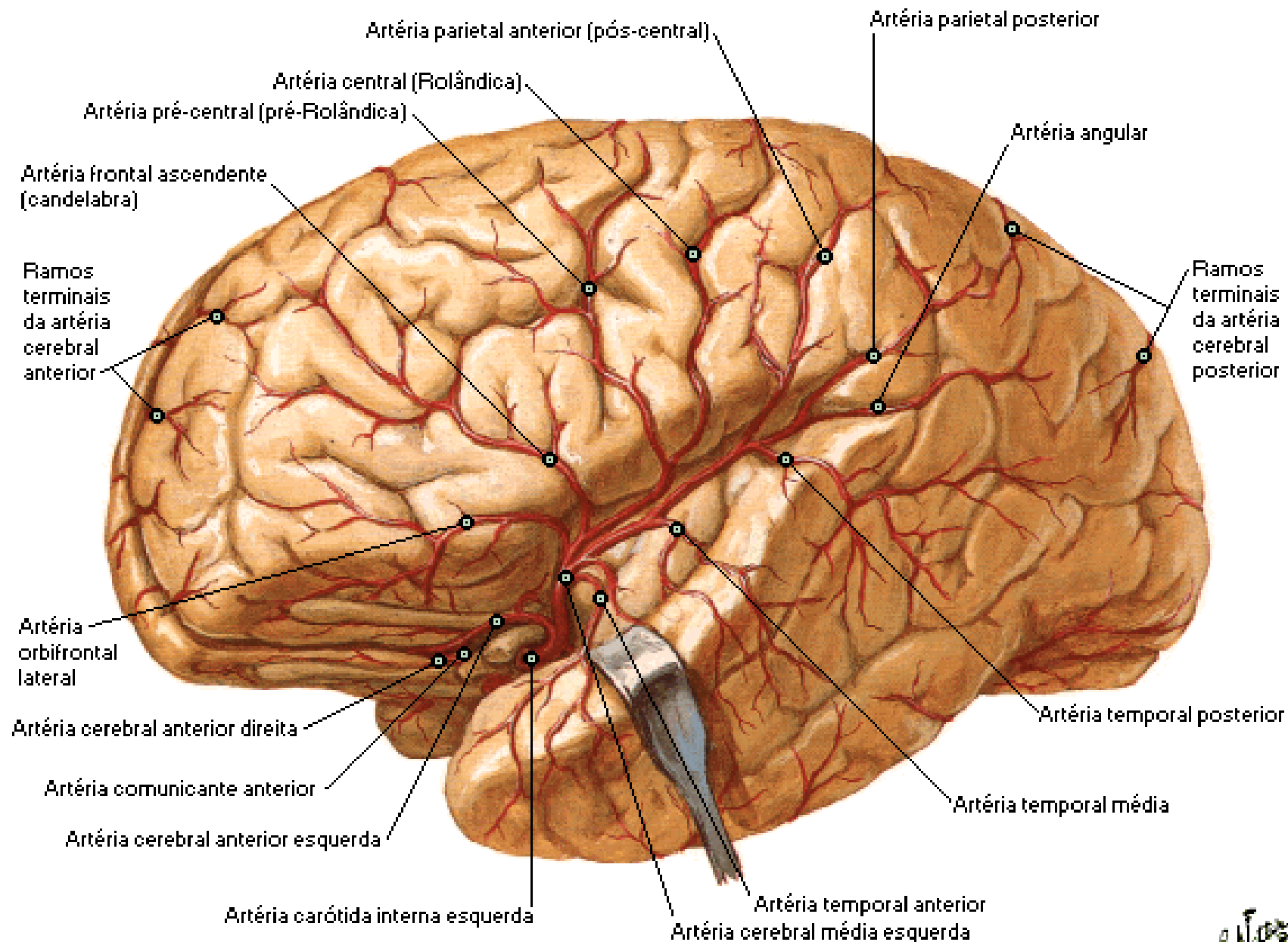
Artérias do Cérebro

Secção Frontal



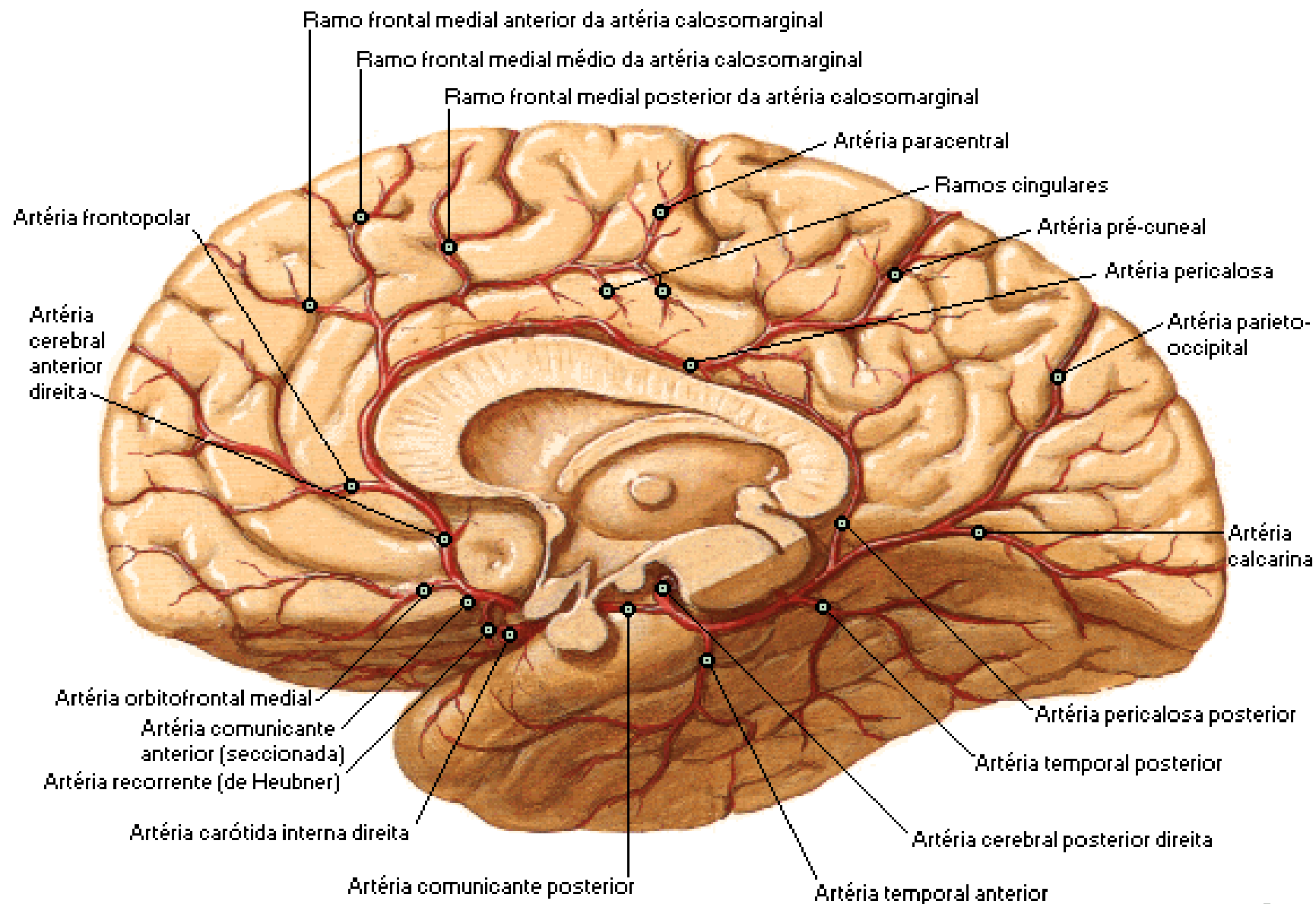
Artérias do Cérebro

Vista Lateral

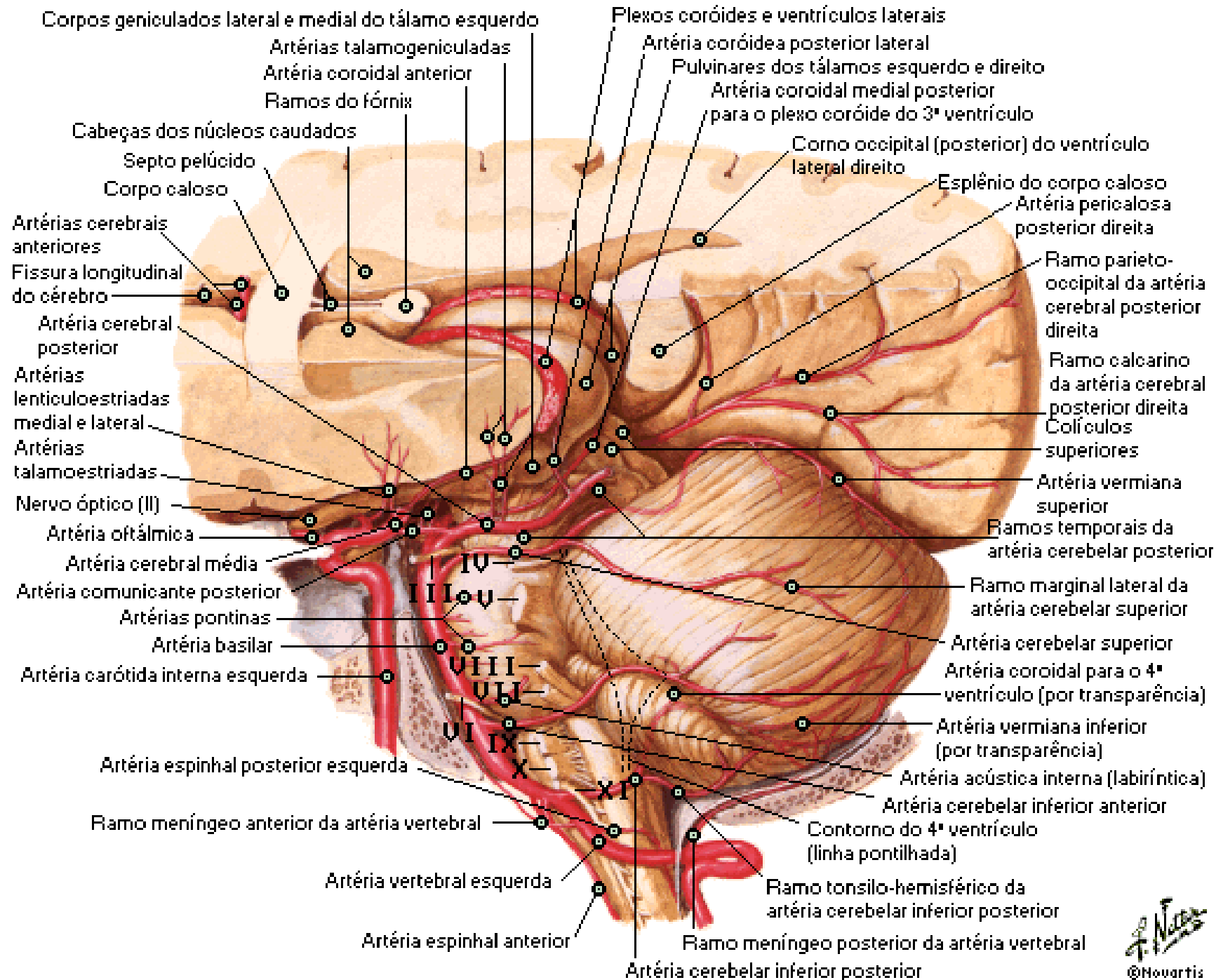


Artérias do Cérebro

Vista Medial

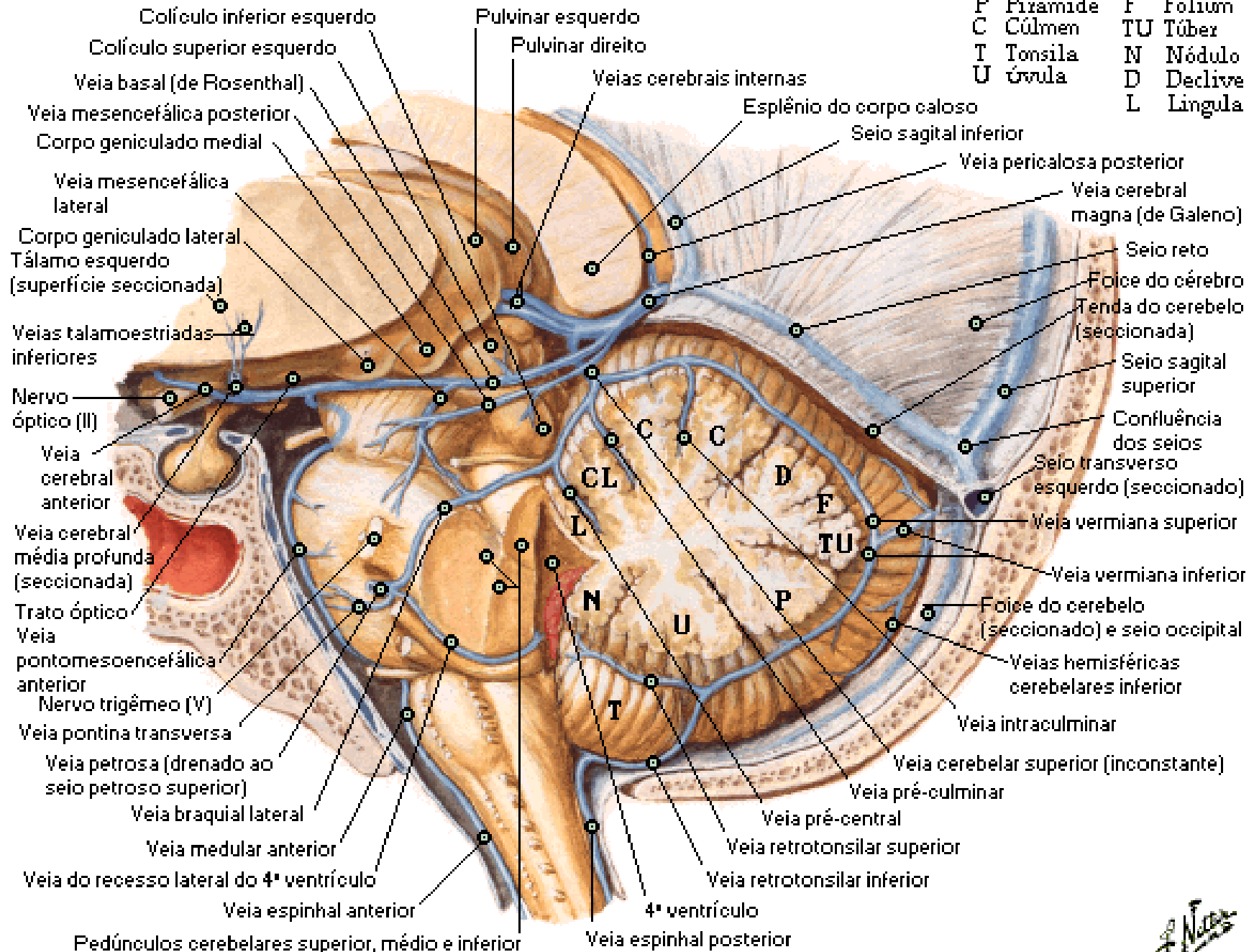


Artérias da Fossa Crânica Posterior



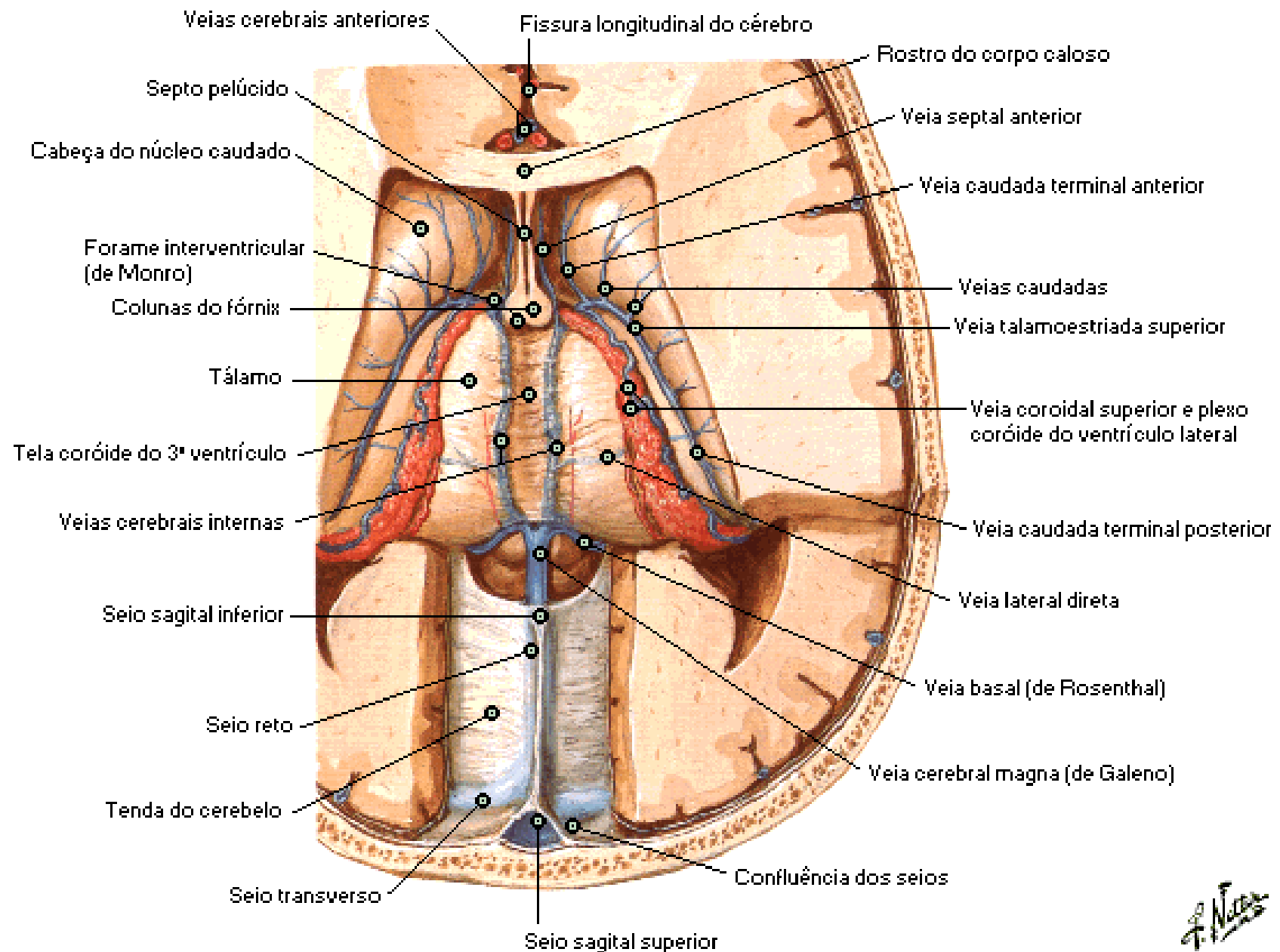
Veias da Fossa Crânica Posterior

Partes do cerebelo			
CL	Lóbulo central		
P	Pirâmide	F	Folium
C	Cúlmen	TU	Tóber
T	Tonsila	N	Nódulo
U	Úvula	D	Declive
		L	Lingula



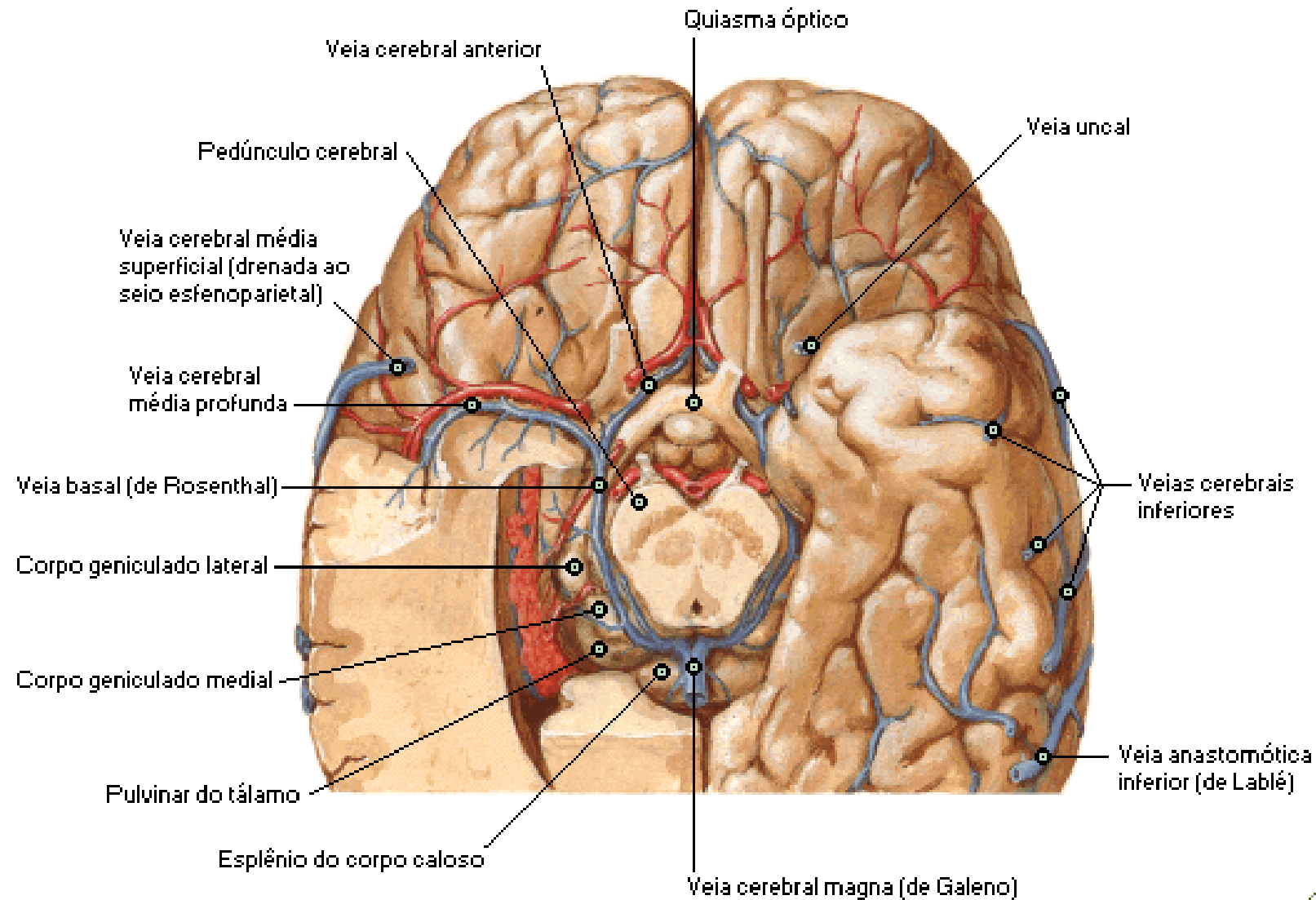
Veias Profundas do Cérebro

Vista Superior



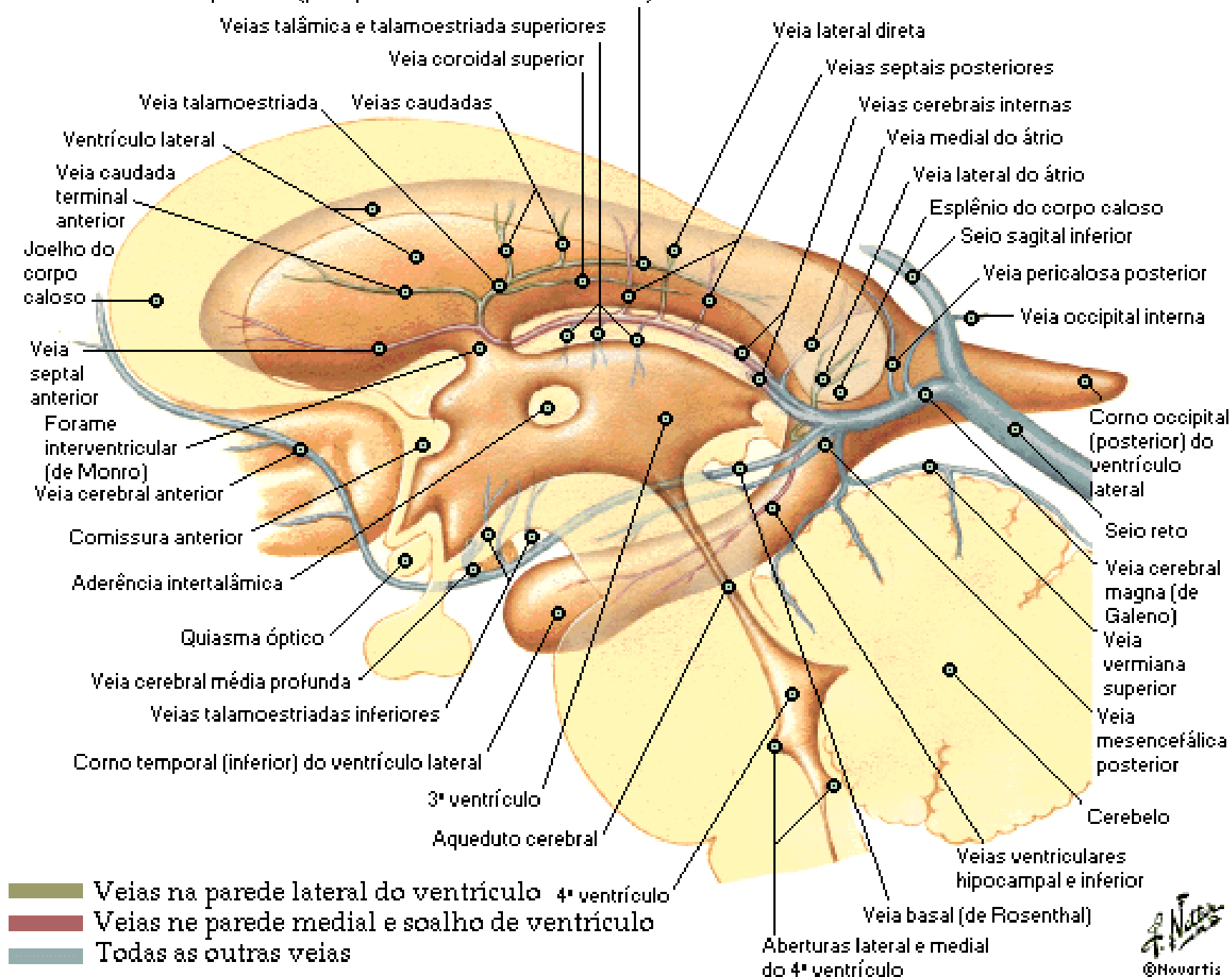
Veias Profundas do Cérebro

Vista Inferior

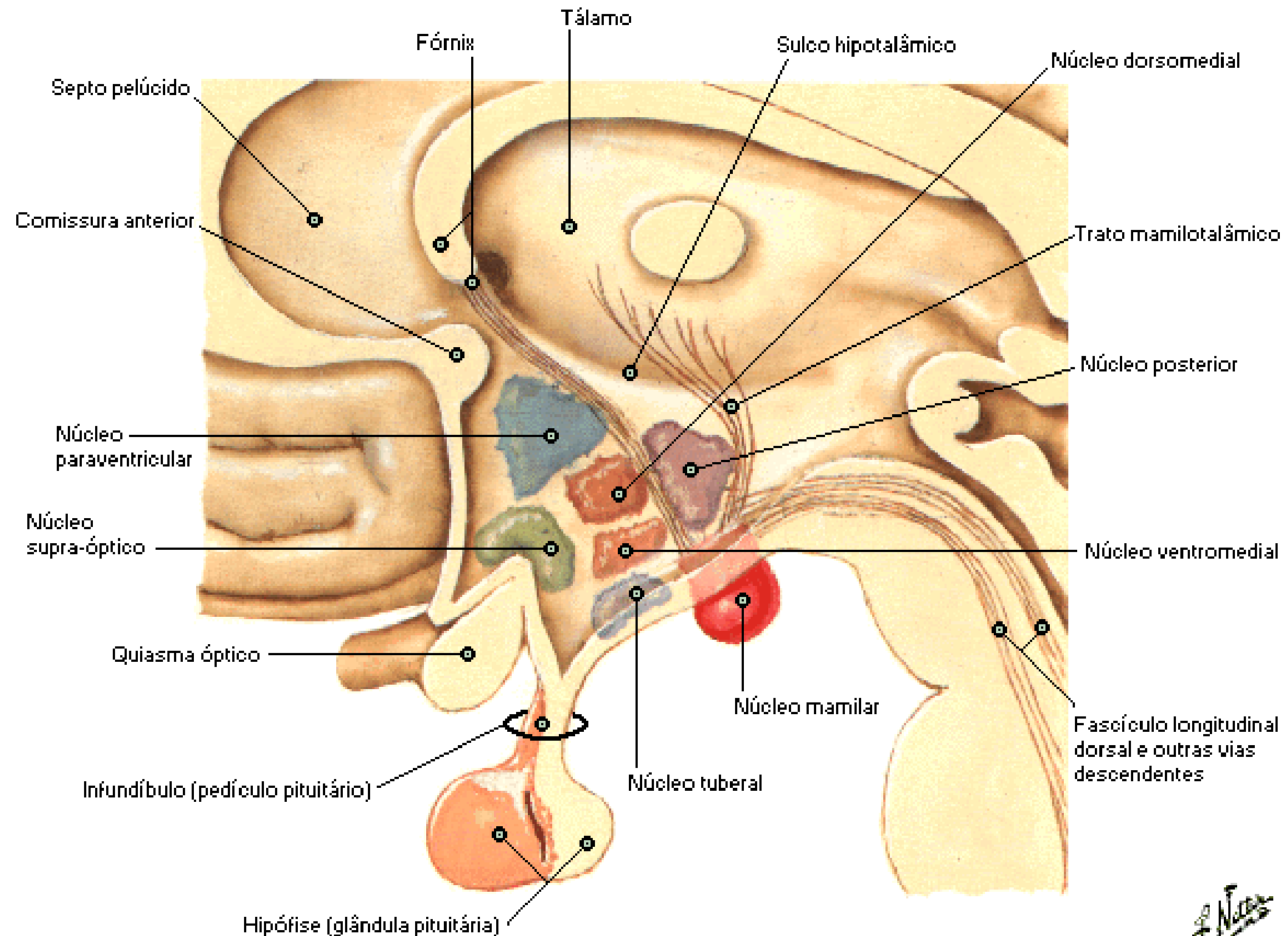


Veias Subependimárias do Cérebro

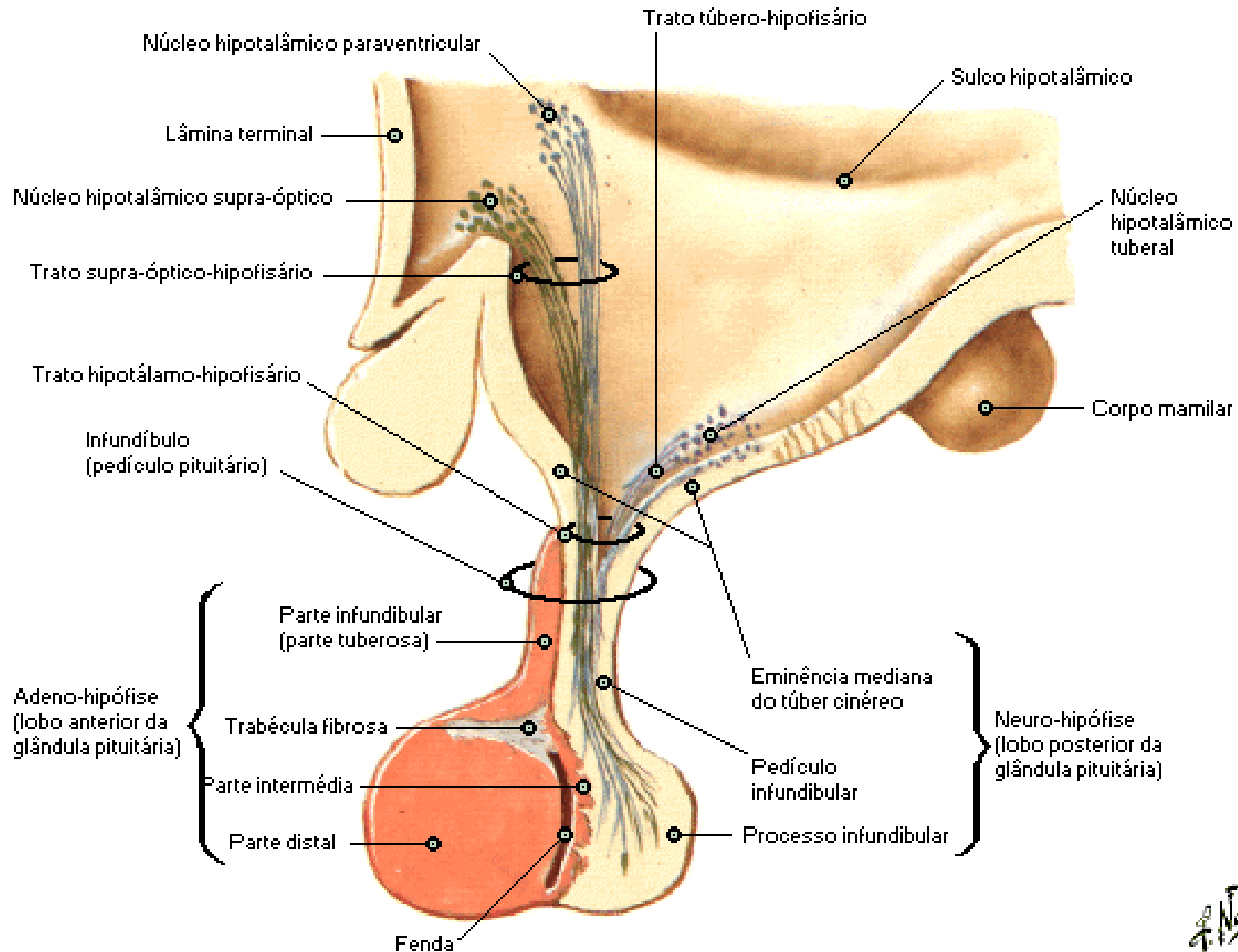
Veia caudada terminal posterior (parte posterior da veia talamoestriada)



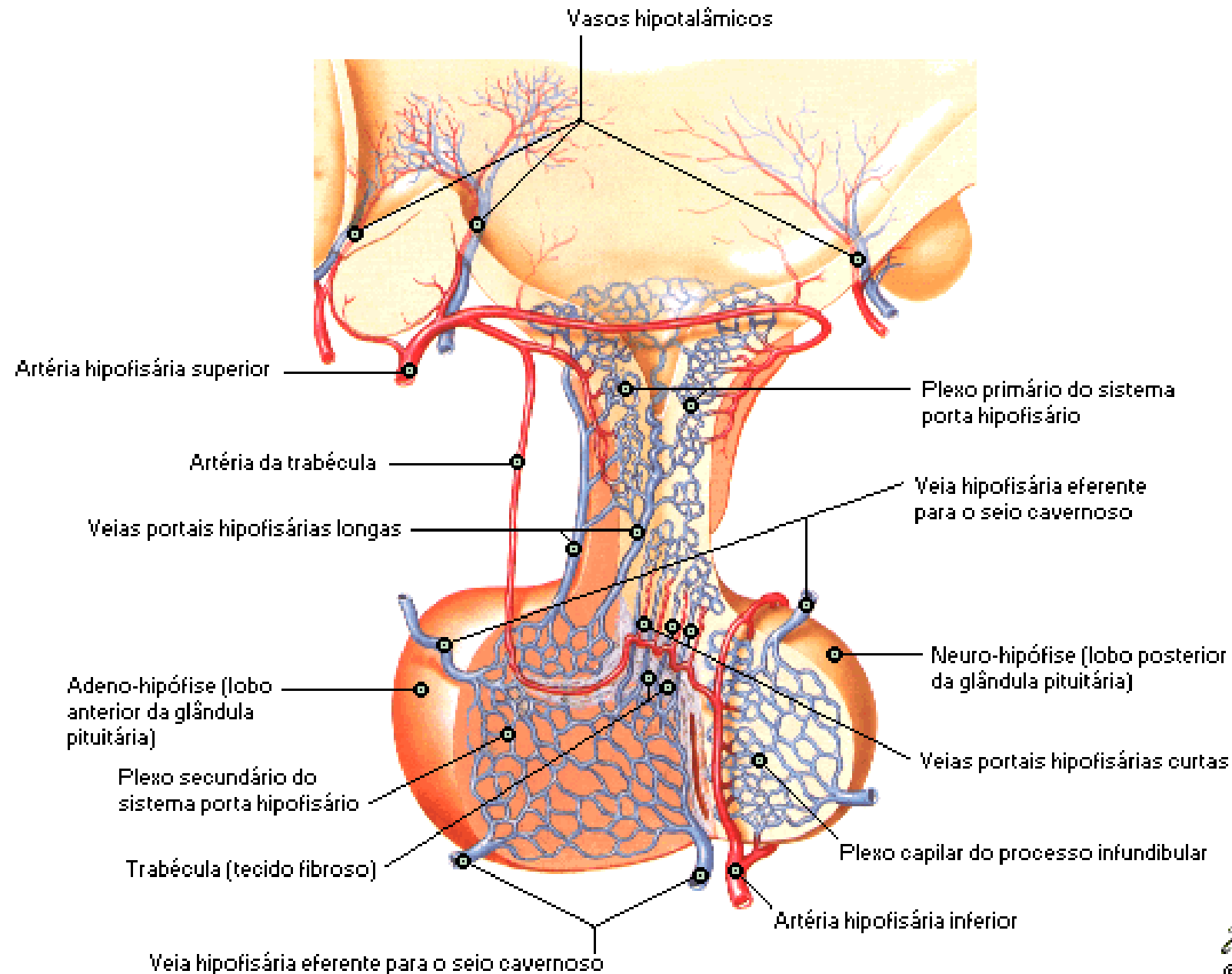
Hipotálamo - Núcleos Principais



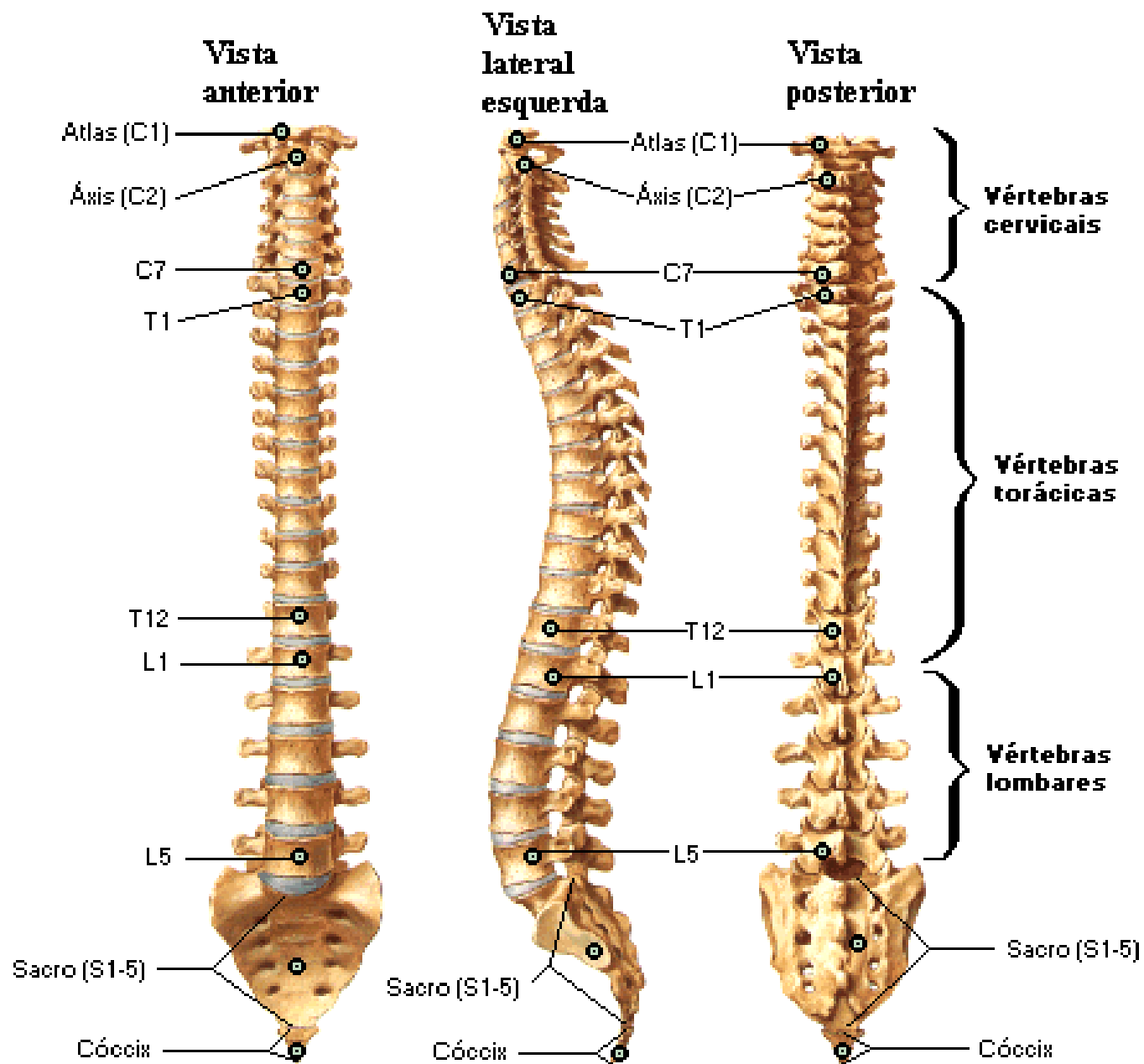
Adeno-hipófise e Neuro-hipófise



Artérias e Veias do Hipotálamo e Hipófise

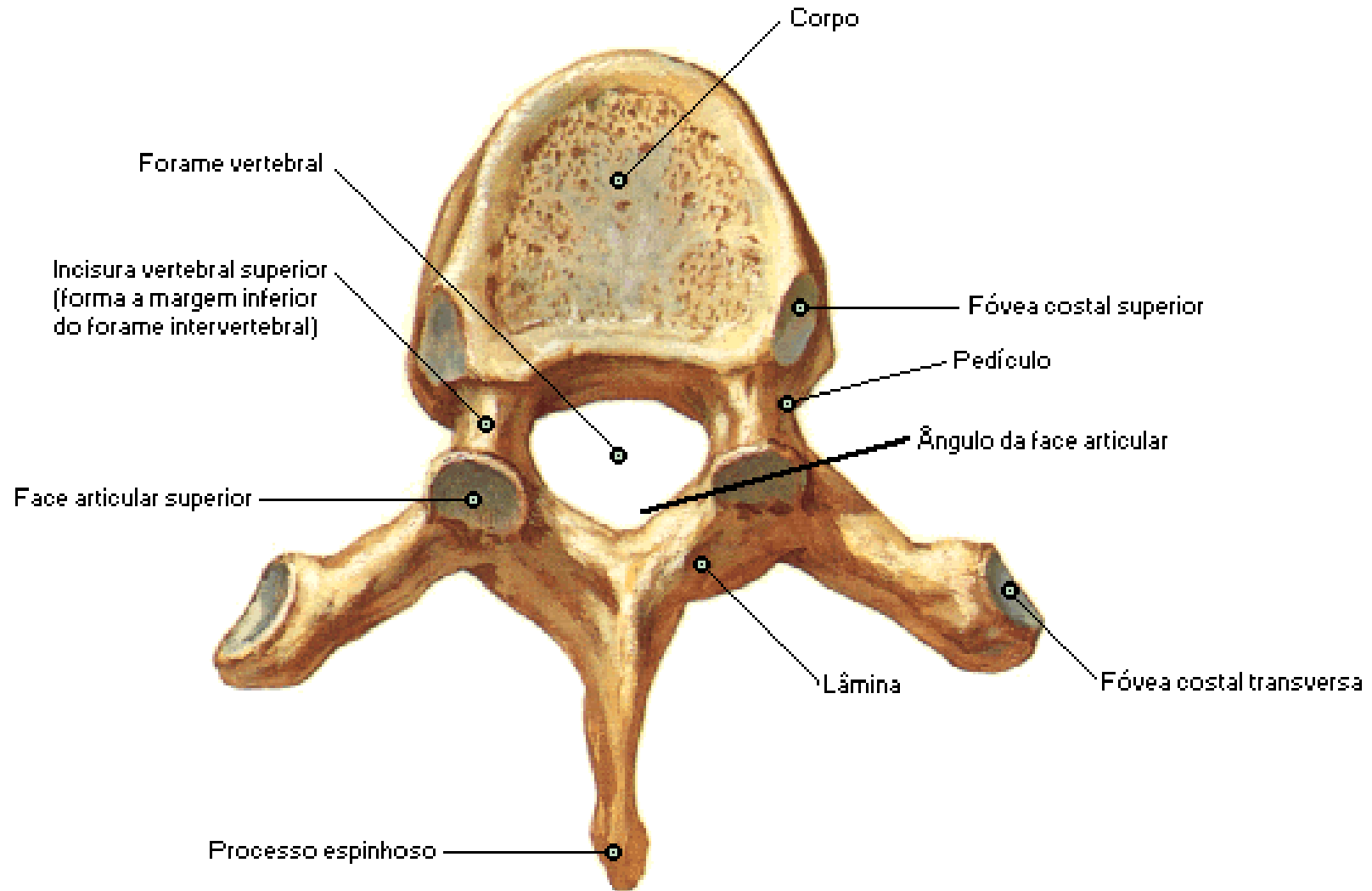


Coluna Vertebral



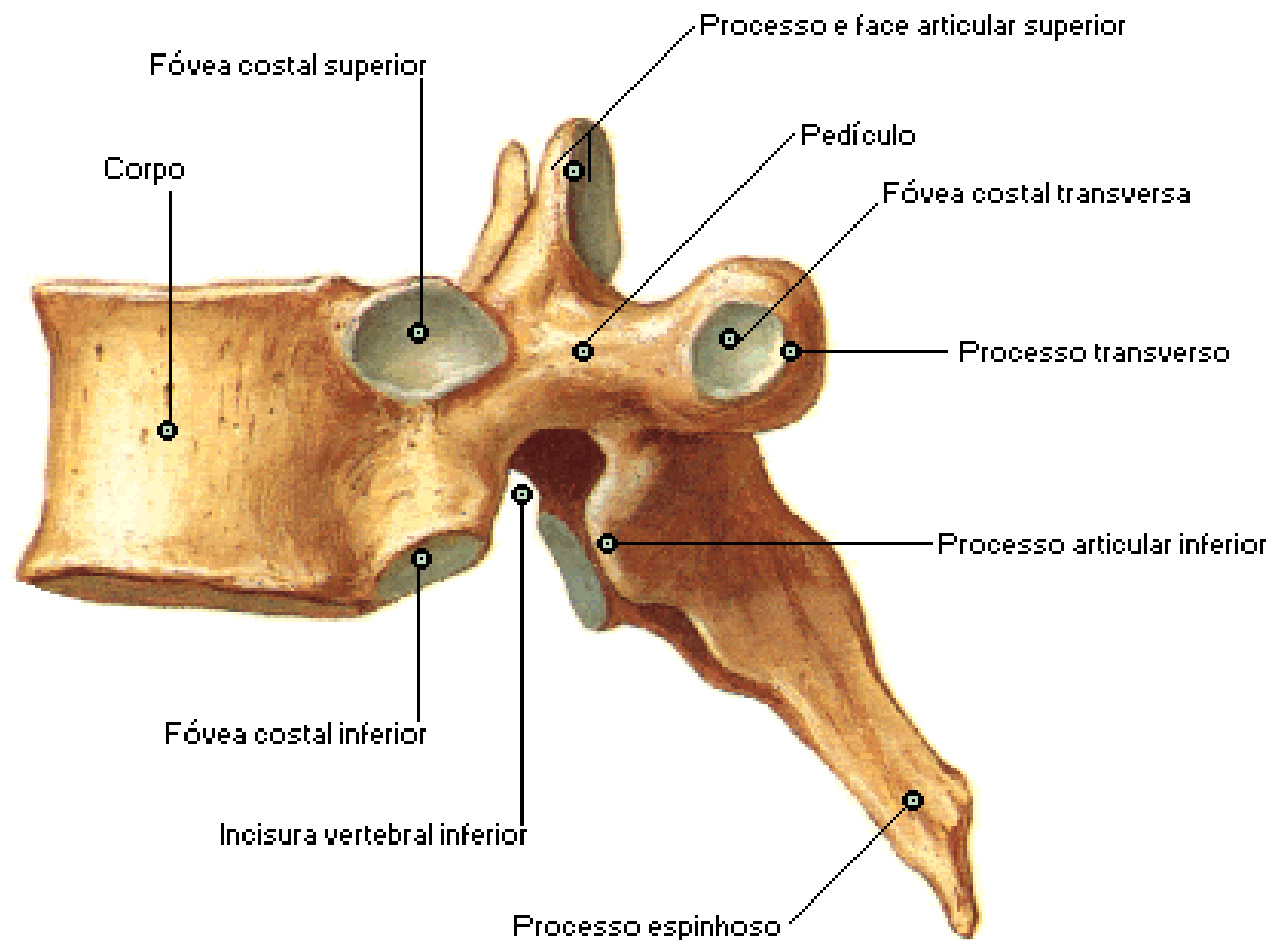
Vértebras Torácicas [T6]

Vista Superior



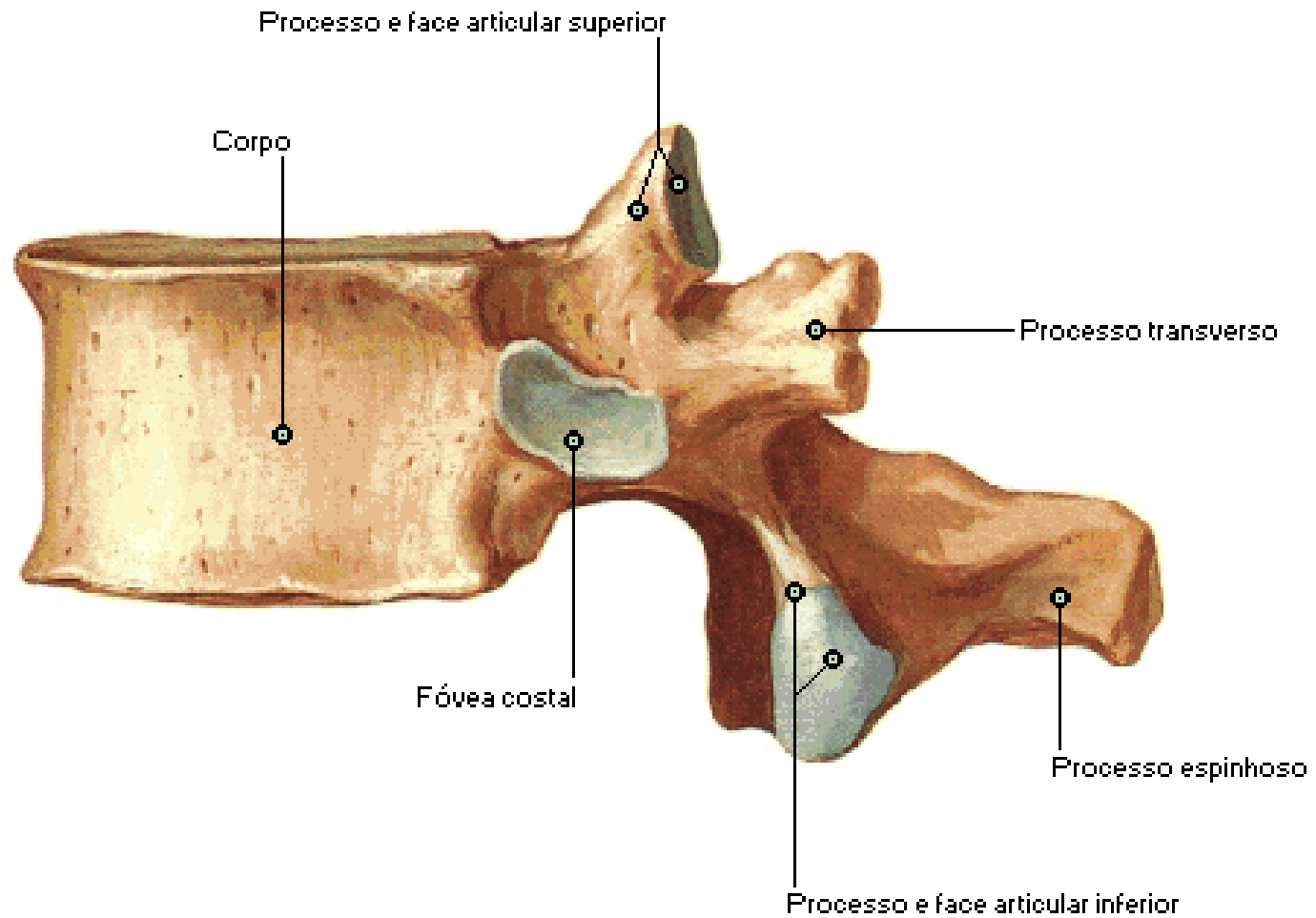
Vértebra Torácica [T6]

Vista Lateral



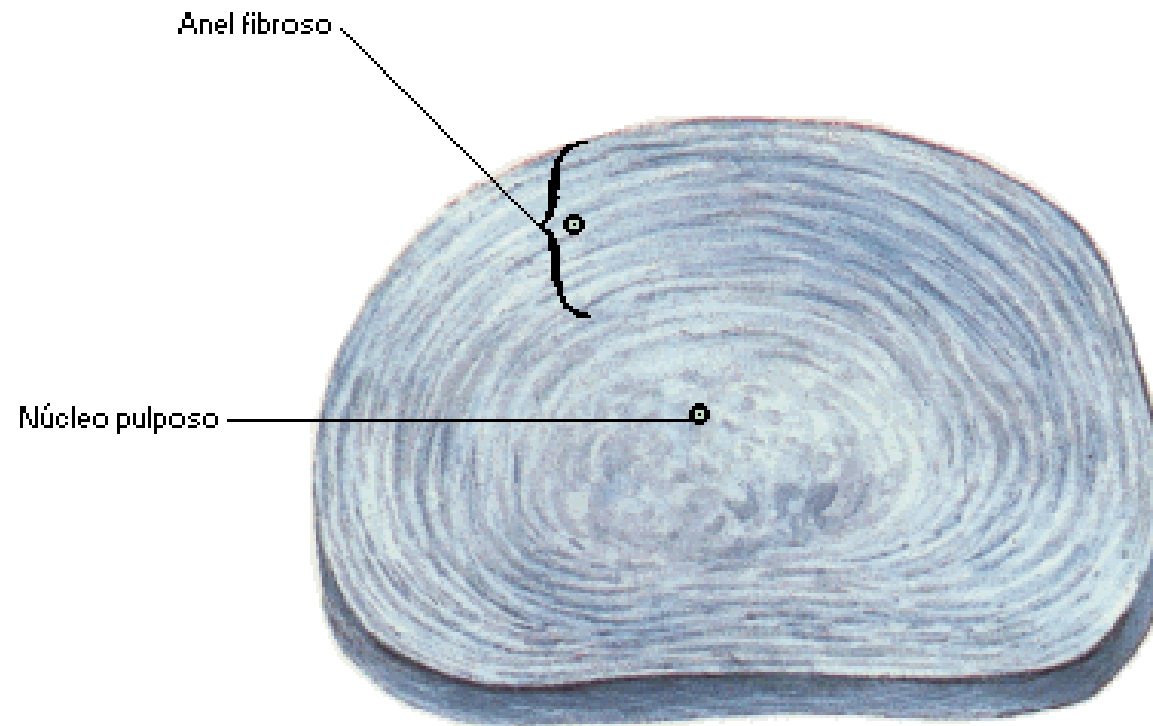
Vértebra Torácica [T12]

Vista Lateral



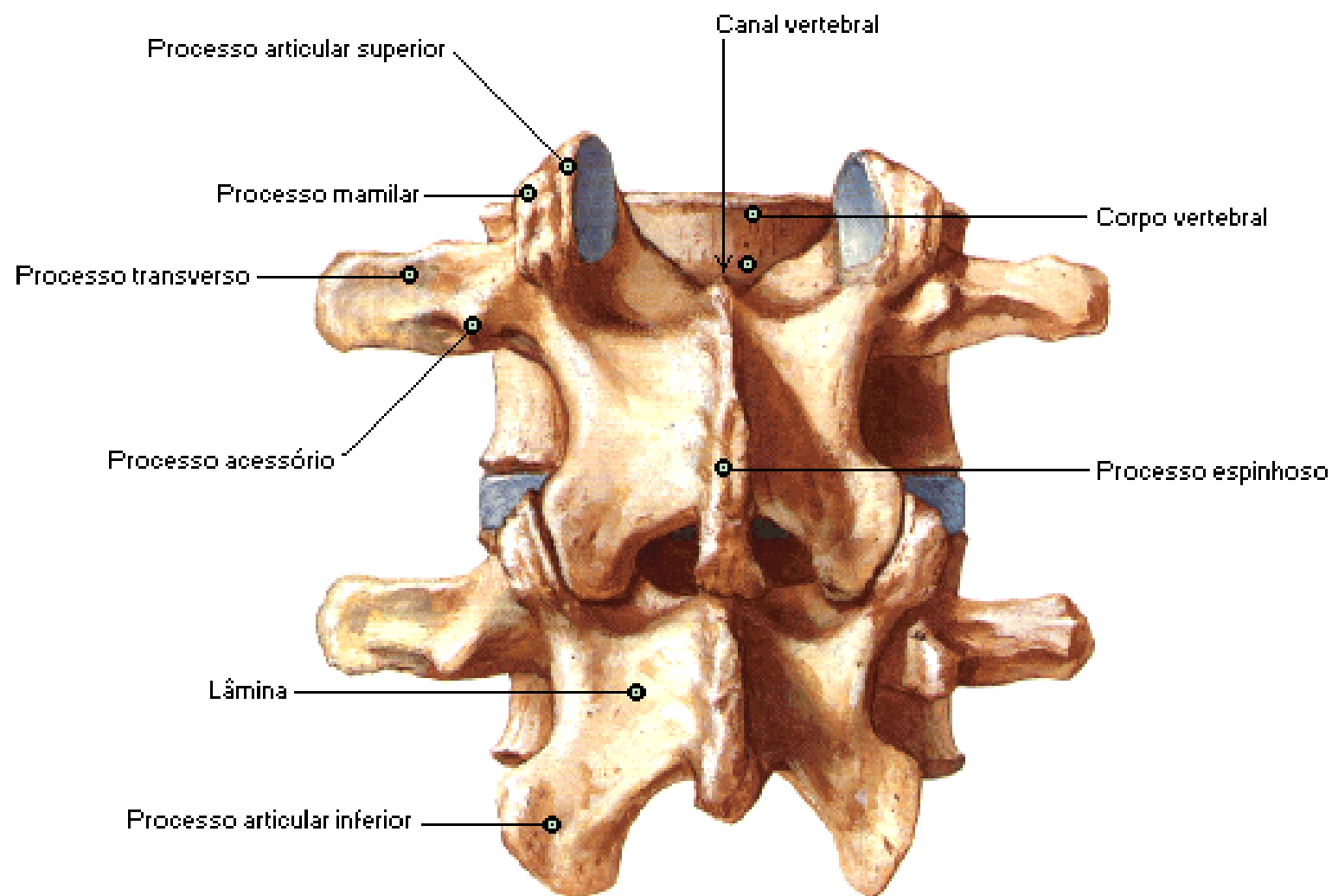
Vértabras Lumbares

Disco Intervertebral



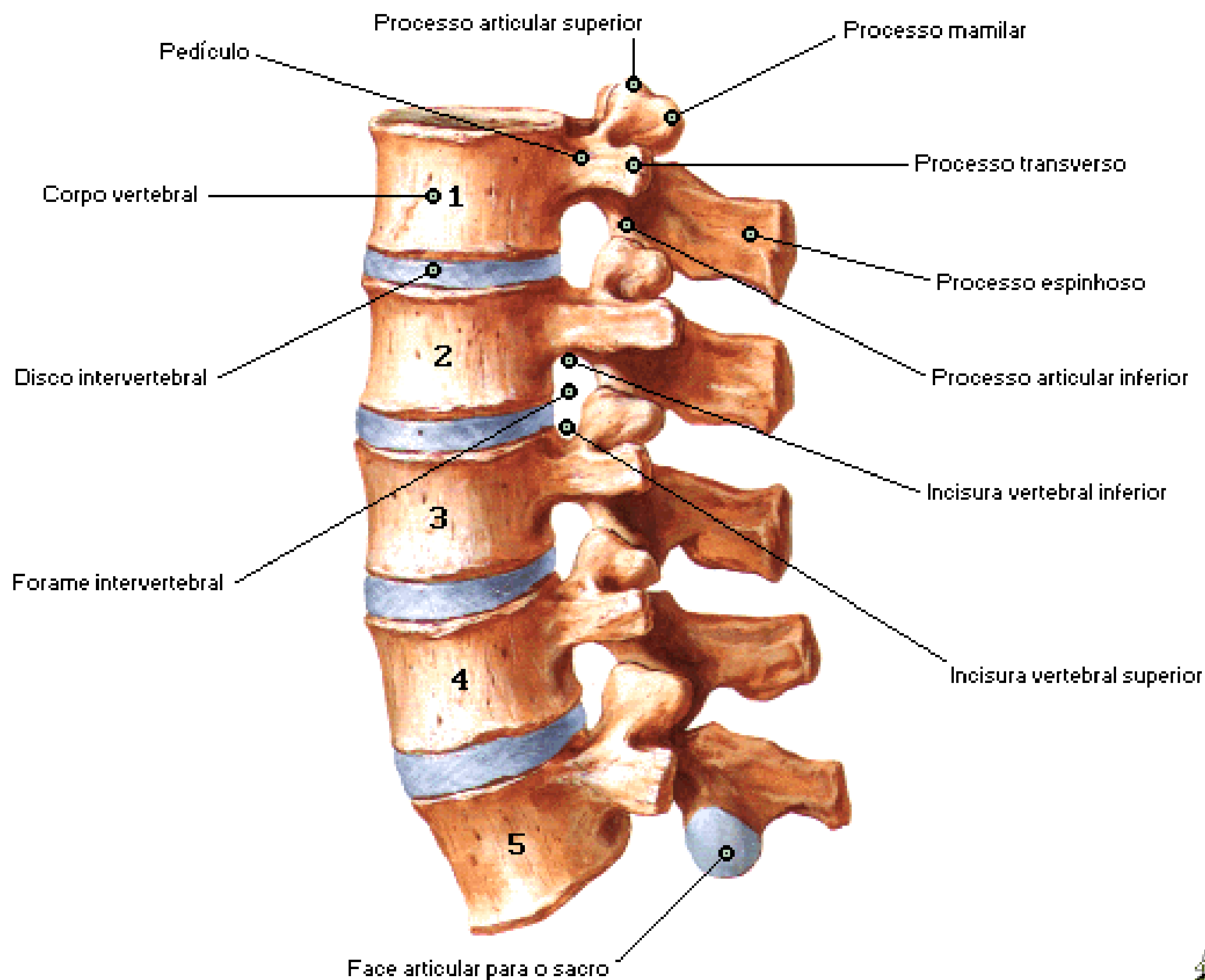
3ª e 4ª Vértebras Lombares

Vista Posterior



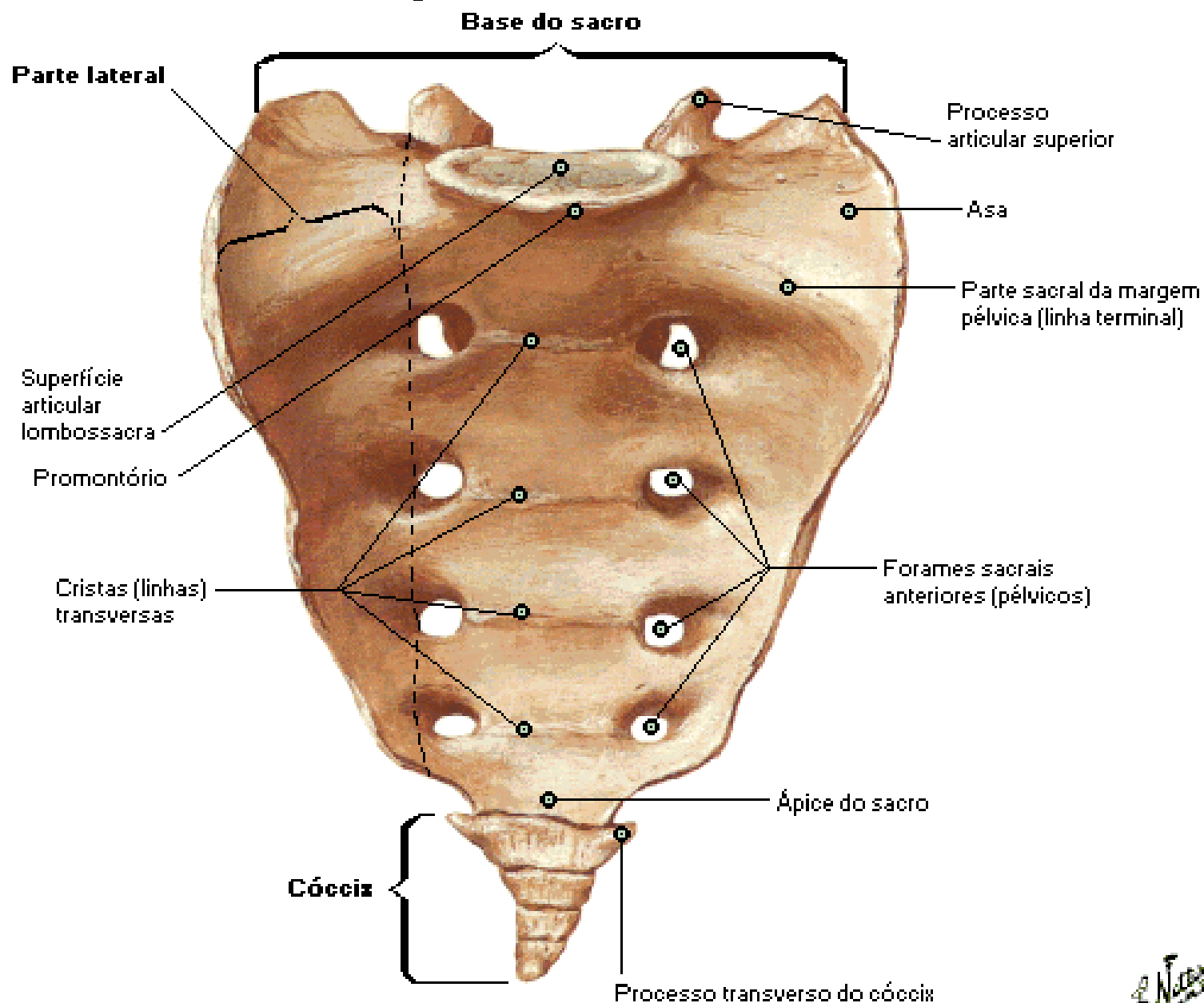
Vértebras Lombares - Articuladas

Vista Lateral Esquerda



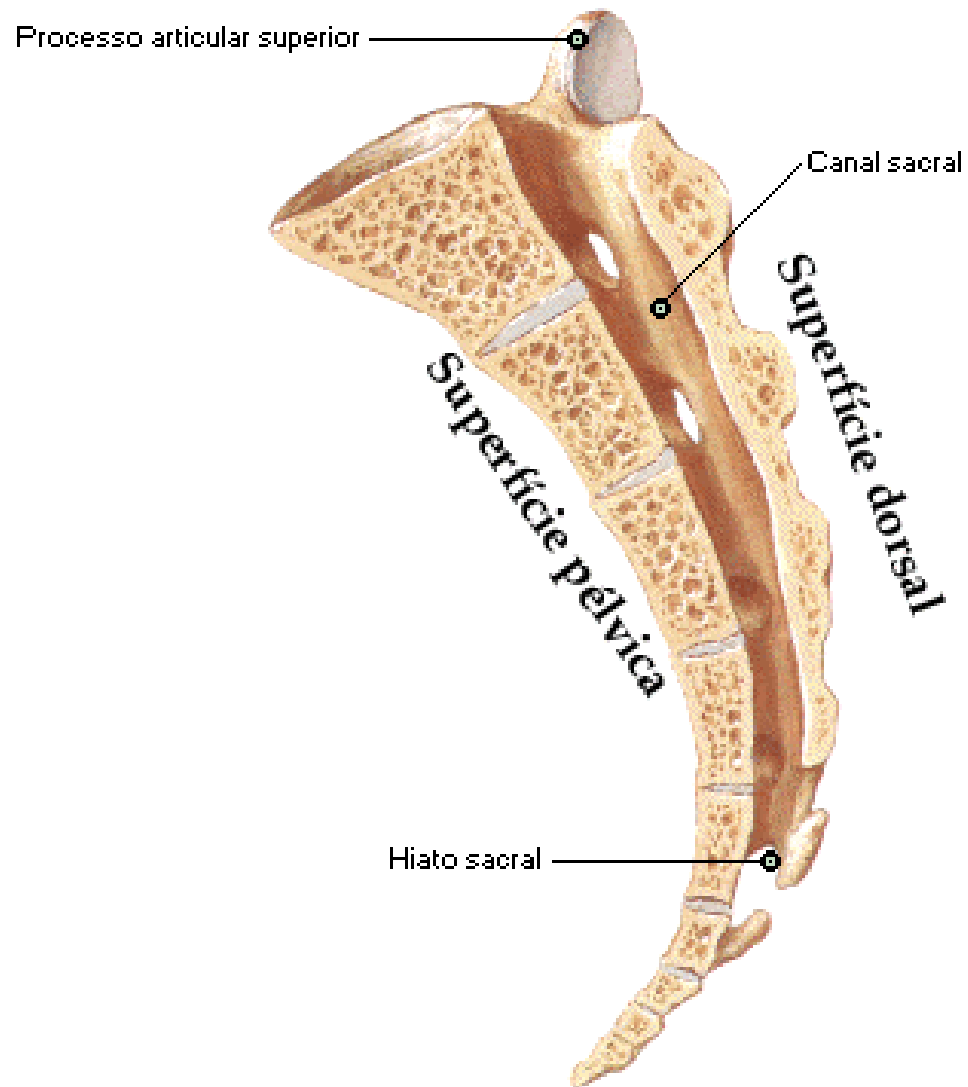
Sacro e Cóccix

Superfície Pélvica



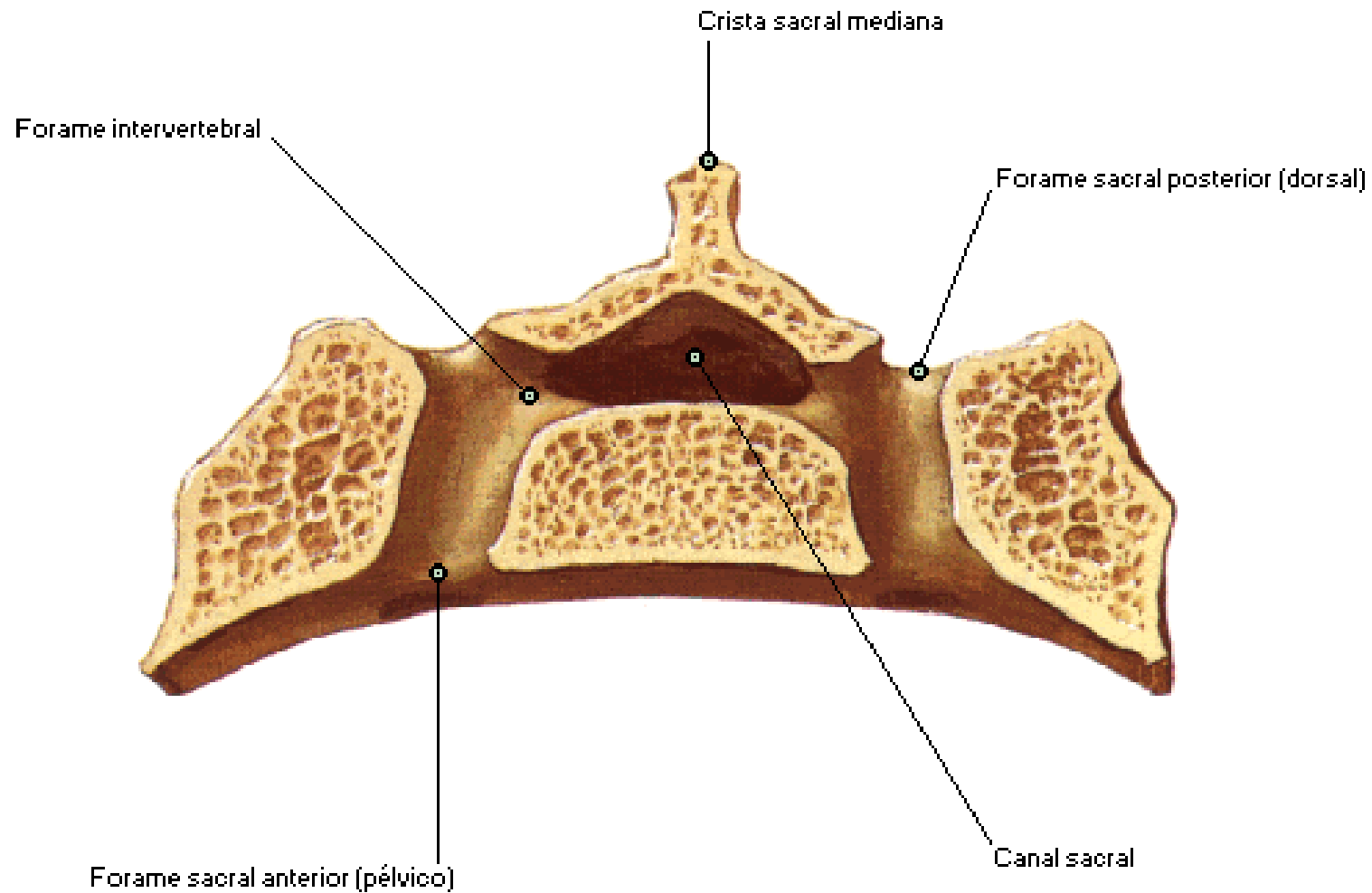
Sacro e Cóccix

Secção Sagital Mediana



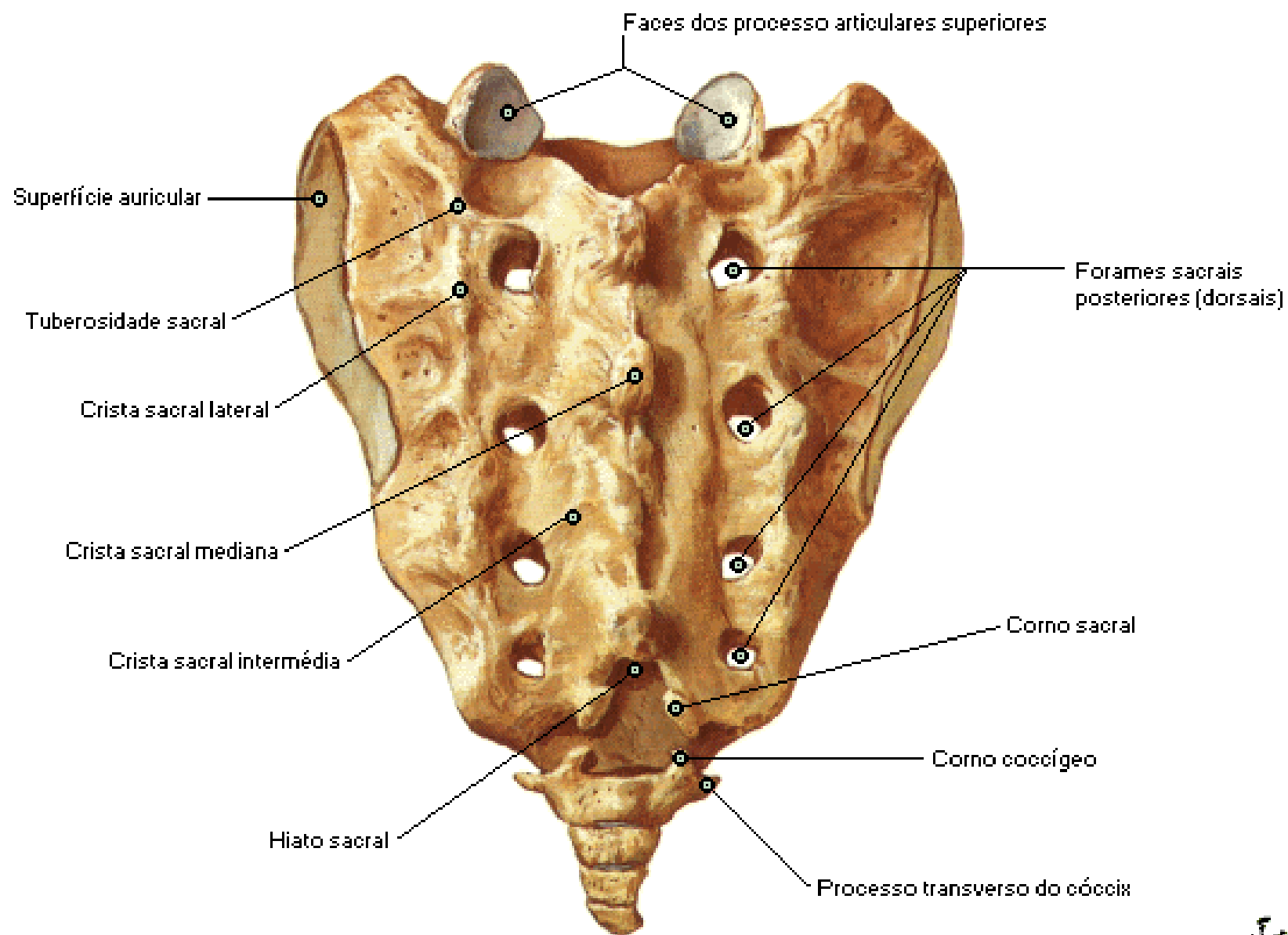
Sacro

Secção Transversal Através dos Forames de S1



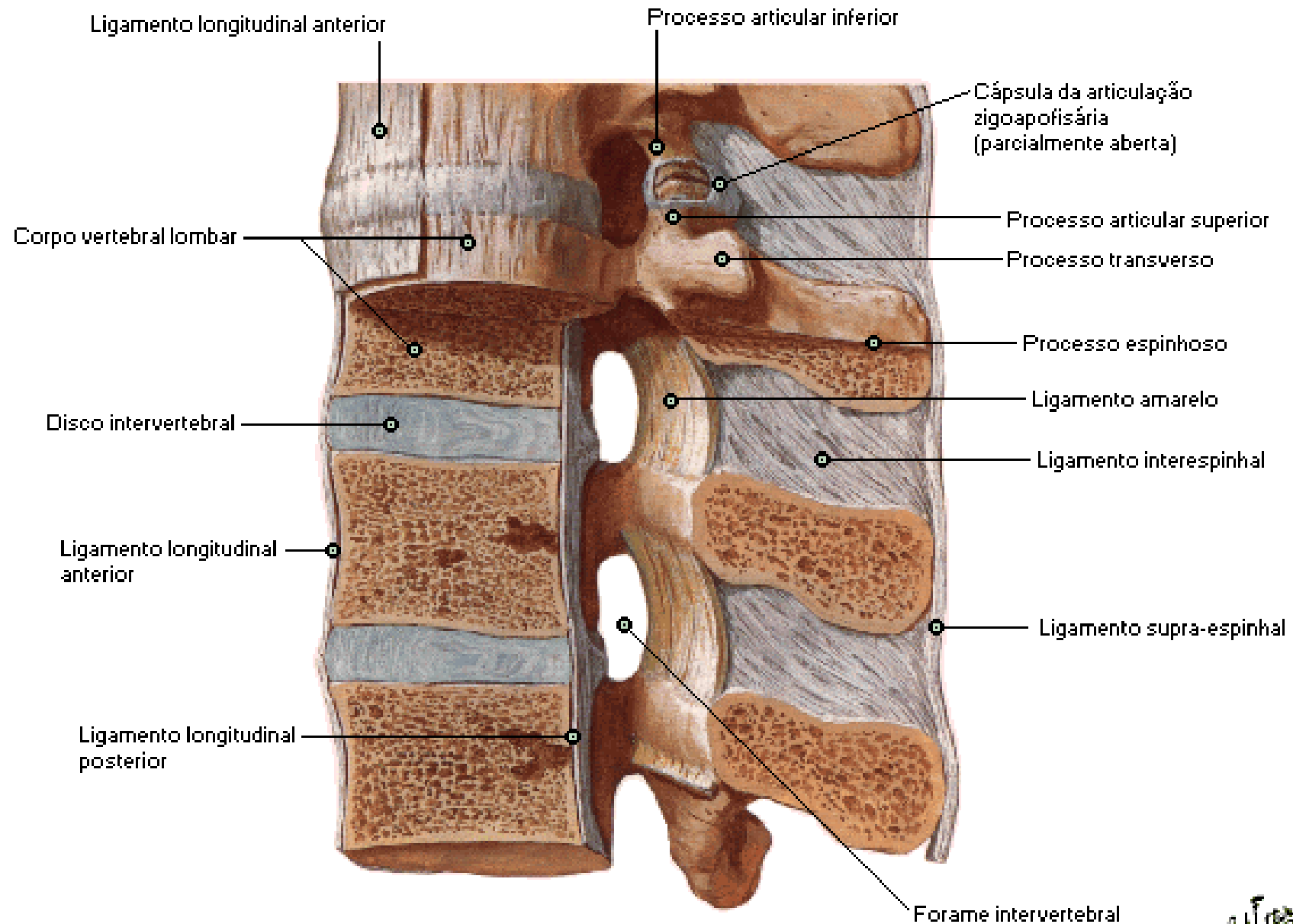
Sacro e Cóccix

Superfície Dorsal



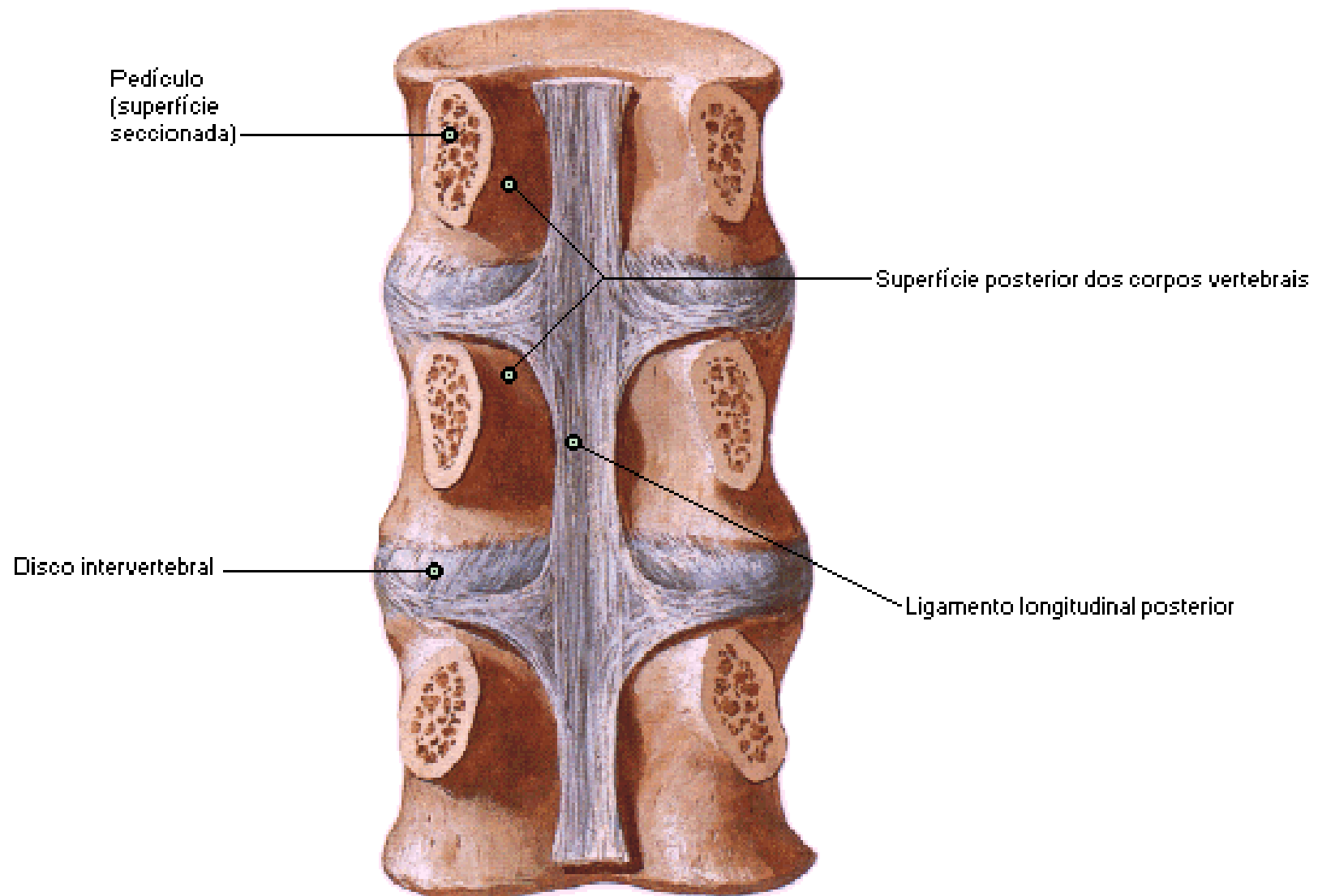
Ligamentos Vertebrais da Região Lombar

Vista Lateral Esquerda [Parcialmente Seccionada]



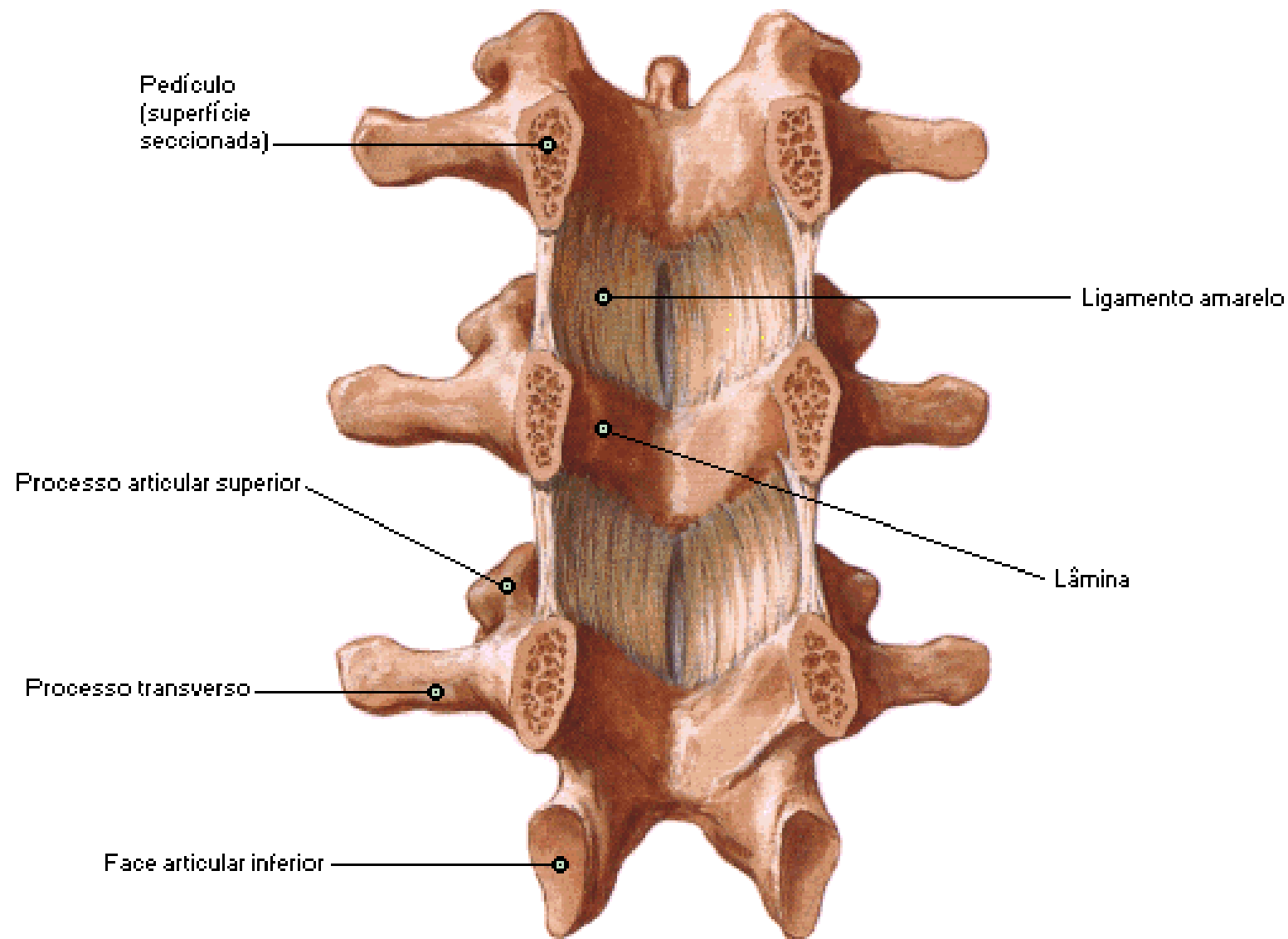
Ligamentos Vertebrais da Região Lombar

Segmentos Vertebrais Anteriores - Vista Posterior



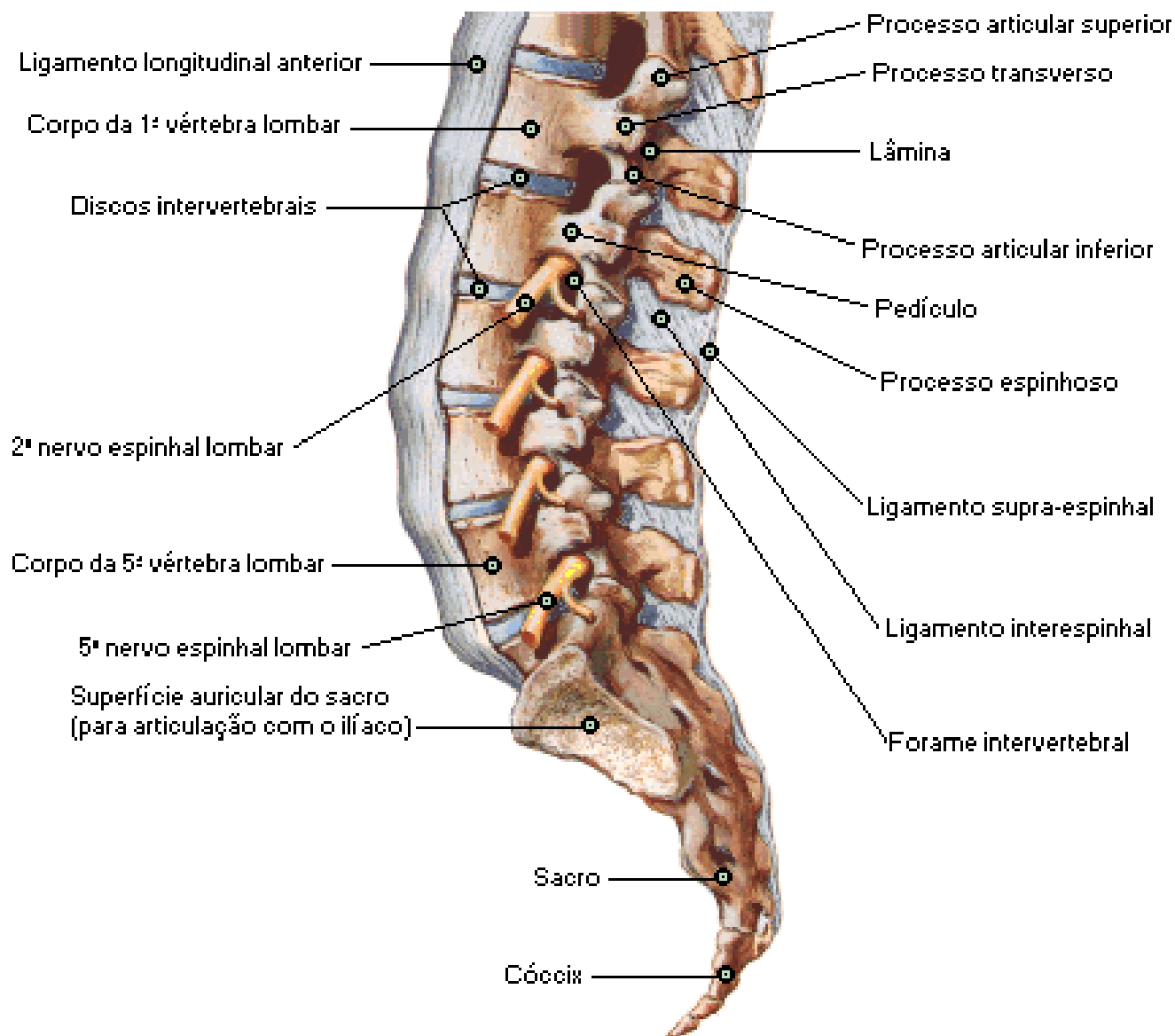
Ligamentos Vertebrais da Região Lombar

Segmentos Vertebrais Posteriores - Vista Anterior



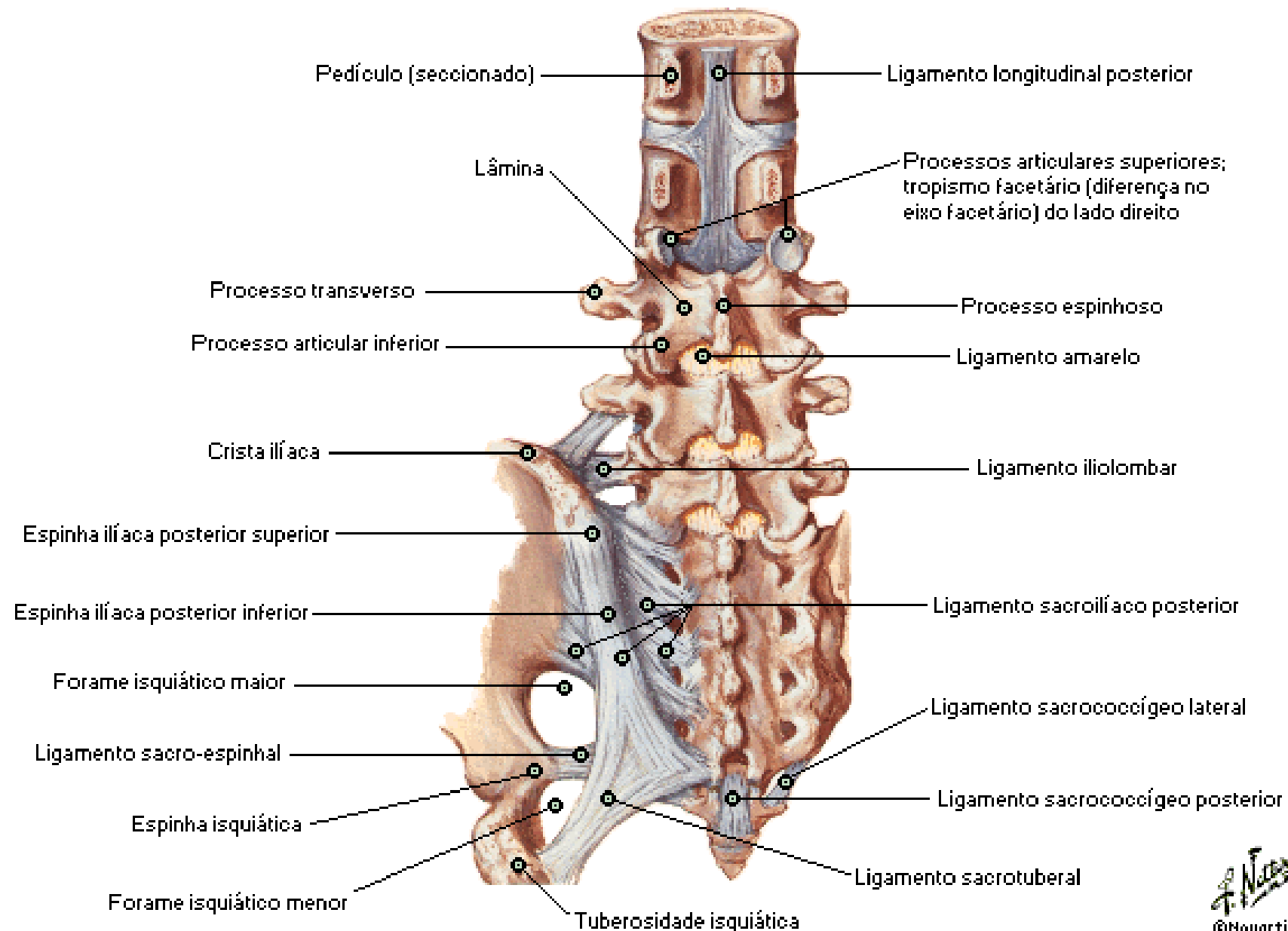
Ligamentos Vertebrais da Região Lombossacral

Vista Lateral Esquerda

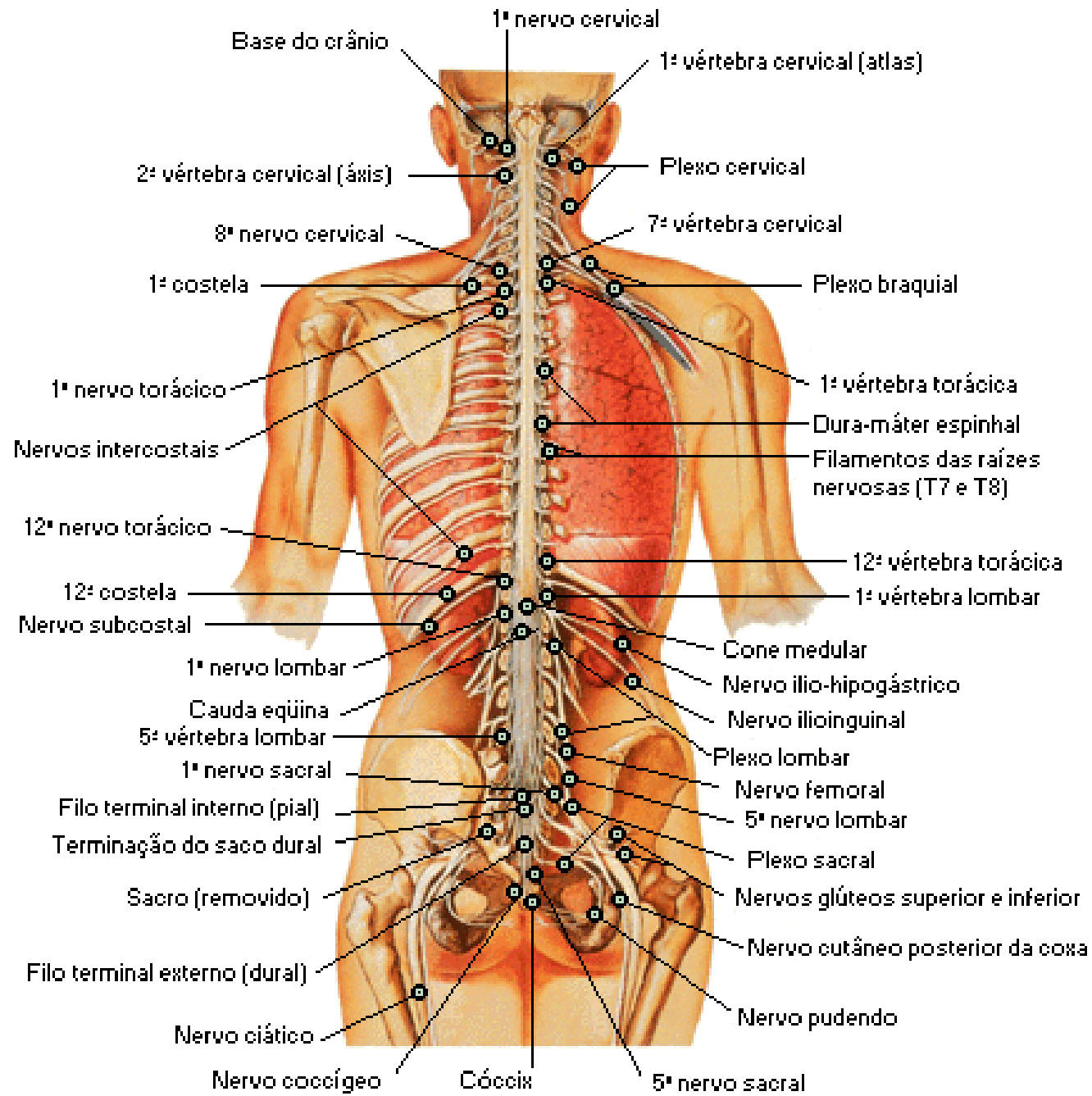


Ligamentos Vertebrais da Região Lombossacral

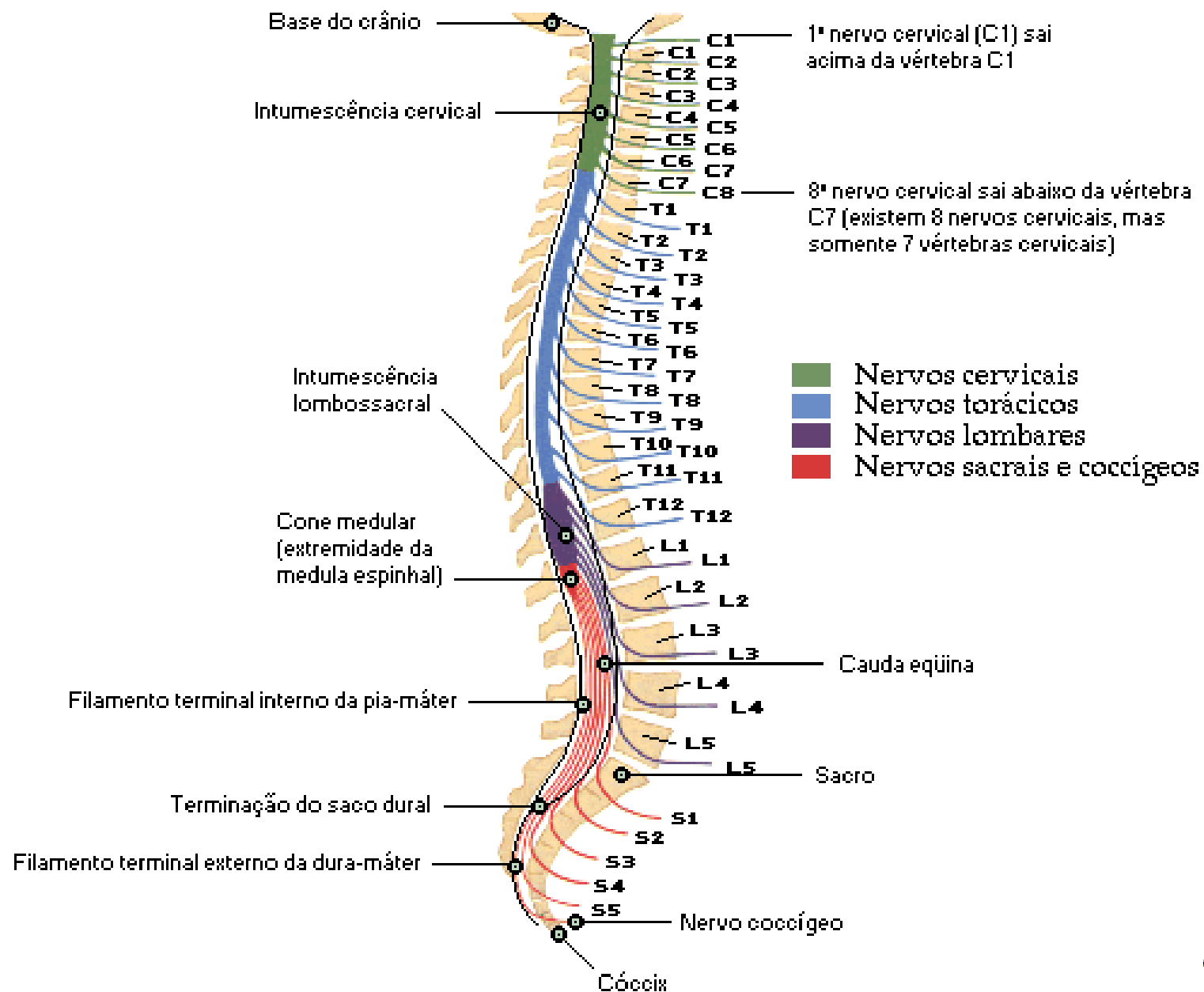
Vista Posterior



Medula Espinhal in Situ

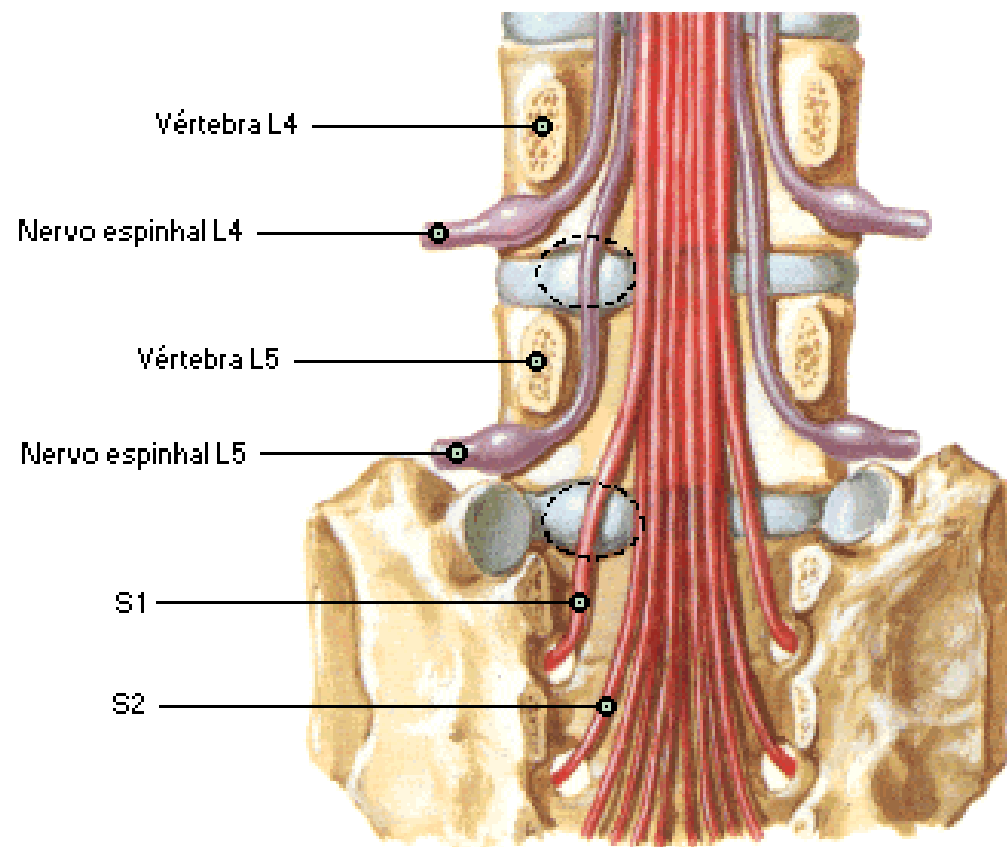


Relação das Raízes Nervosas com as Vértexbras



Relação das Raízes Nervosas com as Vértébras

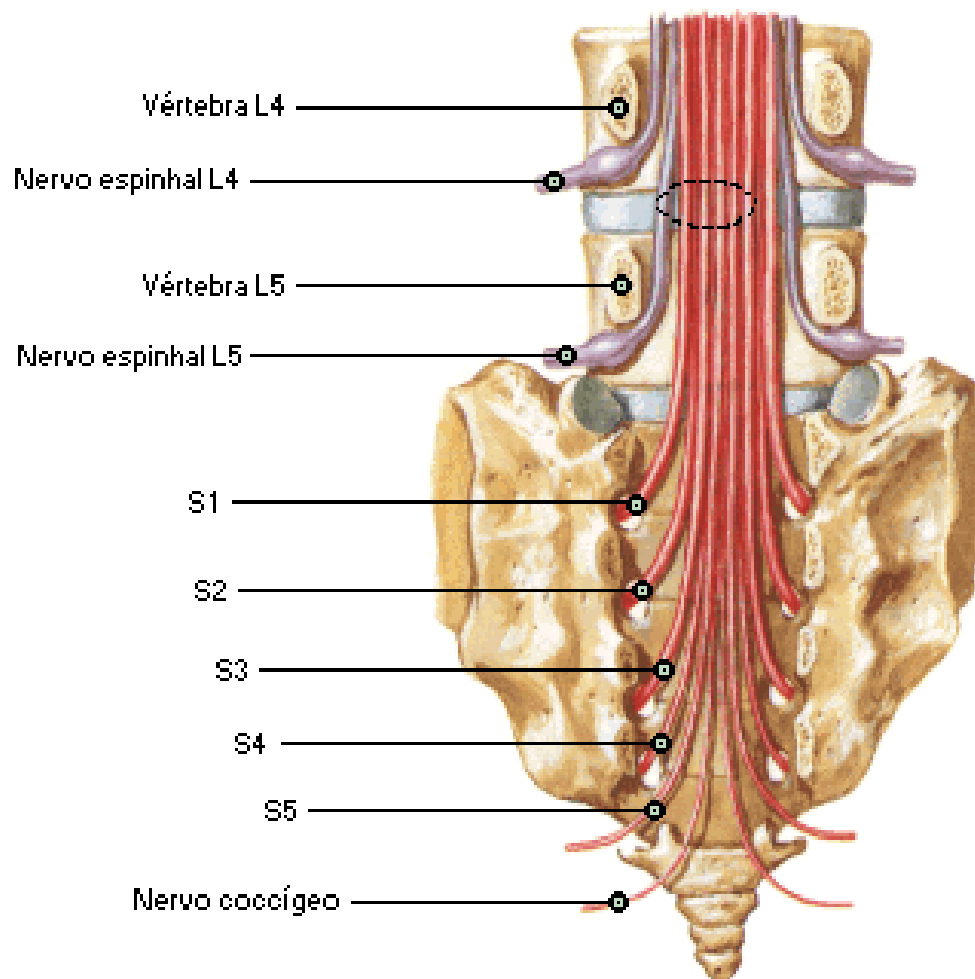
Protusão Lateral



Protusão lombar do disco intervertebral geralmente não afeta nervo emergindo acima do disco. Protusão lateral do disco ao nível de L4-5 afeta o 5º nervo lombar, não o 4º. Protusão ao nível de L5-S1 afeta o 1º nervo sacral, não o 5º nervo lombar

Relação das Raízes Nervosas com as Vértébras

Protusão Medial



Protusão mediana do disco ao nível de L4-5 raramente afeta o 4º nervo lombar, mas pode afetar o 5º nervo lombar e algumas vezes o 1º e o 4º nervo sacral

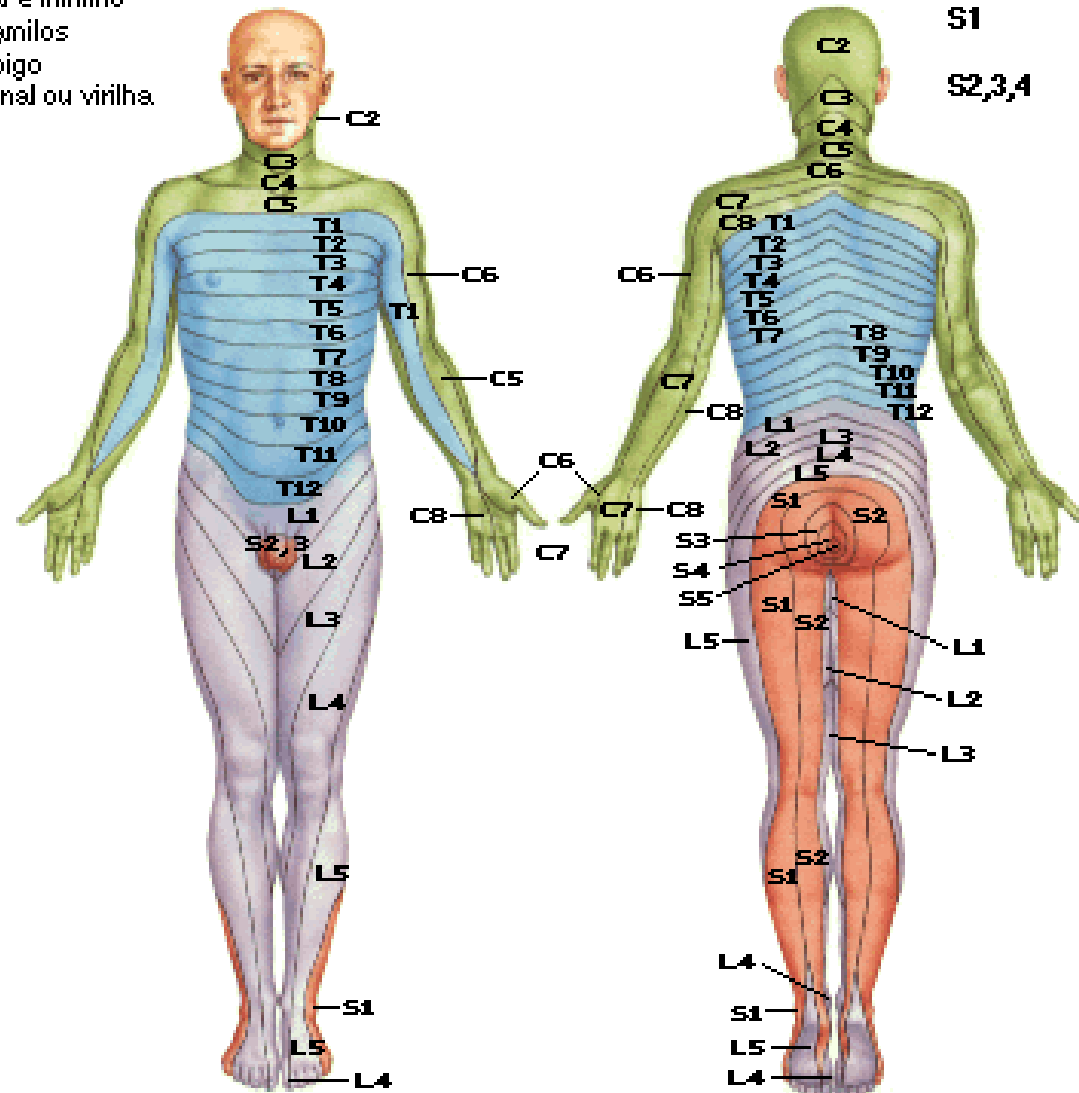
Níveis dos principais dermatômos

- C5** Clavícula
- C5,6,7** Margem lateral dos membros superiores
- C8,T1** Margem medial dos membros superiores
- C6** Polegar
- C6,7,8** Mão
- C8** Dedos anular e mínimo
- T4** Nível dos mamilos
- T10** Nível do umbigo
- T12** Região inguinal ou virilha.

Dermátomos

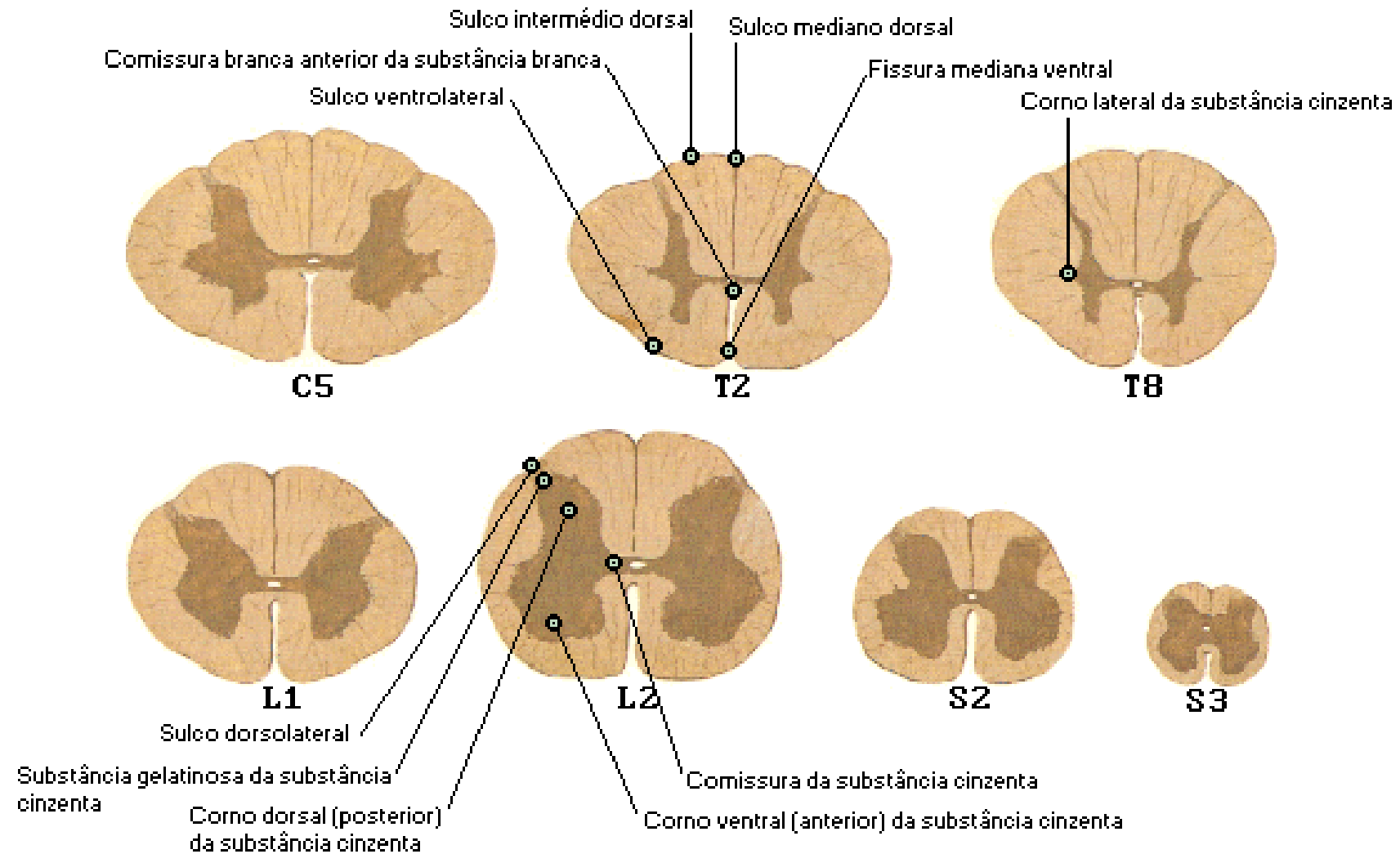
Níveis dos principais dermatômos

- L1,2,3,4** Regiões anterior e medial dos membros inferiores
- L4,5,S1** Pé
- L4** Margem medial do hálux
- S1,2,L5** Regiões posterior e lateral dos membros inferiores
- S1** Margem lateral do pé e dedo mínimo
- S2,3,4** Períneo



Demarcação esquemática dos dermatômos mostrados como segmentos distintos. Existe na realidade uma considerável sobreposição entre dois dermatômos adjacentes quaisquer.

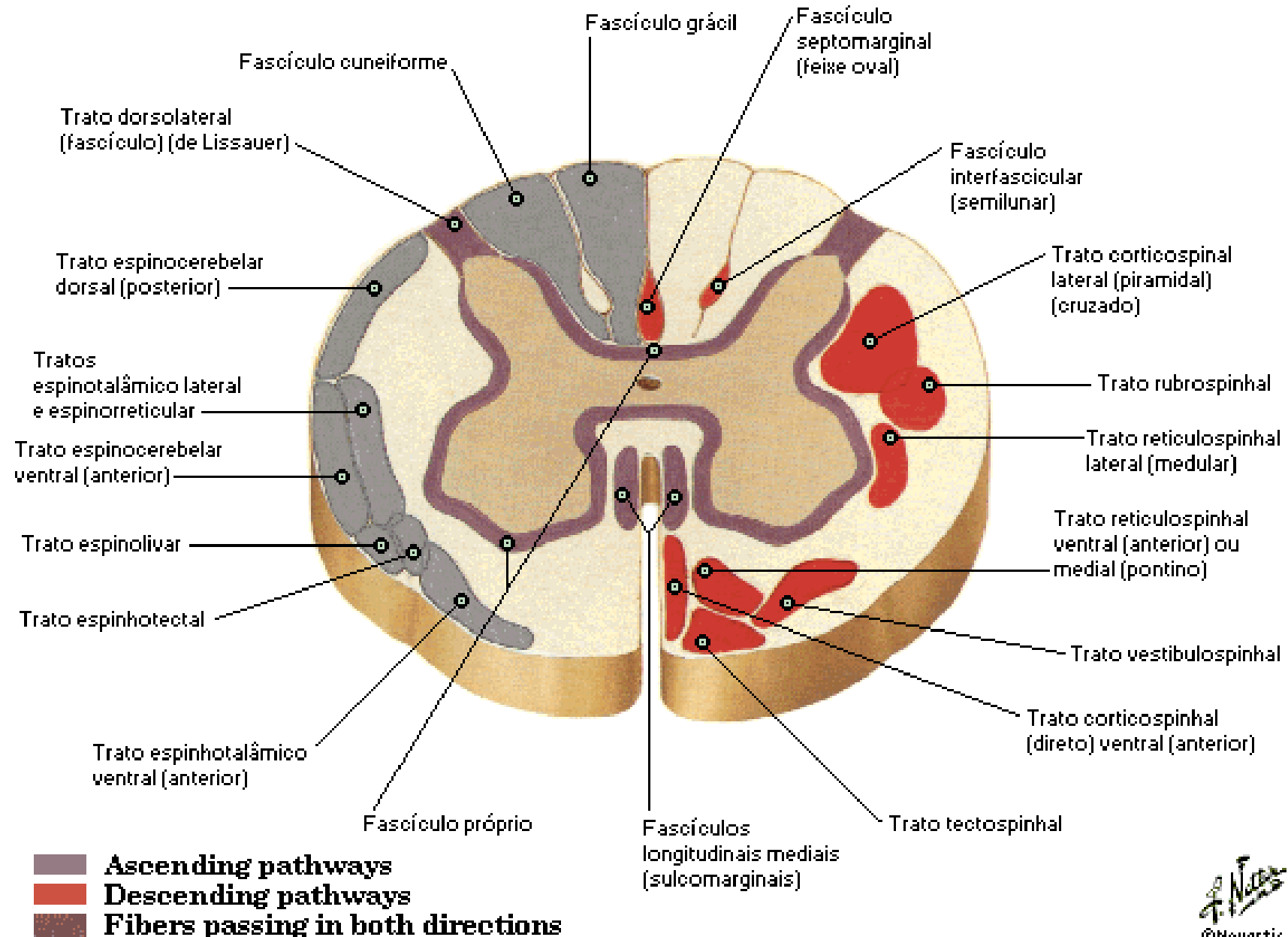
Secções Transversais da Medula Espinhal



Secções através da medula em vários níveis

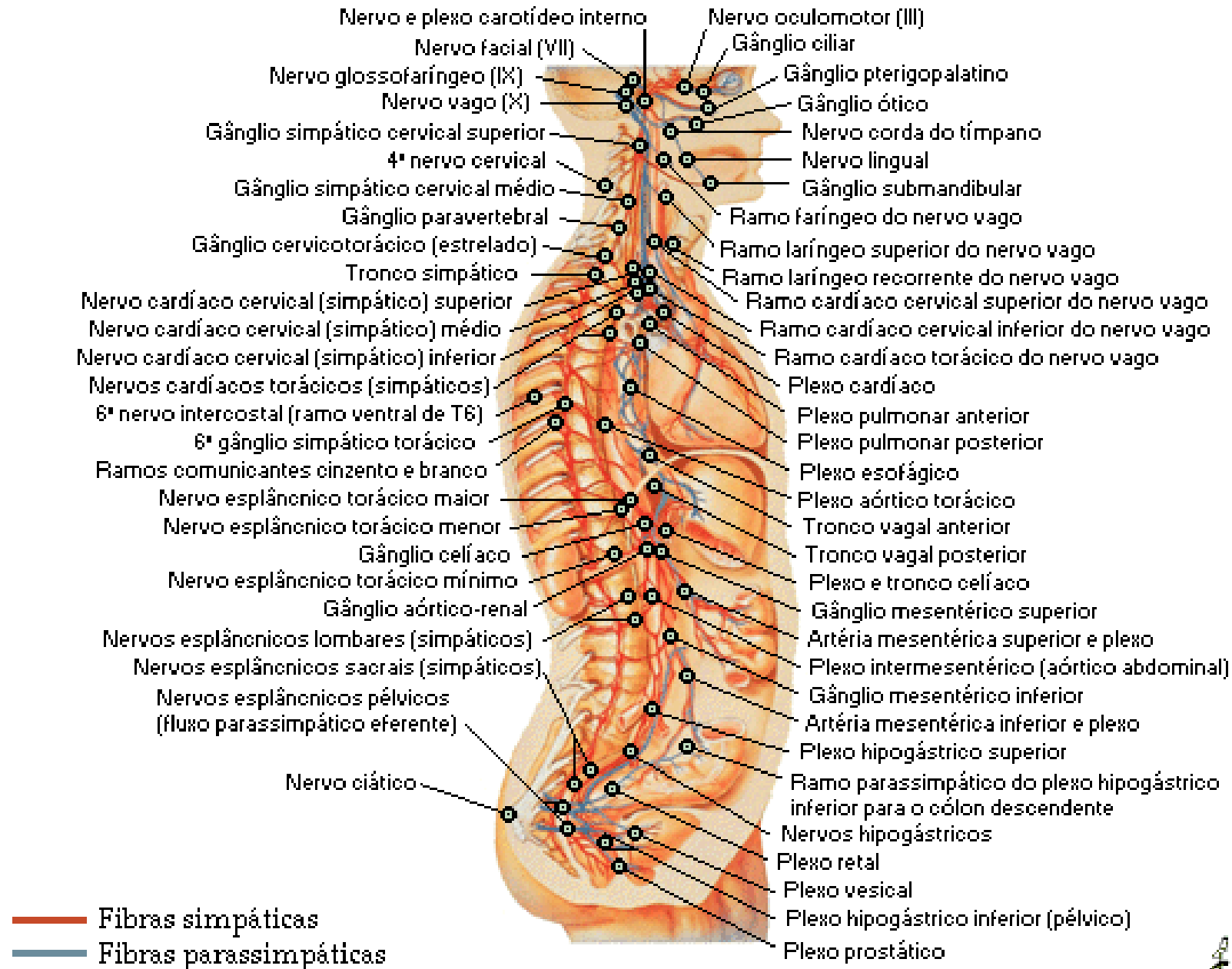
Secções Transversais da Medula Espinhal

Tratos Nervosos



Sistema Nervoso Autônomo

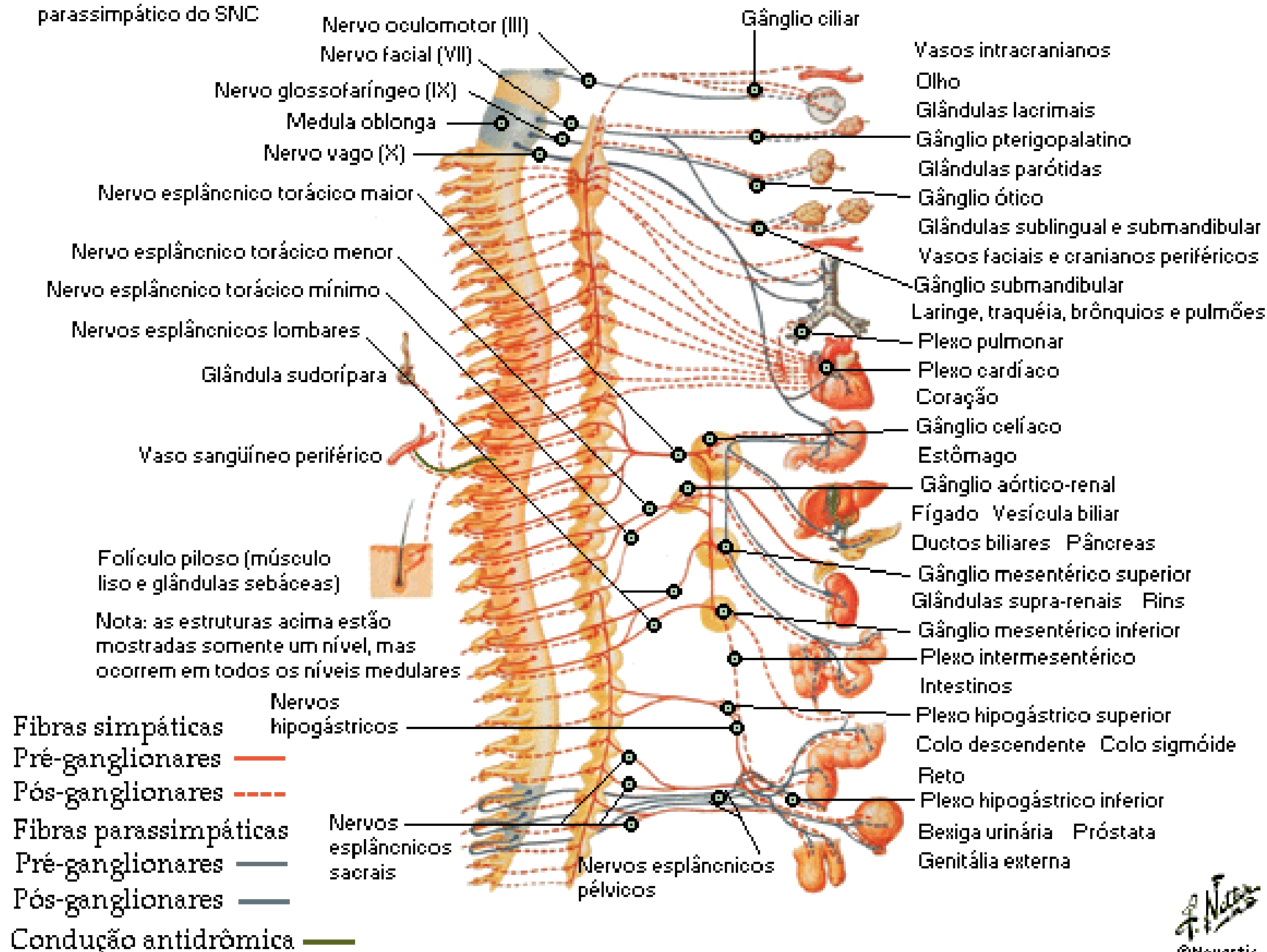
Topografia Geral



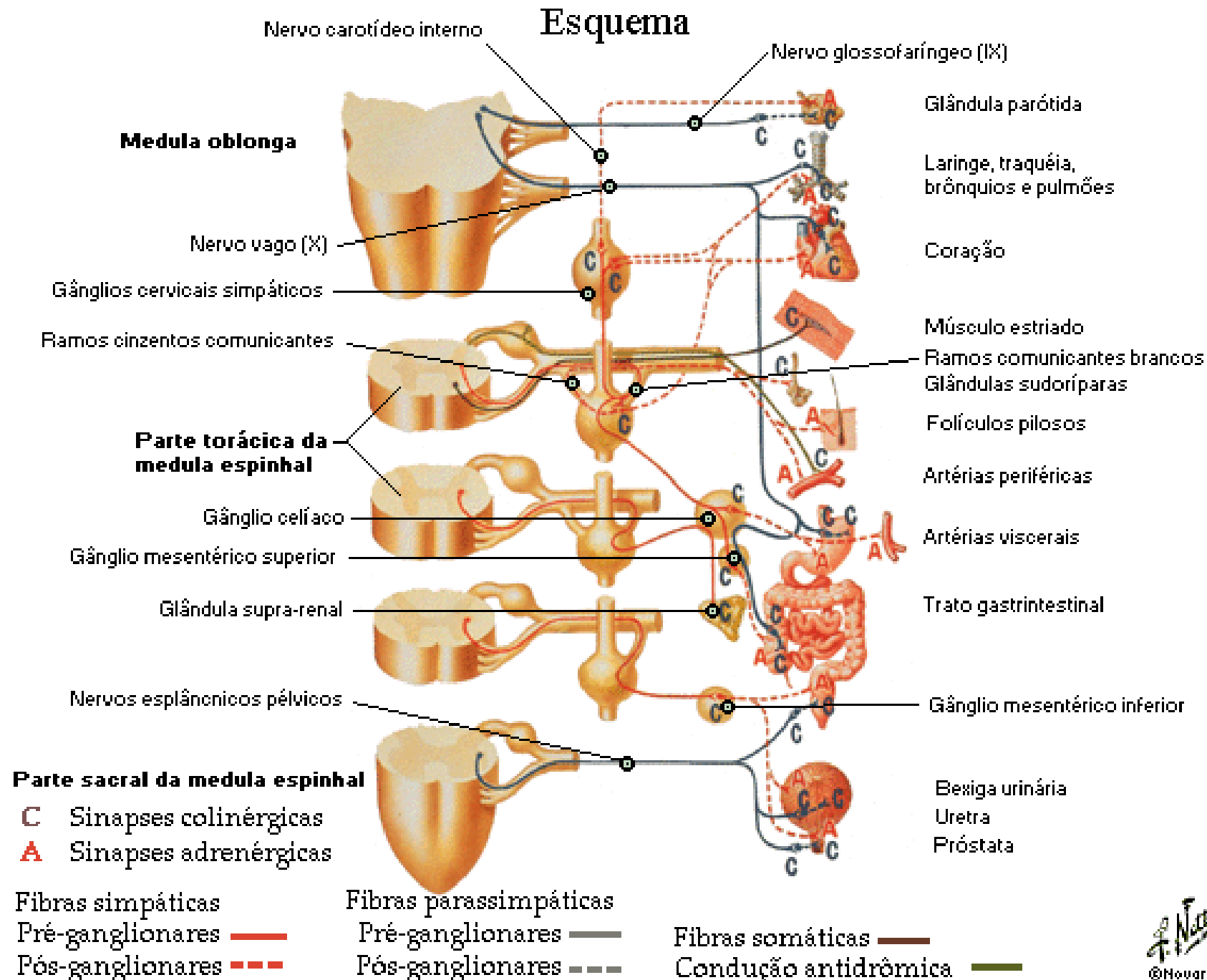
Sistema Nervoso Autônomo

Esquema

Nota: áreas sombreadas de azul indicam zonas de fluxo eferente parassimpático do SNC

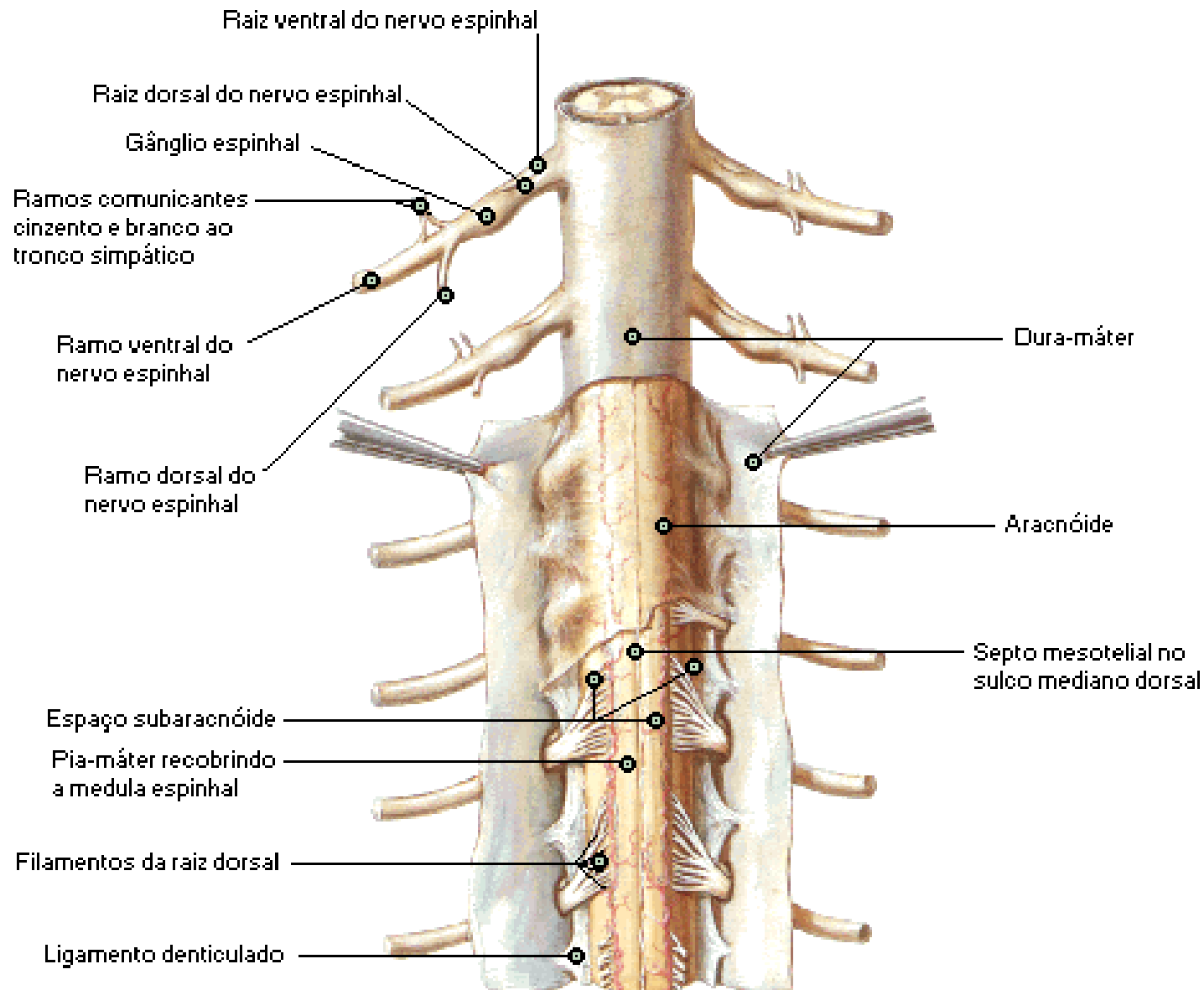


Sinapses Colinérgica e Adrenérgica



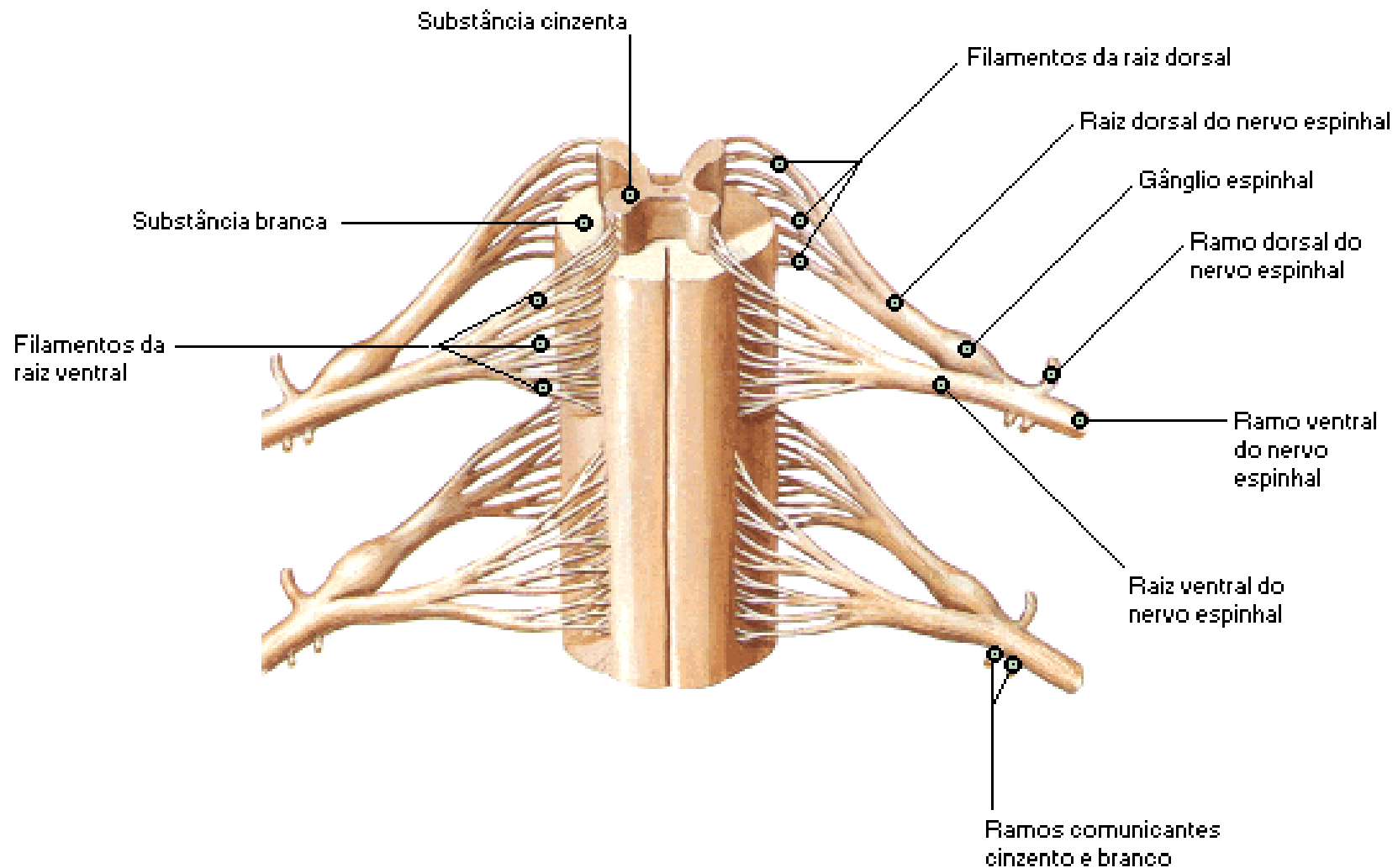
Meninges Espinhais e Raízes Nervosas

Vista Posterior



Meninges Espinhais e Raízes Nervosas

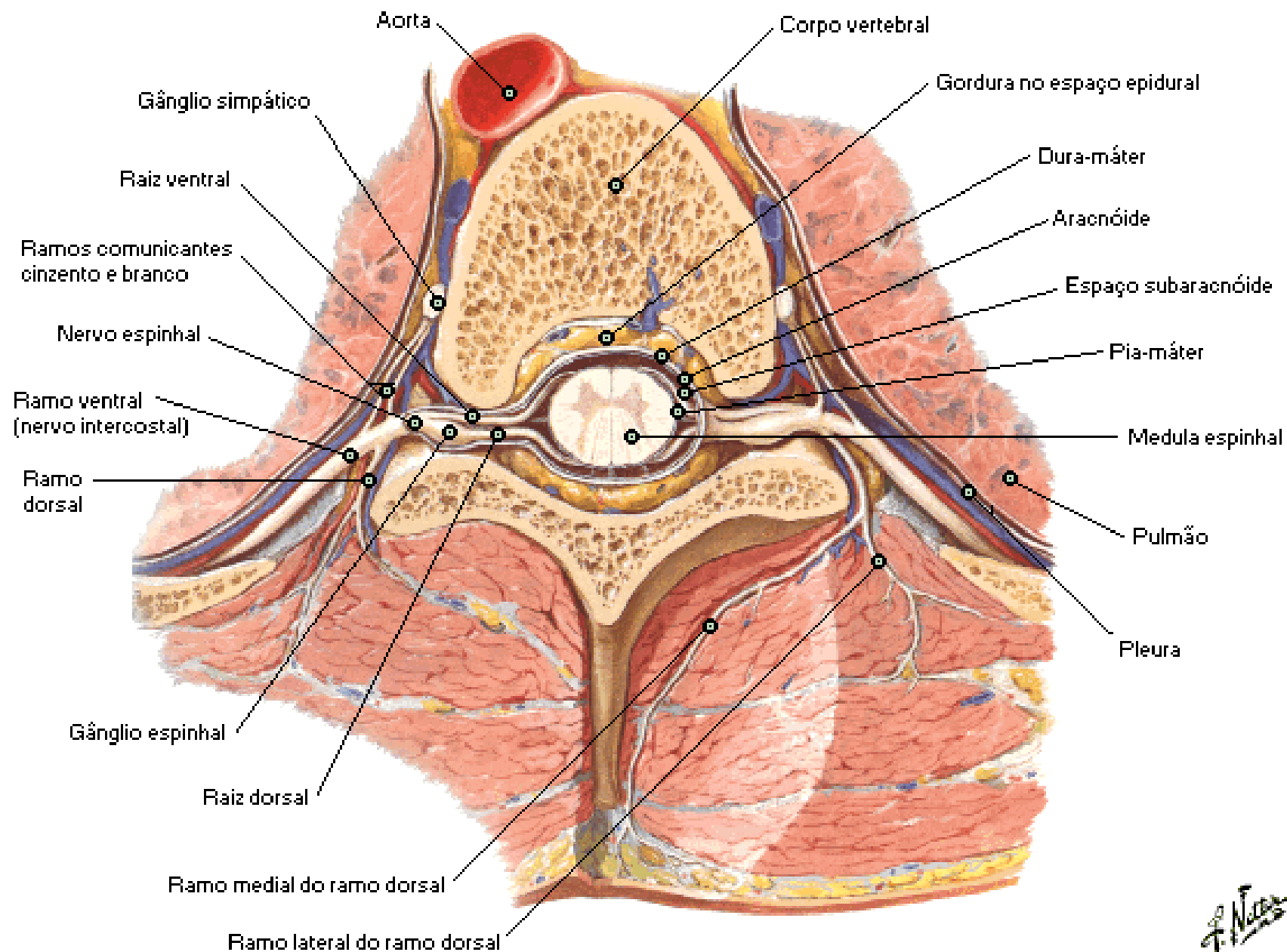
Vista Anterior



Membranas removidas [ampliada]

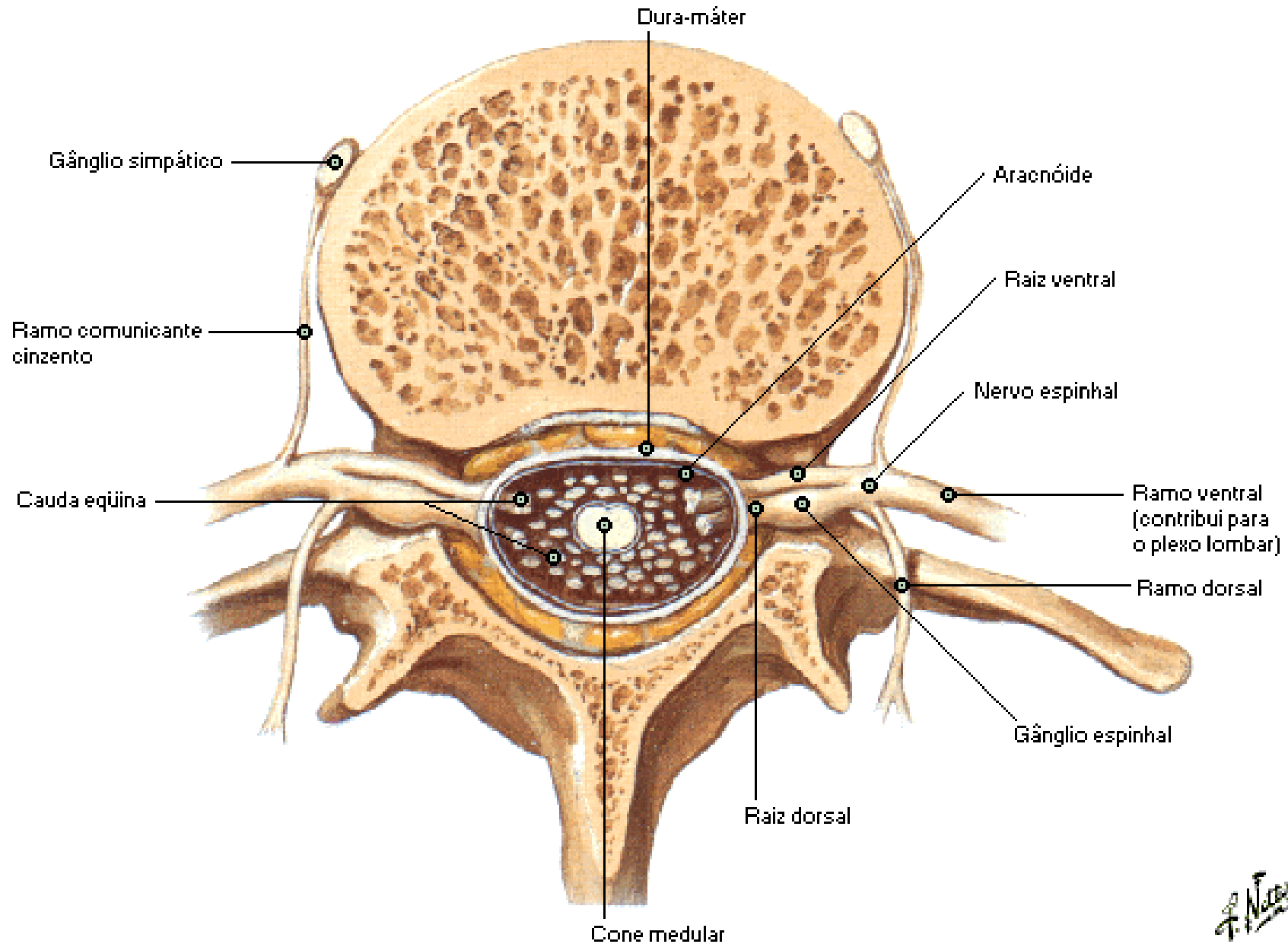
Origem do Nervo Espinhal

Secção Através da Vértebra Torácica



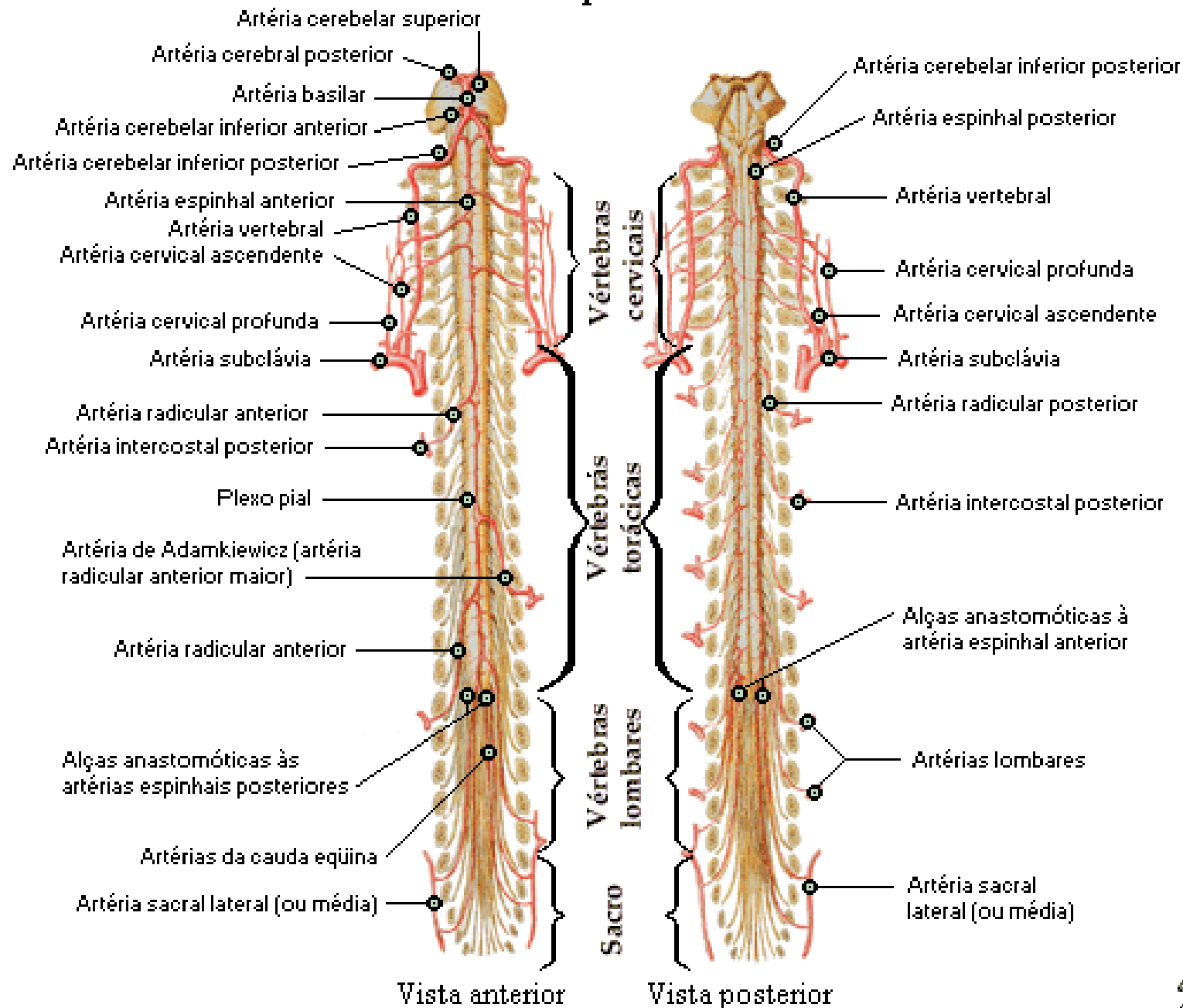
Origem do Nervo Espinhal

Secção Através da Vértebra Lombar



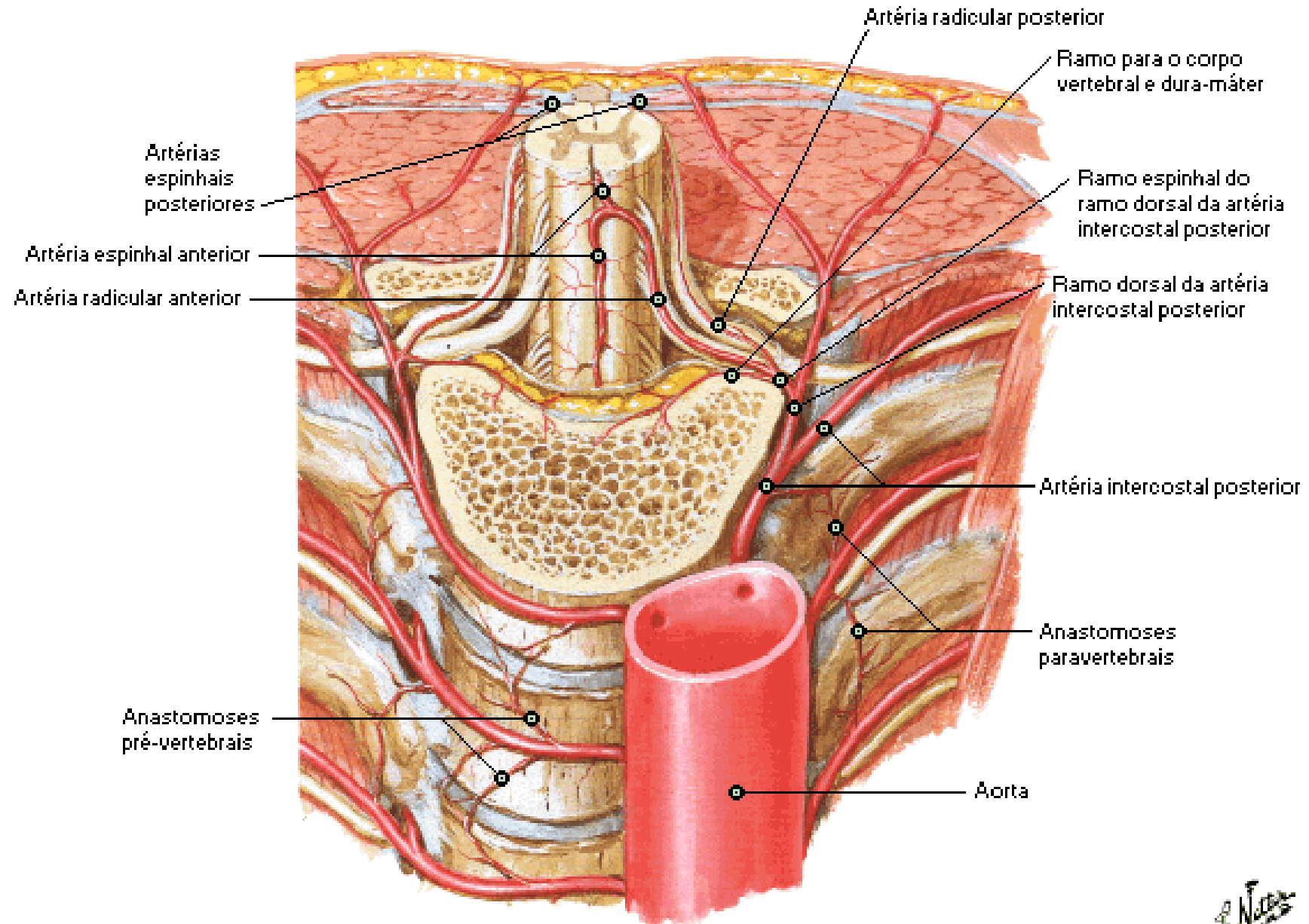
Artérias da Medula Espinhal

Esquema



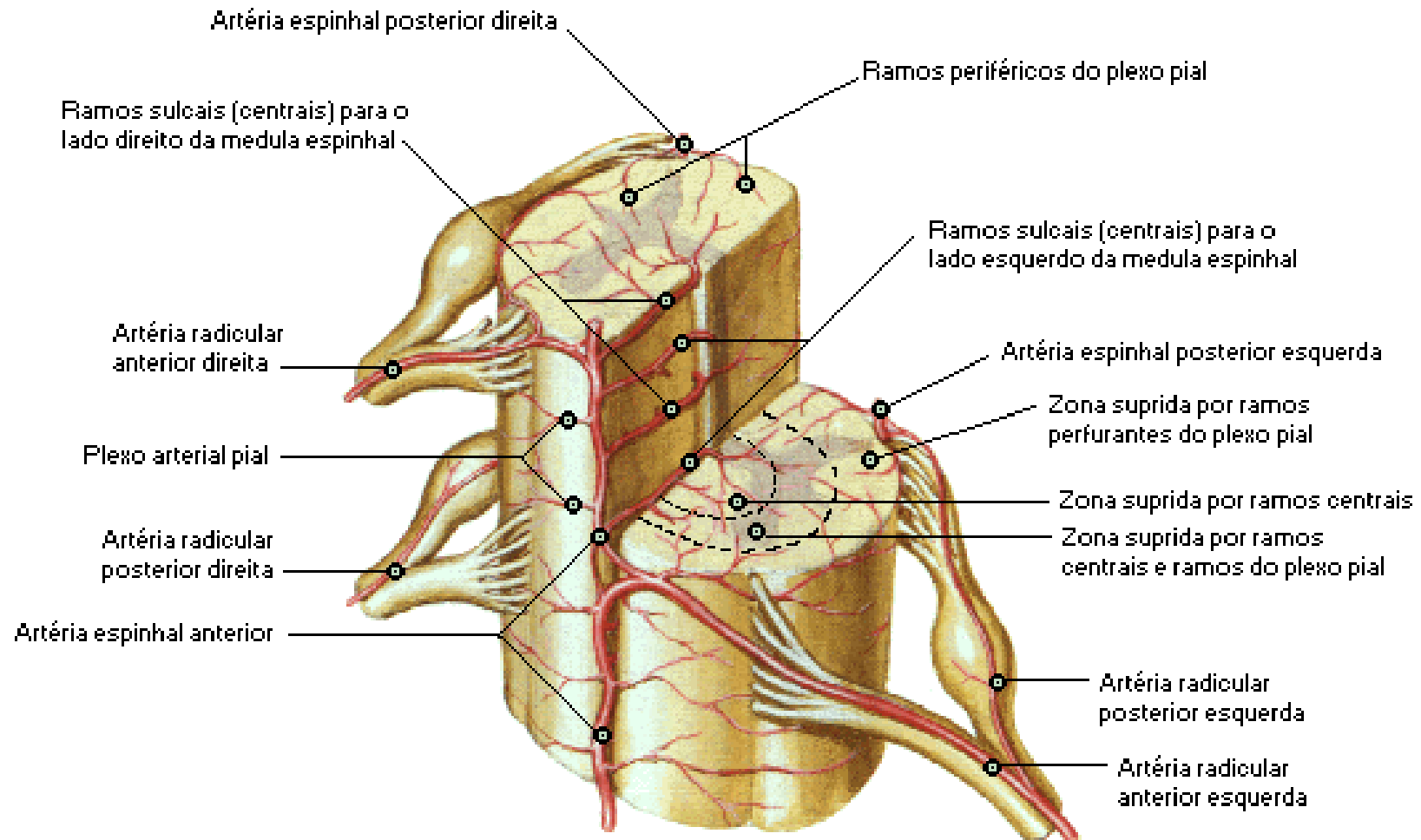
Artérias da Medula Espinhal - Distribuição Intrínseca

Secção Torácica



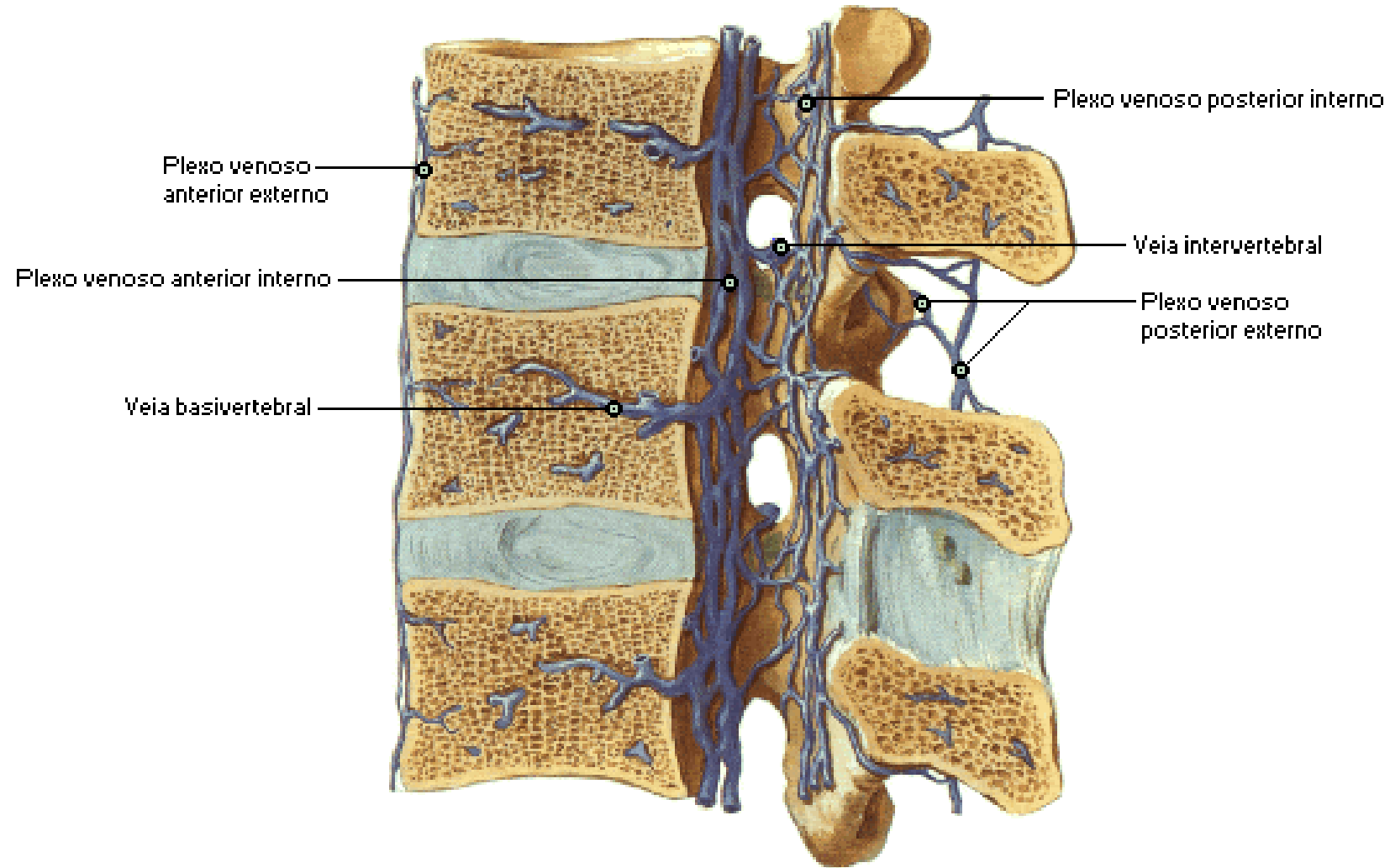
Artérias da Medula Espinhal - Distribuição Intrínseca

Esquema



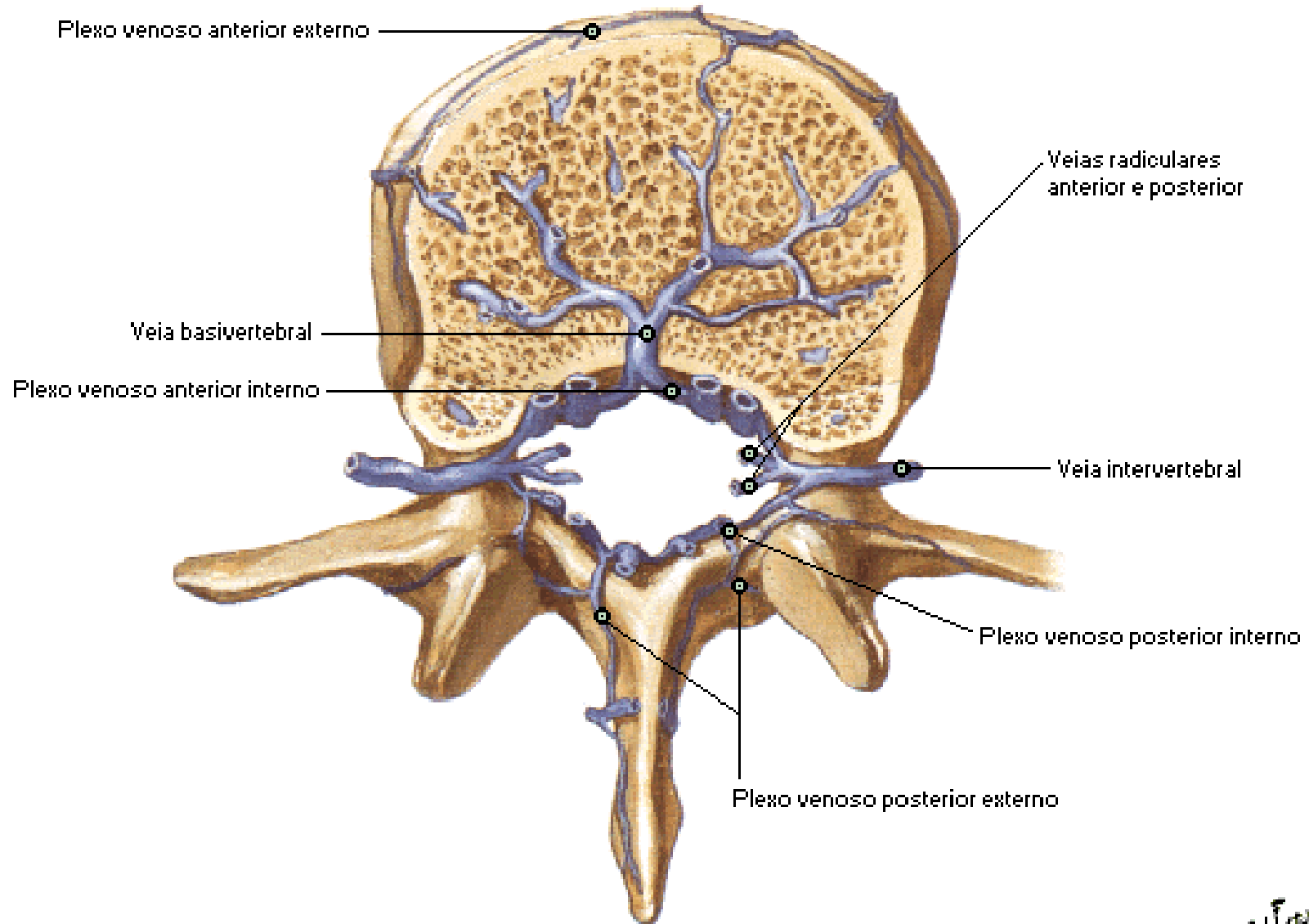
Veias da Medula Espinhal

Secção Sagital [sem Medula]



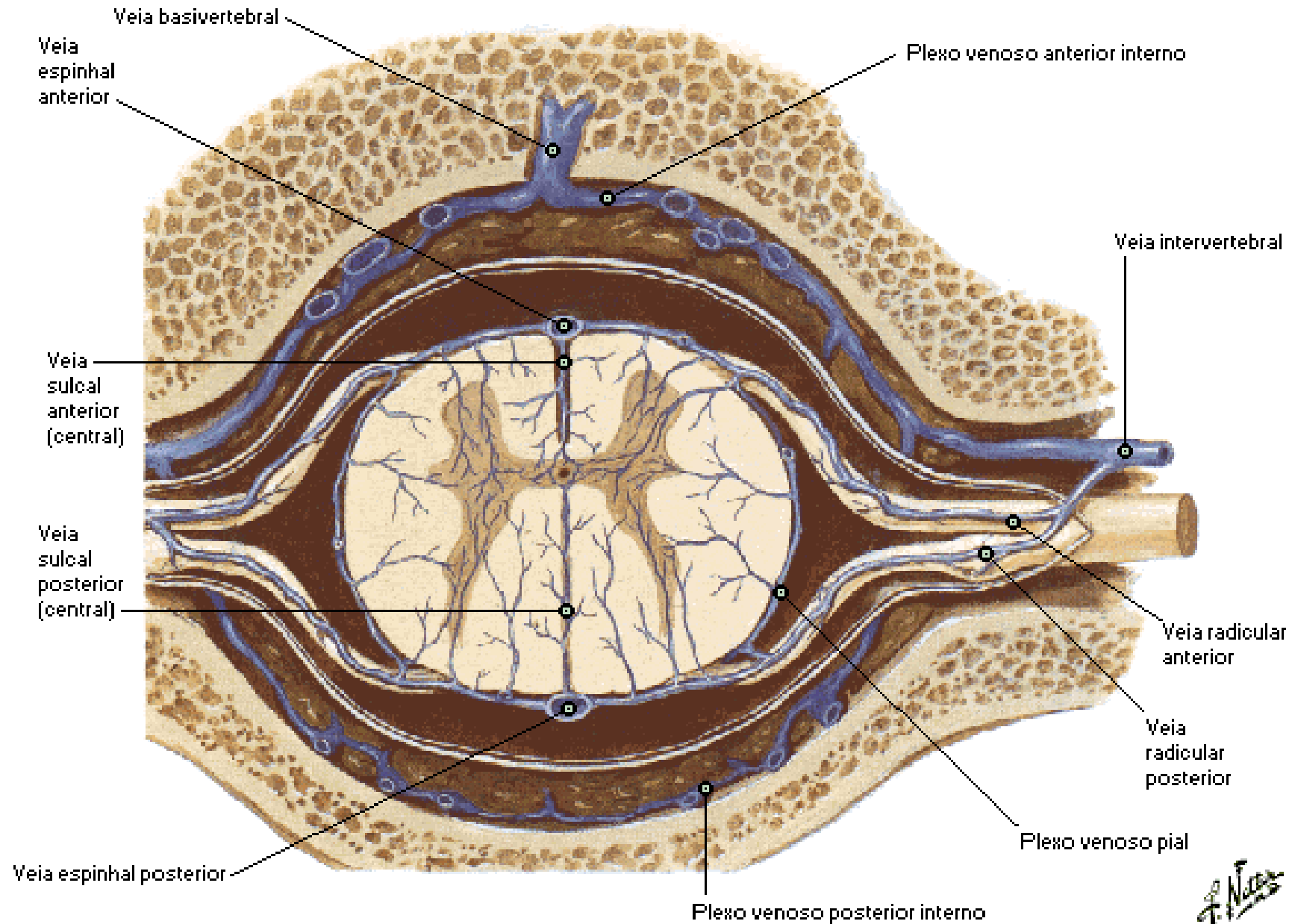
Veias da Medula Espinhal

Vista Superior [sem Medula]



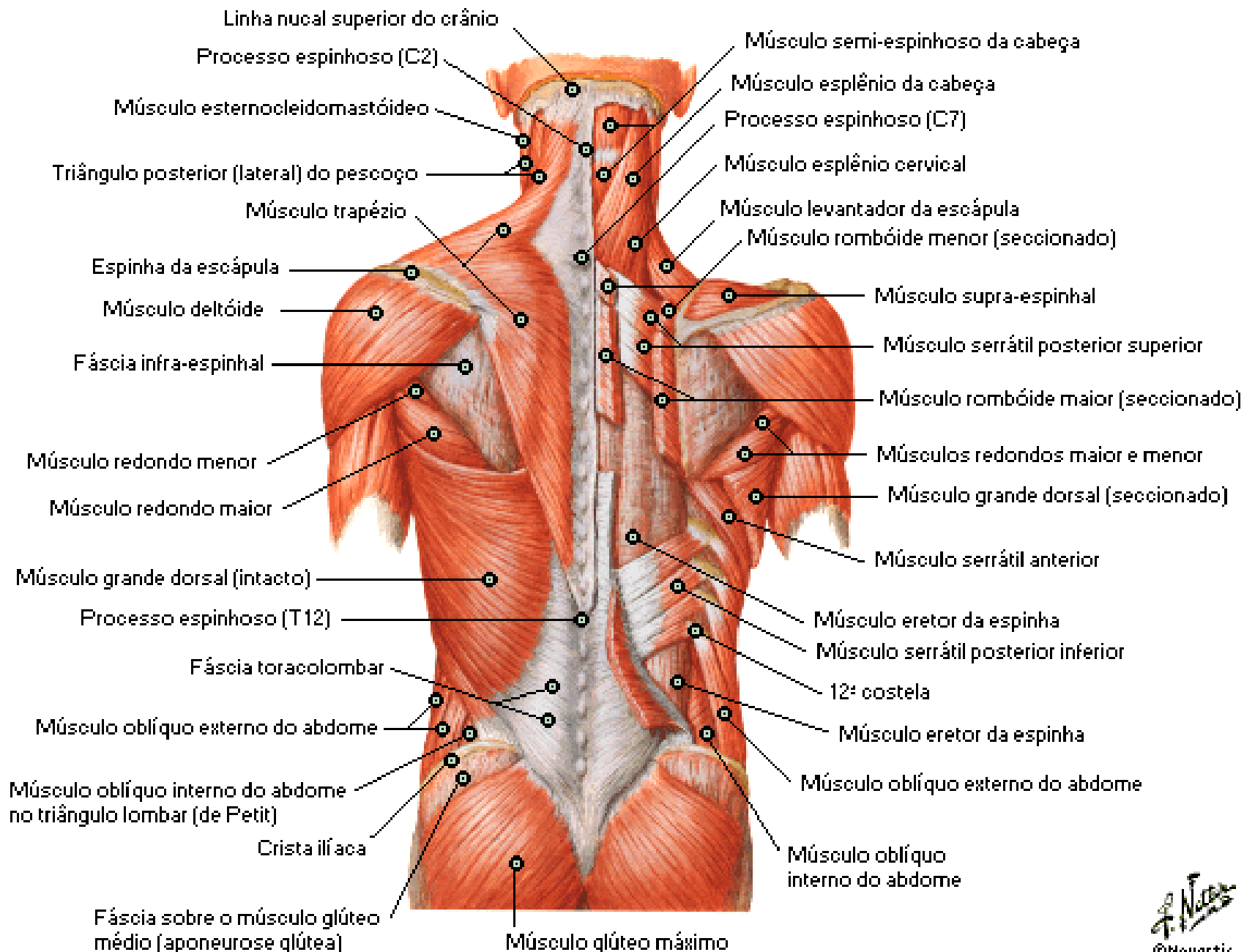
Veias da Medula Espinhal

Vista Superior [Ampliada, com Medula]



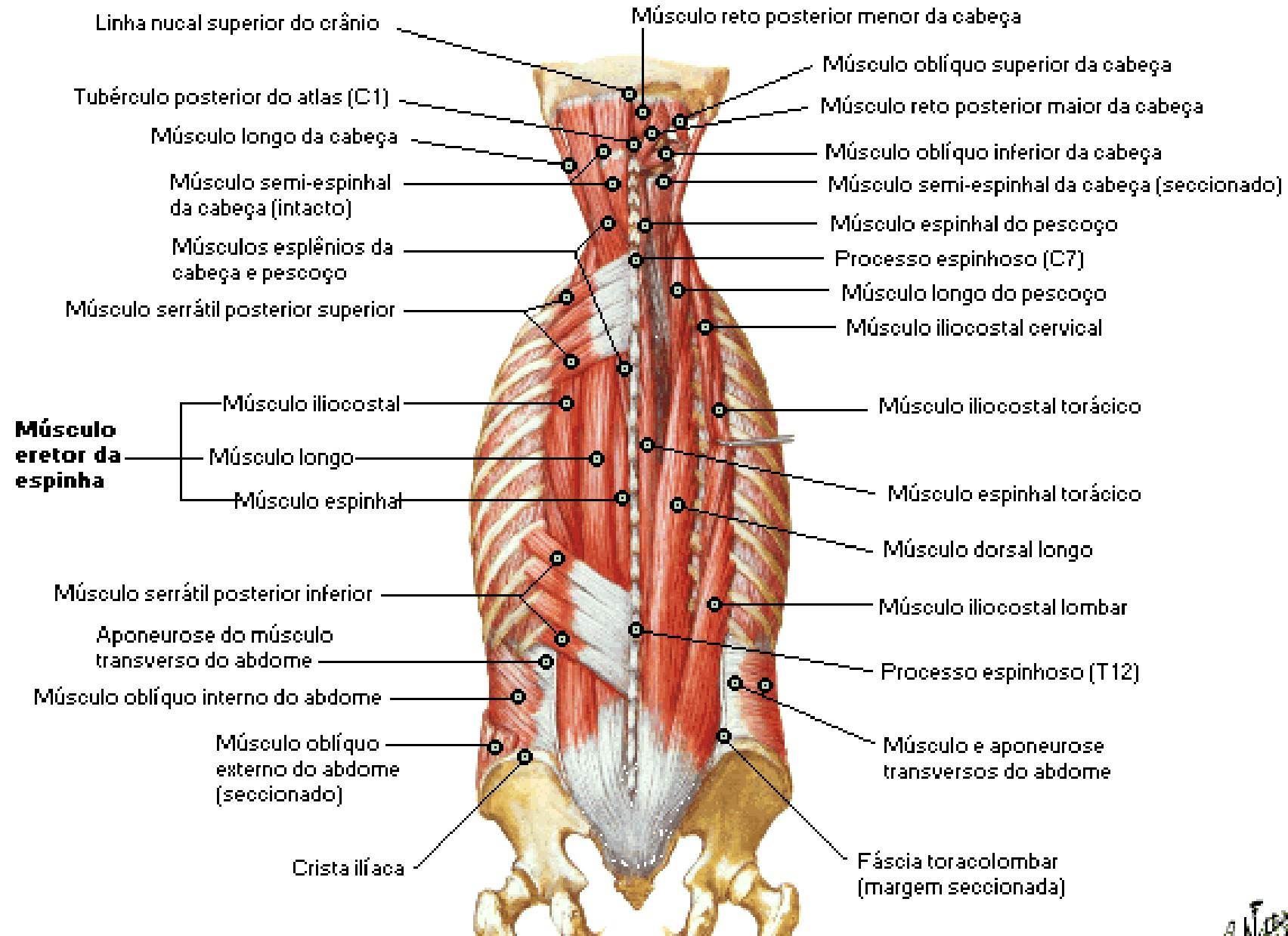
Músculos do Dorso

Camadas Superficiais

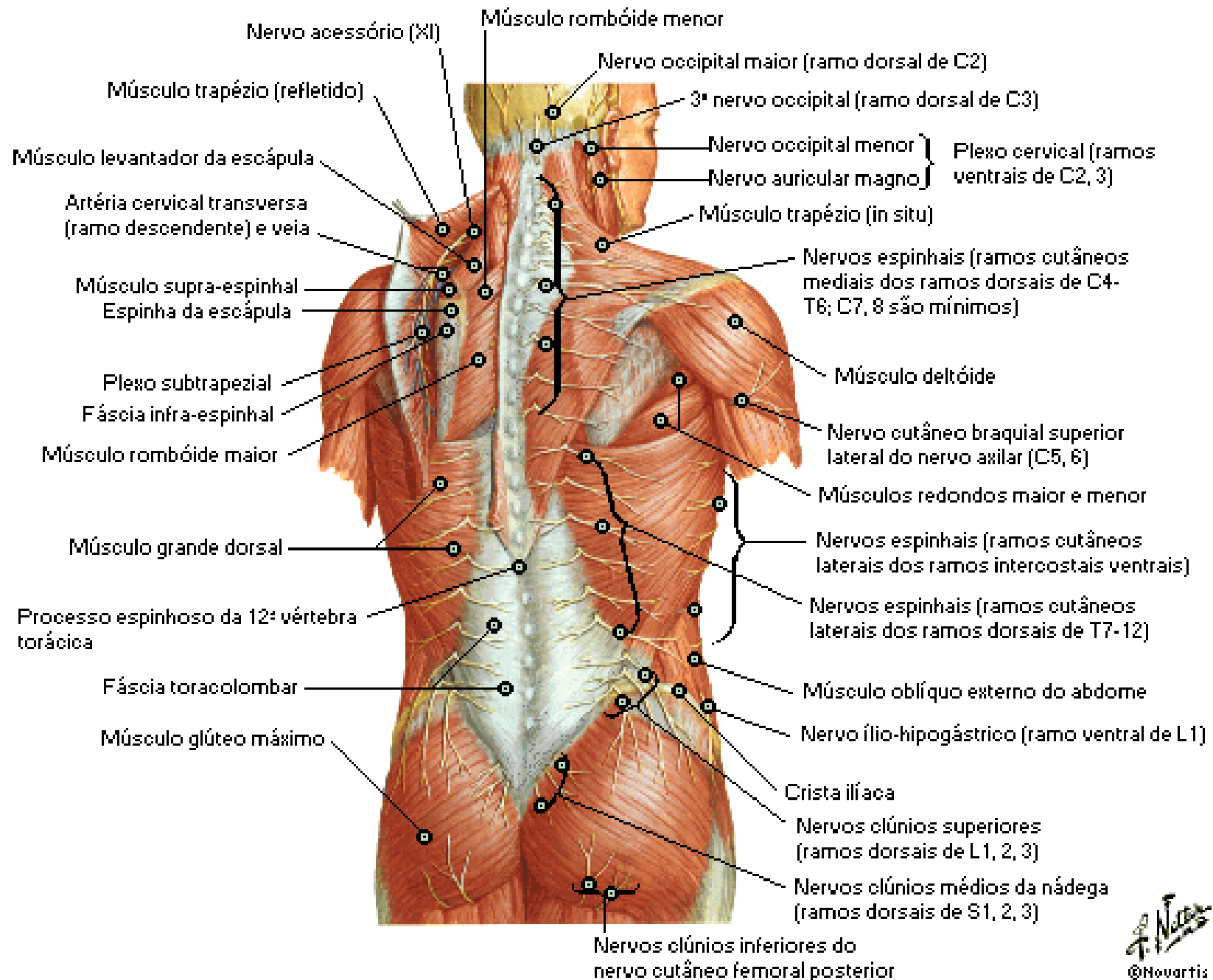


Músculos do Dorso

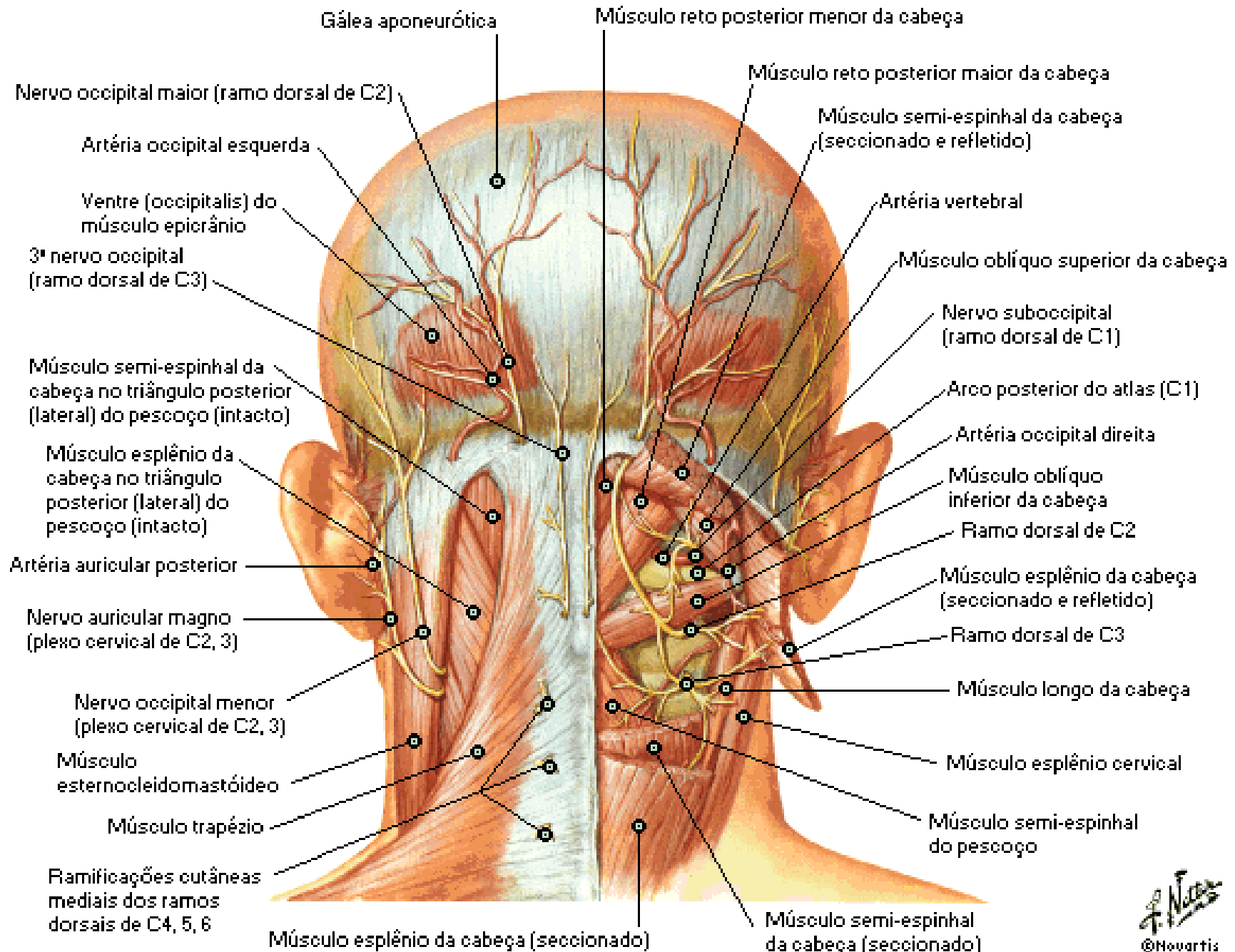
Camada Intermediária



Nervos do Dorso

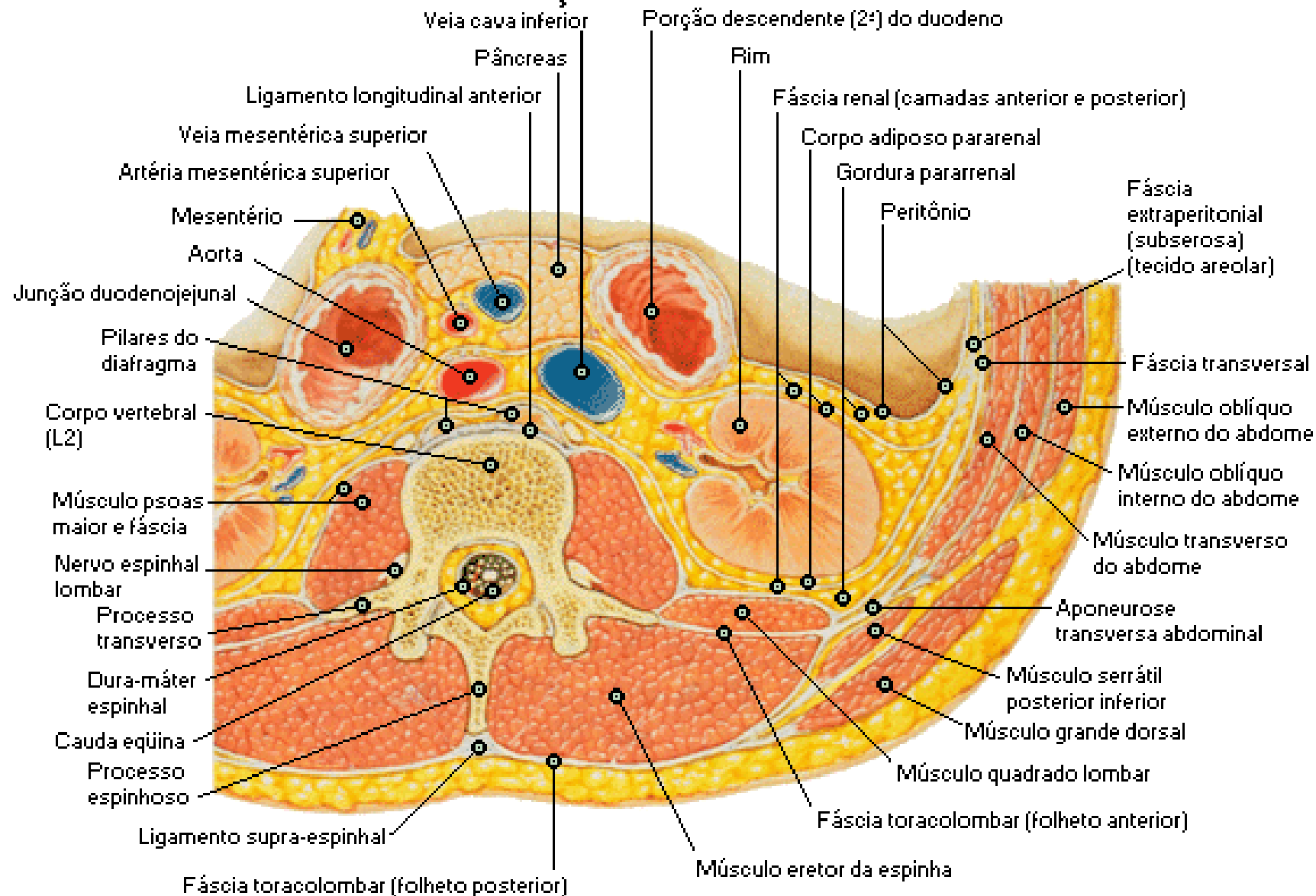


Triângulo Suboccipital



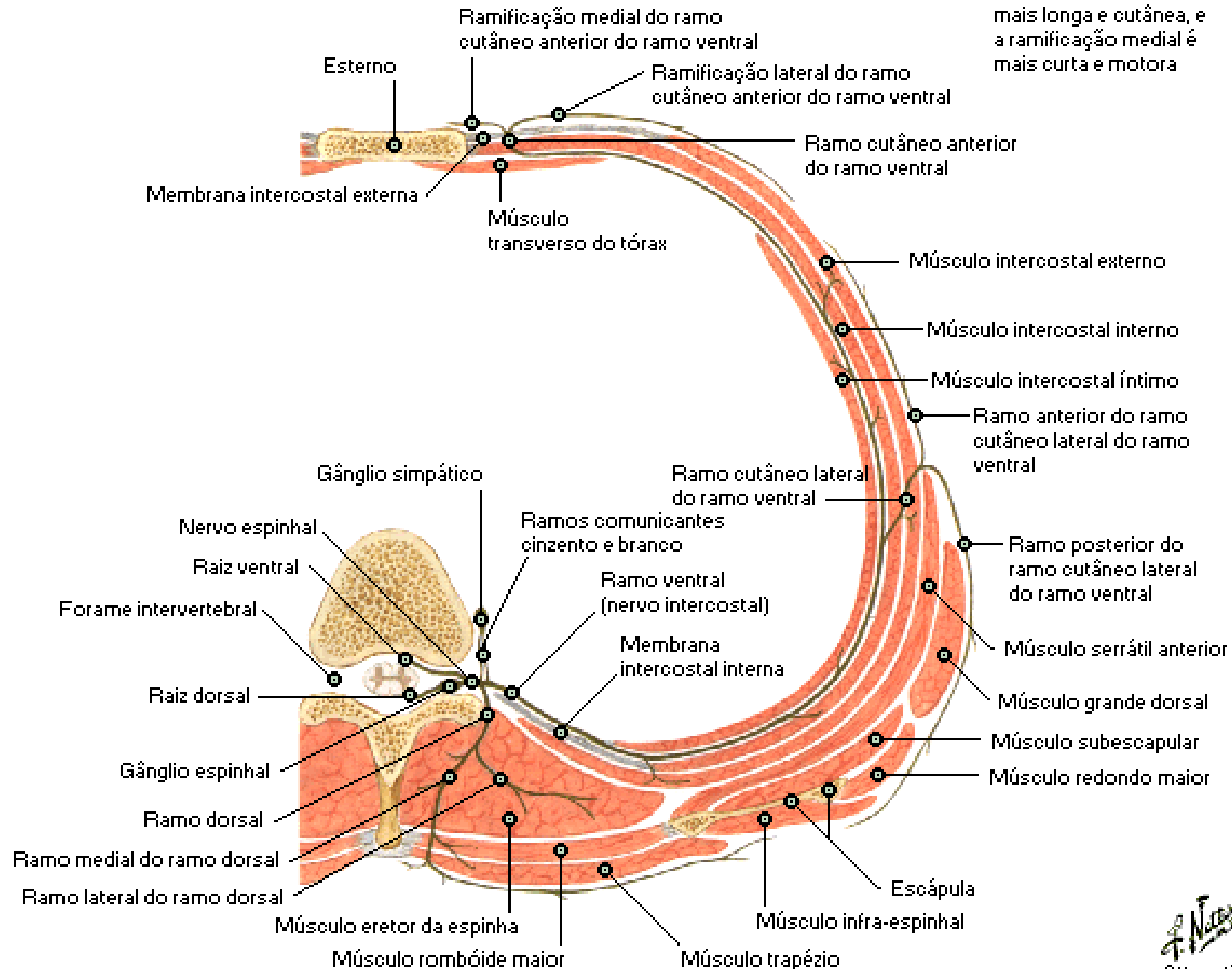
Região Lombar do Dorso

Secção Transversal



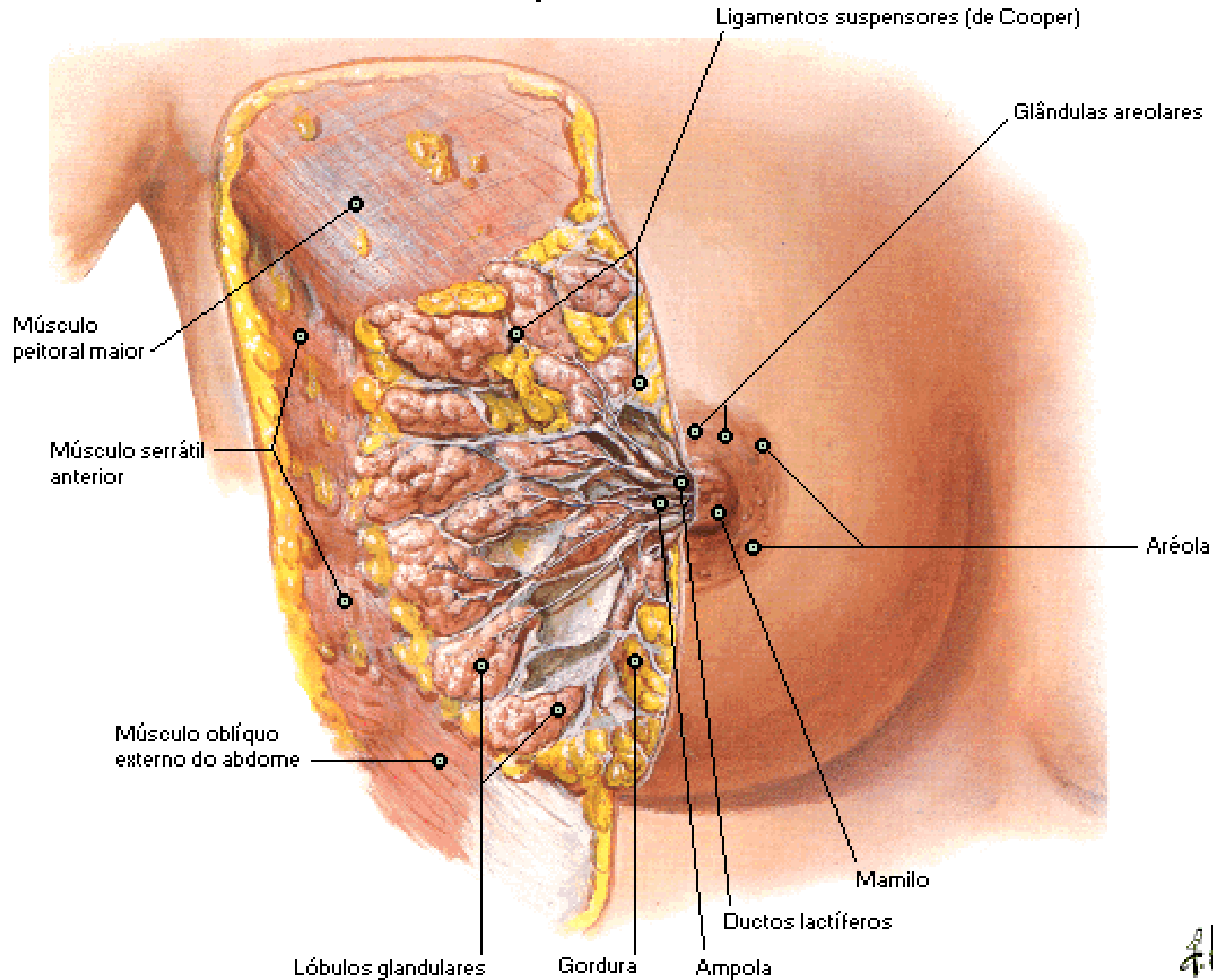
Nervo Espinal Torácico sTípico

Nota: na região torácica inferior, a ramificação lateral do ramo dorsal é mais longa e cutânea, e a ramificação medial é mais curta e motora



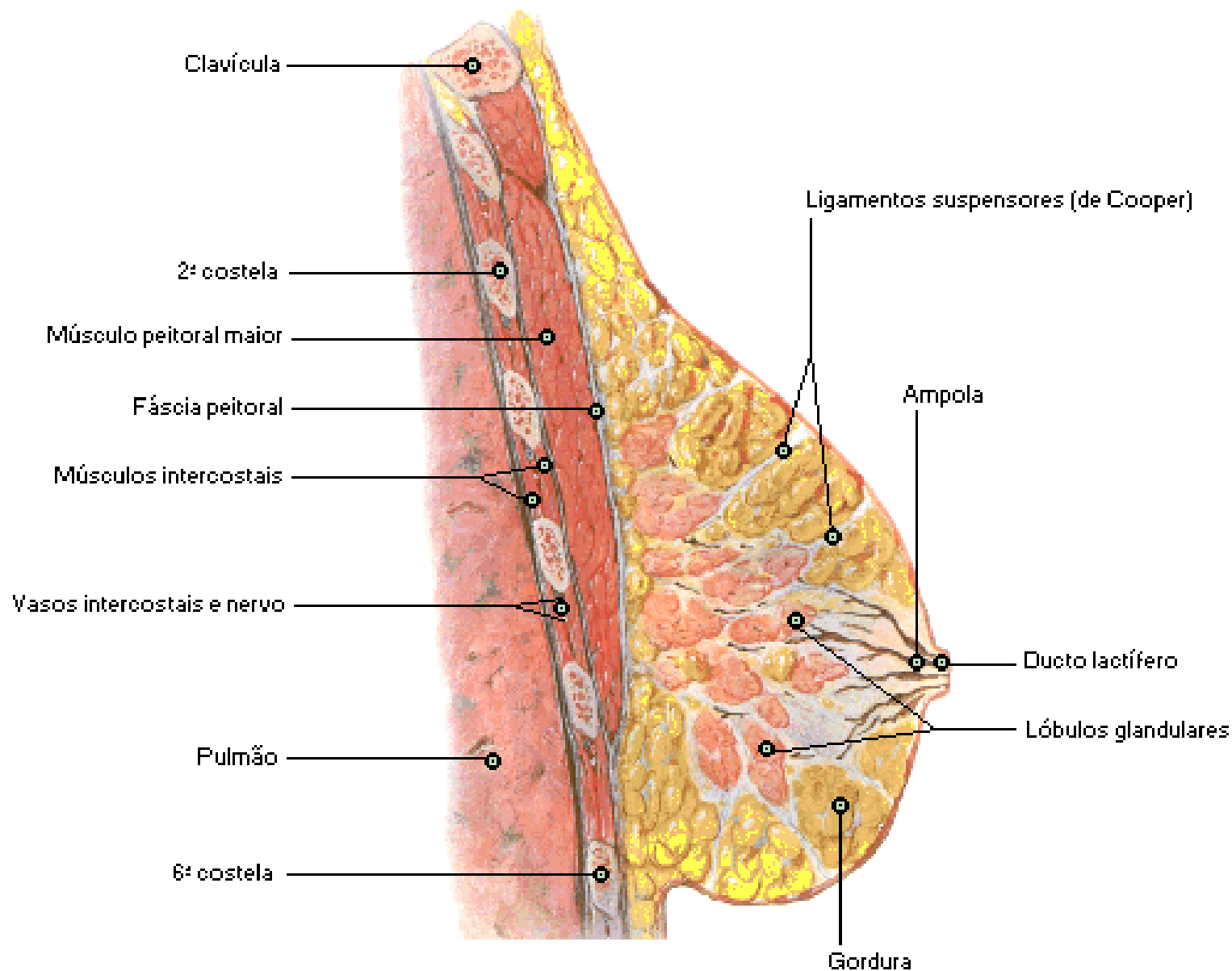
Glândula Mamária

Dissecação Ântero-lateral

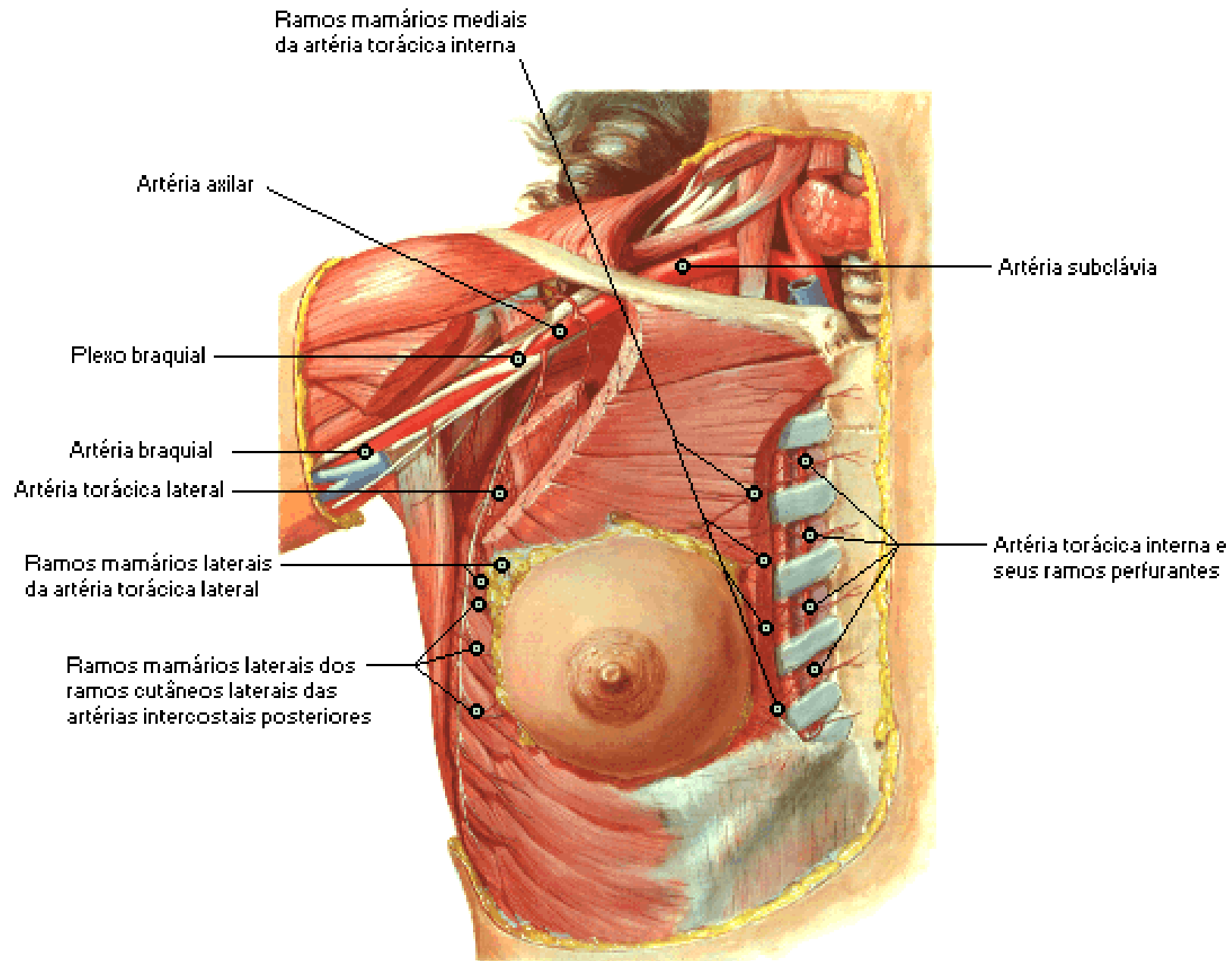


Glândula Mamária

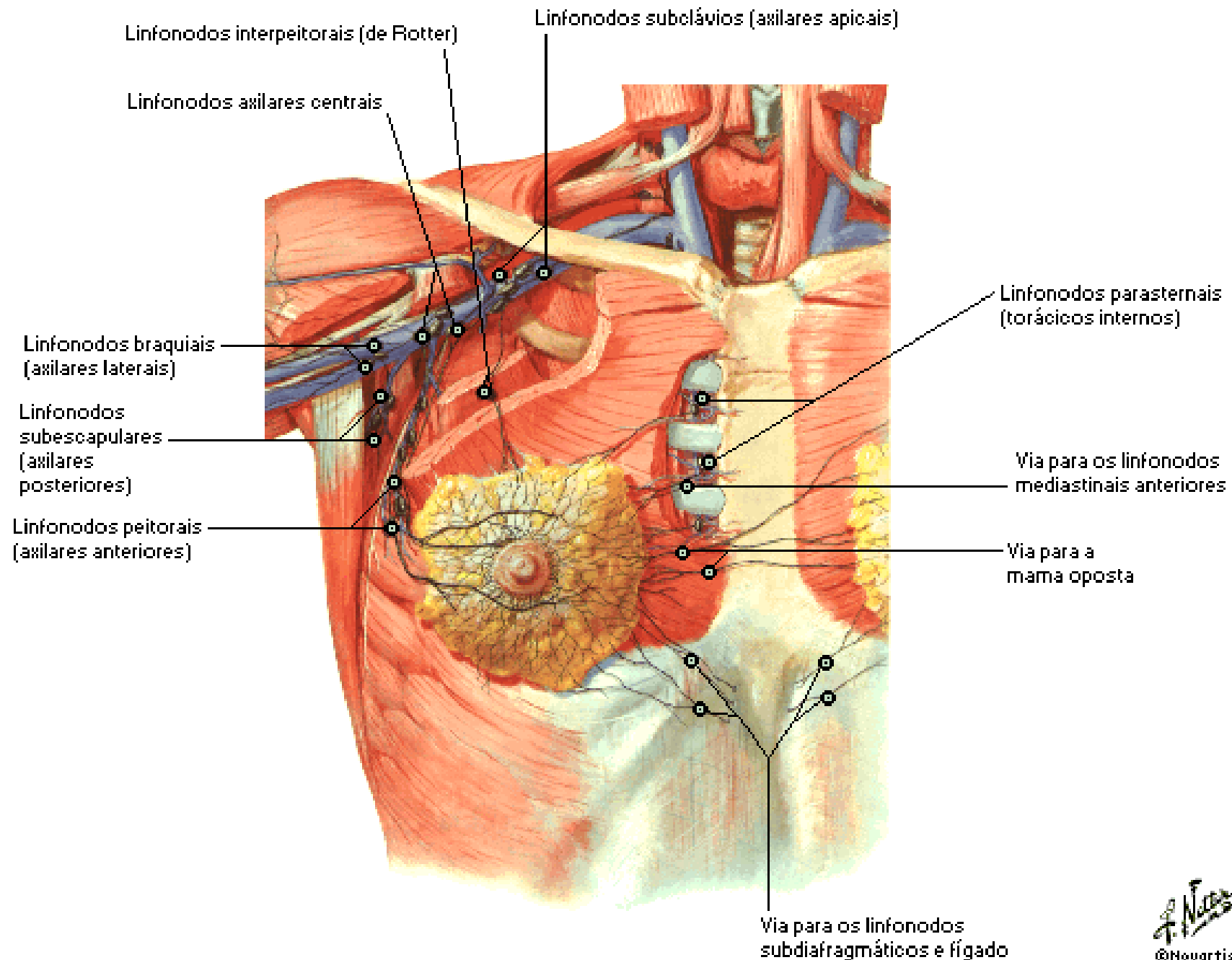
Secção Sagital



Artérias da Glândula Mamária

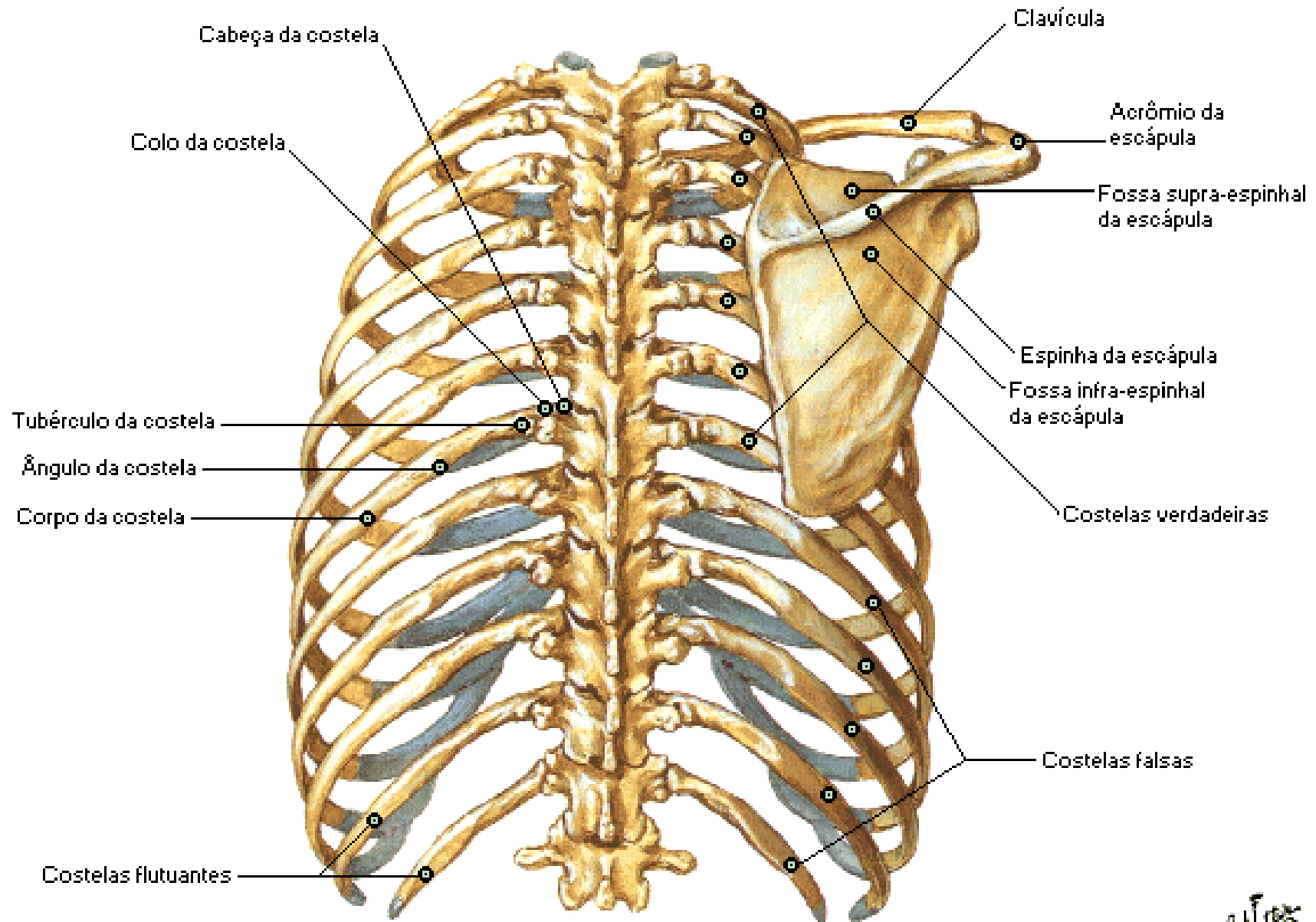


Vasos Linfáticos e Linfonodos da Glândula Mamária



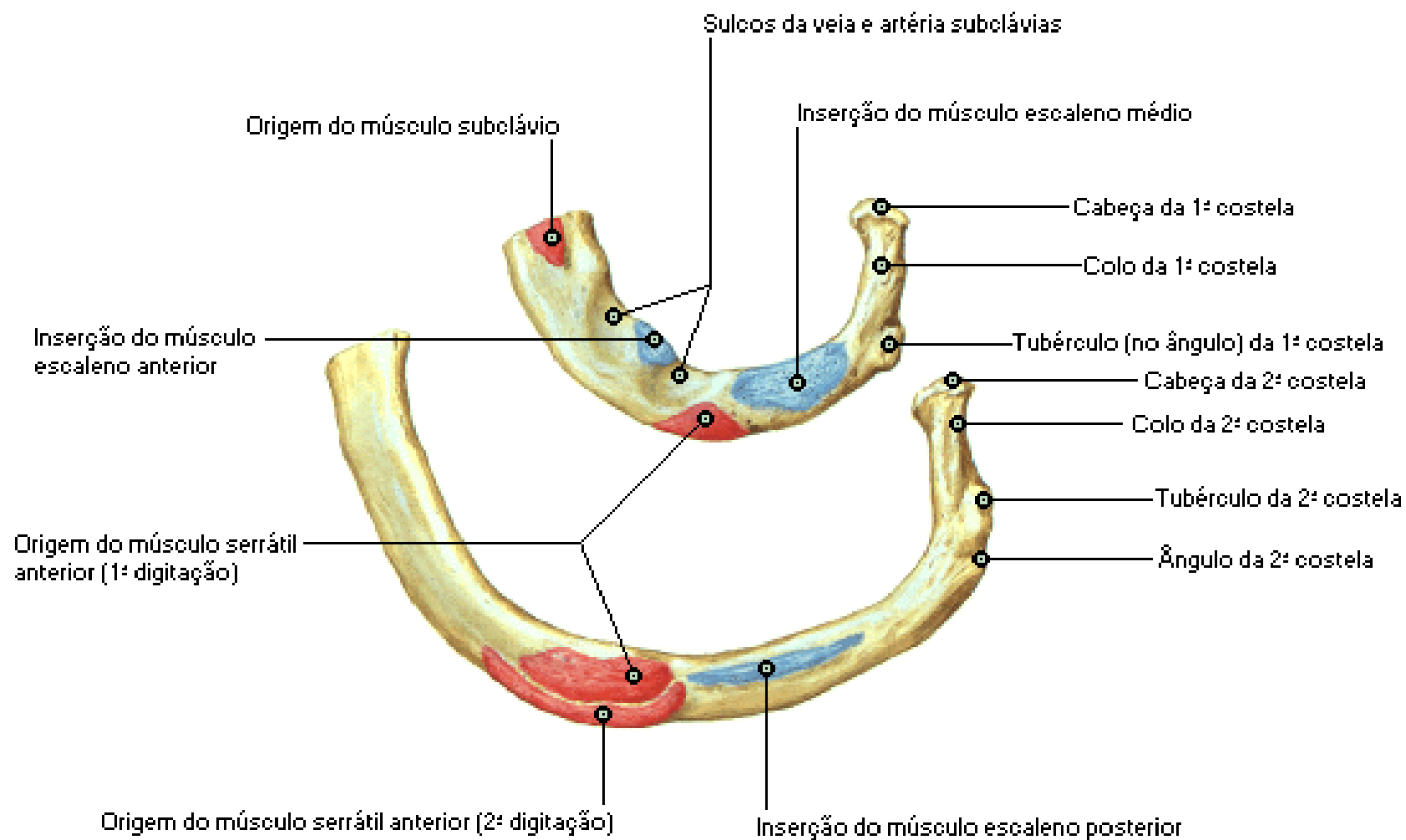
Arcabouço Ósseo do Tórax

Vista Posterior



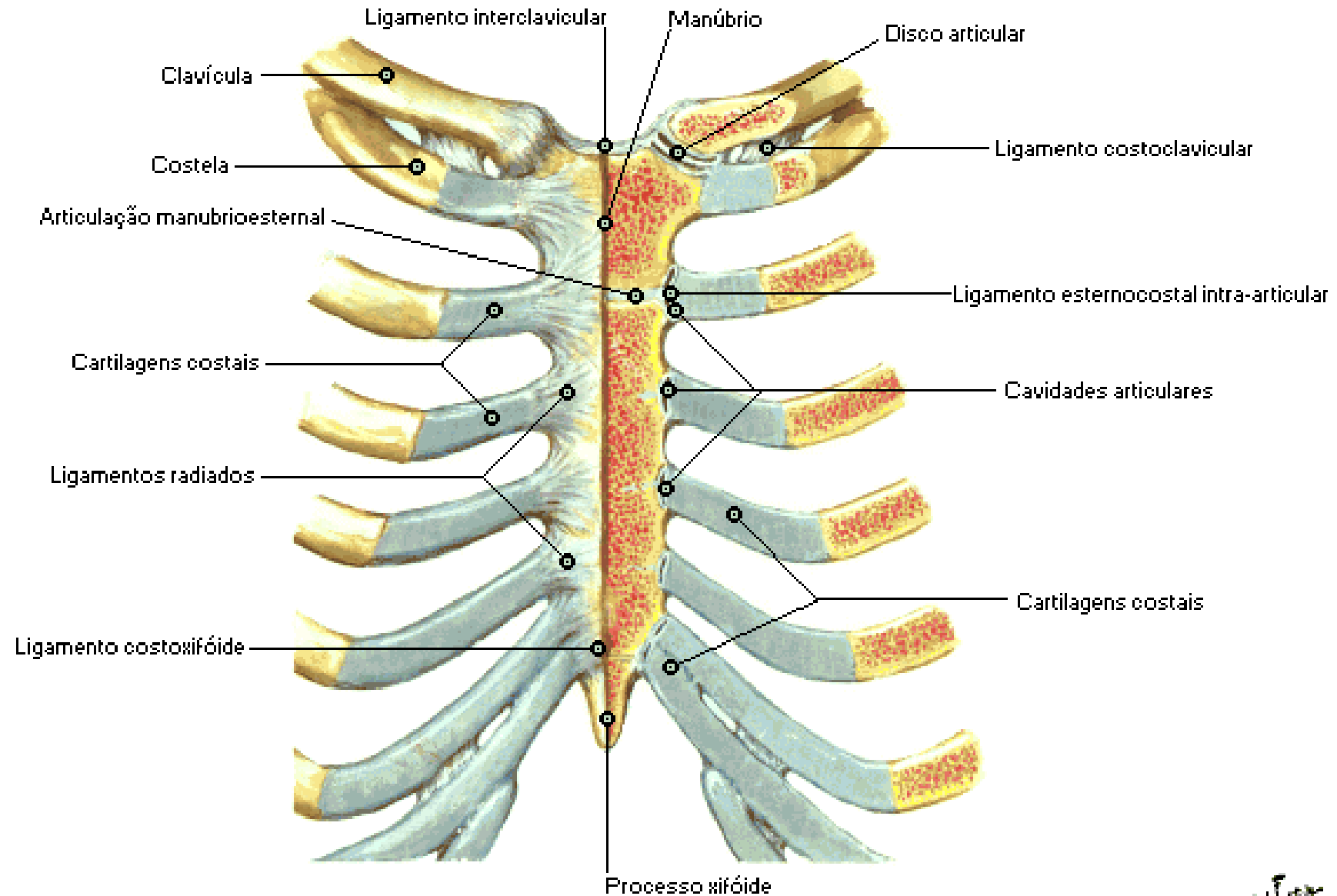
1ª e 2ª Costelas Esquerdas

Vistas Superiores



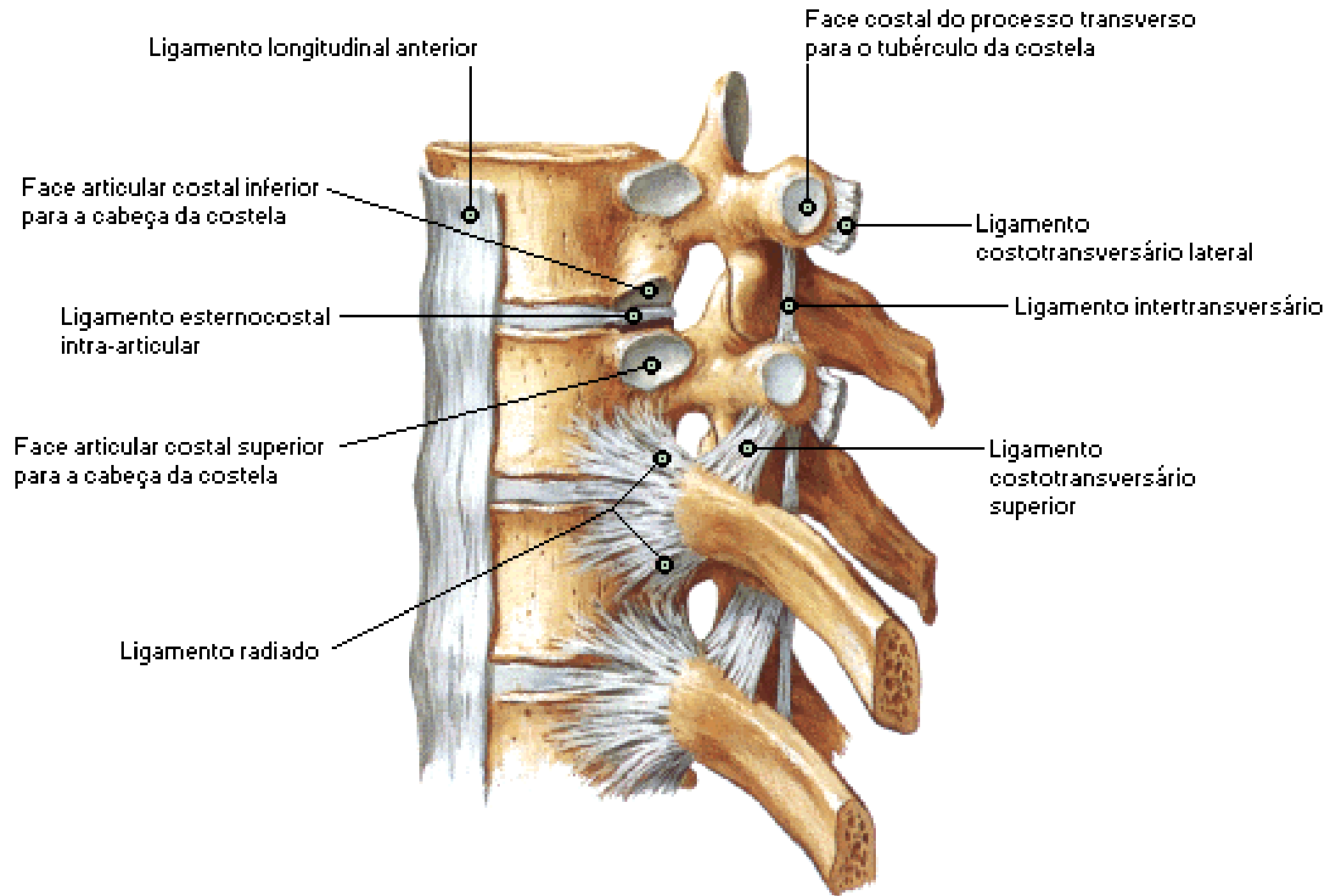
Articulações Esternocostais

Vista Anterior



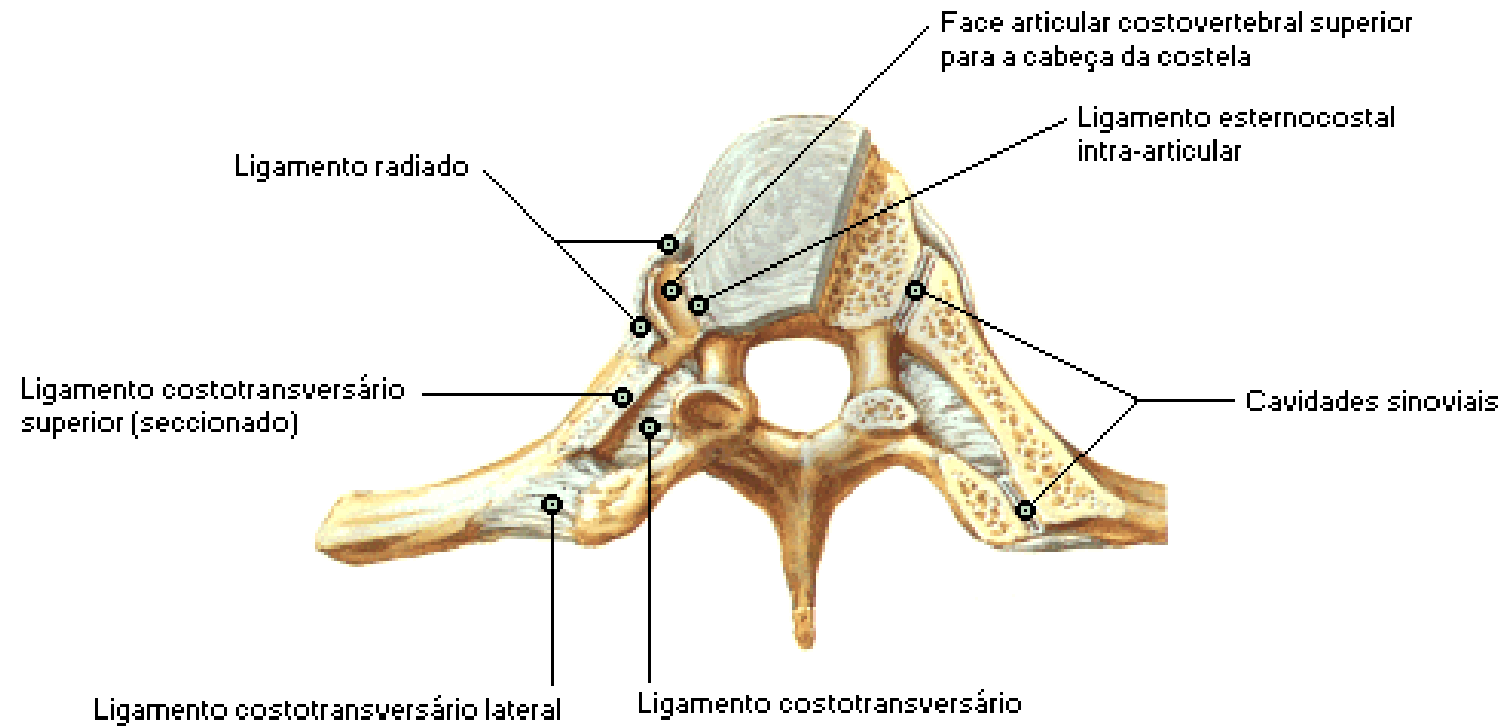
Articulações Costovertebrais

Vista Lateral Esquerda



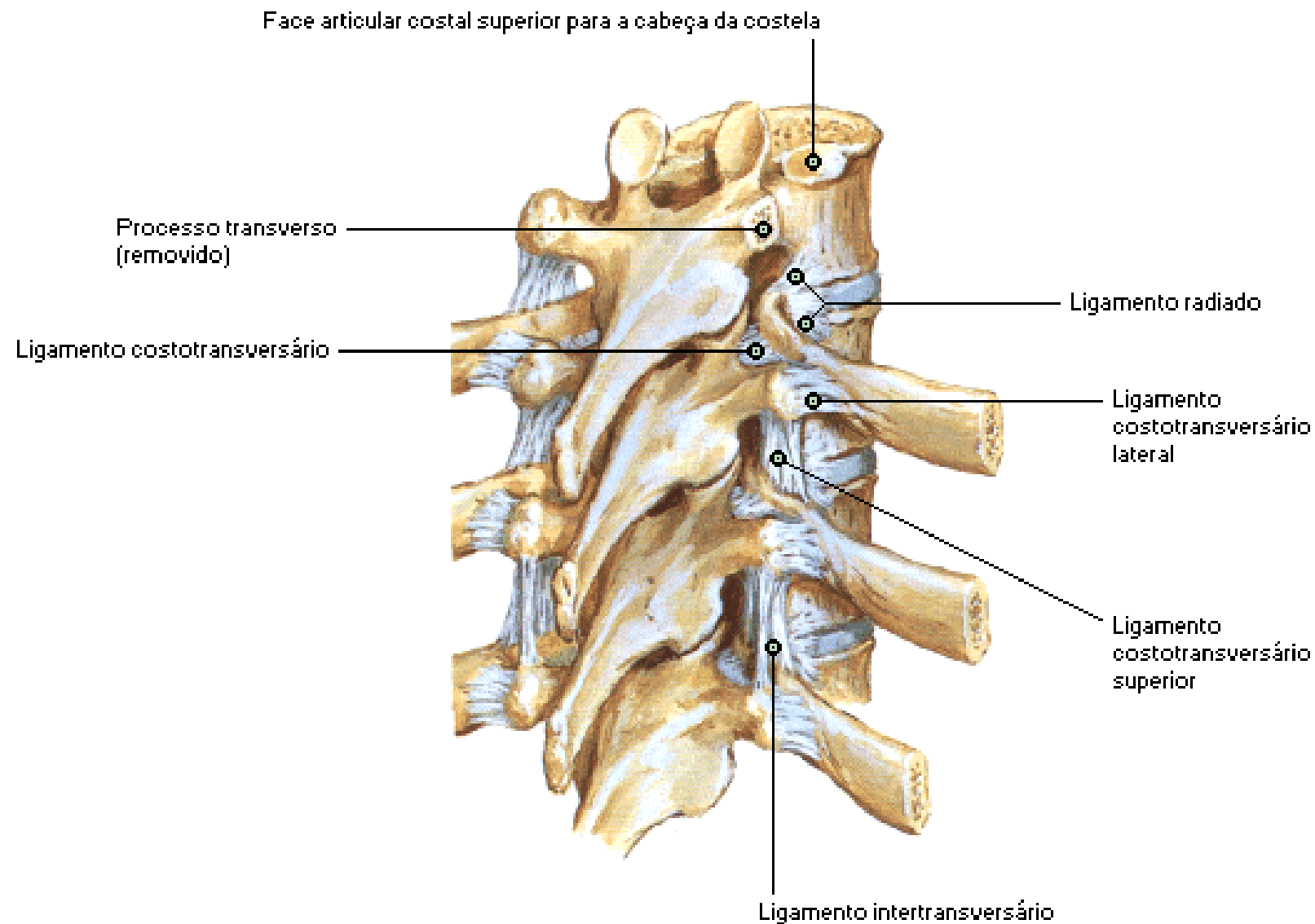
Articulações Costovertebrais

Secção Transversa: Vista Superior

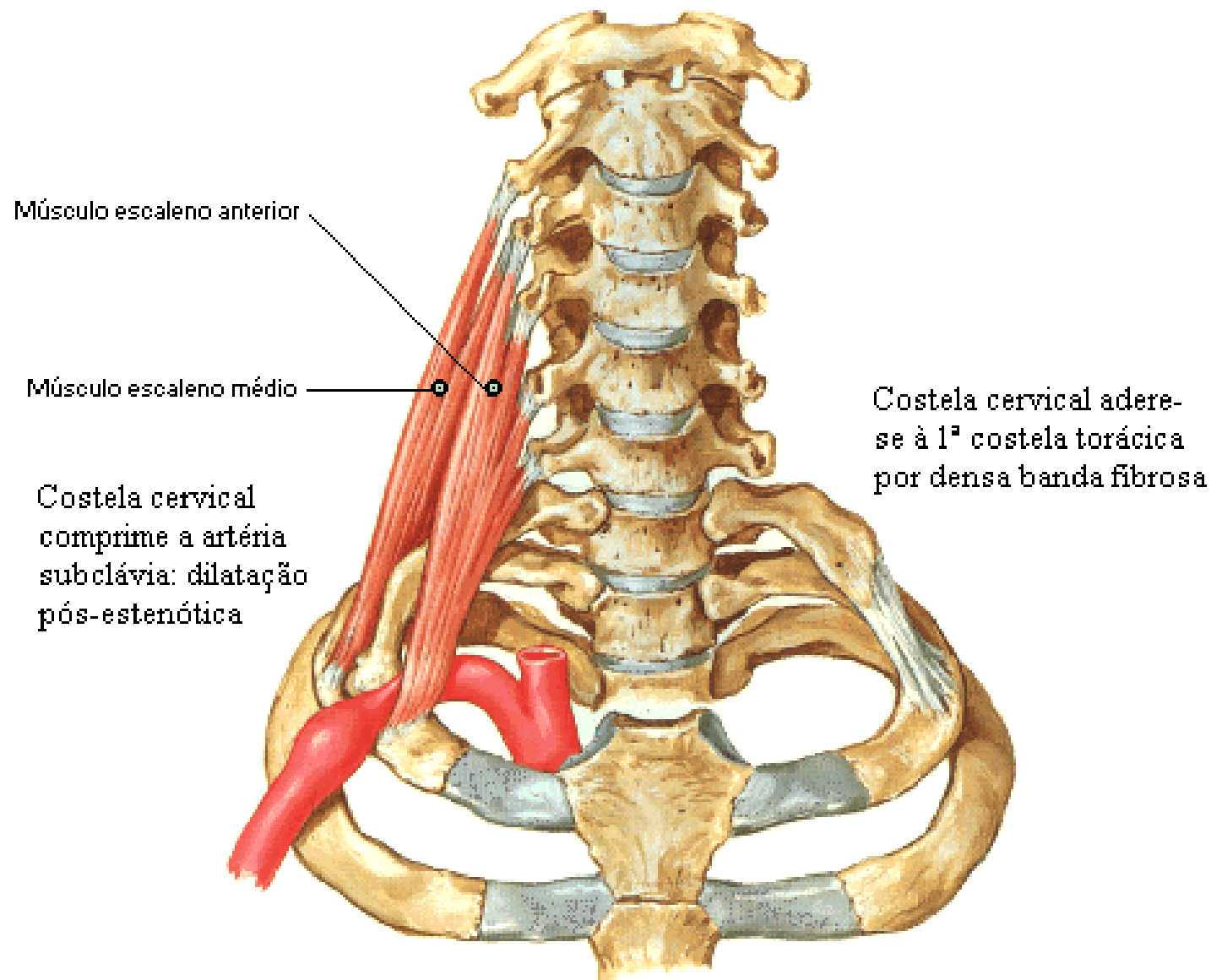


Articulações Costovertebrais

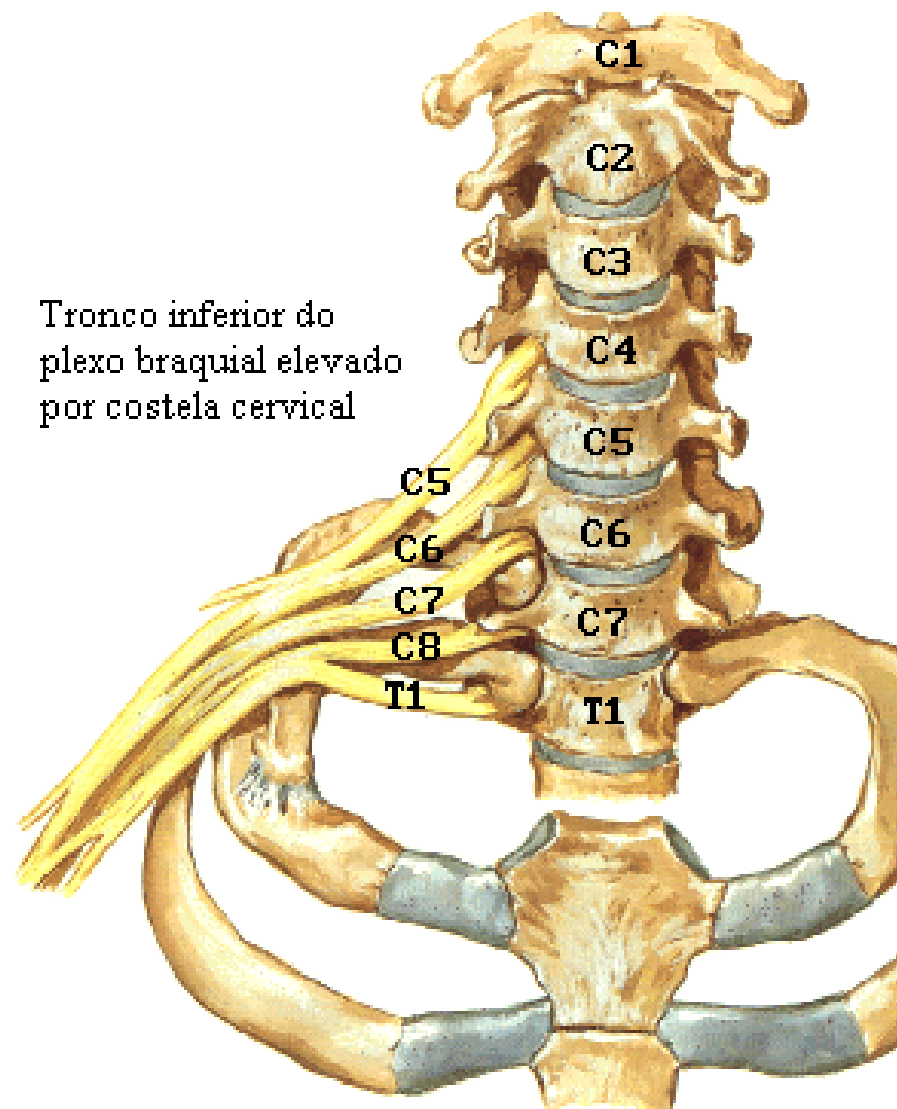
Vista Pósterio-lateral Direita



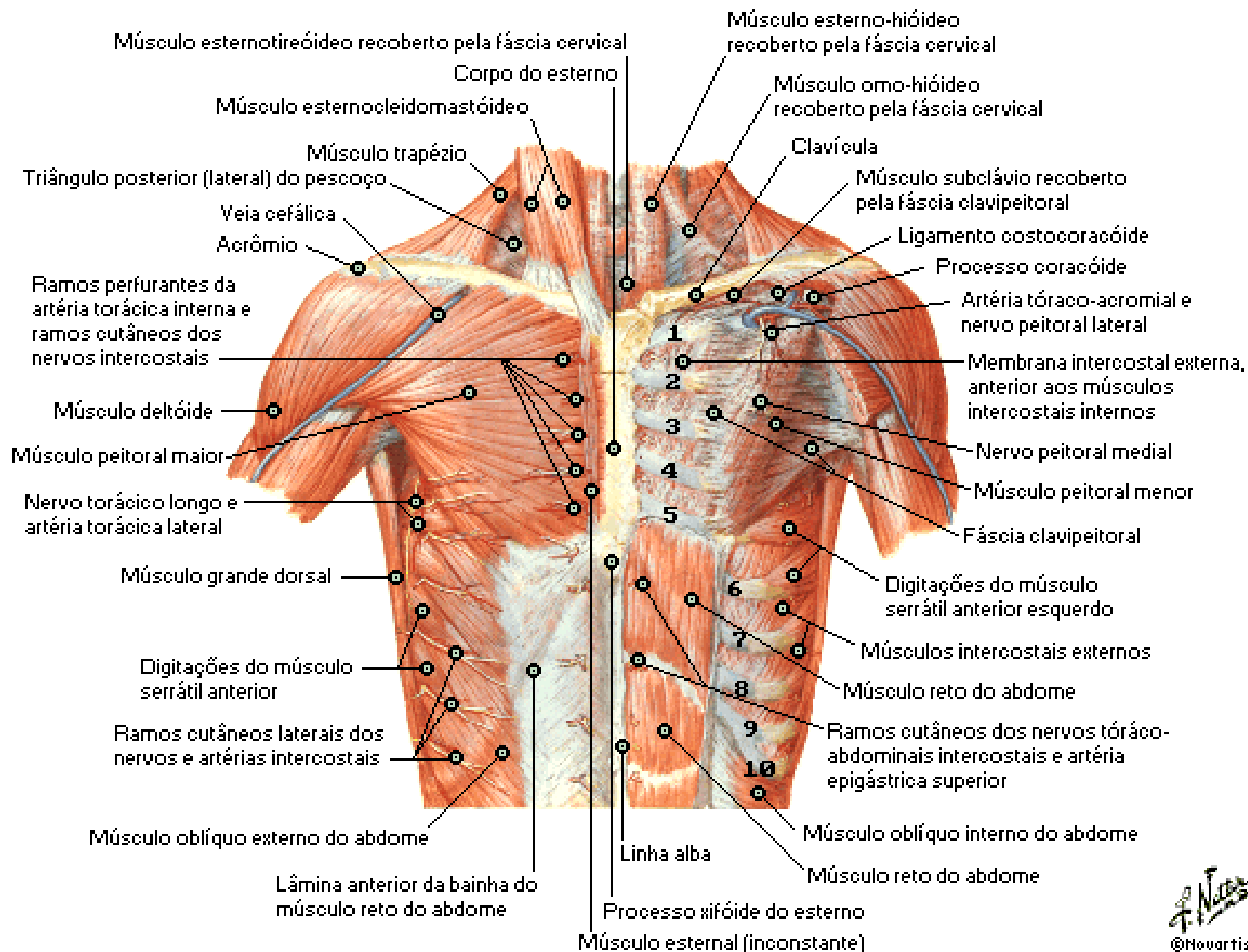
Costelas Cervicais e Anomalias Relacionadas



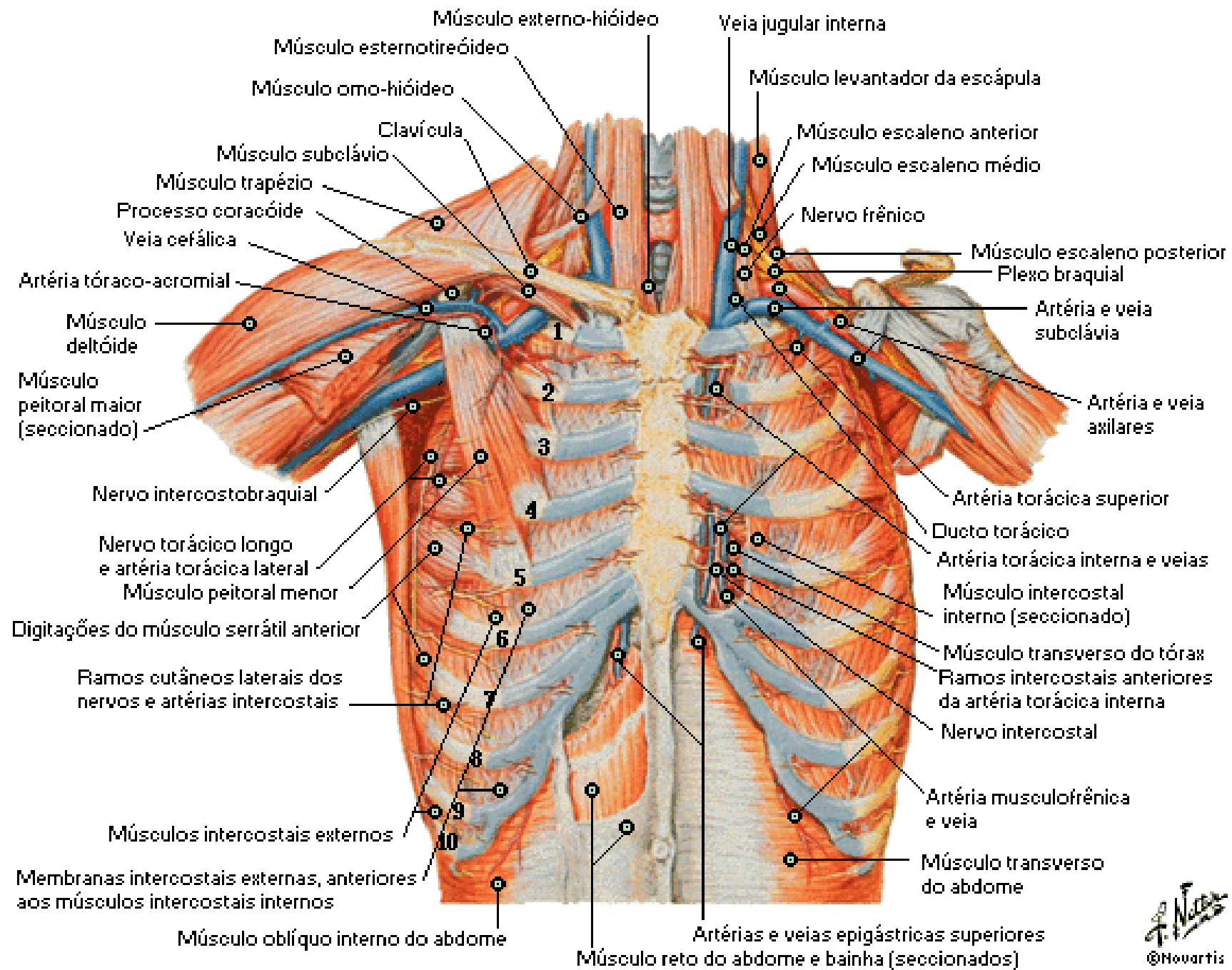
Costelas Cervicais e Anomalias Relacionadas



Parede Anterior do Tórax

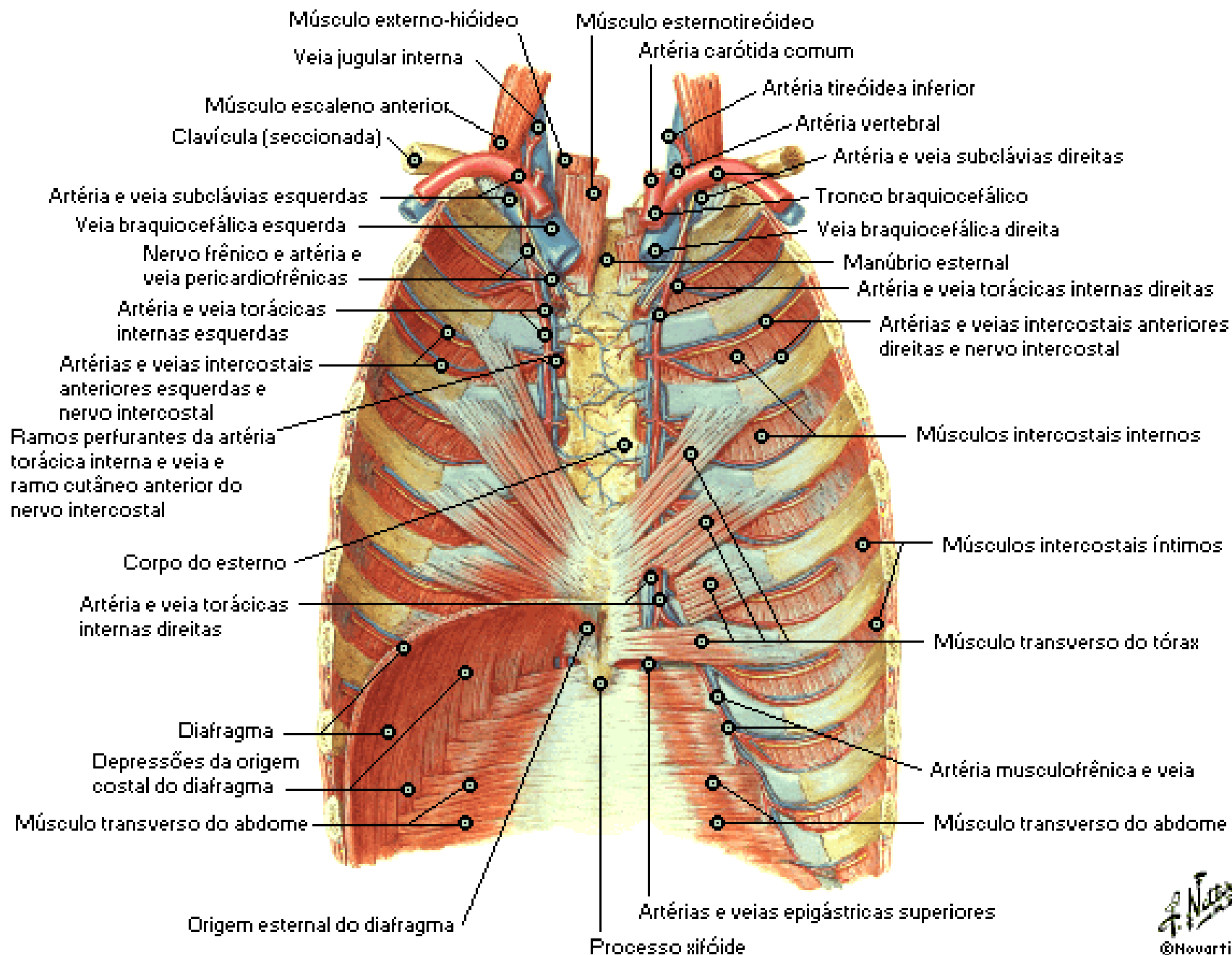


Parede Anterior do Tórax [Continuação]

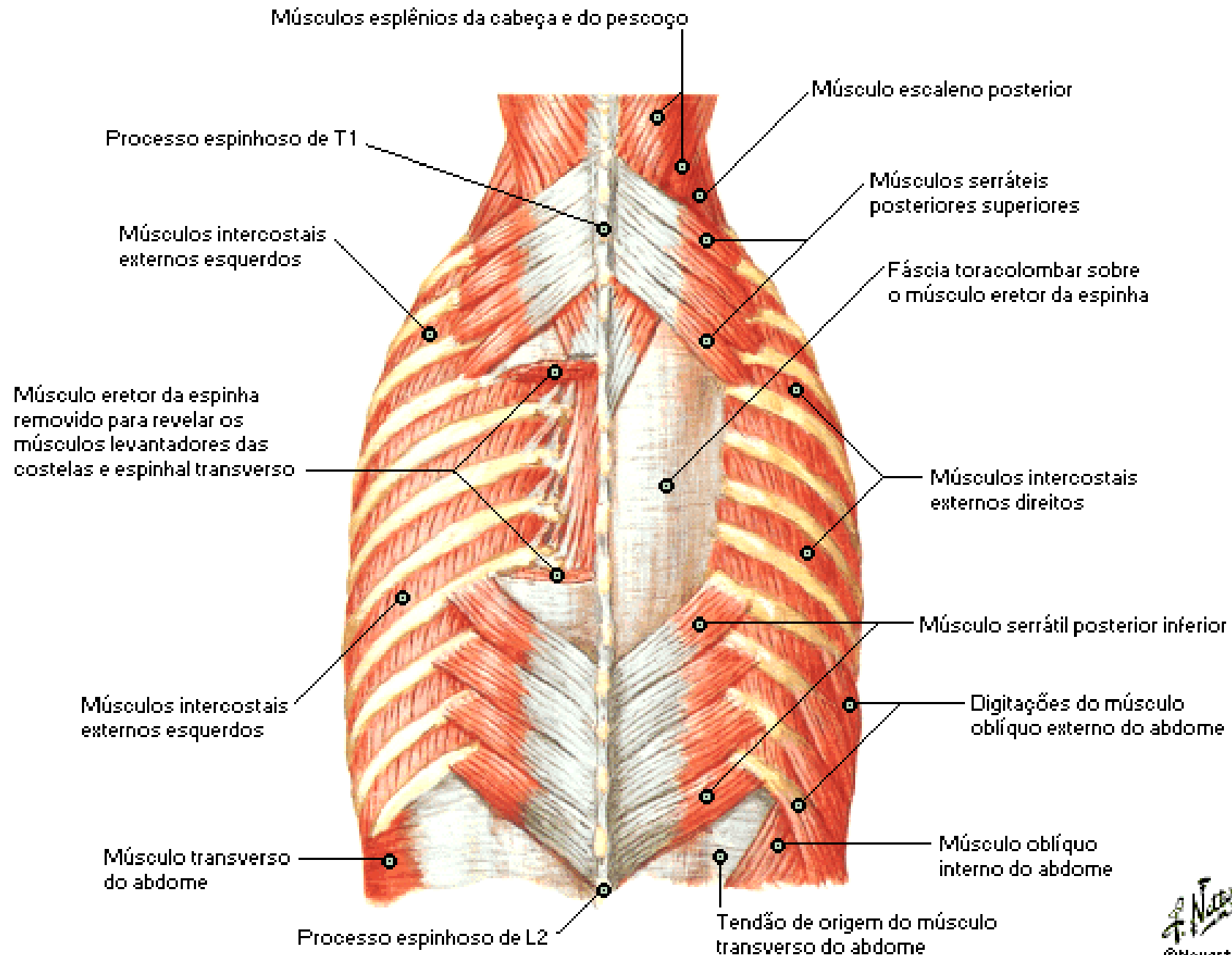


Parede Anterior do Tórax

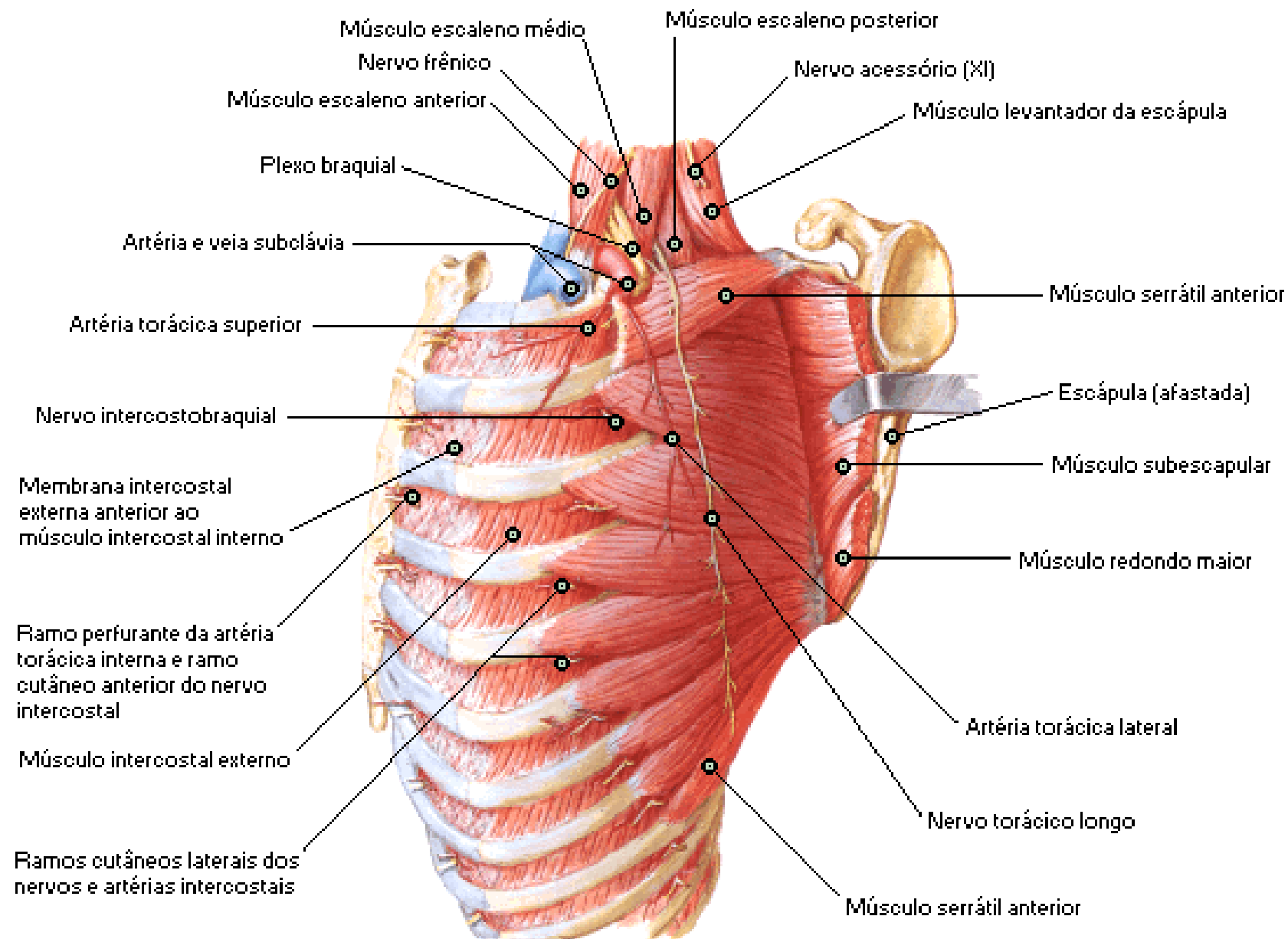
Vista Interna



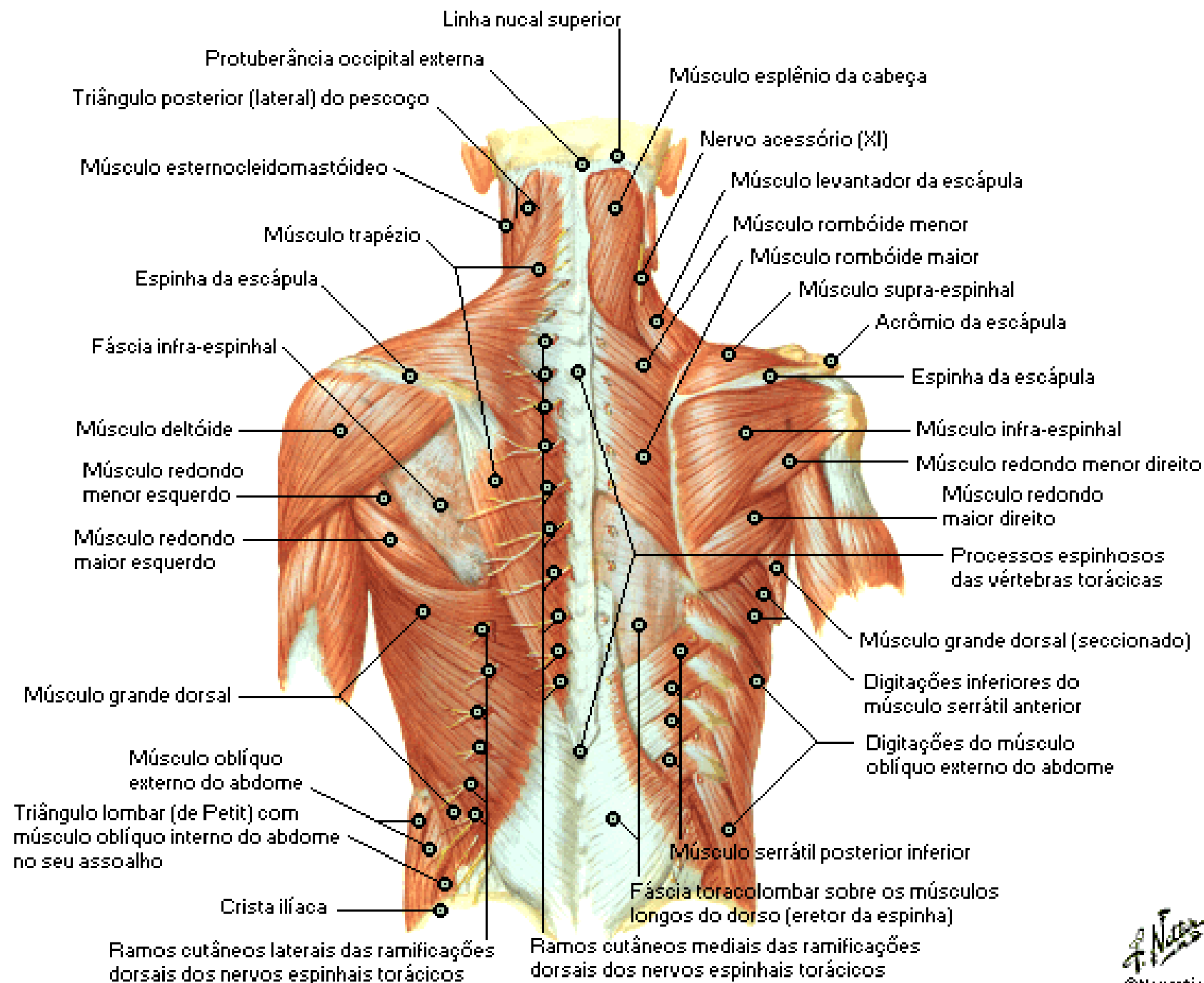
Parede Posterior do Tórax



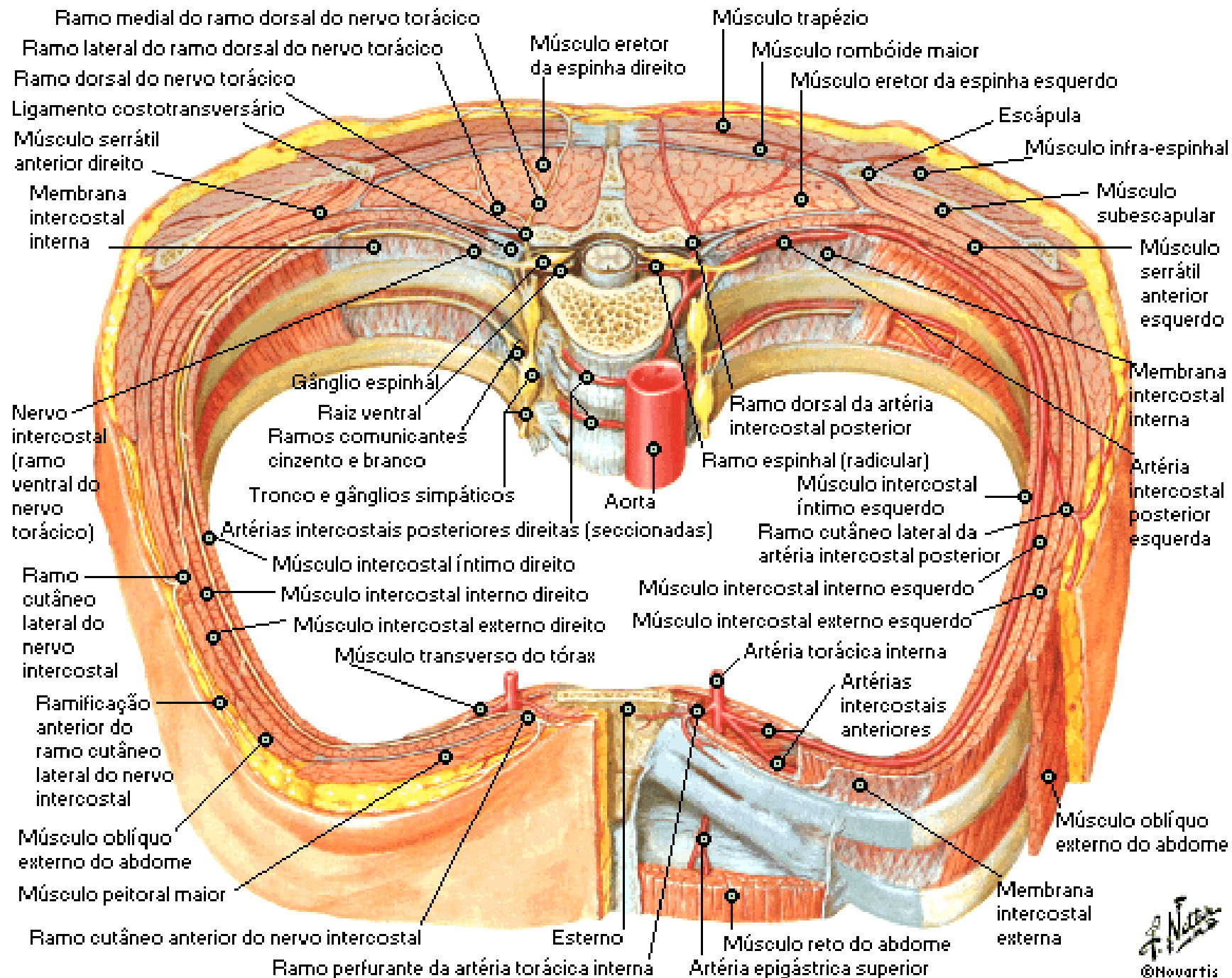
Parede Lateral do Tórax



Parede Posterior do Tórax

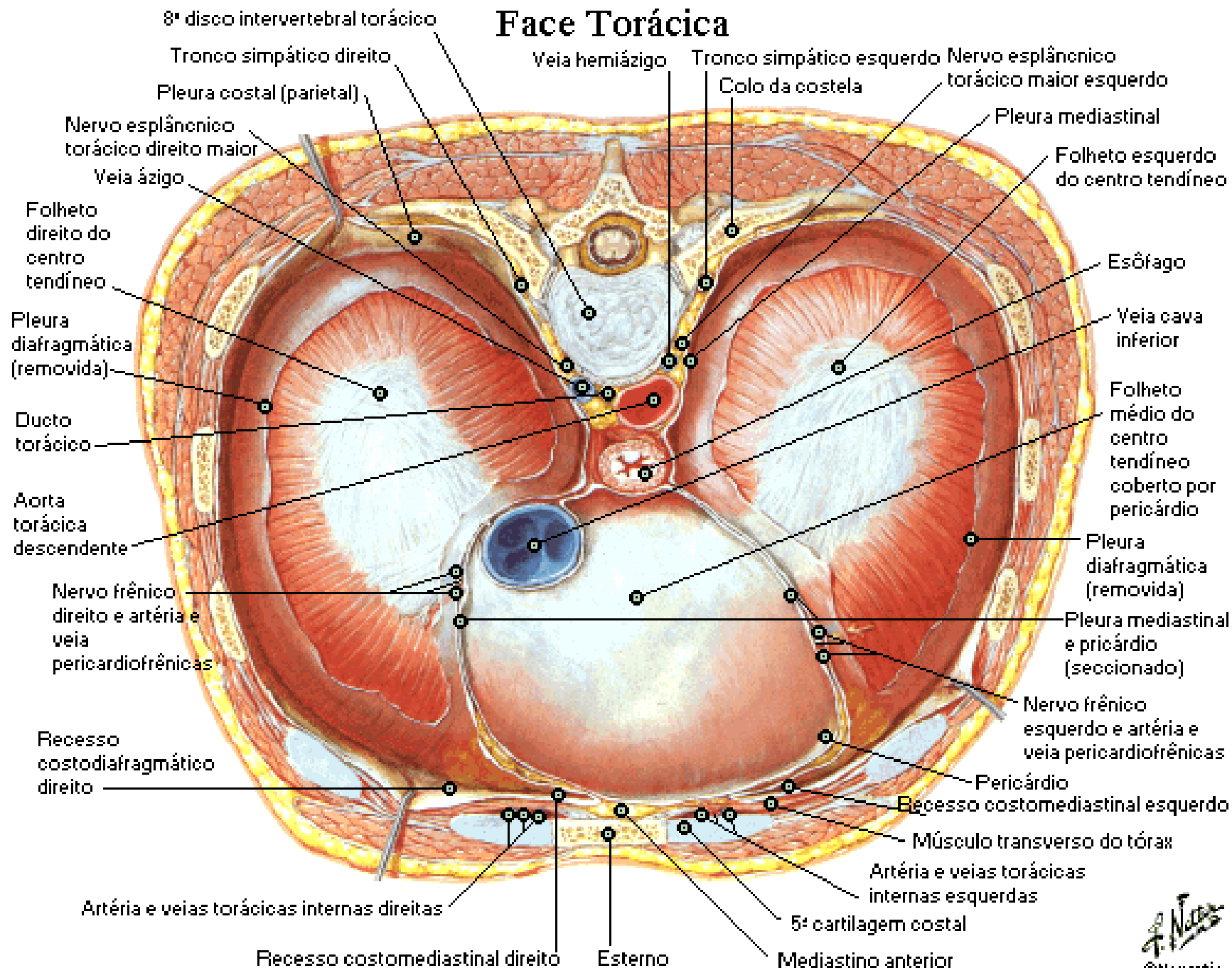


Nervos e Artérias Intercostais



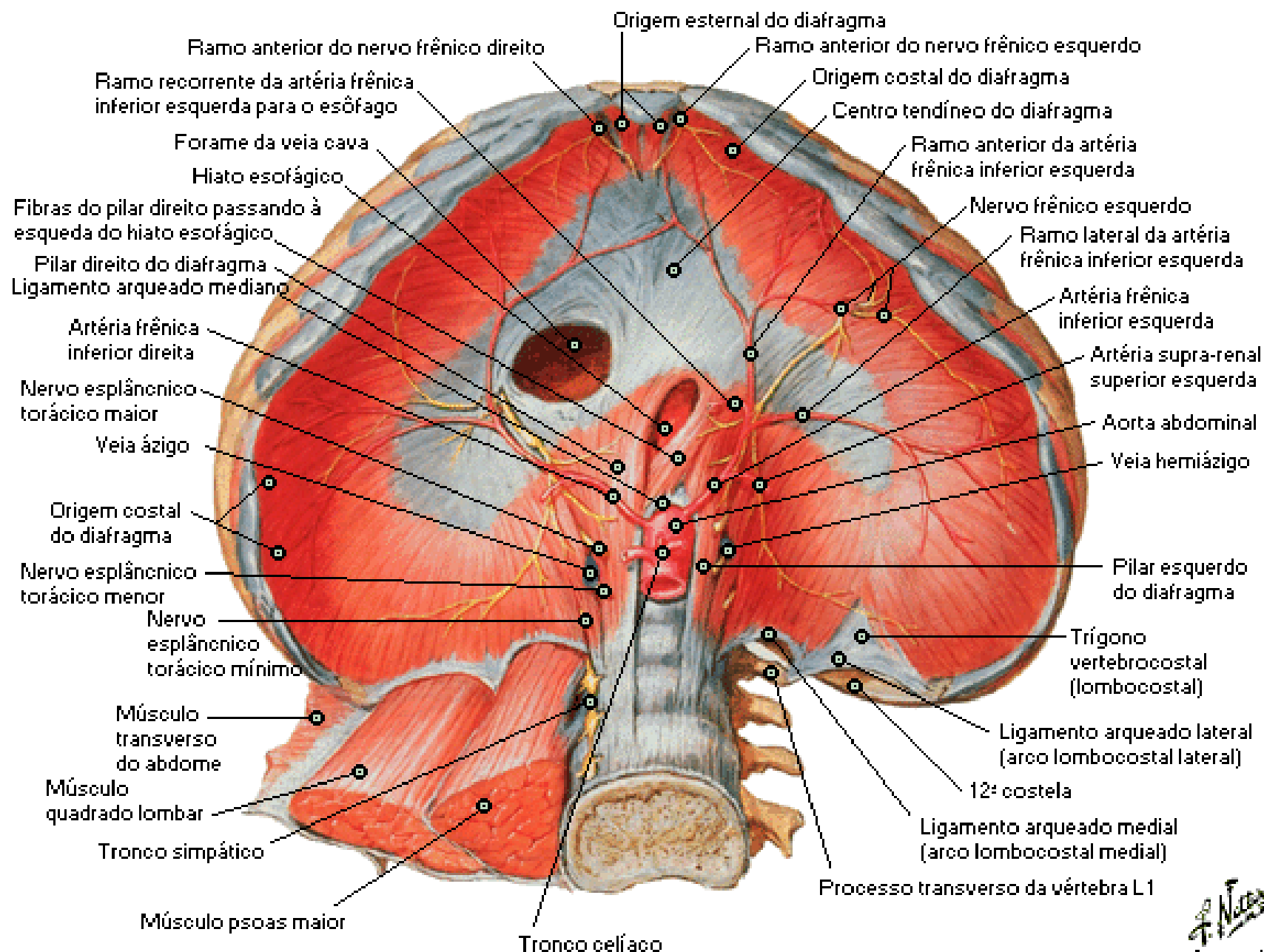
Diafragma

Face Torácica

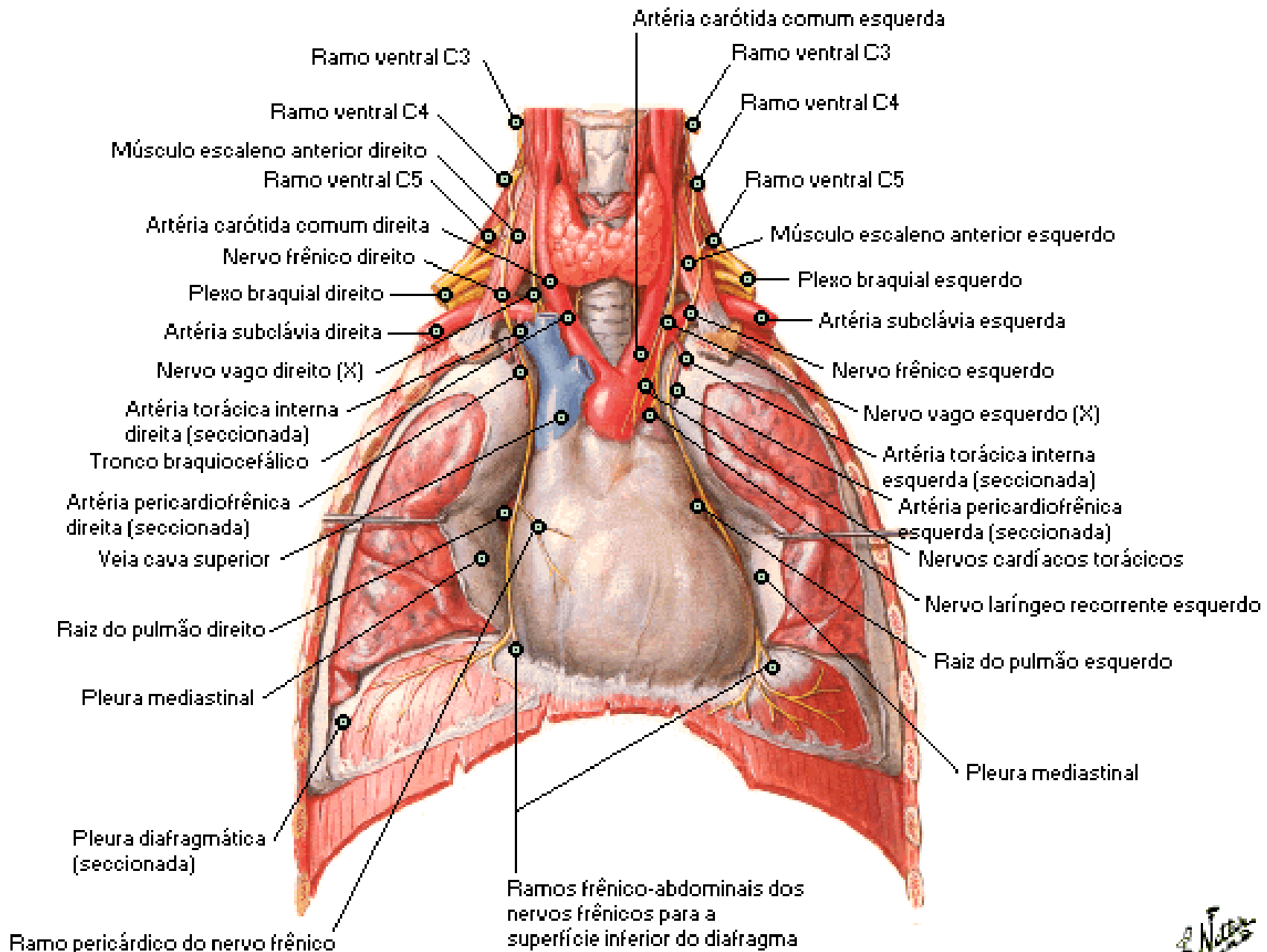


Diafragma

Face Abdominal

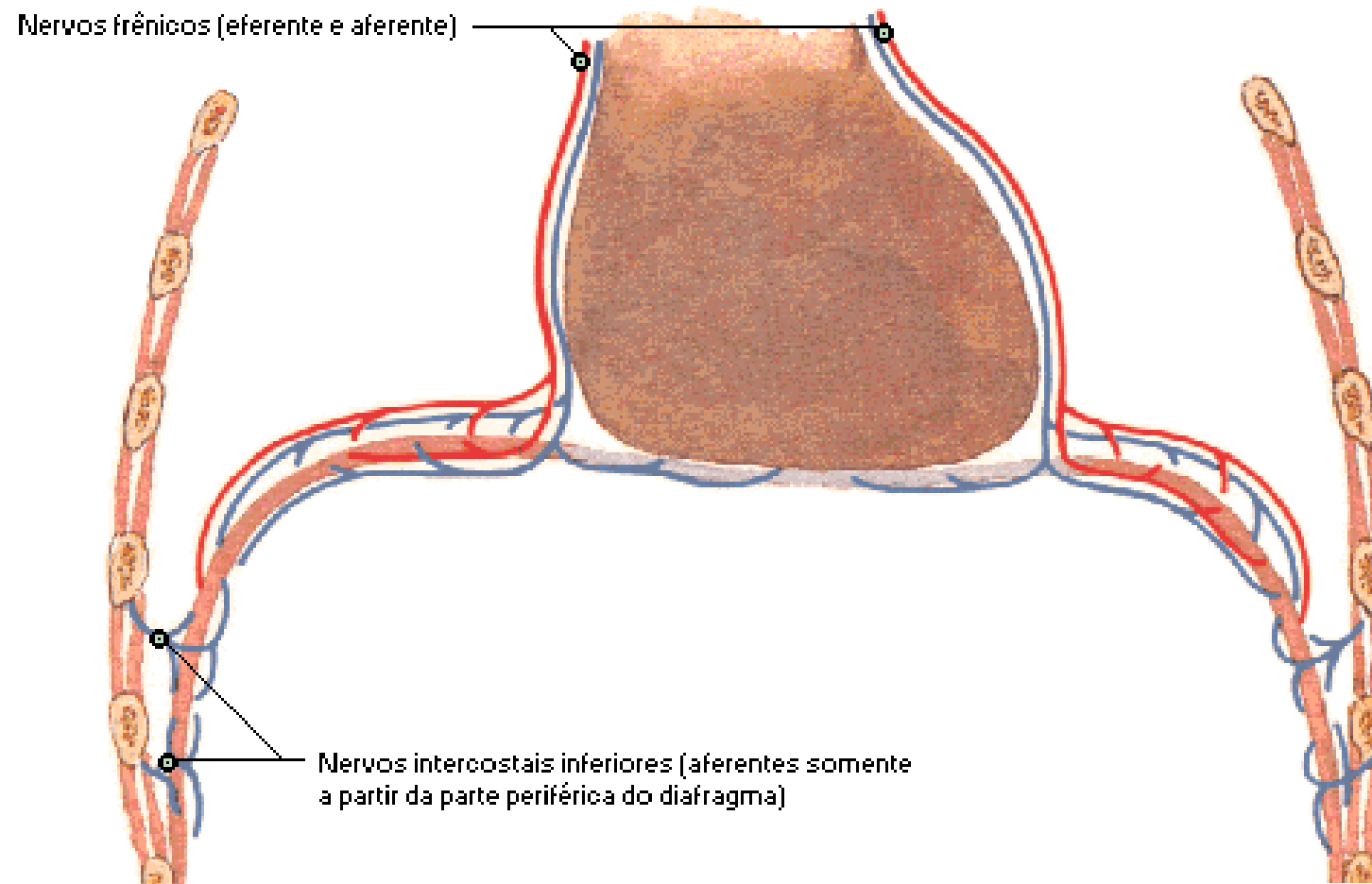


Nervo Frênico in Situ



Nervo Frênico

Esquema



Músculos da inspiração

Músculos da Respiração

Músculos de expiração

Acessórios

Esternocleidomastóideo

Esternocleidomastóideo - Este músculo acessório de inspiração eleva o esterno

Escaleno médio

Escaleno anterior

Escaleno posterior

Escalenos - Estes músculos acessórios de inspiração elevam e fixam as costelas superiores

Principais

Intercostais externos

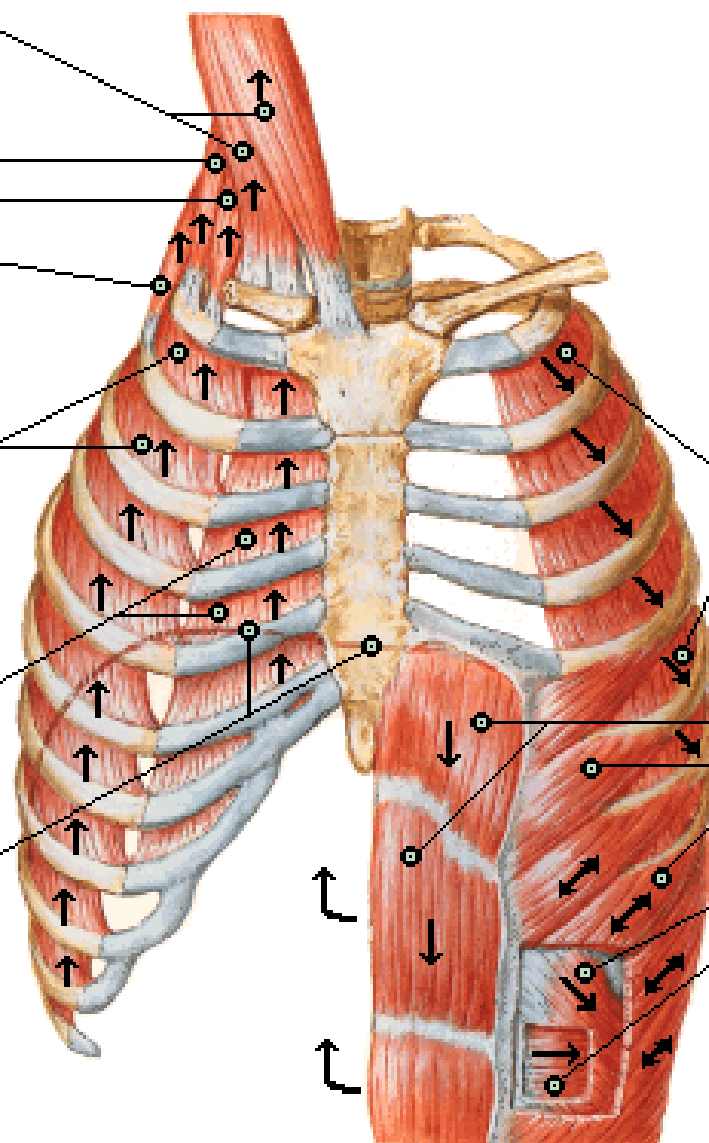
Intercostais externos - Estes músculos principais de inspiração elevam as costelas, ampliando assim a largura da cavidade torácica

Parte intercondral dos intercostais internos

Parte intercondral - Esta parte atua como um músculo principal de inspiração ao elevar as costelas

Diafragma

Diafragma - As cúpulas deste músculo principal de inspiração descem, aumentando assim a dimensão longitudinal da cavidade torácica. O diafragma também auxilia na elevação das costelas inferiores



Expiração quiesscente

A expiração resulta da retração passiva dos pulmões

Expiração ativa

Intercostais internos, exceto parte intercondral

Intercostais internos - Estes músculos de expiração ativa, abaixo das costelas, diminuem a largura da cavidade torácica

Reto do abdome

Oblíquo externo

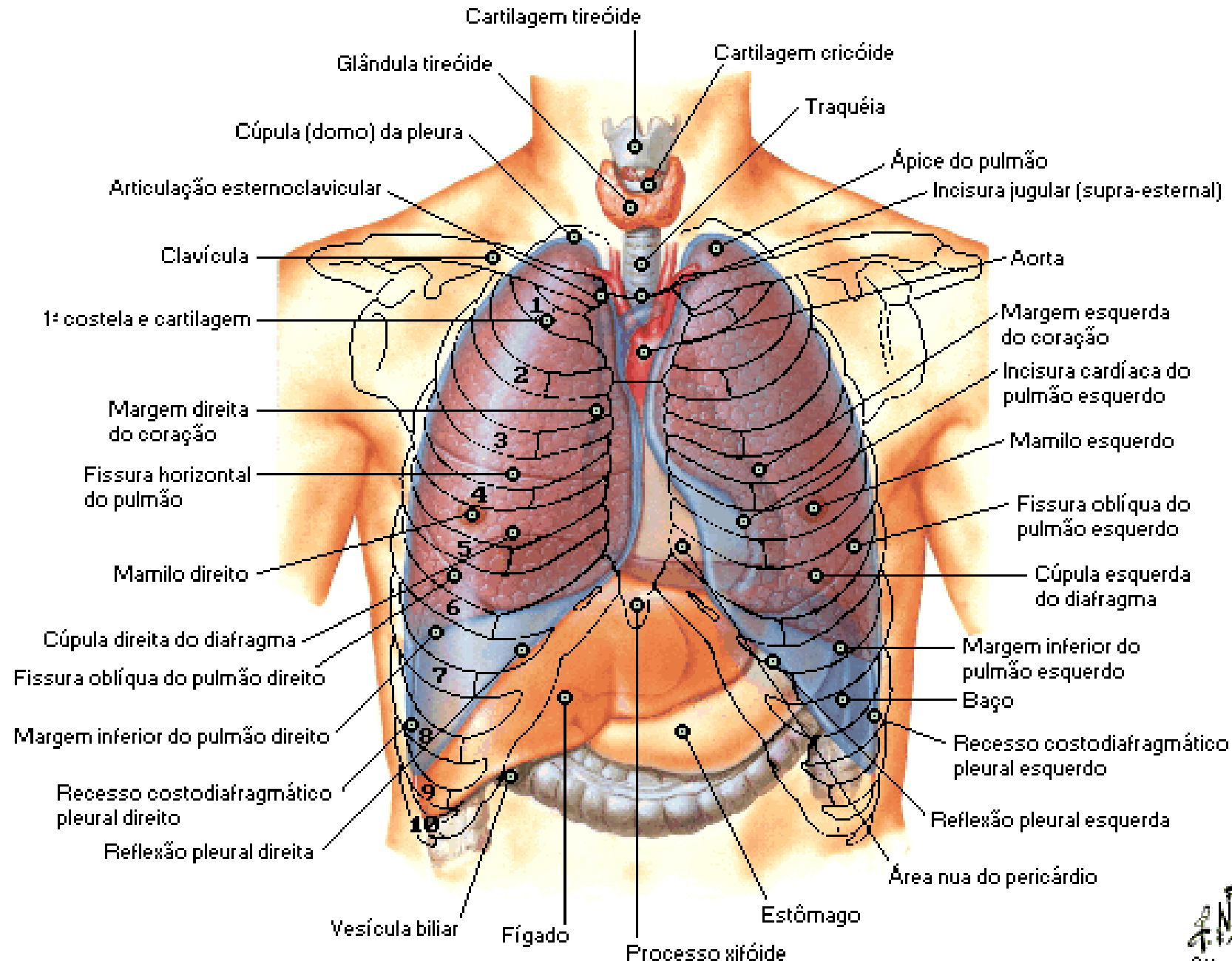
Oblíquo interno

Transverso do abdome

Este músculo de expiração ativa abaixa as costelas inferiores e comprime o conteúdo abdominal, deslocando assim o diafragma para cima

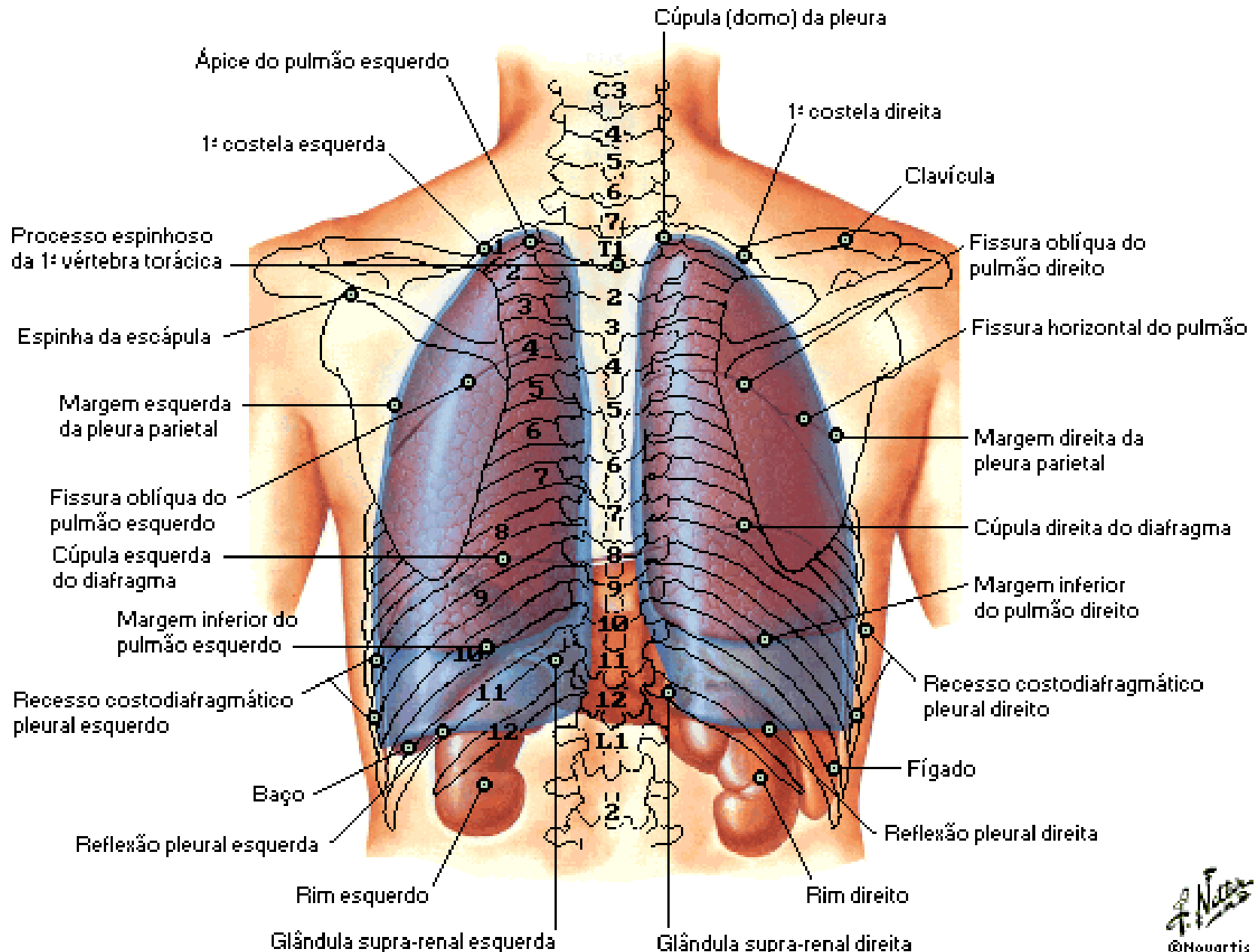
Topografia dos Pulmões

Vista Anterior



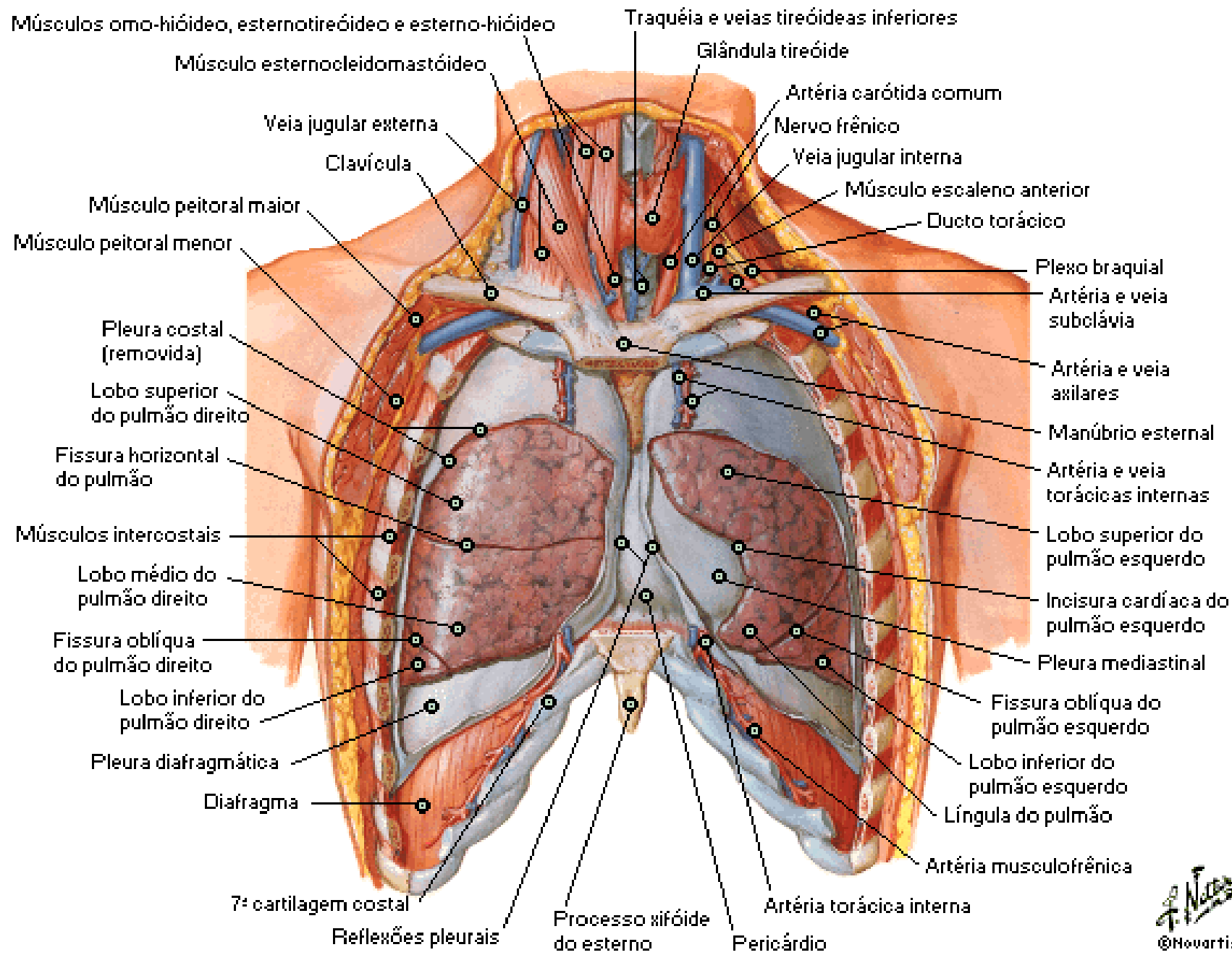
Topografia dos Pulmões

Vista Posterior



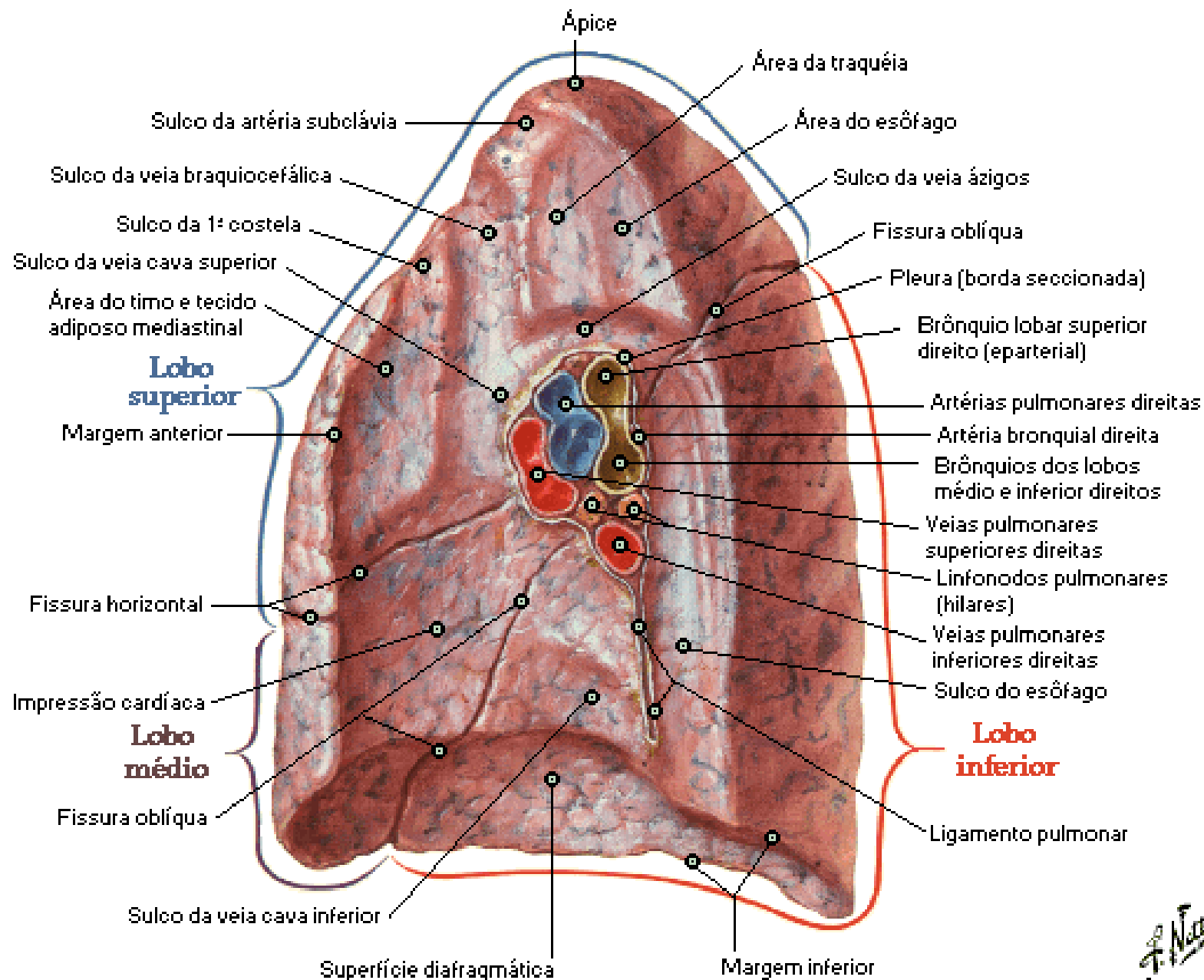
Pulmões in Situ

Vista Anterior



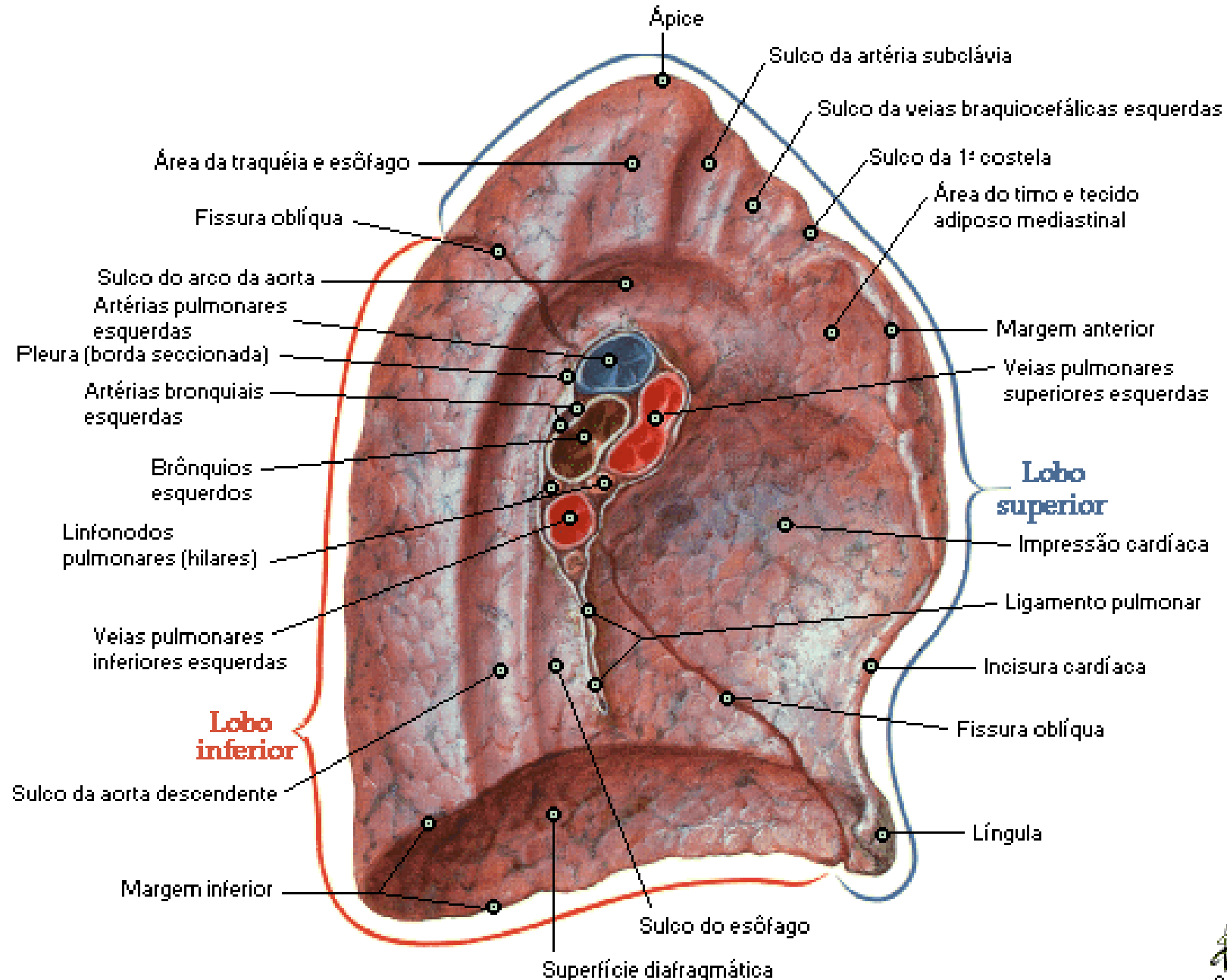
Pulmão Direito

Vista Medial



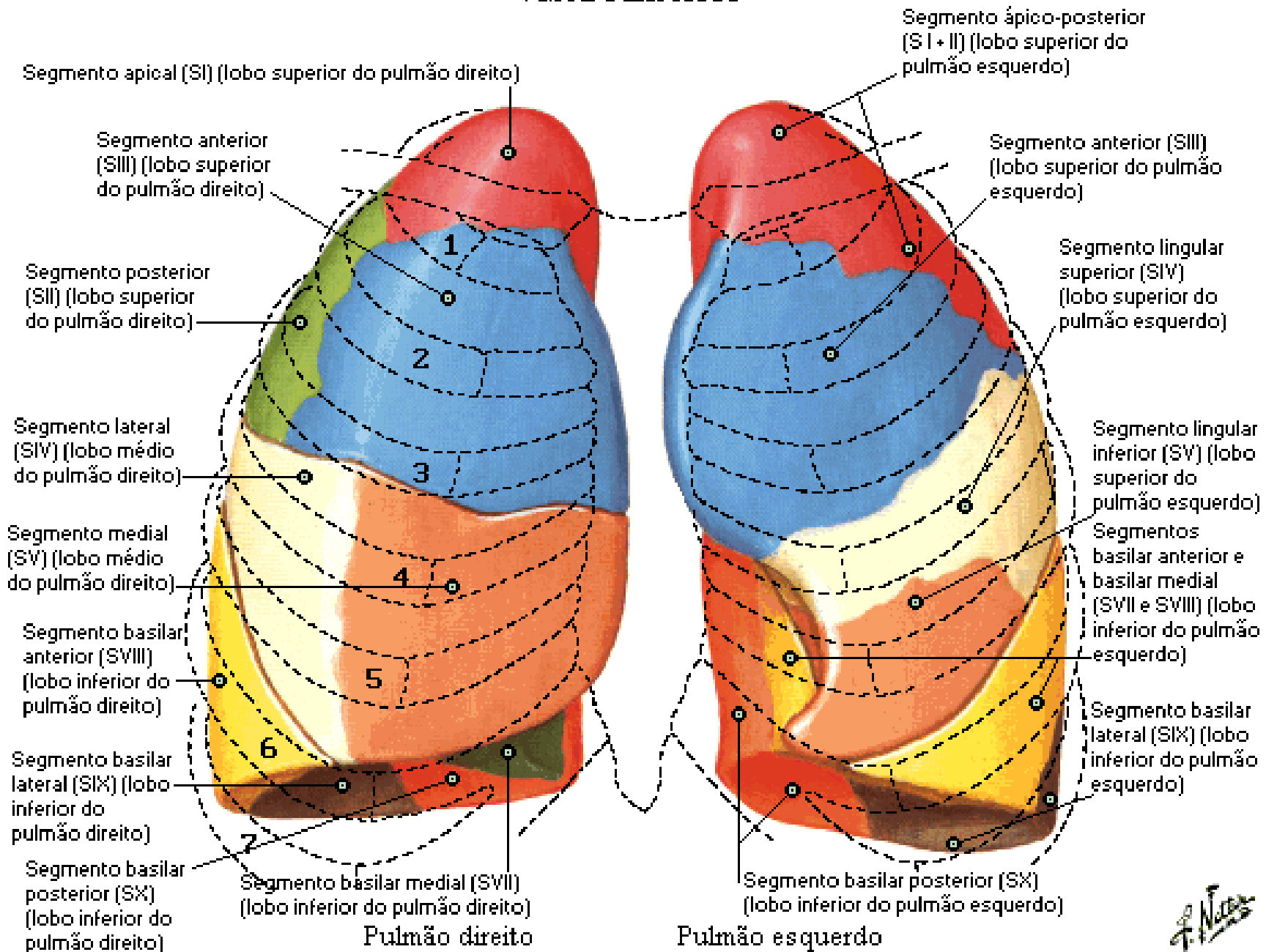
Pulmão Esquerdo

Vista Medial



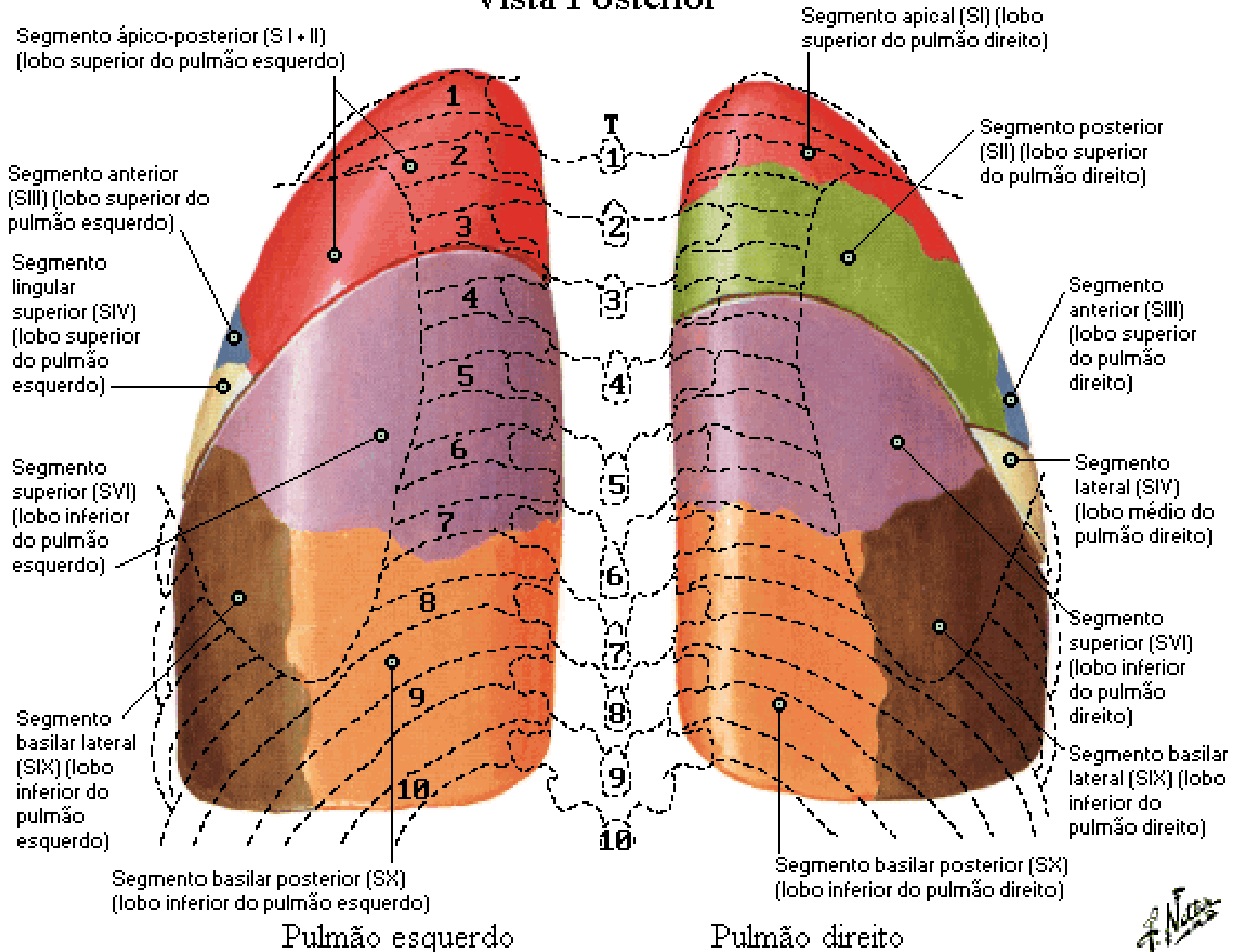
Segmentos Broncopulmonares

Vista Anterior



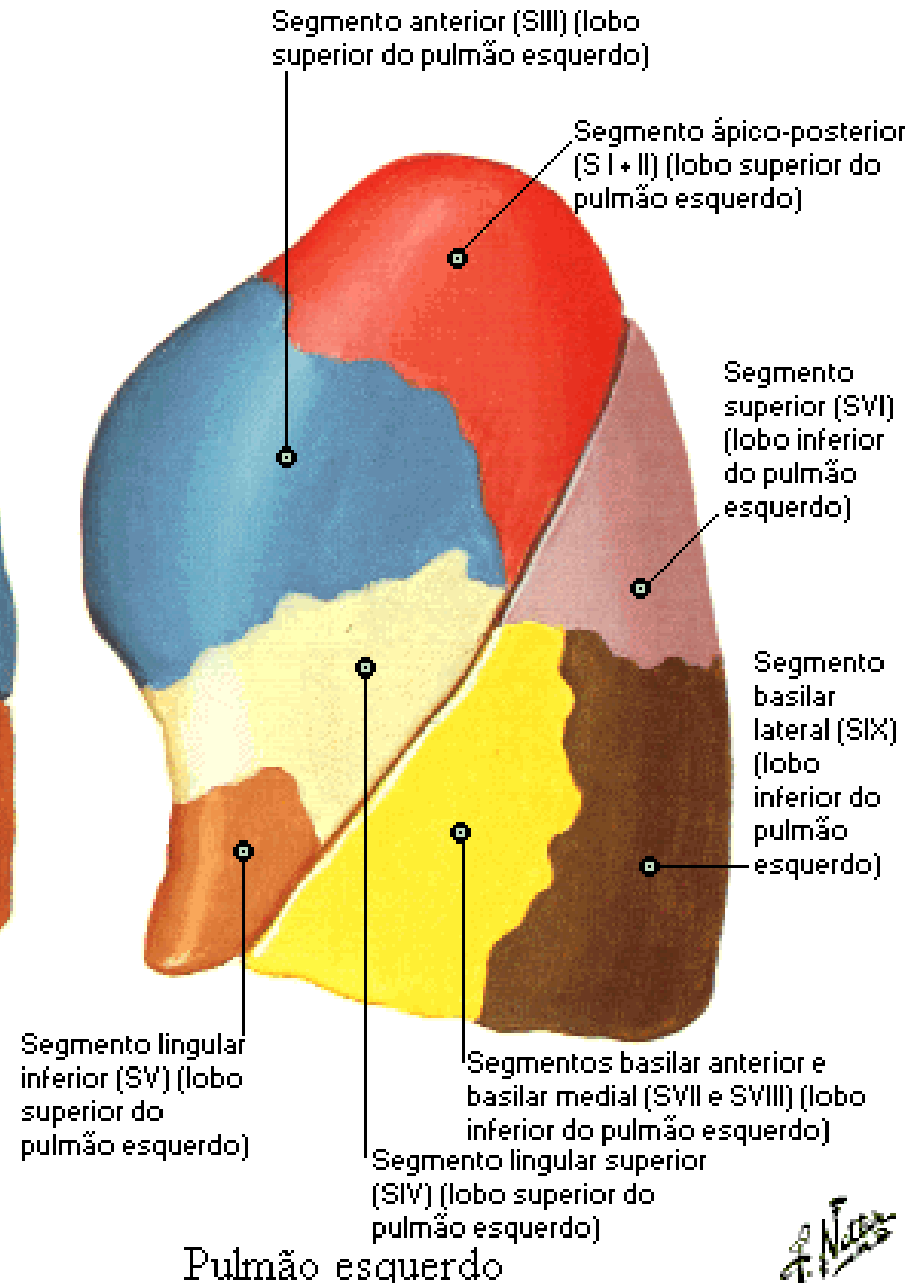
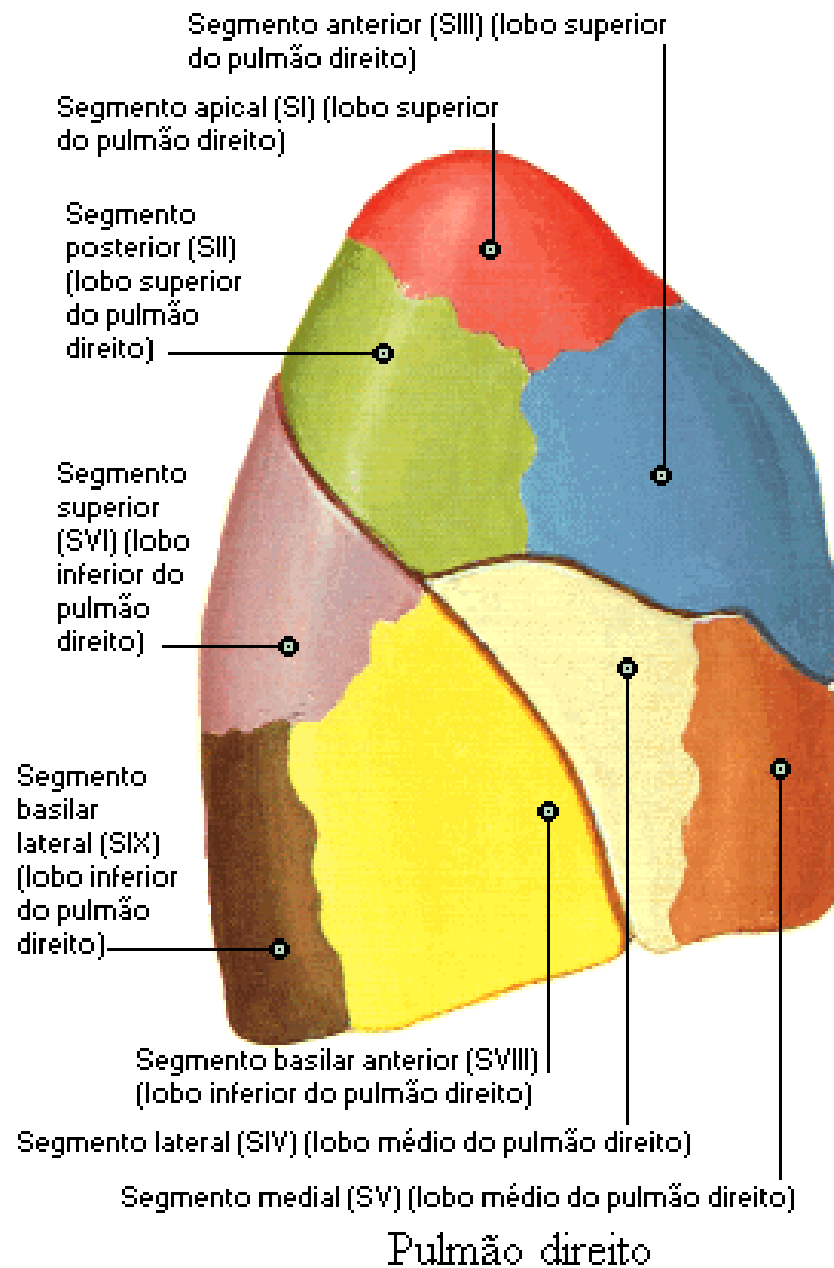
Segmentos Broncopulmonares

Vista Posterior



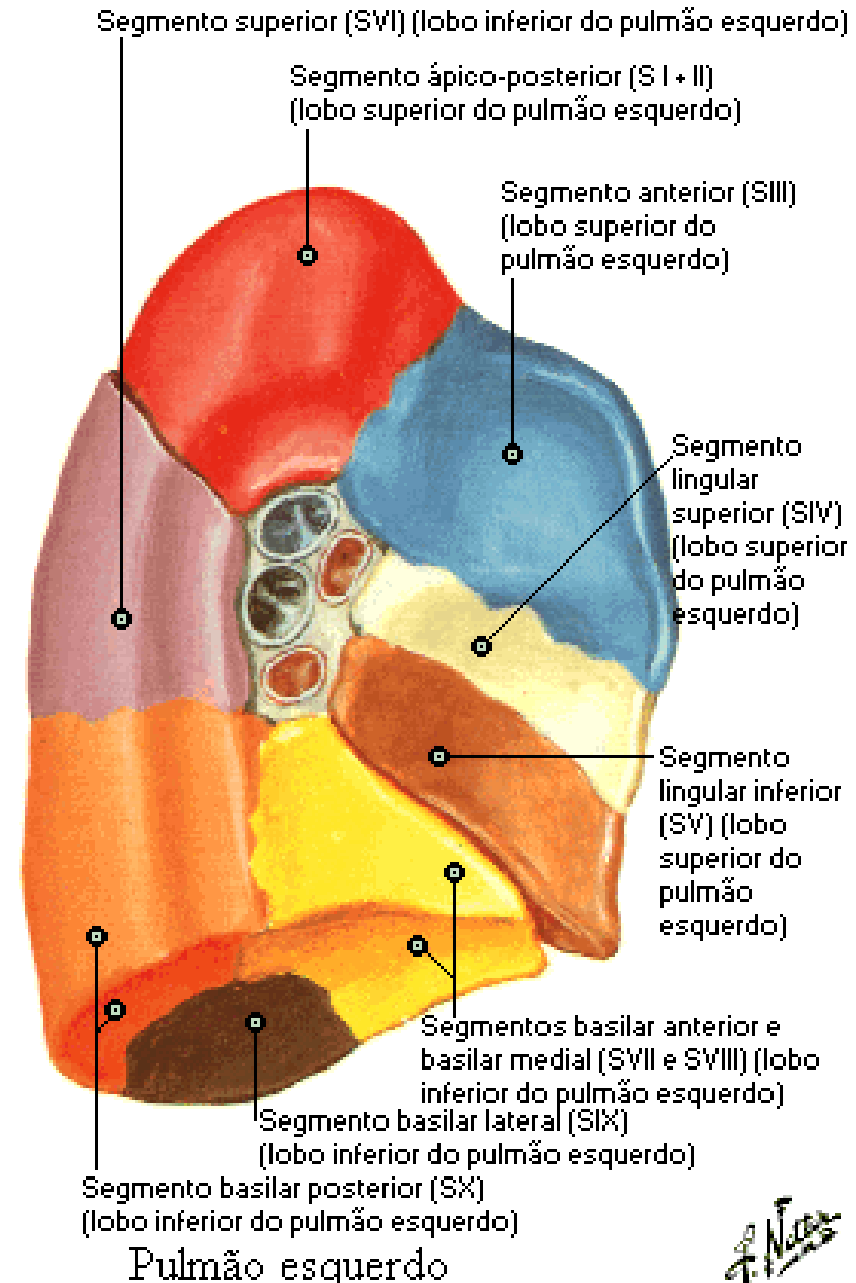
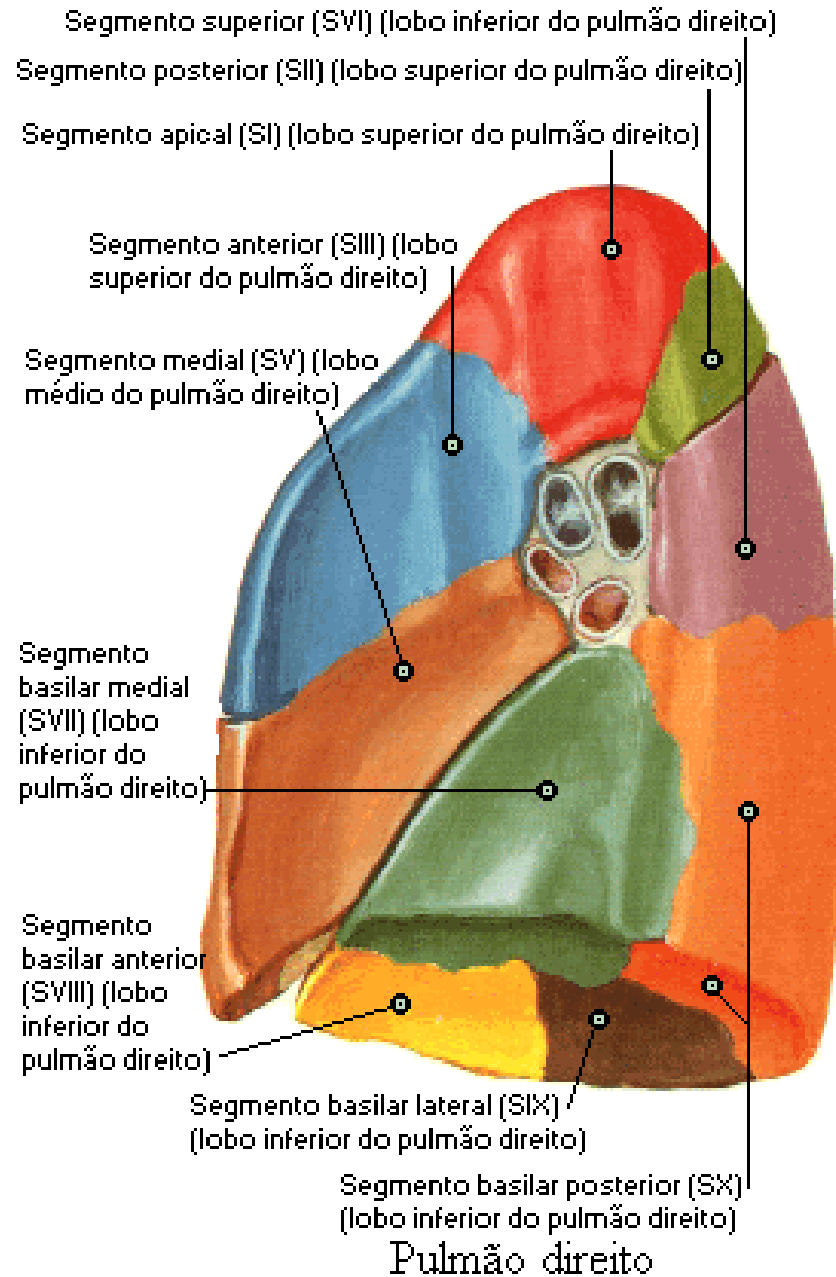
Segmentos Broncopulmonares

Vista Lateral



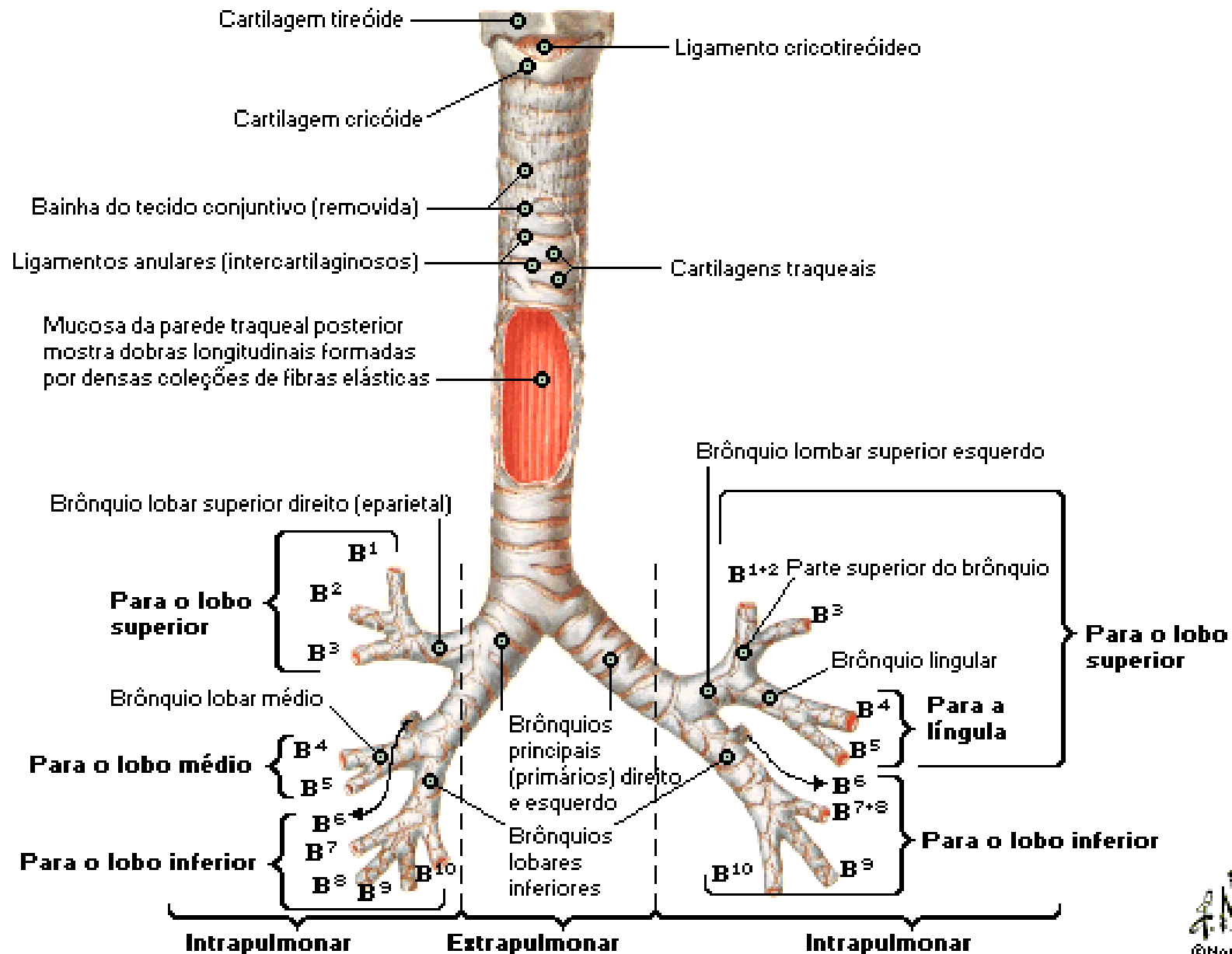
Segmentos Broncopulmonares

Vista Medial



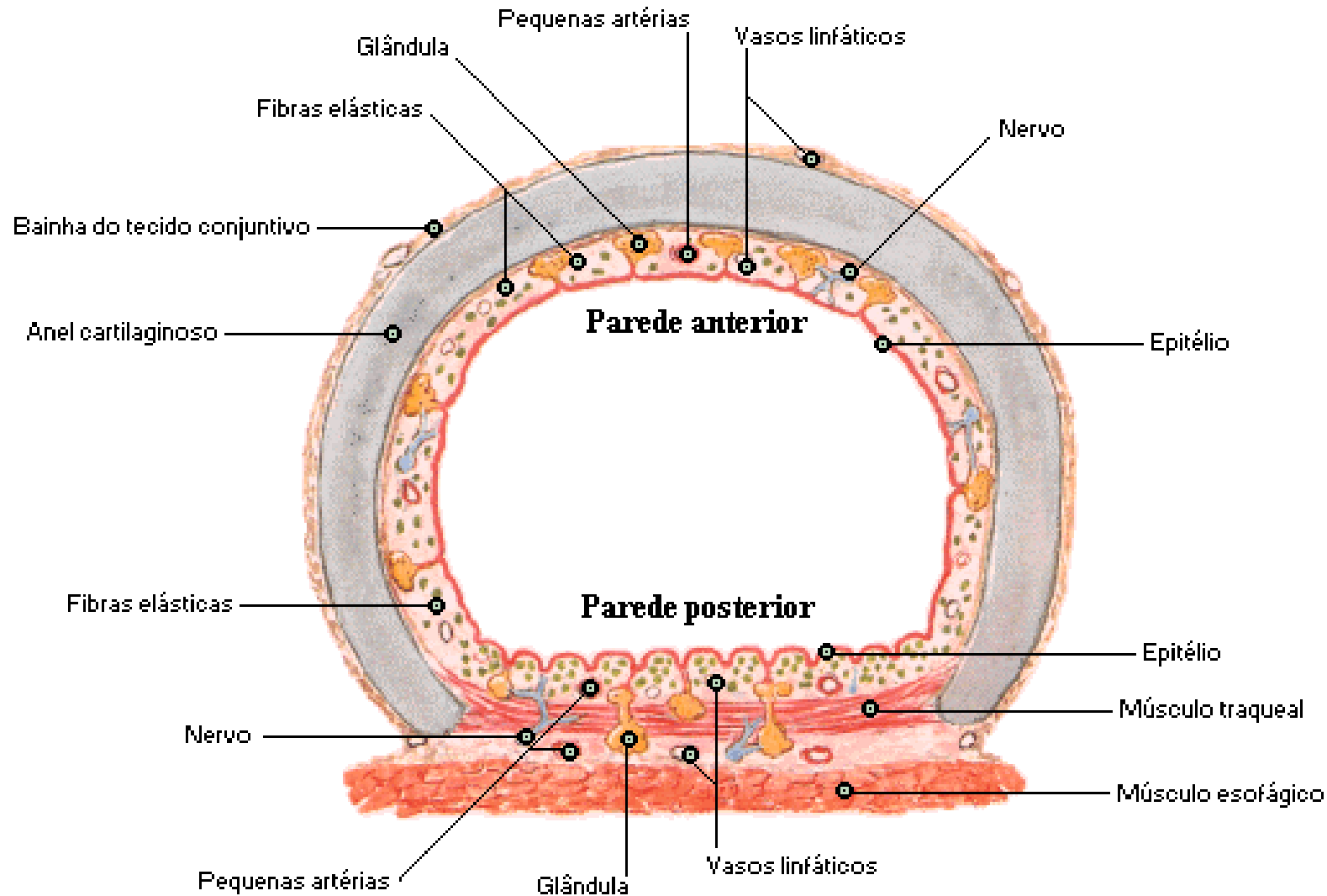
Traquéia e Brônquios Principais

Vista Anterior



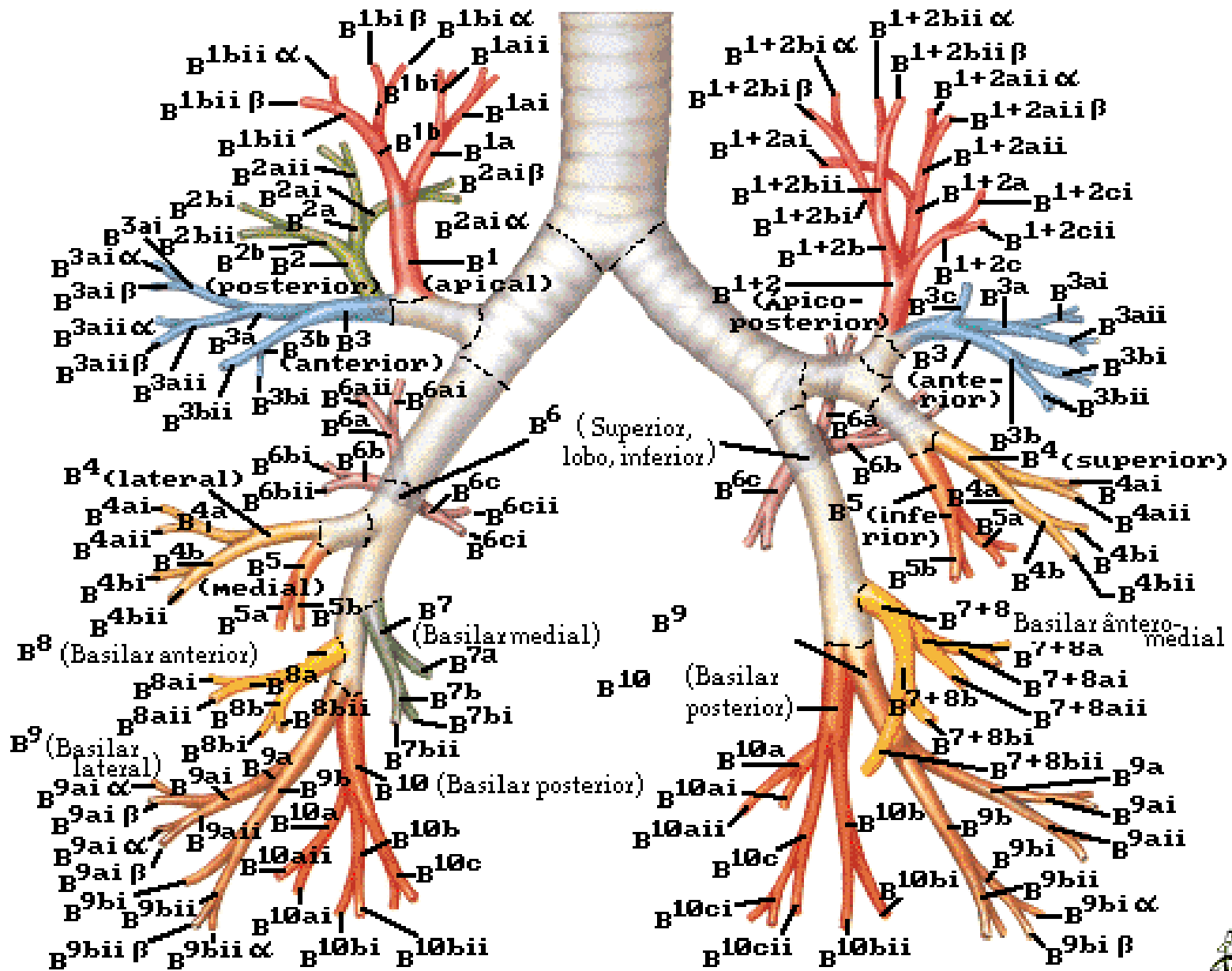
Traquéia

Secção Transversal



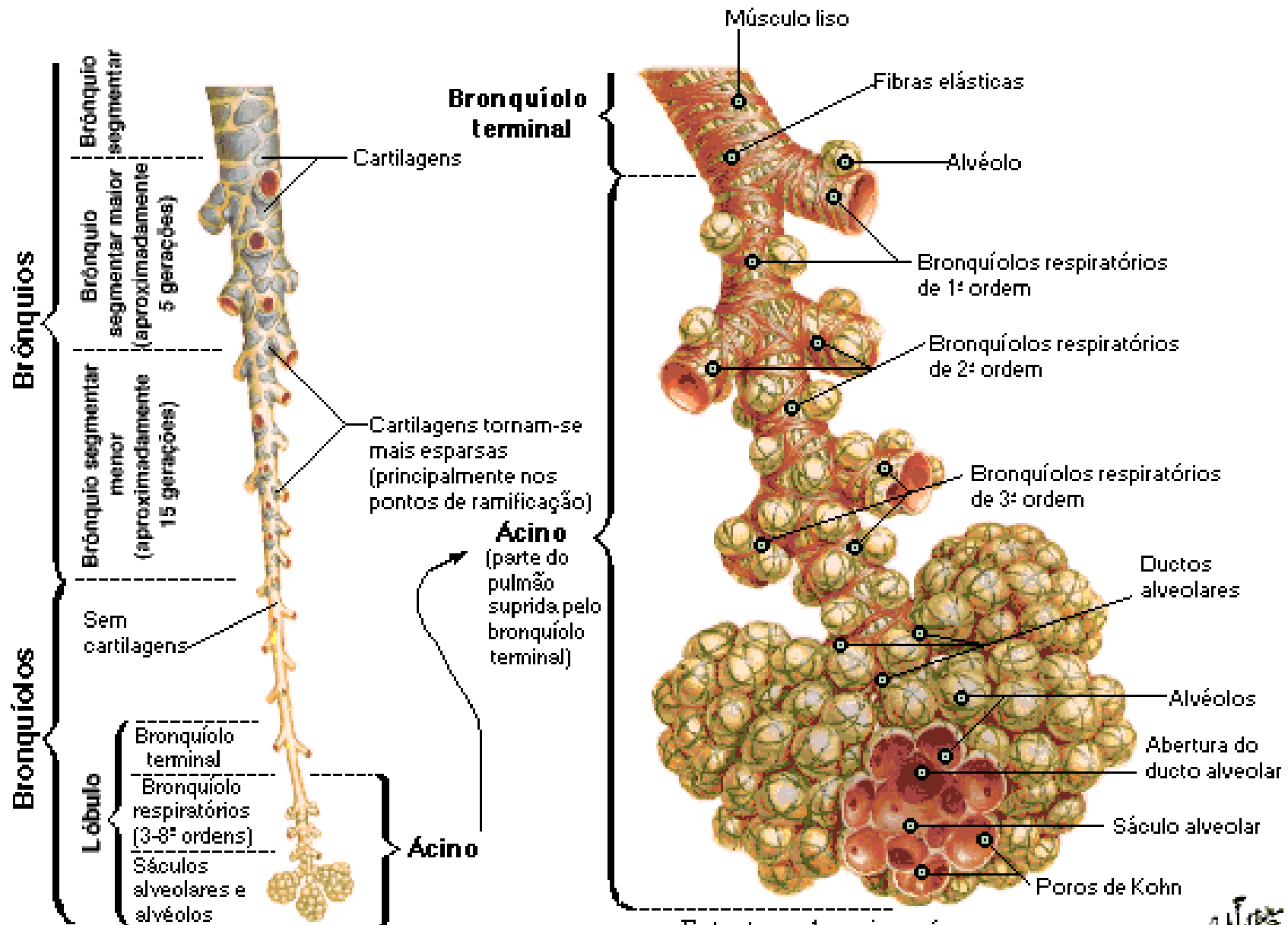
Nomenclatura dos Brônquios

Esquema



Vias Aéreas Intrapulmonares

Esquema

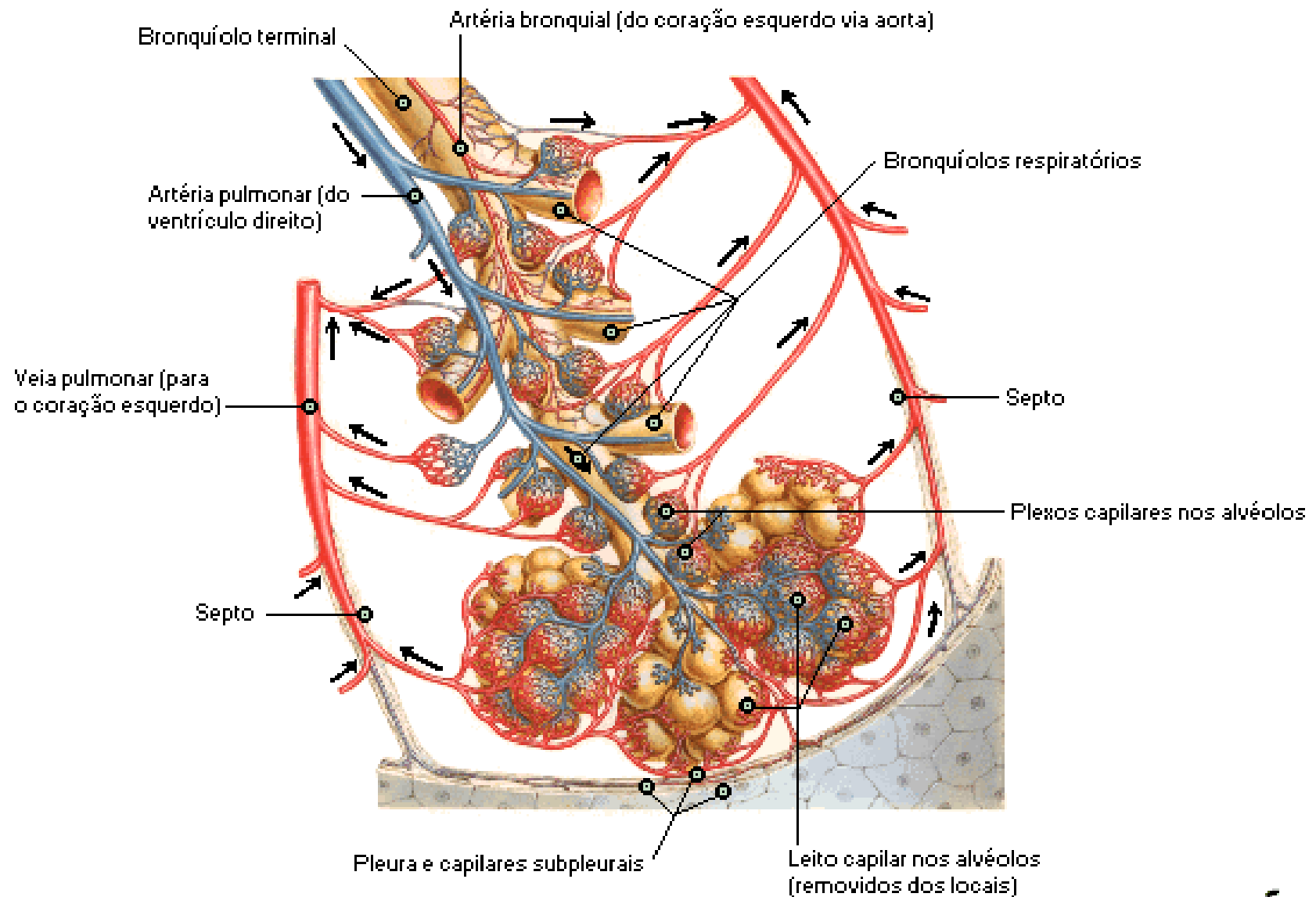


Subdivisões das vias aéreas intrapulmonares

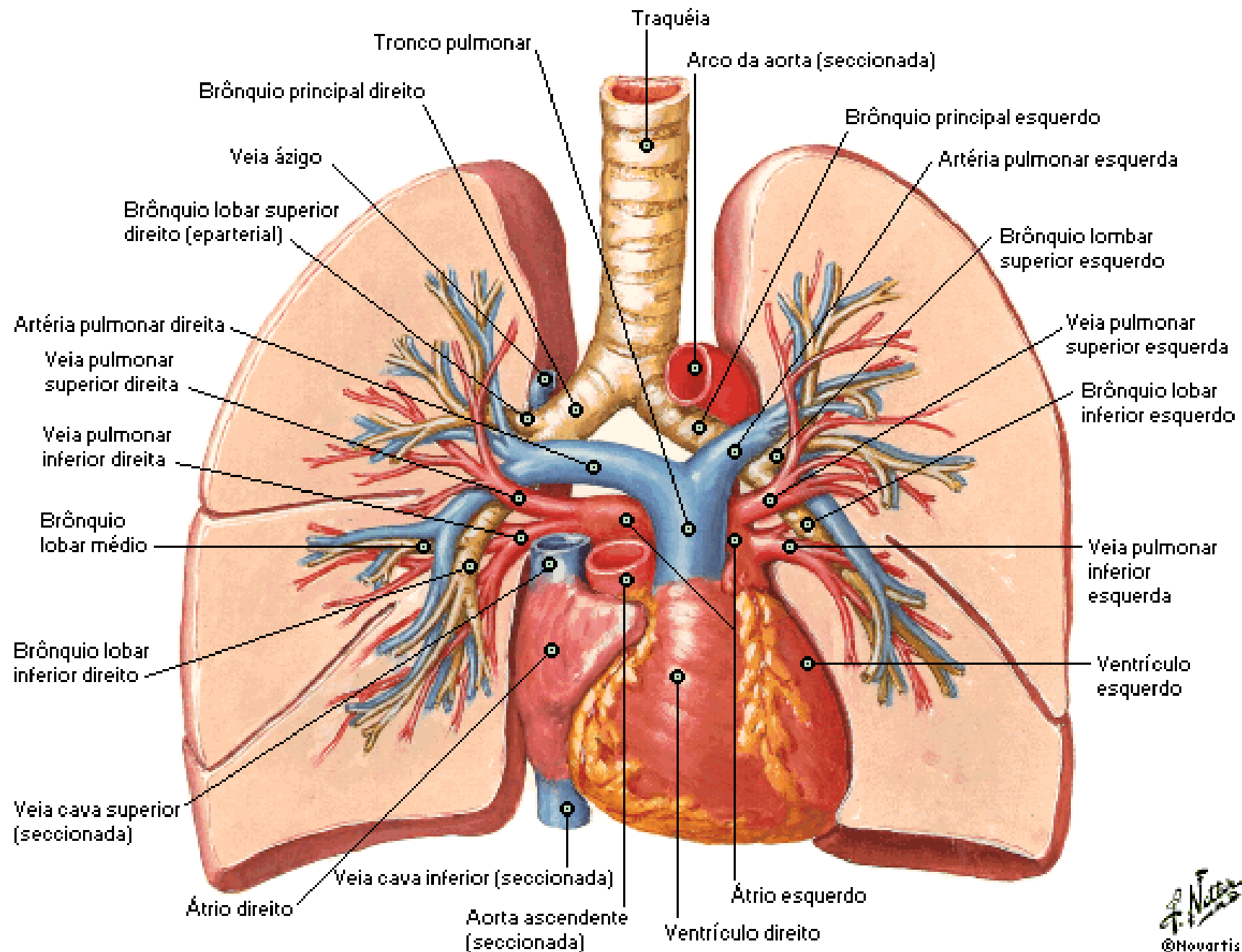
Estrutura das vias aéreas intrapulmonares

Circulação Sangüínea Intrapulmonar

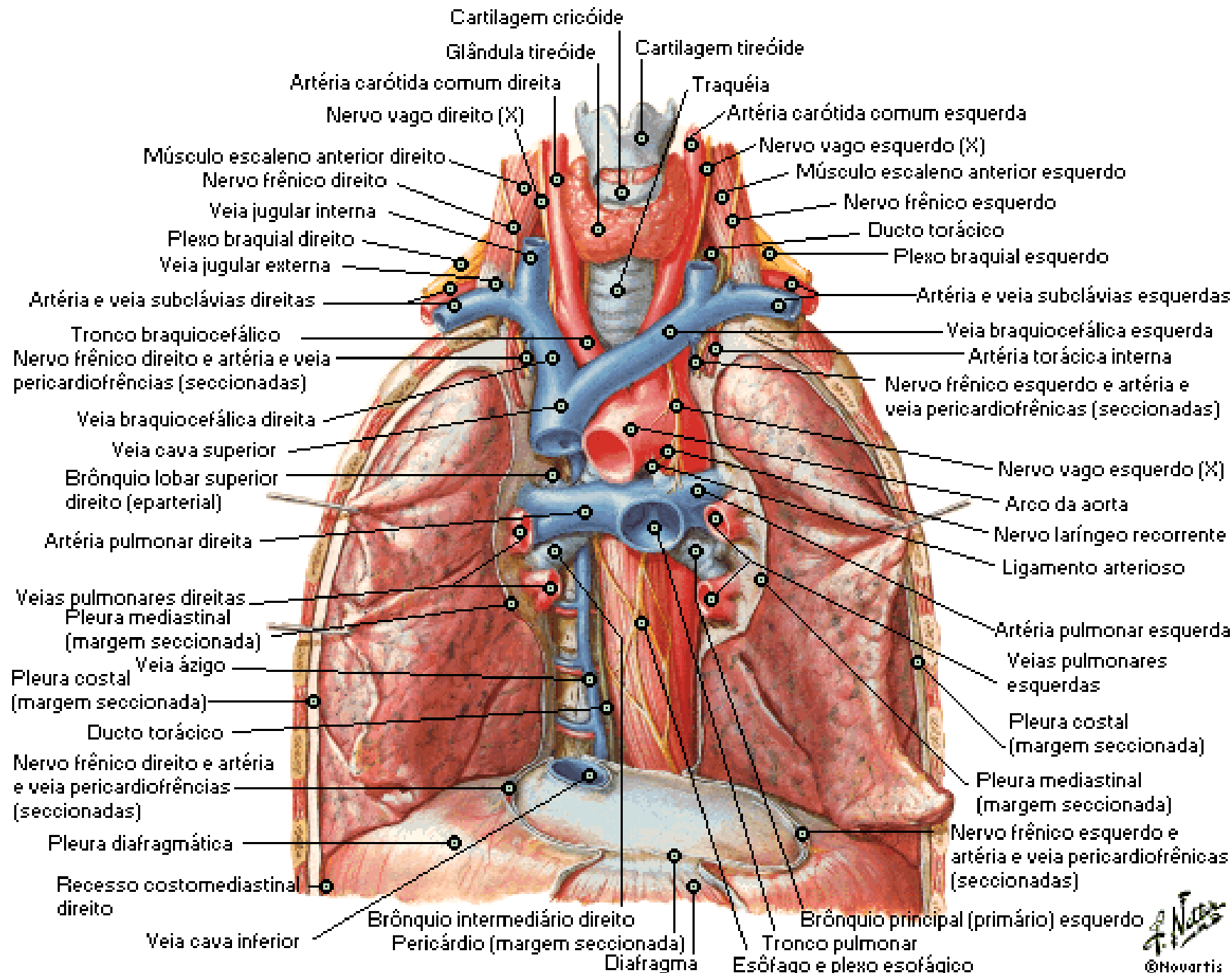
Esquema



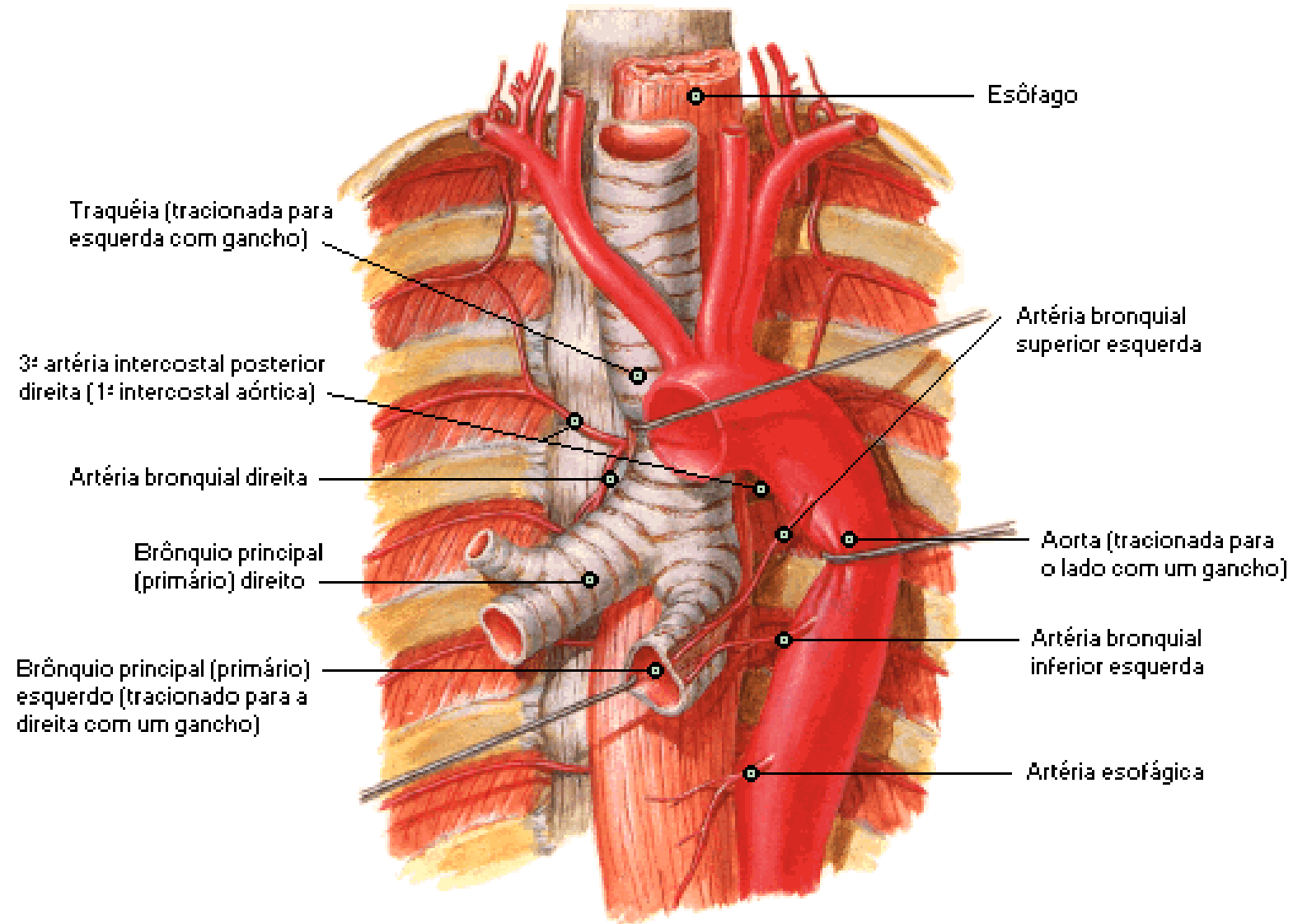
Artérias e Veias Pulmonares



Brônquios - Fonte com Artérias e Veias Pulmonares in Situ

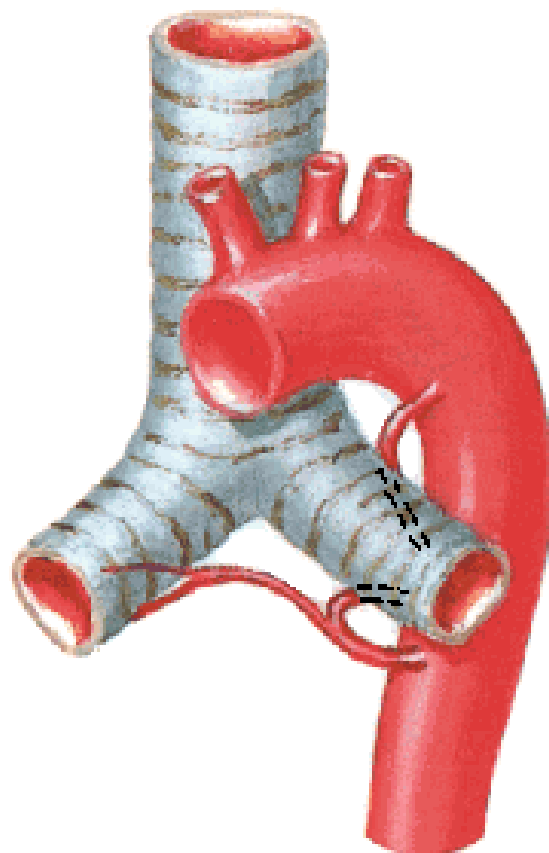


Artérias Bronquiais

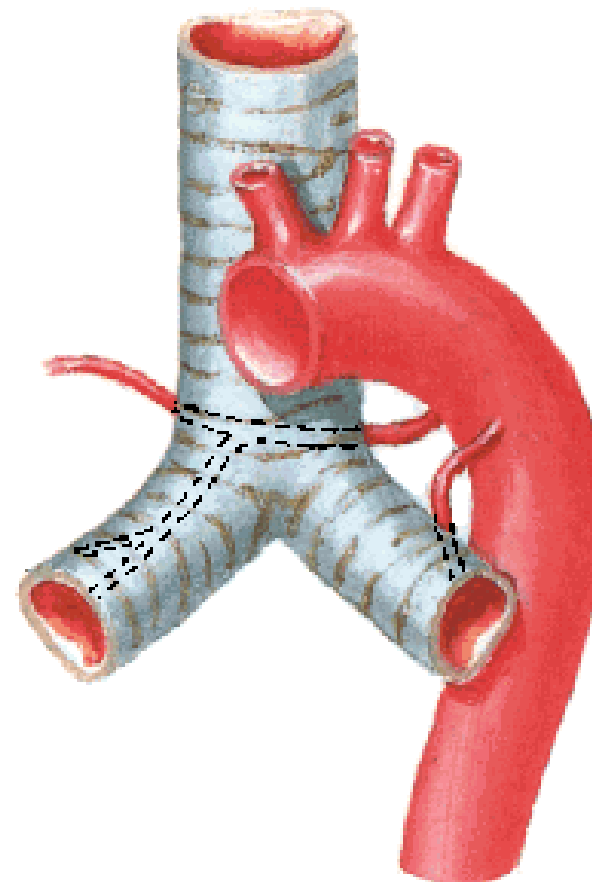


Artérias Bronquiais

Variações

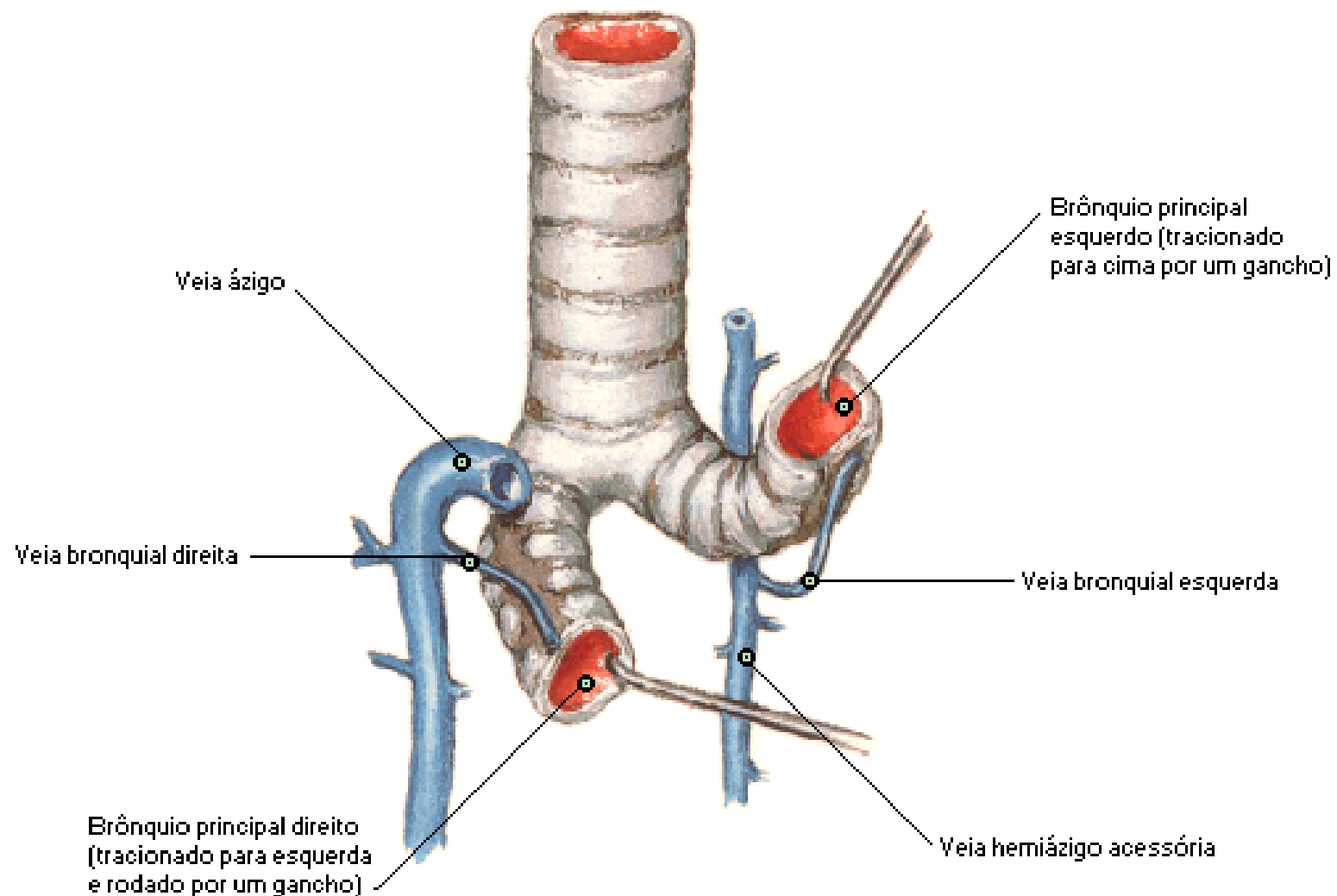


Artérias bronquiais direita e esquerda originando-se da aorta por um tronco único

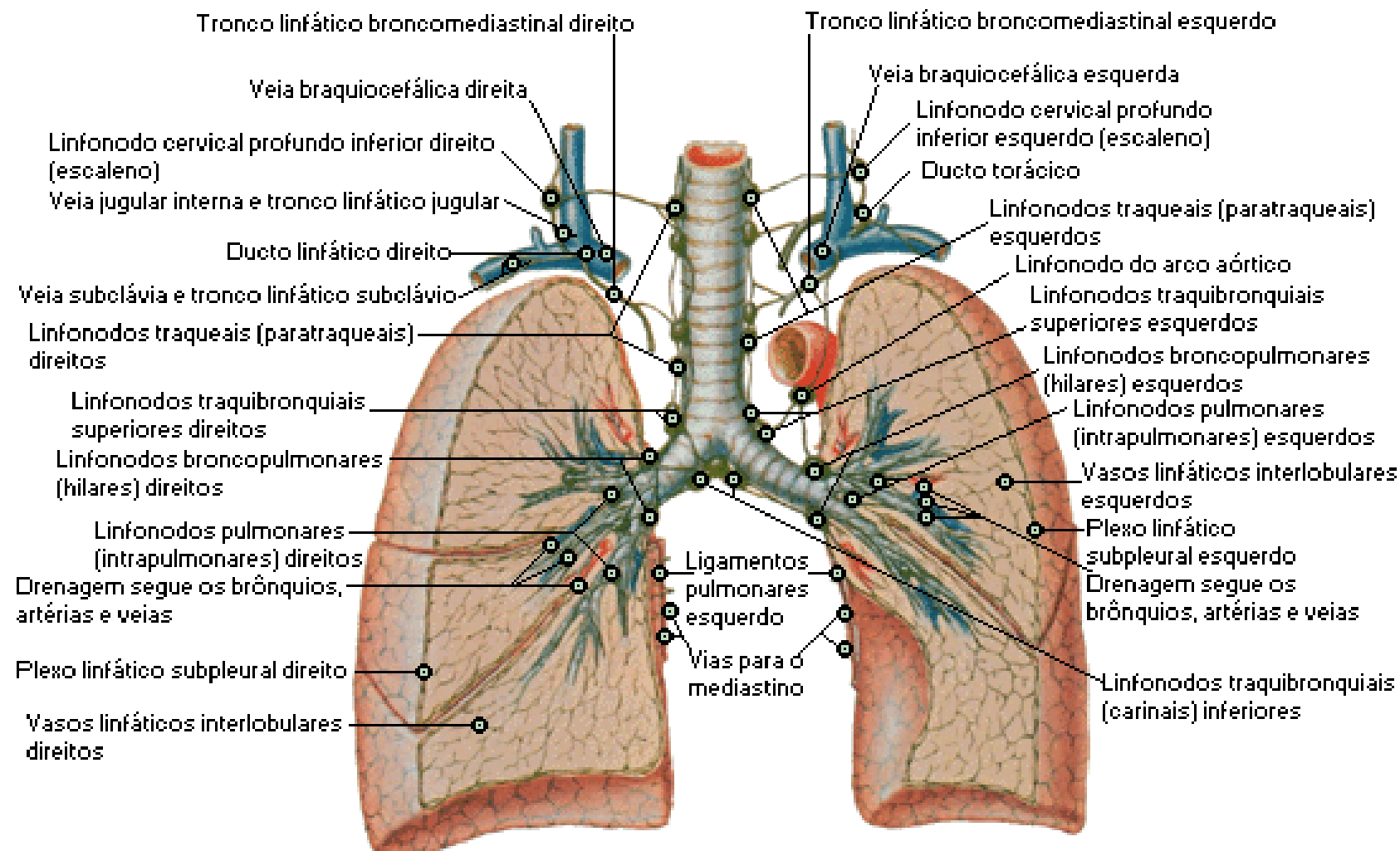


Somente uma única artéria bronquial para cada brônquio (normalmente, duas para o brônquio esquerdo)

Veias Bronquiais



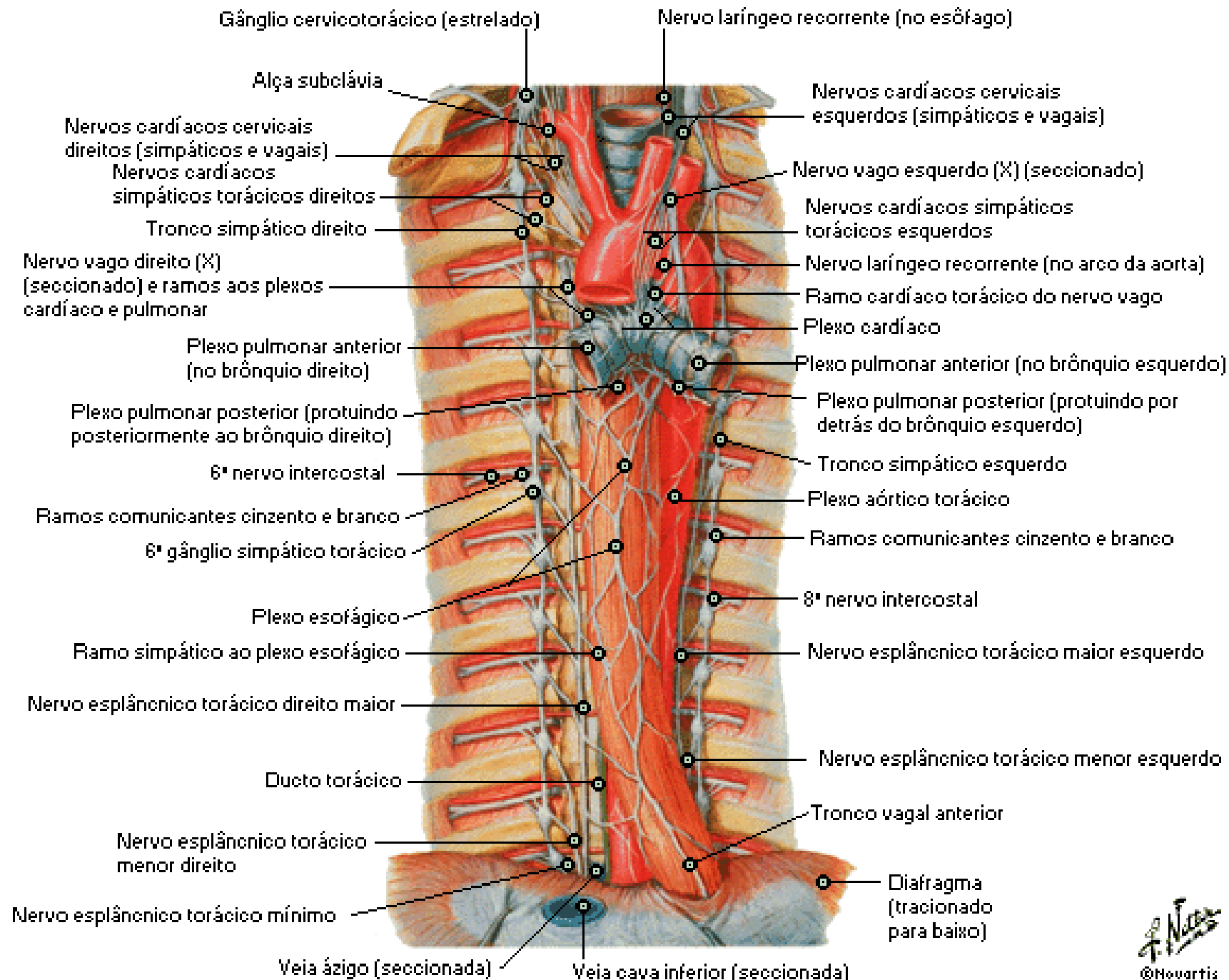
Vasos Linfáticos e Linfonodos do Pulmão



Pulmão direito: todos os lobos drenam para os linfonodos intrapulmonares e broncopulmonares (hilares), então para os linfonodos traquibronquiais inferiores (carinais), linfonodos traquibronquiais superiores direitos e para os linfonodos traqueais direitos, a caminho da veia braquiocéfálica, via tronco linfático broncomediastinal e/ou linfonodo escaleno.

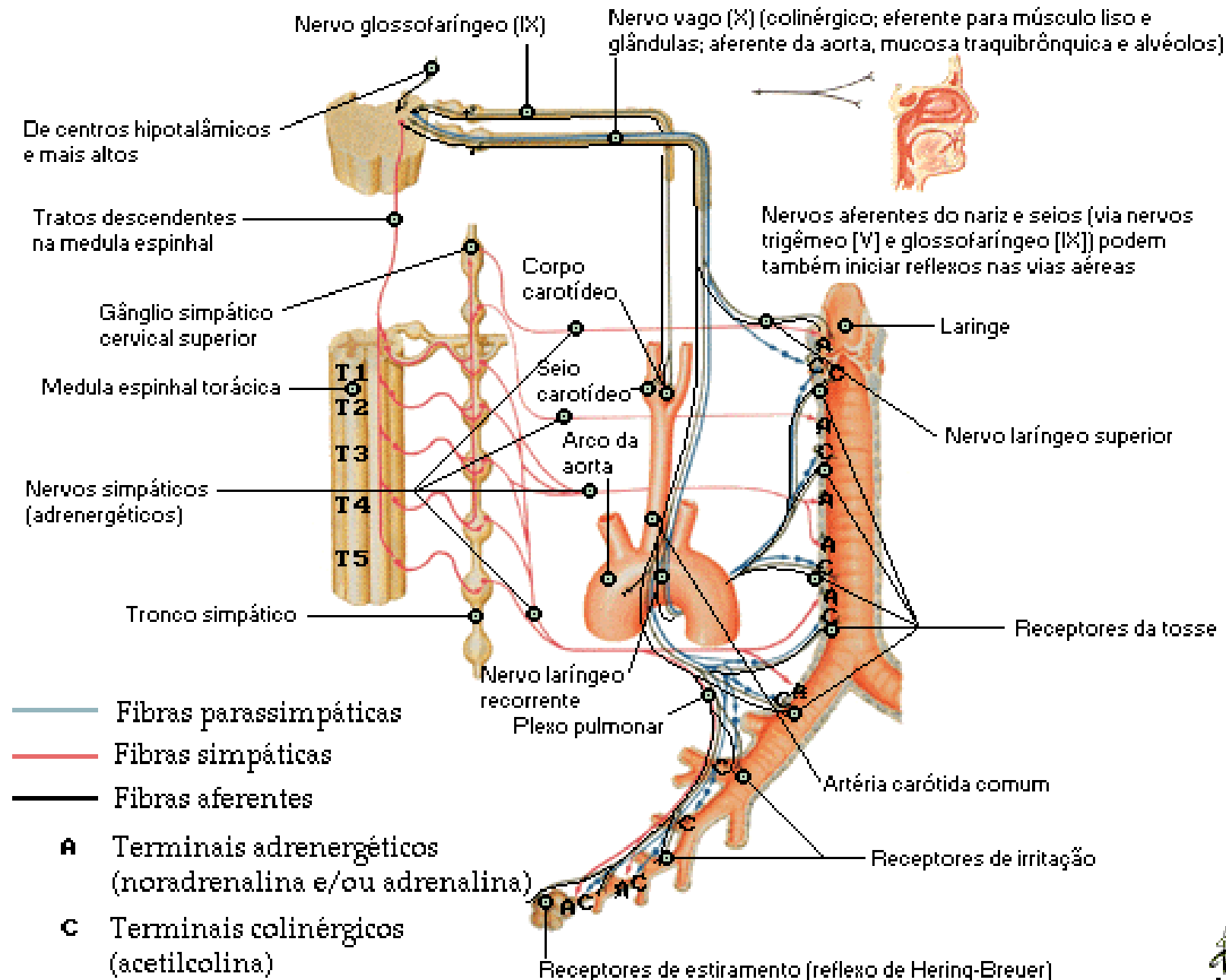
O lobo superior drena para os linfonodos pulmonares e hilares, linfonodos carinais, linfonodos traquibronquiais superiores esquerdos, linfonodos traqueais esquerdos e/ou linfonodo de arco aórtico, então para a veia braquiocéfálica via tronco broncomediastinal esquerdo e ducto torácico. O lobo inferior esquerdo também drena para os linfonodos pulmonares e hilares e para os linfonodos carinais, mas então principalmente para os linfonodos traquibronquiais superiores direitos, onde segue a mesma via da linfa do pulmão direito.

Nervos Autônomos do Tórax

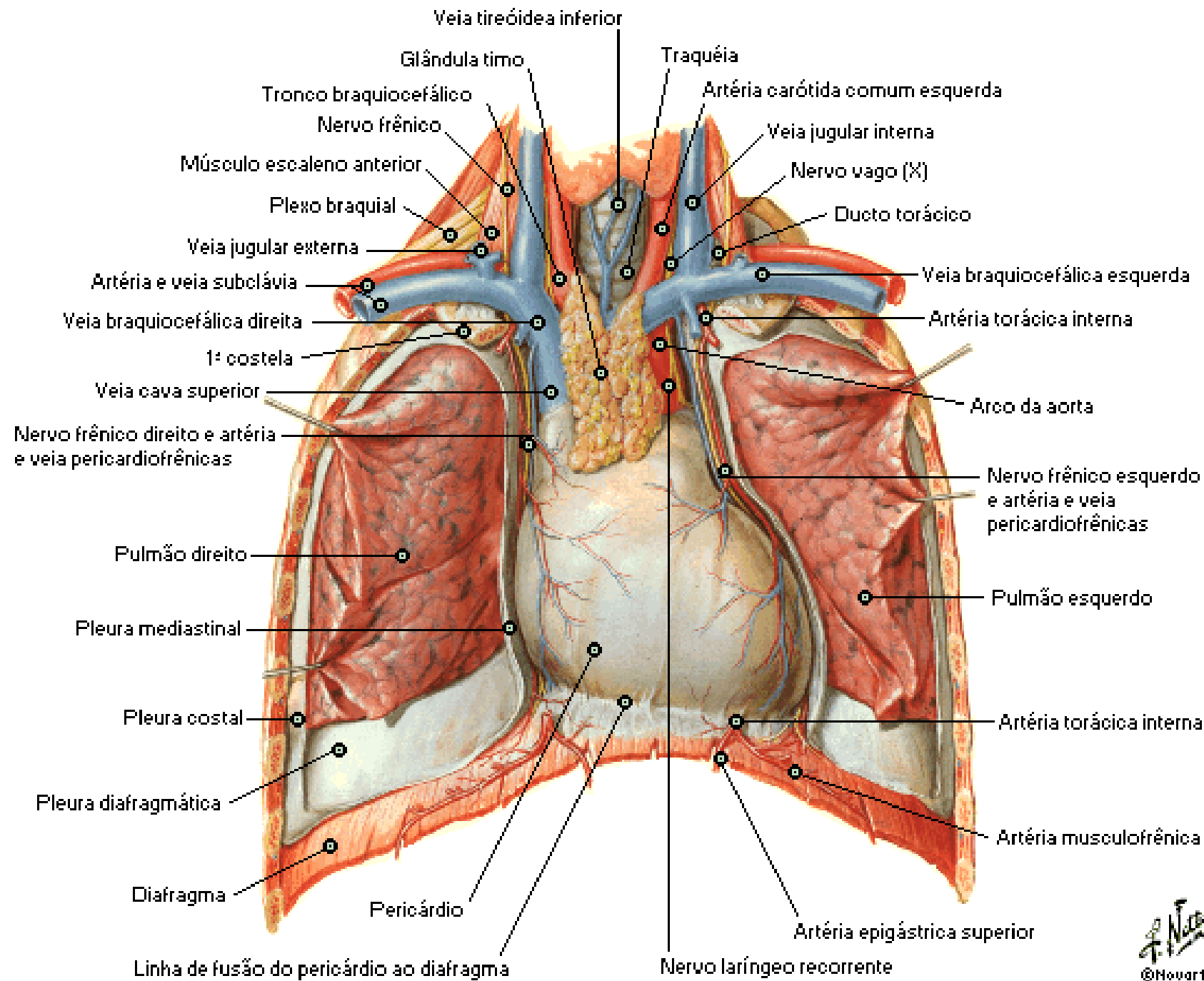


Inervação da Árvore Bronquial

Esquema

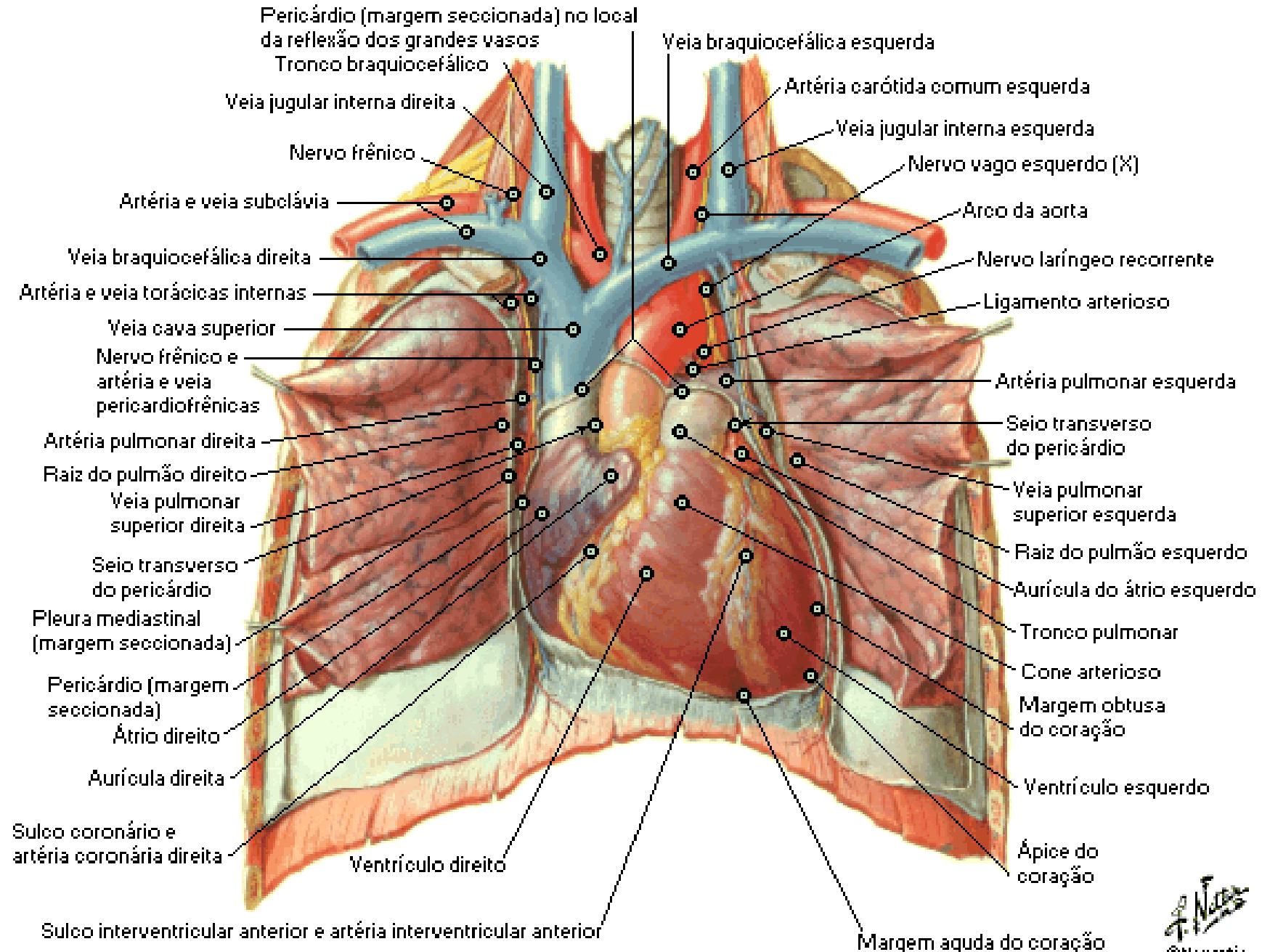


Coração in Situ



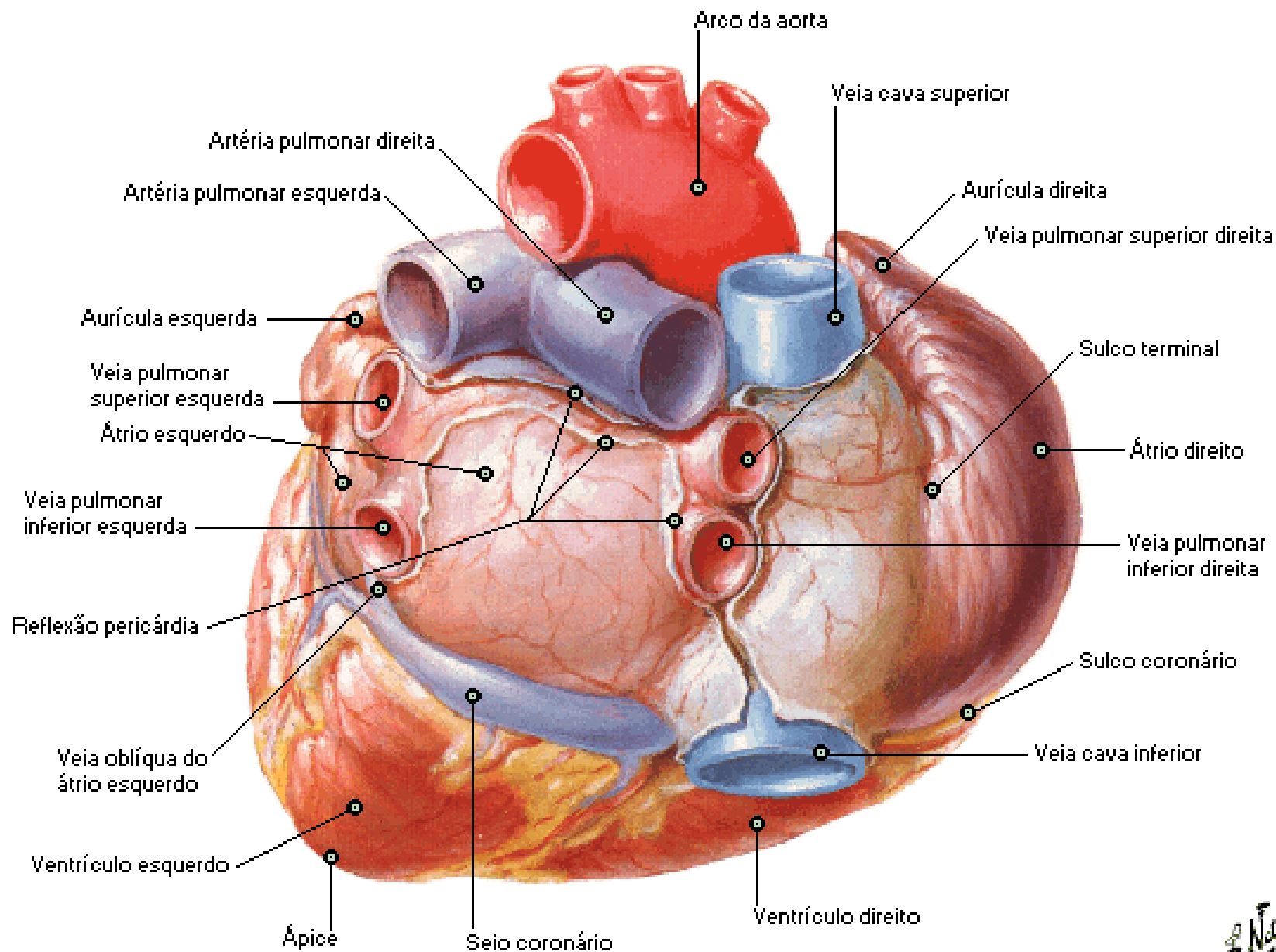
Coração

Vista Anterior



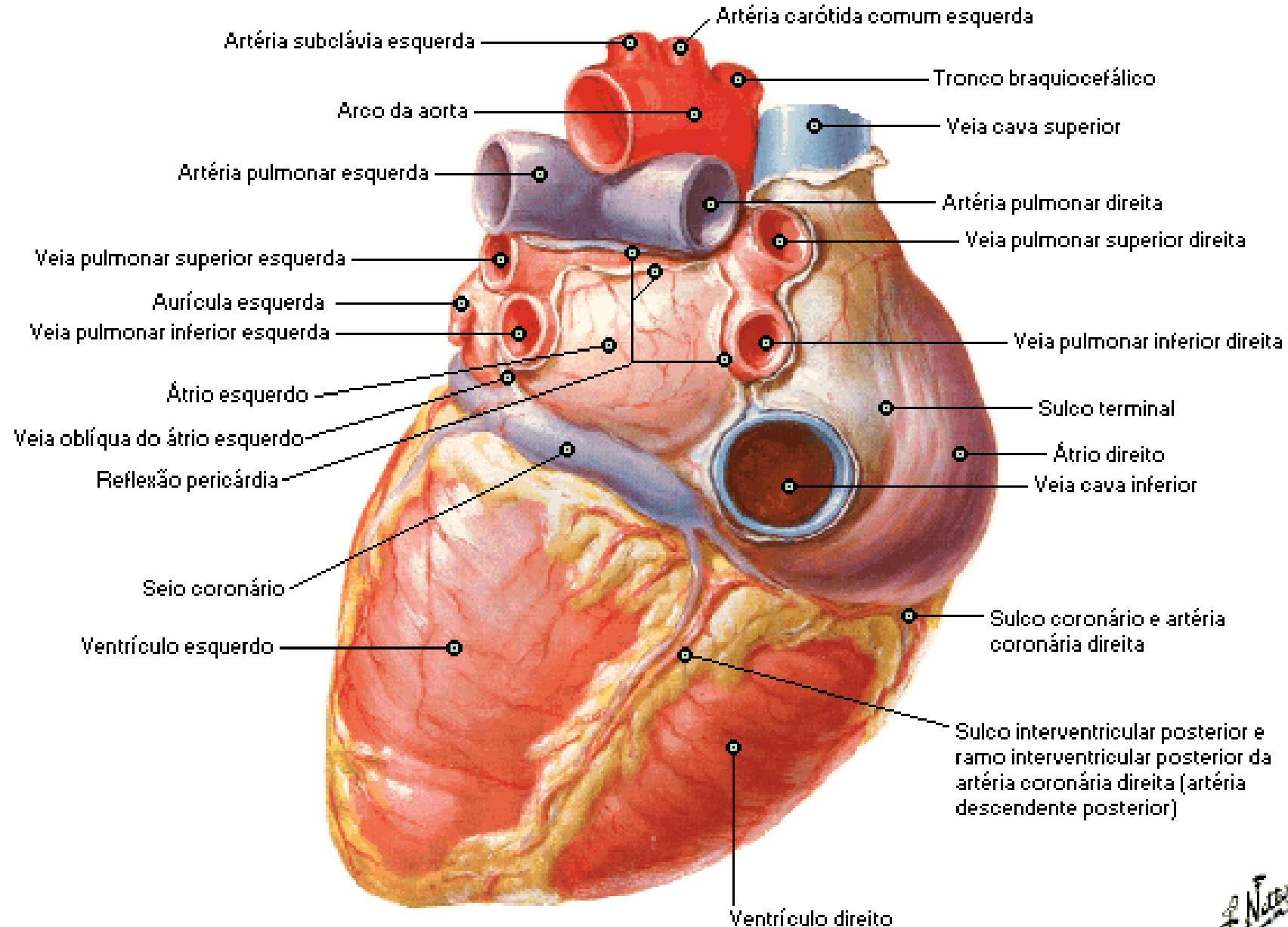
Coração - Base

Vista Posterior



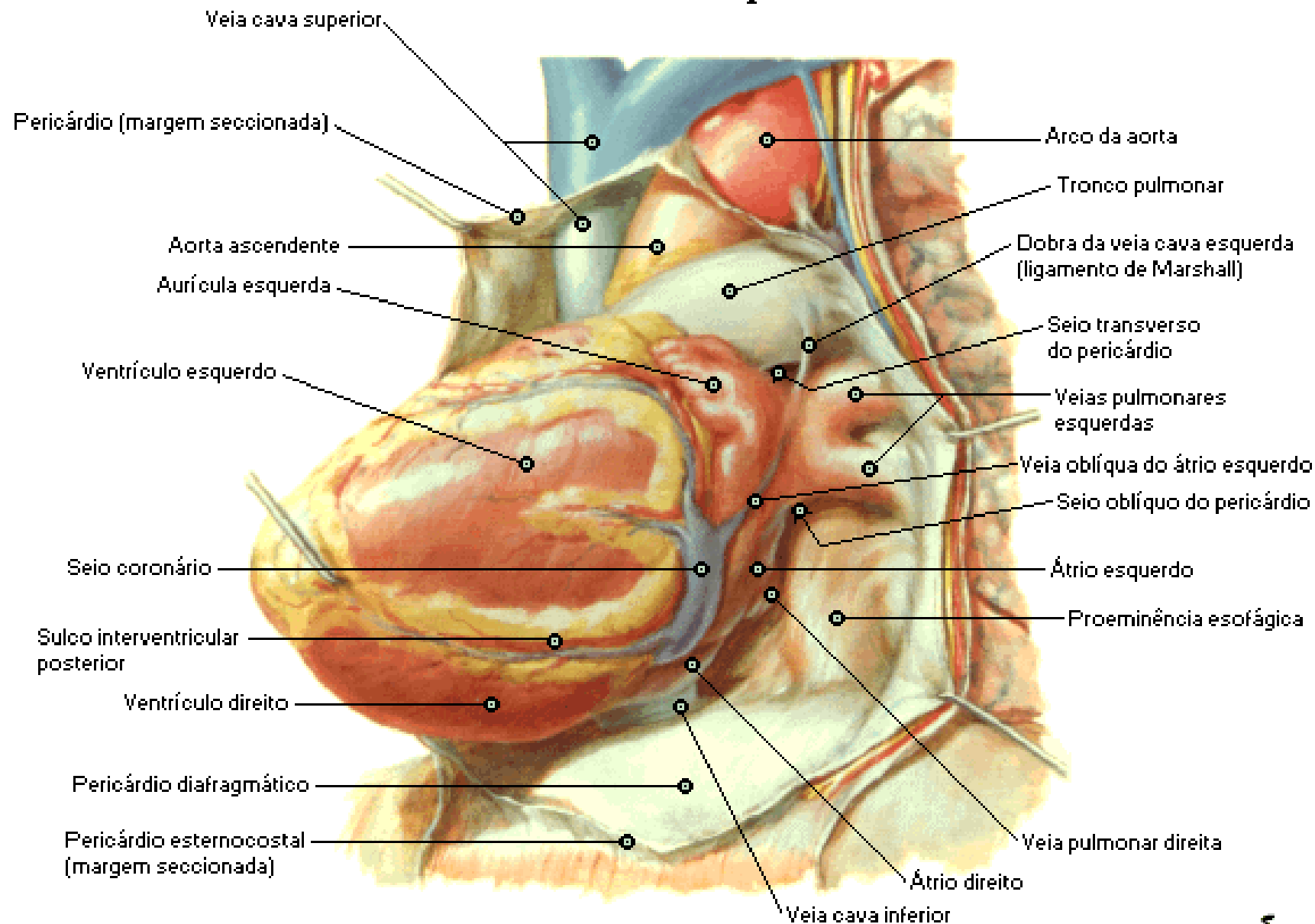
Coração - Face Diafragmática

Vista Pósterio-inferior



Saco Pericárdio - Coração Removido

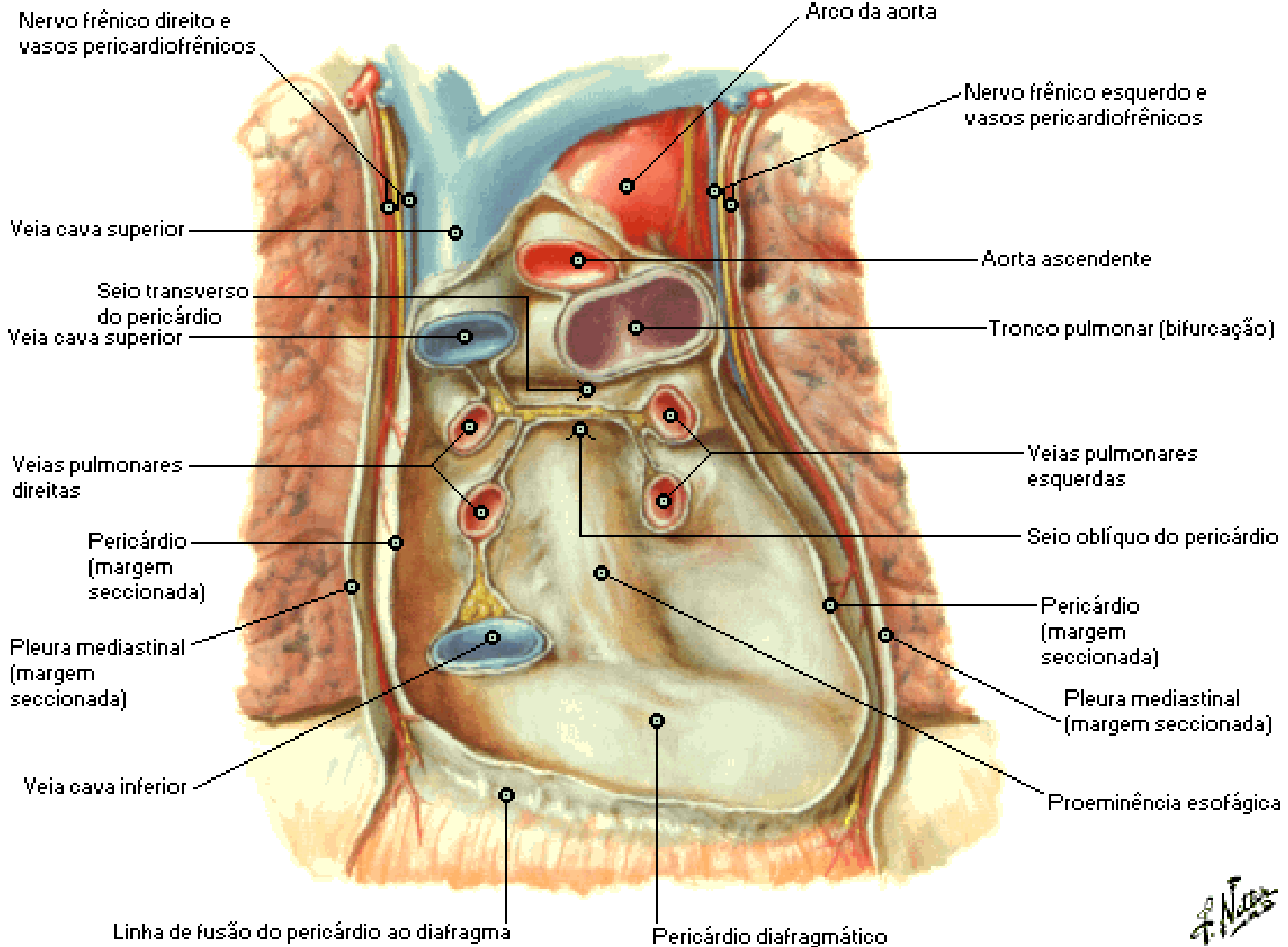
Vista Lateral Esquerda



Coração retirado do saco pericárdico aberto

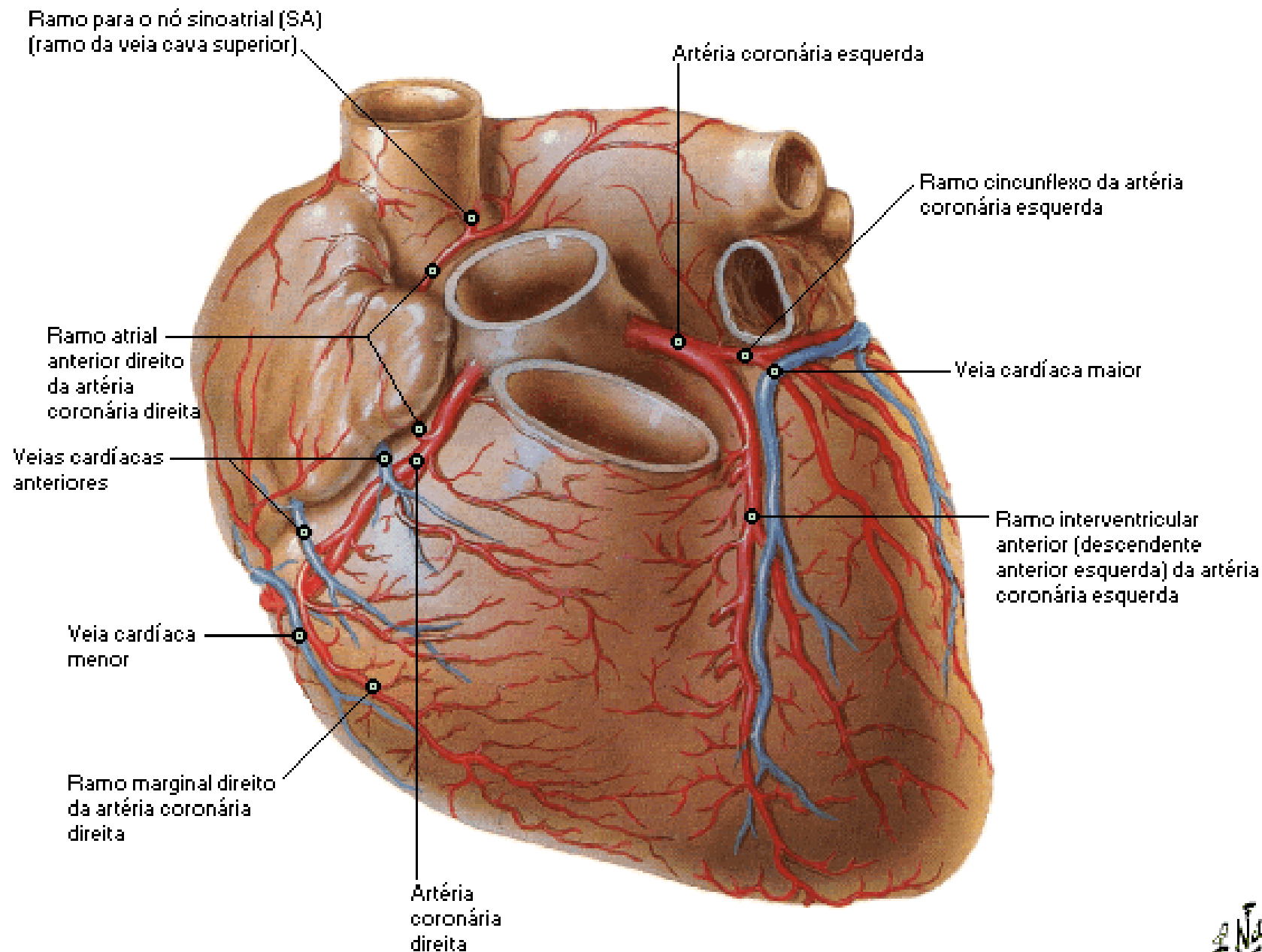
Saco Pericárdico - Coração Removido

Vista Anterior



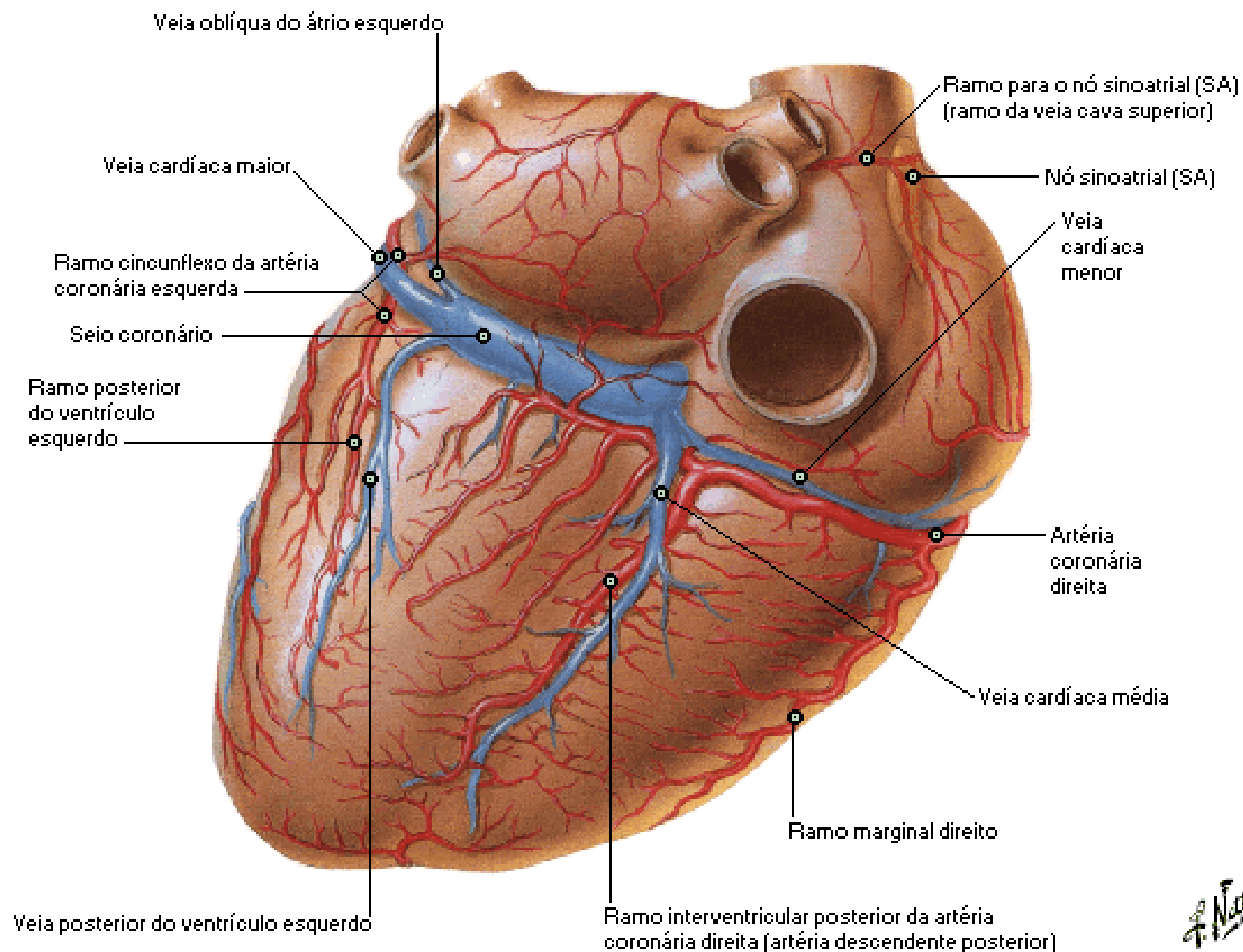
Artérias Coronárias e Veias Cardíacas

Face Esternocostal



Artérias Coronárias e Veias Cardíacas

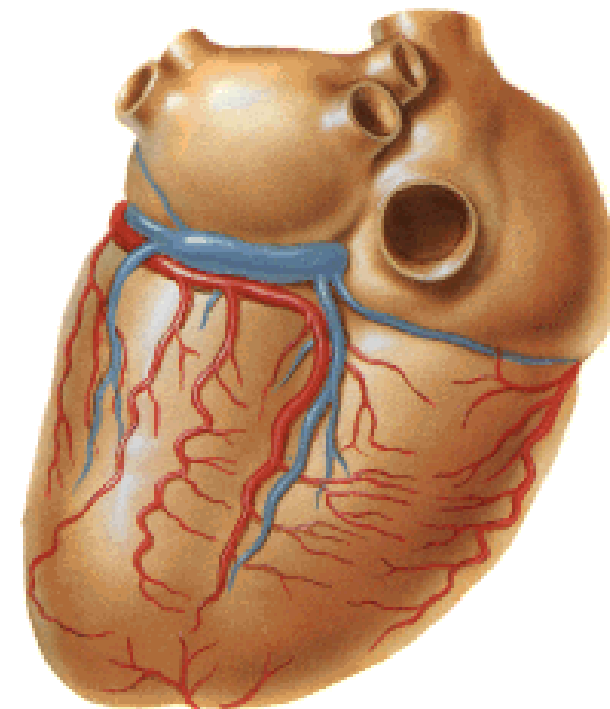
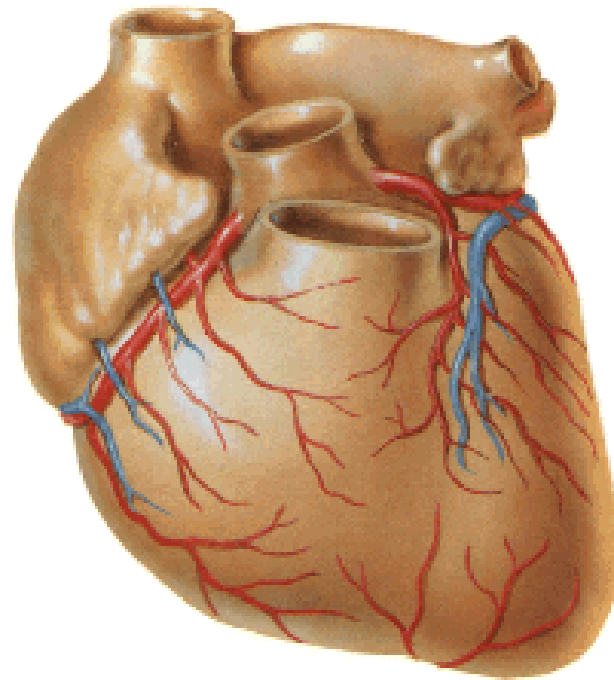
Face Diafragmática



Artérias Coronárias e Veias Cardíacas

Variações

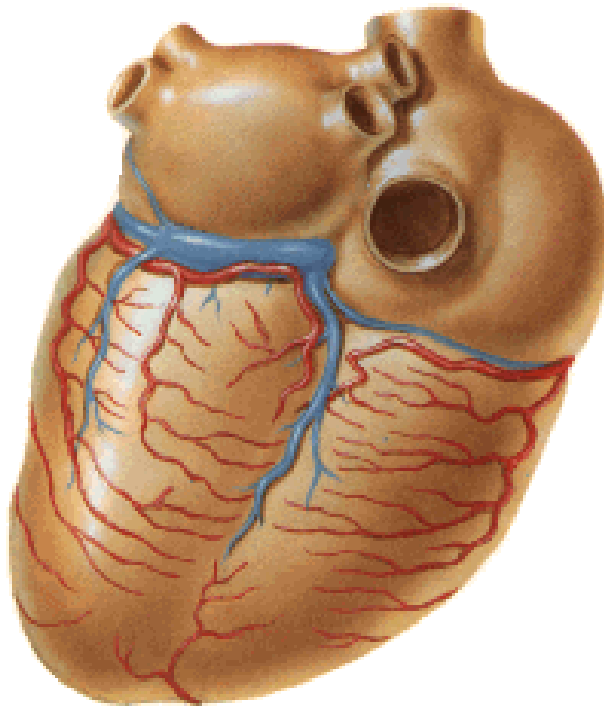
Ramo interventricular posterior (descendente posterior) derivado do ramo circunflexo da artéria coronária esquerda ao invés da artéria coronária direita



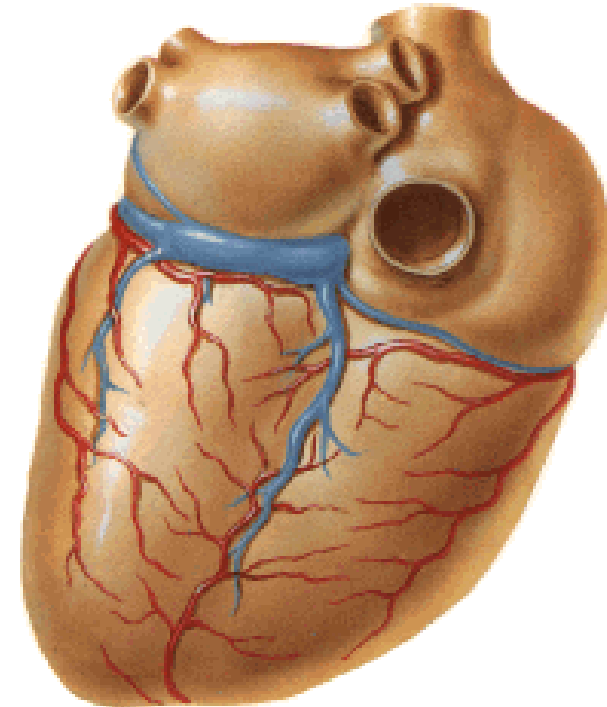
Ramo interventricular anterior (descendente anterior esquerda) muito curto da artéria coronária esquerda. A parte apical da superfície esternocostal suprida pelo ramo interventricular posterior (descendente posterior) da artéria coronária direita, que se curva ao redor do ápice

Artérias Coronárias e Veias Cardíacas

Variações



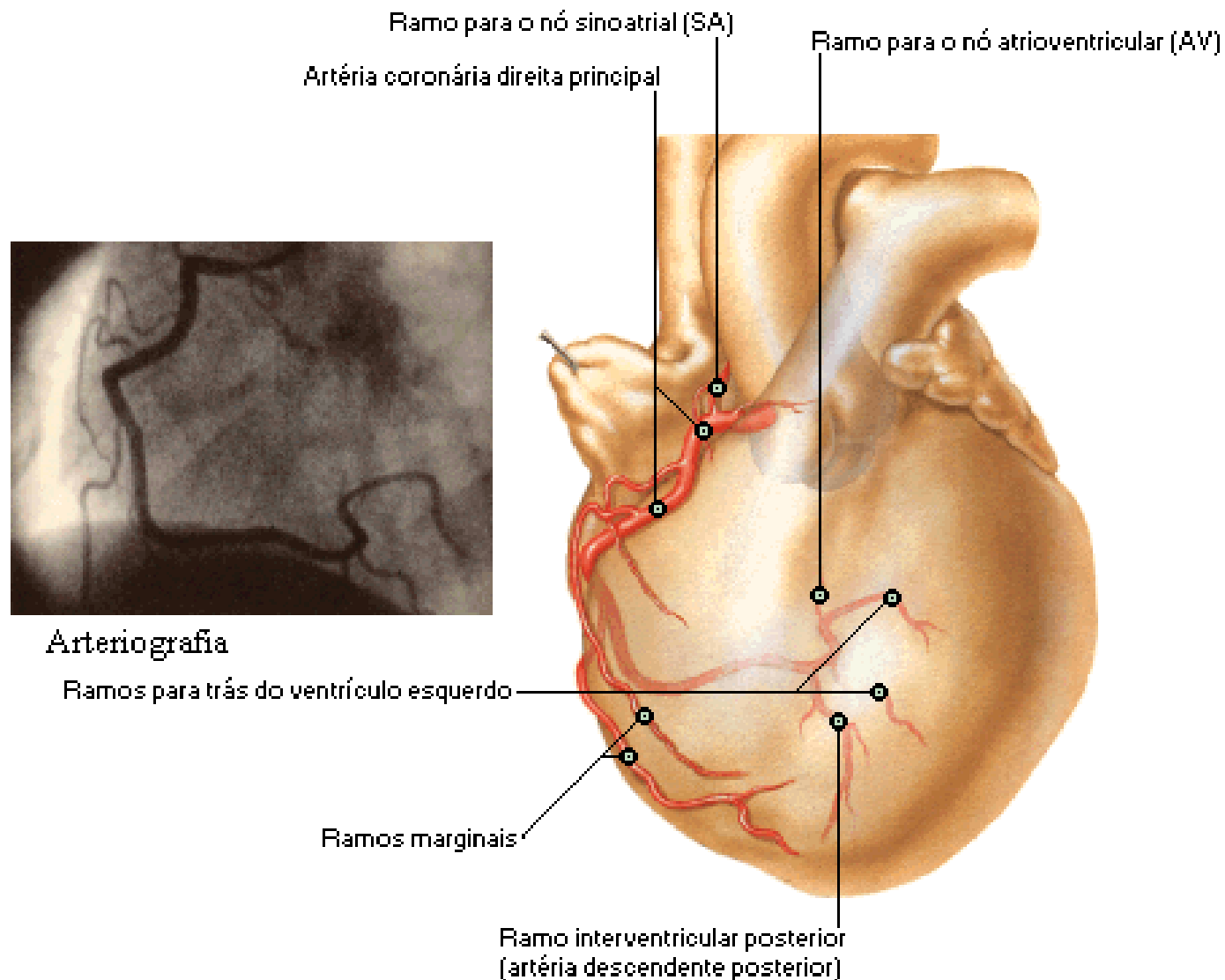
Ramo interventricular posterior (descendente posterior) ausente. Área suprida principalmente por pequenos ramos da ramificação circunflexa da artéria coronária esquerda e pela artéria coronária direita



Ramo interventricular posterior (descendente posterior) ausente. Área suprida principalmente pelo ramo interventricular anterior (descendente anterior esquerda) alongado, curvando-se ao redor do ápice

Artéria Coronária Direita

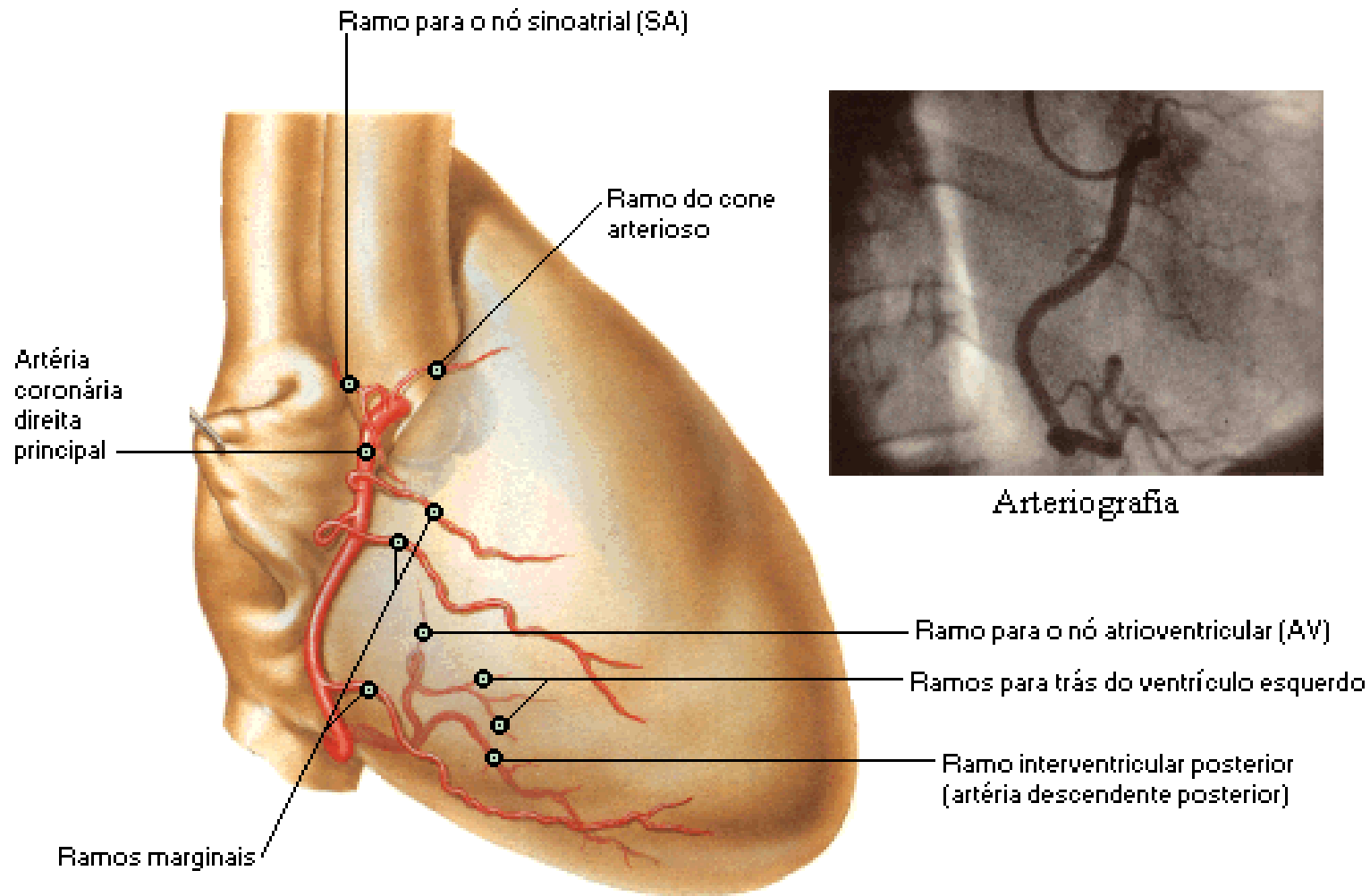
Vista Arteriográfica



Vista oblíqua anterior esquerda

Artéria Coronária Direita

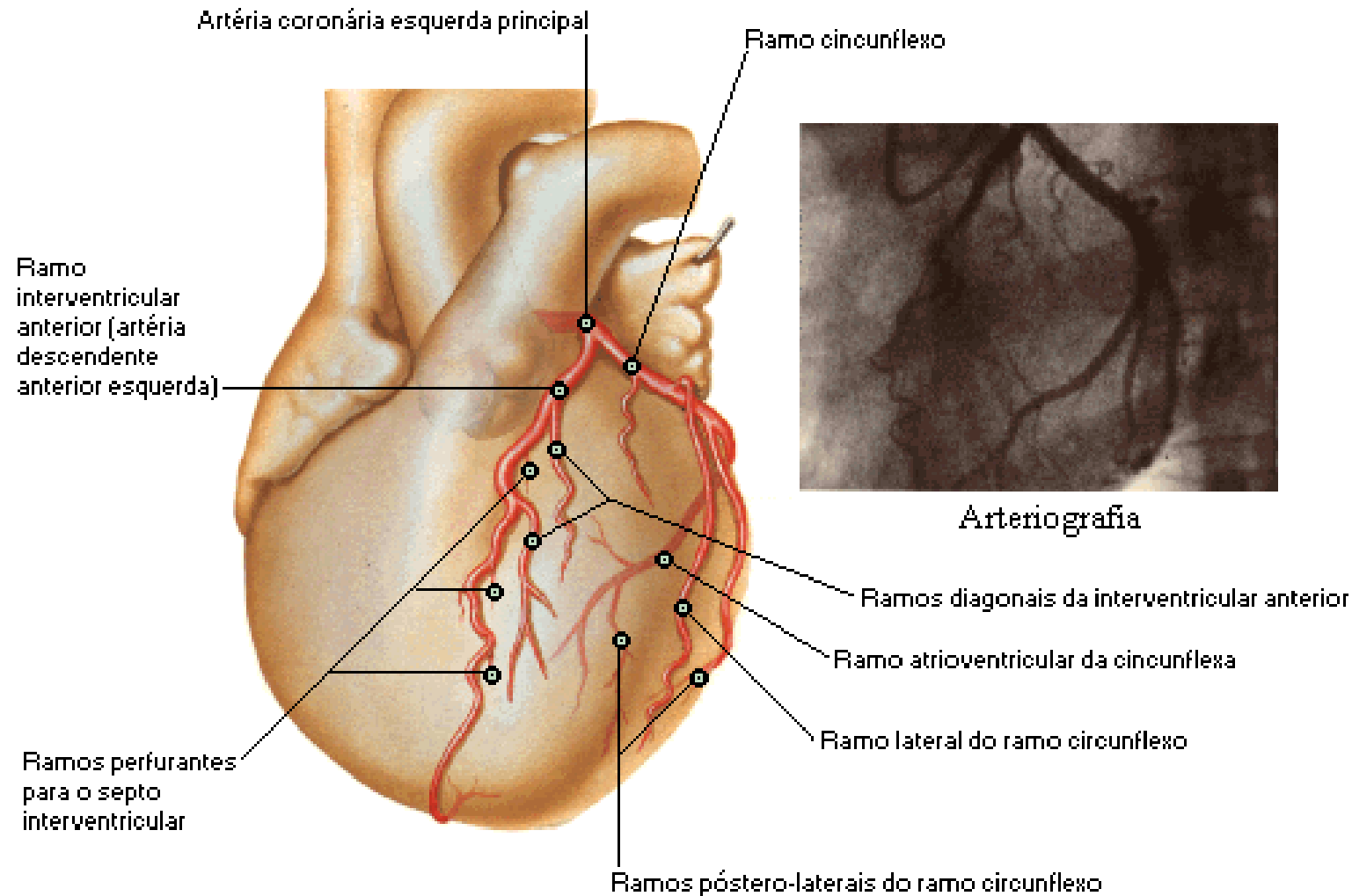
Vista Arteriográfica



Vista oblíqua anterior direita

Artéria Coronária Esquerda

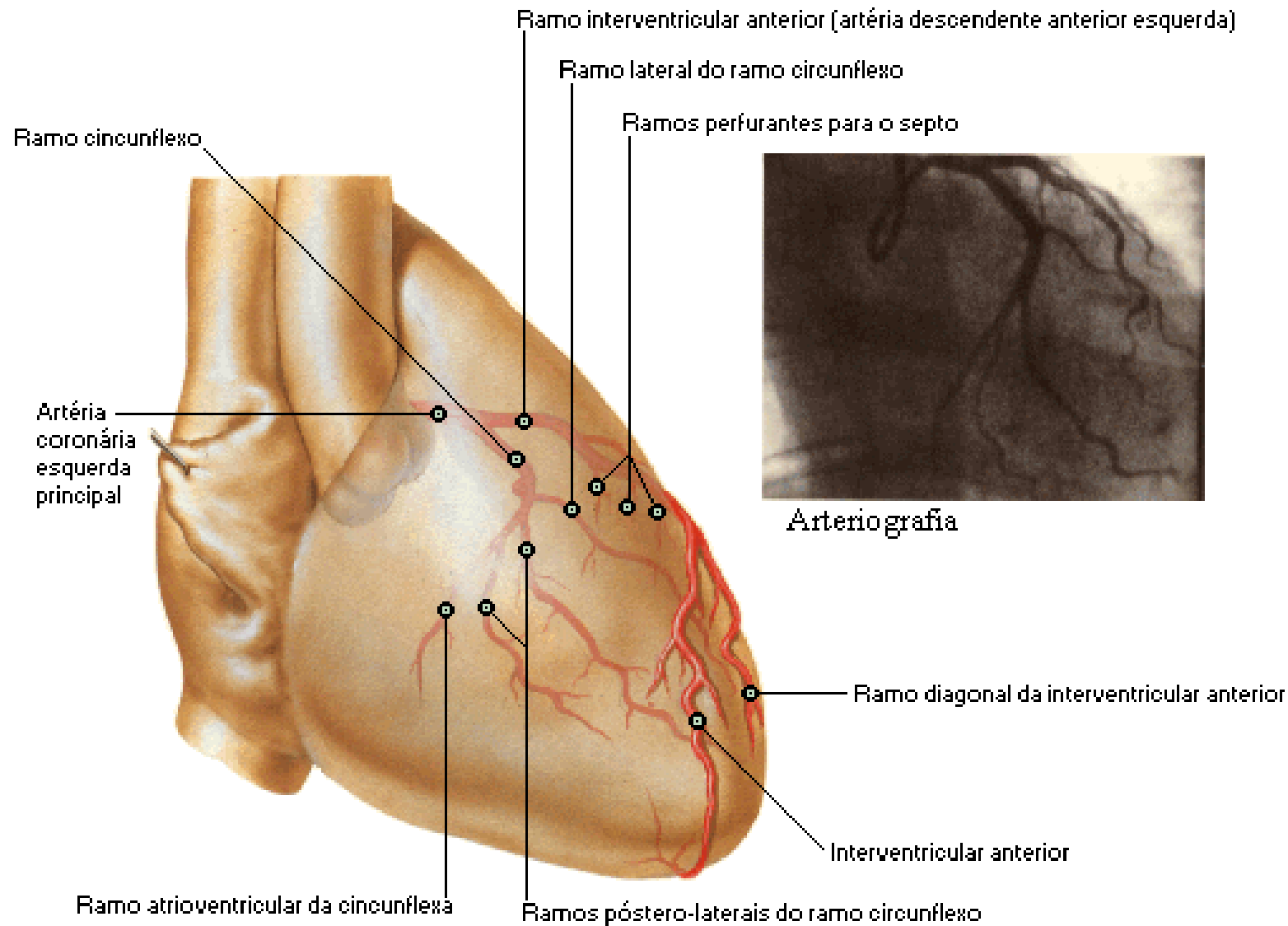
Vista Arteriográfica



Vista oblíqua anterior esquerda

Artéria Coronária Esquerda

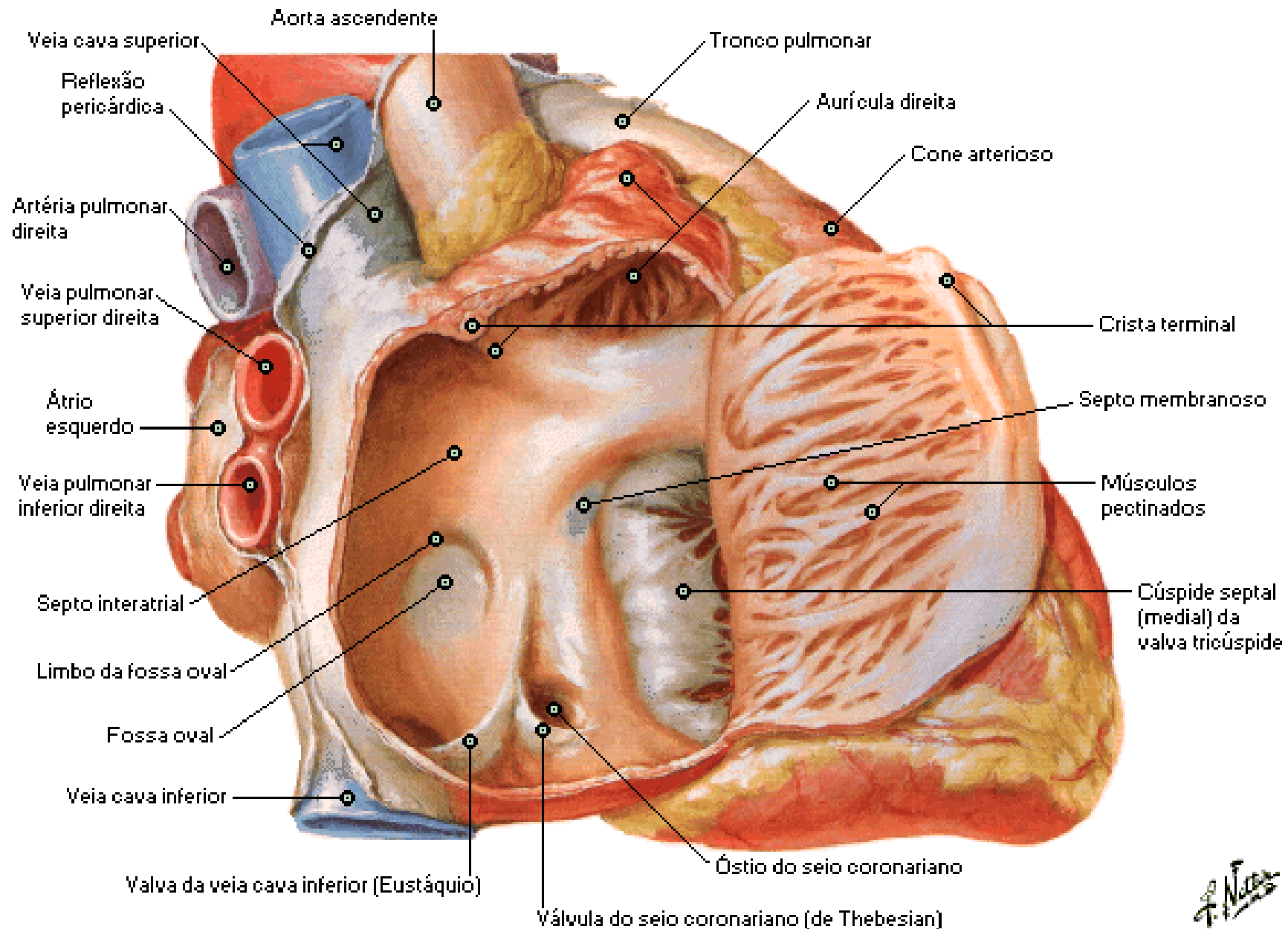
Vista Arteriográfica



Vista oblíqua anterior direita

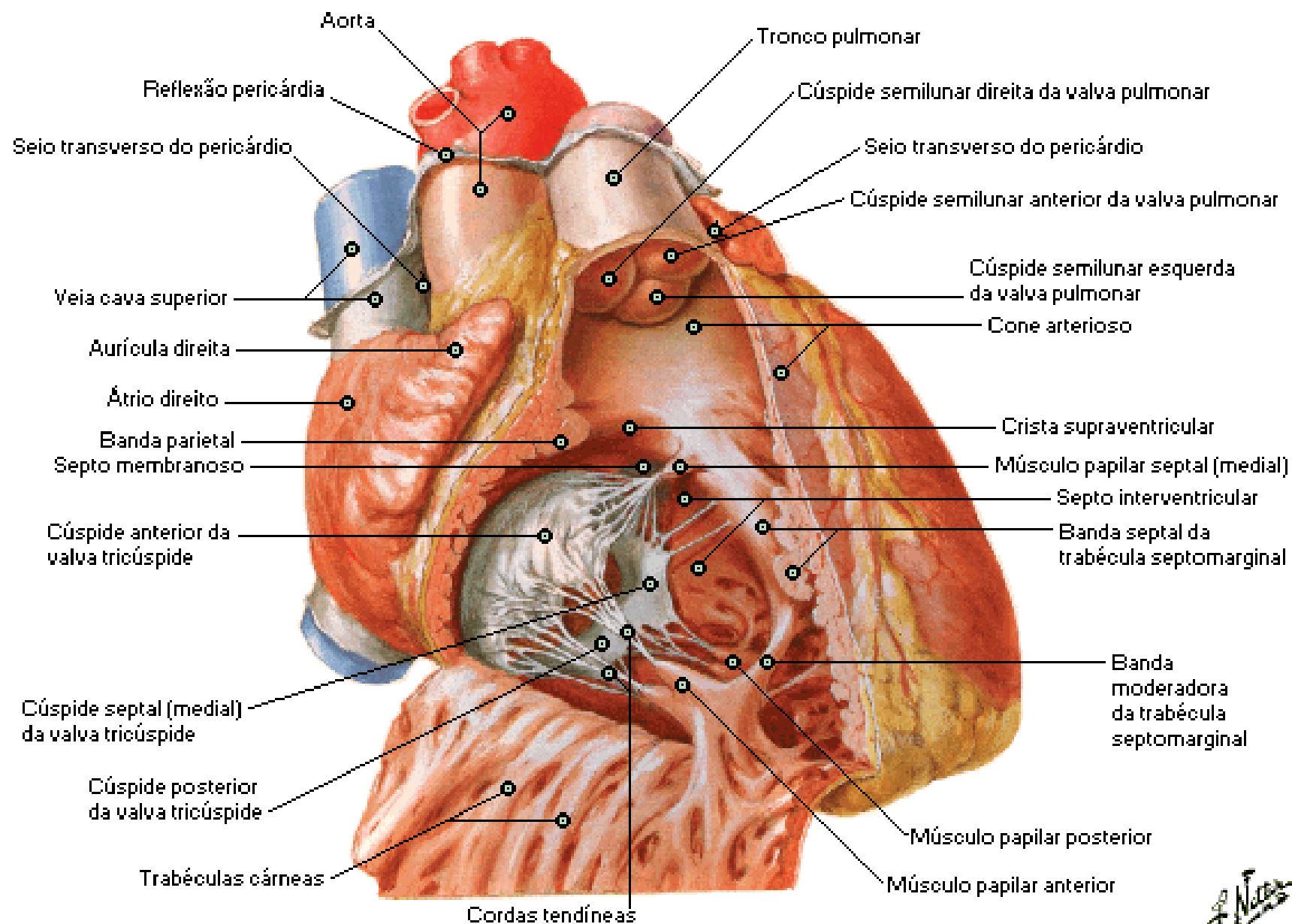
Átrio Direito Aberto

Vista Lateral Direita



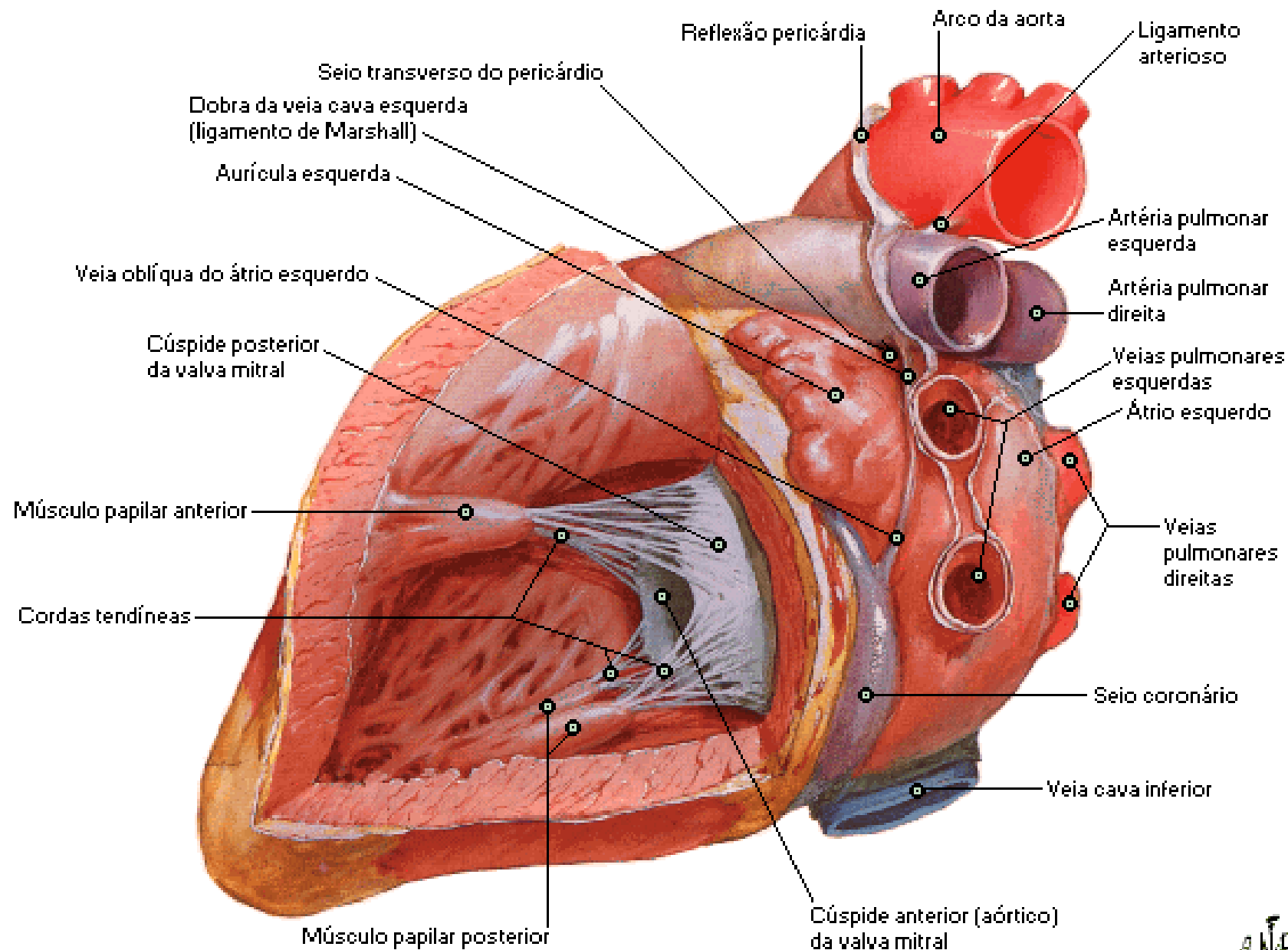
Ventrículo Direito Aberto

Vista Anterior



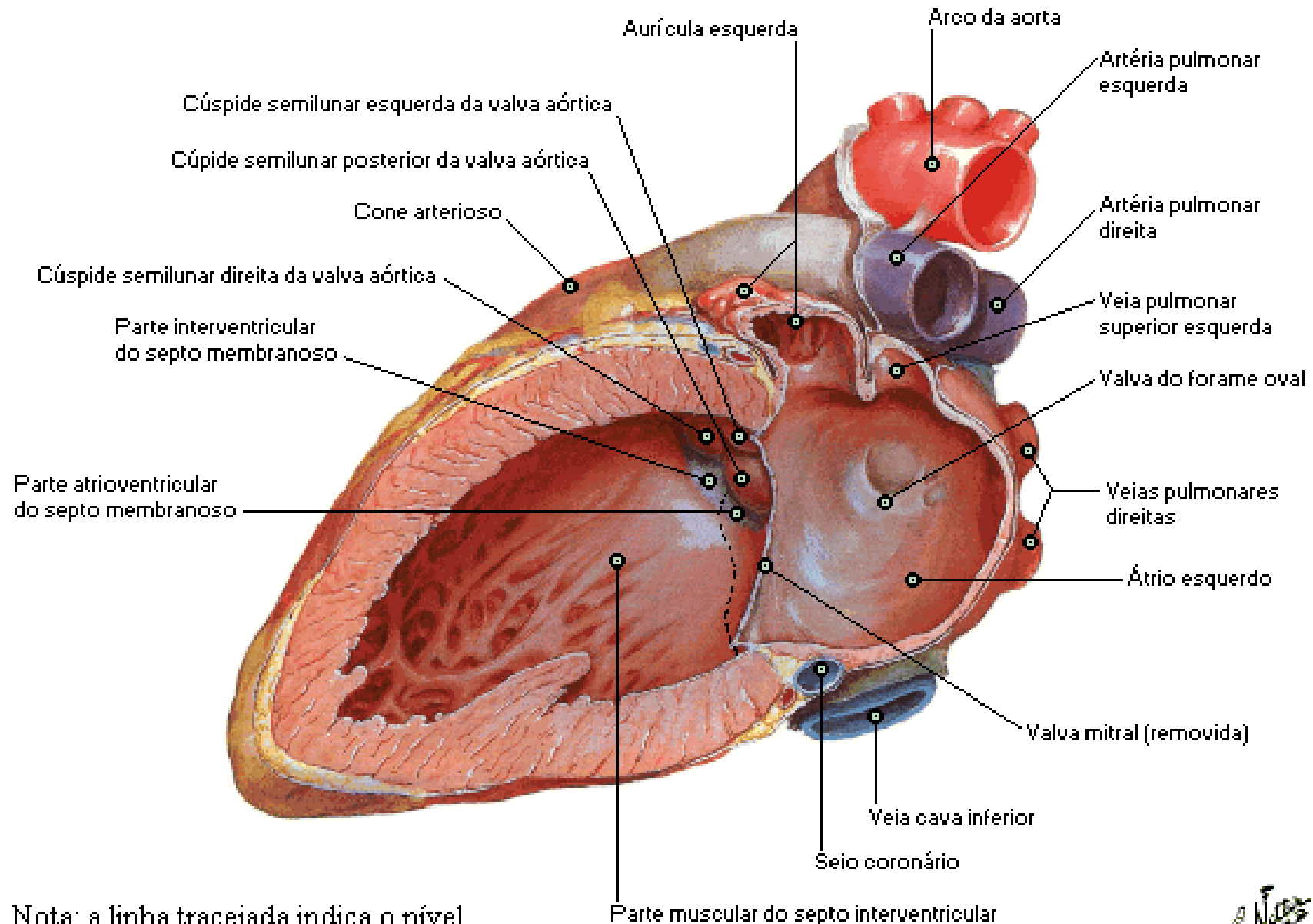
Ventrículo Esquerdo

Retalho Aberto na Parede Póstero-lateral

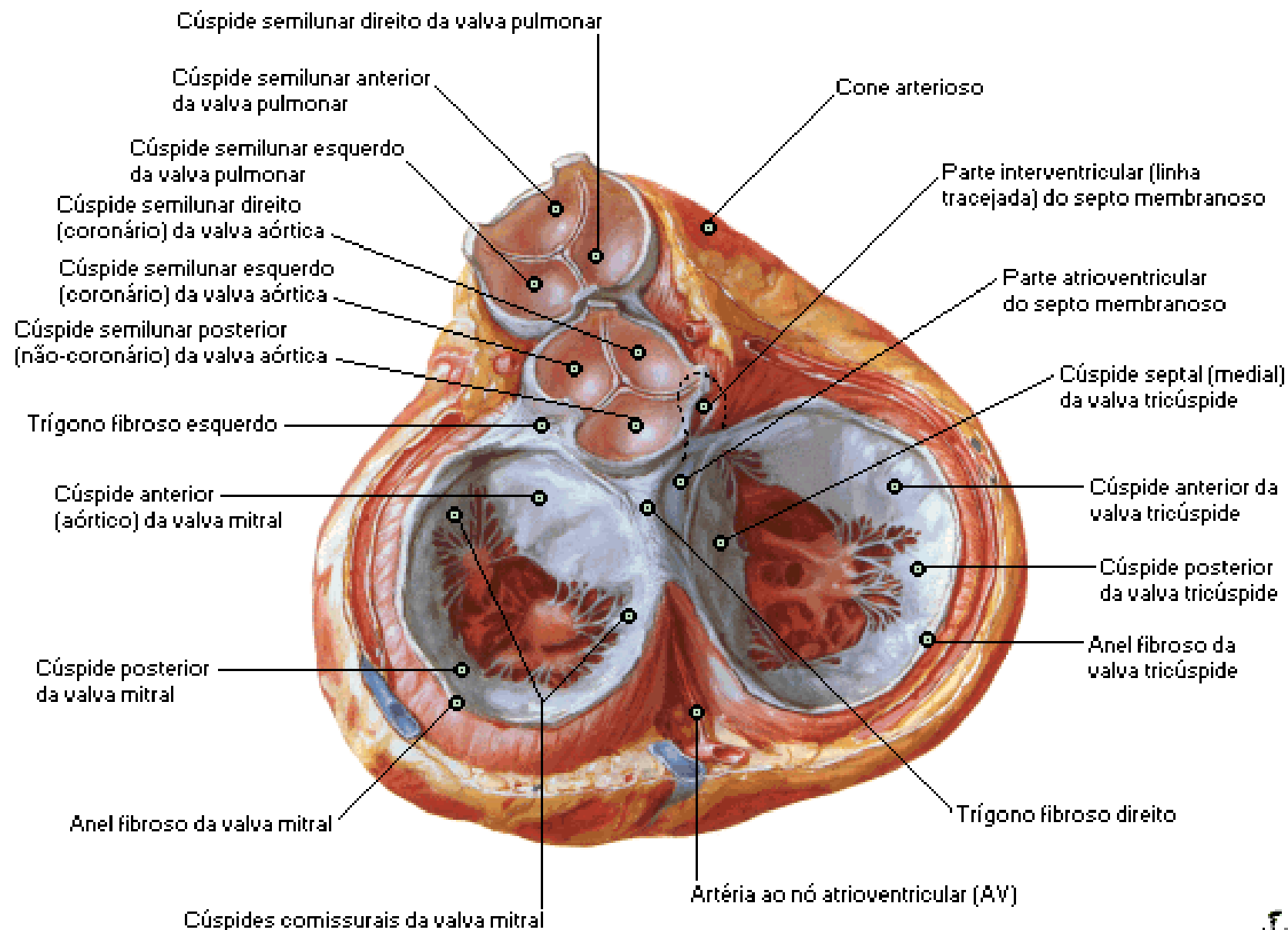


Átrio e Ventrículo Esquerdos

Seccionados com Valva Mitral Removida

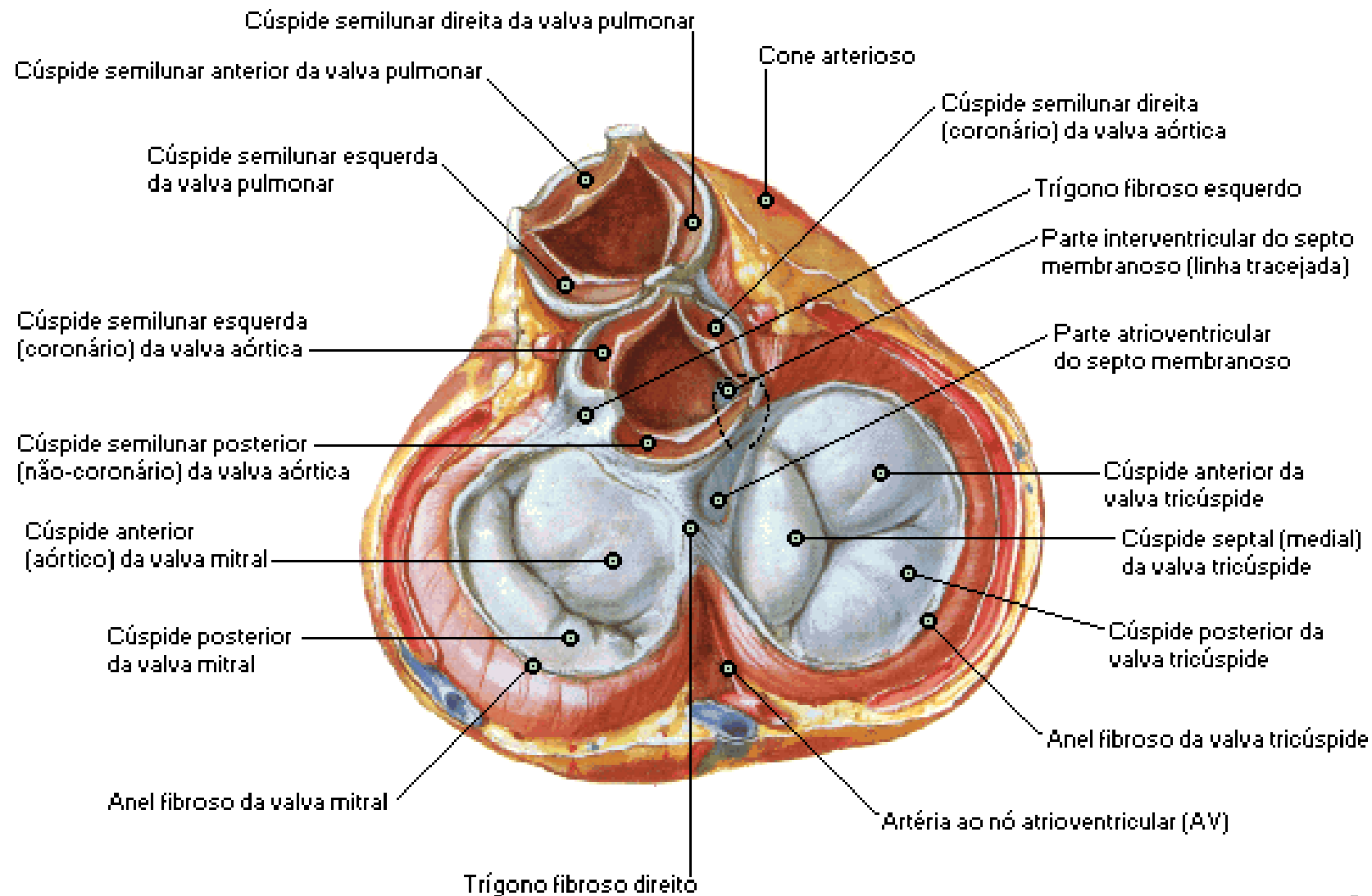


Valvas do Coração na Diástole



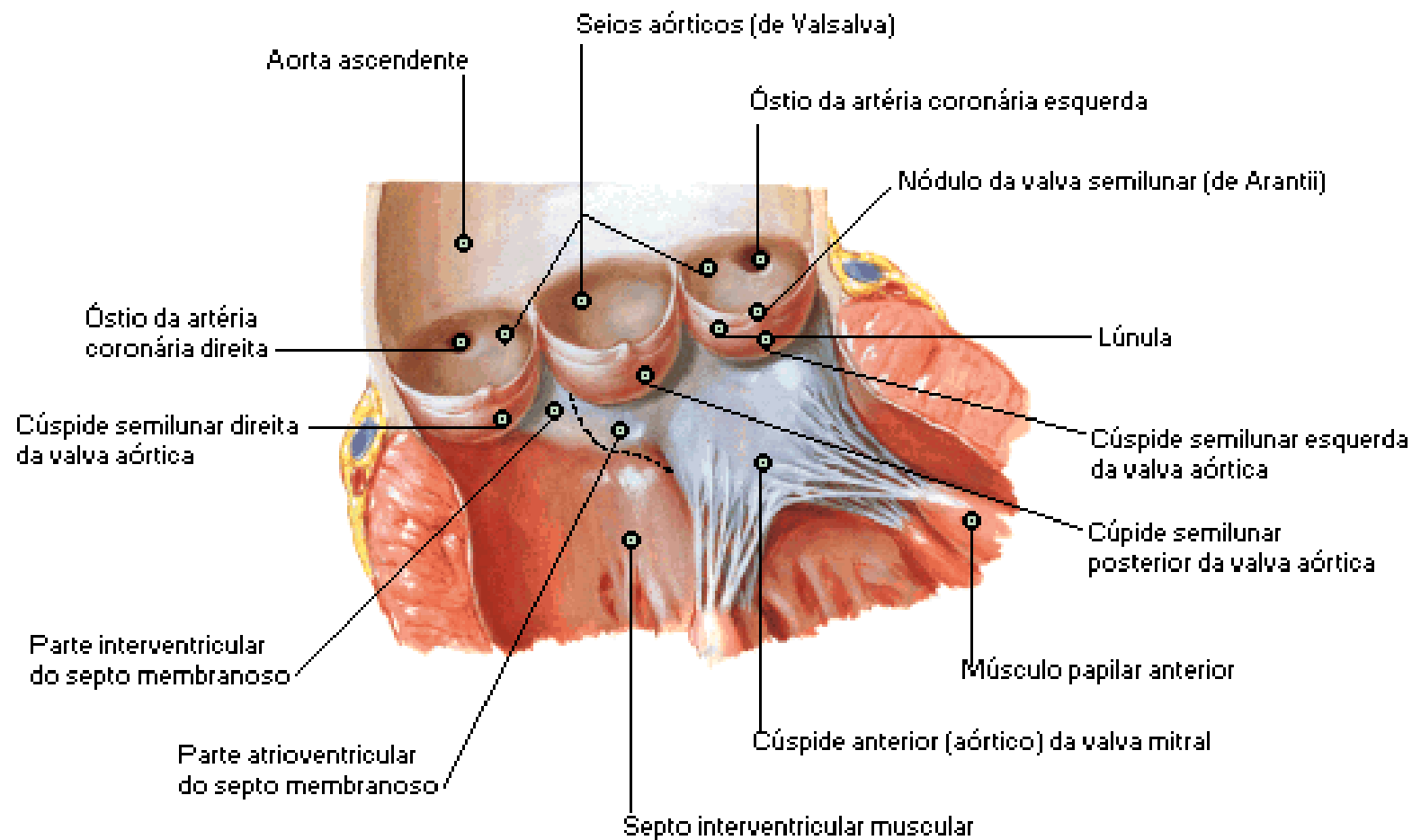
Vista da base com átrios removidos

Valvas do Coração na Sístole



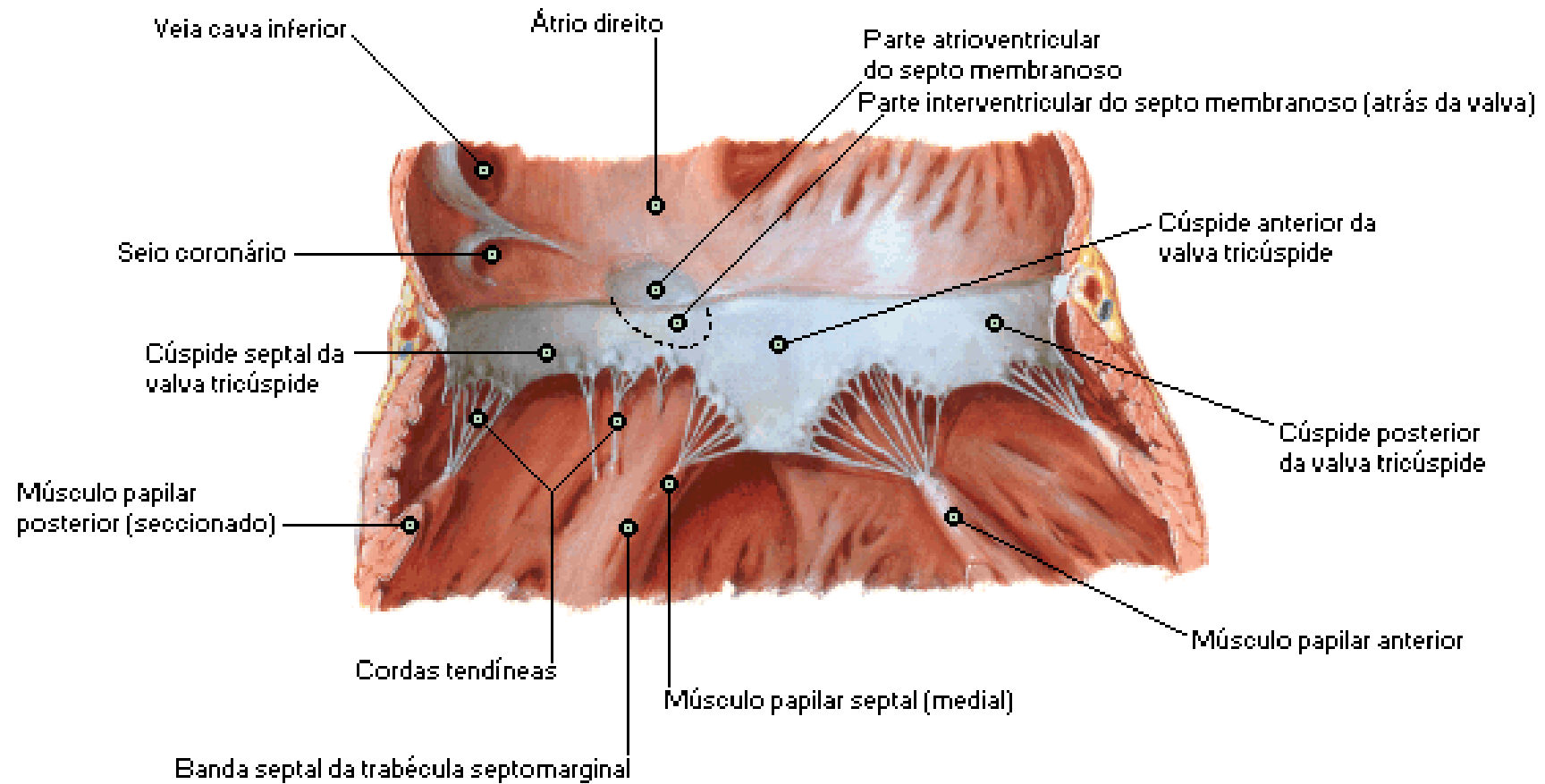
Vista da base com átrios removidos

Valva da Aorta

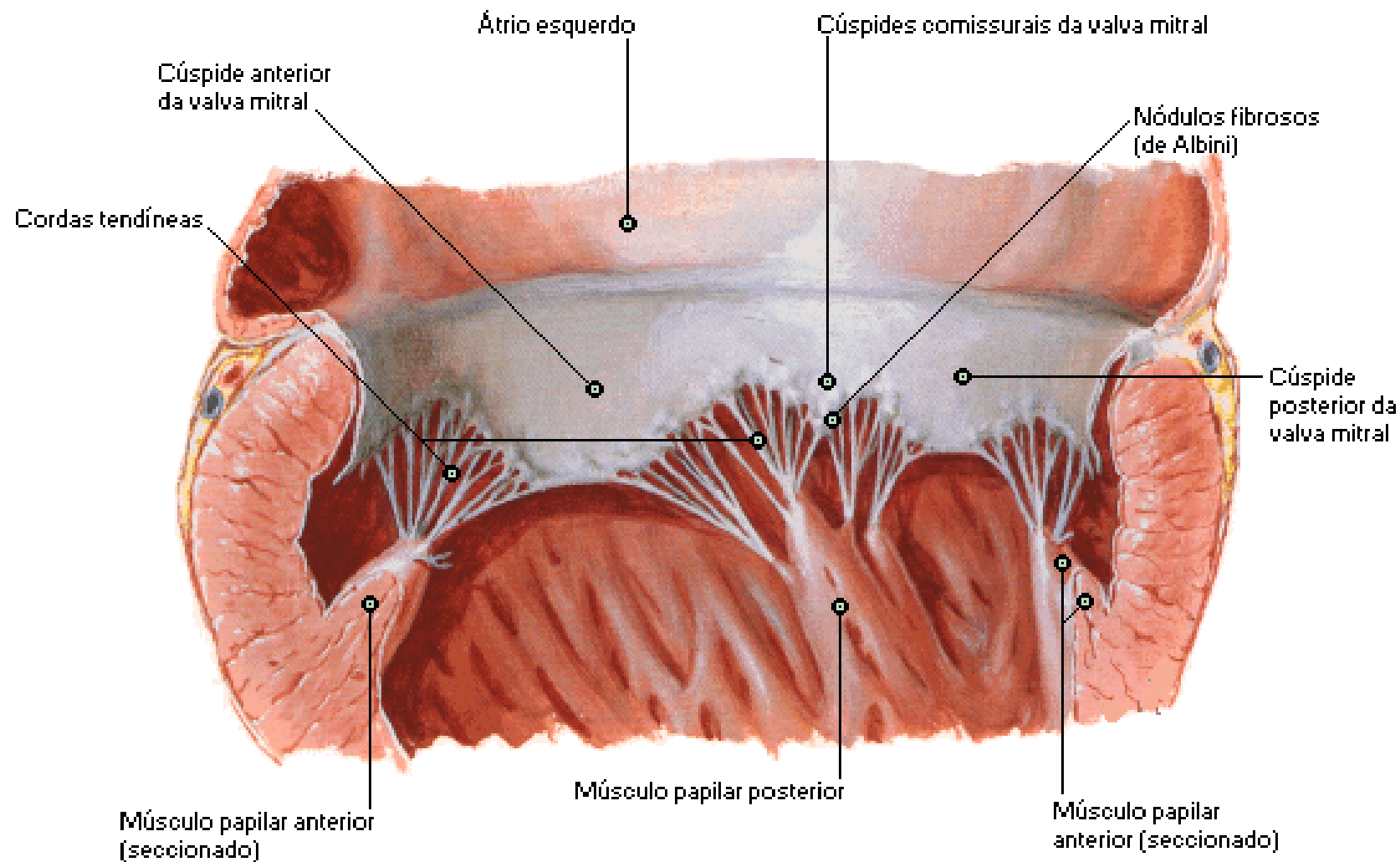


Nota: a linha tracejada indica o nível da origem da valva tricúspide no lado oposto do septo

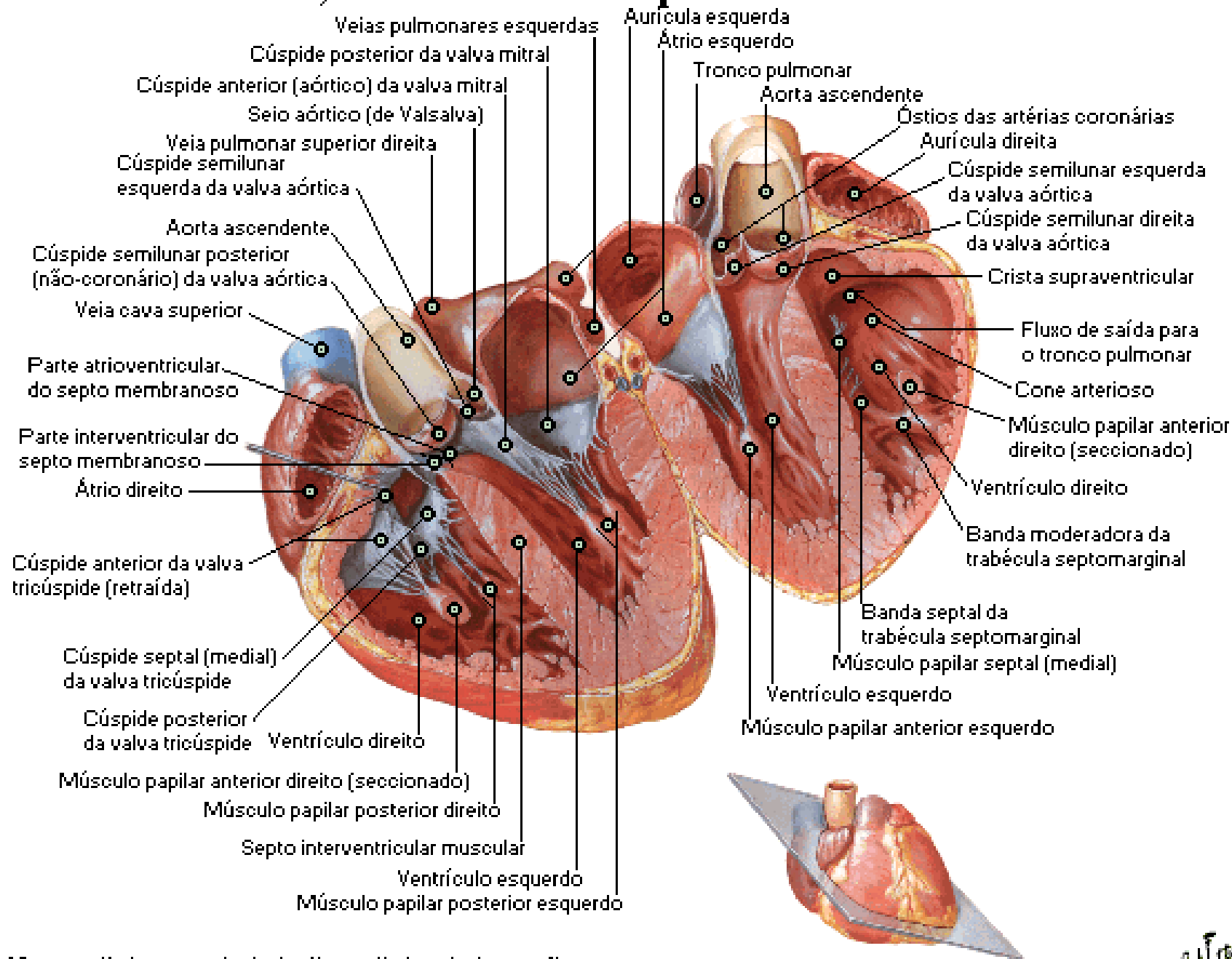
Valva Atrioventricular Direita [Tricúspide]



Valva Atrioventricular Esquerda [Mitral]

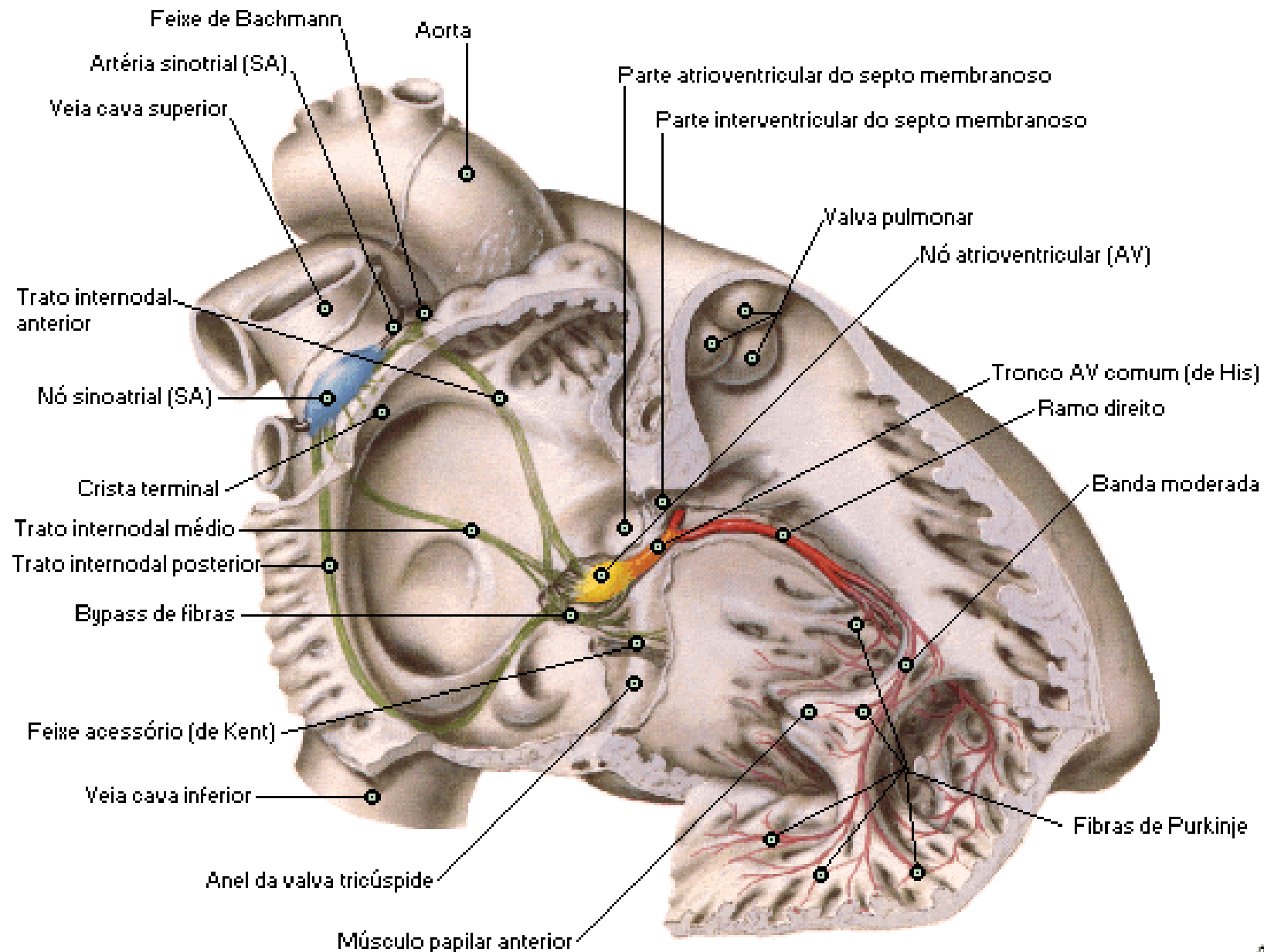


Átrios, Ventrículos e Septo Interventricular



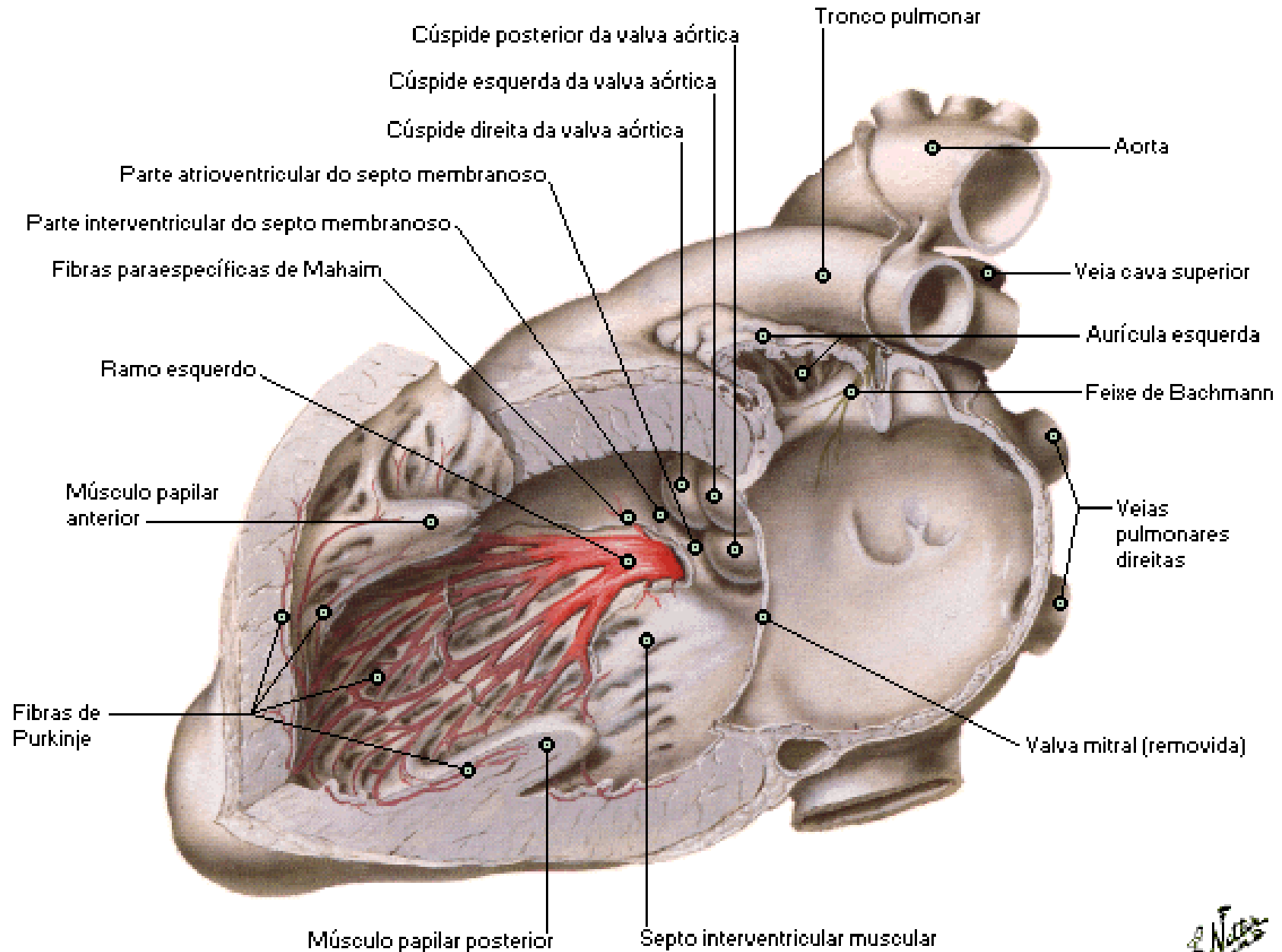
Sistema Condutor do Coração

Lado Direito

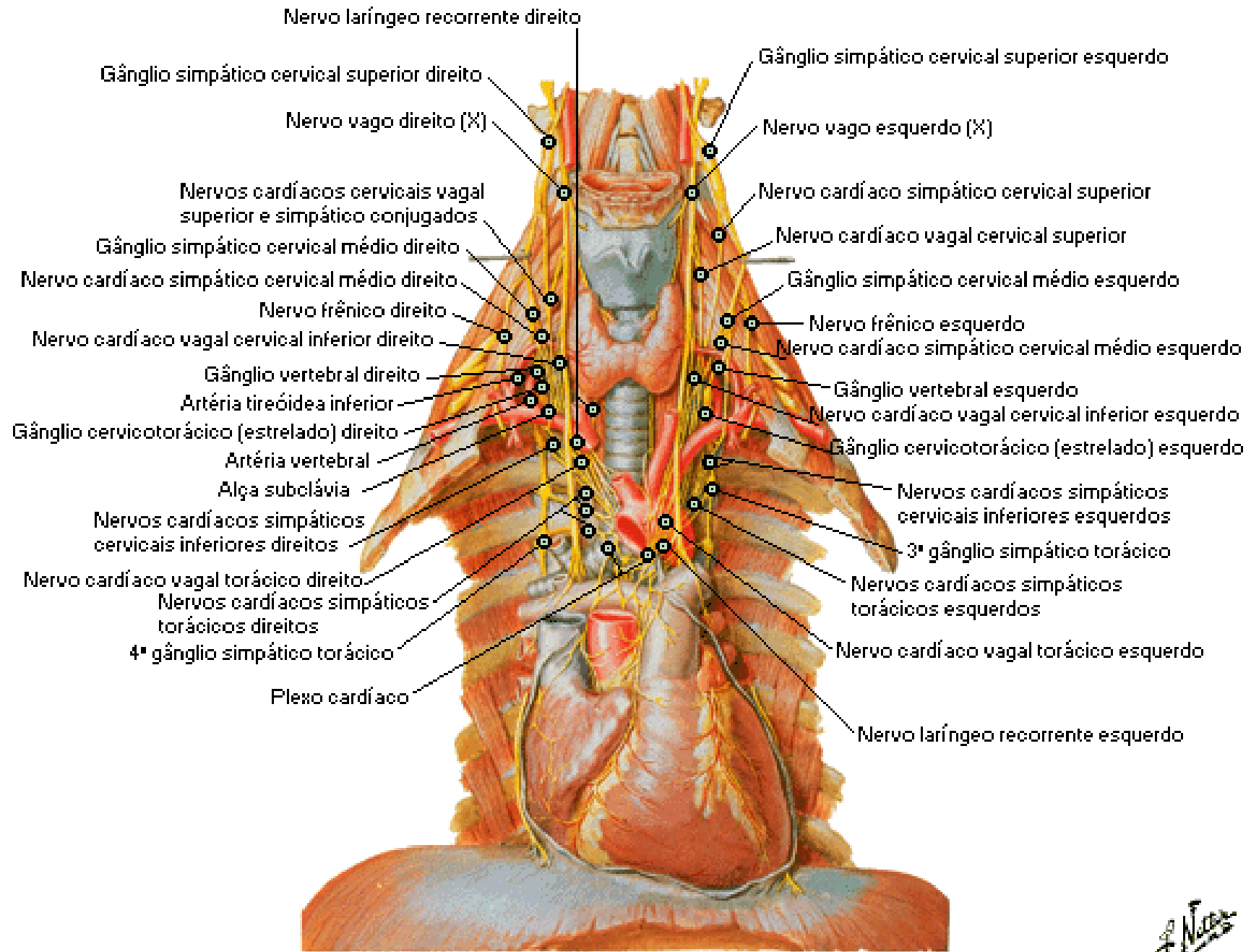


Sistema Condutor do Coração

Lado Esquerdo

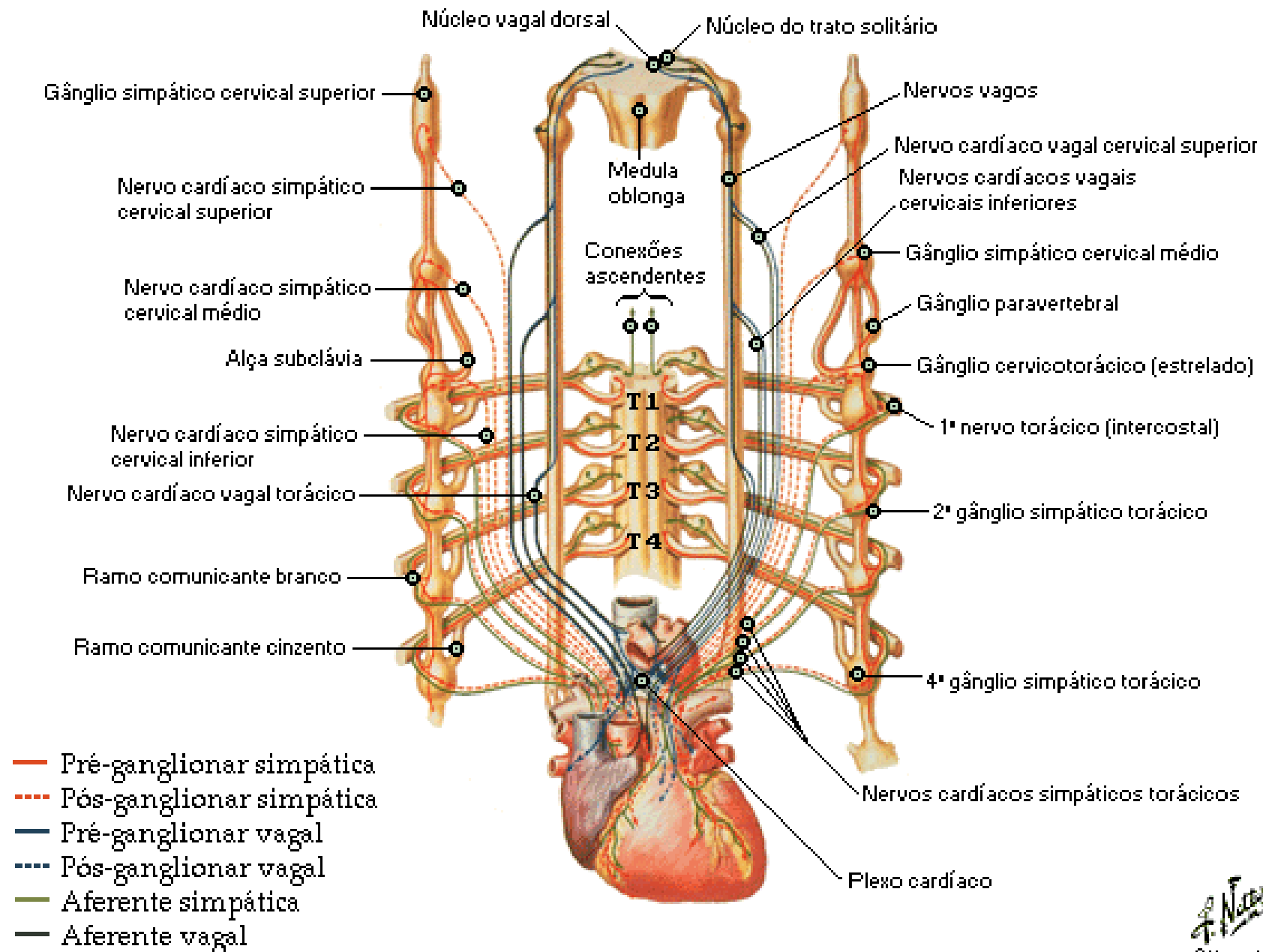


Nervos do Coração



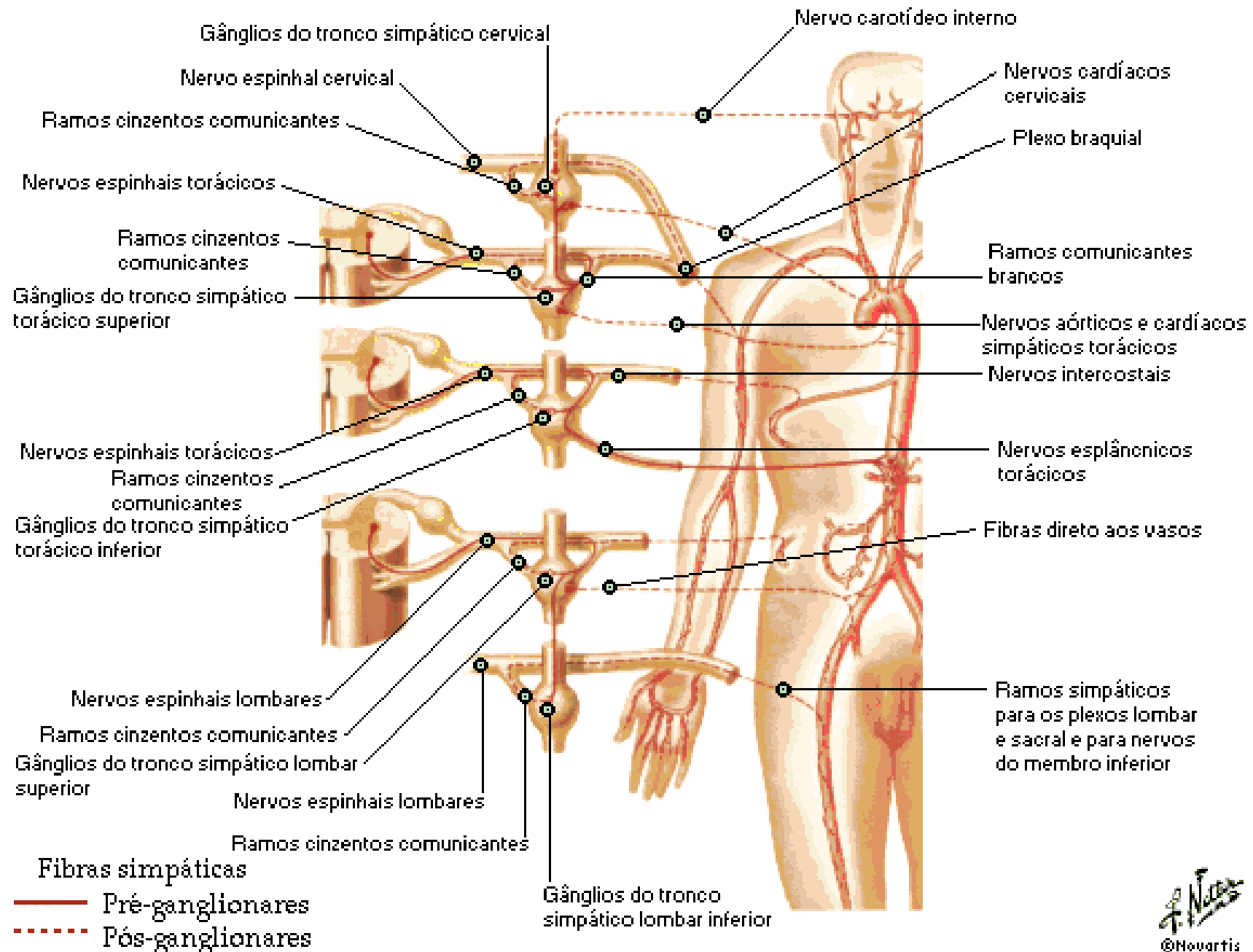
Inervação do Coração

Esquema

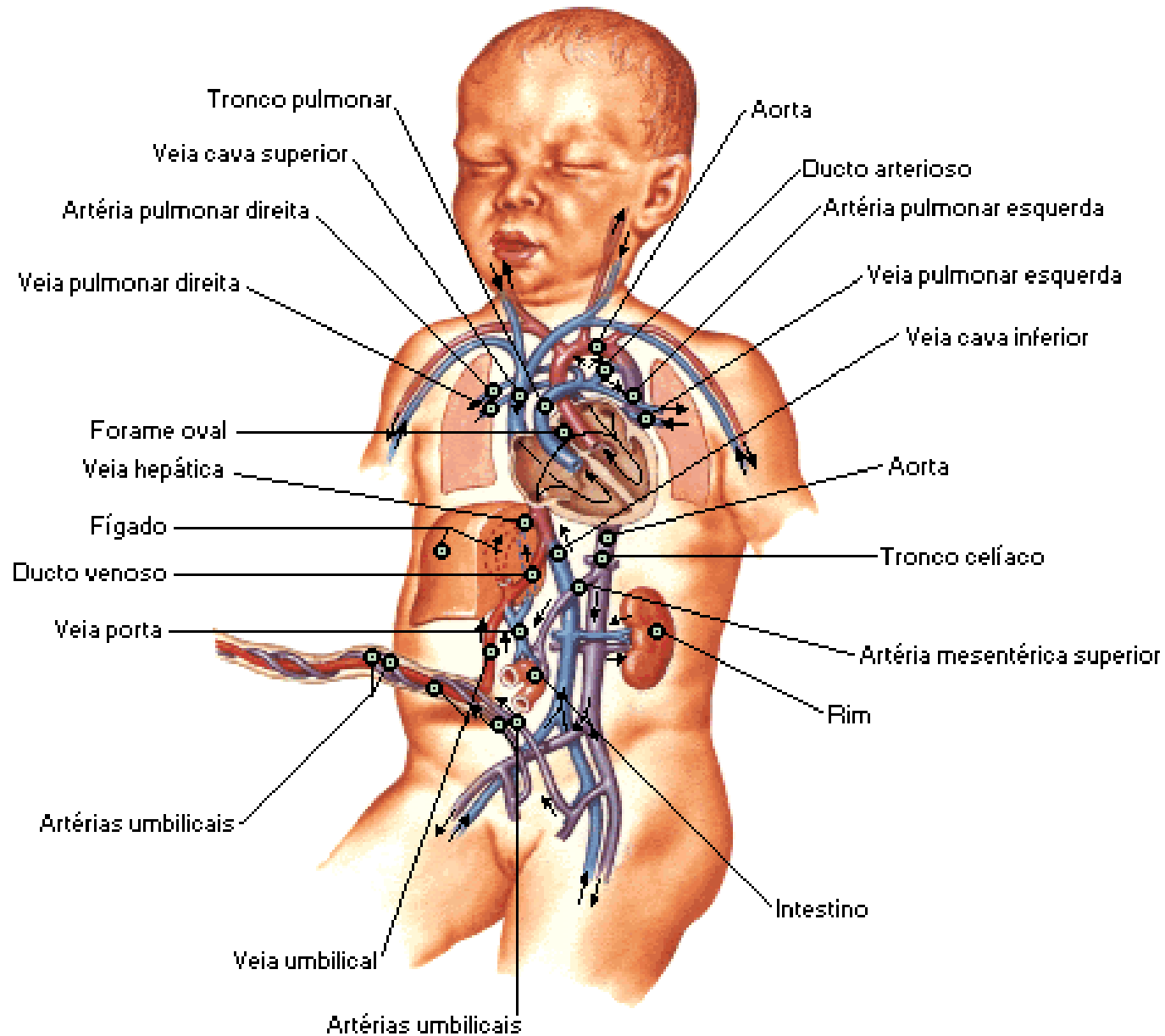


Inervação do Coração

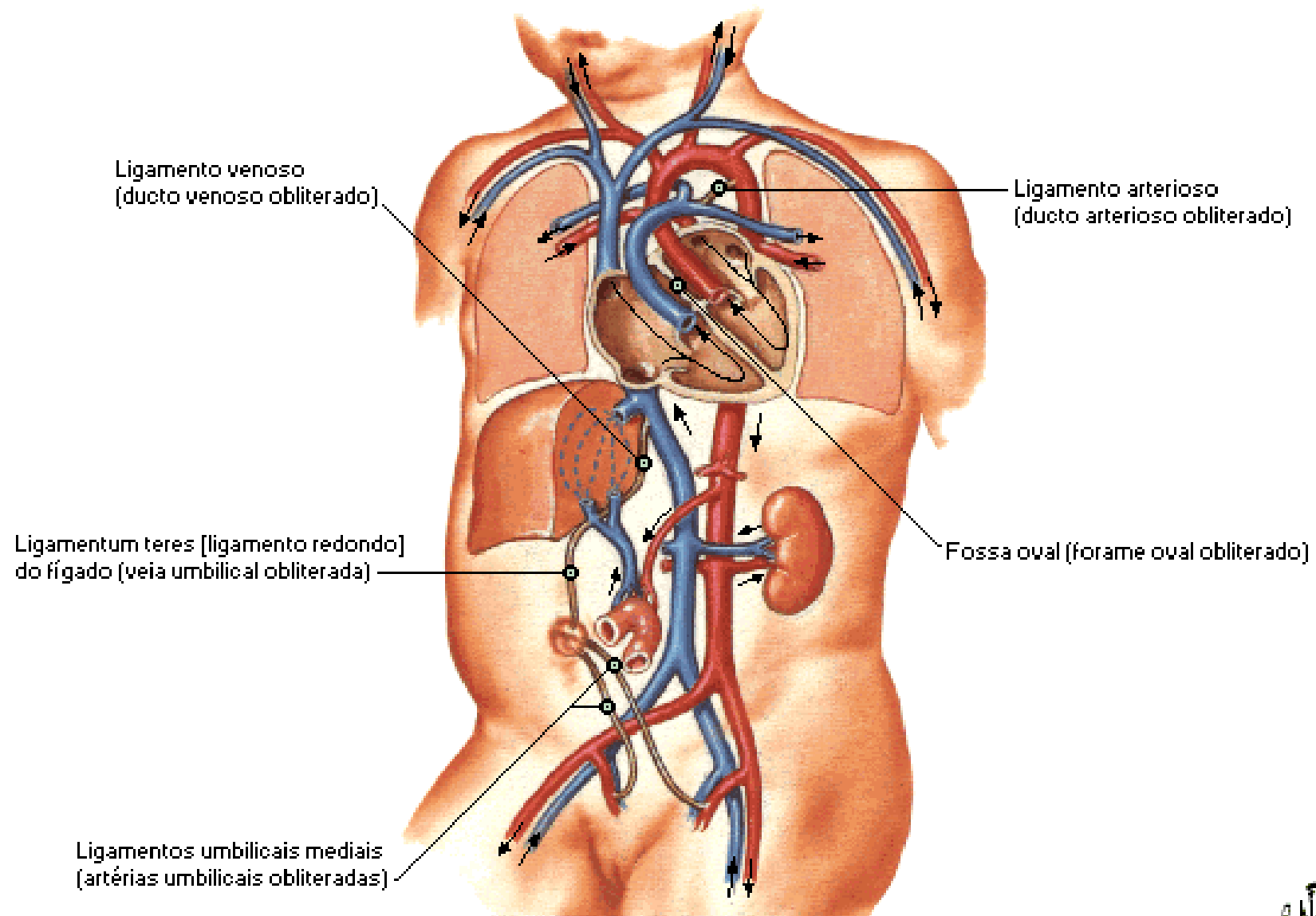
Esquema



Circulação Pré-natal

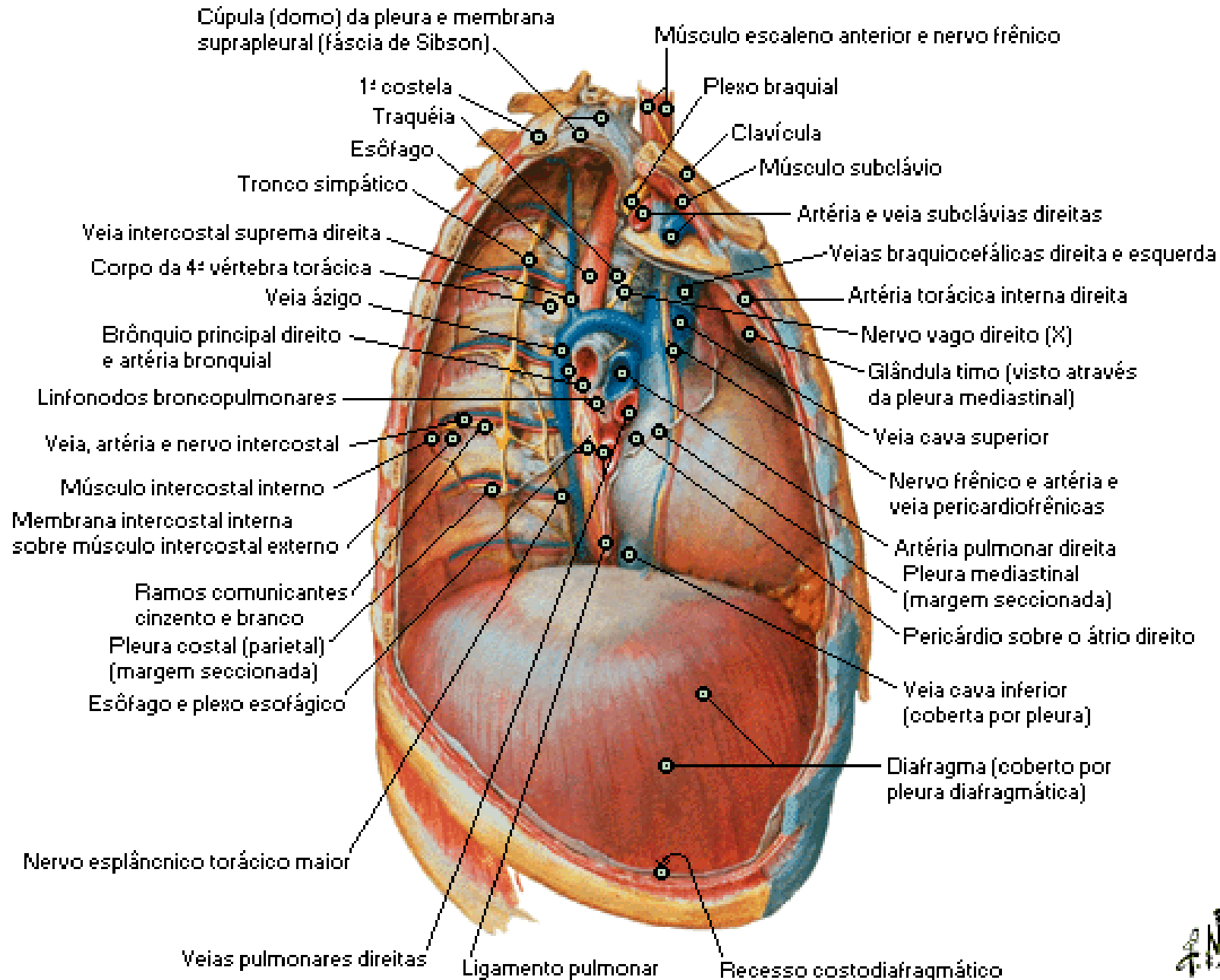


Circulação Pós-natal



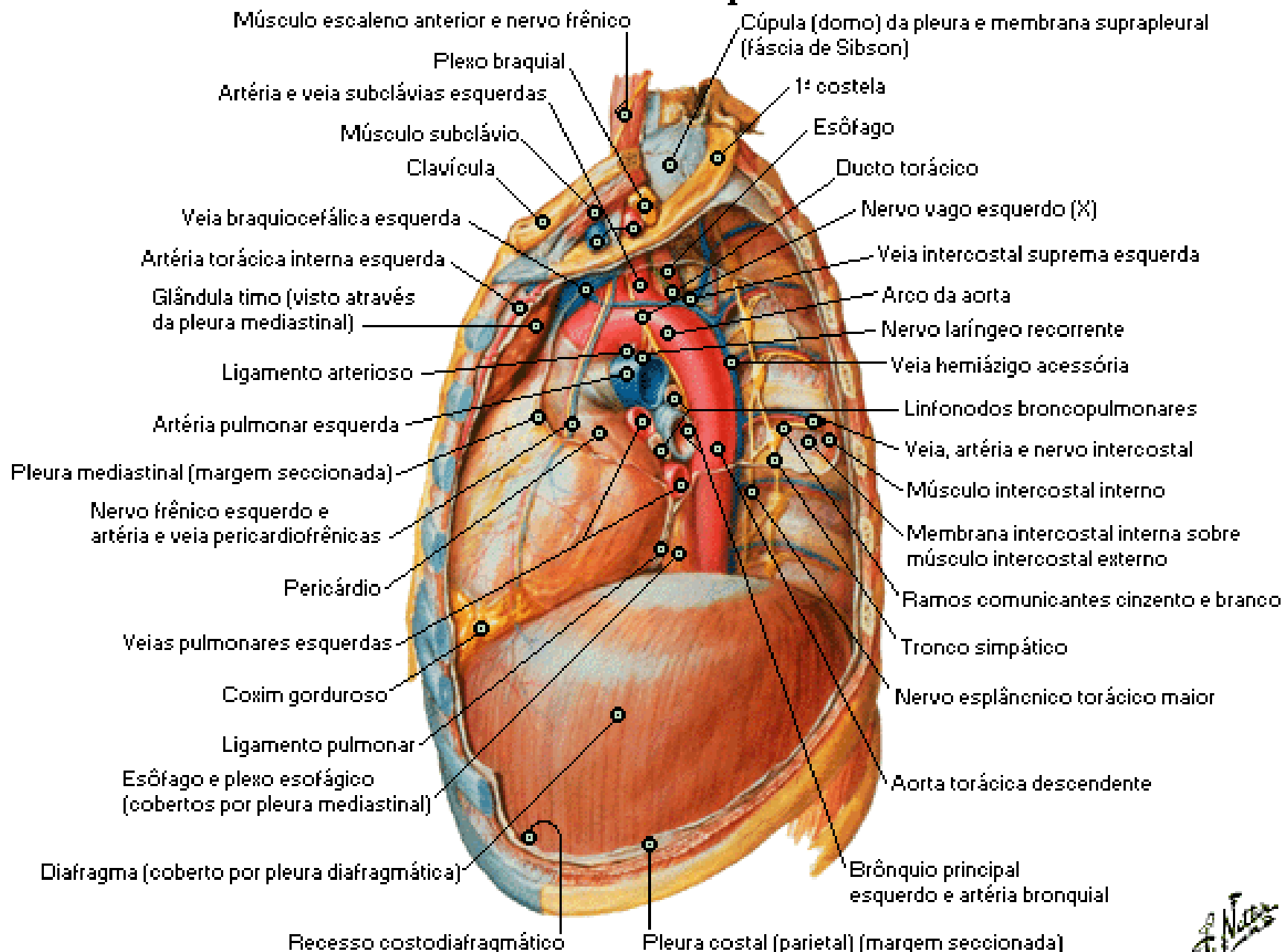
Mediastino

Vista Lateral Direita

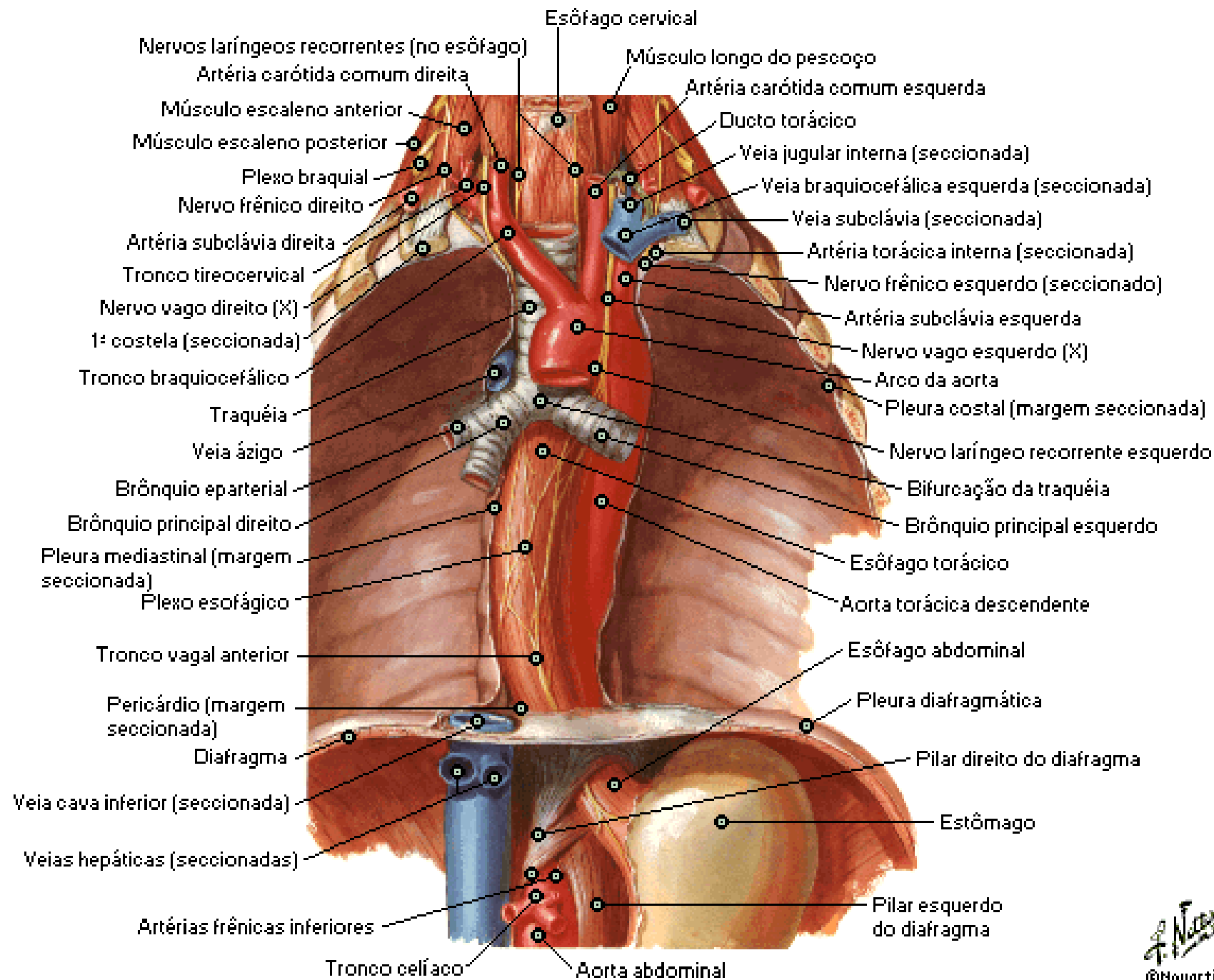


Mediastino

Vista Lateral Esquerda

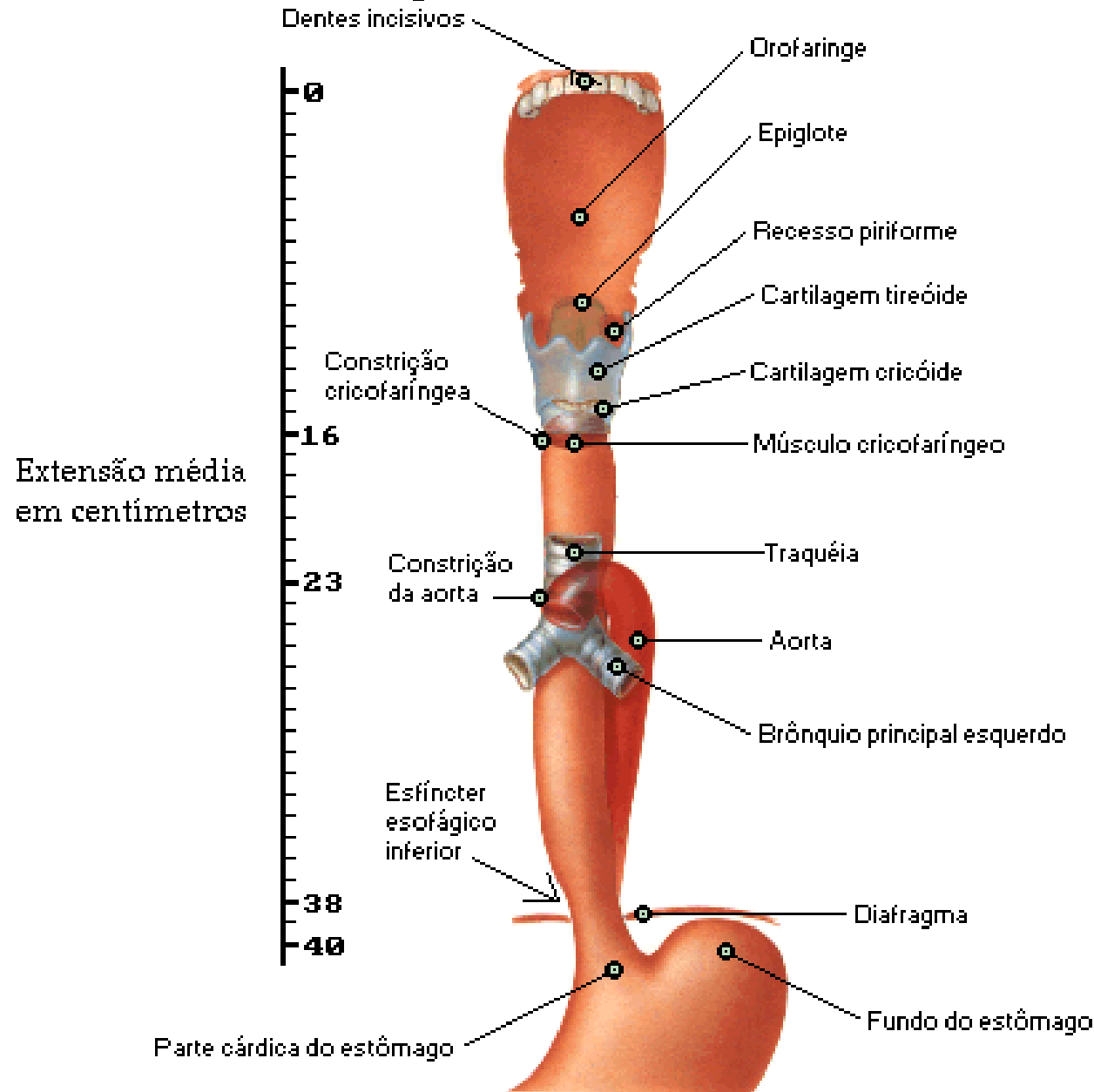


Esôfago in Situ



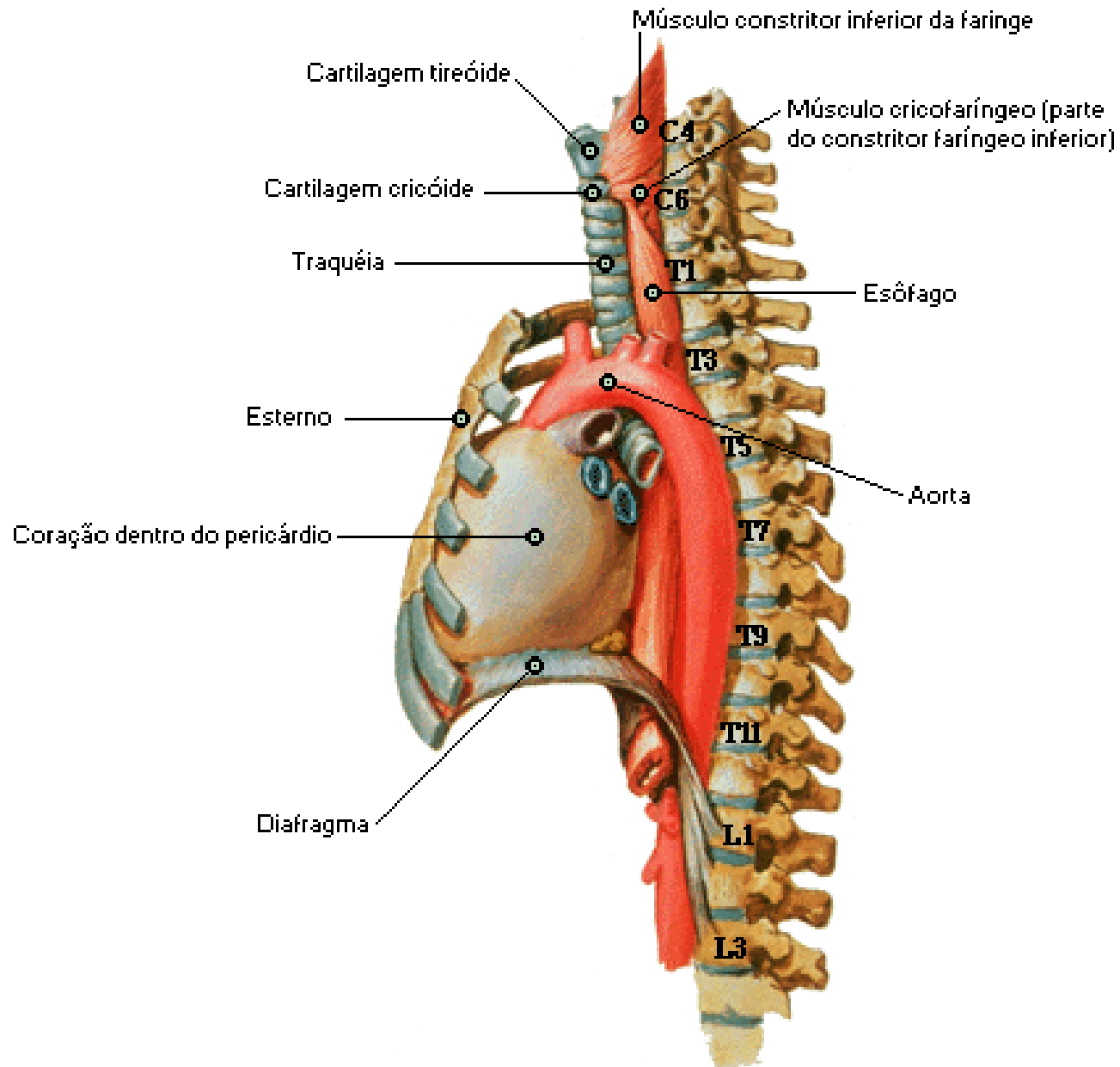
Topografia e Condições do Esôfago

Esquema - Vista Anterior

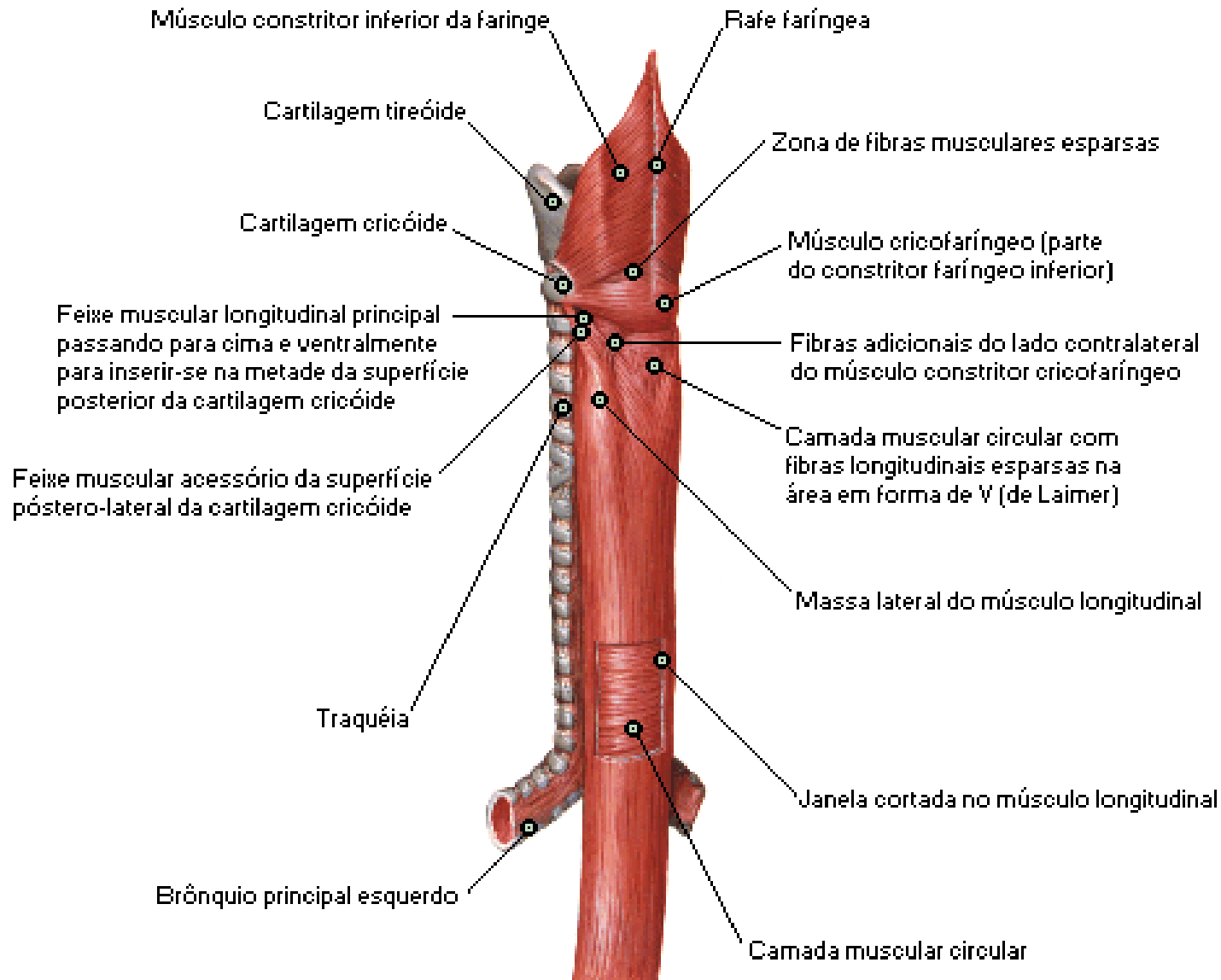


Topografia e Condições do Esôfago

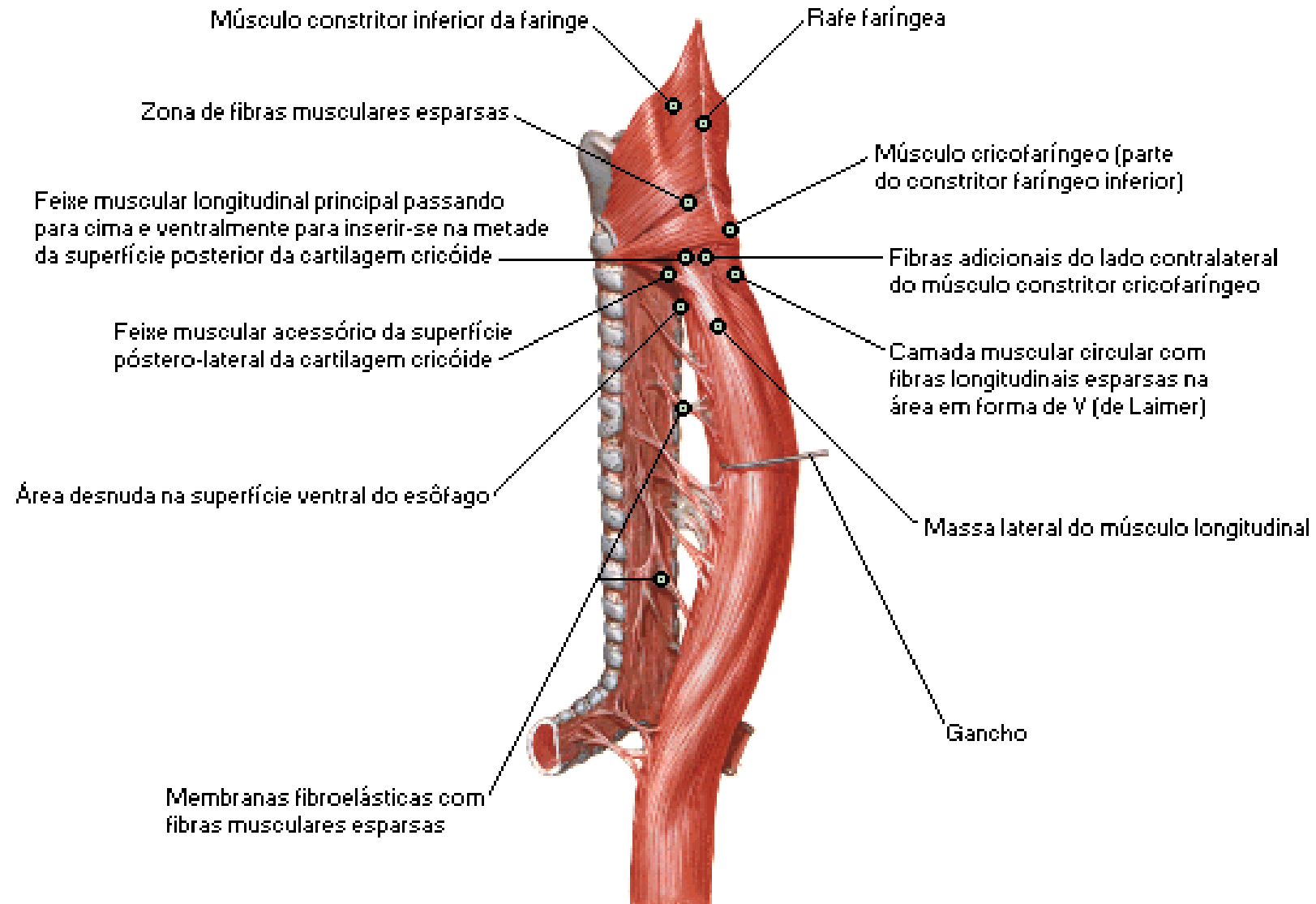
Vista Lateral



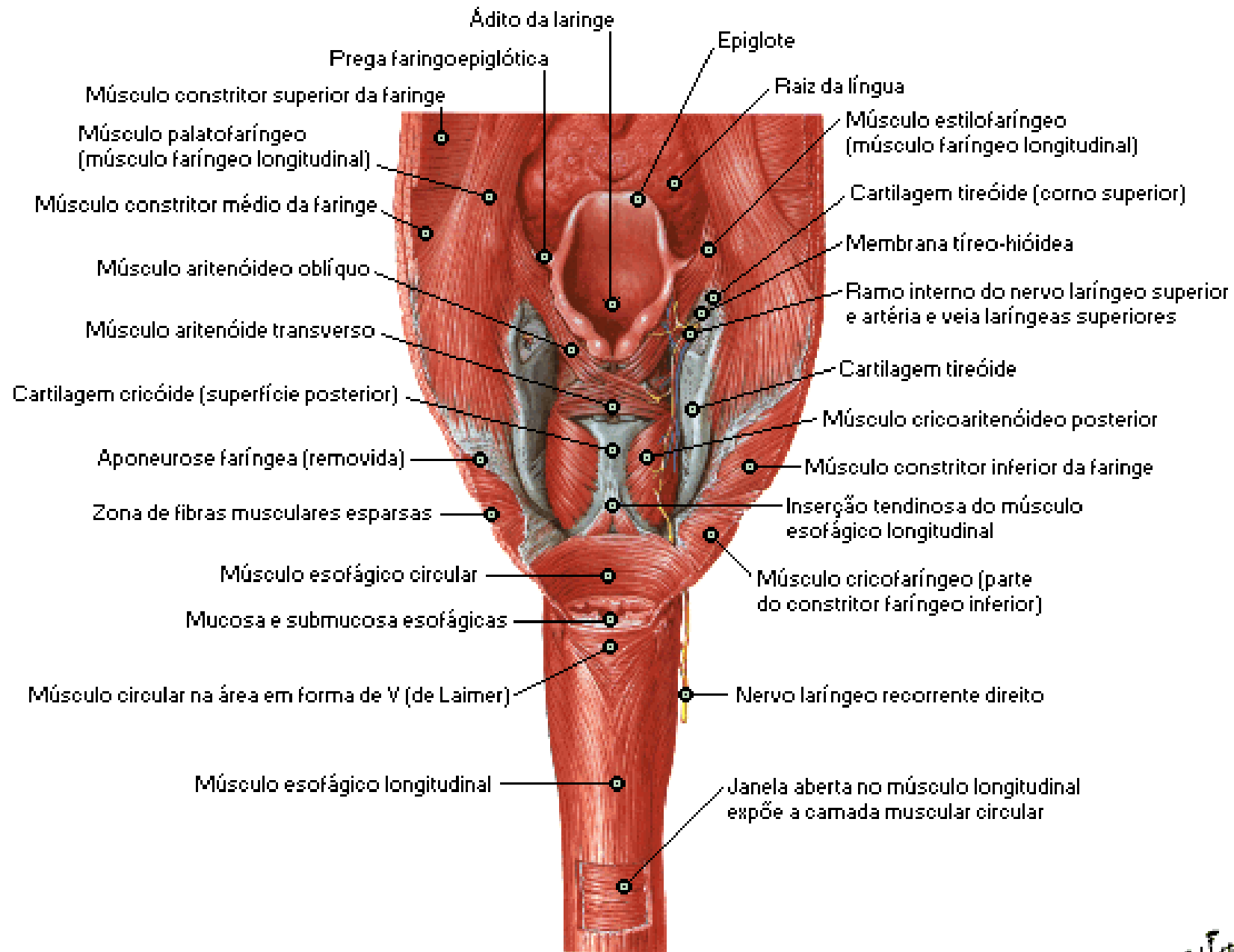
Musculatura do Esôfago



Musculatura do Esôfago



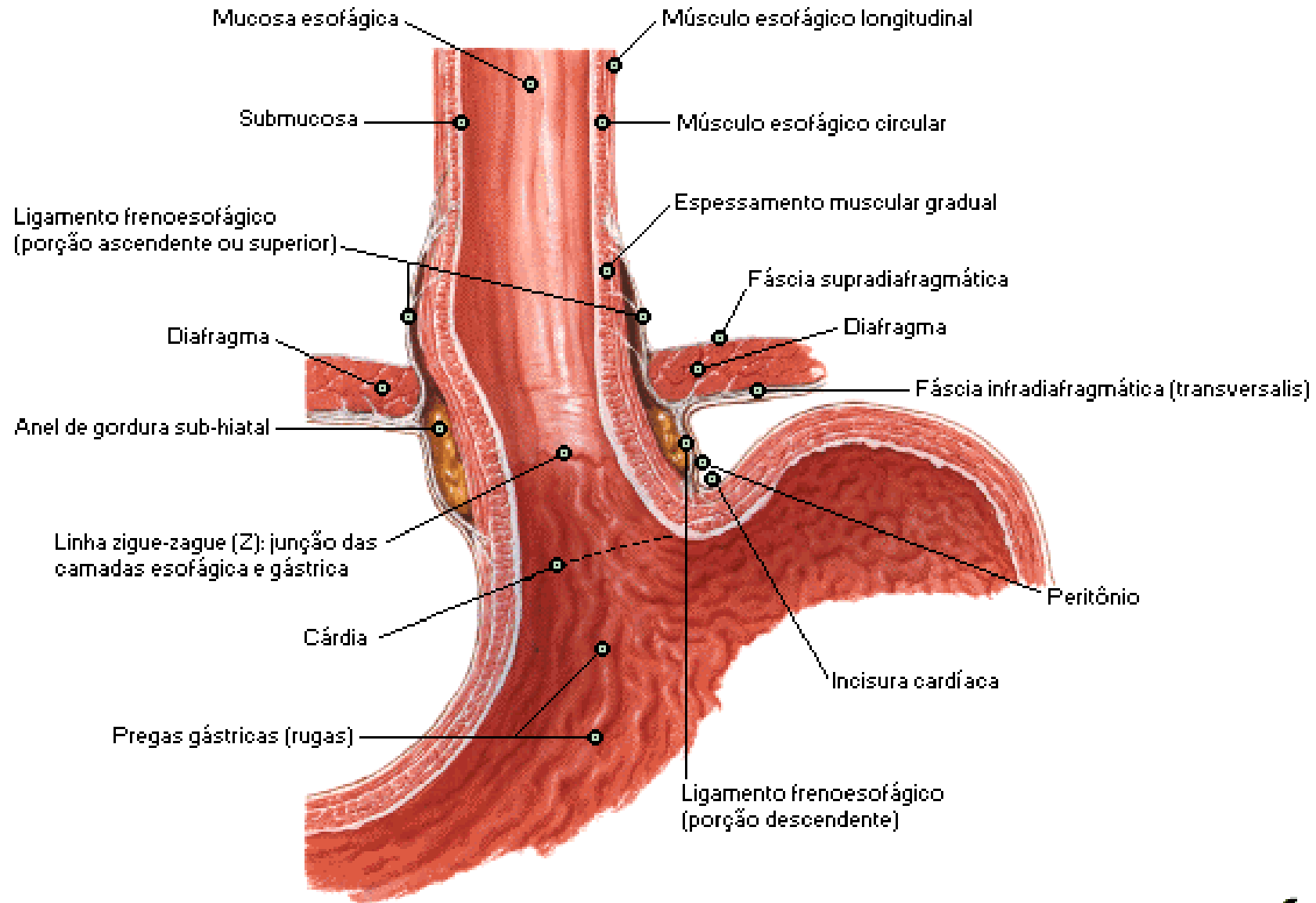
Junção Faringoesofágica



Vista posterior com a faringe aberta e a mucosa removida

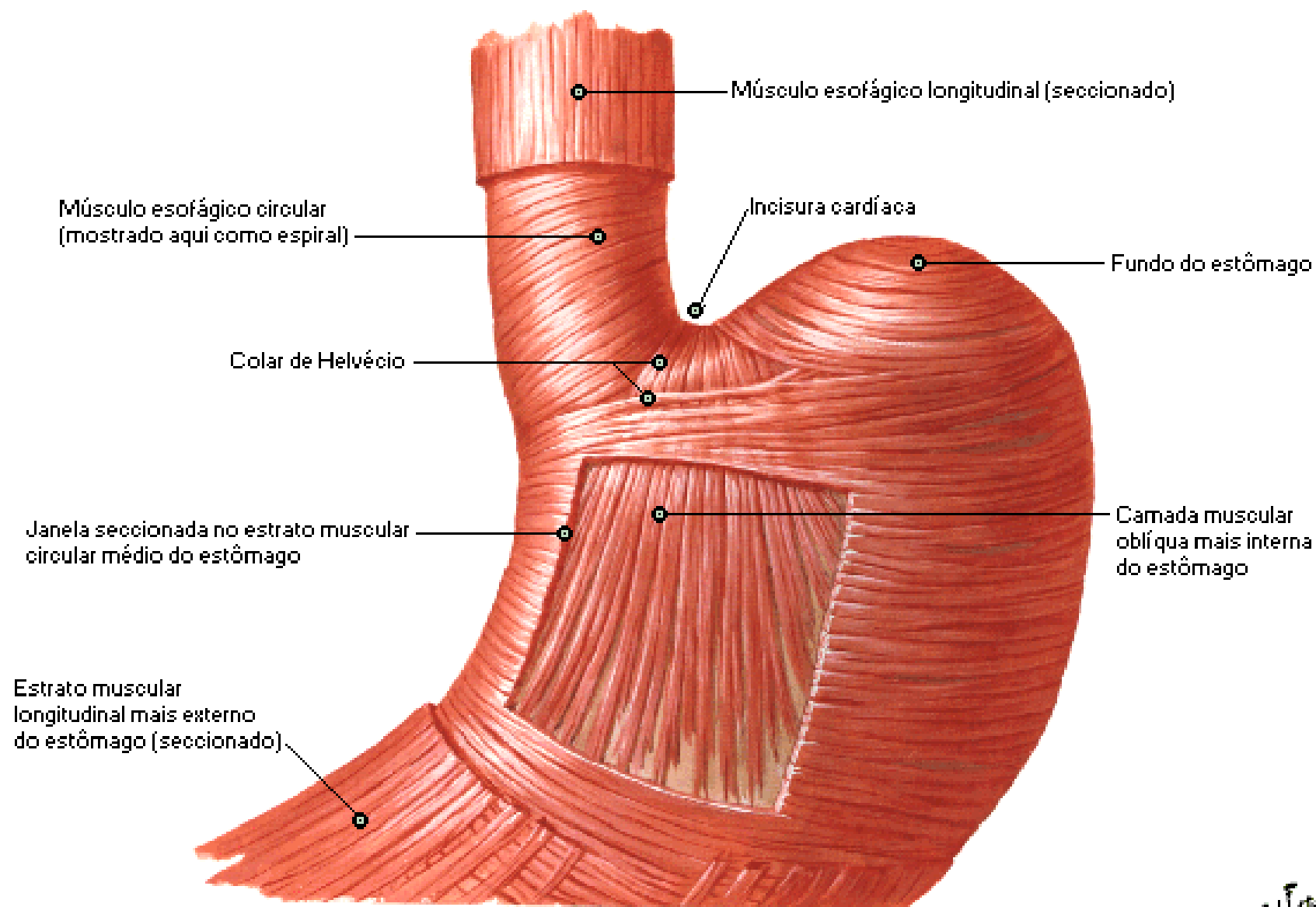
Junção Esofagogástrica

Secção Coronal

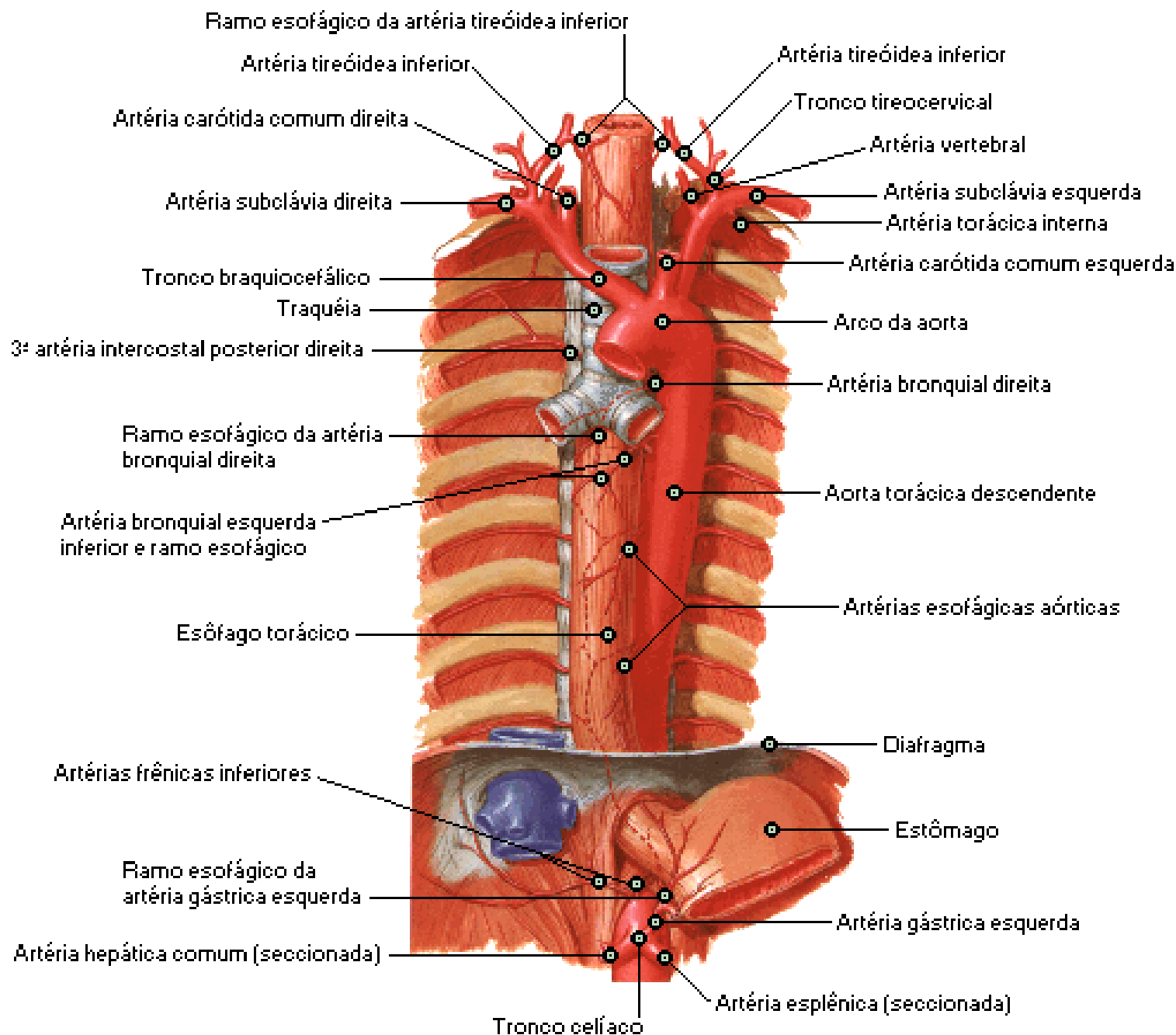


Junção Esofagogástrica

Vista Anterior

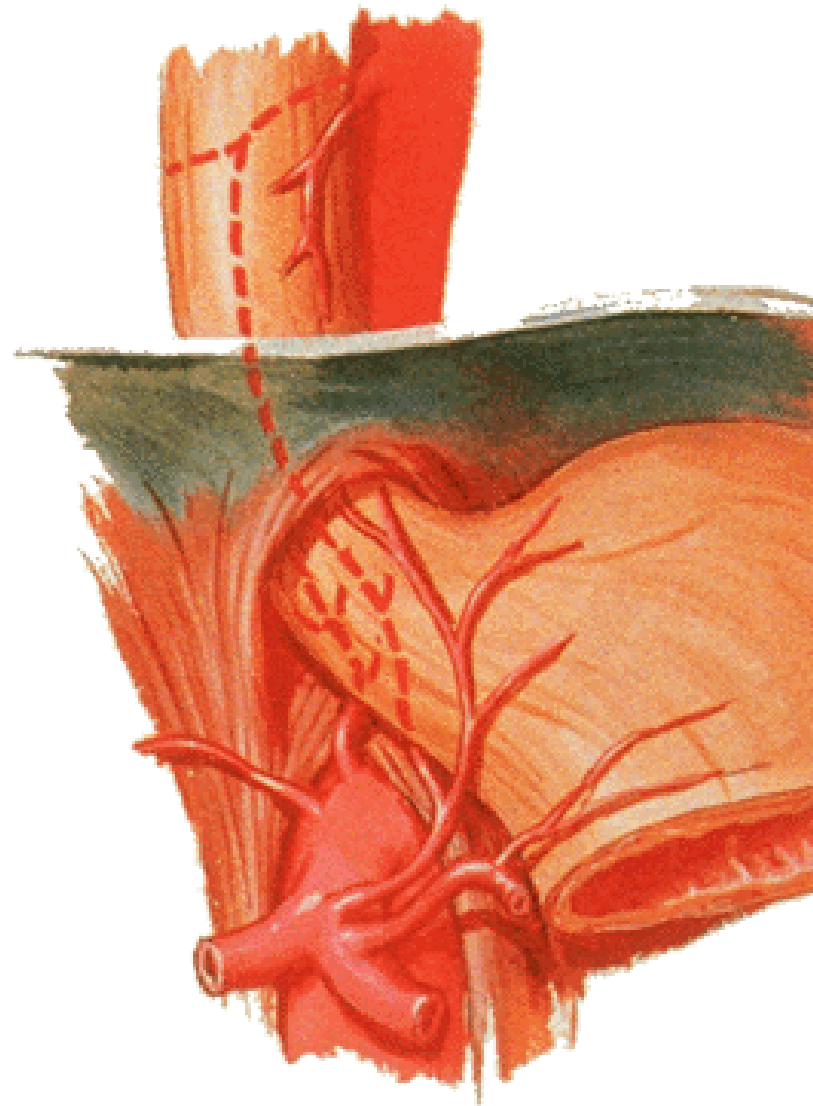


Artérias do Esôfago



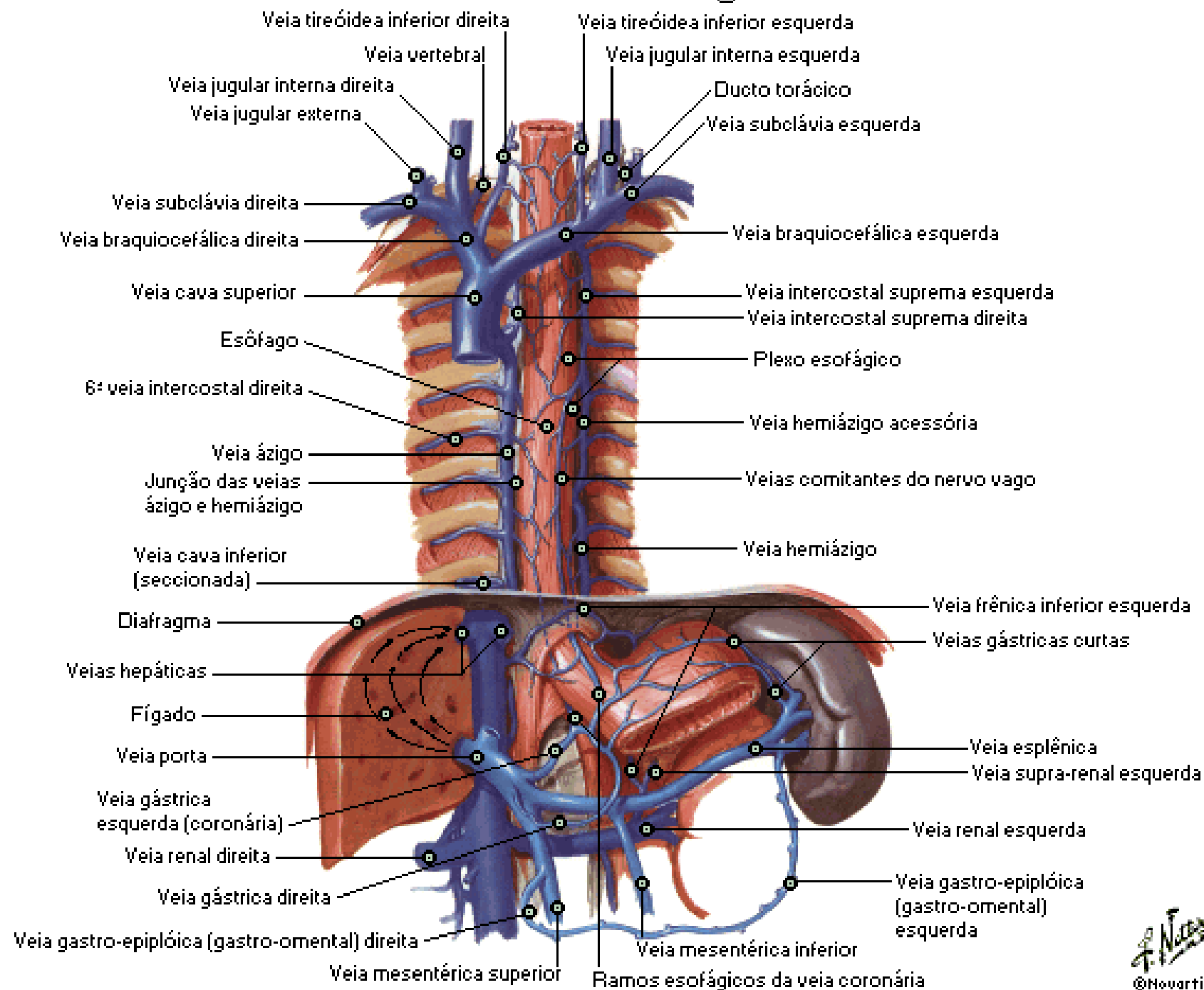
Artérias do Esôfago

Variações



Variações comuns: ramos esofágicos podem originar-se da artéria frênica inferior esquerda e/ou diretamente do tronco celíaco. Os ramos para o esôfago abdominal podem também se originar das artérias esplênica ou gástrica curtas

Veias do Esôfago

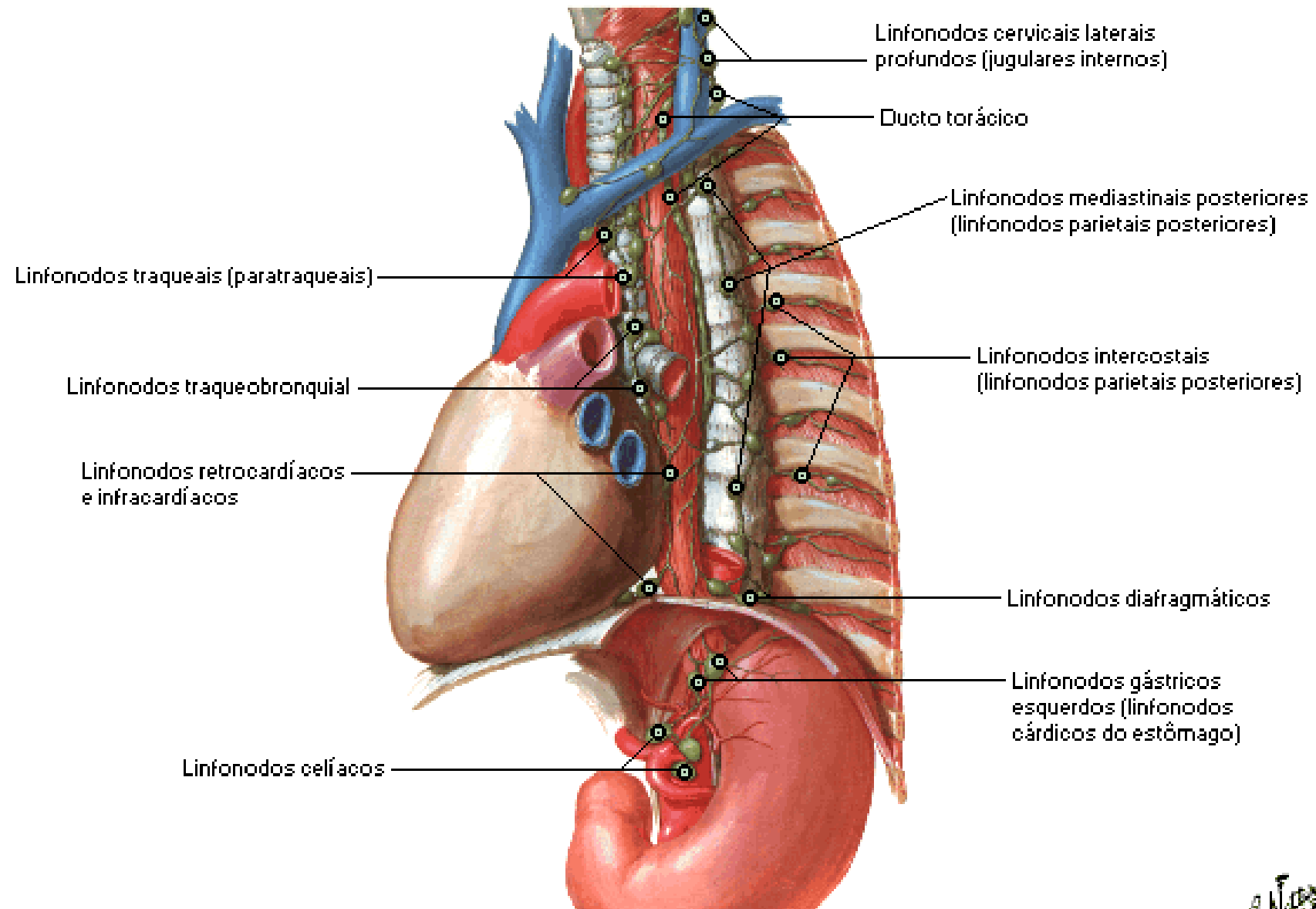


Veias do Esôfago

Plexo Venoso Submucoso

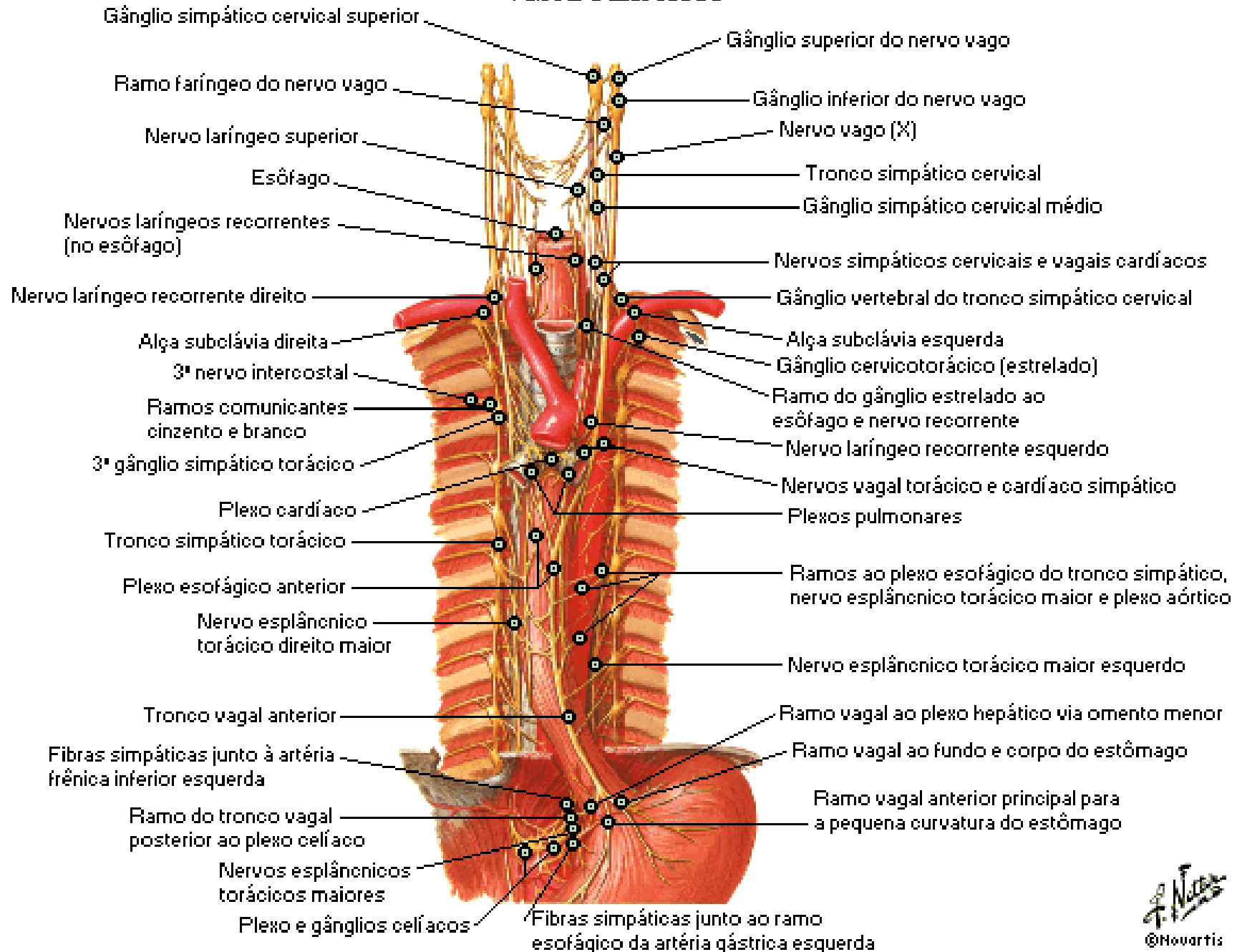


Vasos Linfáticos e Linfonodos do Esôfago



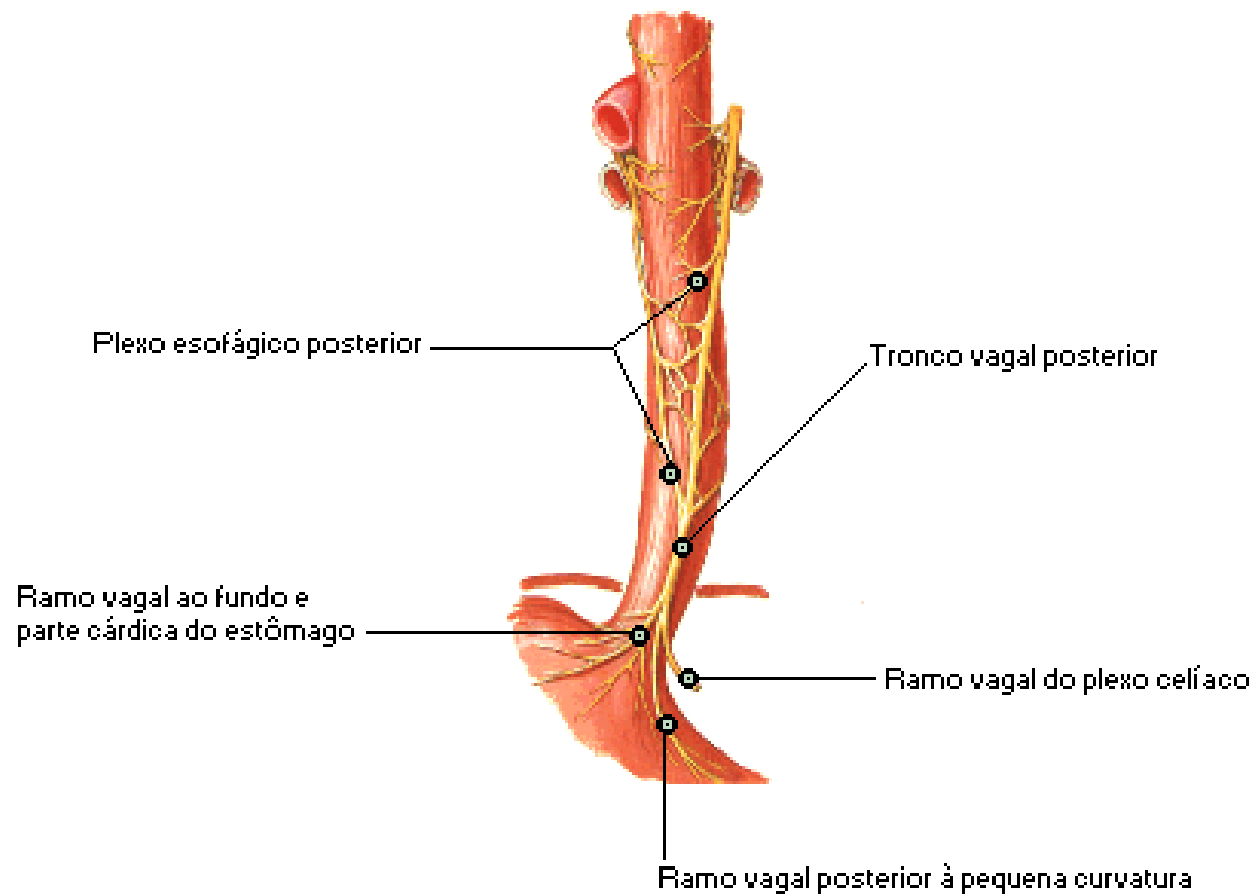
Nervos do Esôfago

Vista Anterior



Nervos do Esôfago

Vista Posterior




Nervos do Esôfago

Variações

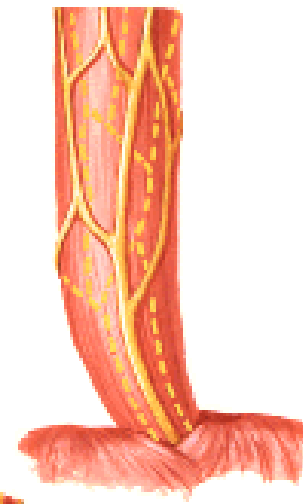Múltiplos troncos vagais anteriores



Um único tronco vagal anterior divide-se logo acima do diafragma



Múltiplos troncos vagais posteriores



Emergência alta de um único tronco

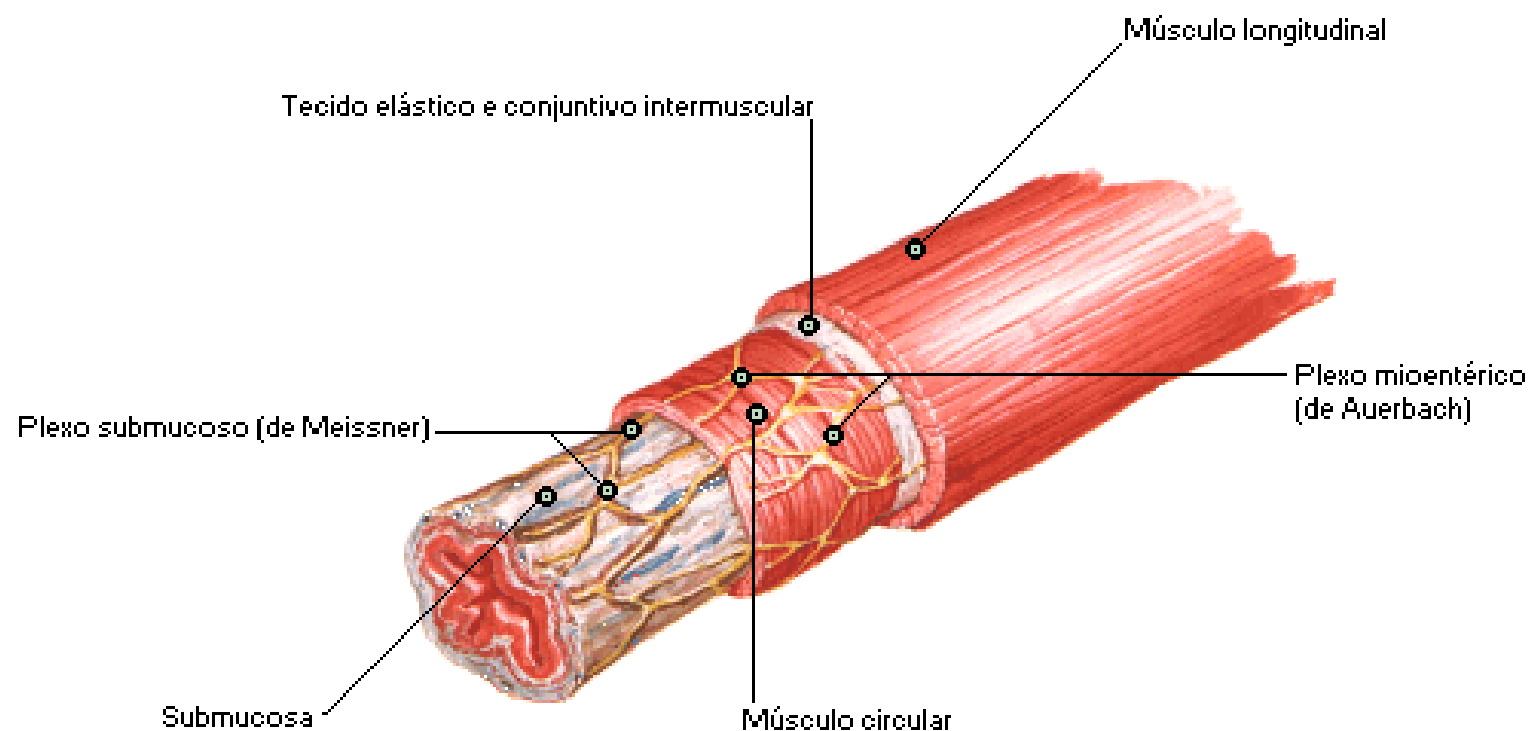


Emergência baixa de um único tronco



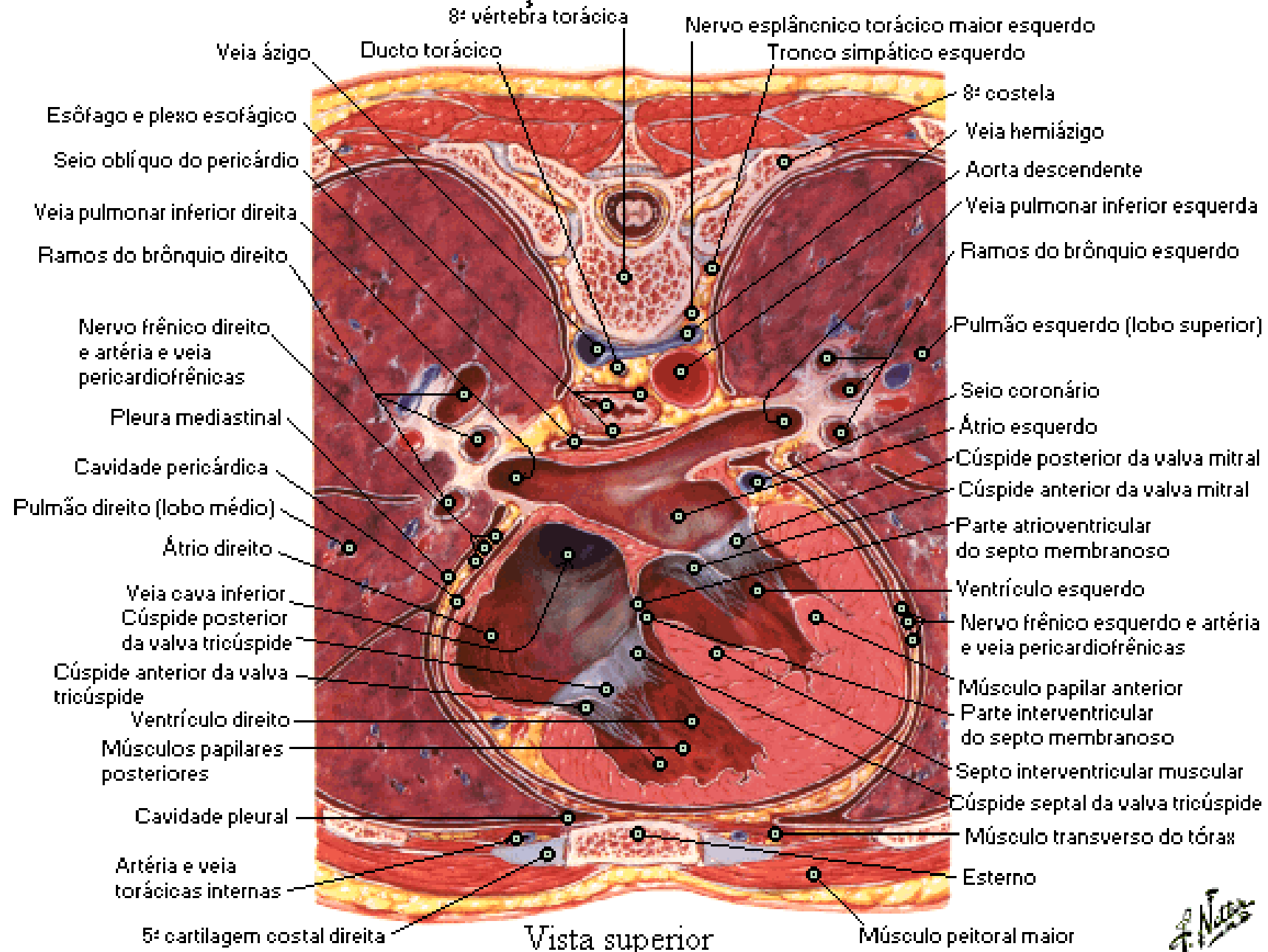
Nervos Intrínsecos do Esôfago

Esquema

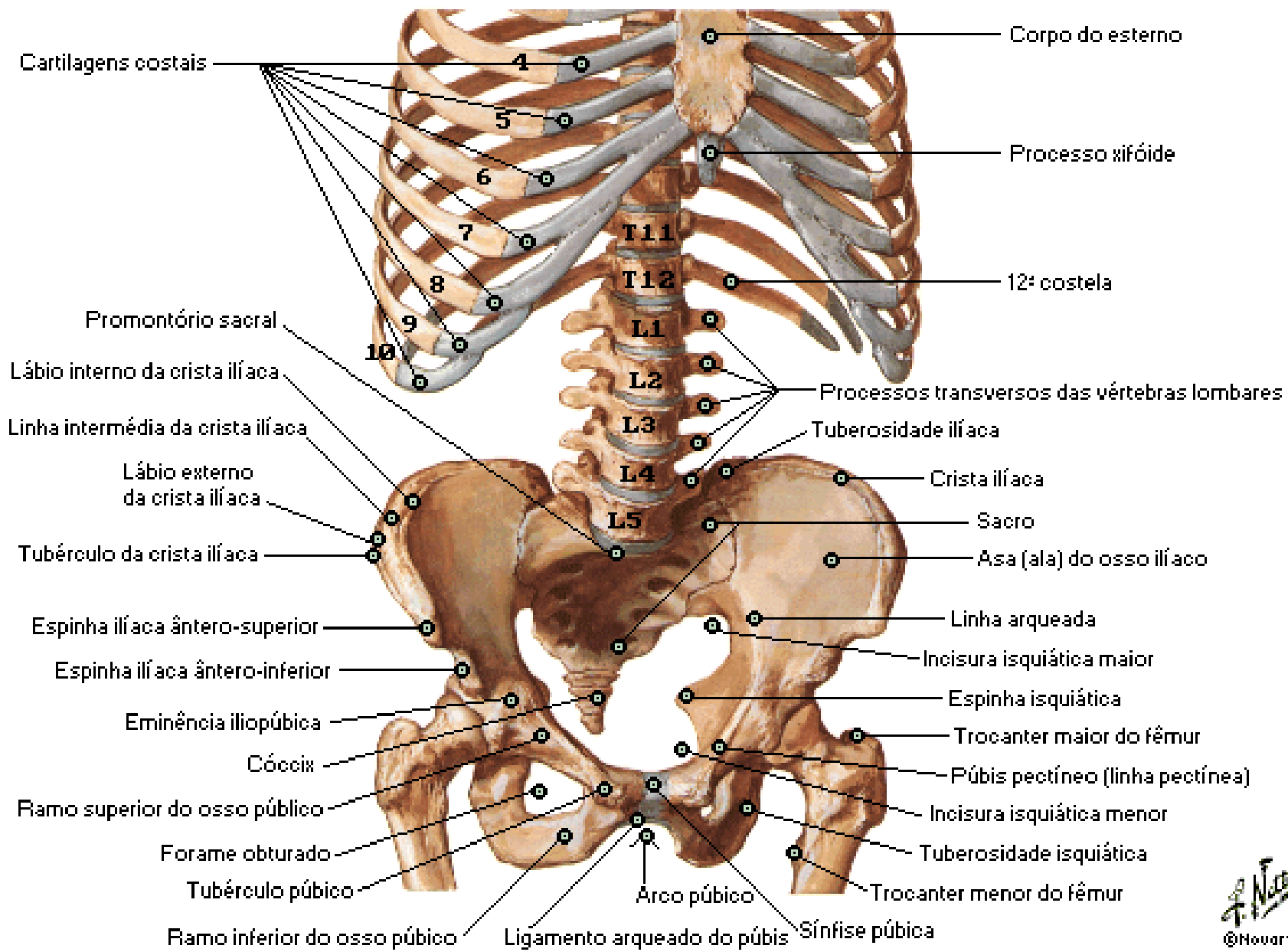


Mediastino

Secção Transversal

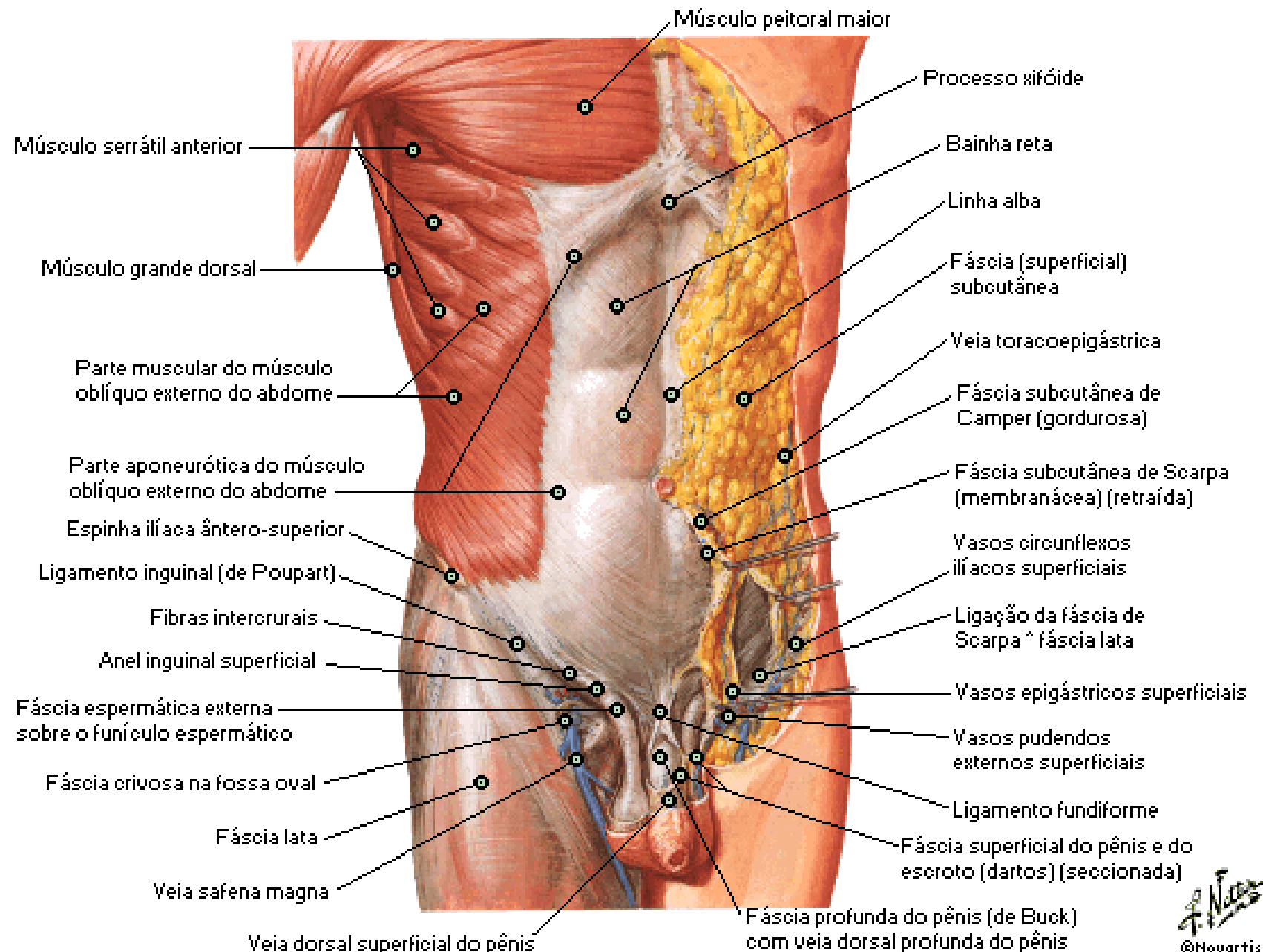


Arcabouço Ósseo do Abdome



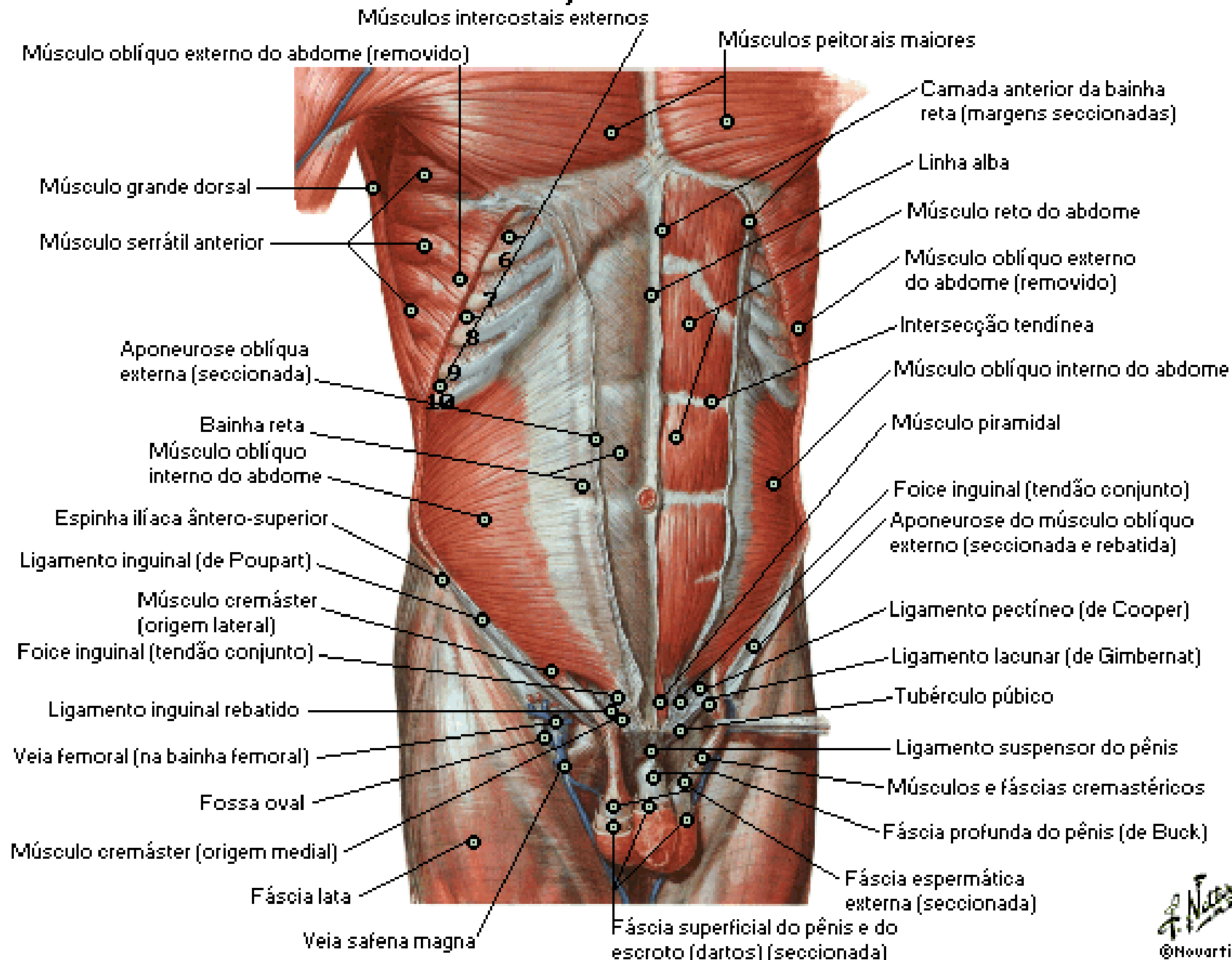
Parede Abdominal Anterior

Dissecação Superficial



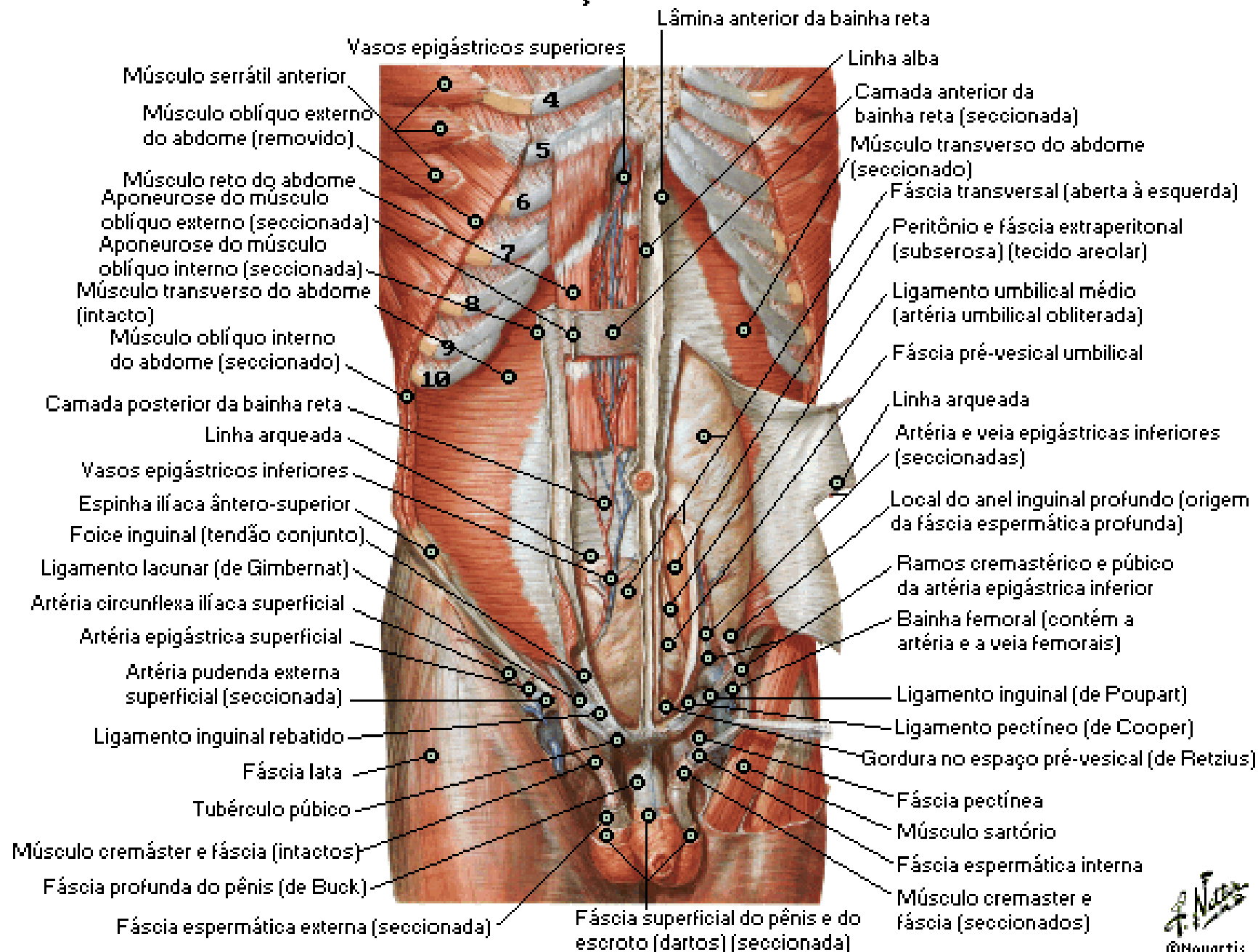
Parede Abdominal Anterior

Dissecação Intermédia



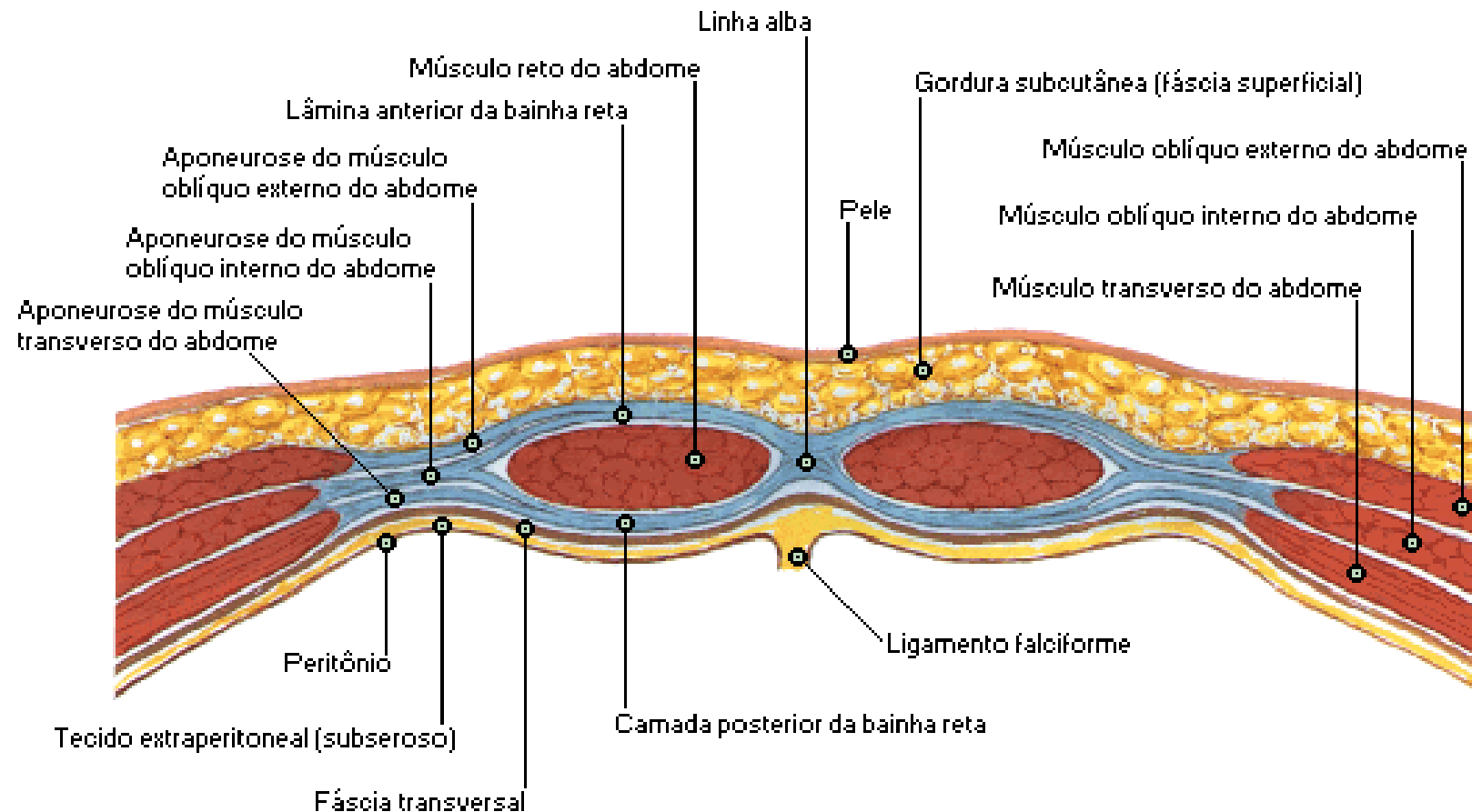
Parede Abdominal Anterior

Dissecação Profunda



Bainha do Músculo Reto do Abdome

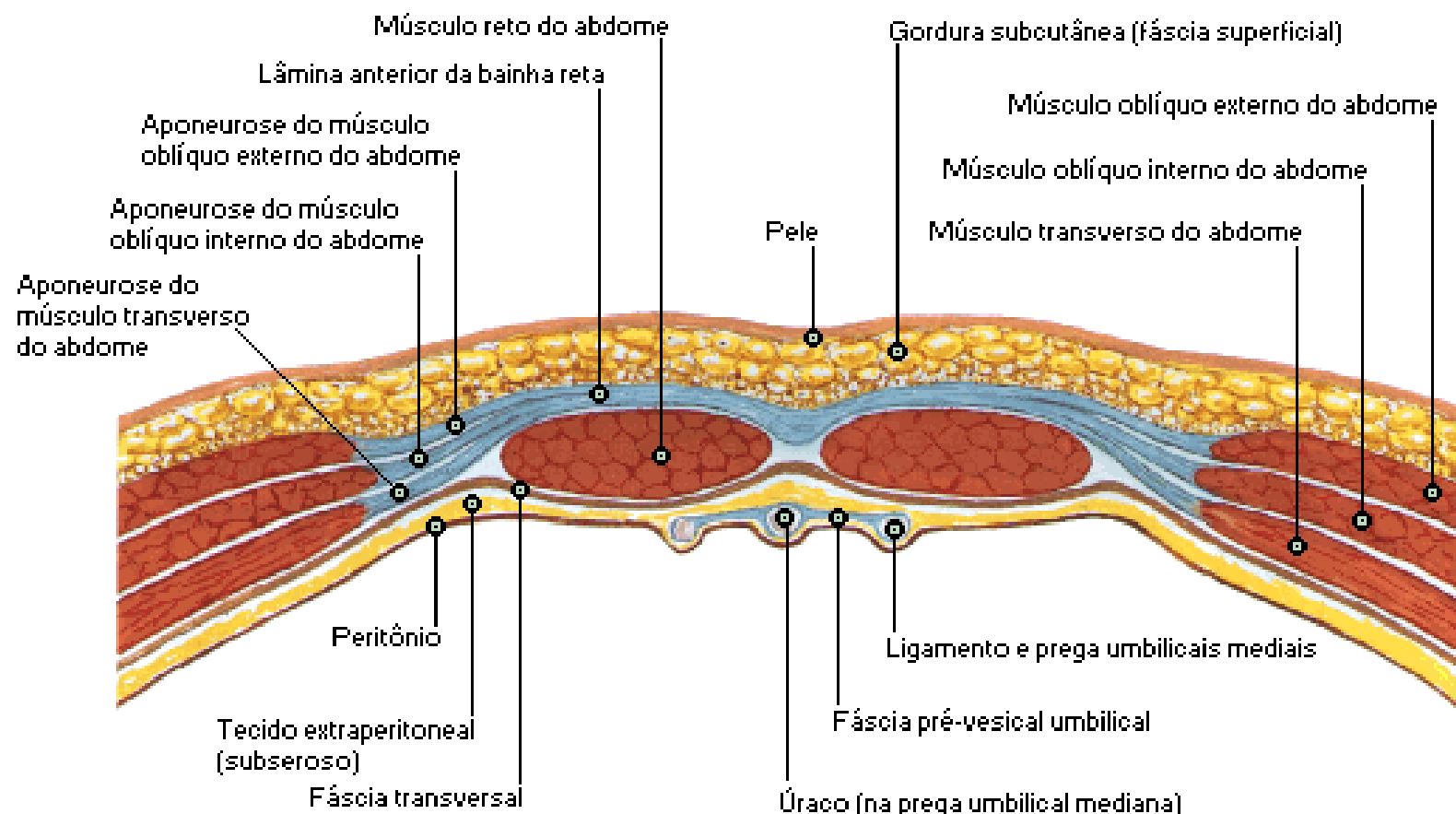
Secção Transversal Acima da Linha Arqueada



A aponeurose do músculo oblíquo interno do abdome divide-se para formar as lâminas anterior e posterior da bainha do músculo reto do abdome. A aponeurose do músculo oblíquo externo do abdome une-se à lâmina anterior da bainha; a aponeurose do músculo transverso do abdome une-se à lâmina posterior. As lâminas anterior e posterior da bainha do músculo reto do abdome unem-se medialmente para formar a linha alba

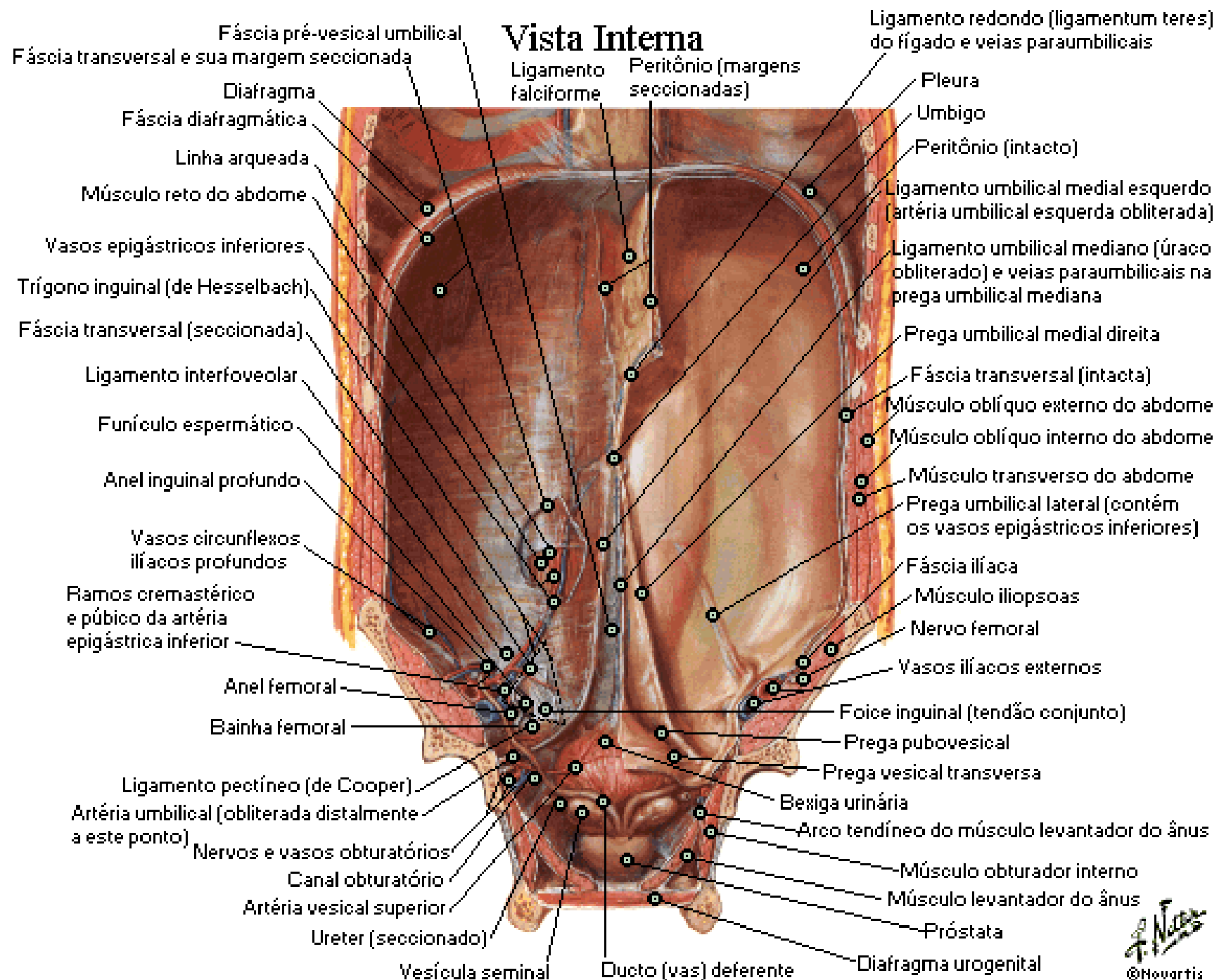
Bainha do Músculo Reto do Abdome

Secção Transversal Abaixo da Linha Arqueada

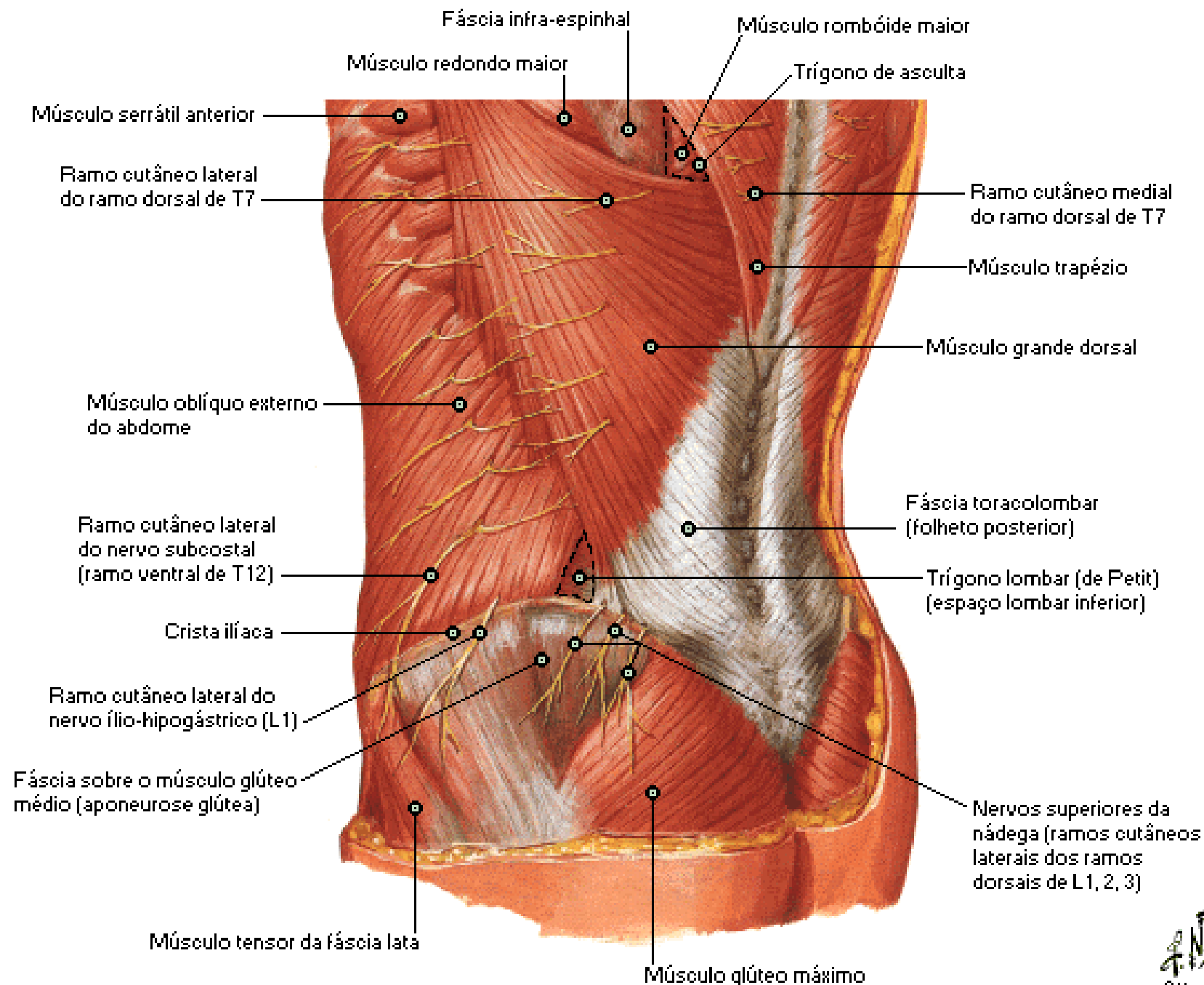


A aponeurose do músculo oblíquo interno do abdome não se divide neste nível, mas passa inteiramente anterior ao músculo reto do abdome e funde-se ali com ambas as aponeuroses dos músculos oblíquo externo e transverso do abdome. Assim, a lâmina posterior da bainha do músculo reto do abdome está mais delgada abaixo da linha arqueada, e constituída por fáscia transversal, tecido extraperitoneal e peritônio

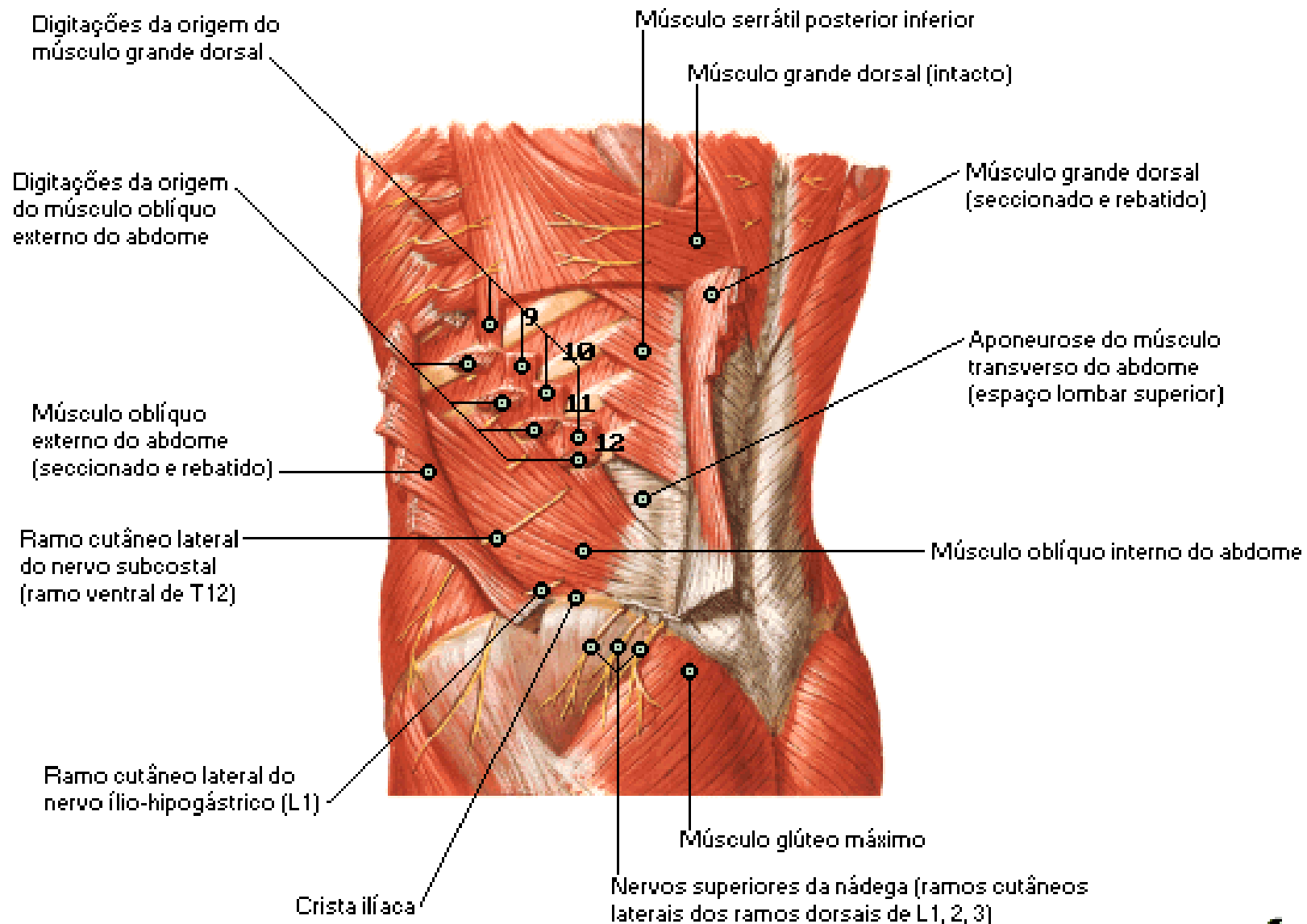
Parede Abdominal Anterior



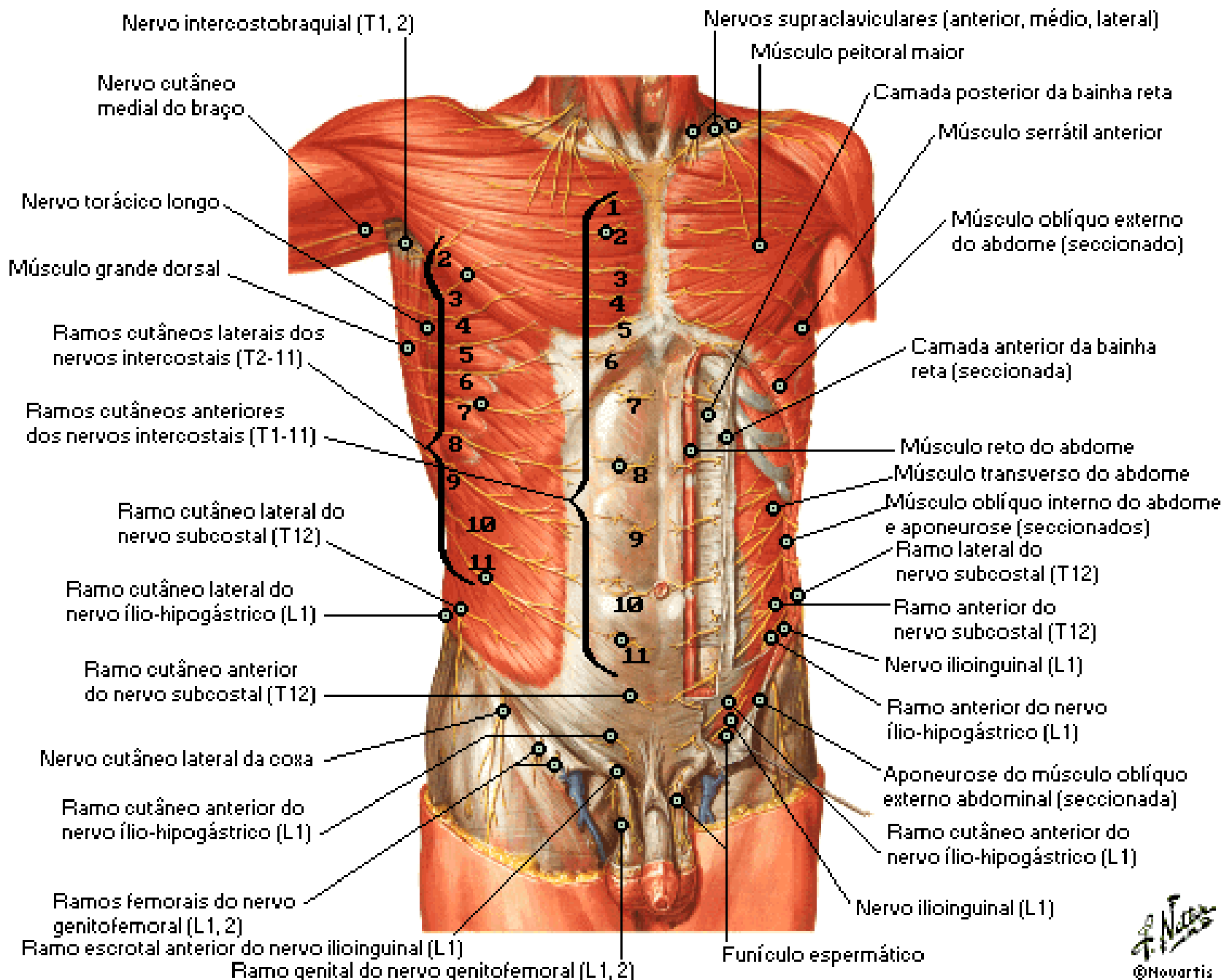
Parede Abdominal Pósterio-lateral



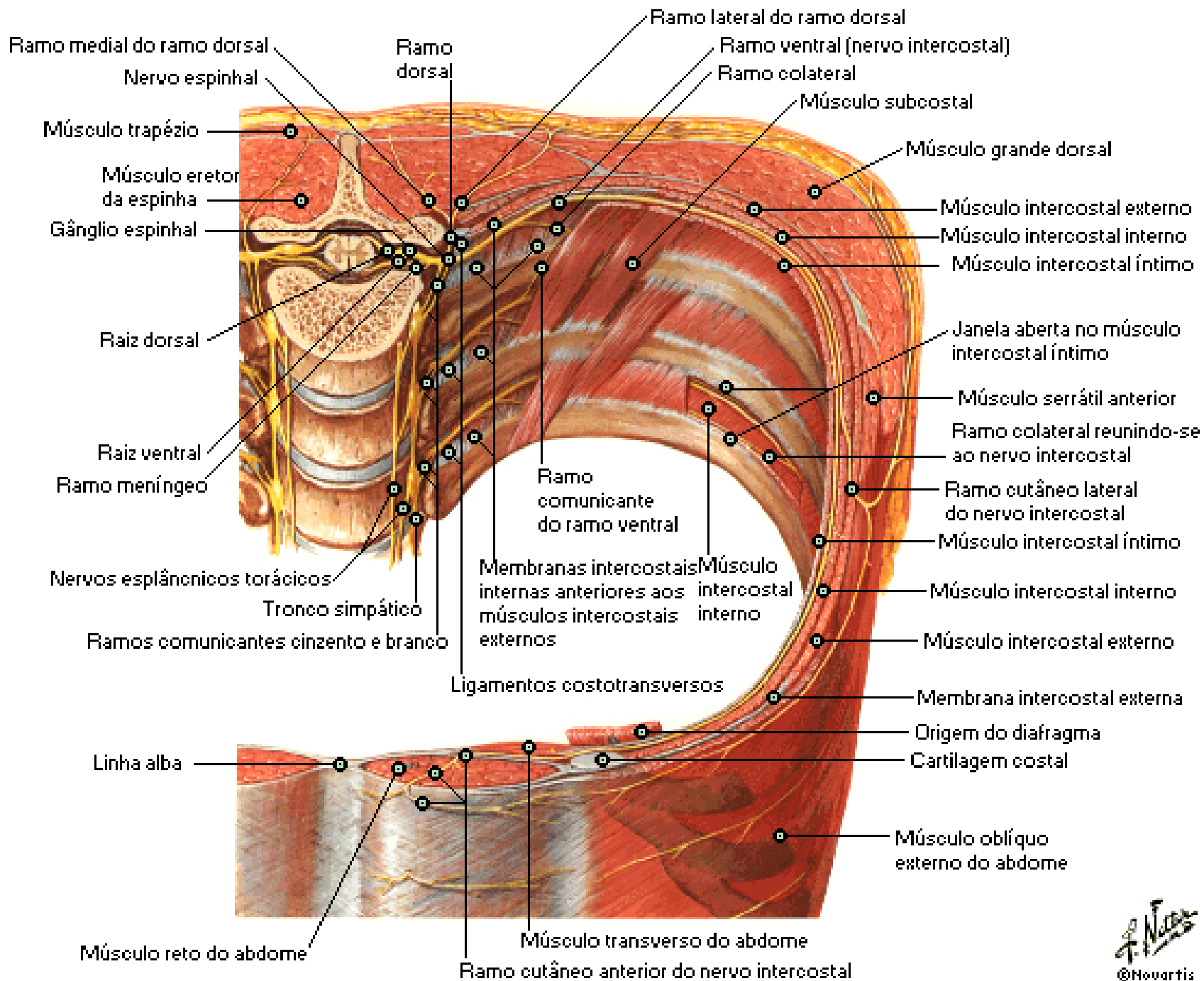
Parede Abdominal Pósterio-lateral



Nervos da Parede Abdominal Anterior

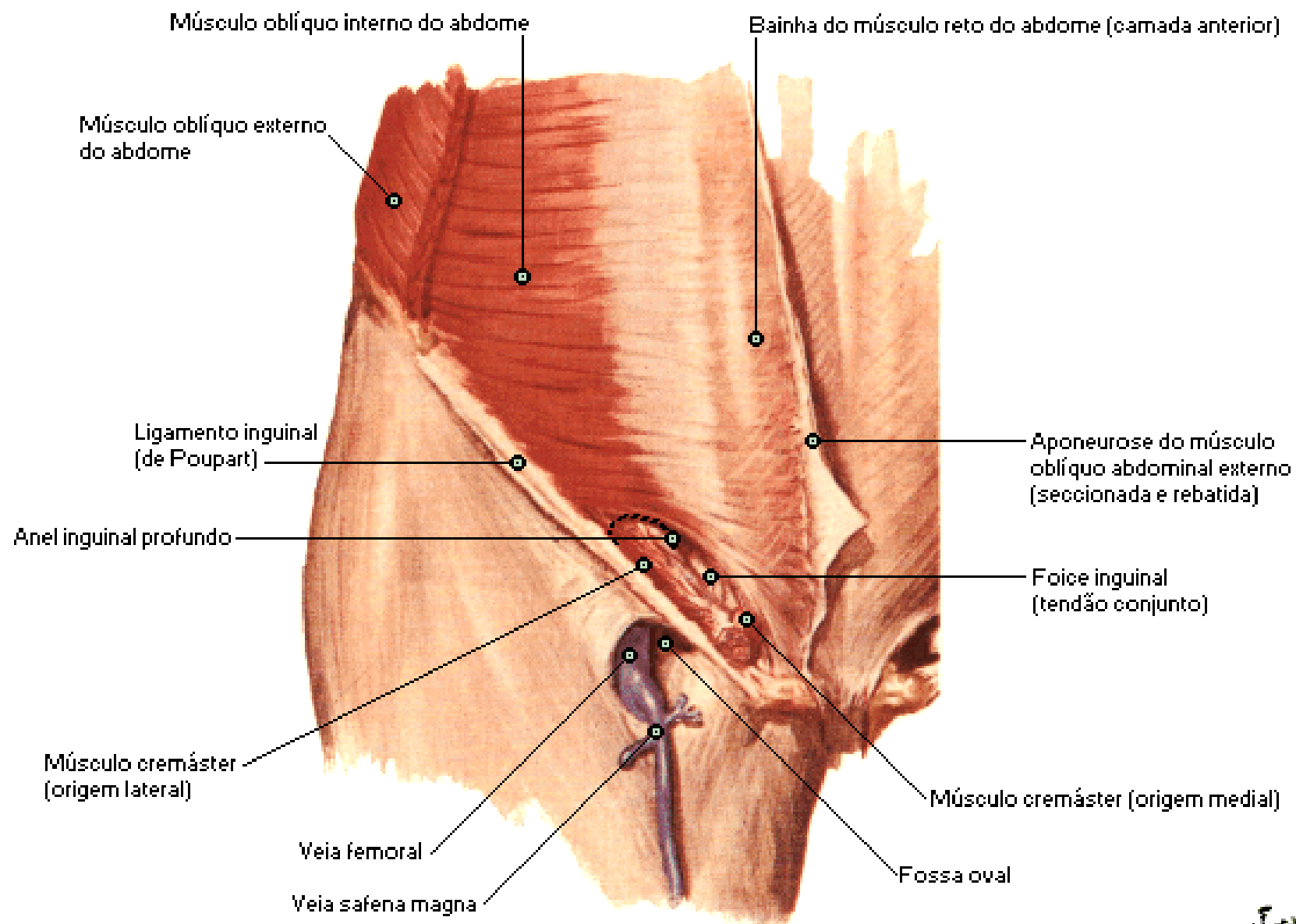


Nervos Toracoabdominais



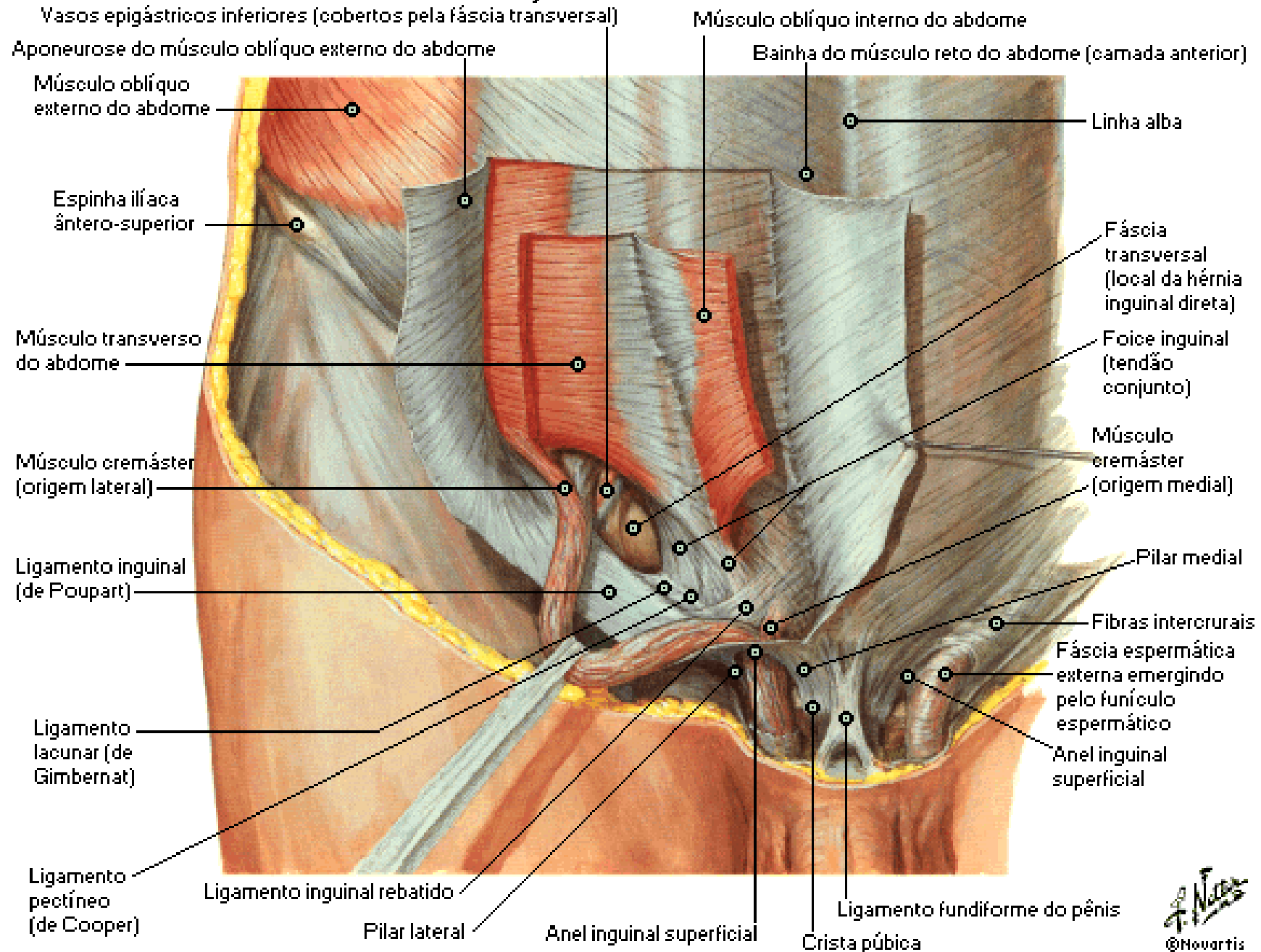
Regiões Inguinal e Femoral

Fáscia Crivosa Removida



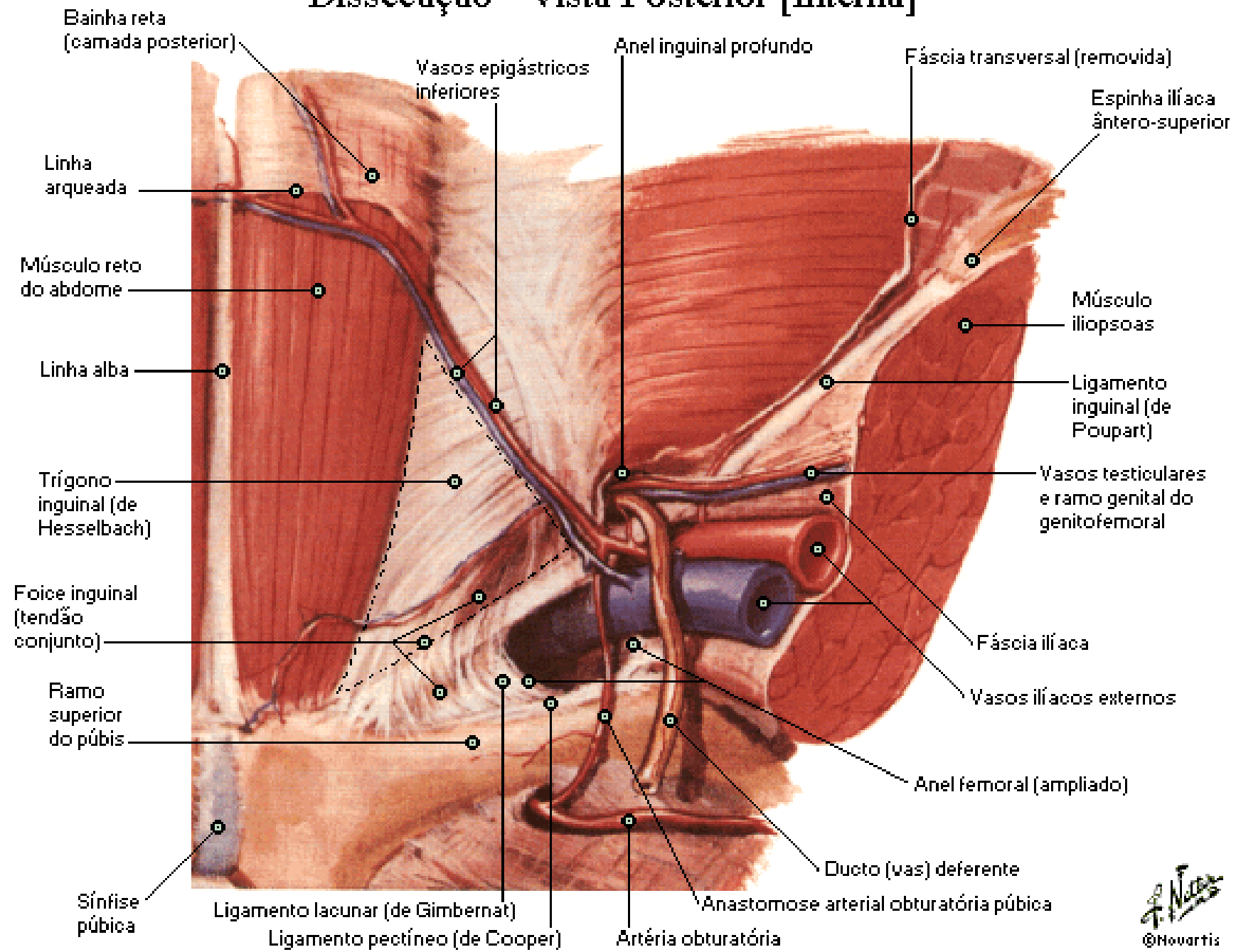
Região Inguinal

Dissecação - Vista Anterior

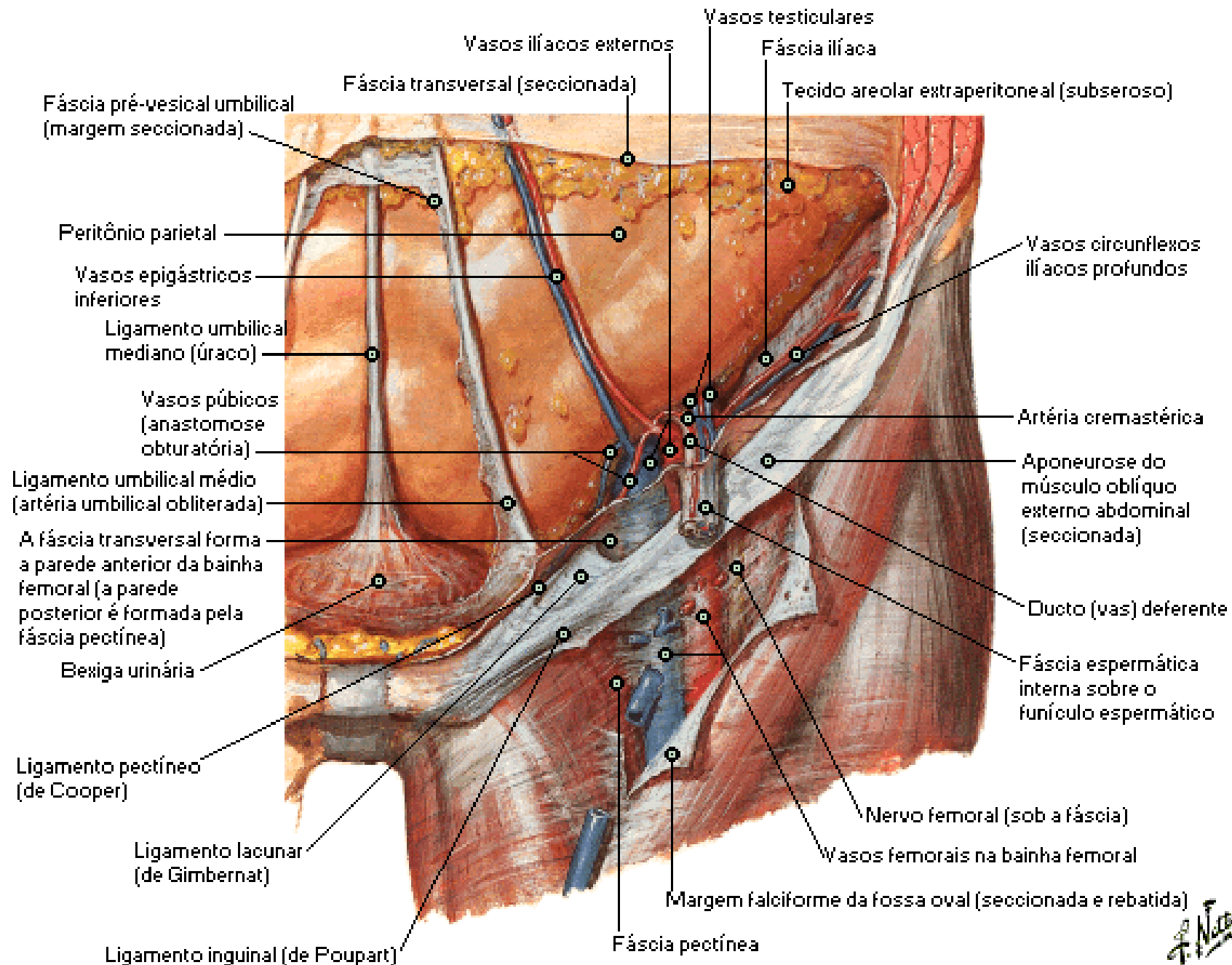


Região Inguinal

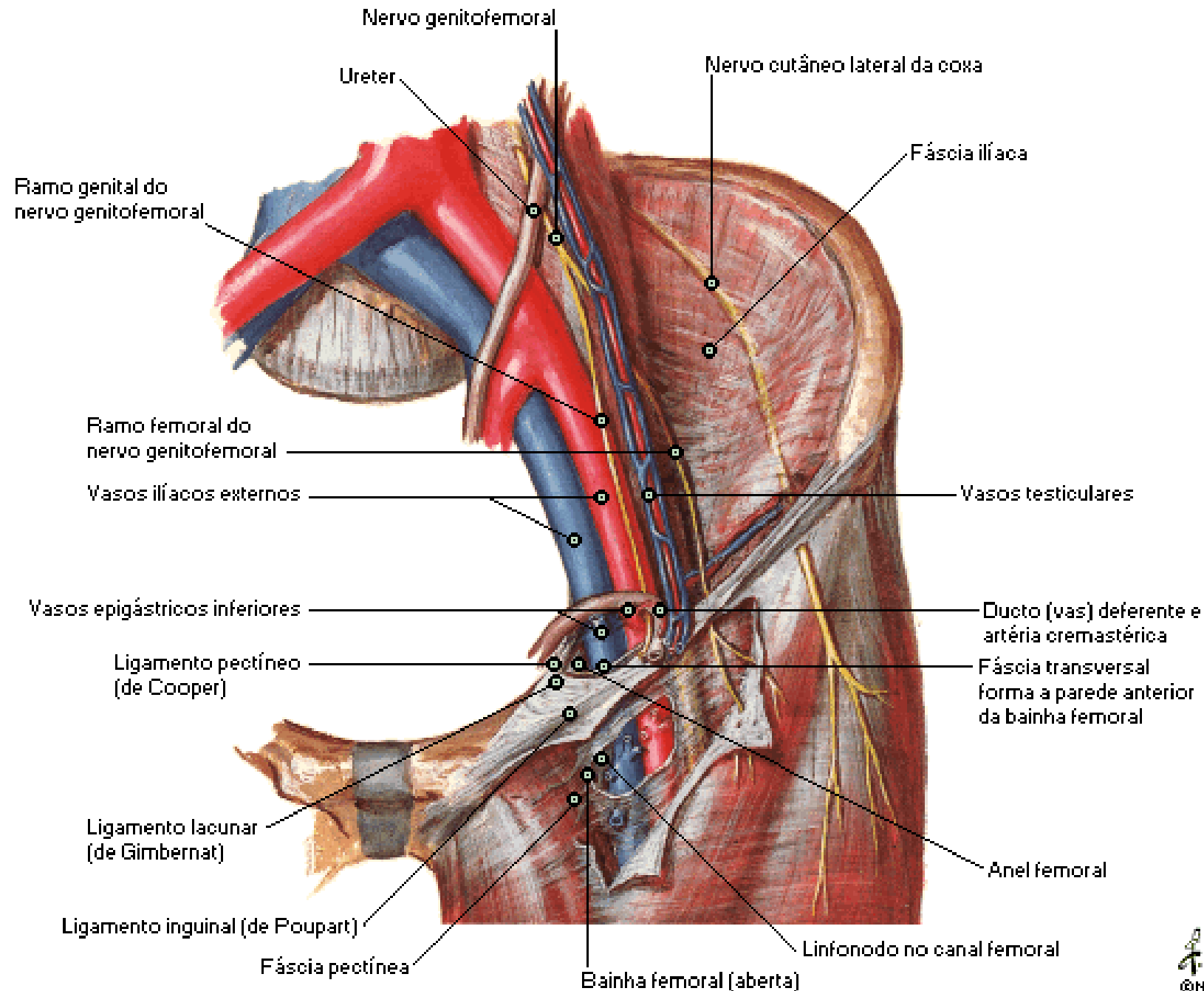
Dissecação - Vista Posterior [Interna]



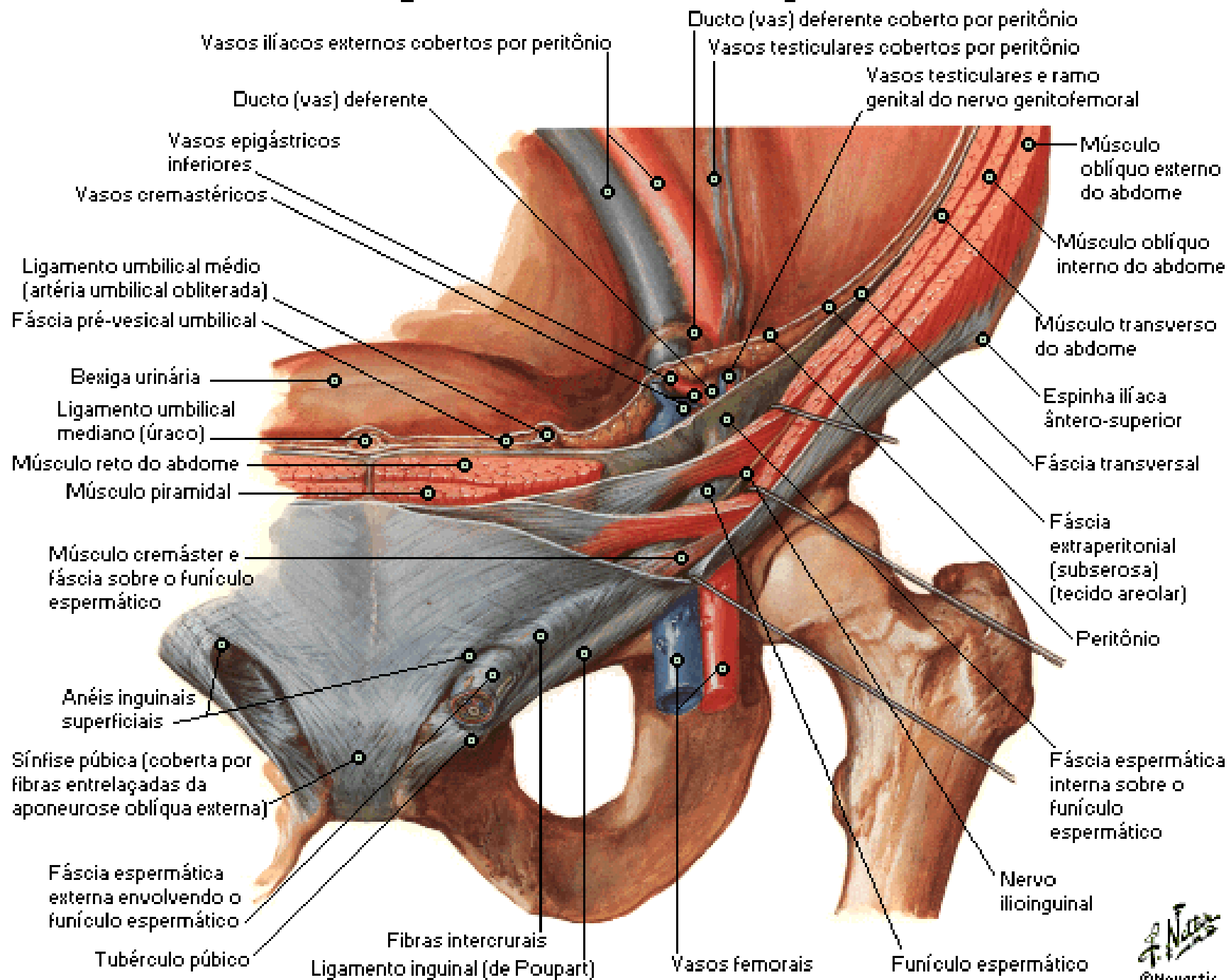
Bainha Femoral e Canal Inguinal



Bainha Femoral e Canal Inguinal [Profundo]

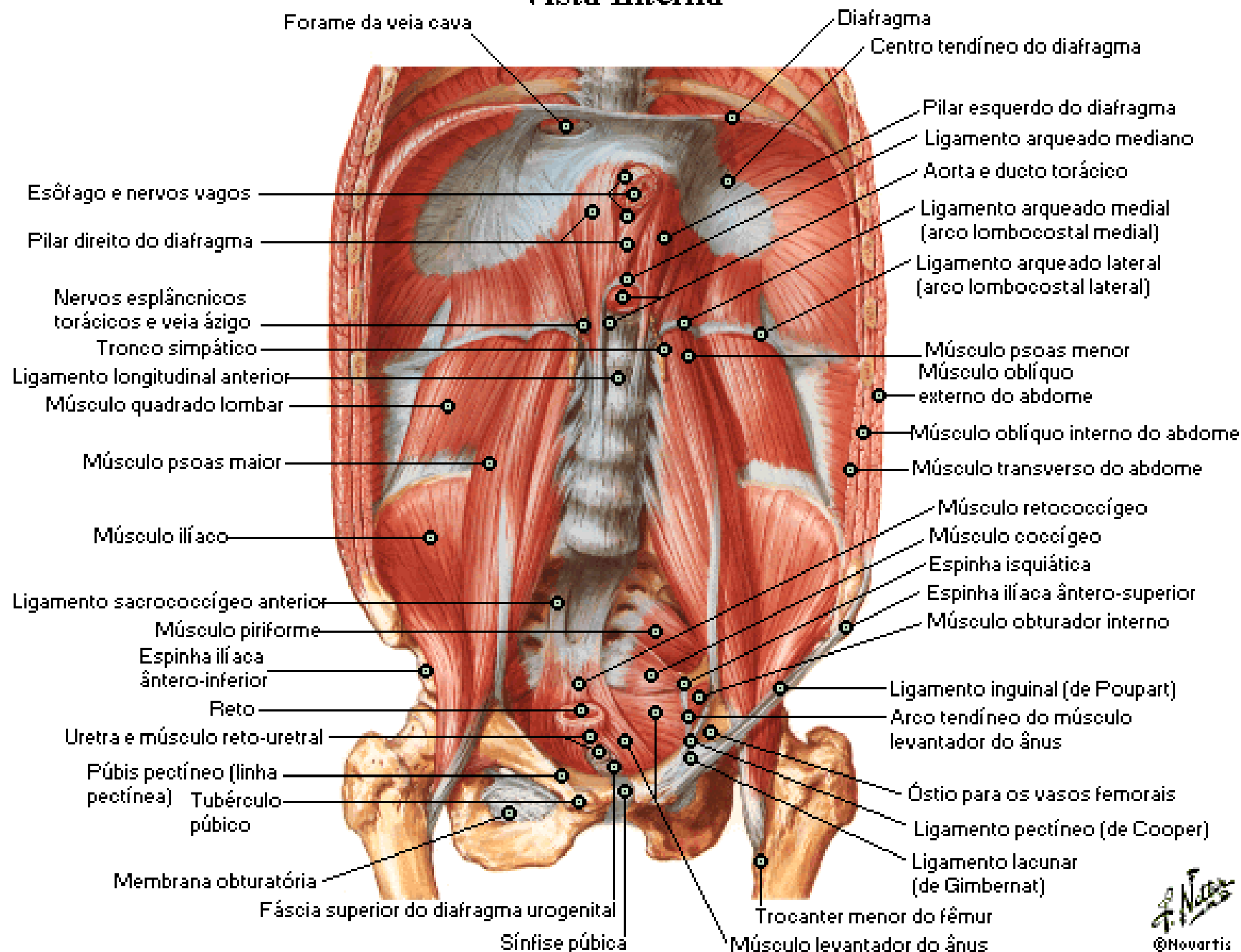


Canal Inguinal e Funículo Espermático

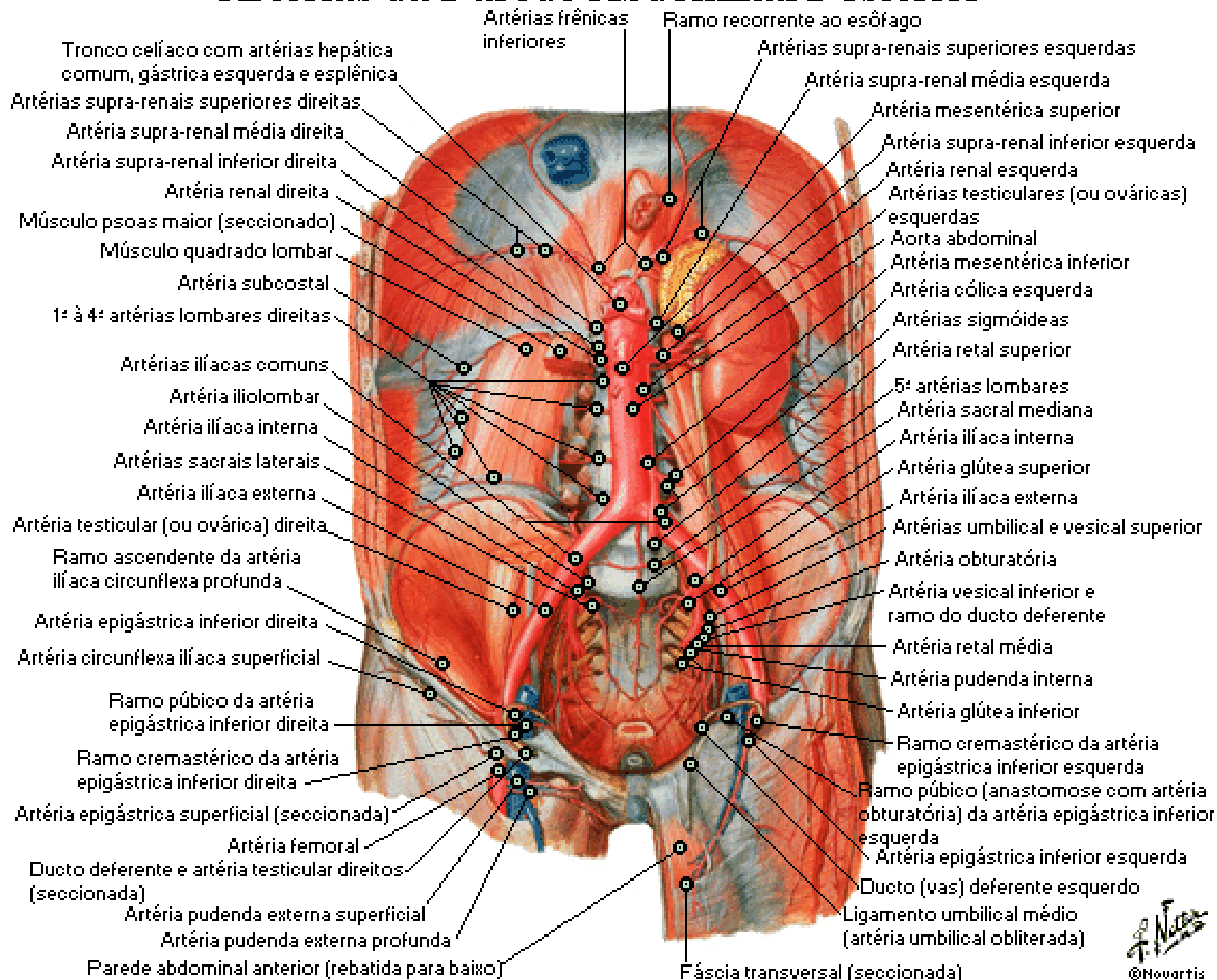


Parede Abdominal Posterior

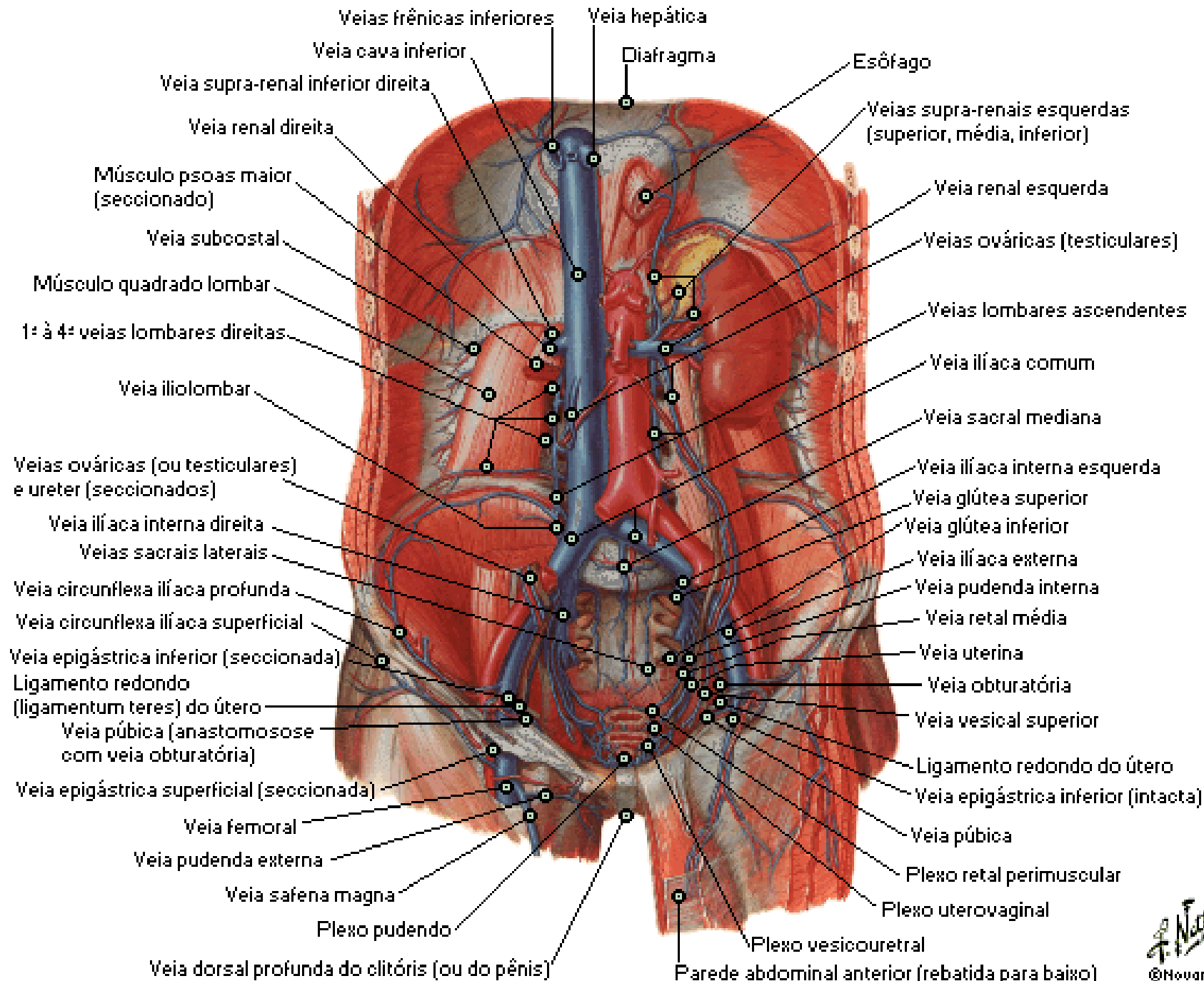
Vista Interna



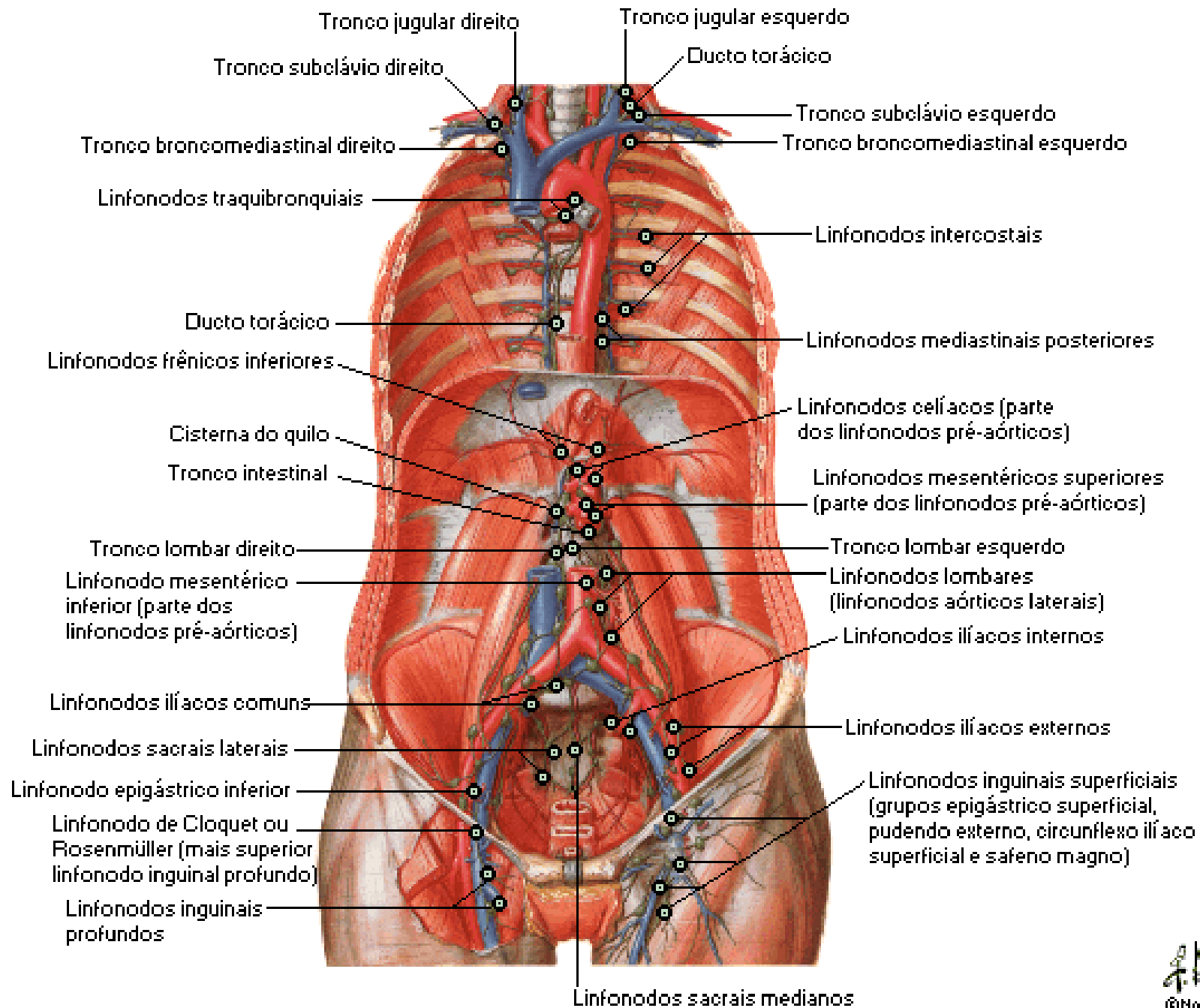
Artérias da Parede Abdominal Posterior



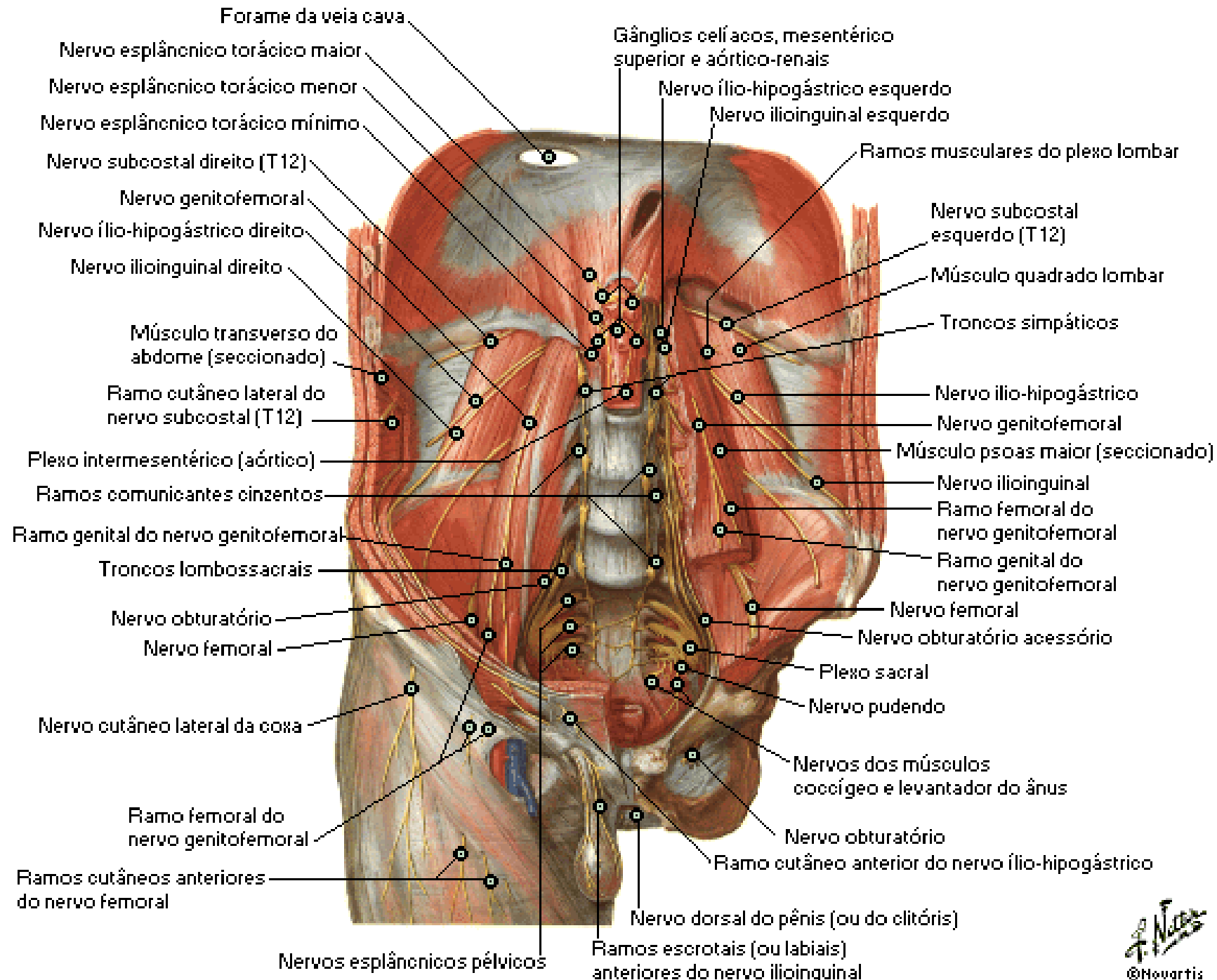
Veias da Parede Abdominal Posterior



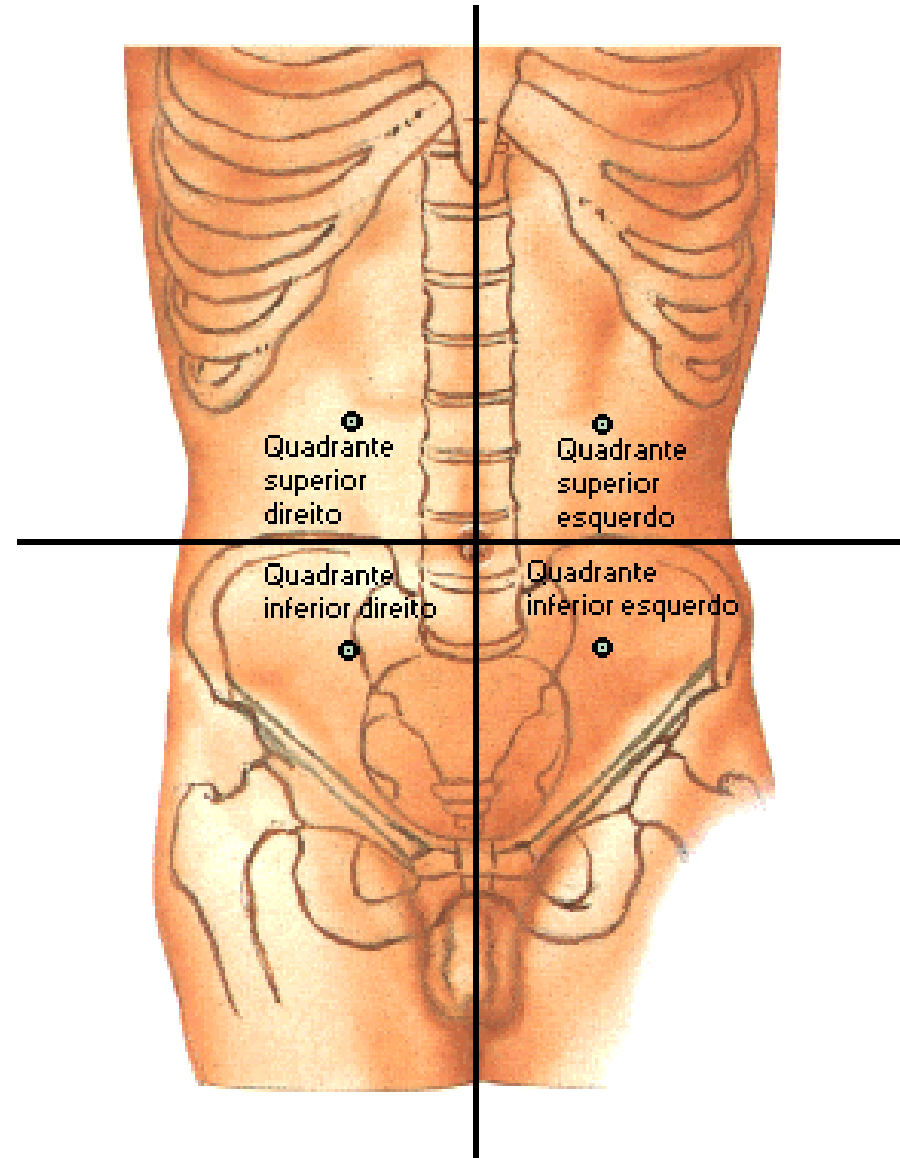
Vasos Linfáticos e Linfonodos da Parede Abdominal Posterior



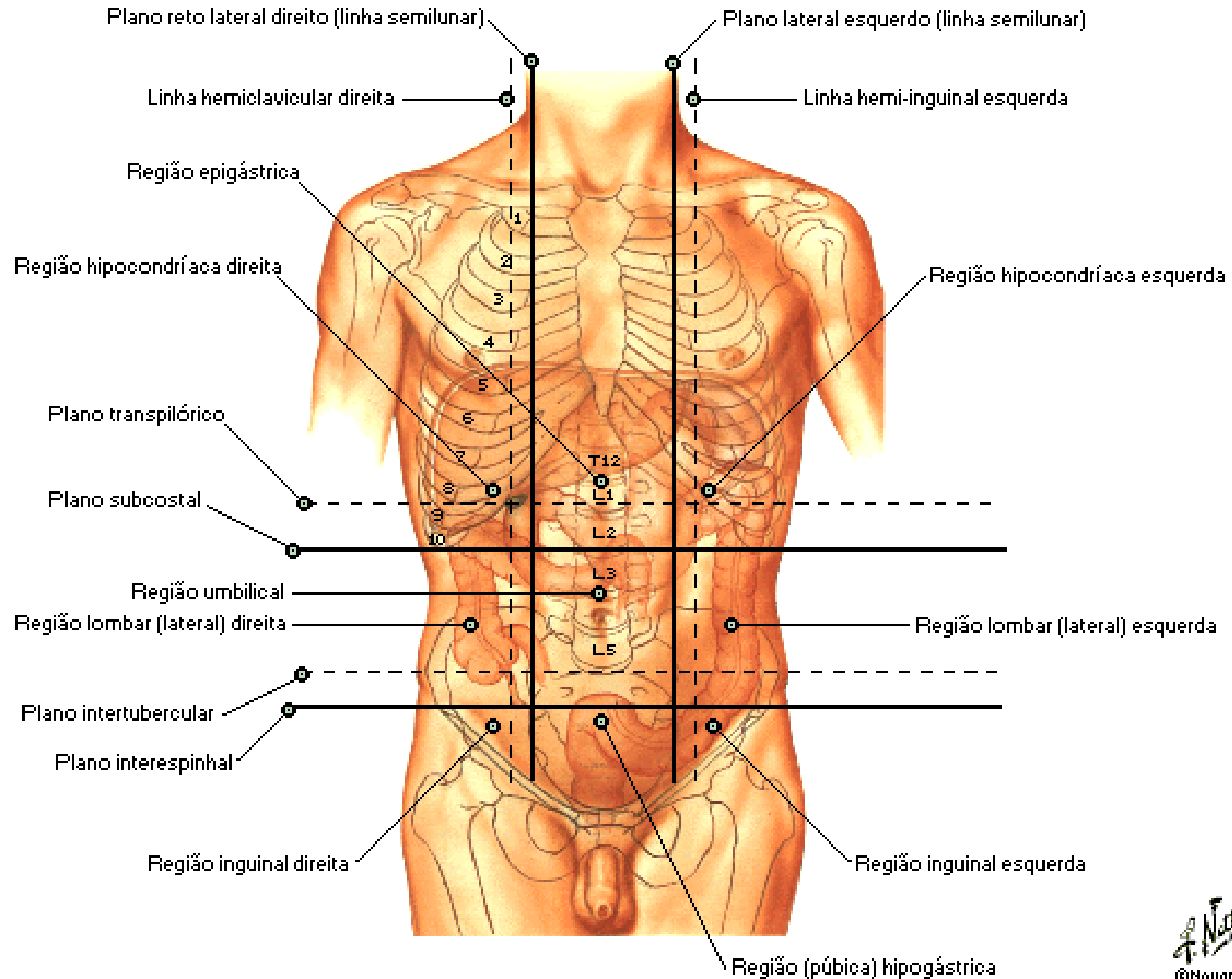
Nervos da Parede Abdominal Posterior



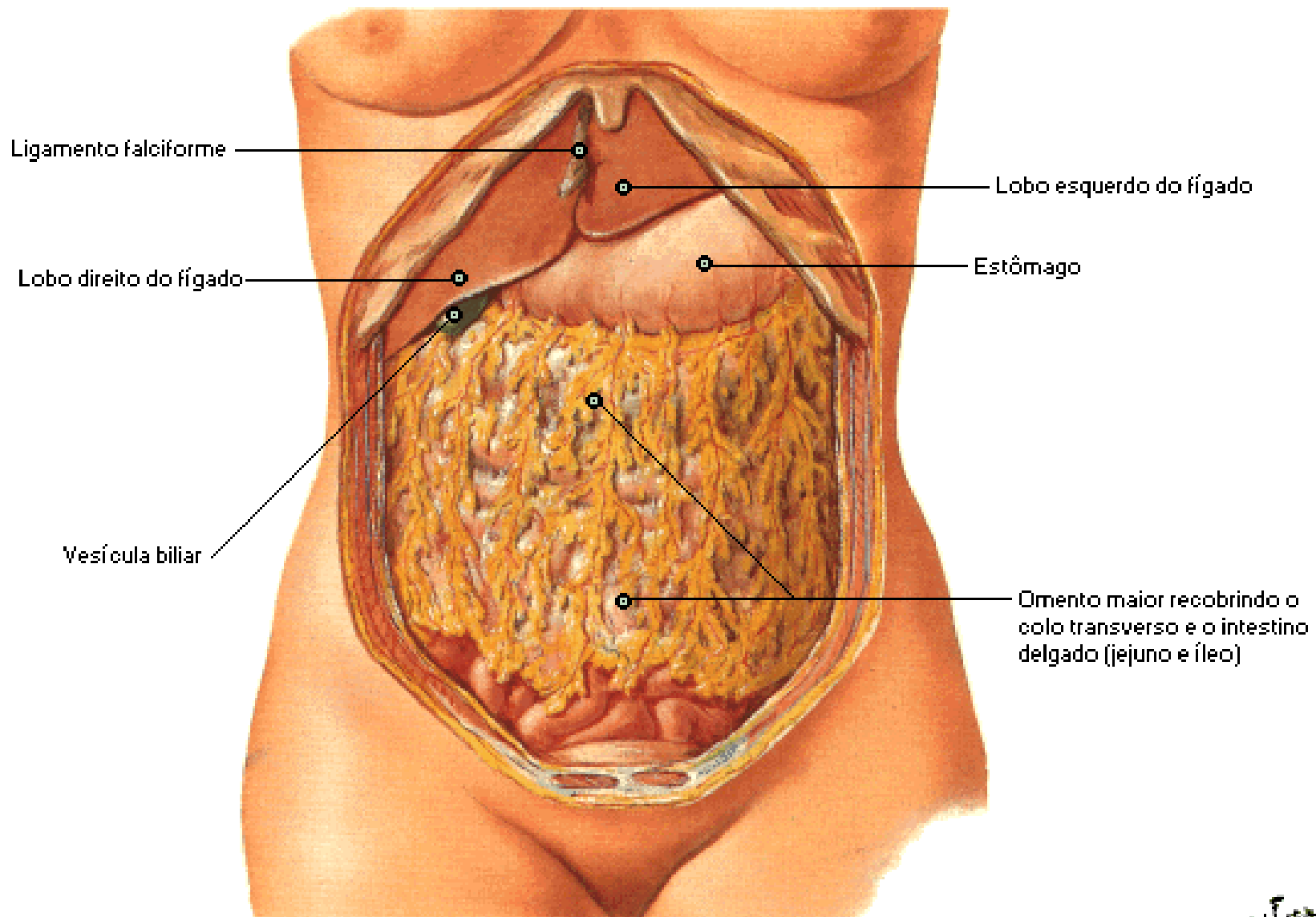
Quadrantes do abdome



Regiões e Planos do Abdome

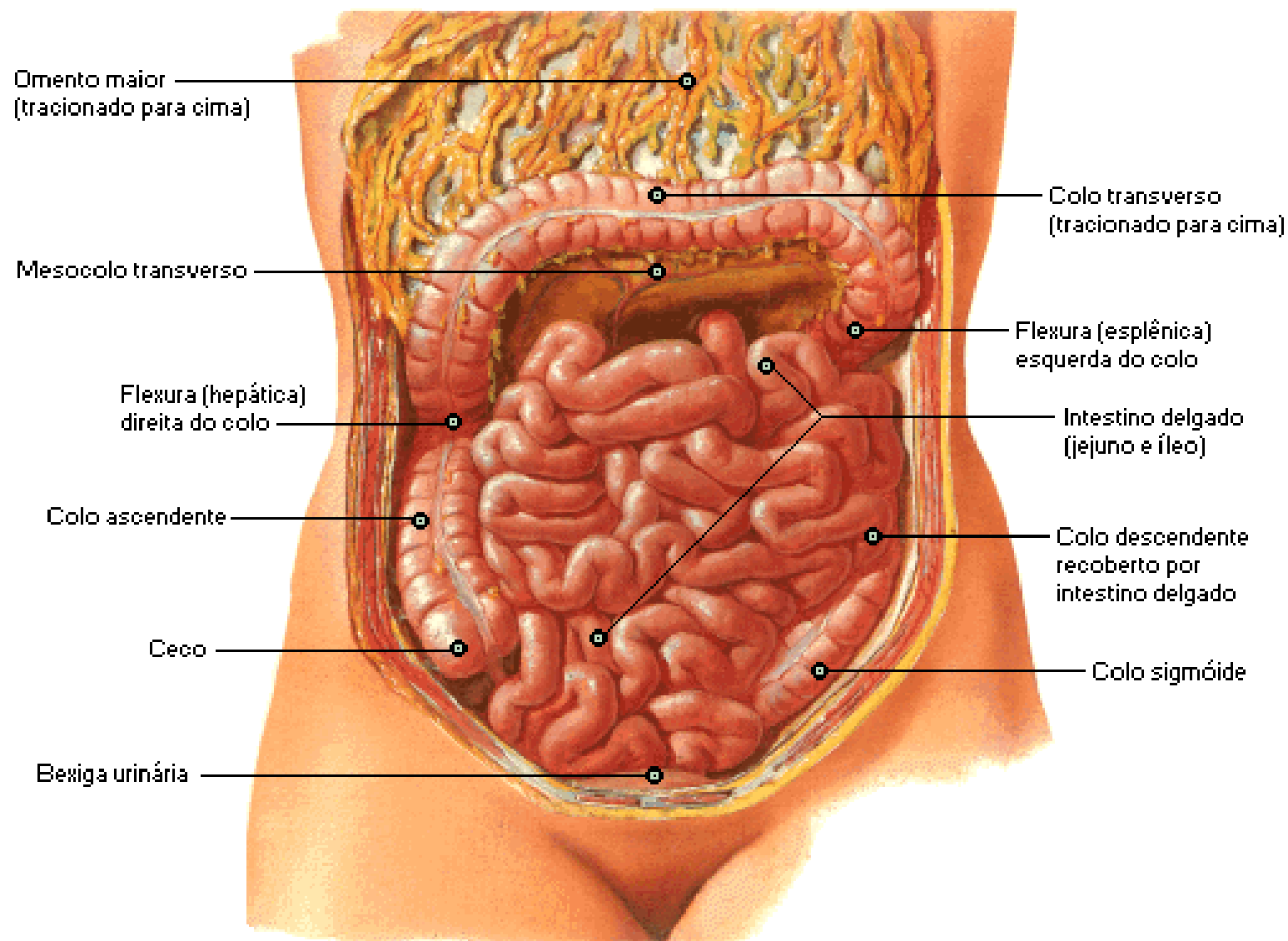


Omento Maior e Visceras Abdominais



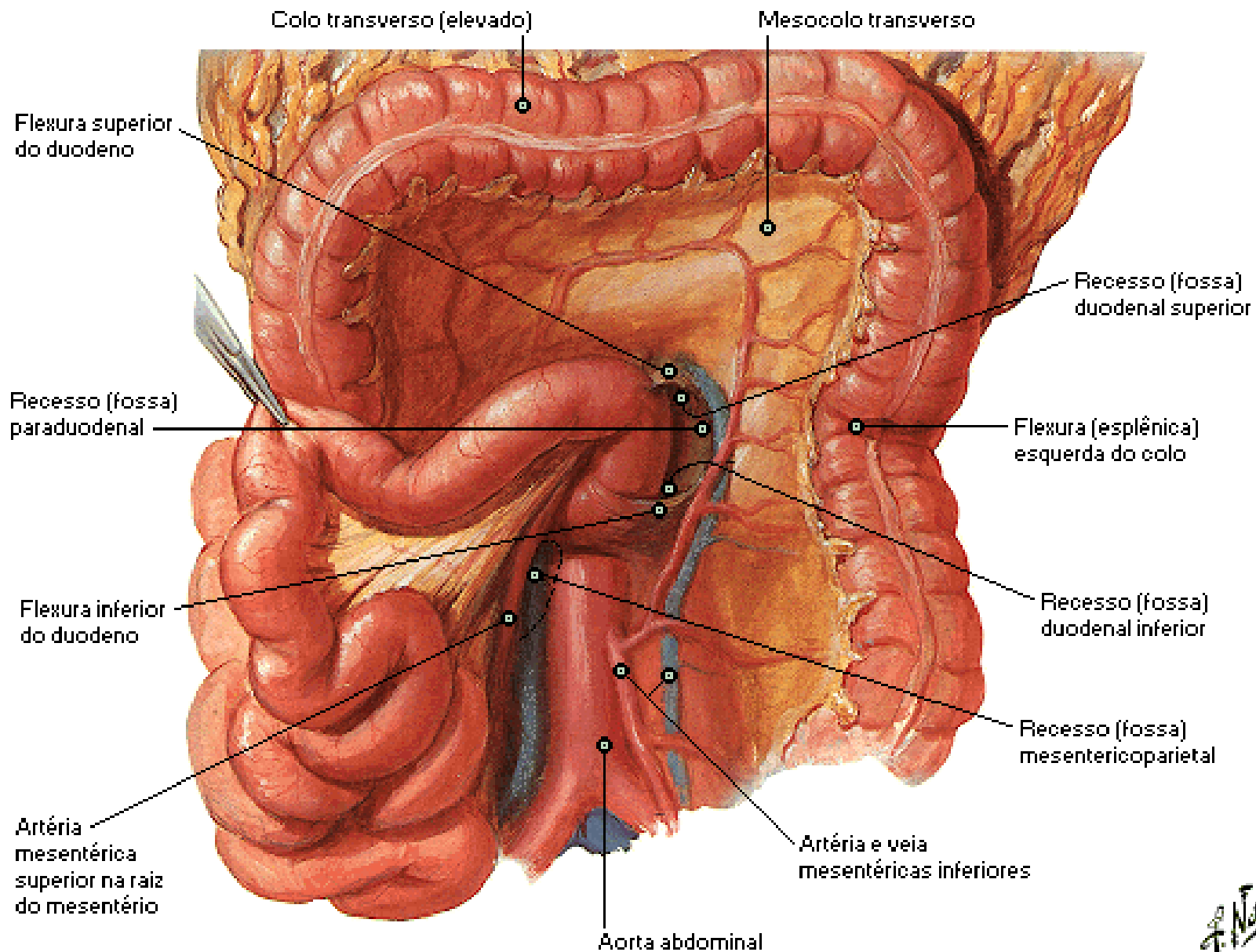
Omento Maior e Visceras Abdominais

Omento Tracionado para Cima



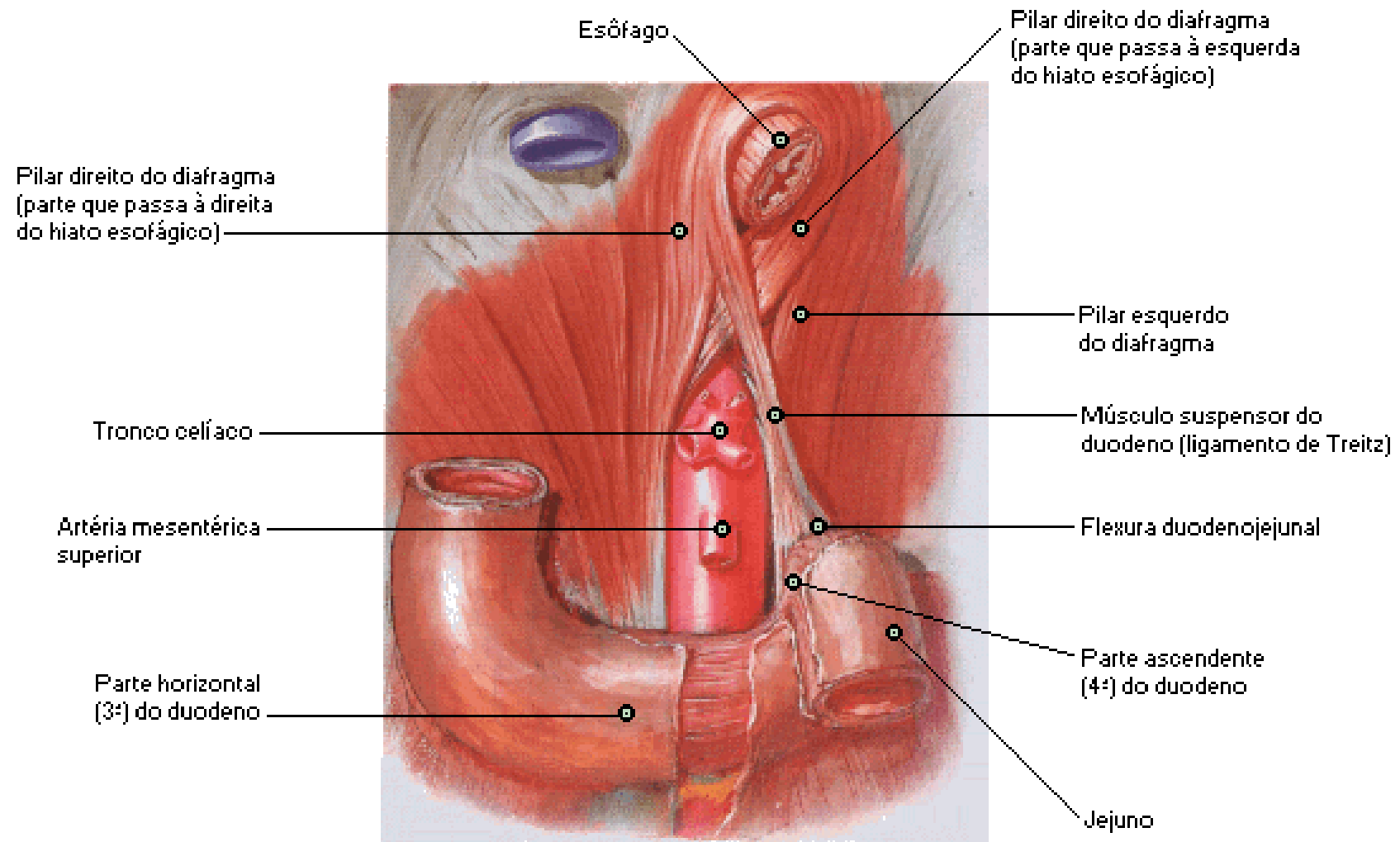
Relações Peritoneais dos Intestinos

Colo Transverso [Elevado]



Relações Peritoneais dos Intestinos

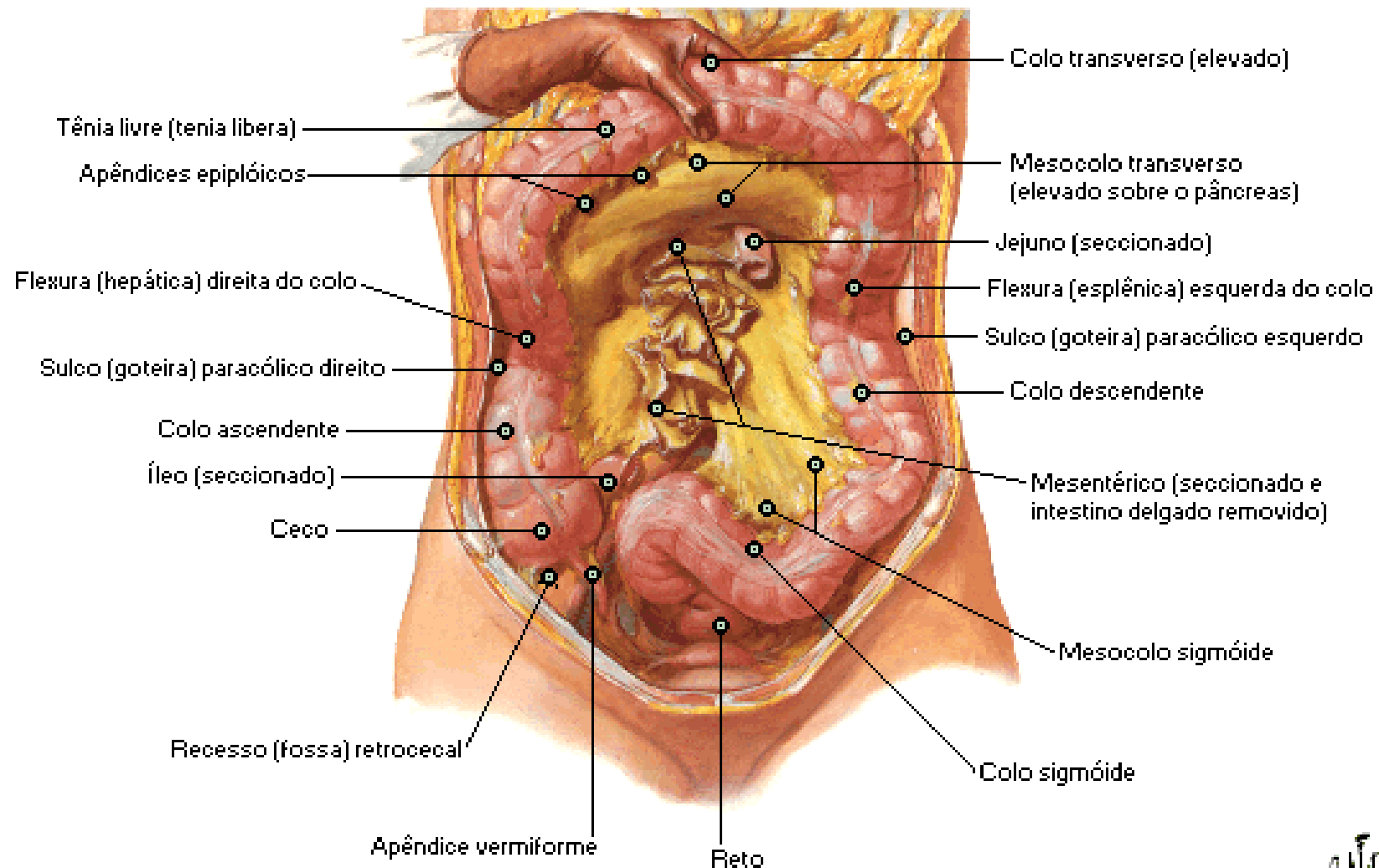
Músculo Suspensor do Duodeno



Exposição do músculo suspensor do duodeno (ligamento de Treitz)

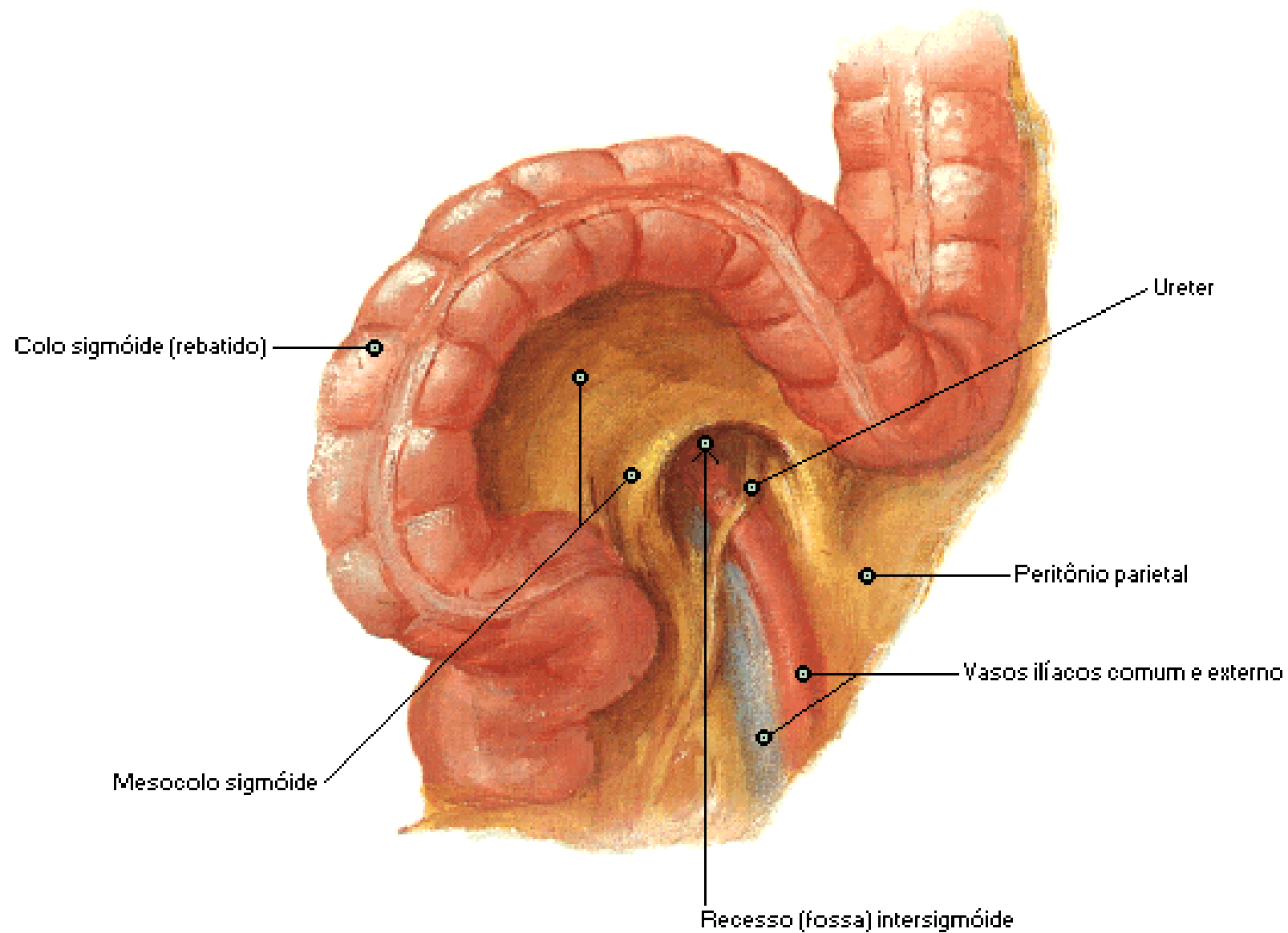
Relações Peritoneais dos Intestinos

Intestino Delgado Removido



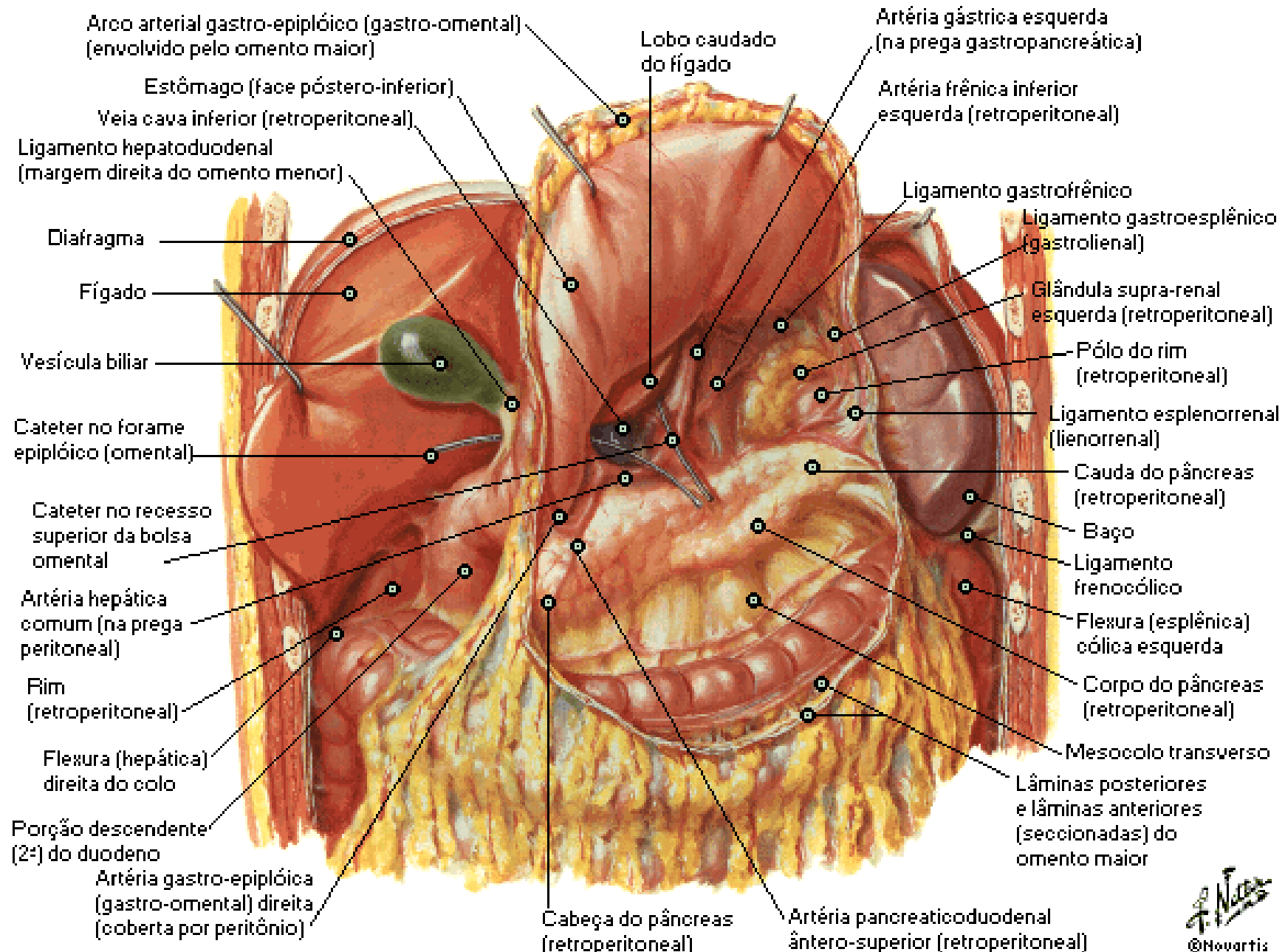
Relações Peritoneiais dos Intestinos

Colo Sigmóide [Rebatido]



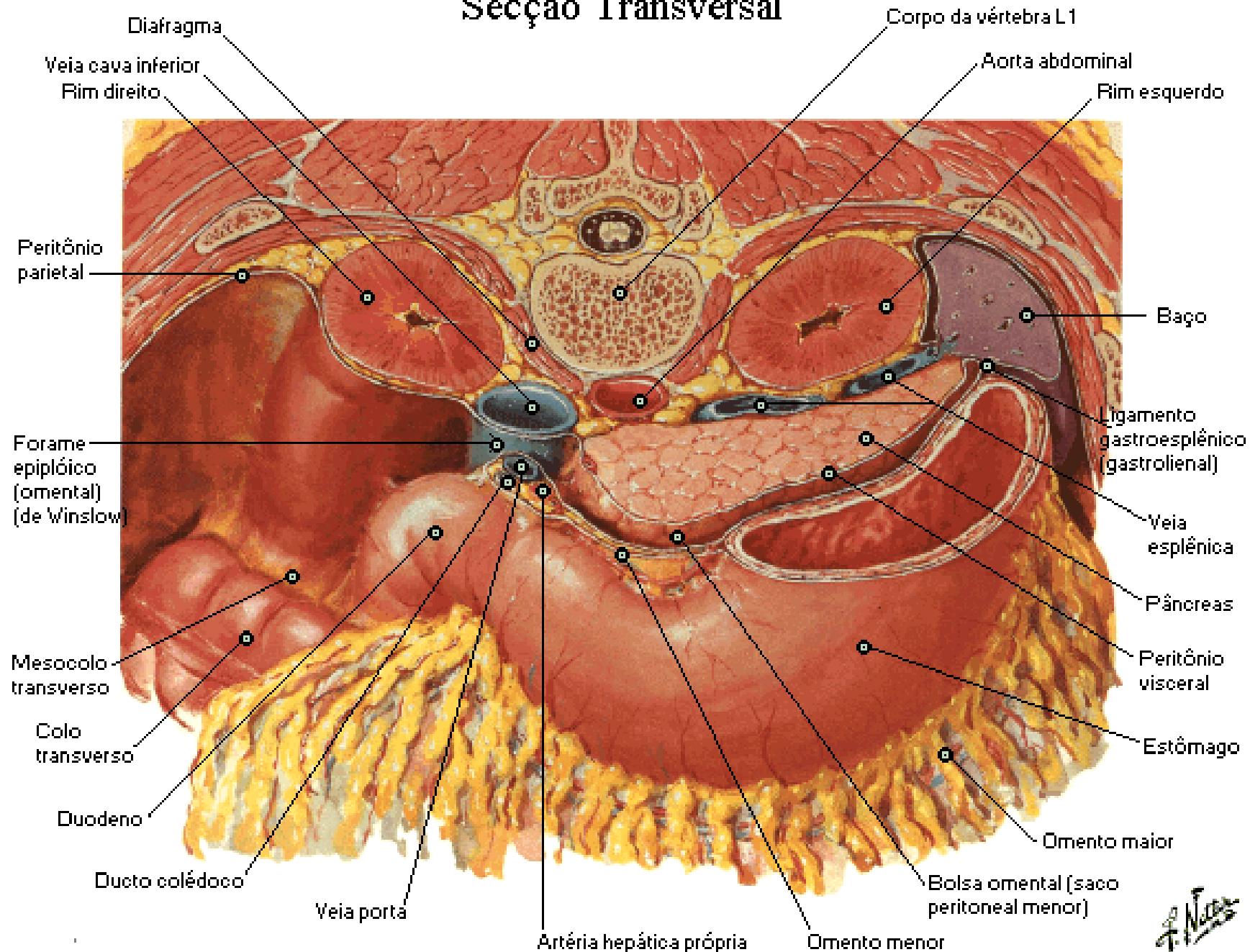
Bolsa Omental

Estômago Refletido

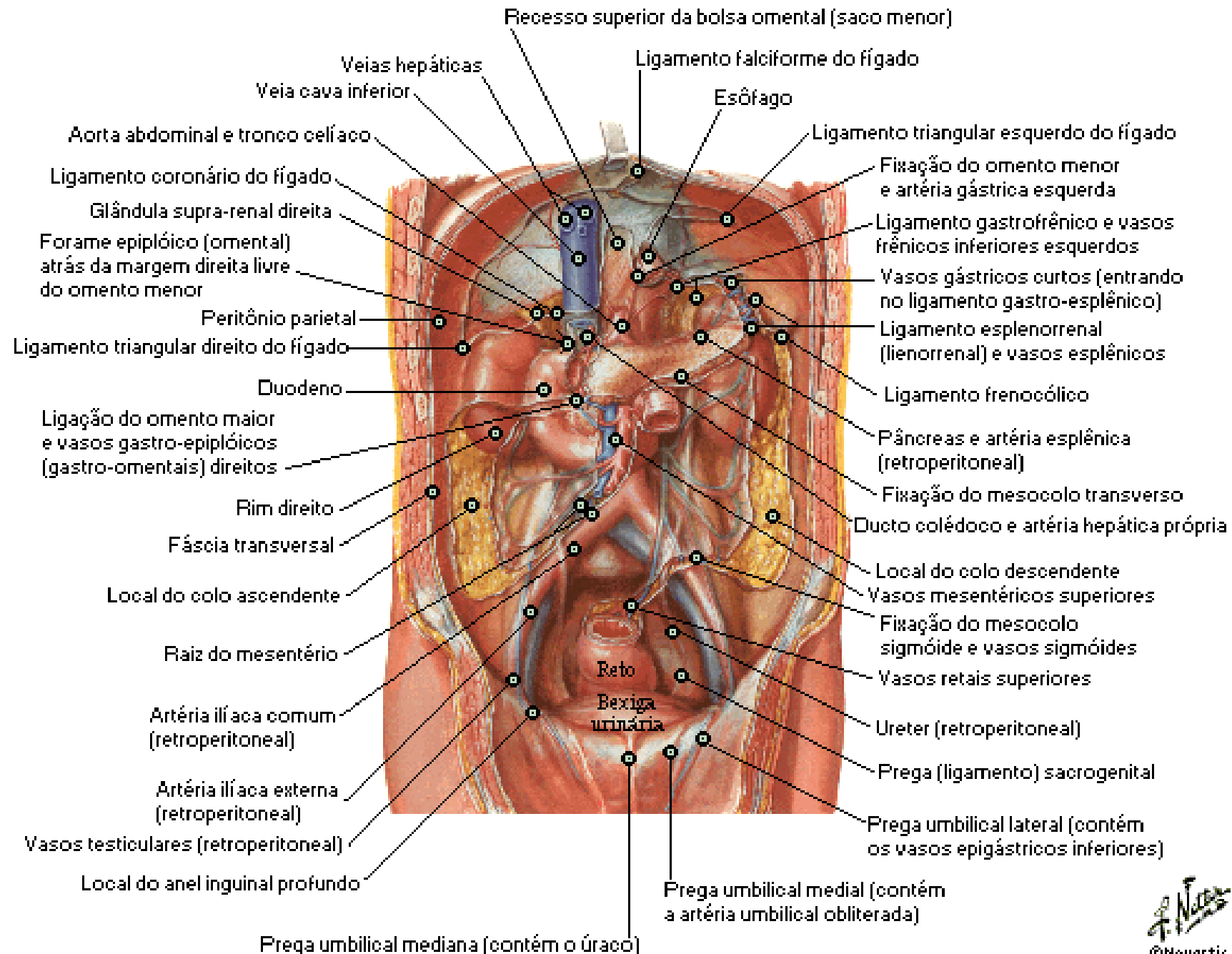


Bolsa Omental

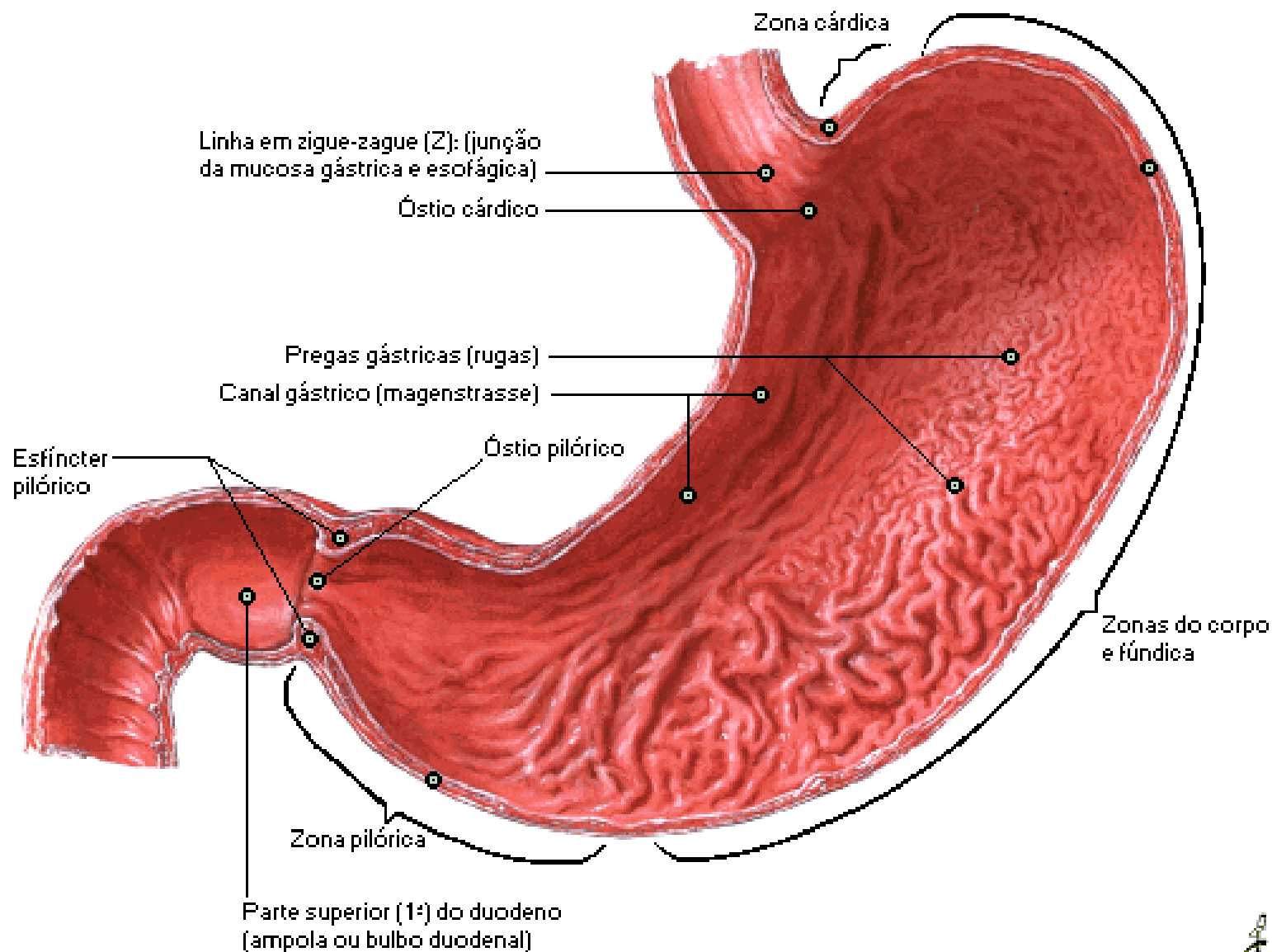
Secção Transversal



Peritônio da Parede Abdominal Posterior

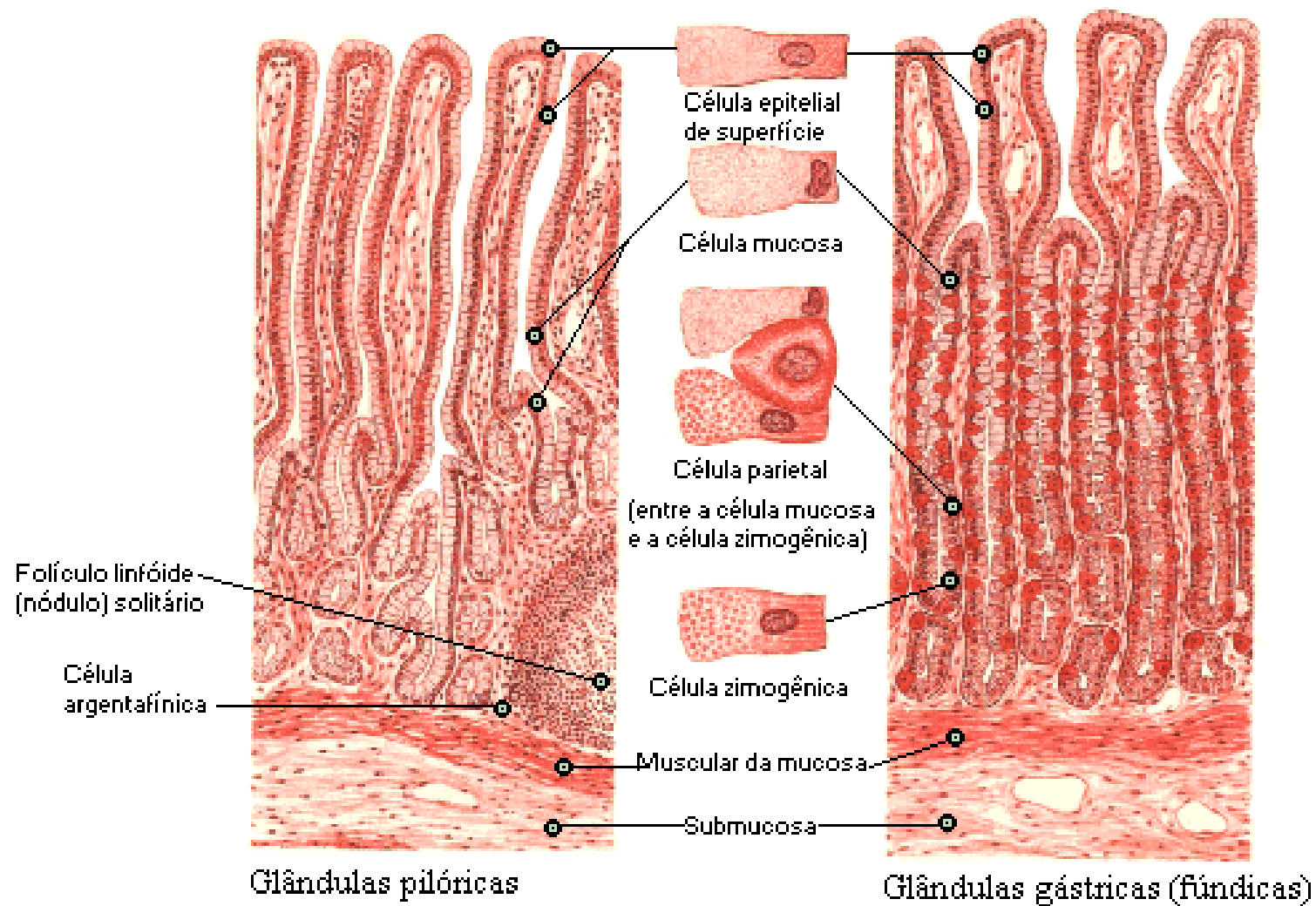


Mucosa do Estômago

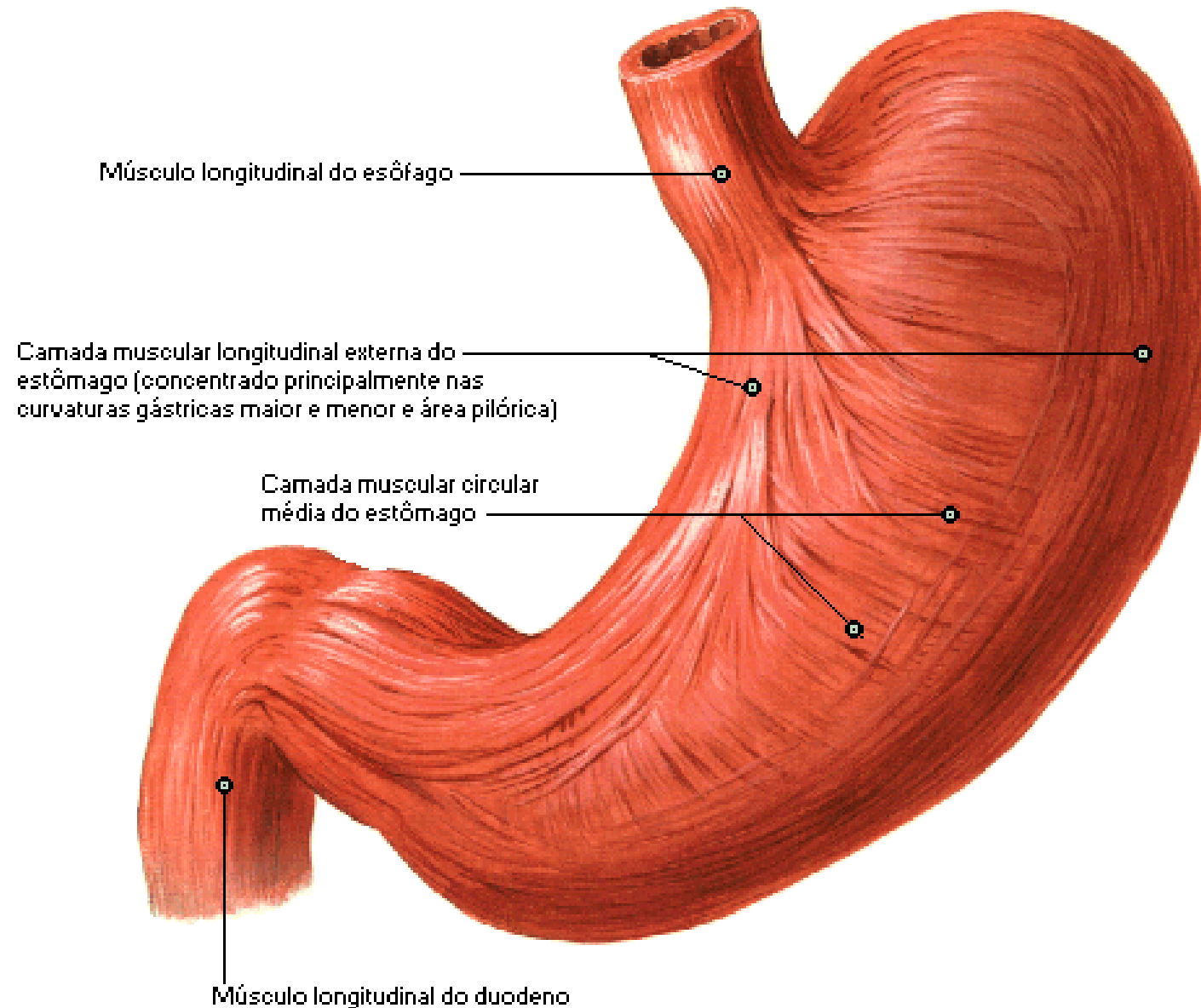


Mucosa do Estômago

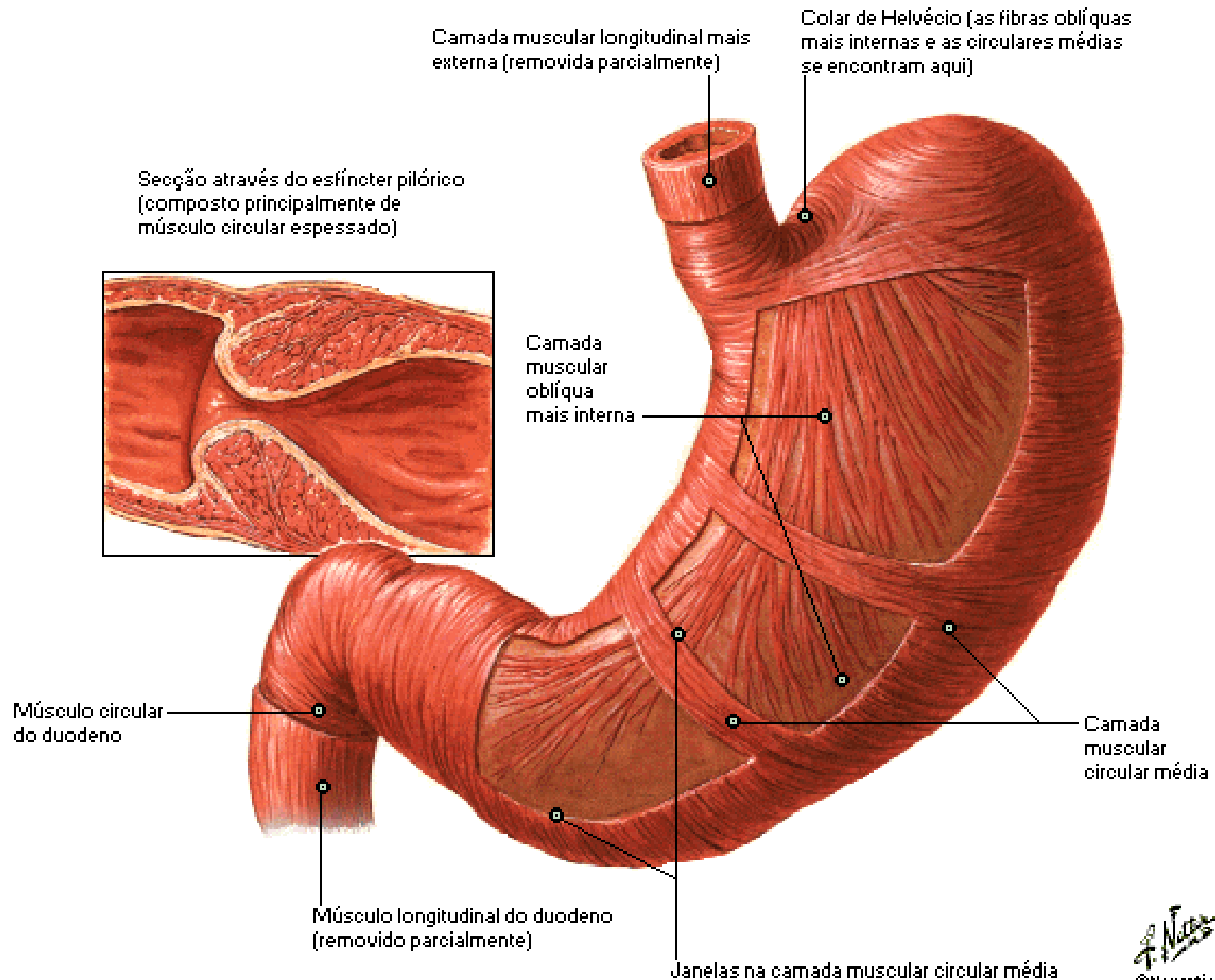
Histologia



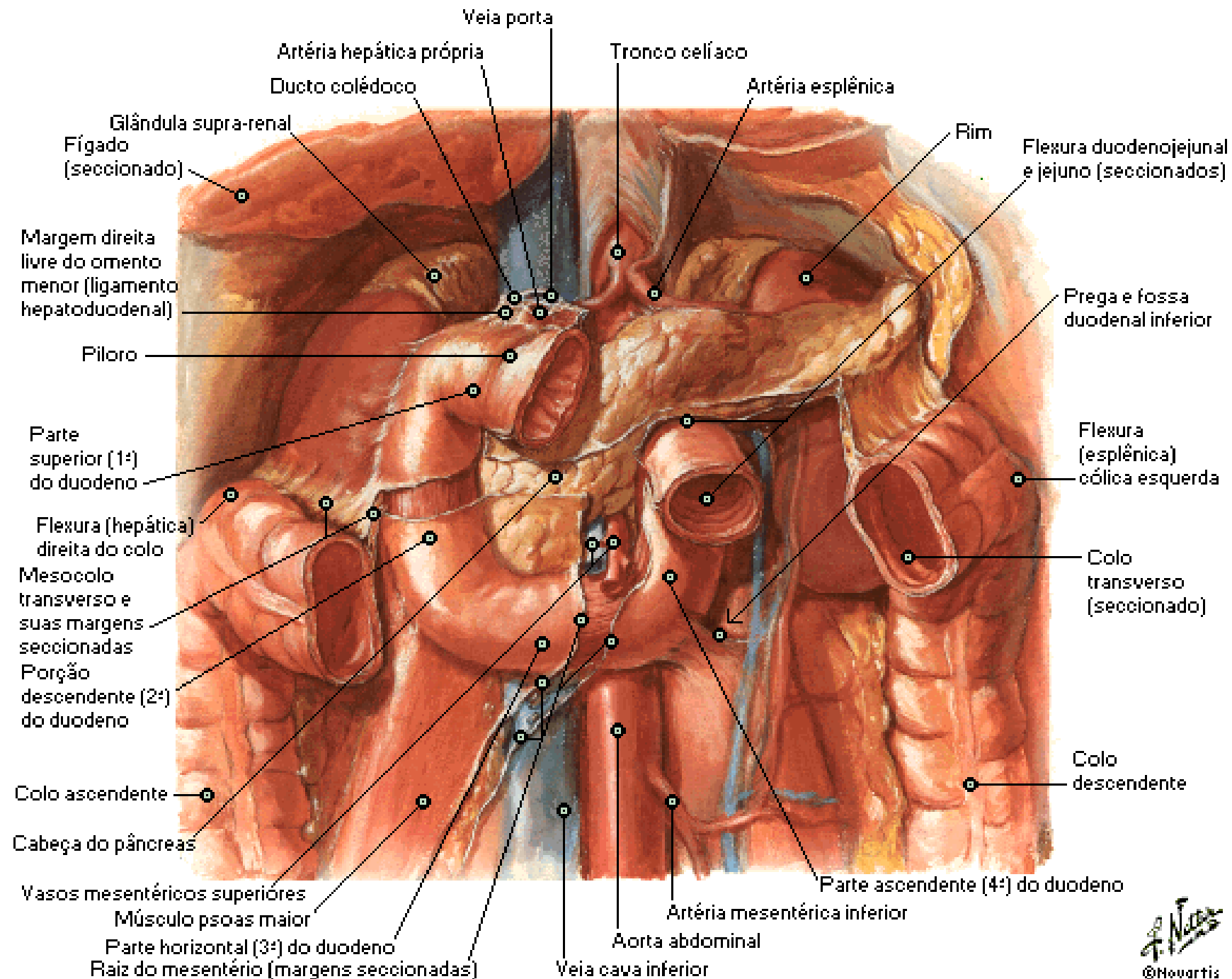
Musculatura do Estômago



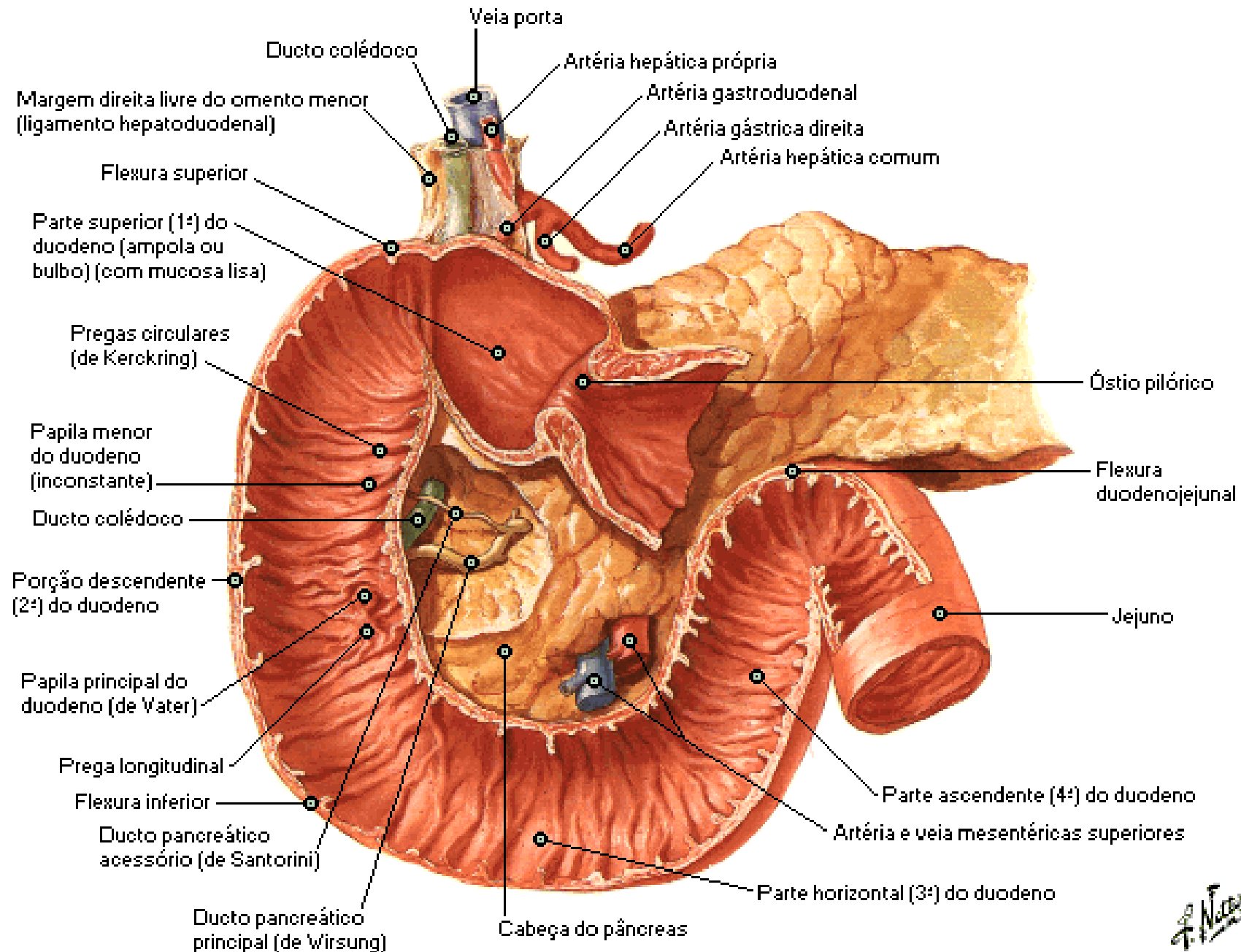
Musculatura do Estômago [Continuação]



Duodeno in Situ



Mucosa do Duodeno



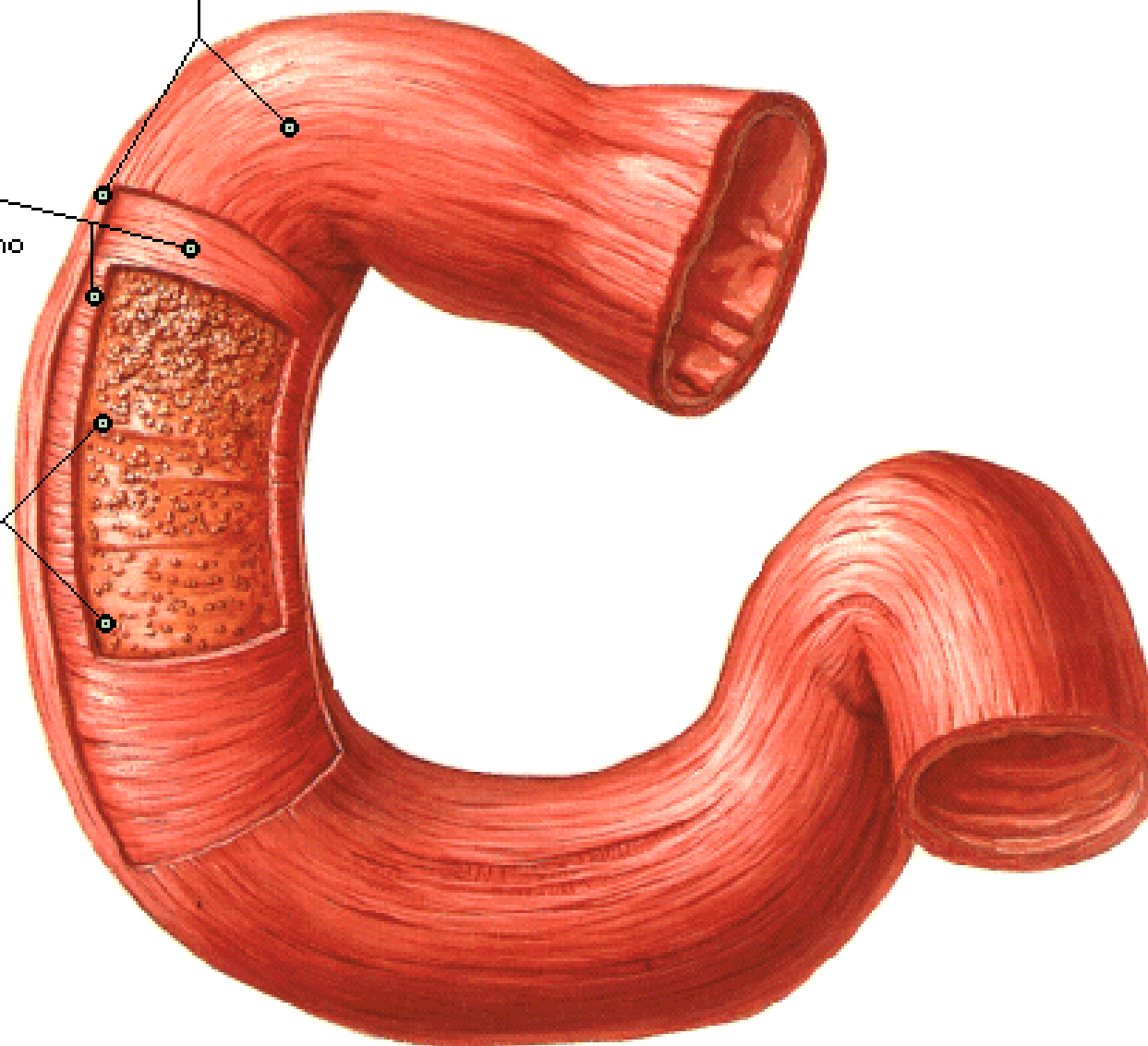
Musculatura do Duodeno

Camadas da Parede

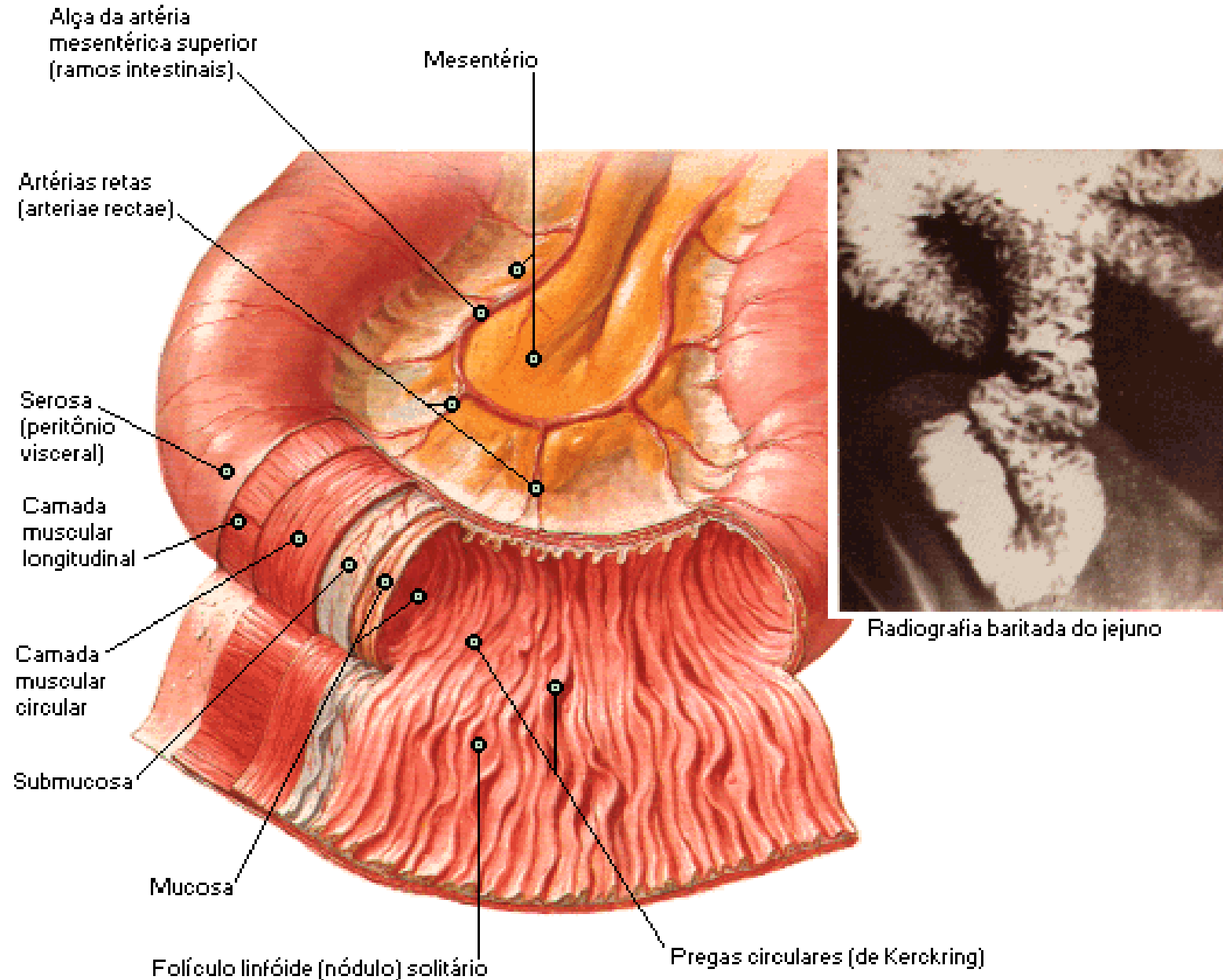
Camada muscular longitudinal externa (com janela aberta)

Estrato muscular circular interno (com janela aberta)

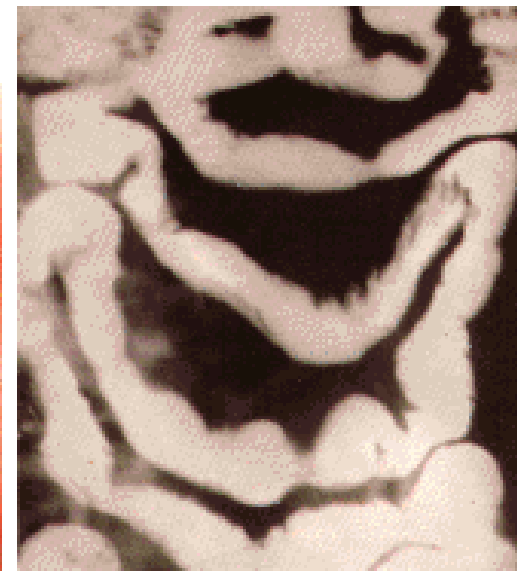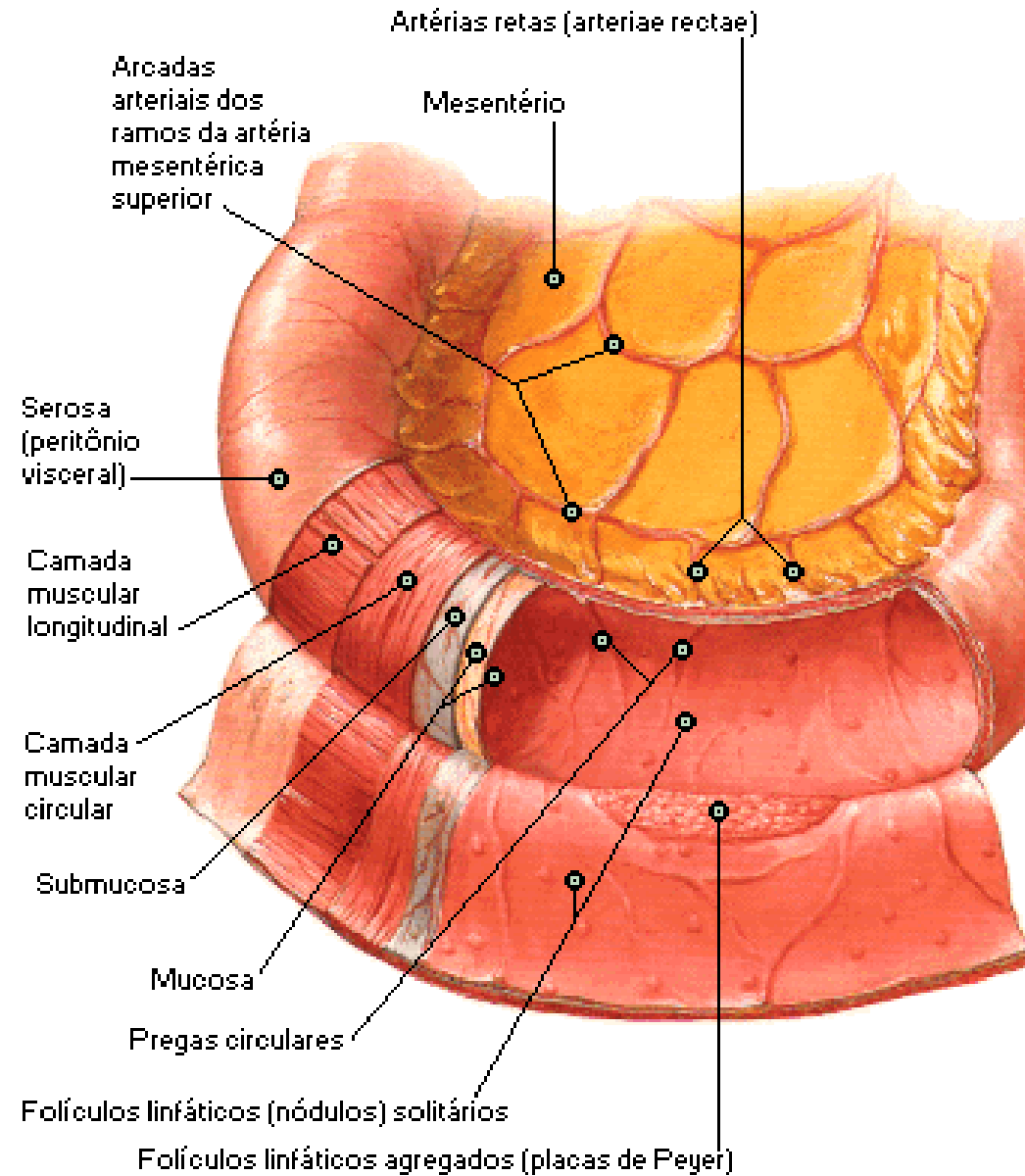
Submucosa com as glândulas duodenais (de Brünner)



Mucosa e Musculatura do Jejuno

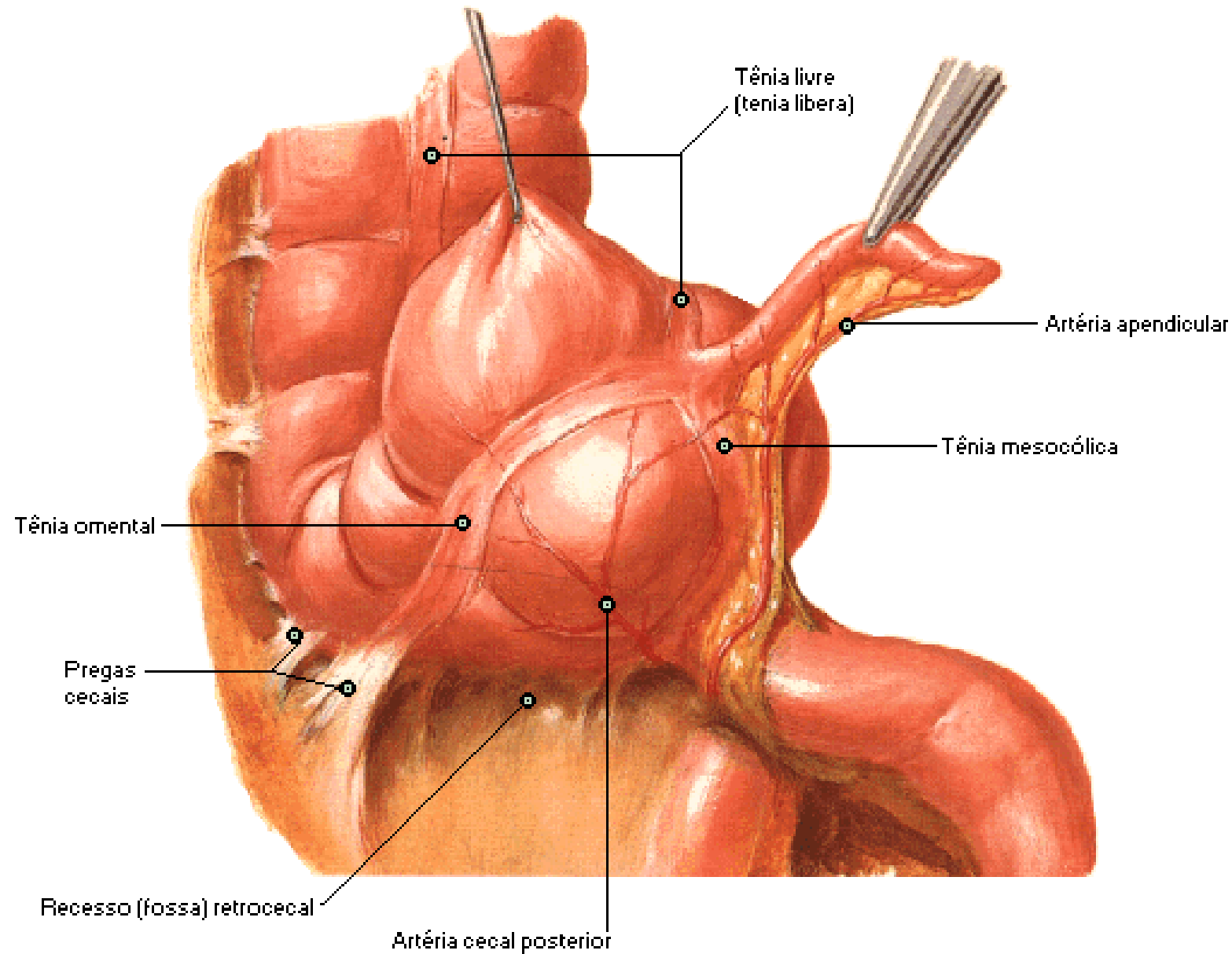


Mucosa e Musculatura do Íleo



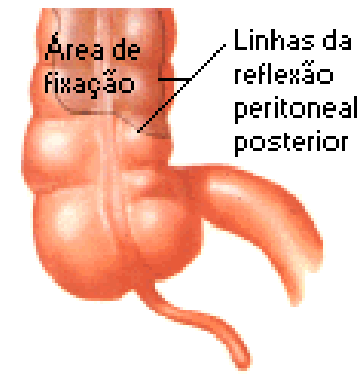
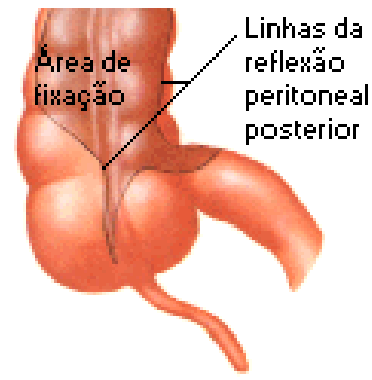
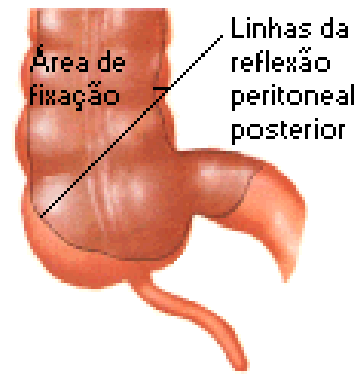
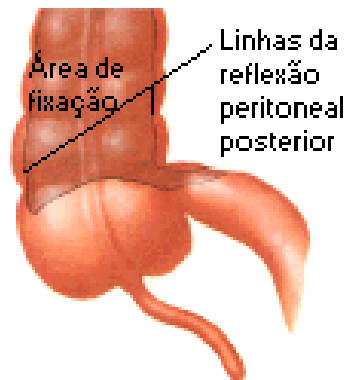
Região Ileocecal

Recesso [Fossa] Retrocecal Exposto



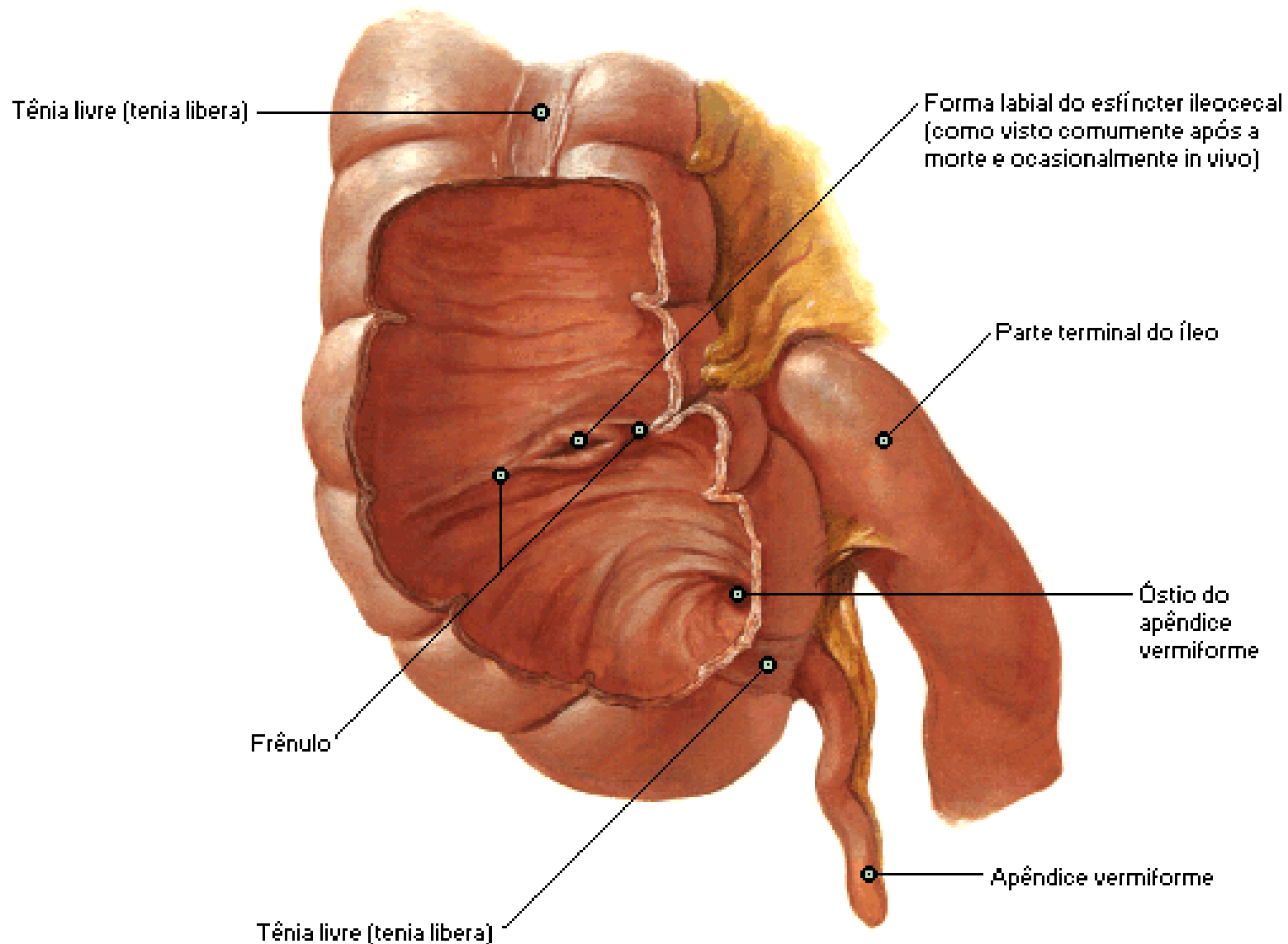
Região Ileocecal

Variações na Fixação Posterior do Peritônio



Região Ileocecal

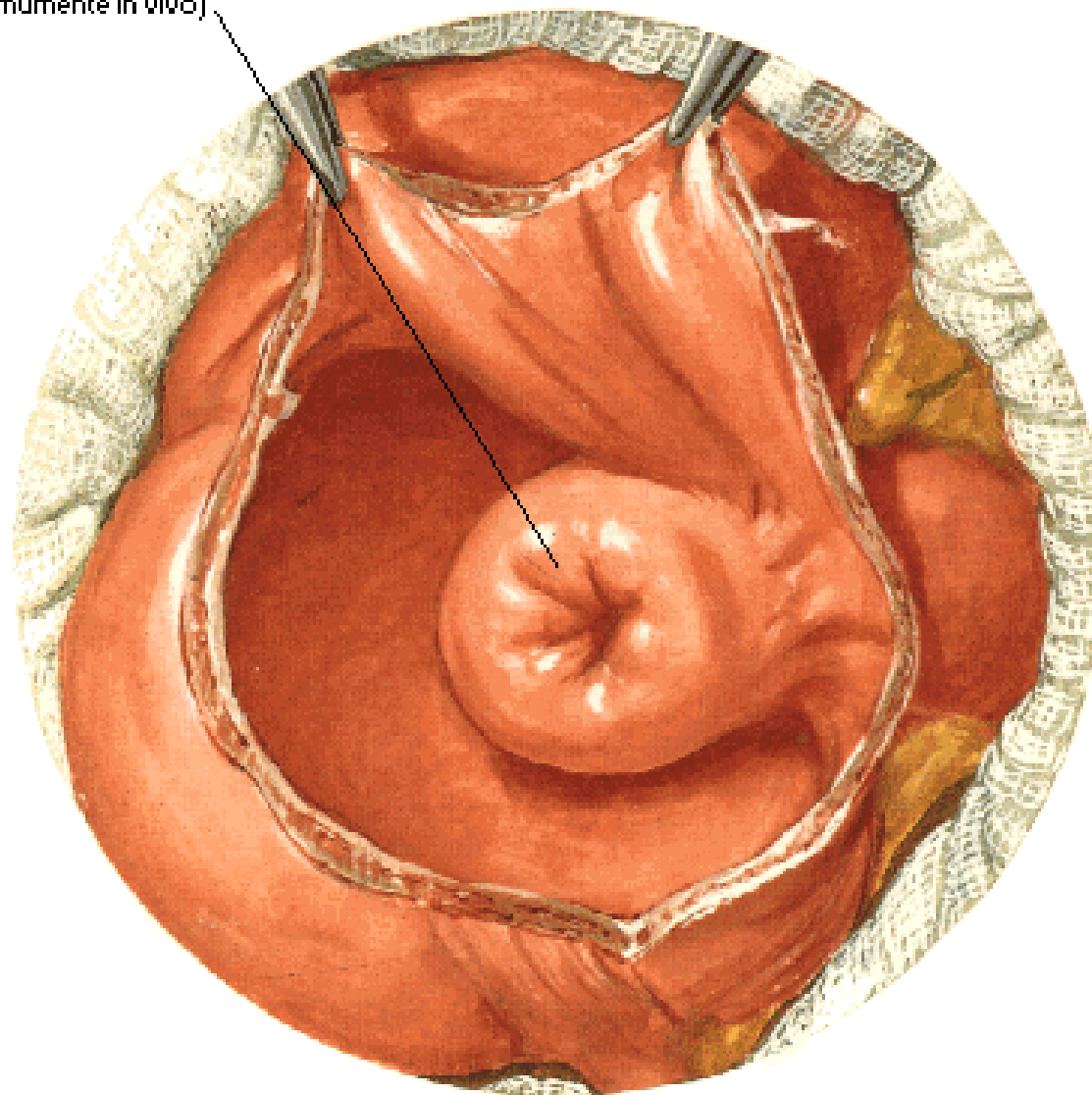
Forma Labial da Valva Ileocecal



Região Ileocecal

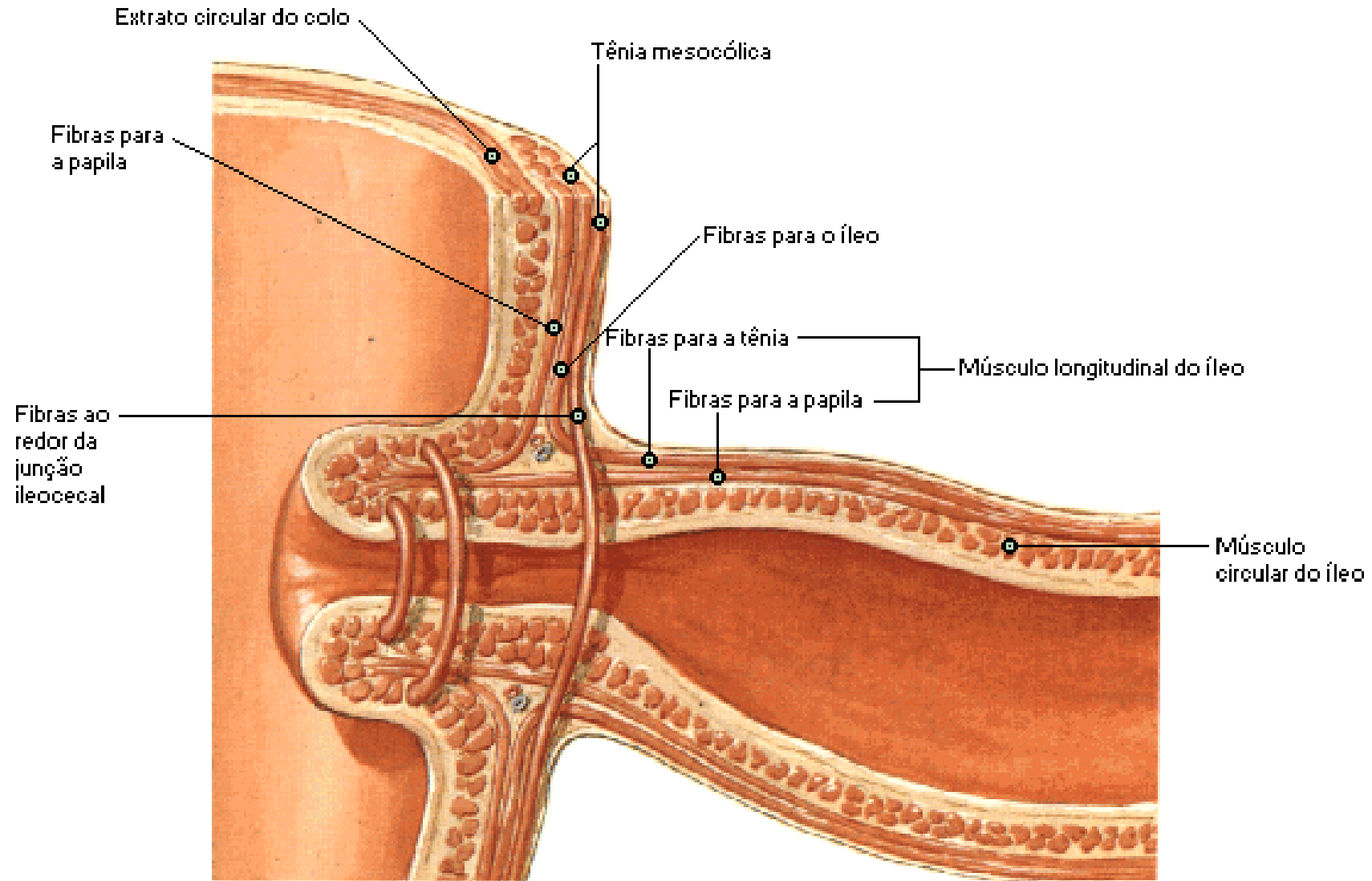
Forma Papilar da Valva Ileocecal

Forma papilar do esfíncter ileocecal
(encontrada mais comumente in vivo)



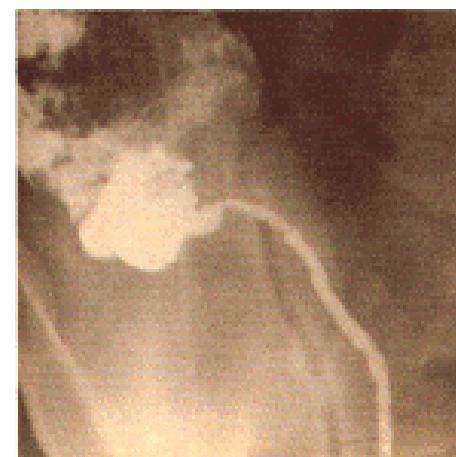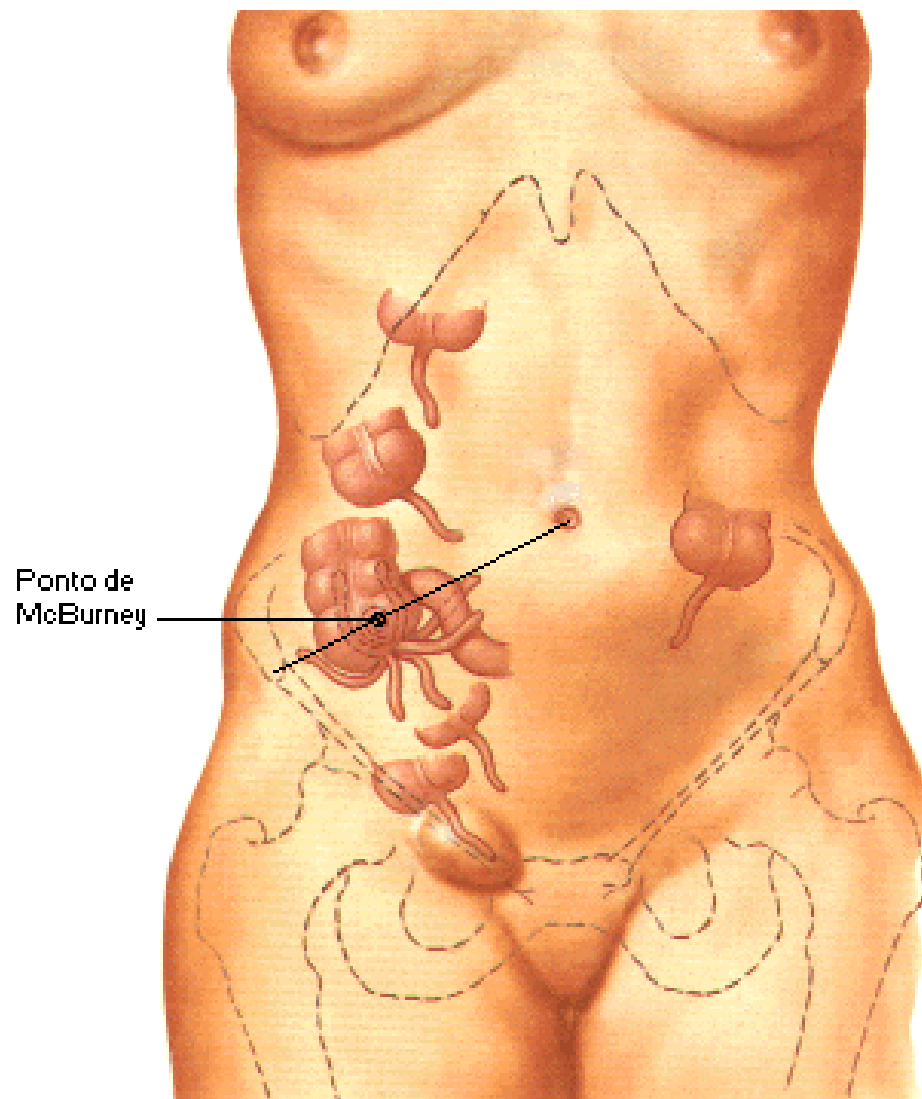
Região Ileocecal

Esquemas de Fibras Musculares na Valva Ileocecal



Apêndice Vermiforme

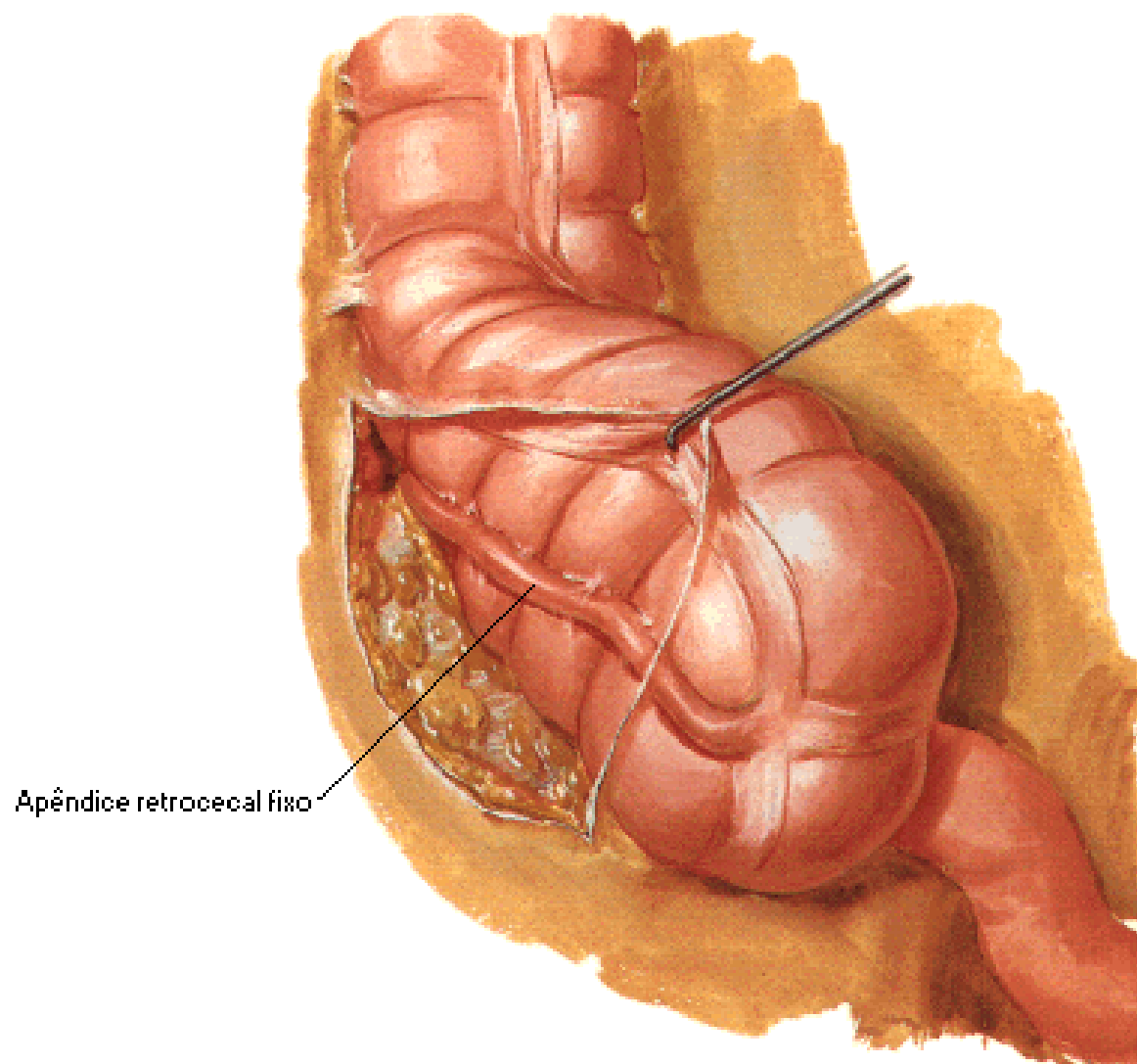
Variações na Posição



Apêndice incomumente longo se estendendo até a pelve (radiografia baritada)

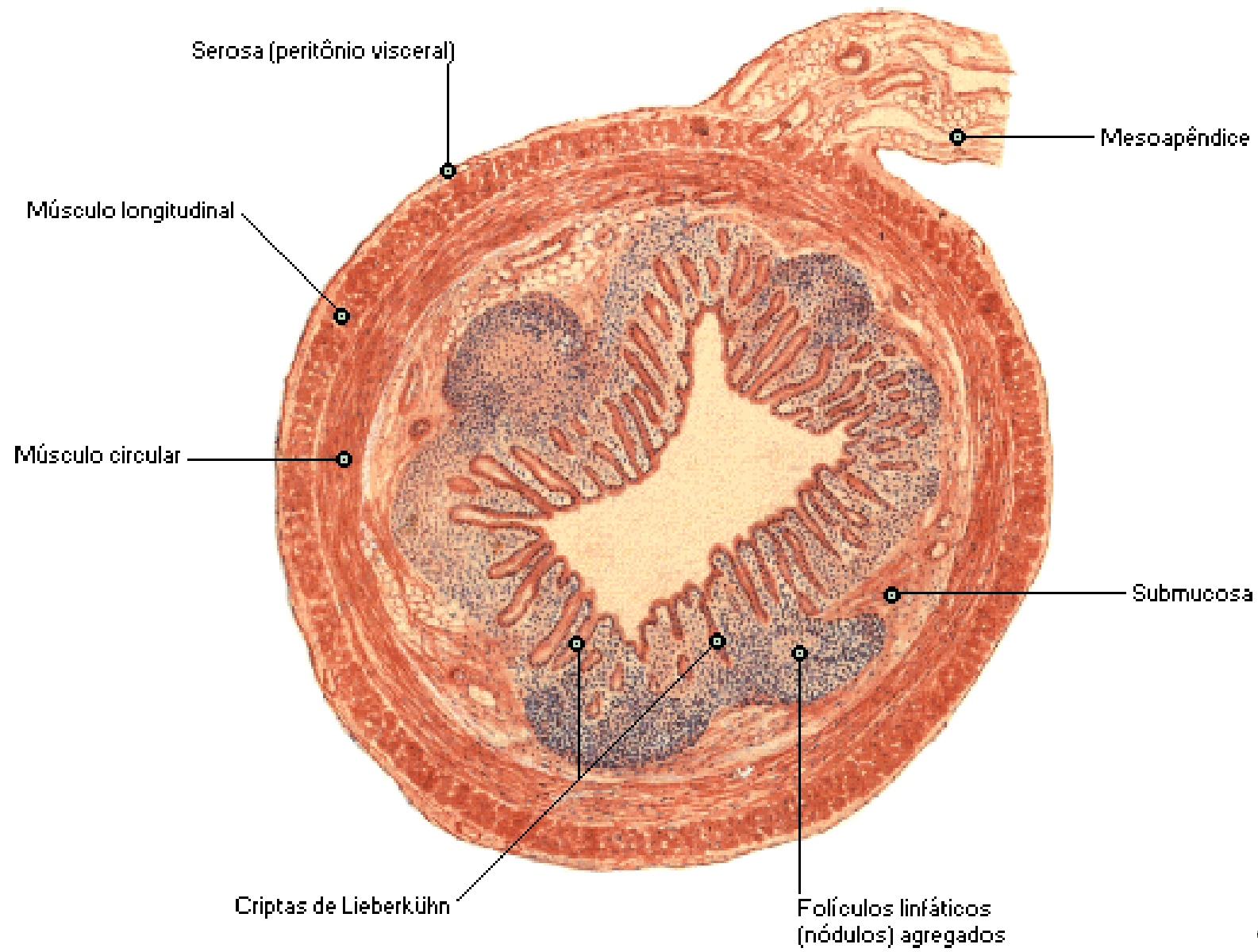
Apêndice Vermiforme

Retrocecal Fixo

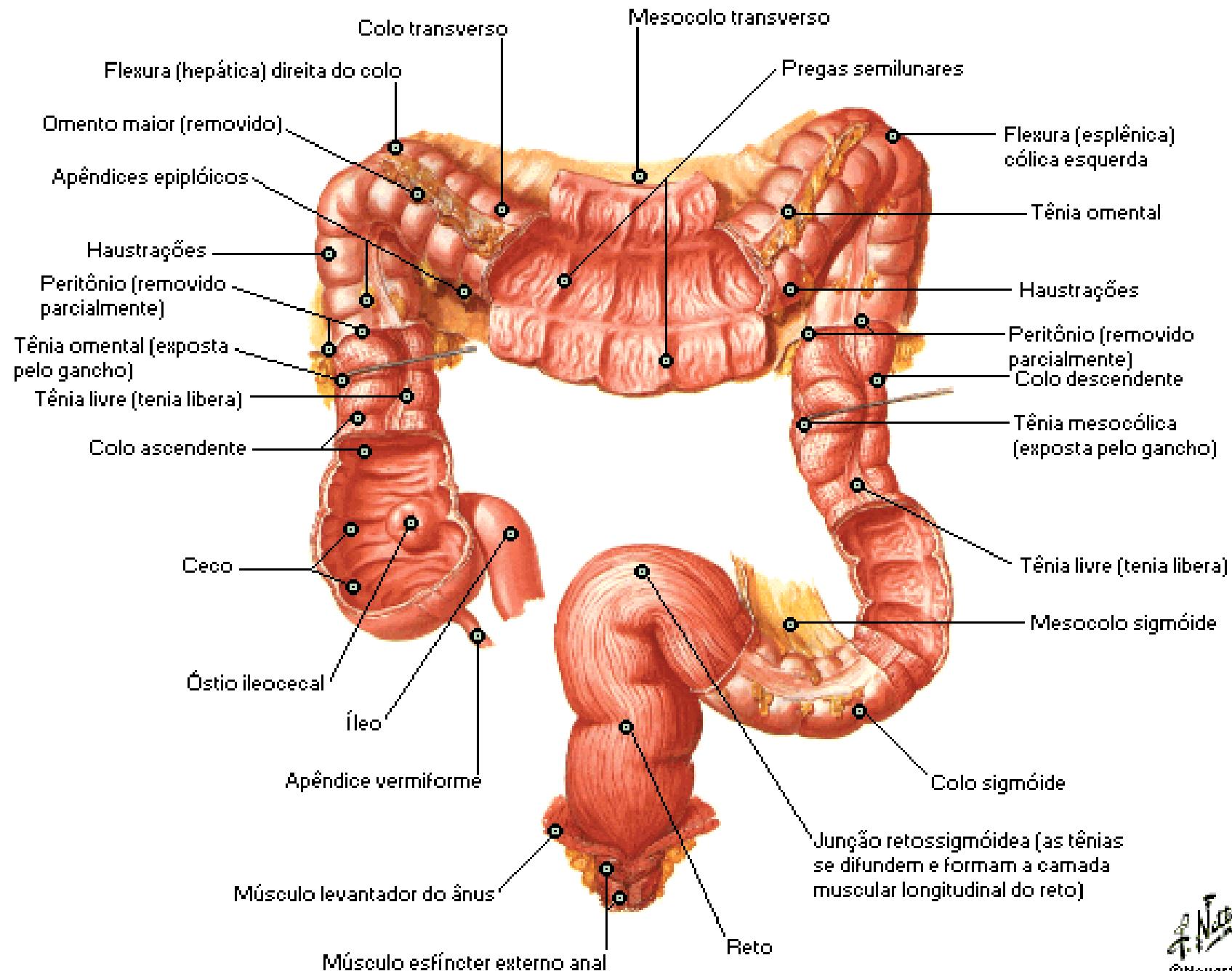


Apêndice Vermiforme

Secção Transversal

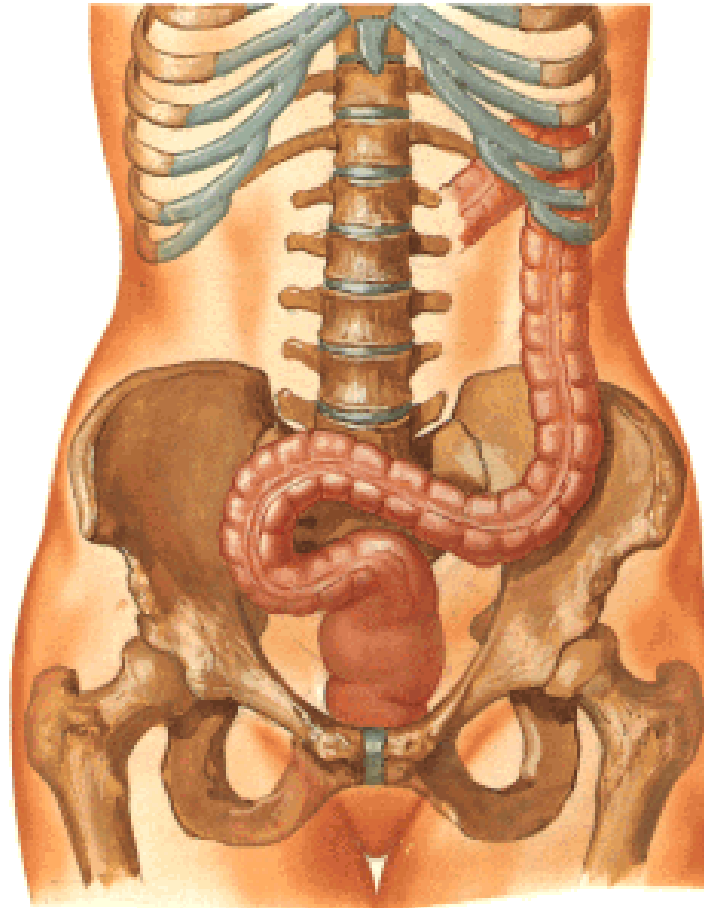


Mucosa e Musculatura do Intestino Grosso

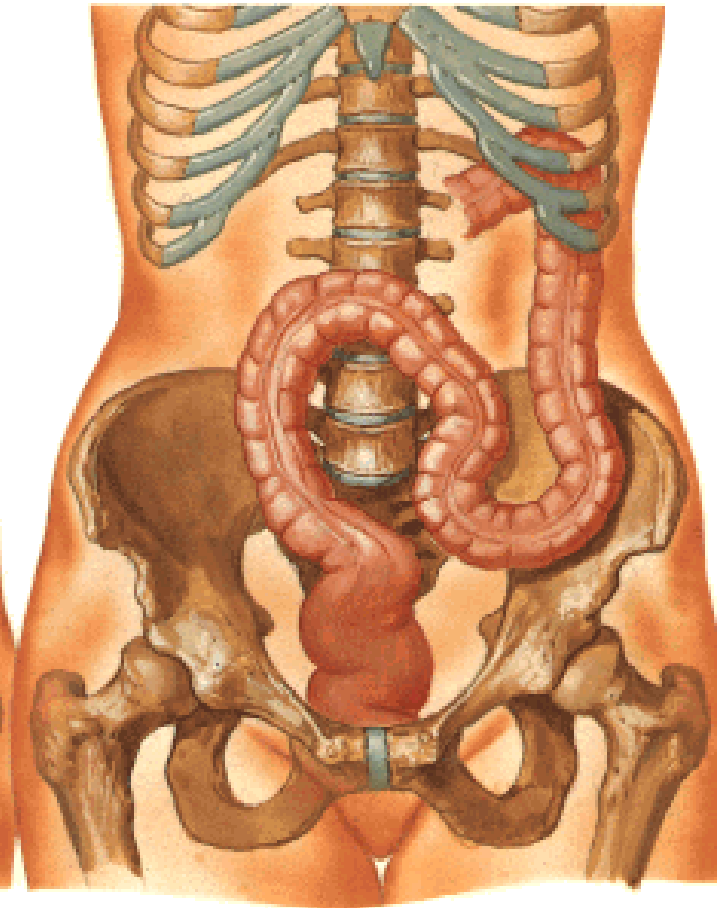


Colo Sigmóide [Continuação]

Variações na Posição



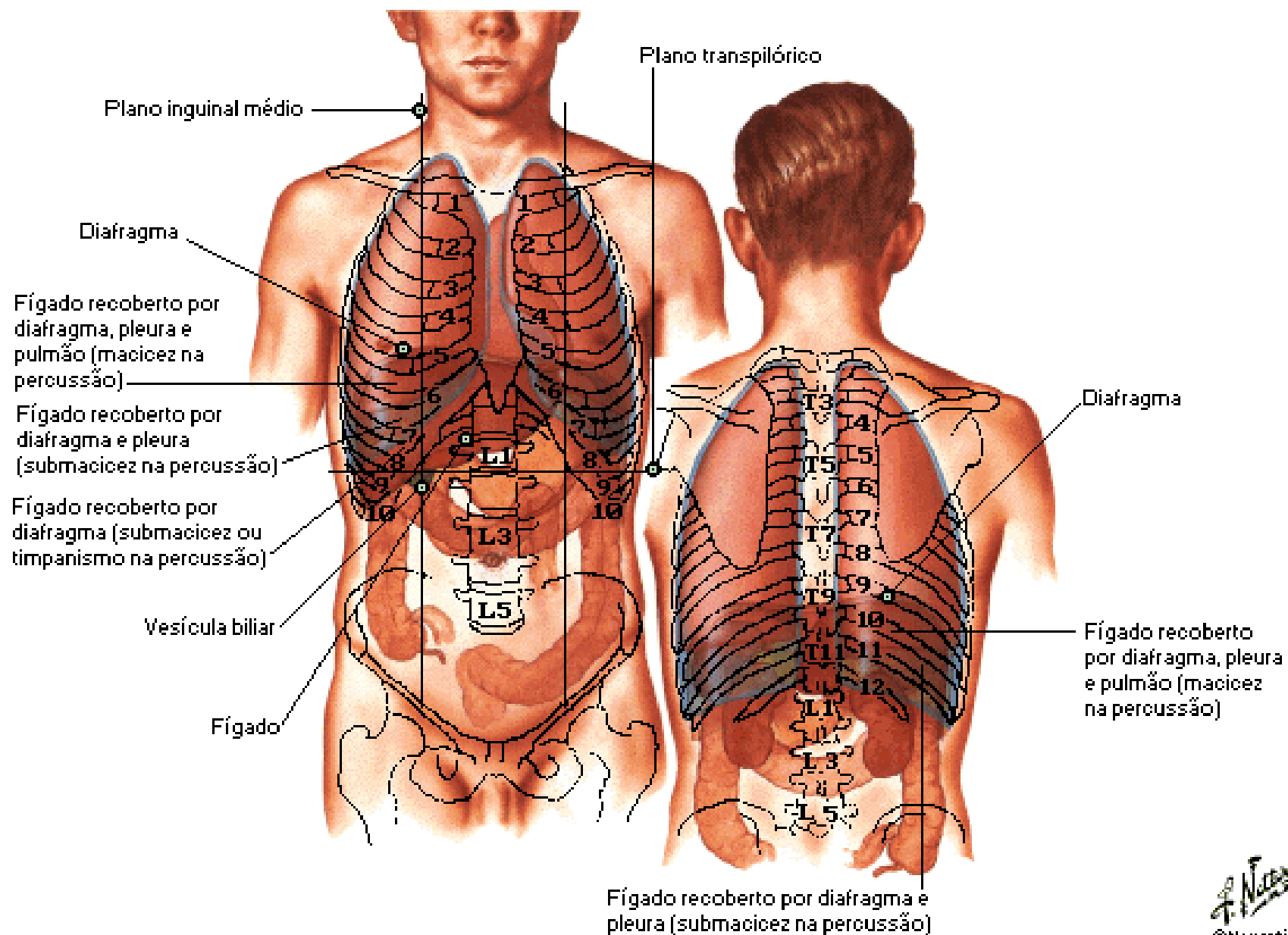
Com a alça voltada para o lado direito



Ascendendo para o abdome

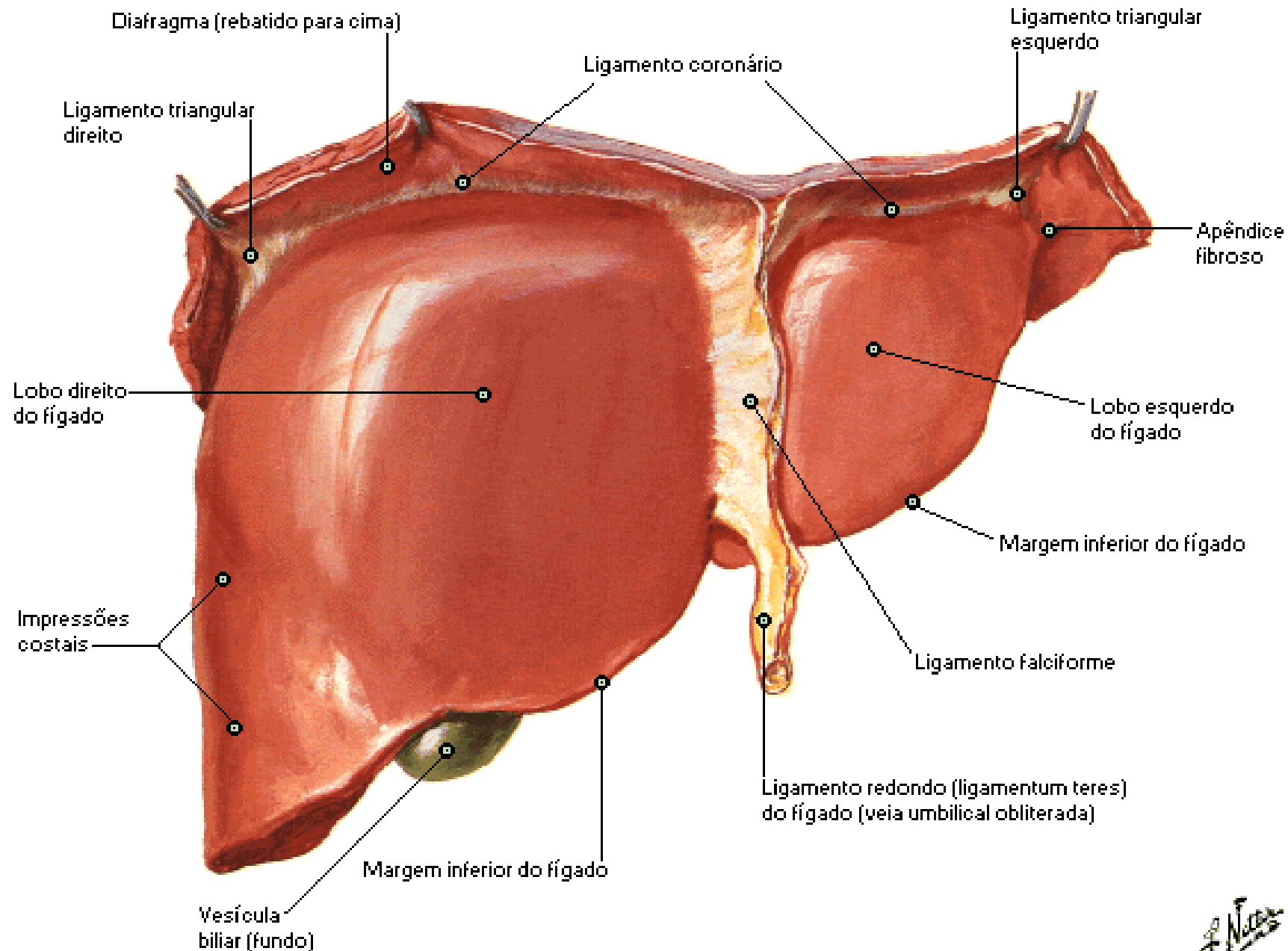
Topografia do Fígado

Vistas Anterior e Posterior



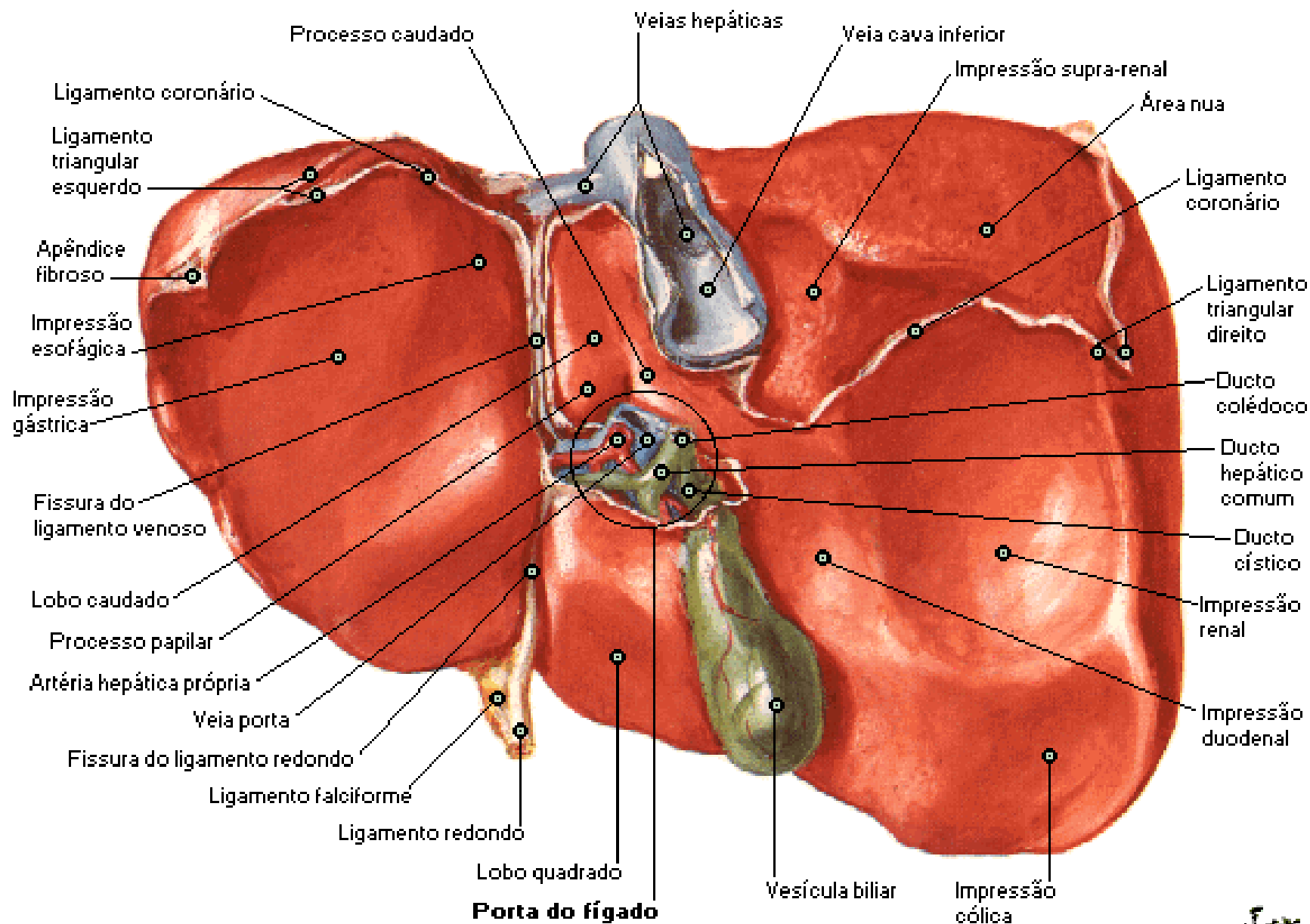
Faces e Leito Hepático

Vista Anterior



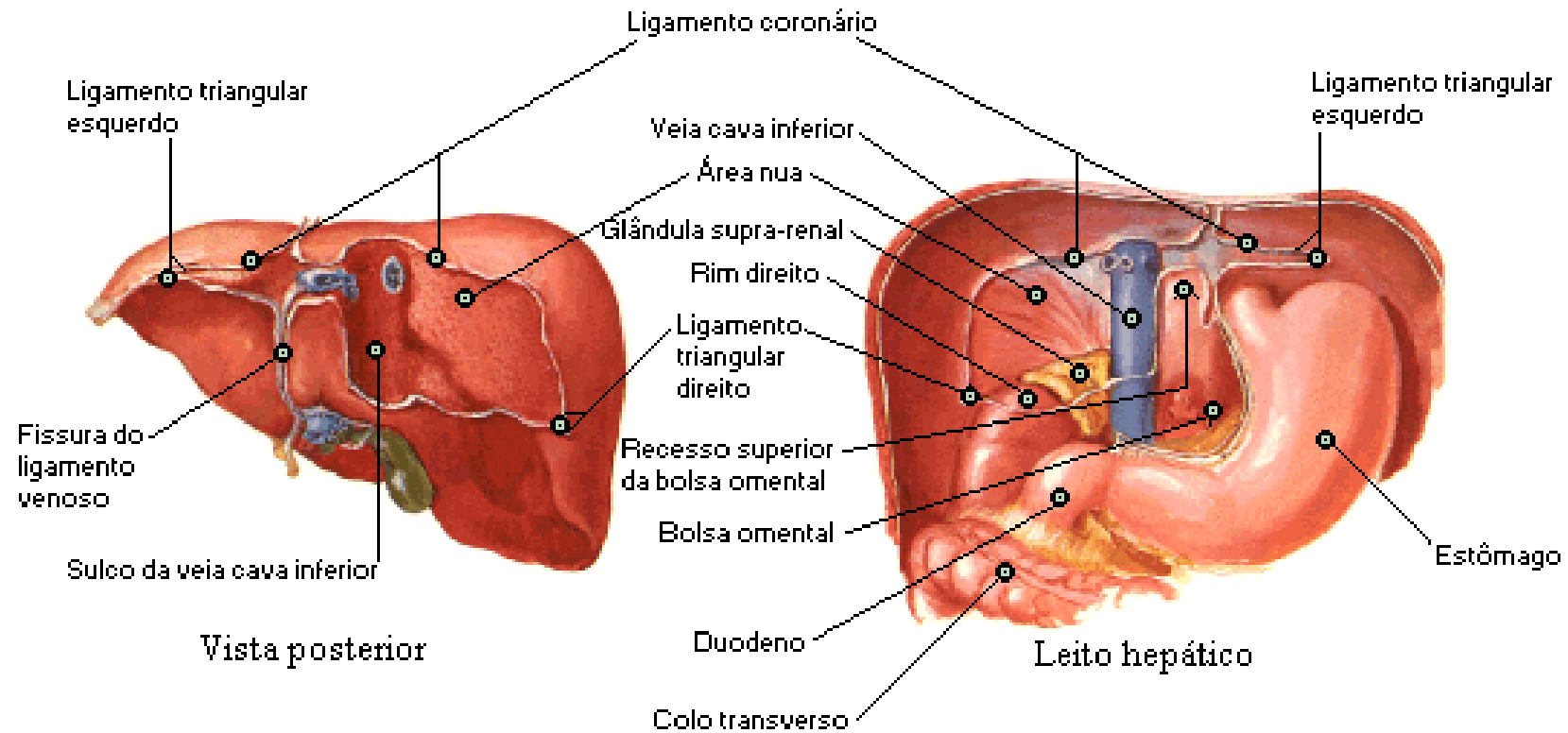
Faces e Leito Hepático

Face Visceral

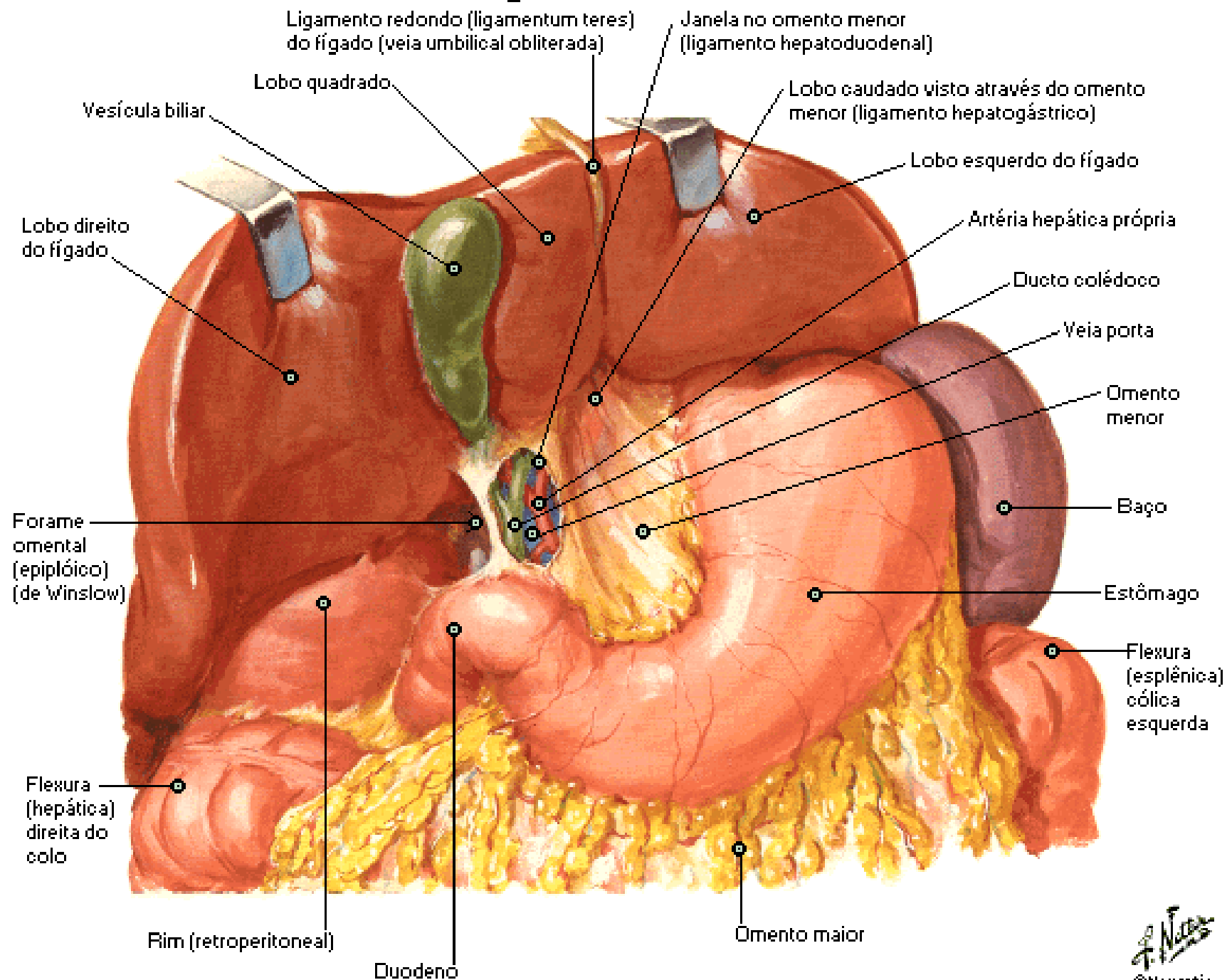


Faces e Leito Hepático

Vista Posterior e Leito Hepático

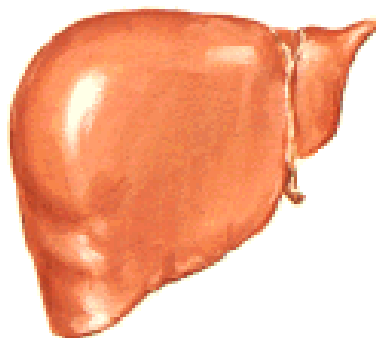


Fígado in Situ

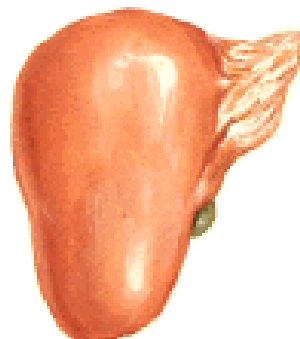


Variações na Forma do Fígado

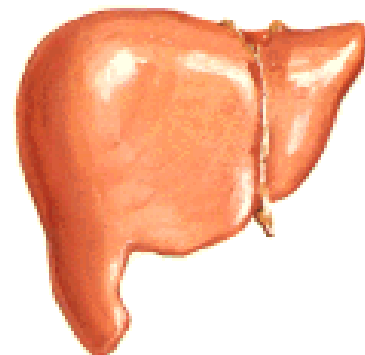
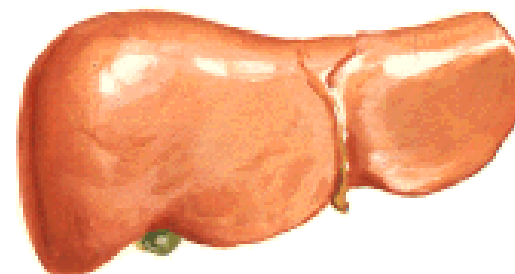
Lobo esquerdo muito pequeno, impressões costais profundas



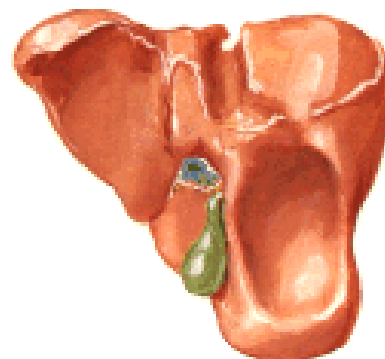
Atrofia completa do lobo esquerdo (compressão da veia porta à esquerda)



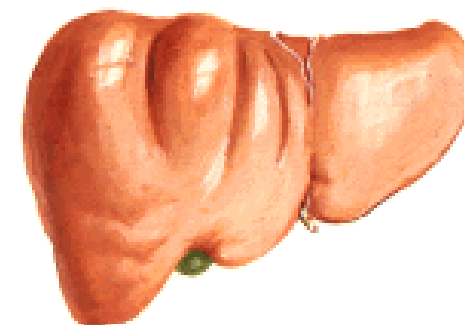
Fígado transverso, tipo "sela", lobo esquerdo relativamente grande



Processo tipo "língua" do lobo direito



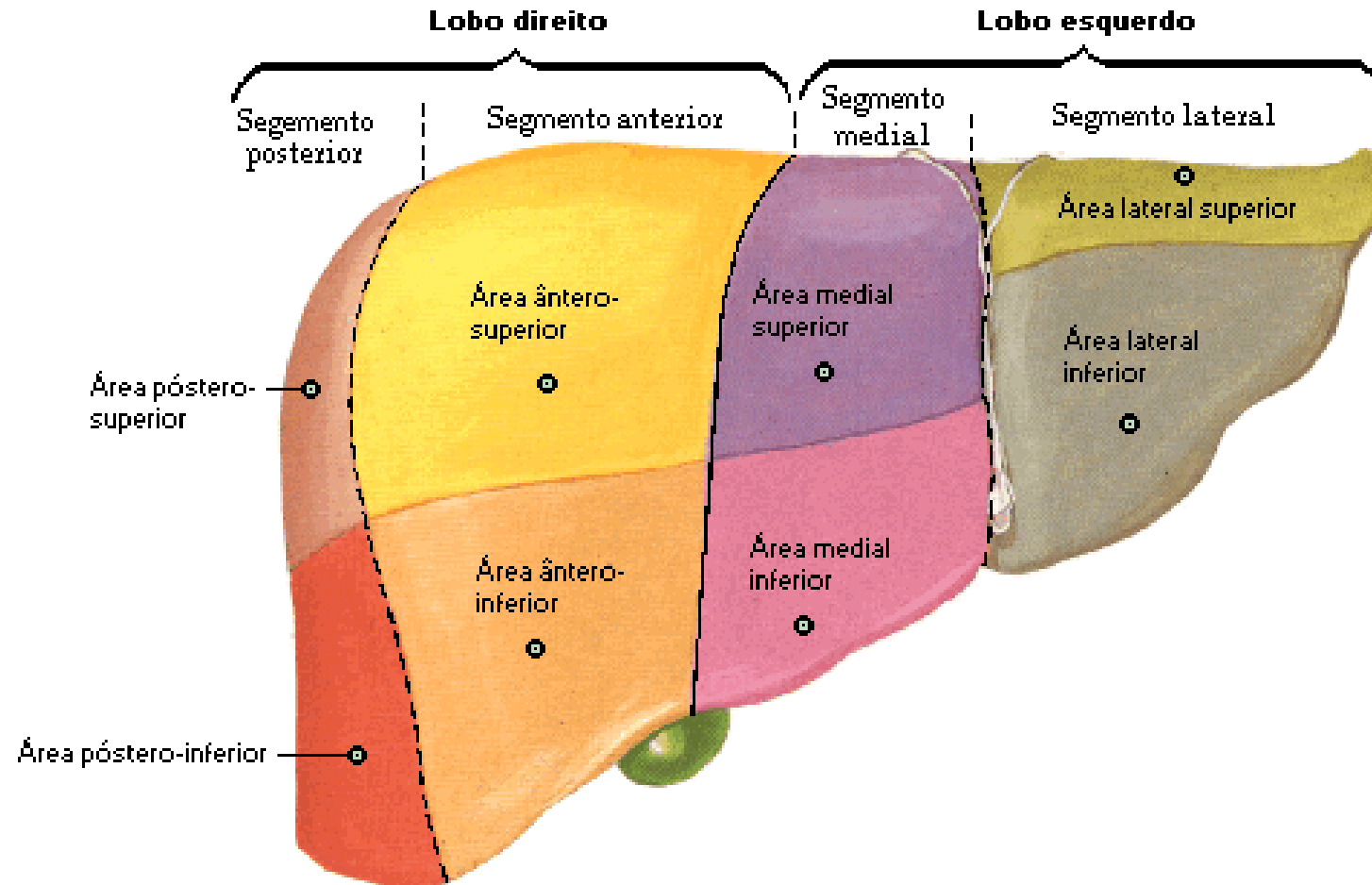
Impressão renal muito profunda e constrição tipo "espartilho"



Sulcos diafragmáticos

Segmentos e Lobos do Fígado

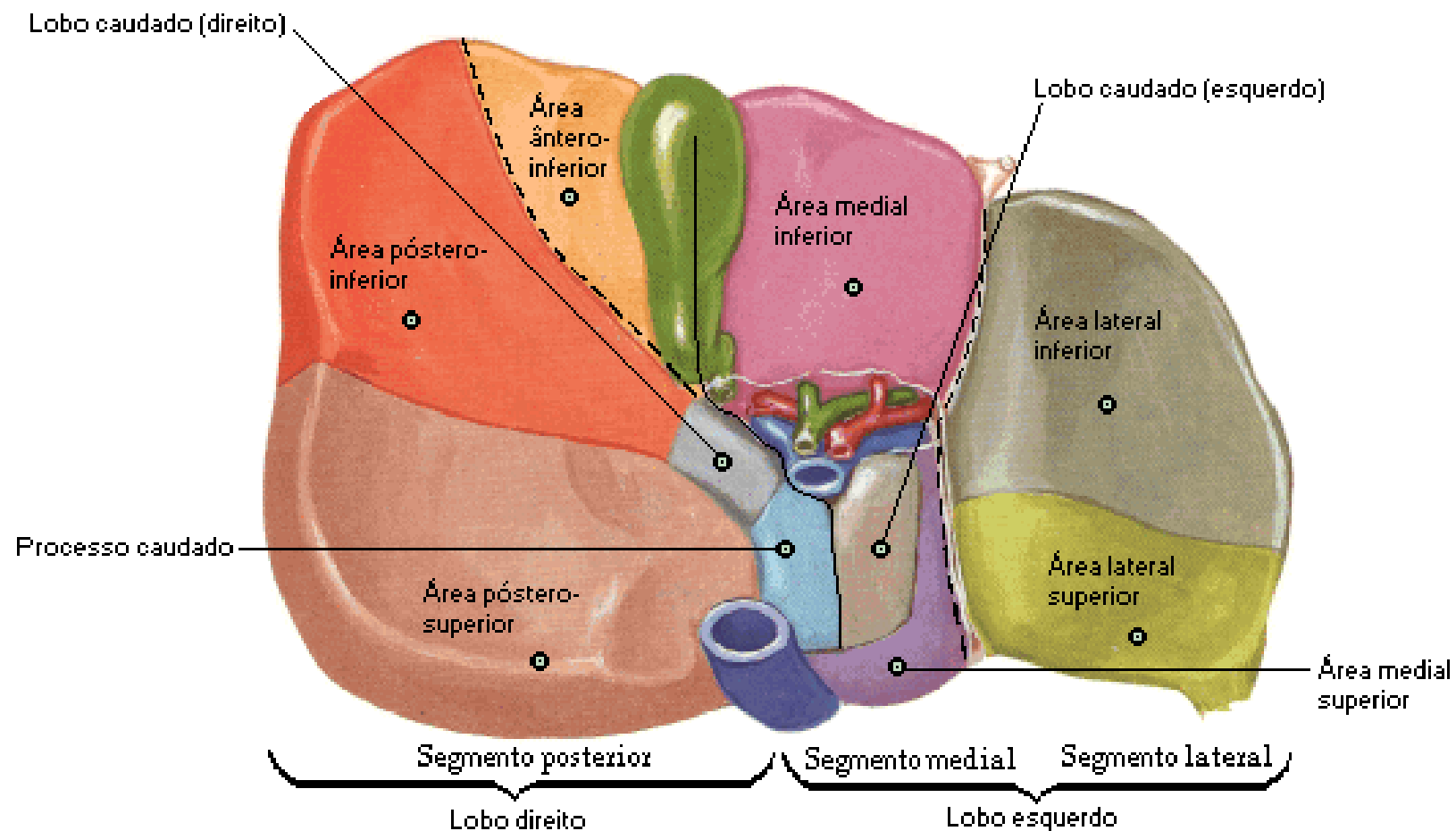
Face Diafragmática



A divisão em segmentos é baseada nas ramificações dos ductos biliares e vasos hepáticos. Não corresponde inteiramente à divisão em lobos

Segmentos e Lobos do Fígado

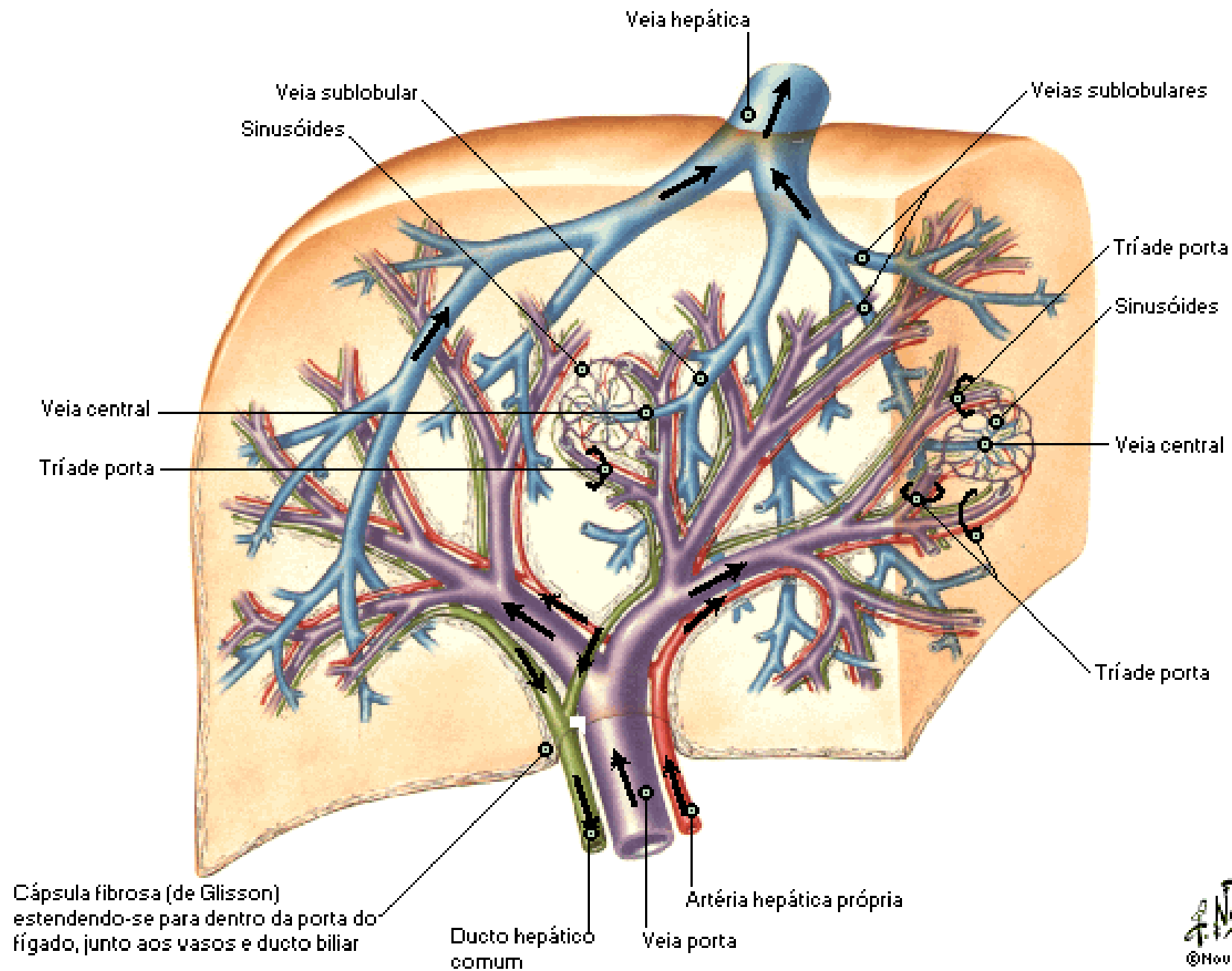
Face Visceral



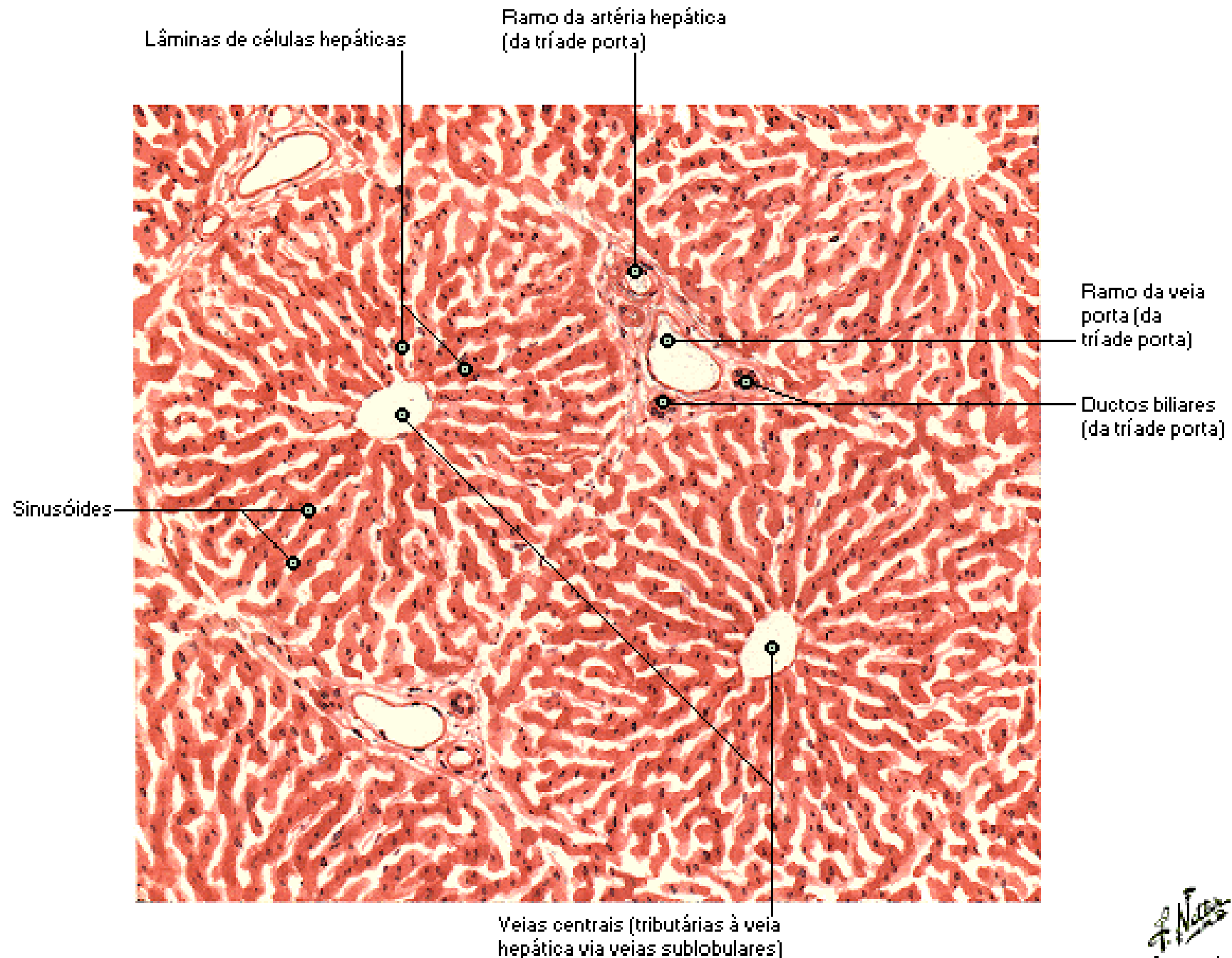
A divisão em segmentos é baseada nas ramificações dos ductos biliares e vasos hepáticos. Não corresponde inteiramente à divisão em lobos

Sistemas Vascular e Ductal Intra-hepáticos

Esquema

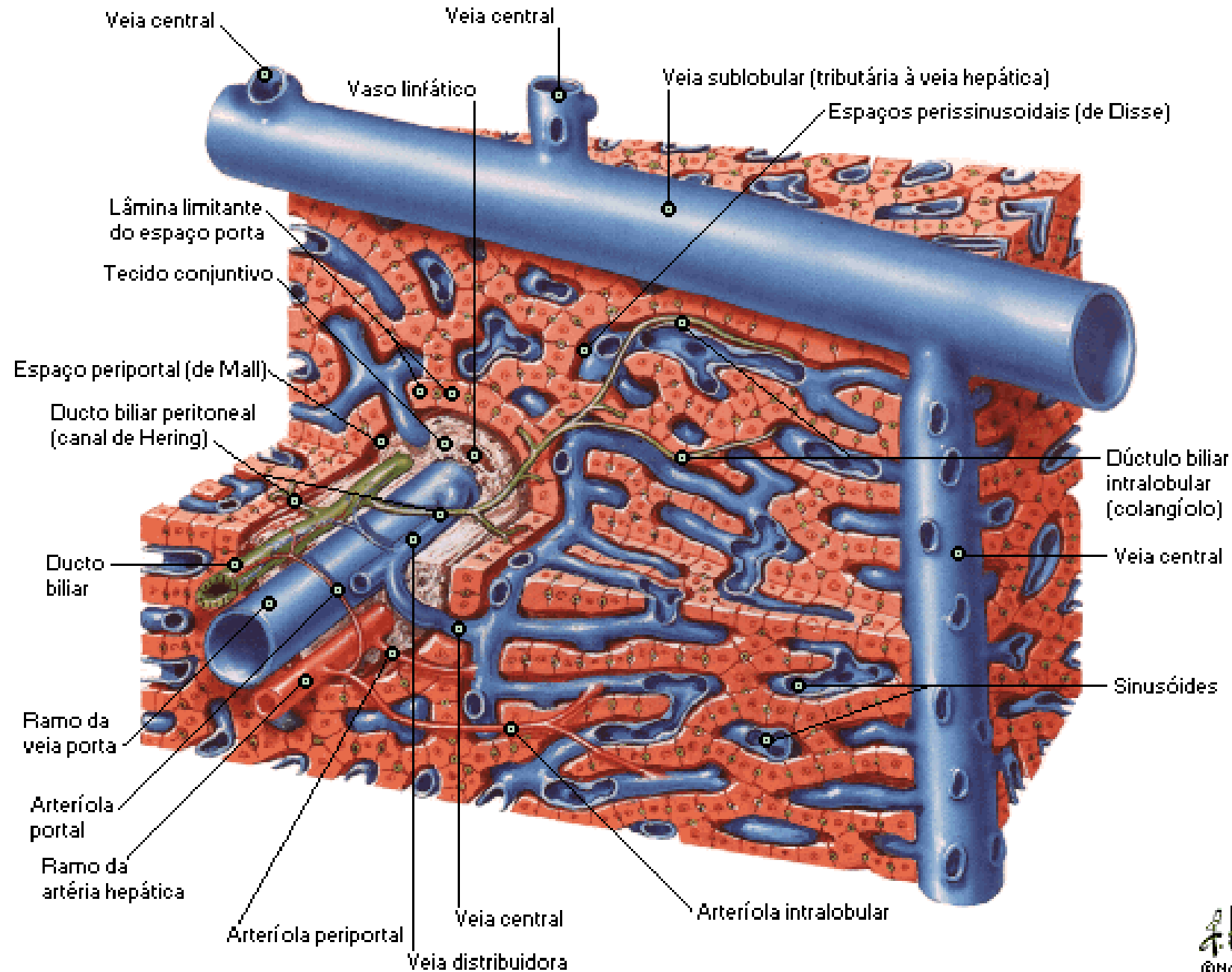


Padrão Lobular Normal do Fígado



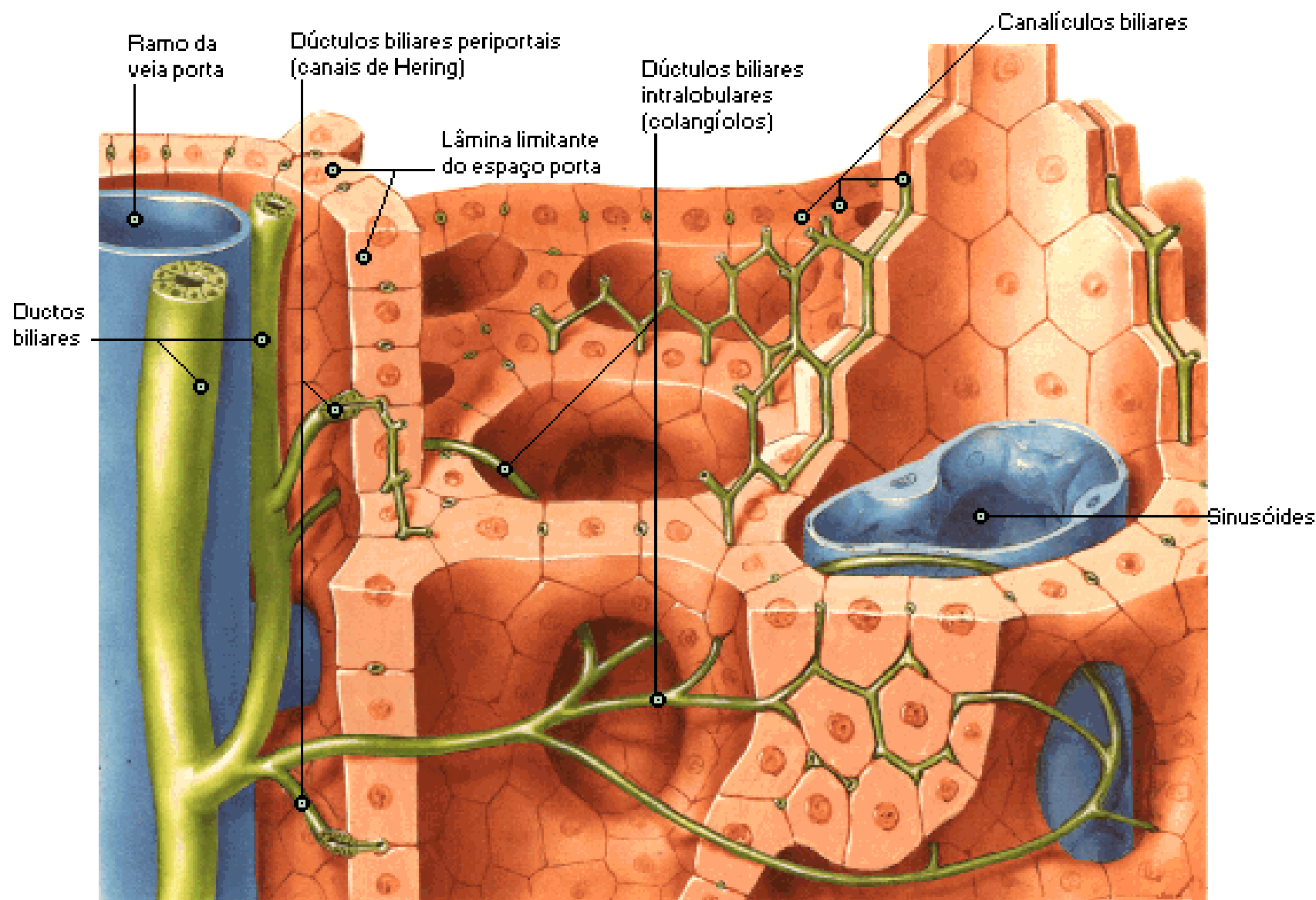
Estrutura do Fígado

Esquema



Sistema Biliar Intra-hepático

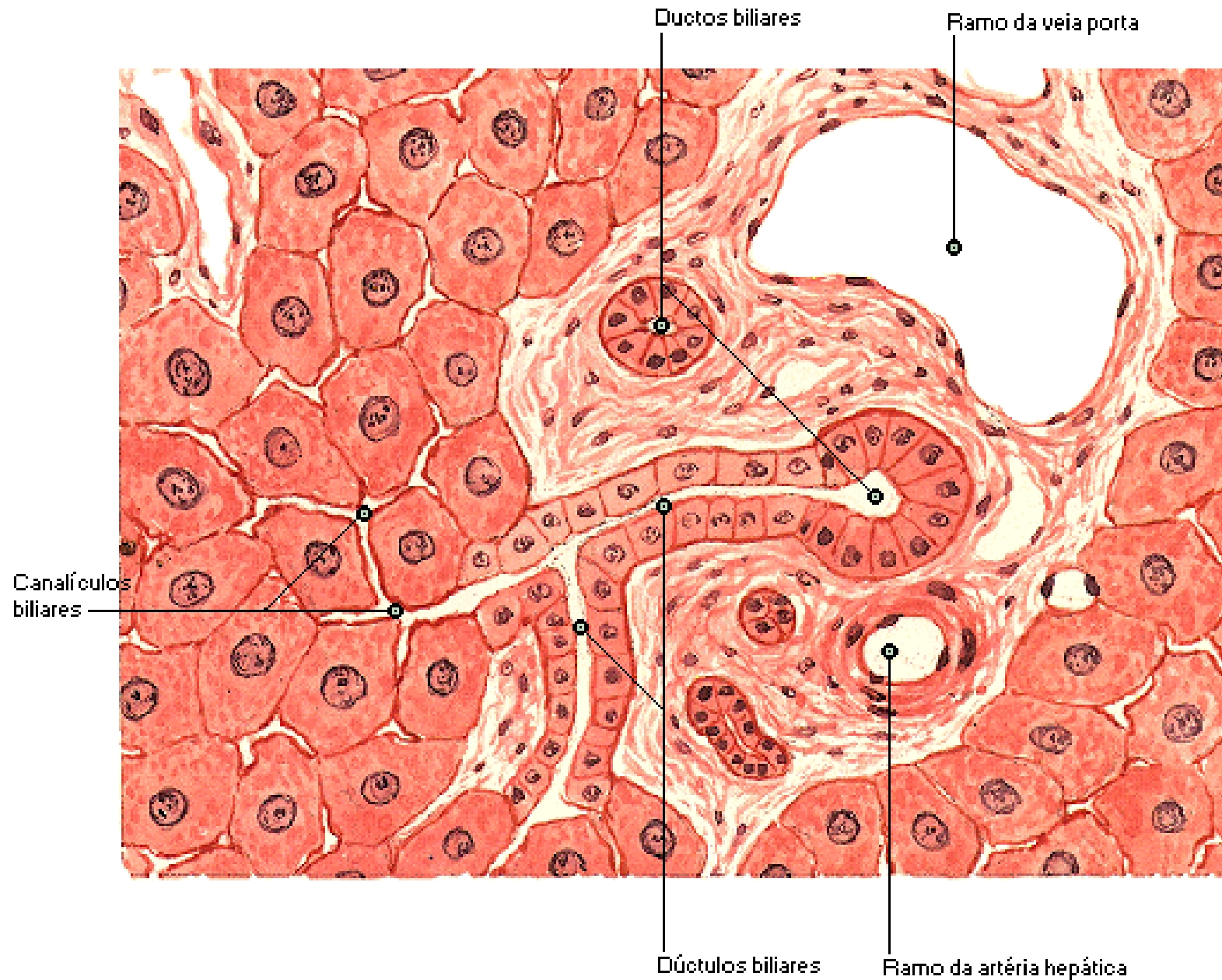
Esquema



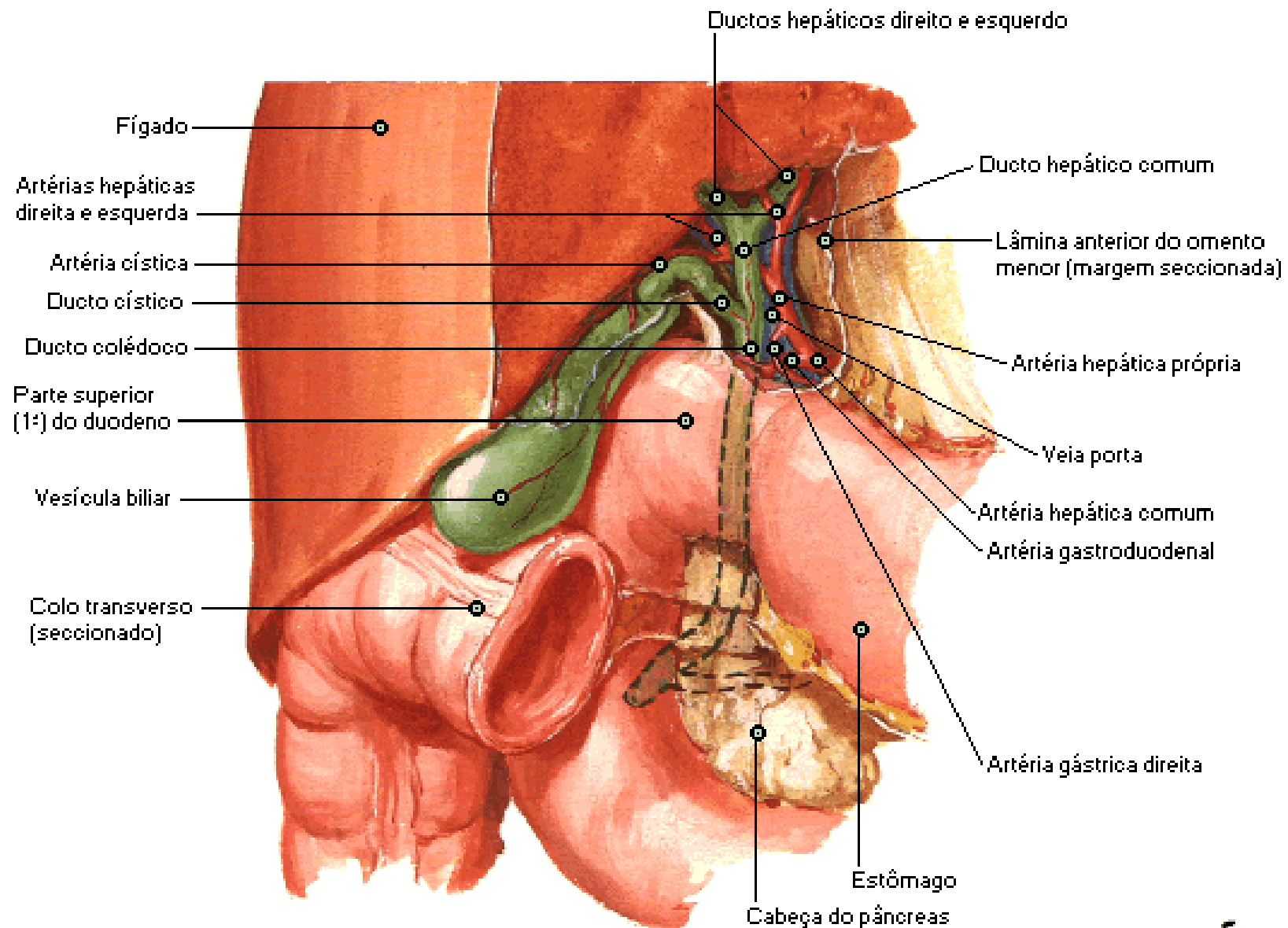
Nota: na ilustração acima, os canalículos biliares aparecem como estruturas com paredes próprias. Entretanto, como mostrado na secção histológica à direita, os limites dos canalículos são na realidade uma especialização das membranas de superfície das células hepáticas parenquimatosas adjacentes.

Sistema Biliar Intra-hepático

Histologia

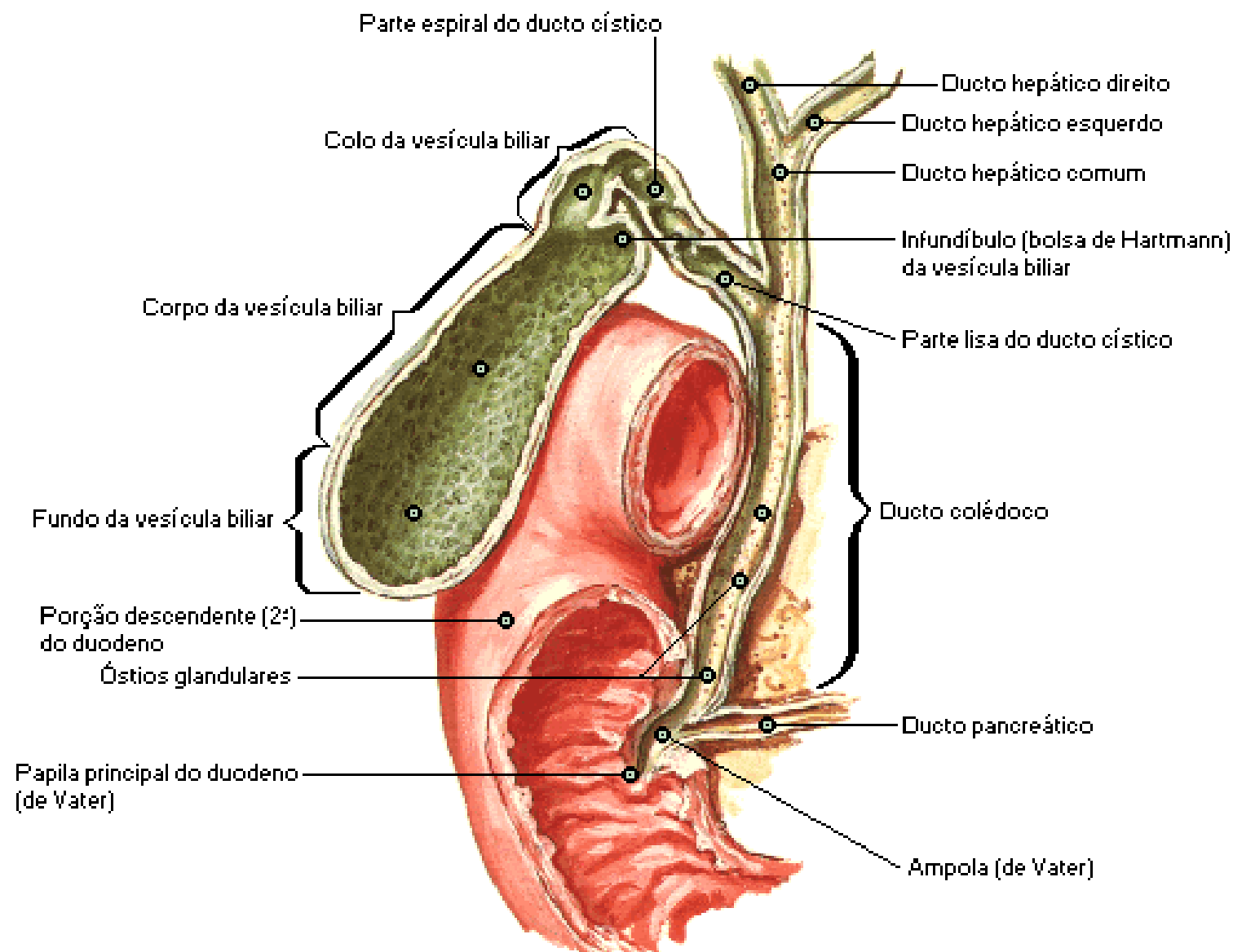


Vesícula Biliar e Ductos Biliares Extra-hepáticos



Vesícula Biliar e Ductos Biliares Extra-hepáticos

Seccionada



Variações no Ducto Cístico

União baixa com o
ducto hepático comum



Aderido ao ducto
hepático comum



União alta com o ducto
hepático comum



Ducto cístico
ausente ou
muito curto



Espiral anterior
unindo-se ao ducto
hepático comum no
lado esquerdo



Espiral posterior
unindo-se ao ducto
hepático comum no
lado esquerdo

Variações em Ductos Hepáticos Acessórios [Aberrantes]

Unindo-se ao ducto
hepático comum



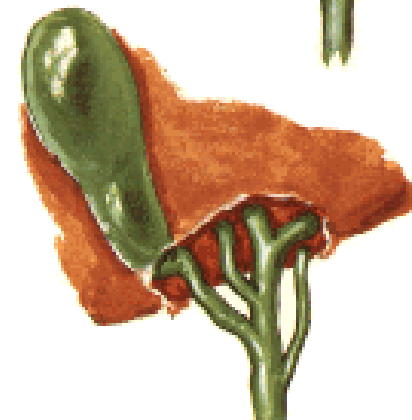
Unindo-se ao
ducto cístico



Unindo-se ao
ducto colédoco

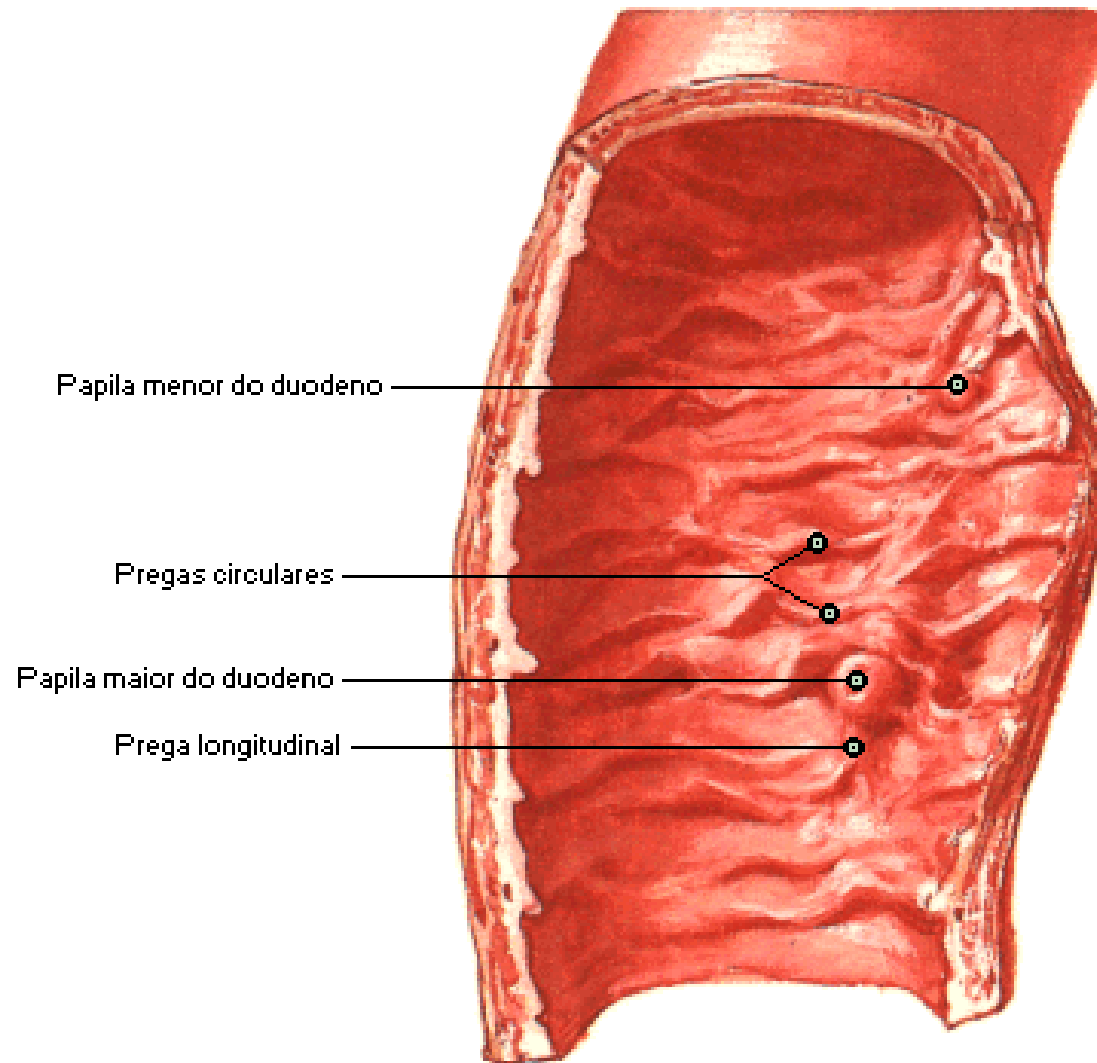


Unindo-se à
vesícula biliar



Dois ductos
hepáticos acessórios

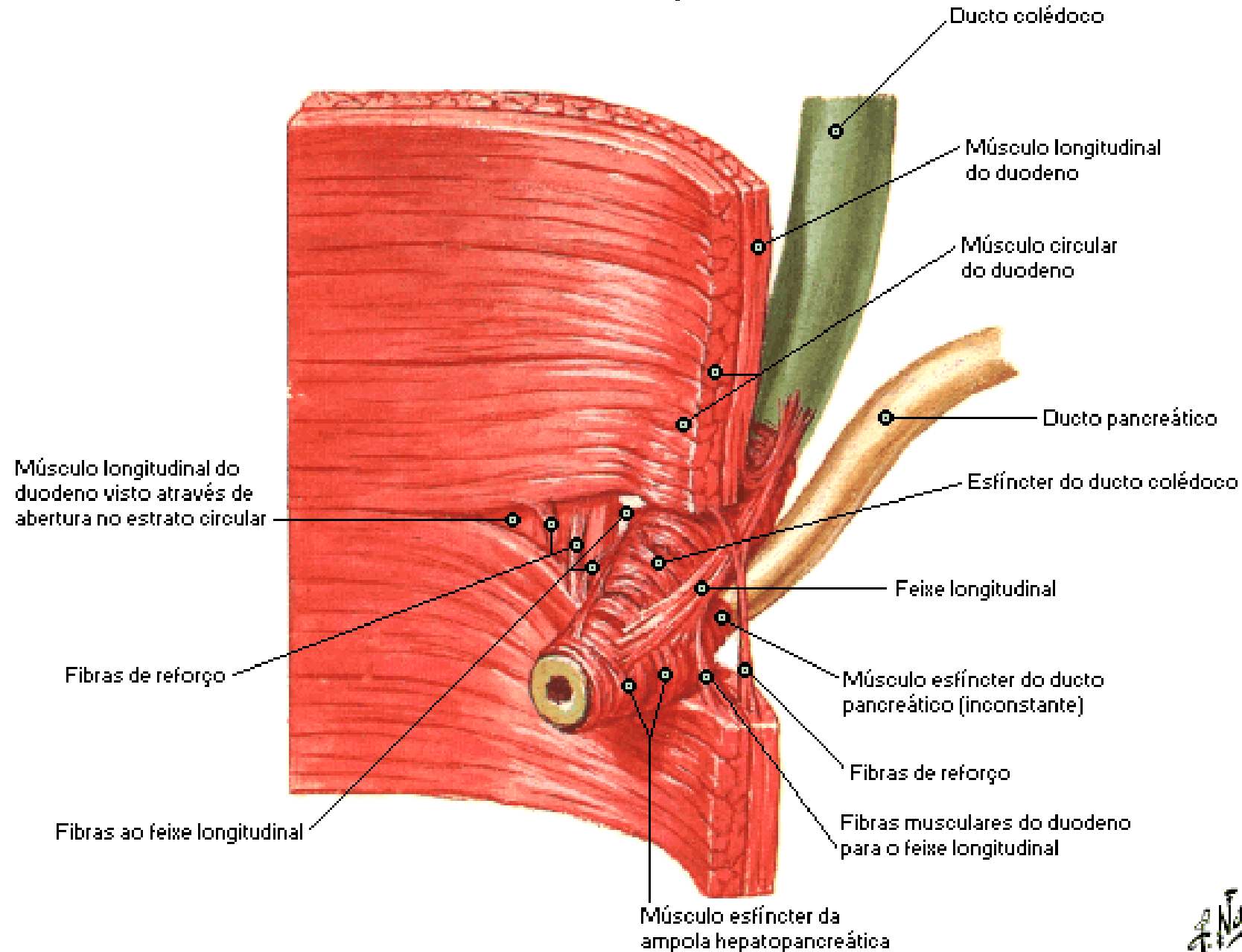
Junção Coledocoduodenal



Interior da parte descendente (2^a) do duodeno

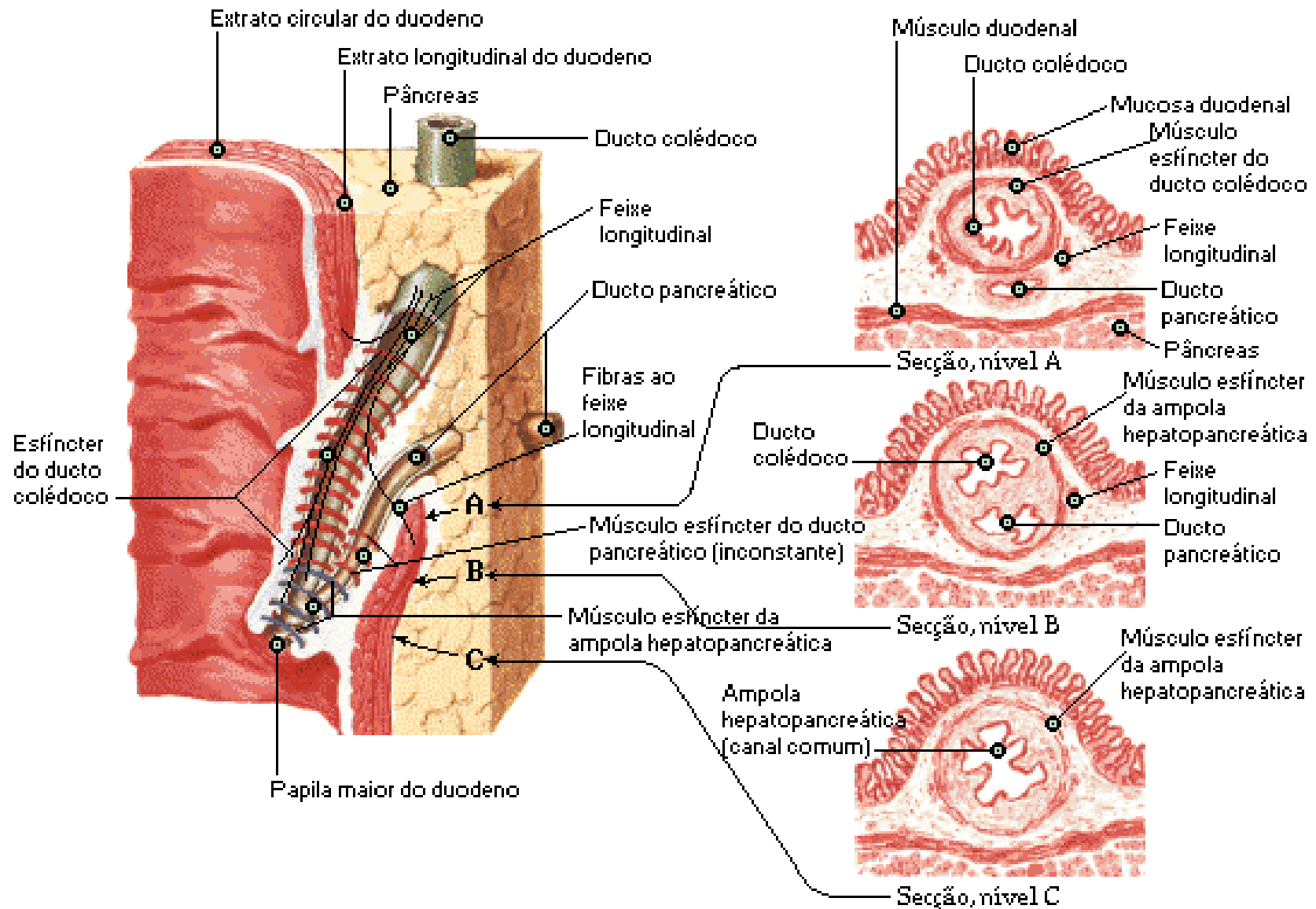
Junção Coledocoduodenal

Dissecação



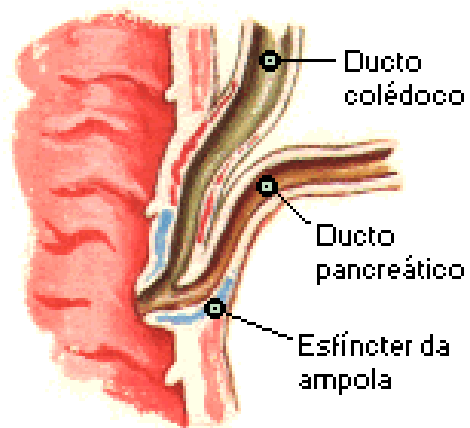
Junção Coledocoduodenal

Reconstrução

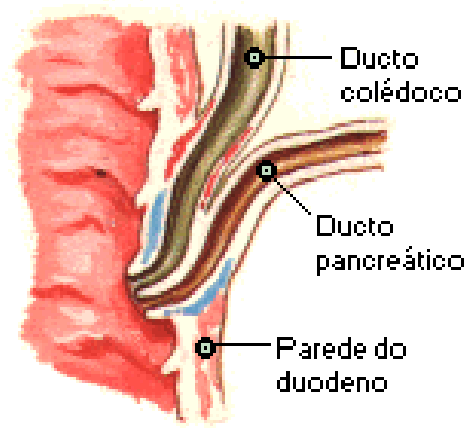


Variações na União dos Ductos Colédoco e Pancreático

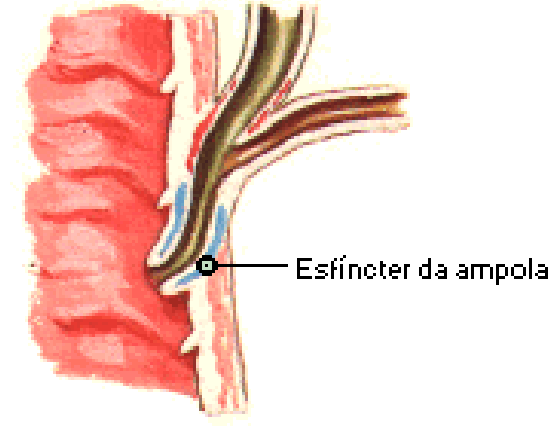
Canal comum curto



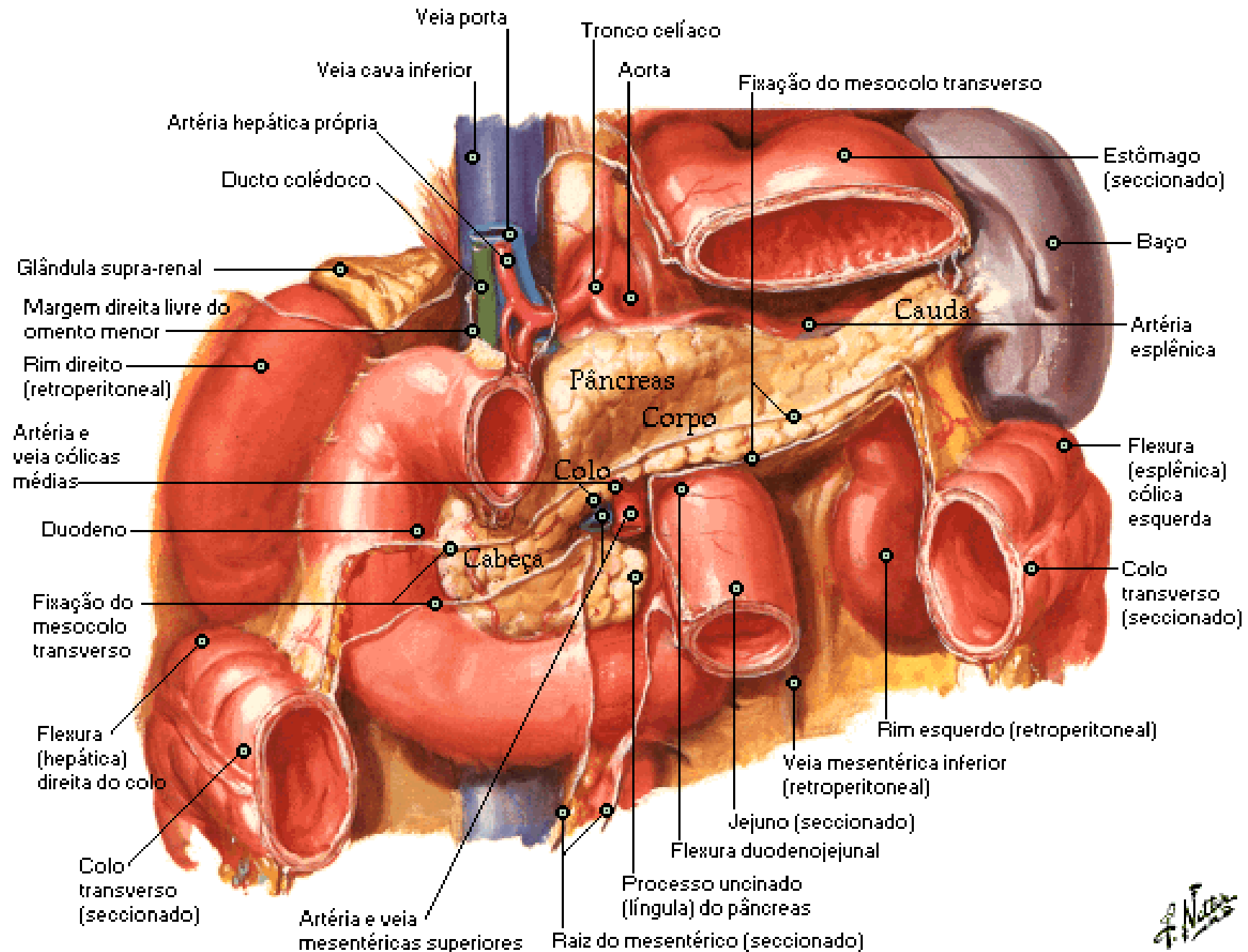
Sem canal comum



Canal comum longo

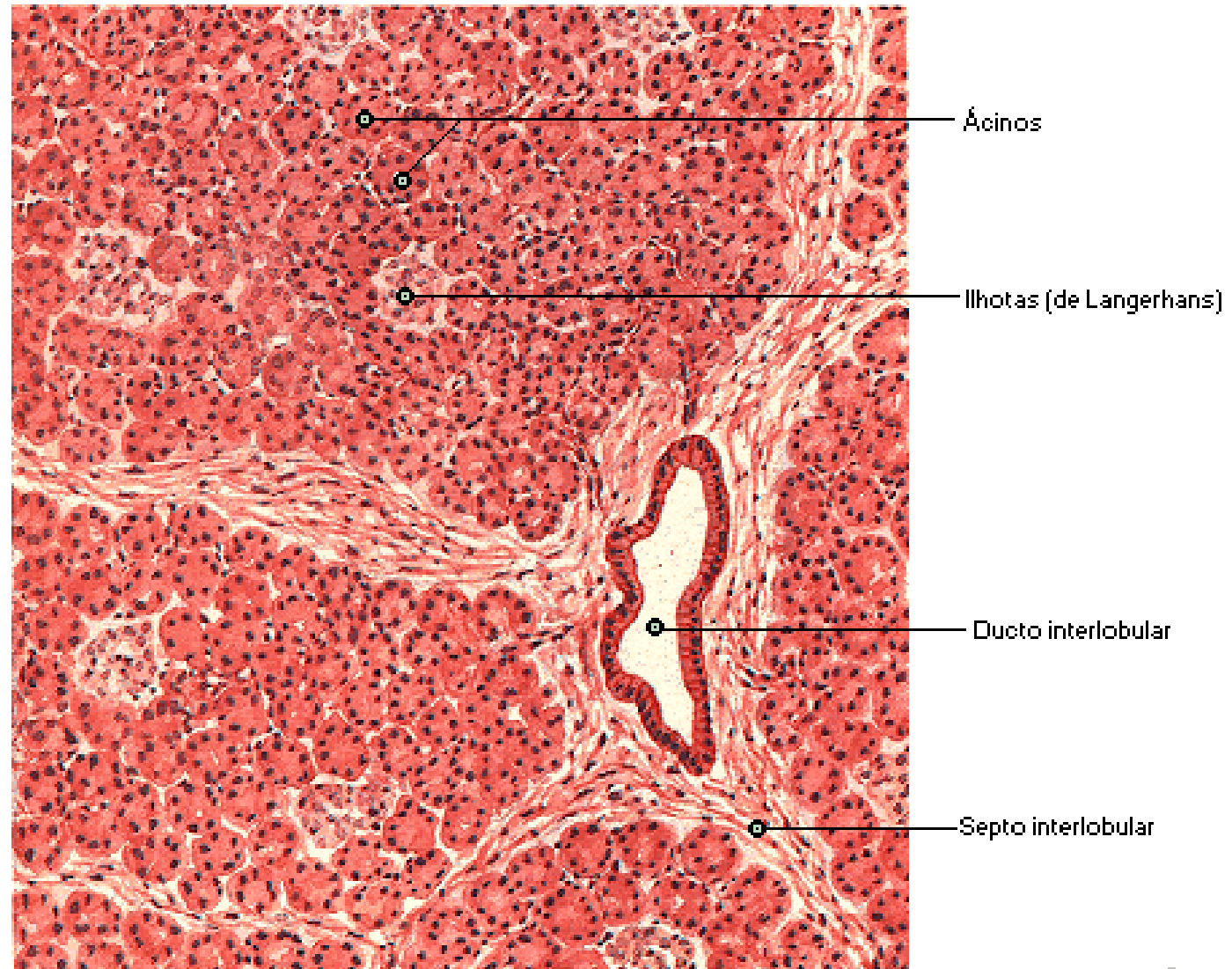


Pâncreas in Situ



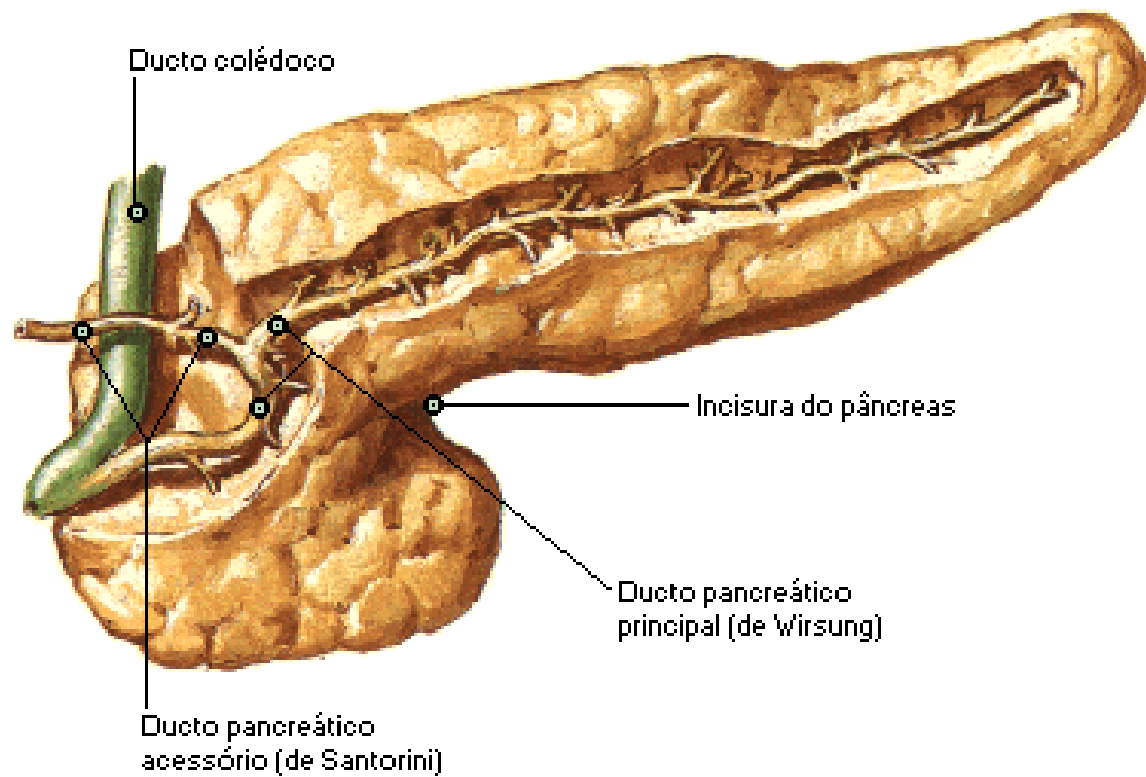
Pâncreas

Histologia



Secção do pâncreas com pequeno aumento

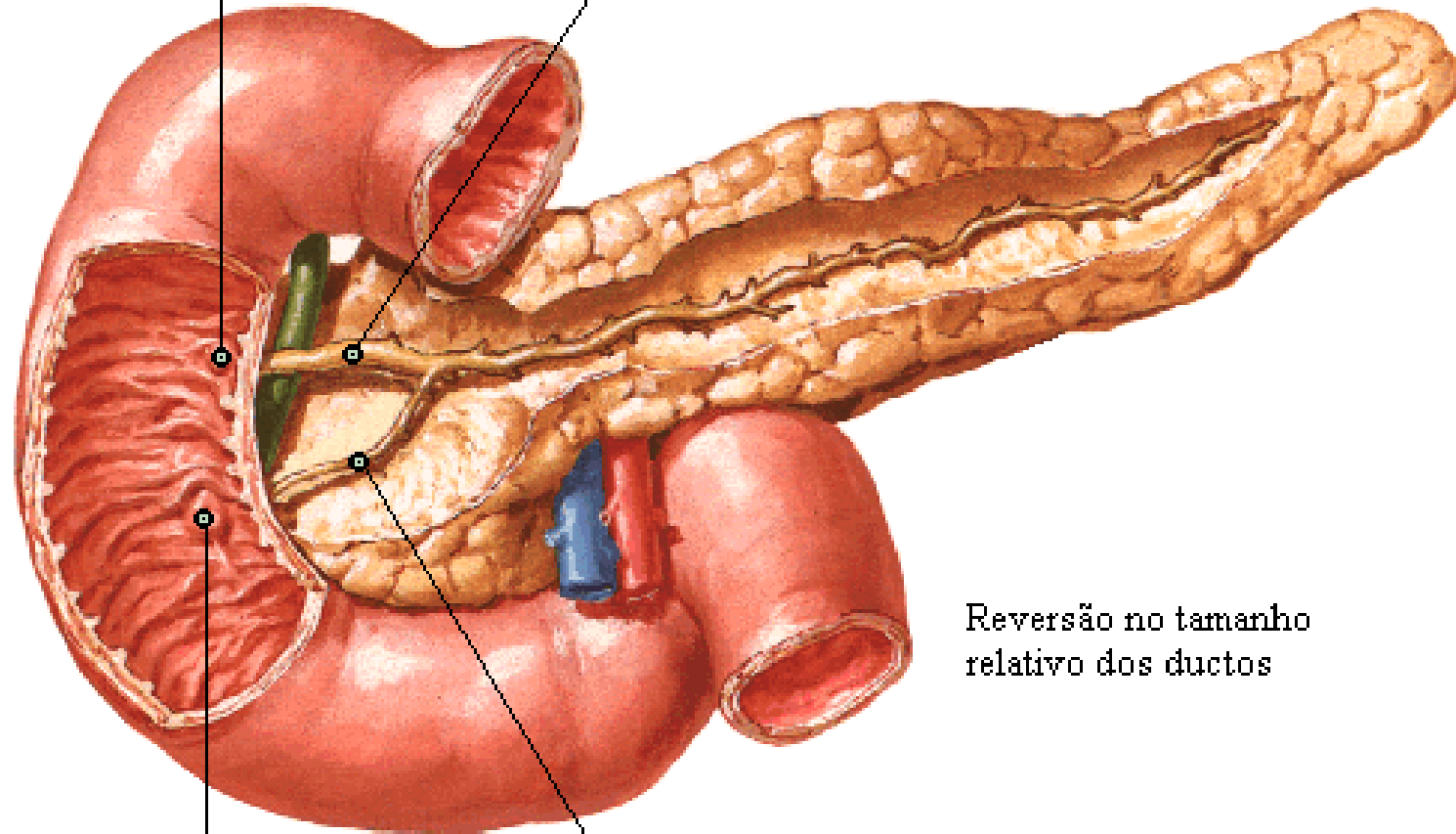
Pâncreas



Variações nos Ductos Pancreáticos

Papila menor do duodeno

Ducto acessório (de Santorini) anormalmente aumentado

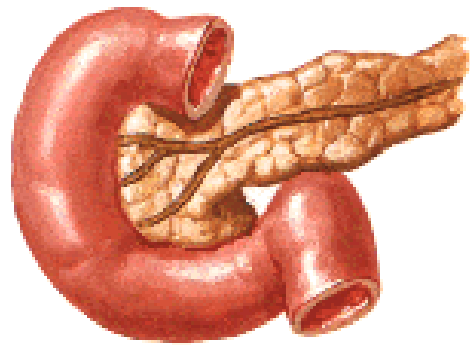


Papila maior do duodeno

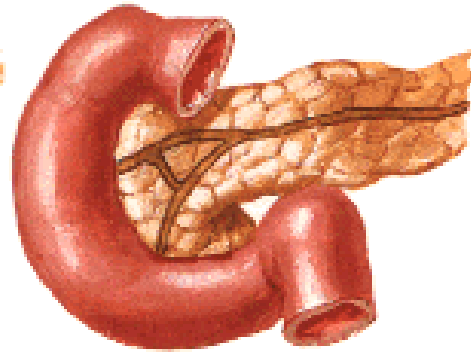
Ducto principal (de Wirsung) anormalmente diminuído

Reversão no tamanho relativo dos ductos

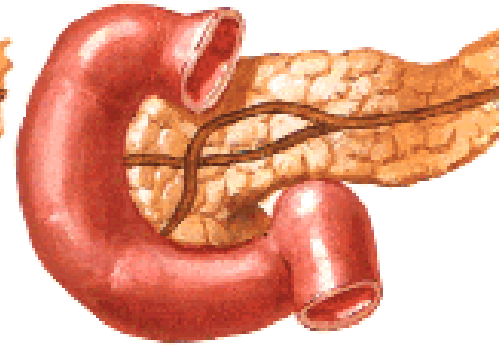
Variações nos Ductos Pancreáticos



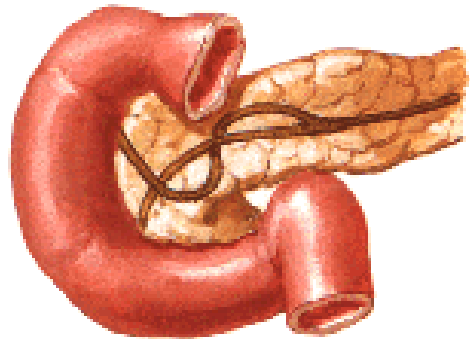
Ducto acessório (de Santorini) duplo



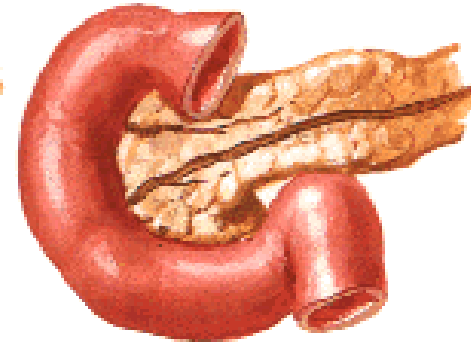
Anastomose entre ductos



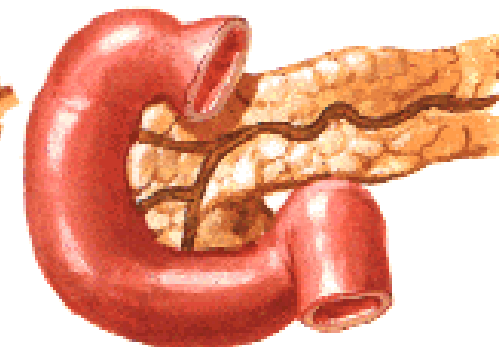
Cruzamento dos ductos



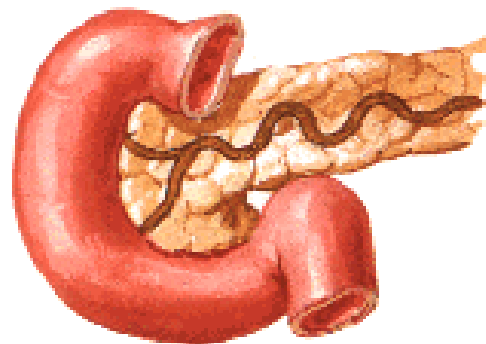
Cruzamento duplo dos ductos



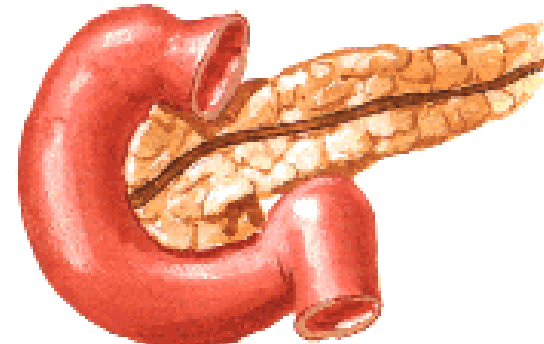
Sem comunicação entre os ductos



Ducto principal (de Wirsung) duplo



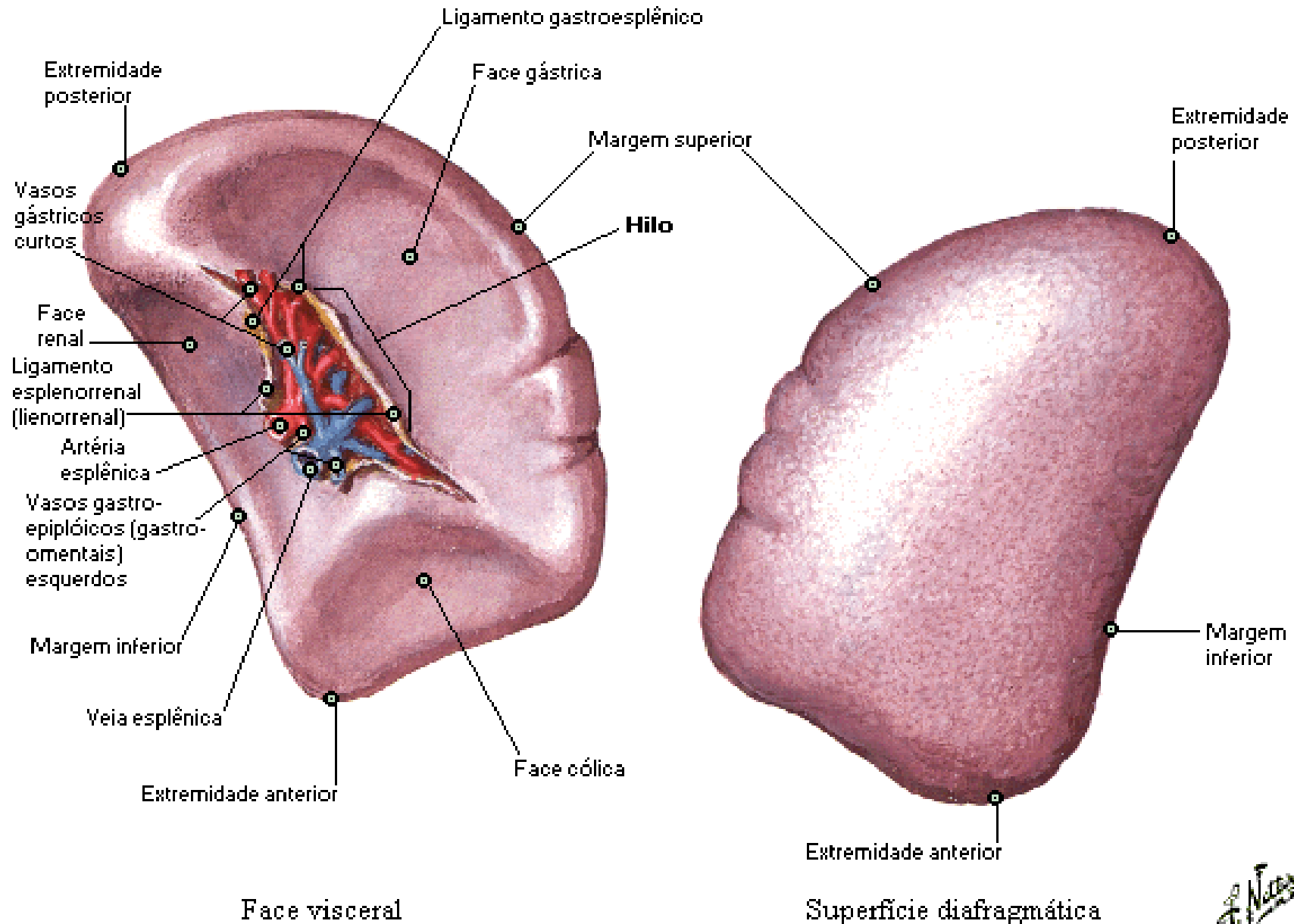
Tortuosidade dos ductos



Ausência do ducto acessório (de Santorini)

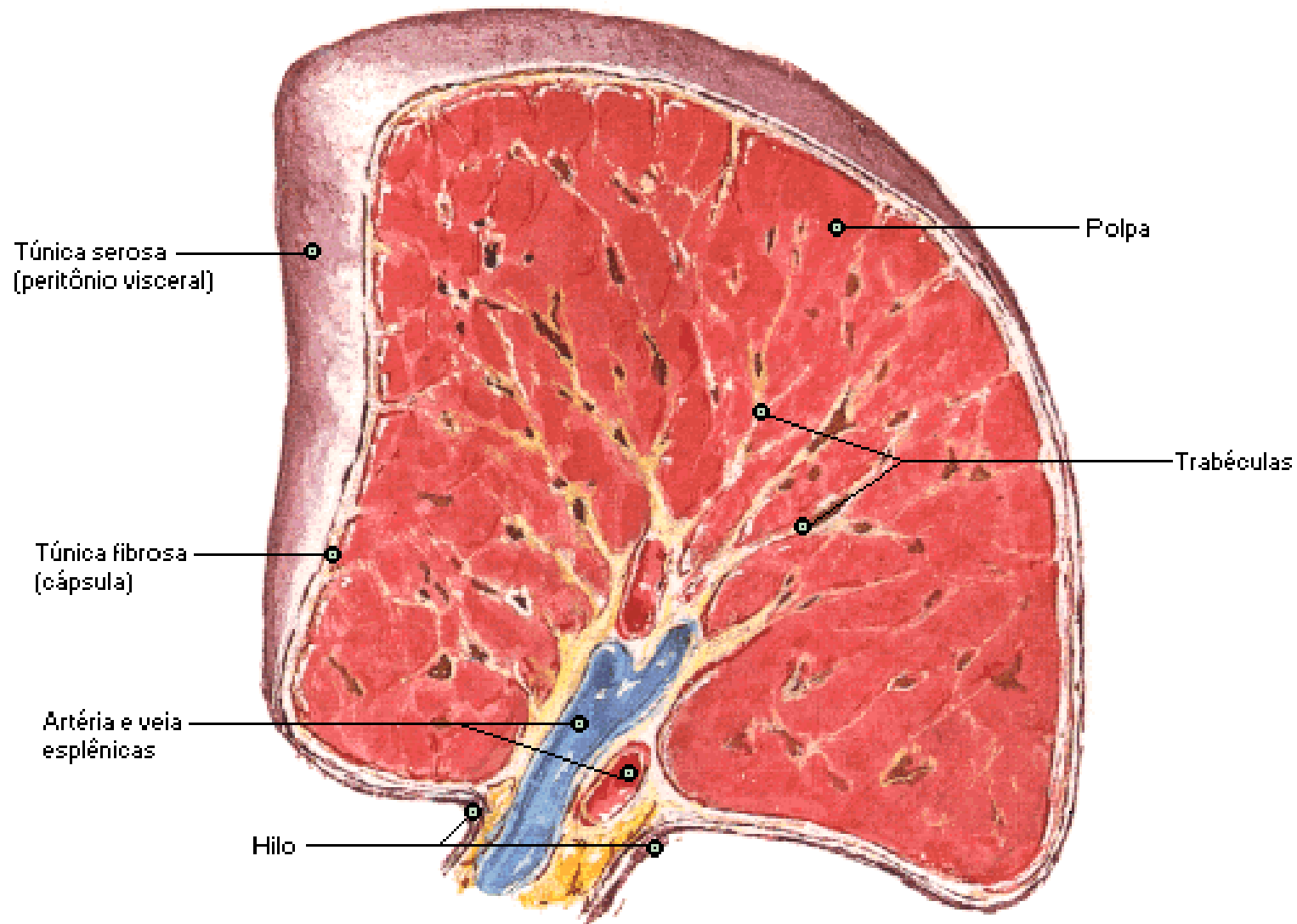
Baço

Faces Visceral e Diafragmática

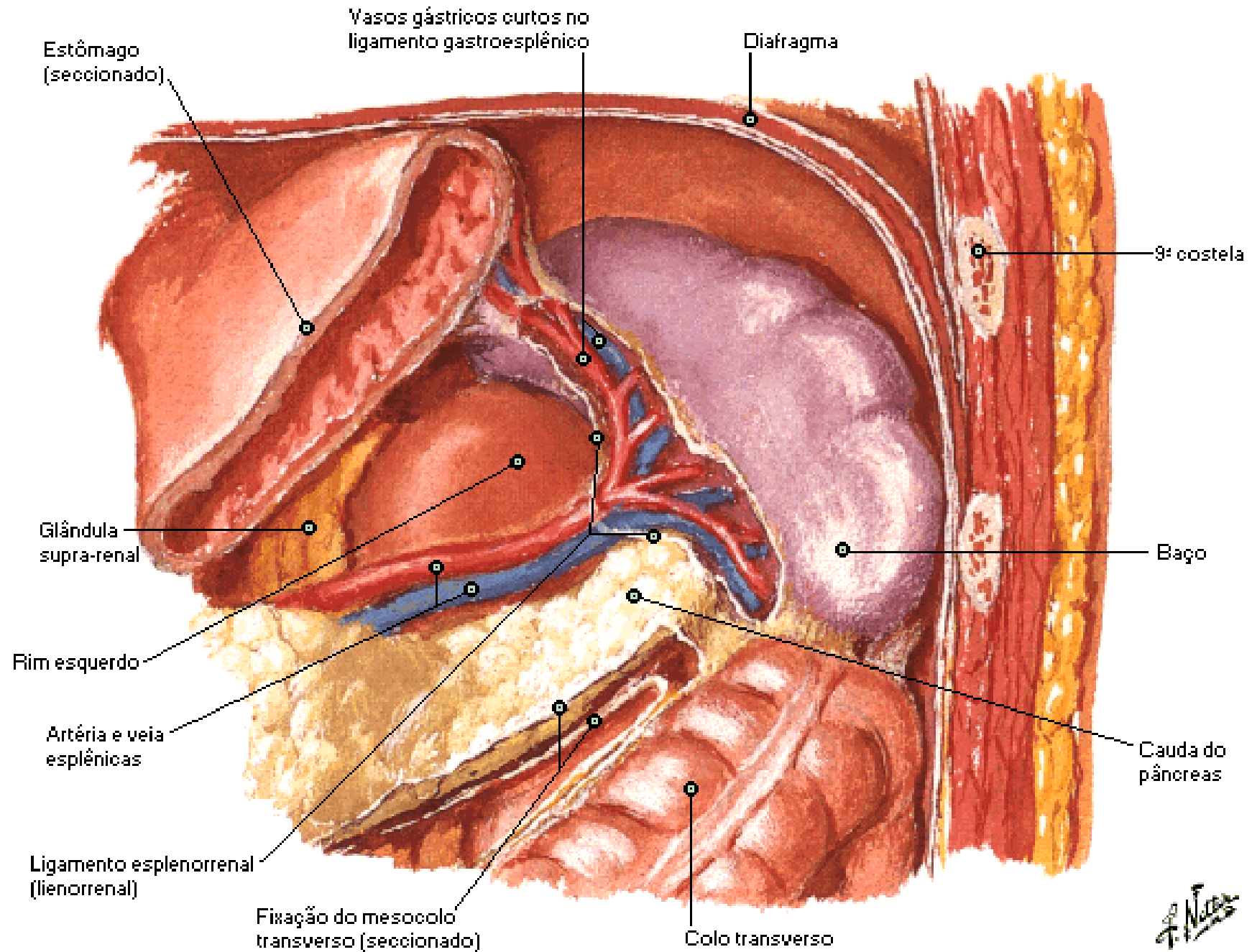


Baço

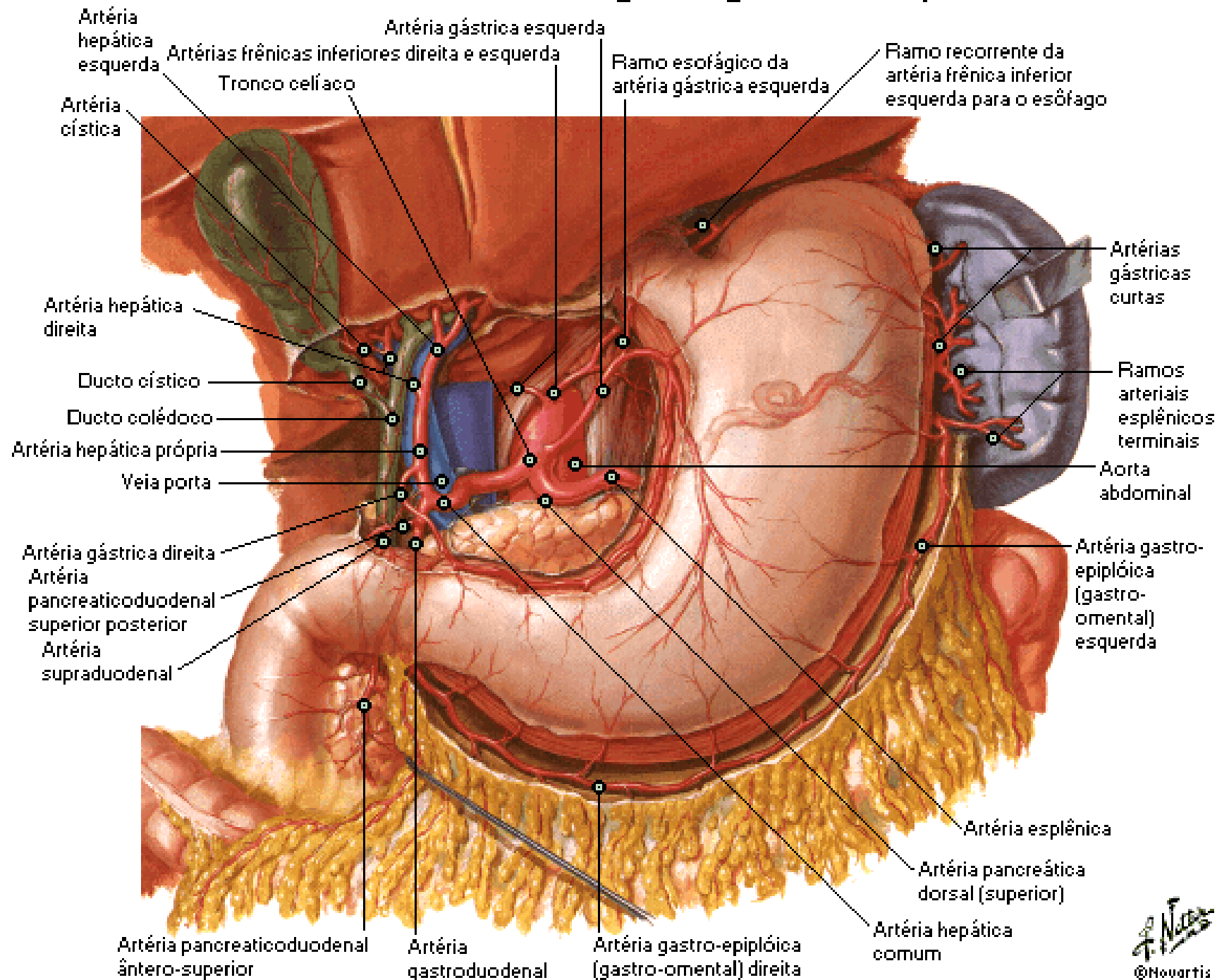
Secção Transversal



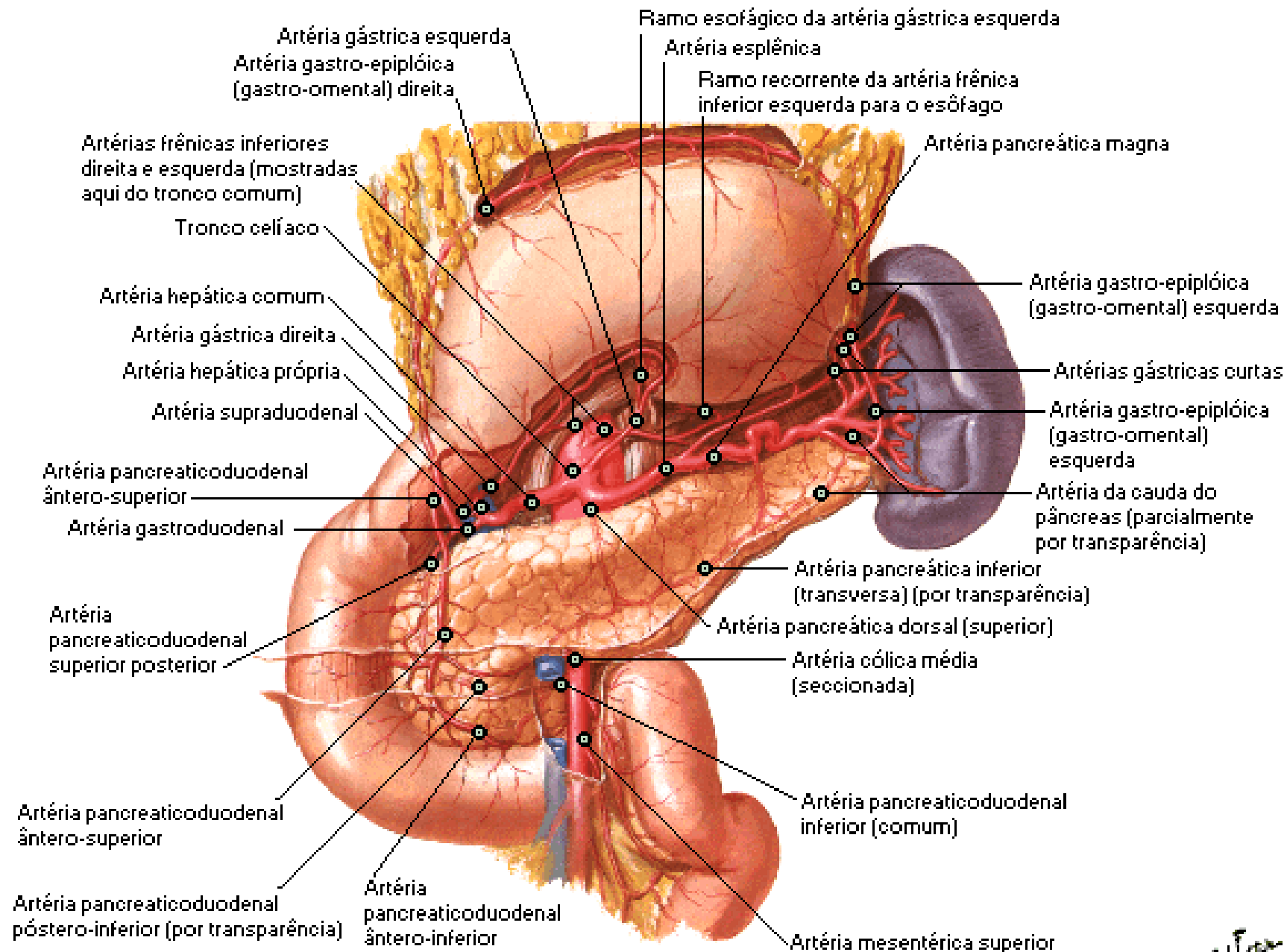
Baço in Situ



Artérias do Estômago, Fígado e Baço

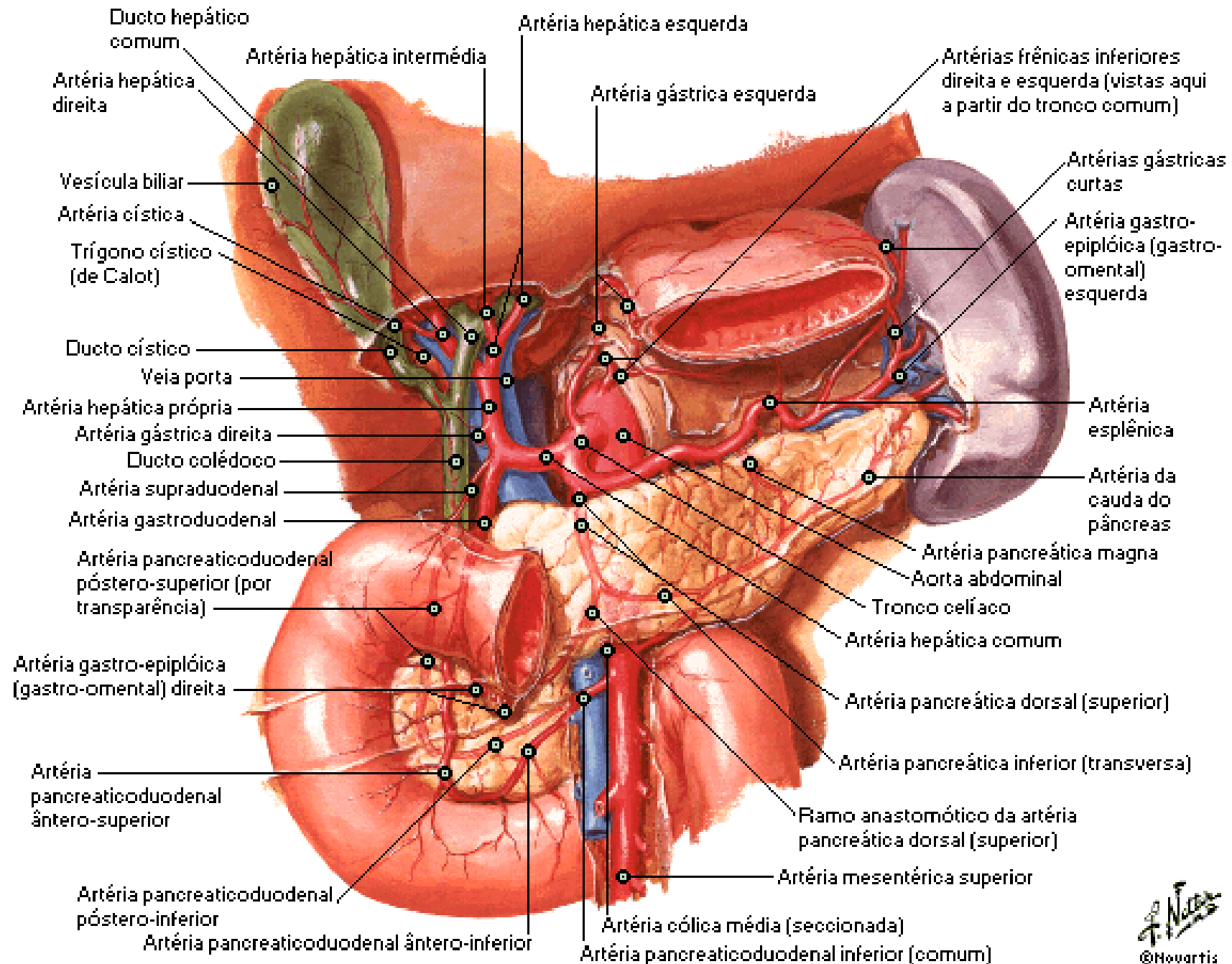


Artérias do Estômago, Duodeno, Pâncreas e Baço



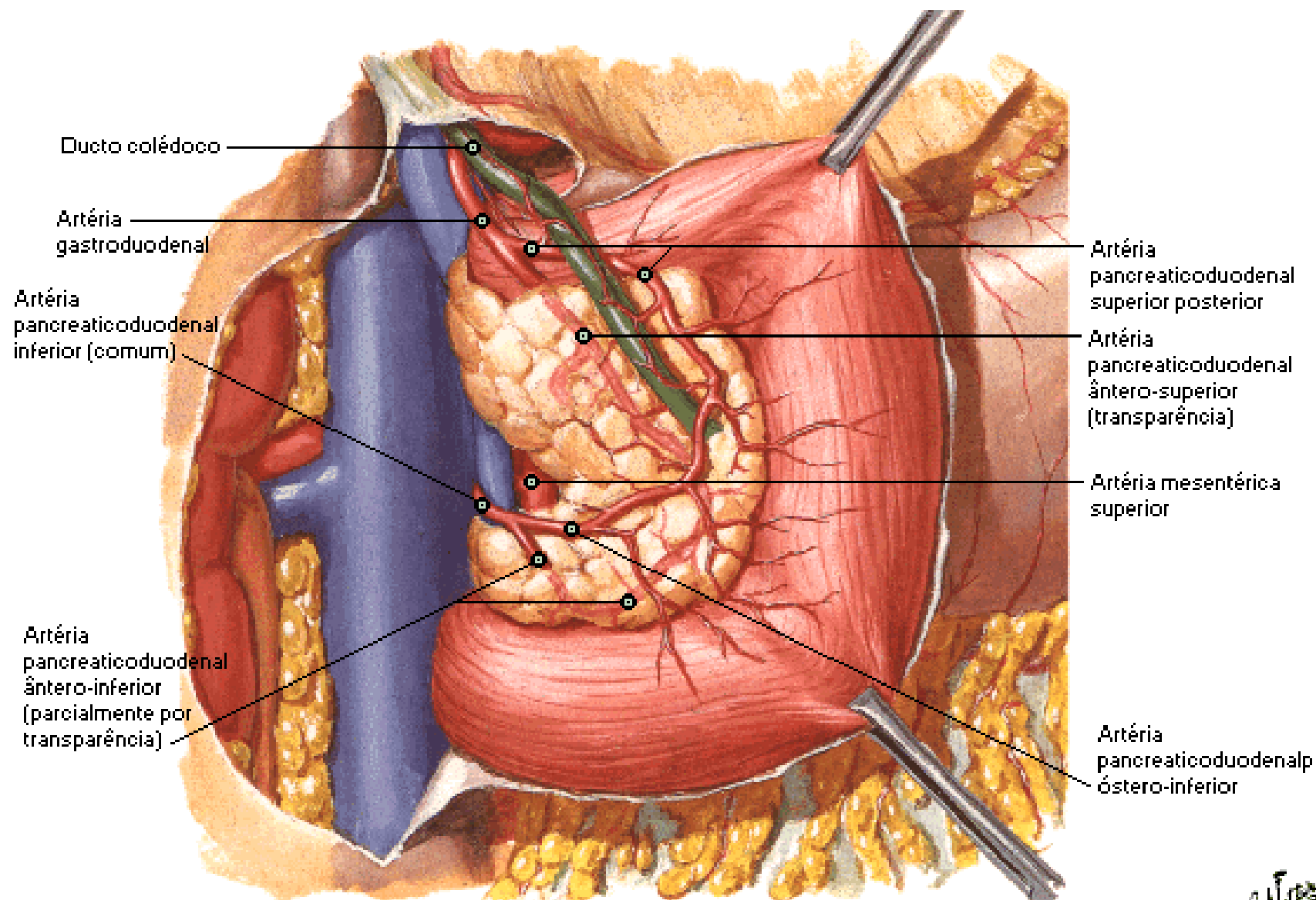
Vista com o estômago rebatido superiormente

Artérias do Fígado, Pâncreas, Duodeno e Baço



Artérias do Duodeno e Cabeça do Pâncreas

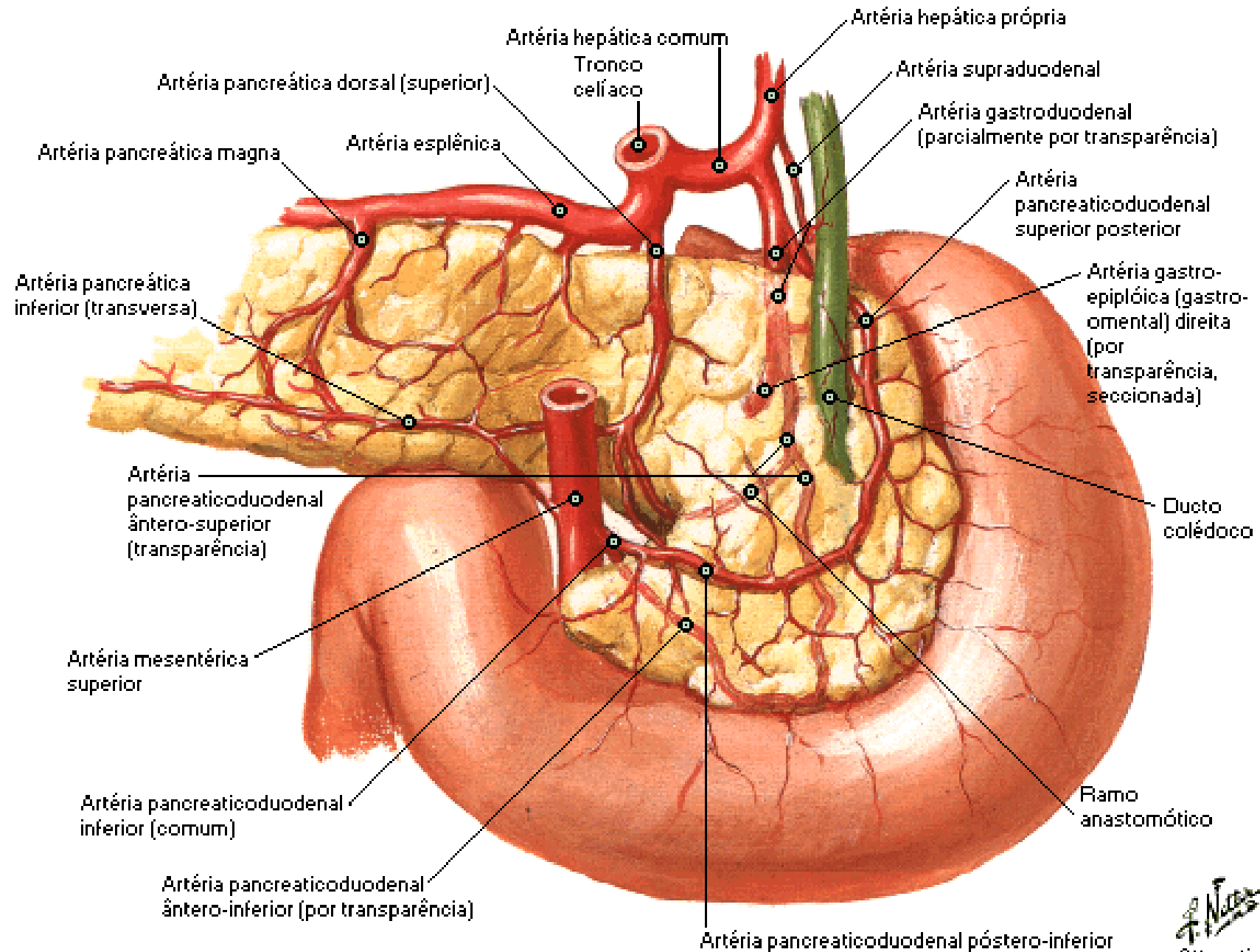
Rebatidos para a Esquerda



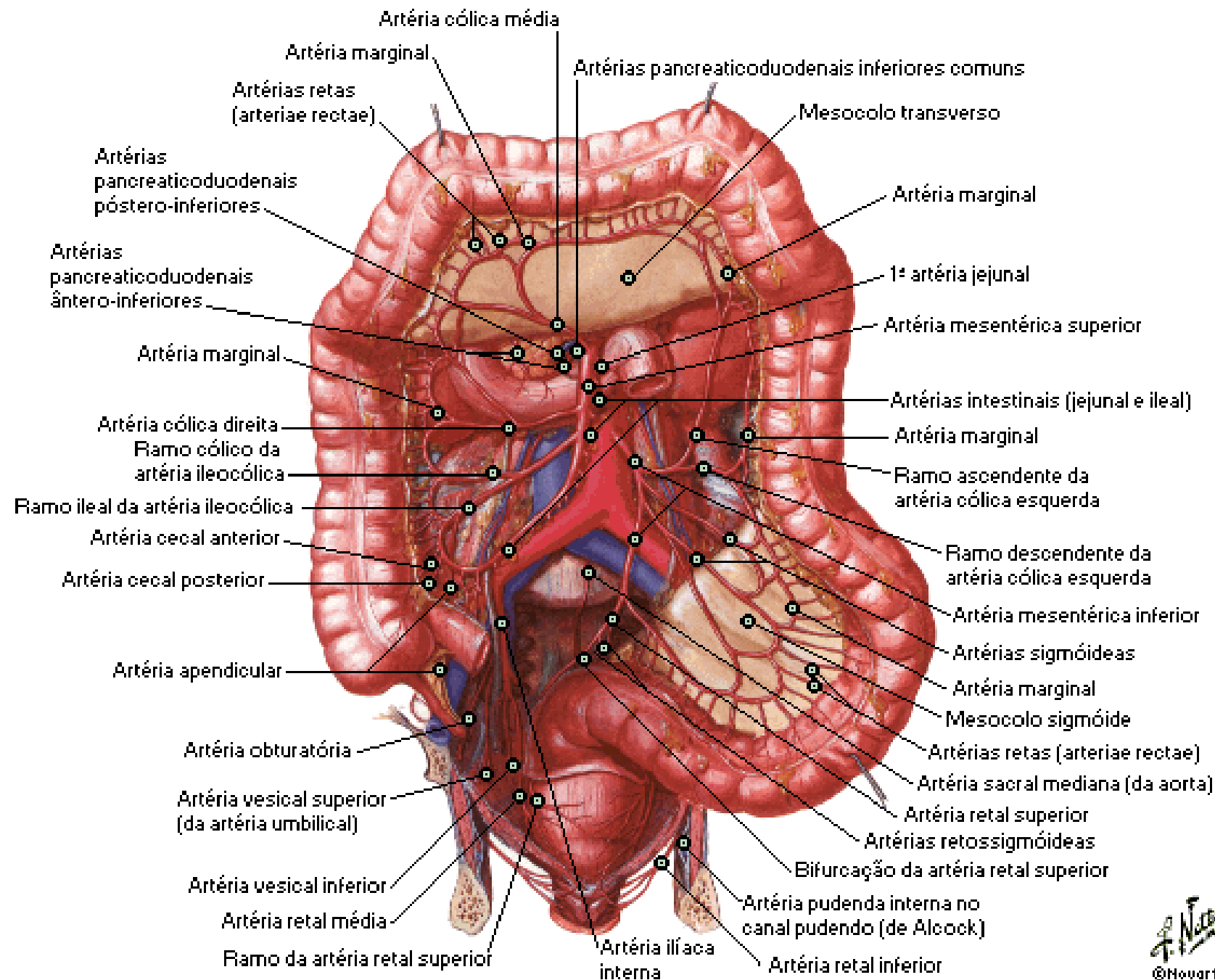
Duodeno e cabeça do pâncreas rebatidos para a esquerda

Artérias do Duodeno e Cabeça do Pâncreas

Vista Posterior

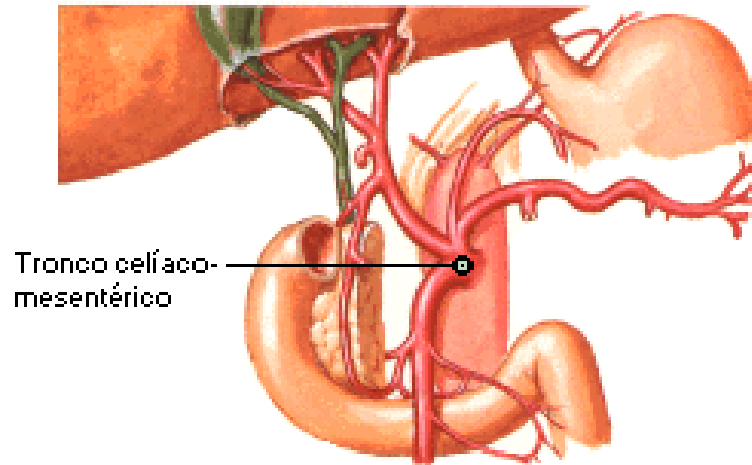


Artérias do Intestino Grosso

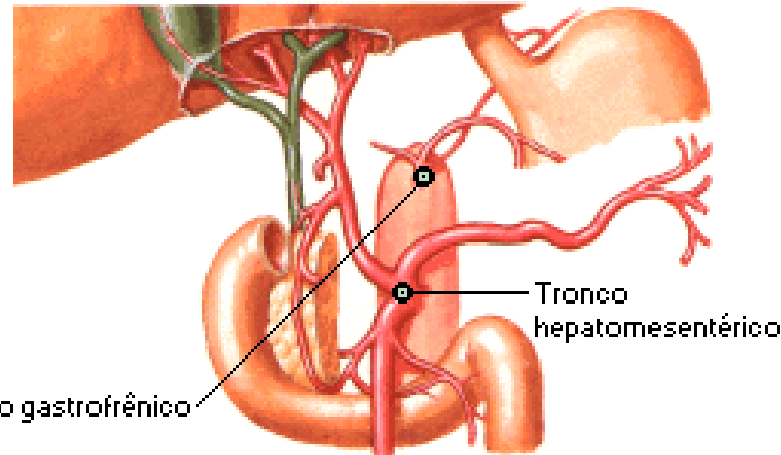
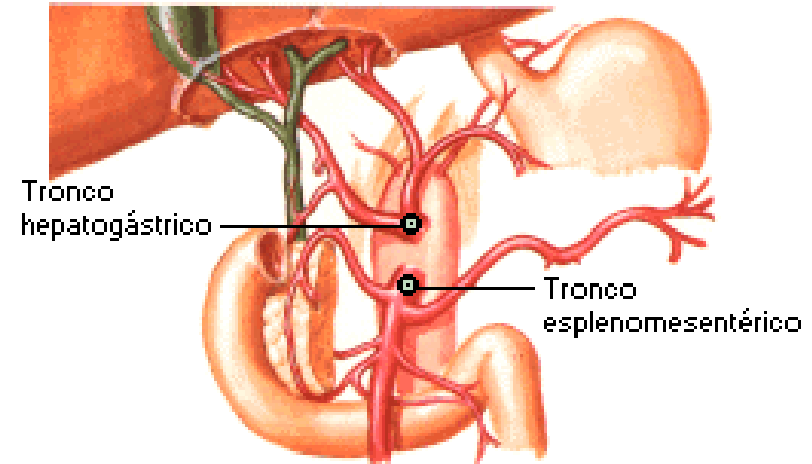


Variações do Tronco Celíaco

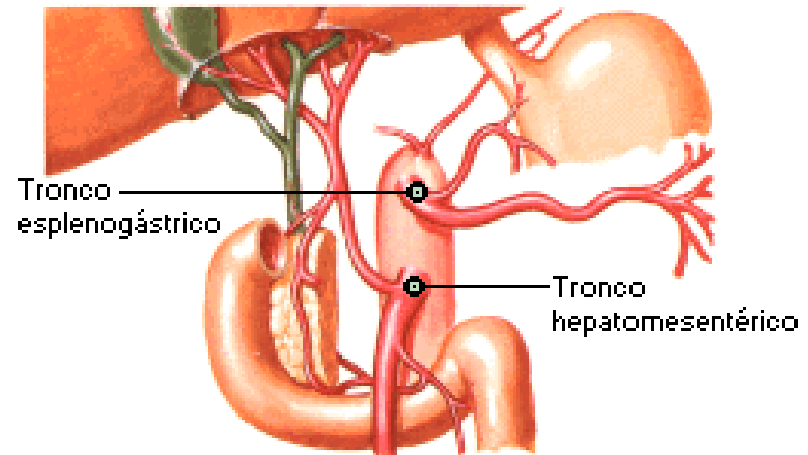
Origem comum do tronco celíaco e
artéria mesentérica superior



Artéria esplênica origina-se da mesentérica superior (notar a artéria hepática esquerda recolocada da gástrica esquerda)



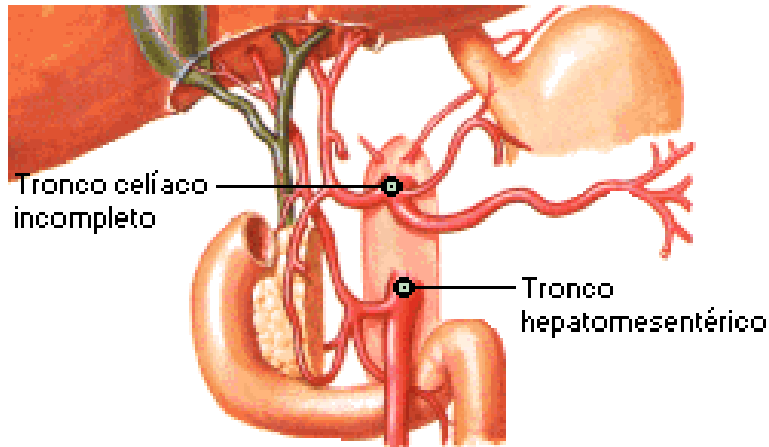
Artérias esplênica e hepática comum
originam-se da mesentérica superior



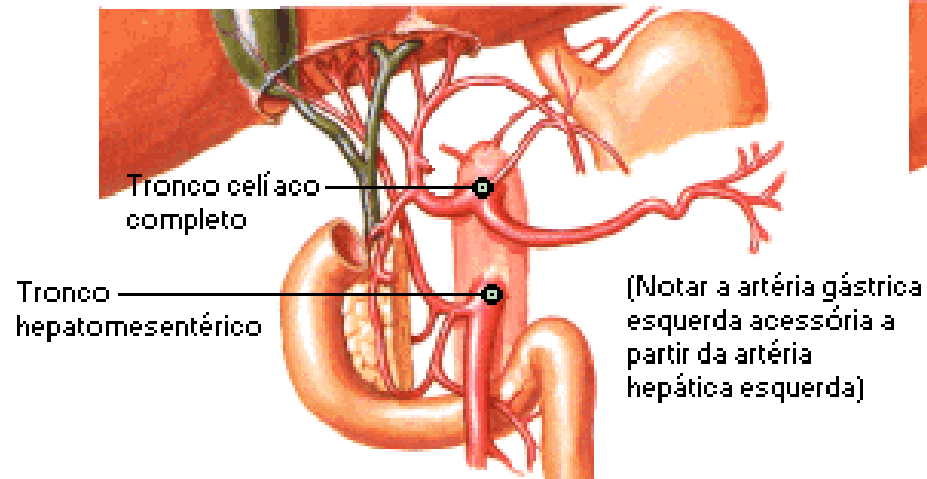
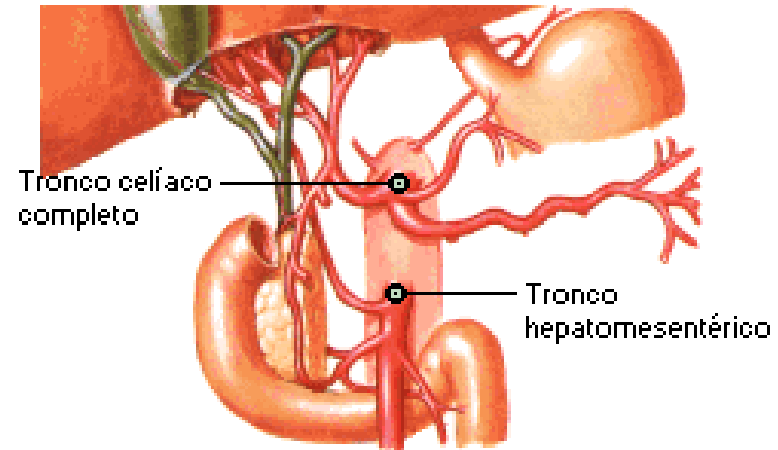
Artéria hepática comum origina-se da mesentérica superior (notar a artéria pancreatoduodenal inferior a partir da 1ª jejunal)

Variações do Tronco Celíaco [Continuação]

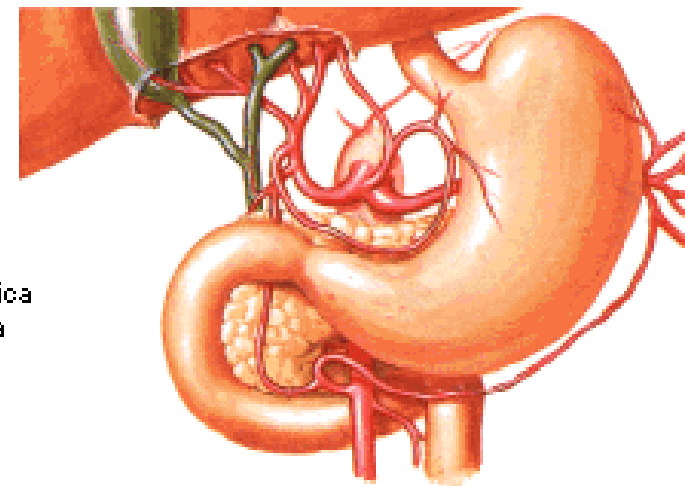
Artéria hepática direita recolocada origina-se da mesentérica superior; as artérias pancreaticoduodenal inferior e 1ª jejunal originam-se da artéria hepática direita



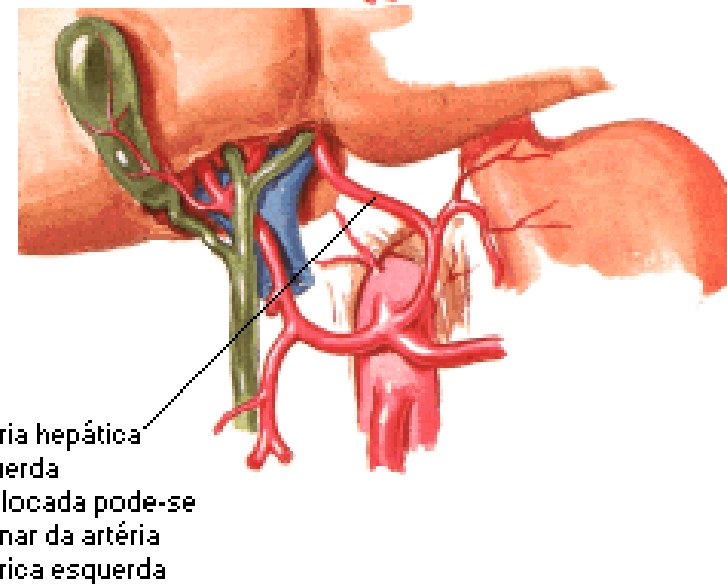
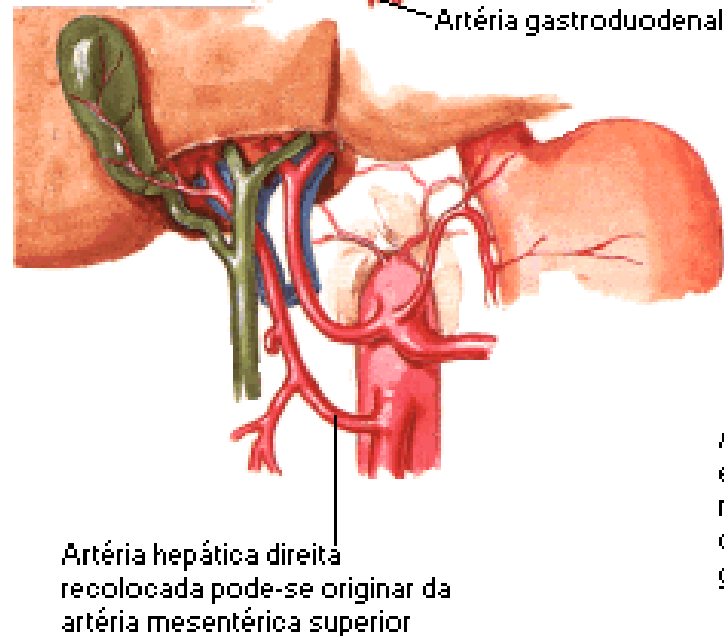
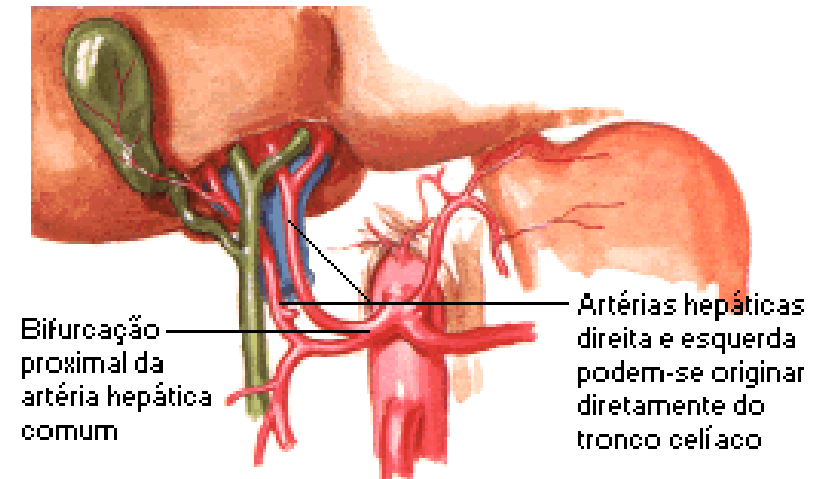
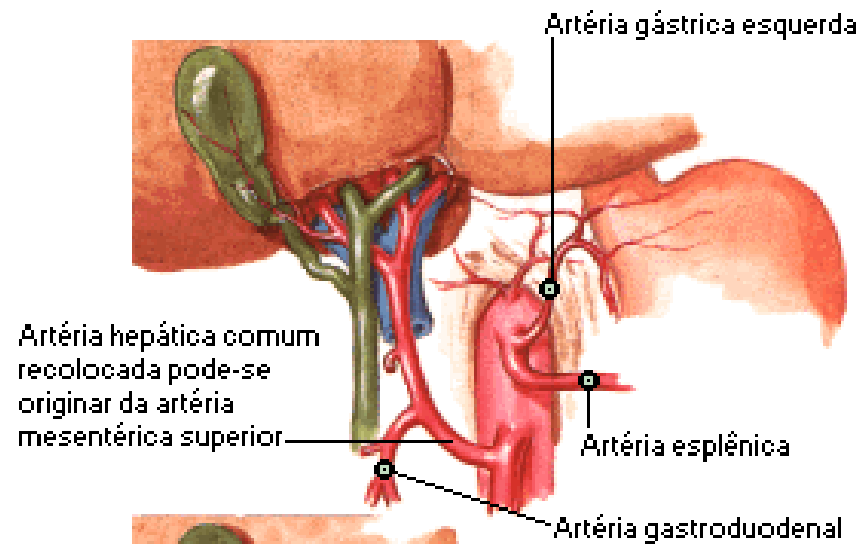
Artéria hepática direita acessória origina-se da artéria mesentérica superior



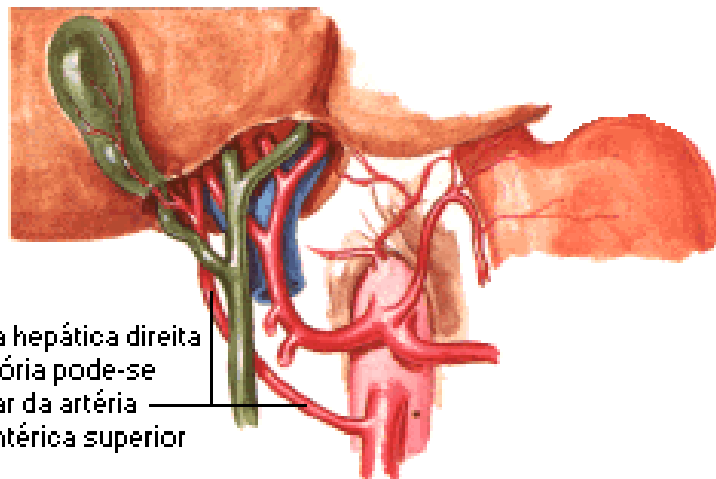
Artéria hepática direita acessória origina-se da mesentérica superior; artérias pancreaticoduodenais inferiores, da hepática direita acessória; a 1ª jejunal, da pancreaticoduodenal inferior anterior



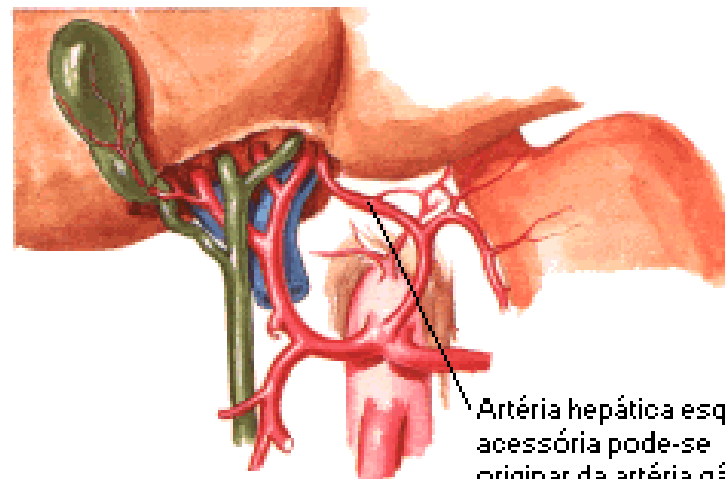
Variações nas Artérias Hepáticas



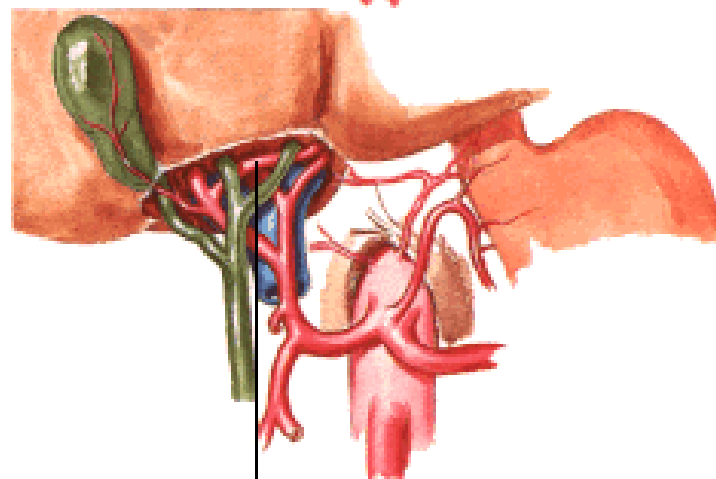
Variações nas Artérias Hepáticas [Continuação]



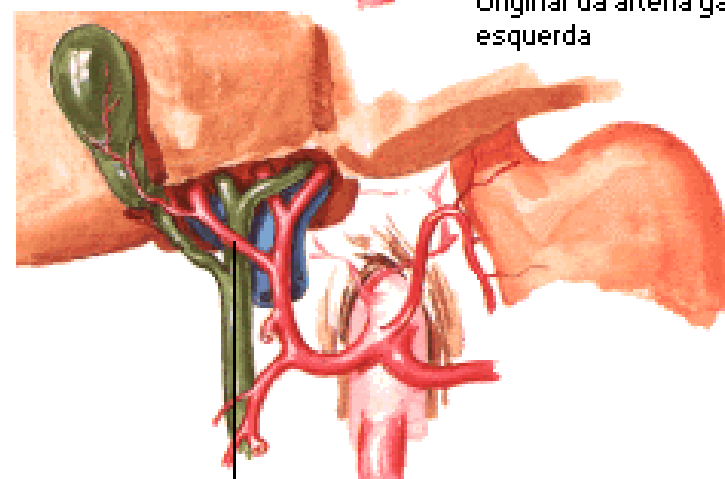Artéria hepática direita
acessória pode-se
originar da artéria
mesentérica superior



Artéria hepática esquerda
acessória pode-se
originar da artéria gástrica
esquerda



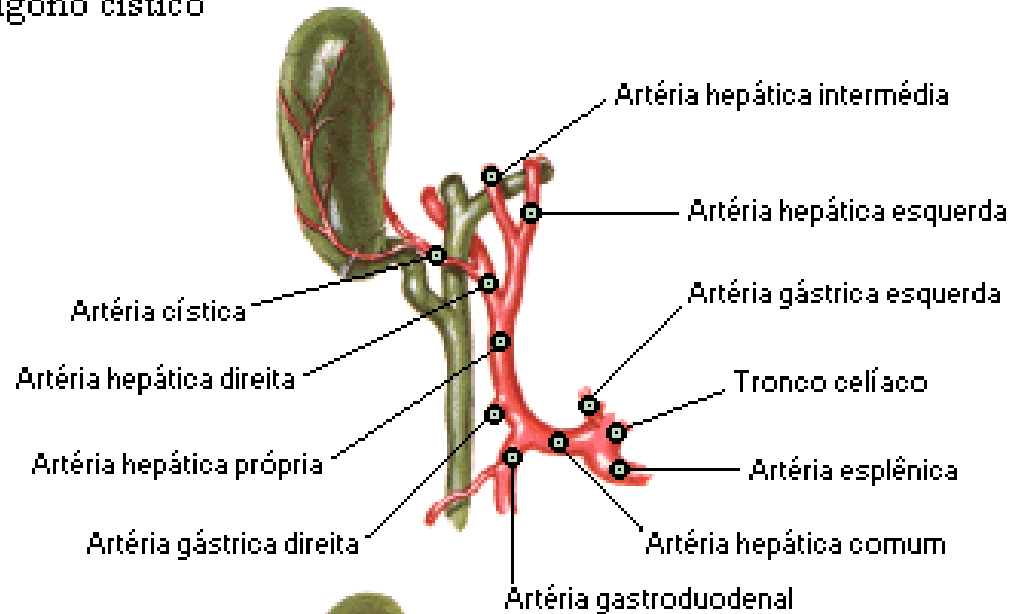
Artéria hepática esquerda
acessória pode-se originar
da artéria hepática direita



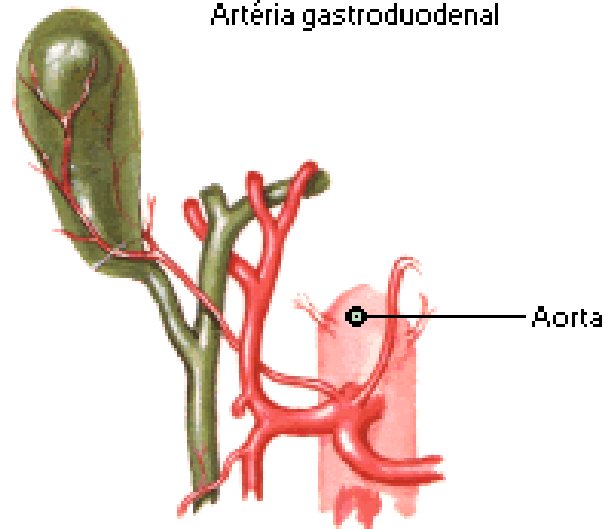
Artéria hepática direita pode
cruzar ao invés de posteriormente
ao ducto hepático comum

Variações na Artéria Cística 1

Pode originar-se da hepática direita normal fora do trígono cístico



Pode originar-se do tronco celíaco (ou da aorta)

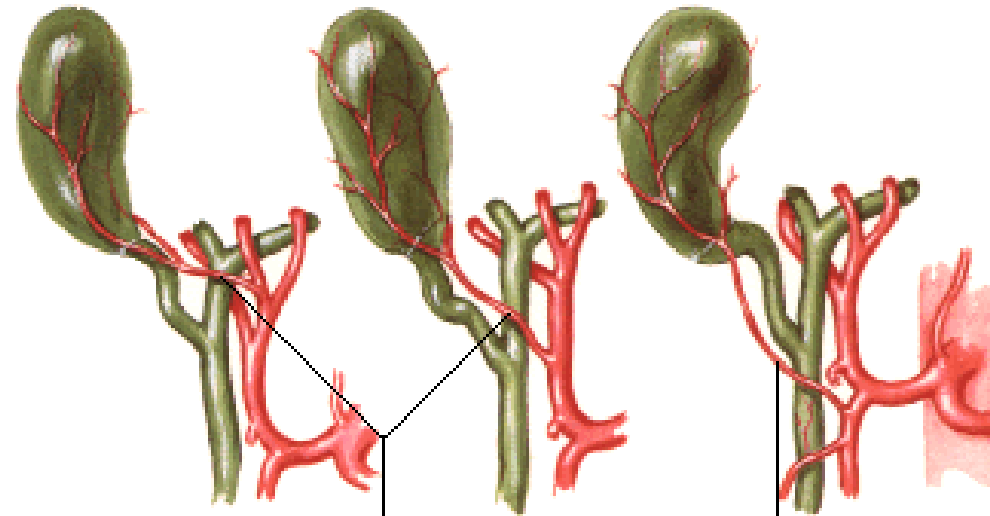


Variações na Artéria Cística 2

Pode originar-se da
hepática intermédia
(ou esquerda)

Pode originar-se da
hepática própria

Pode originar-se da
gastroduodenal

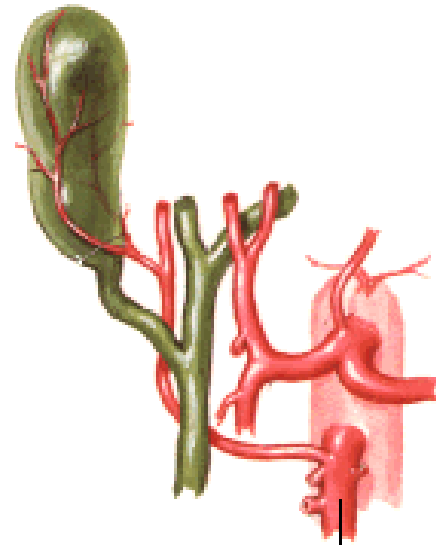


Pode cruzar anteriormente
ao ducto colédoco

Pode cruzar anteriormente
ao ducto hepático comum

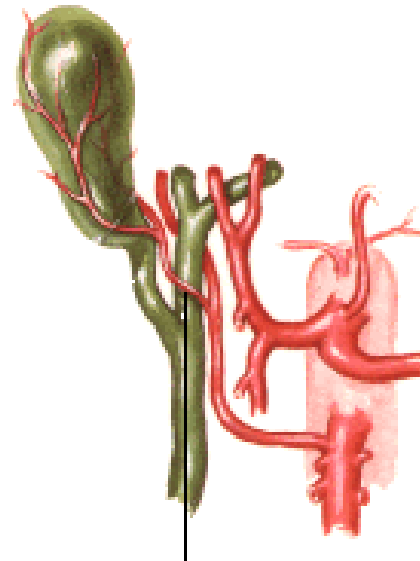
Variações na Artéria Cística 3

Pode originar-se no trígono cístico a partir de uma hepática direita acessória (da mesentérica superior)



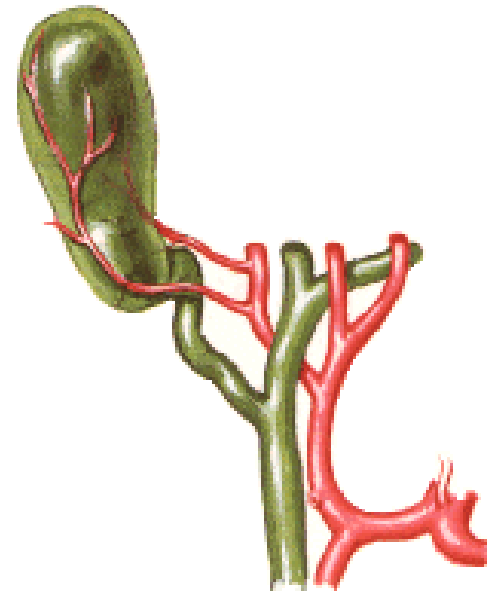
Artéria mesentérica superior

Pode originar-se fora do trígono cístico de uma hepática direita acessória



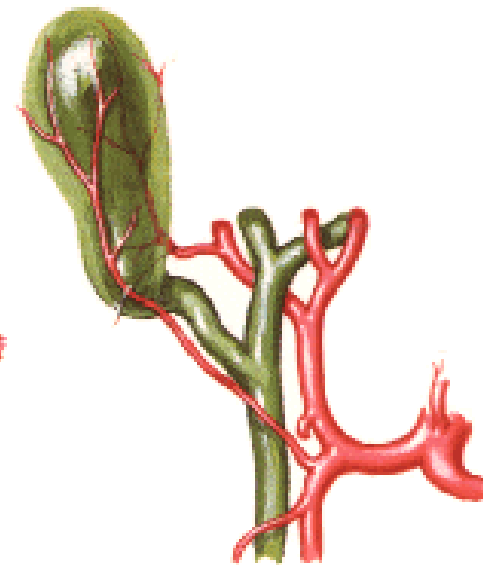
Pode cruzar anteriormente ao ducto colédoco

Variações na Artéria Cística 4

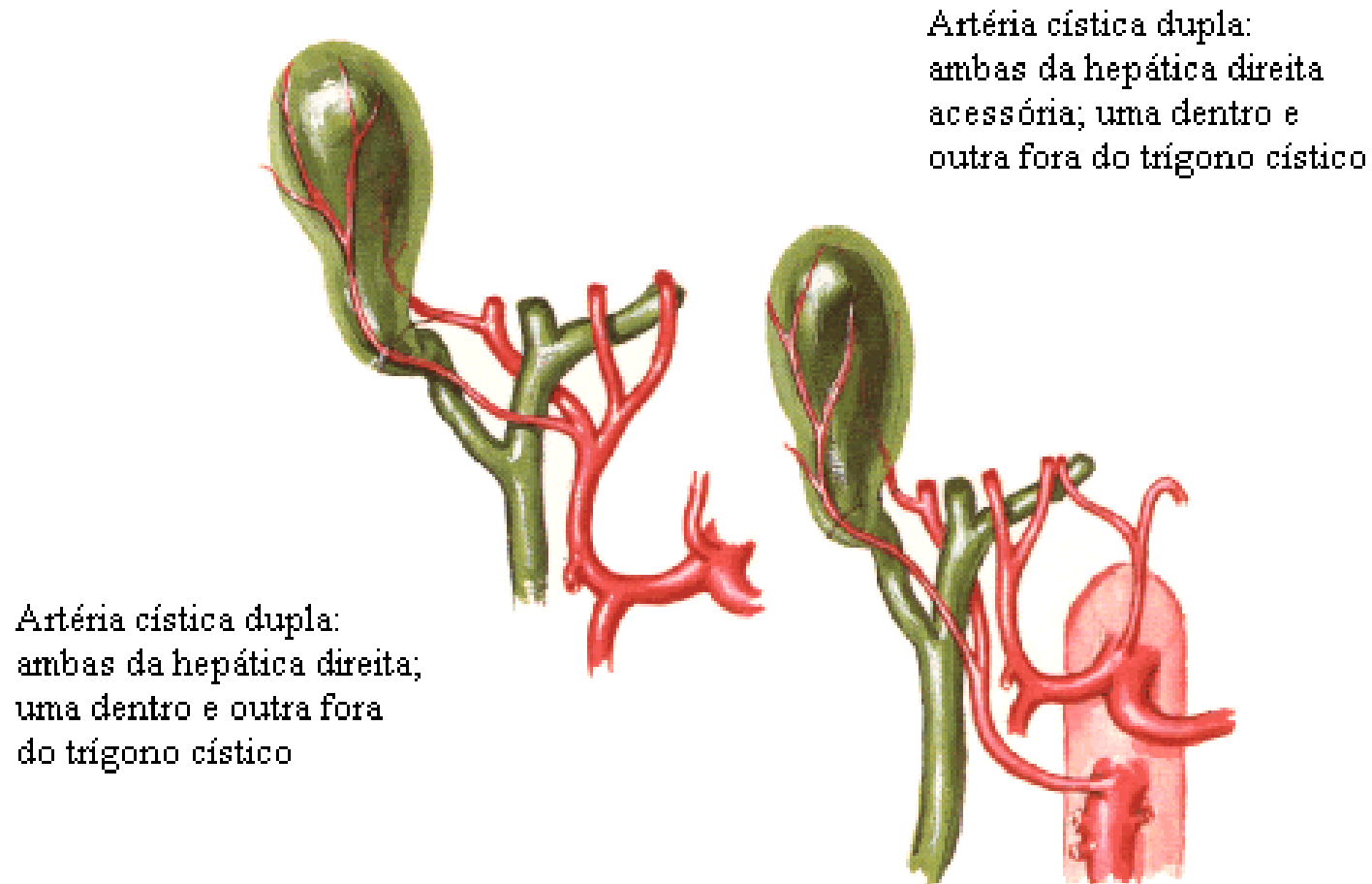


Artéria cística dupla:
ambas a partir da hepática
direita no triângulo cístico

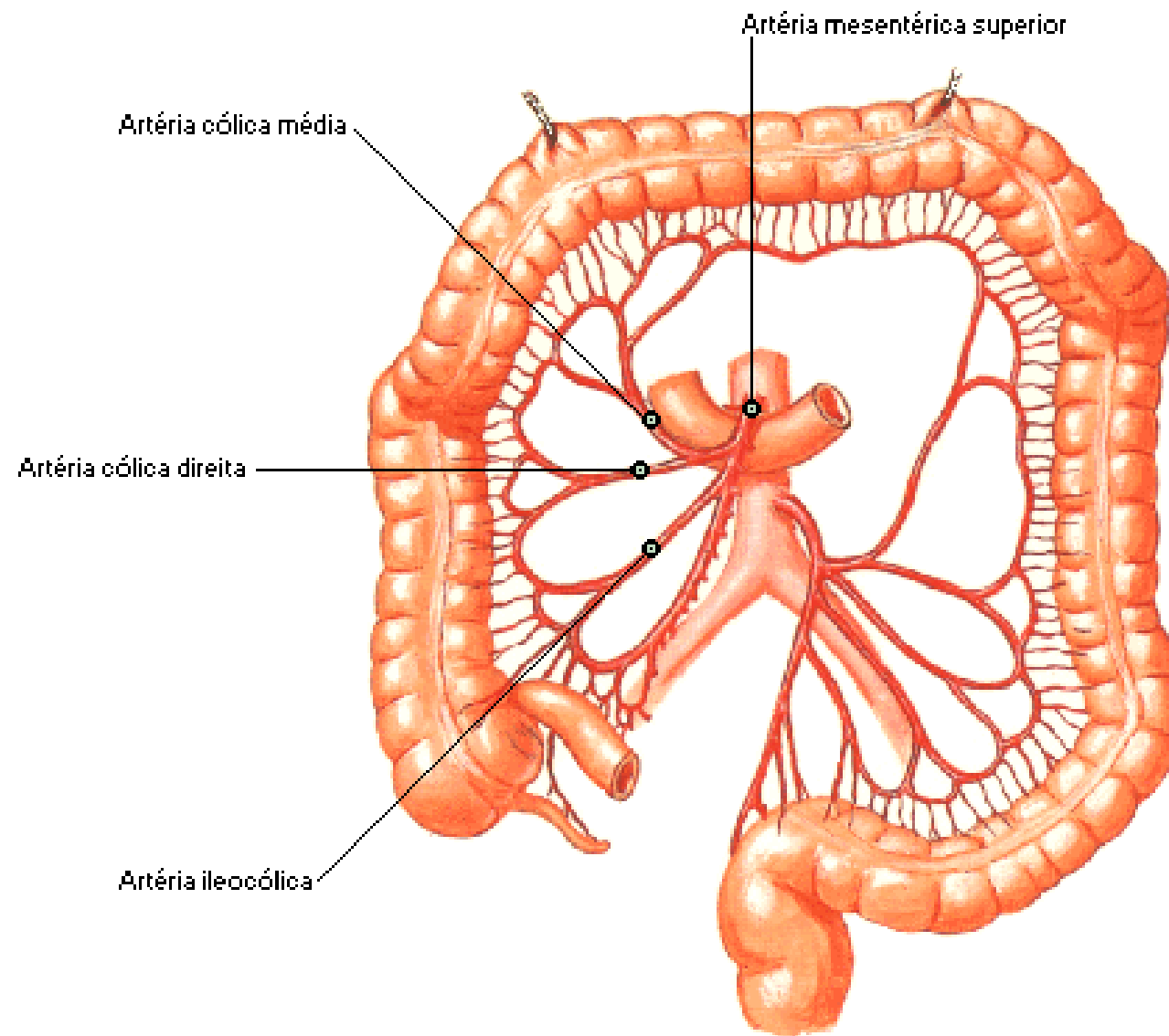
Artéria cística dupla:
posterior da hepática direita;
anterior da gastroduodenal



Variações na Artéria Cística 5

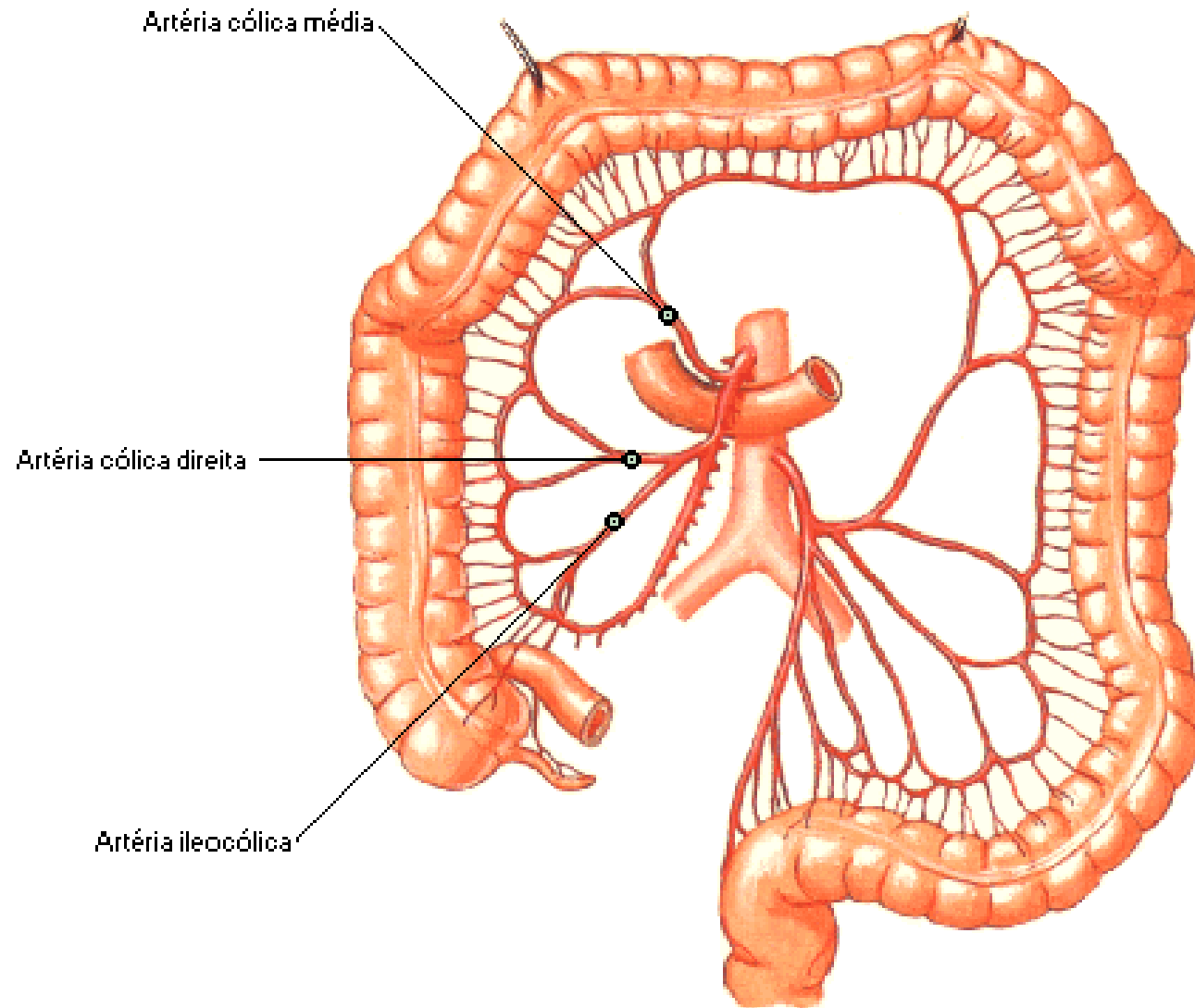


Variações nas Artérias Cólicas 1



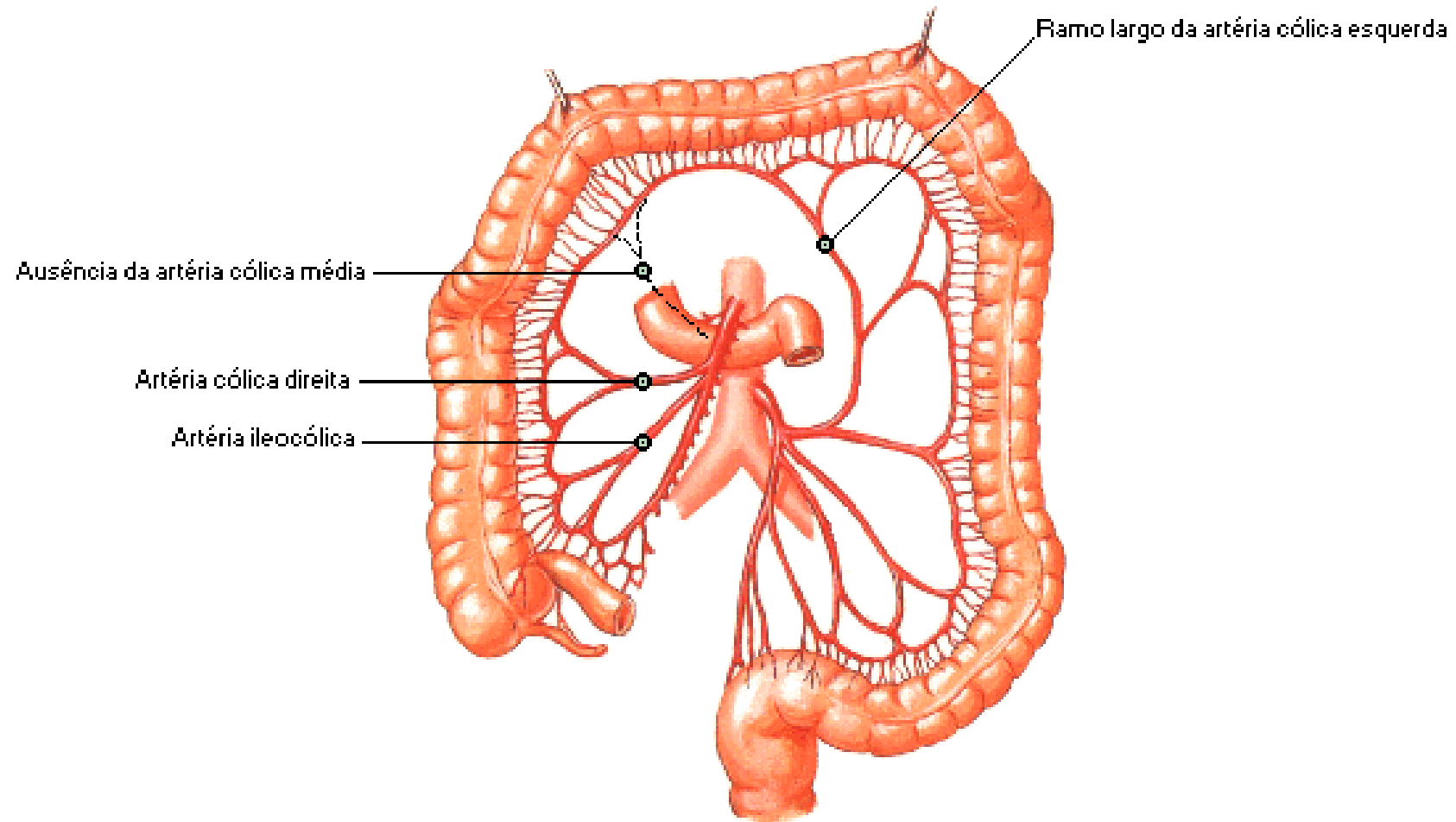
Origem comum das artérias cólicas direita e média

Variações nas Artérias Cólicas 2



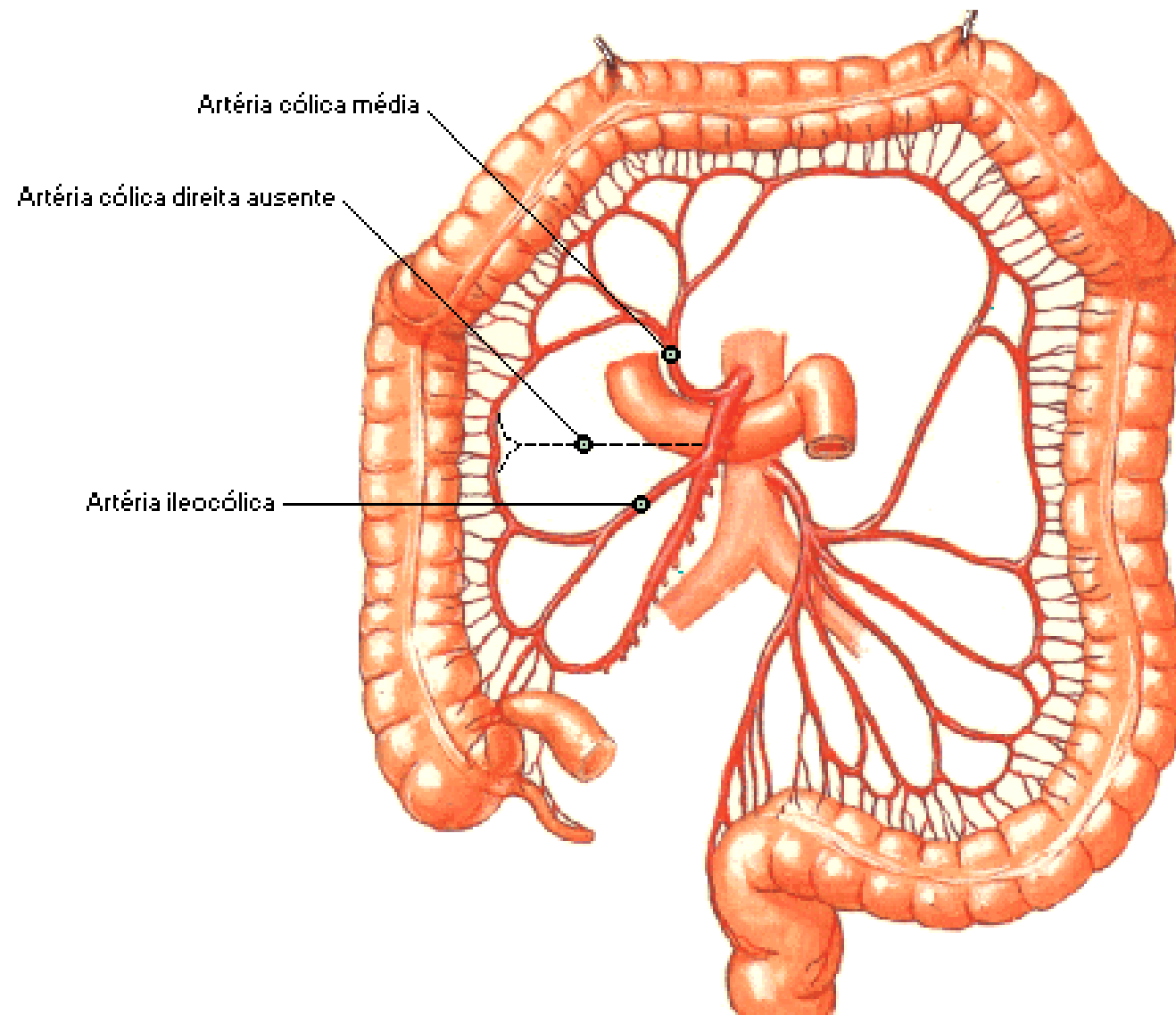
Origem comum das artérias cólica direita e ileocólica

Variações nas Artérias Cólicas 3



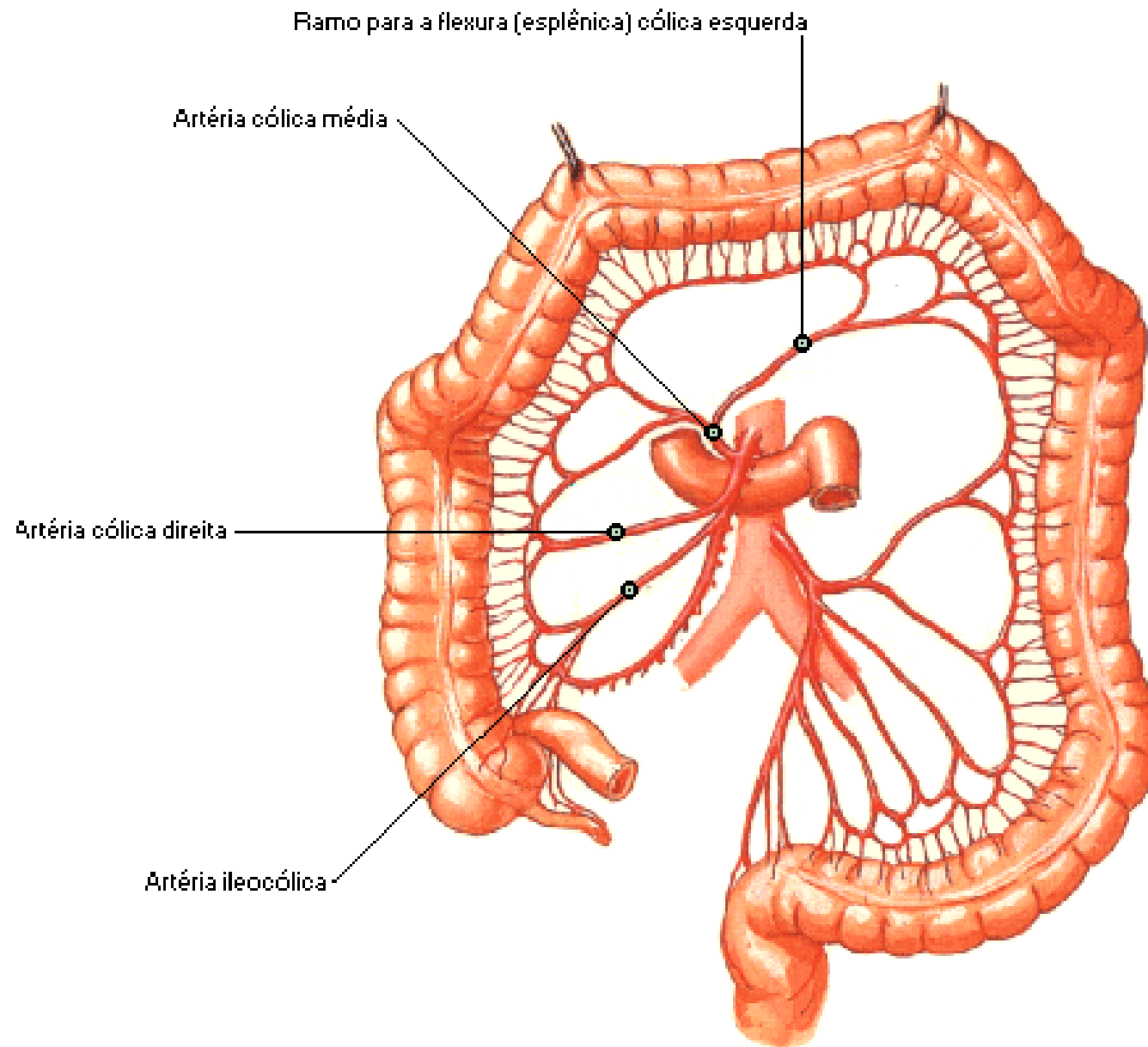
Ausência da artéria cólica média substituída por um importante ramo da cólica esquerda

Variações nas Artérias Cólicas 4



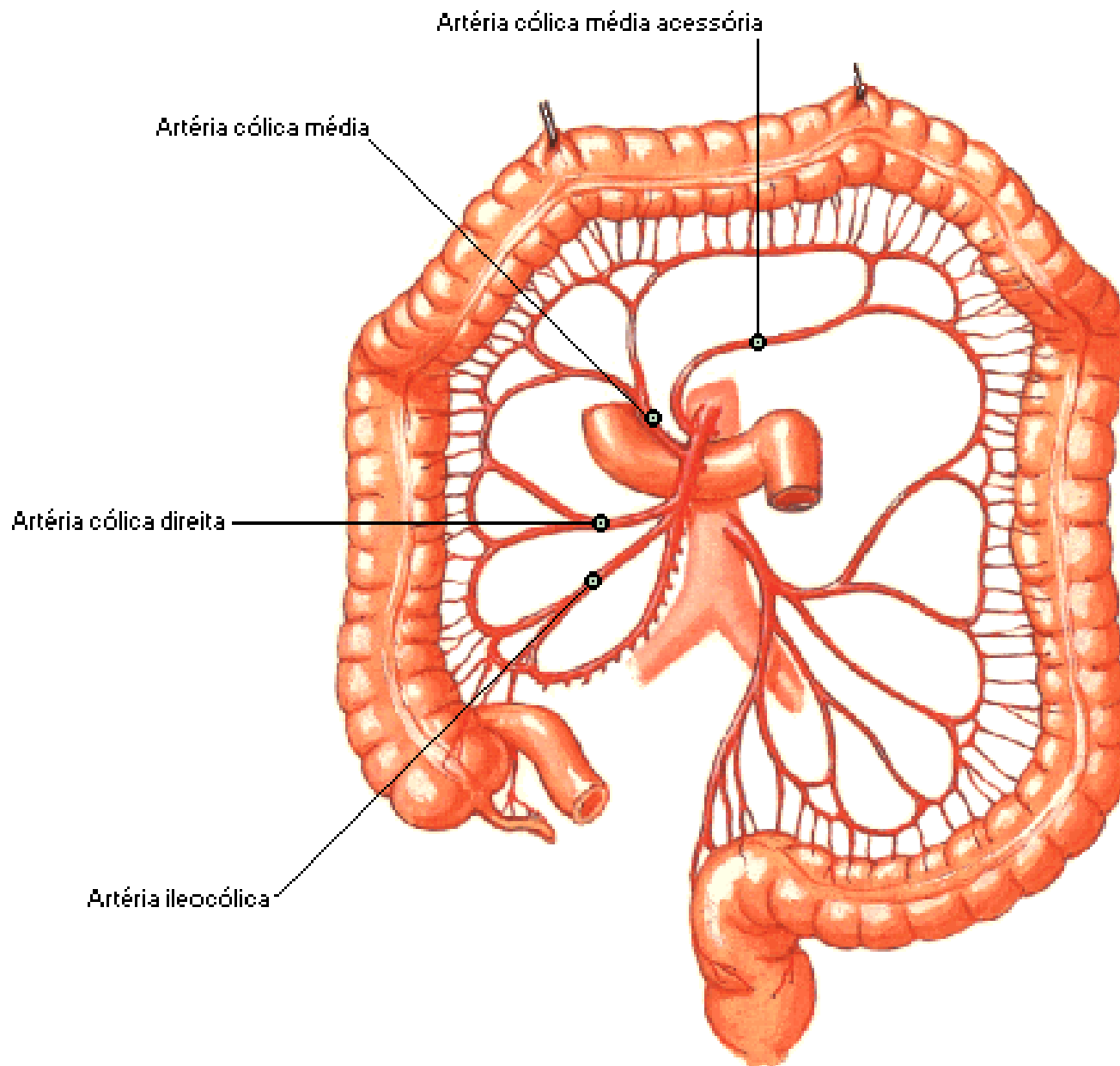
Ausência da artéria cólica direita

Variações nas Artérias Cólicas 5



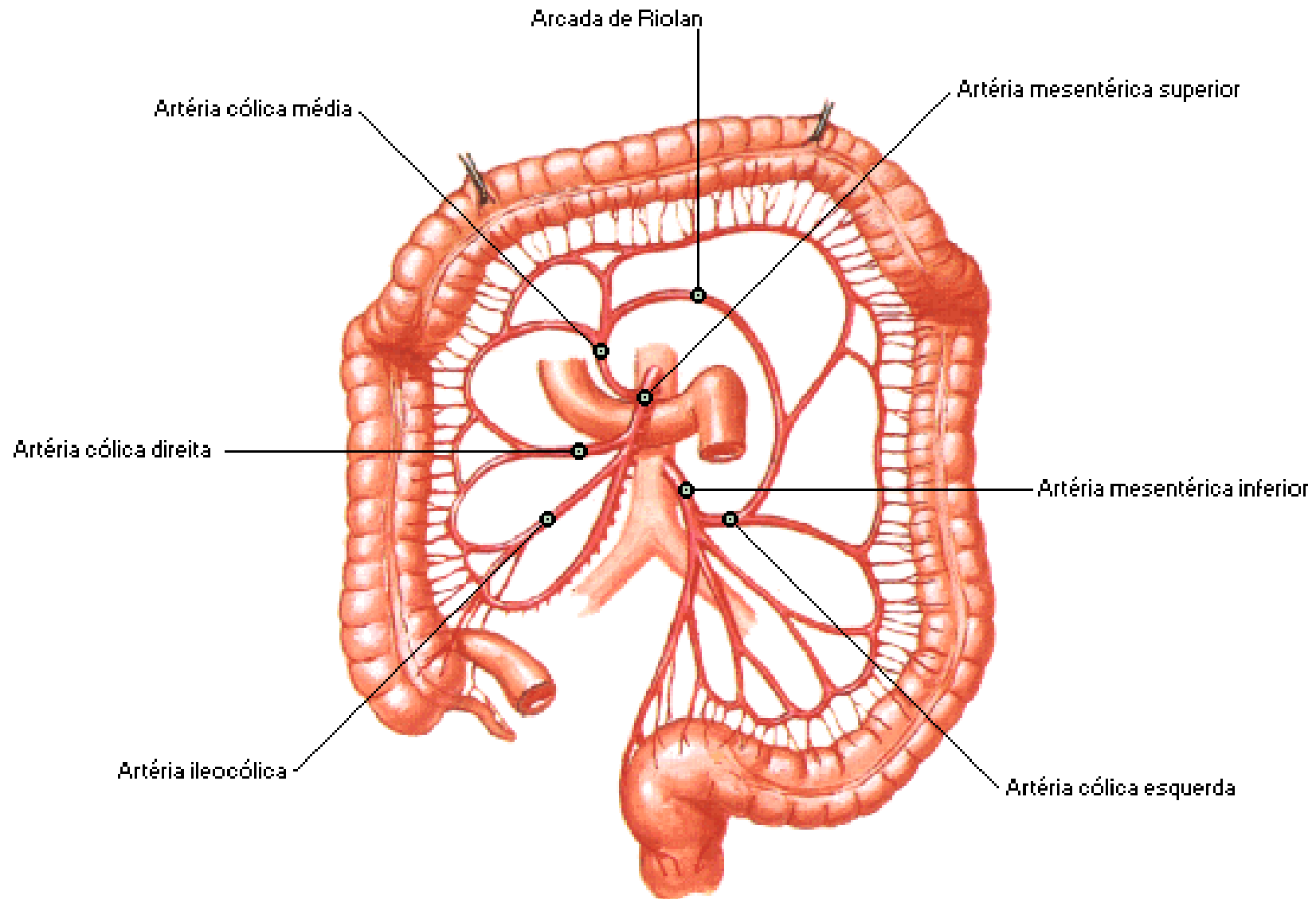
Ramo da artéria cólica média para a flexura (esplênica) cólica esquerda

Variações nas Artérias Cólicas 6



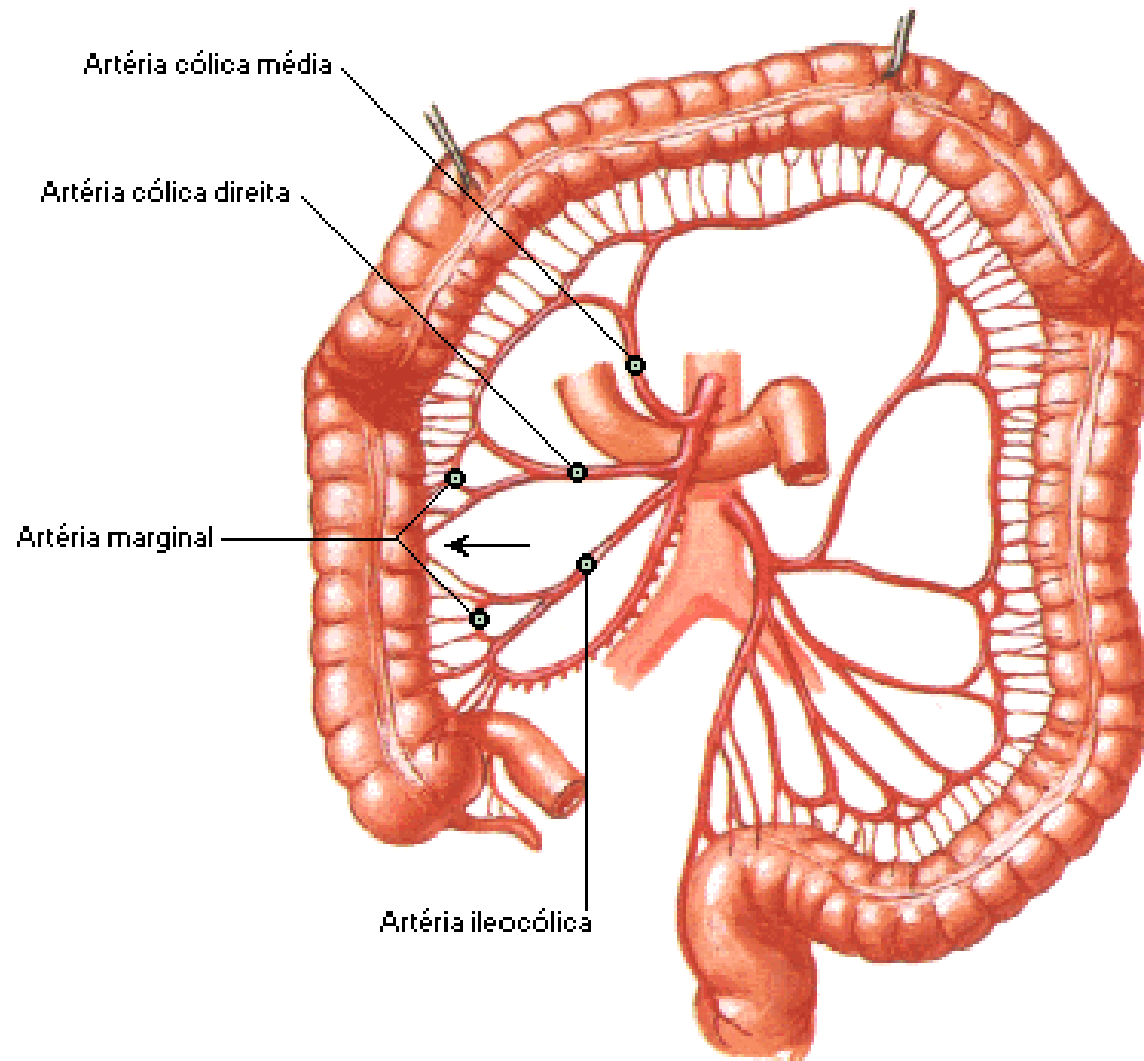
Artéria cólica média acessória para a flexura (esplênica) cólica esquerda

Variações nas Artérias Cólicas 7



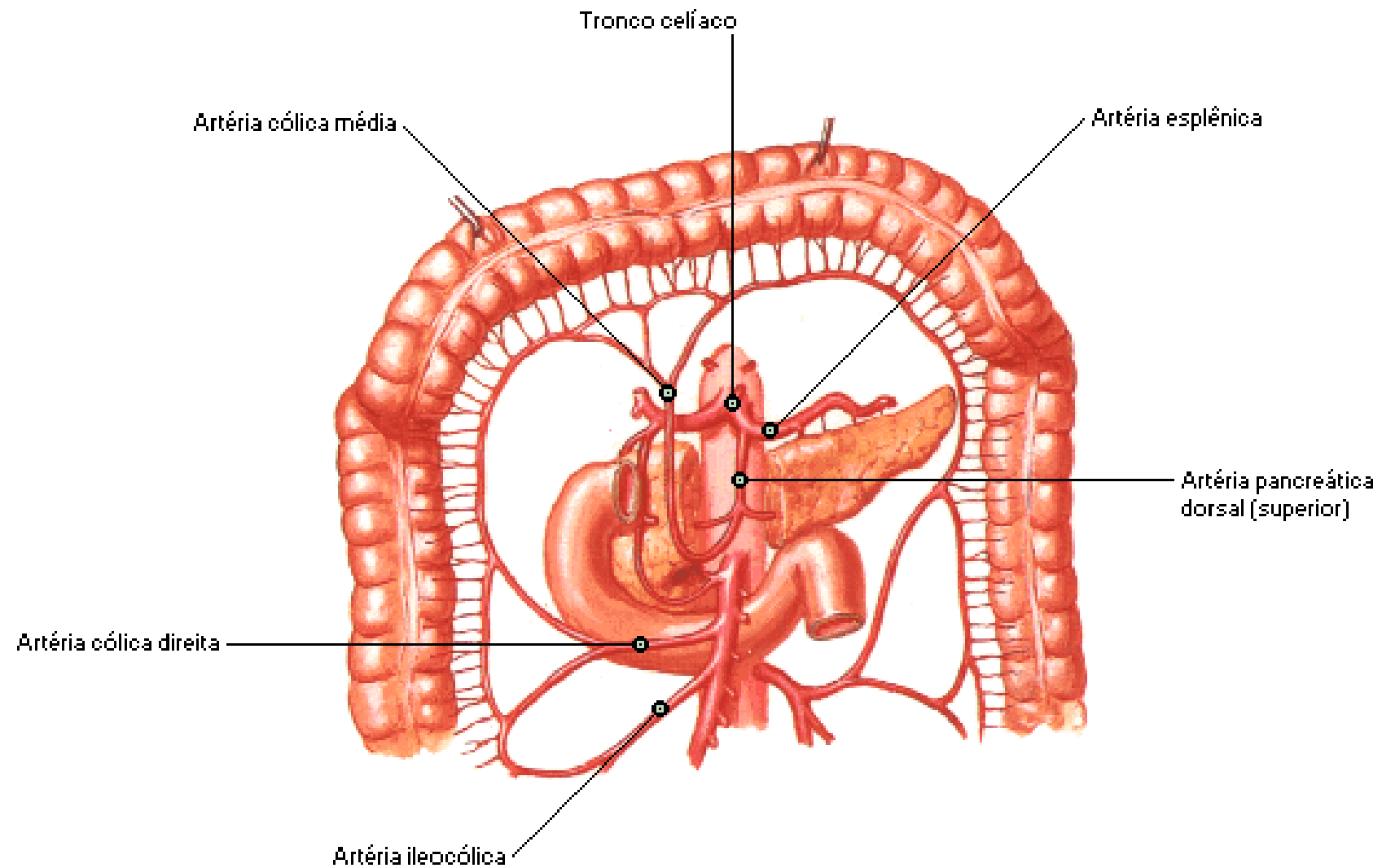
Arcada de Riolan entre as artérias cólica média e cólica esquerda

Variações nas Artérias Cólicas 8



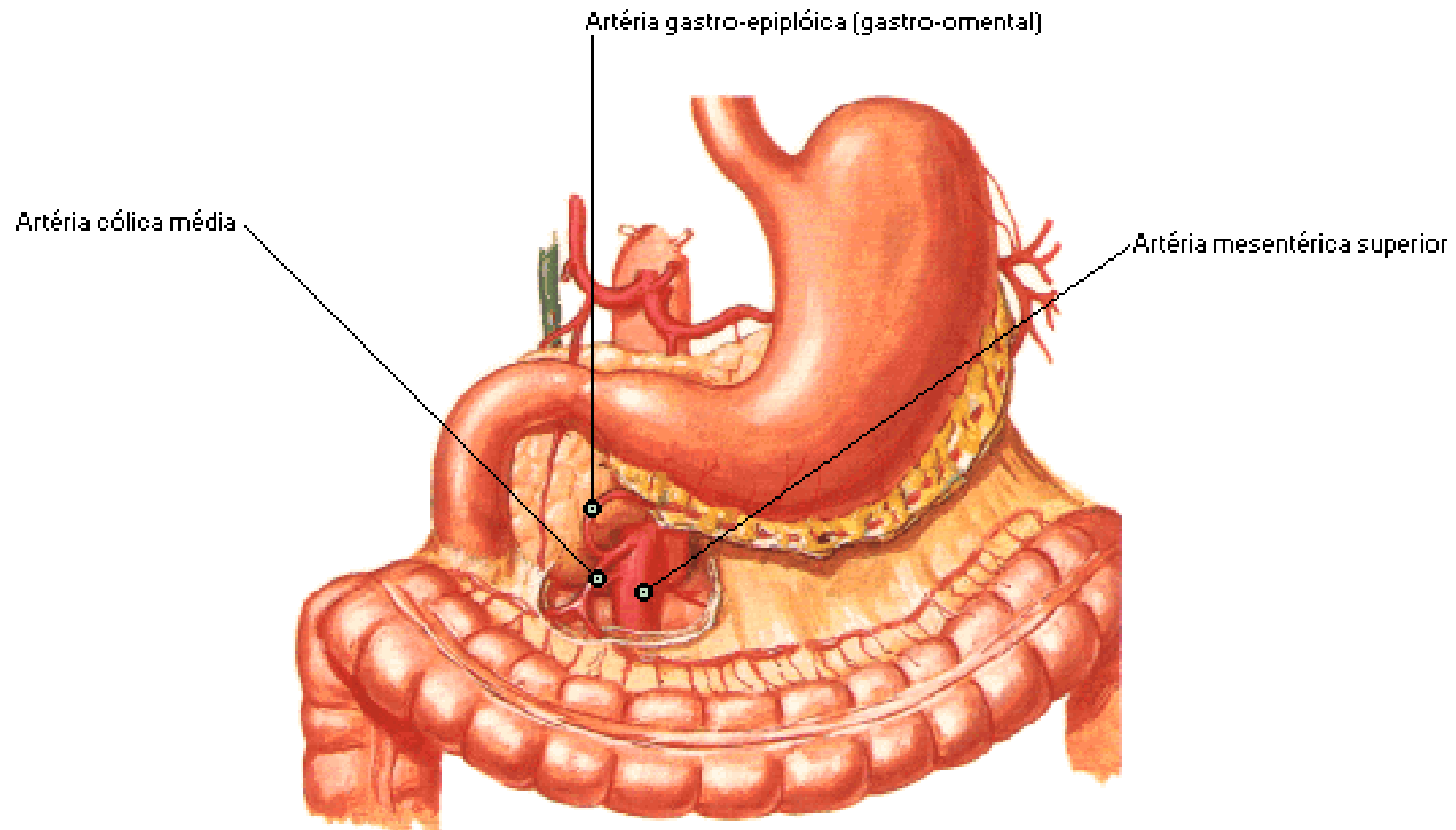
Descontinuidade da artéria marginal entre as artérias cólica direita e ileocólica

Variações nas Artérias Cólicas 9



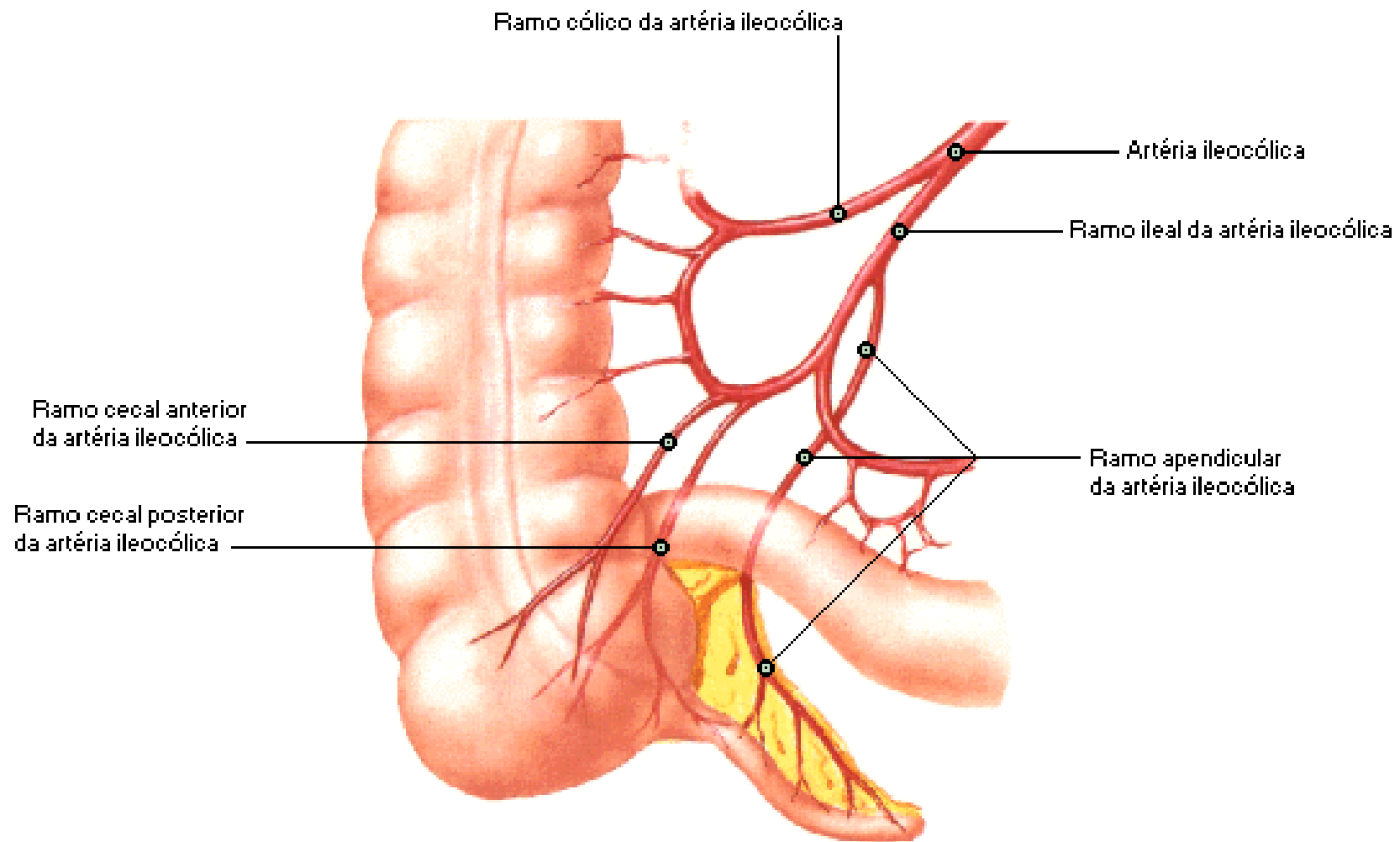
Artéria cólica média origina-se do tronco celíaco via artéria pancreática dorsal

Variações nas Artérias Cólicas 12



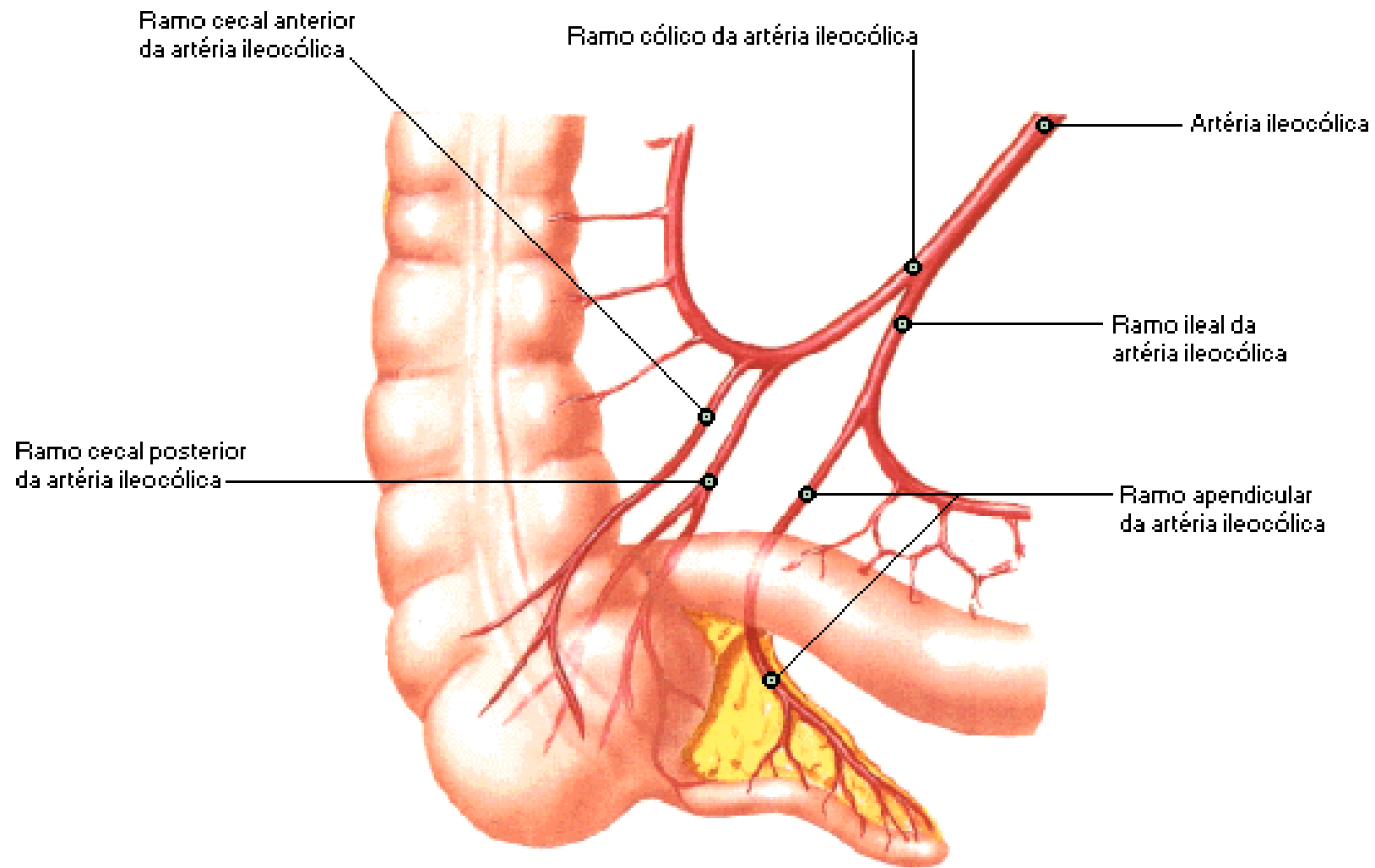
Artéria cólica média tem origem com artéria gastro-epiplóica (gastro-omental) direita, a partir da artéria mesentérica superior

Variações nas Artérias Cecal e Apendicular 1



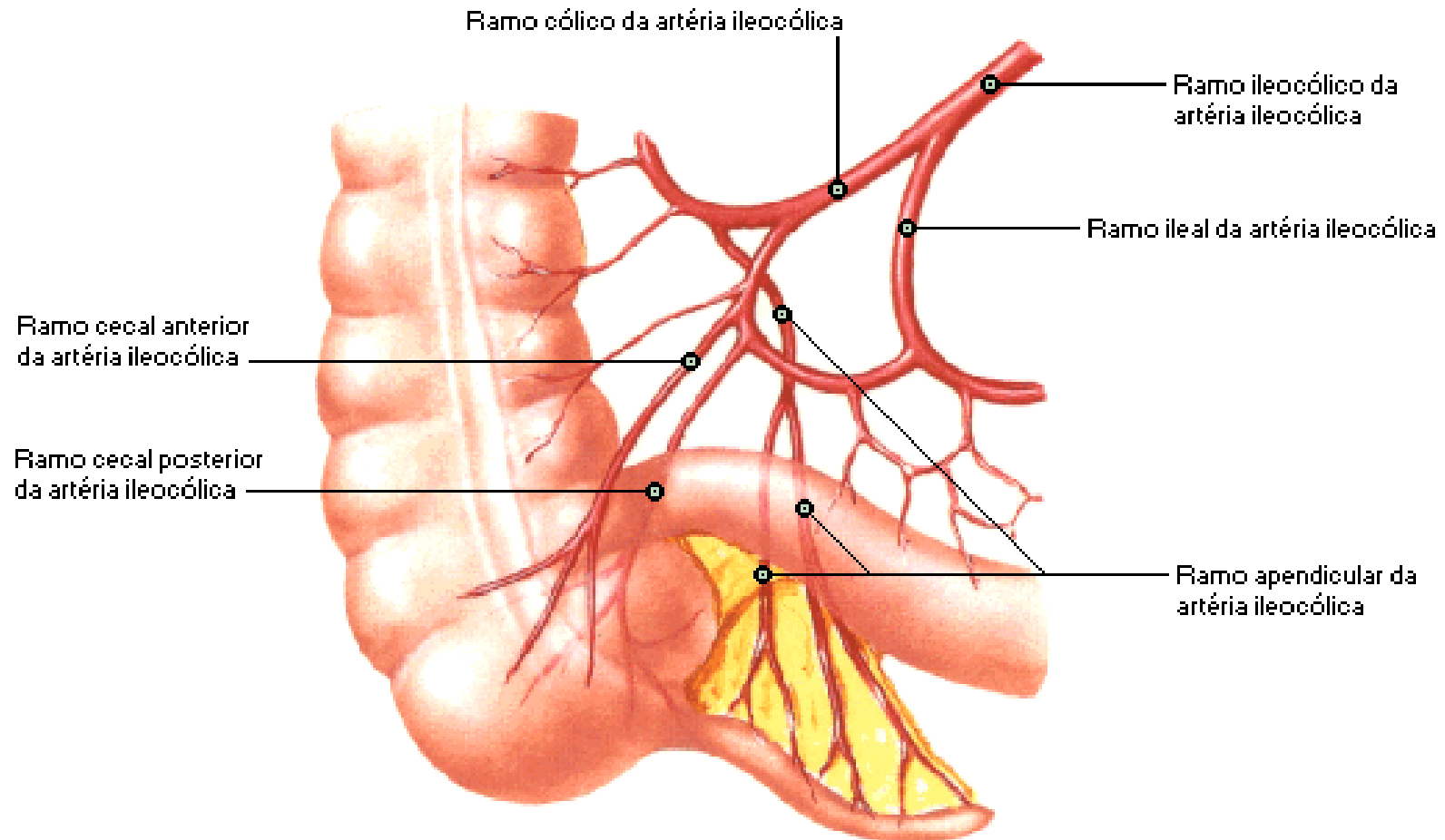
Artérias cecal anterior e cecal posterior originam-se da arcada entre os ramos cólico e ileal da ileocólica; a artéria apendicular, do ramo ileal

Variações nas Artérias Cecal e Apendicular 2



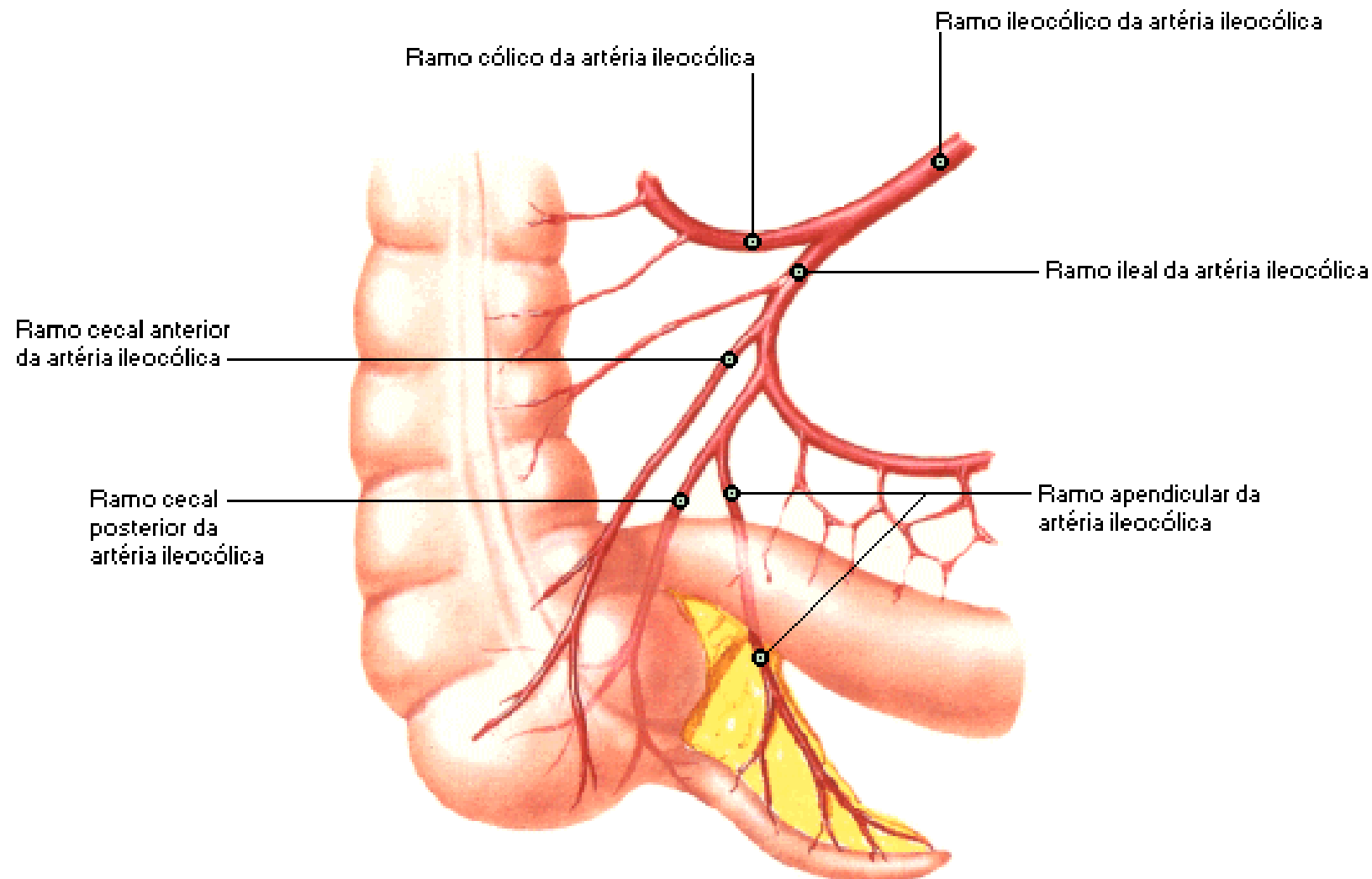
Artérias cecal anterior e cecal posterior originam-se do ramo cólico;
a artéria apendicular, do ramo ileal da artéria ileocólica

Variações nas Artérias Cecal e Apendicular 4



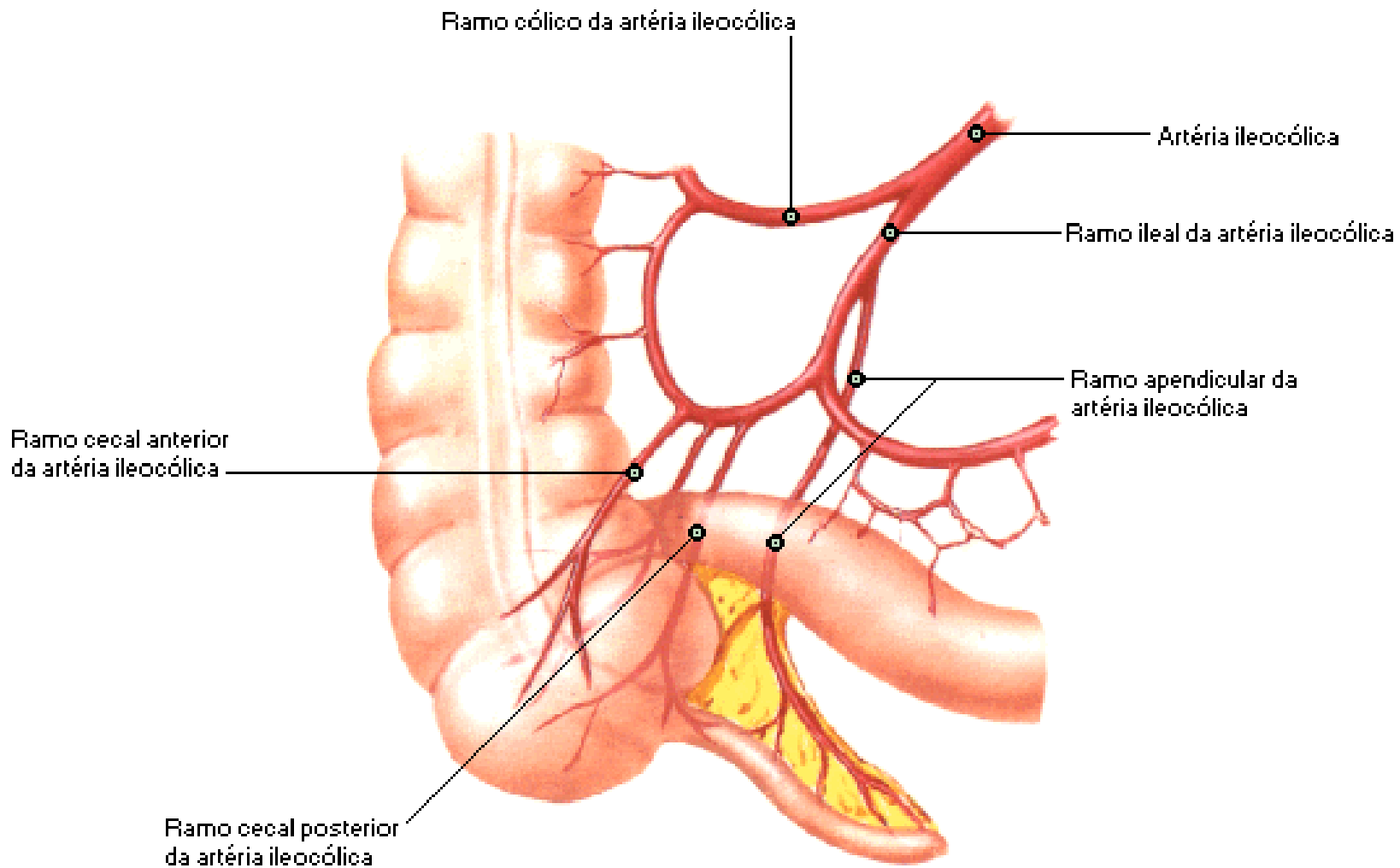
Artérias cecal anterior e cecal posterior originam-se da arcada entre os ramos cólico e ileal da artéria ileocólica; a artéria apendicular, do ramo cólico e bifurcação alta

Variações nas Artérias Cecal e Apendicular 5



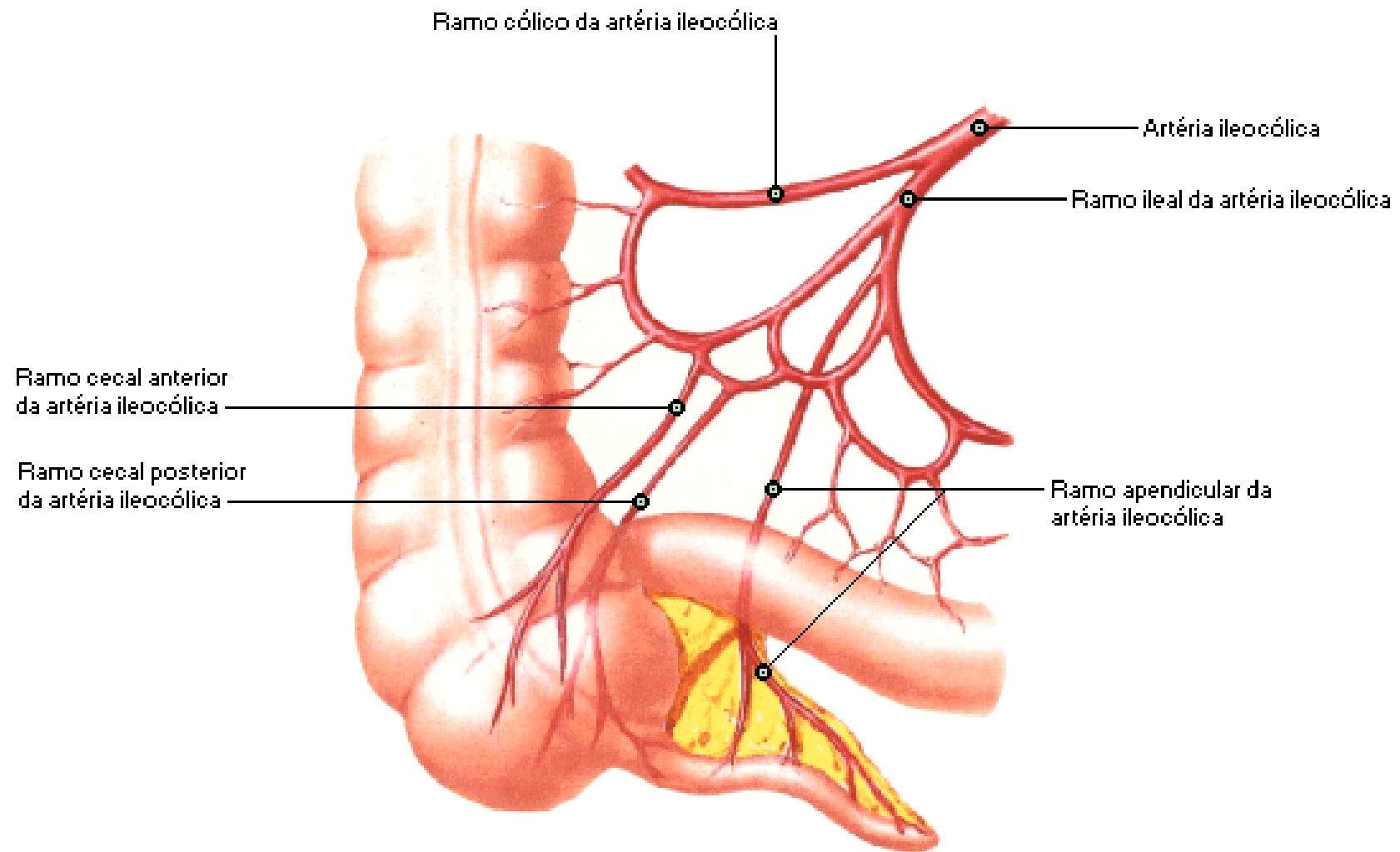
Artérias cecais anterior e posterior originam-se do ramo ileal da artéria ileocólica; a artéria apendicular, da artéria cecal posterior

Variações nas Artérias Cecal e Apendicular 6



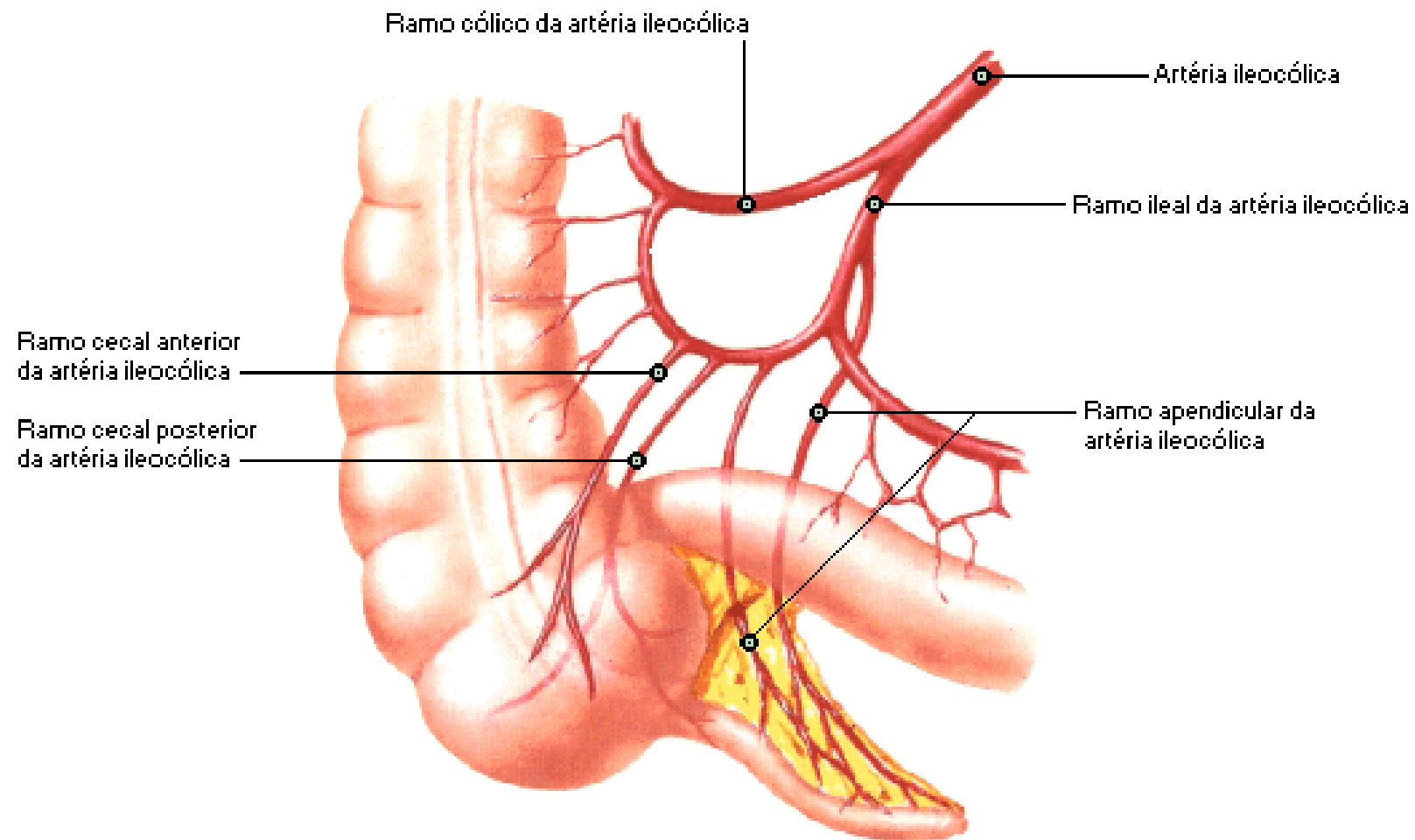
Artéria cecal anterior e duas cecais posteriores originam-se da arcada; a artéria apendicular, do ramo ileal da artéria ileocólica

Variações nas Artérias Cecal e Apendicular 7



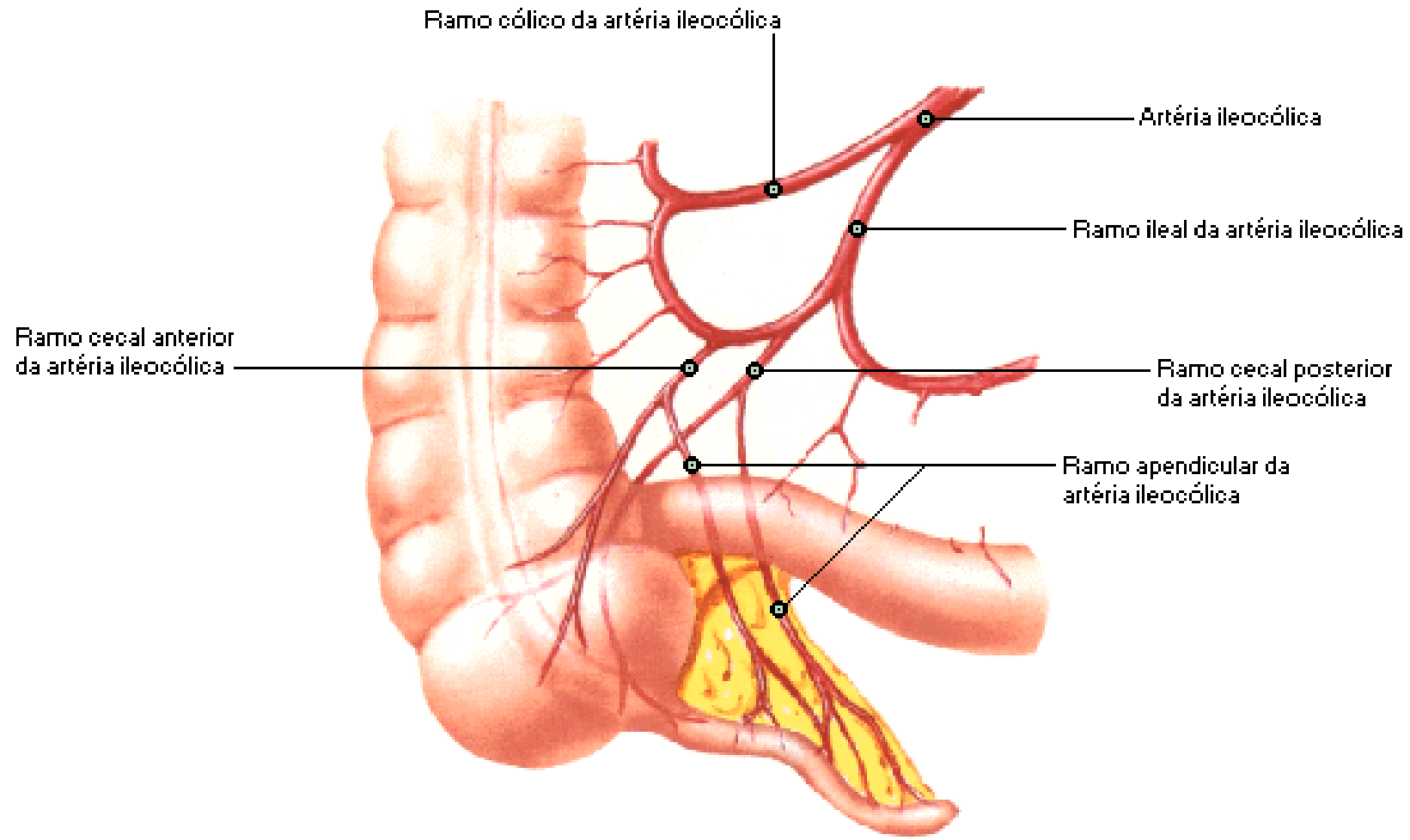
Múltiplas arcadas entre o ramo ileal e o ramo cólico da ileocólica; as cecais anterior e posterior originam-se dessas arcadas; a artéria apendicular, do ramo ileal da artéria ileocólica

Variações nas Artérias Cecal e Apendicular 8



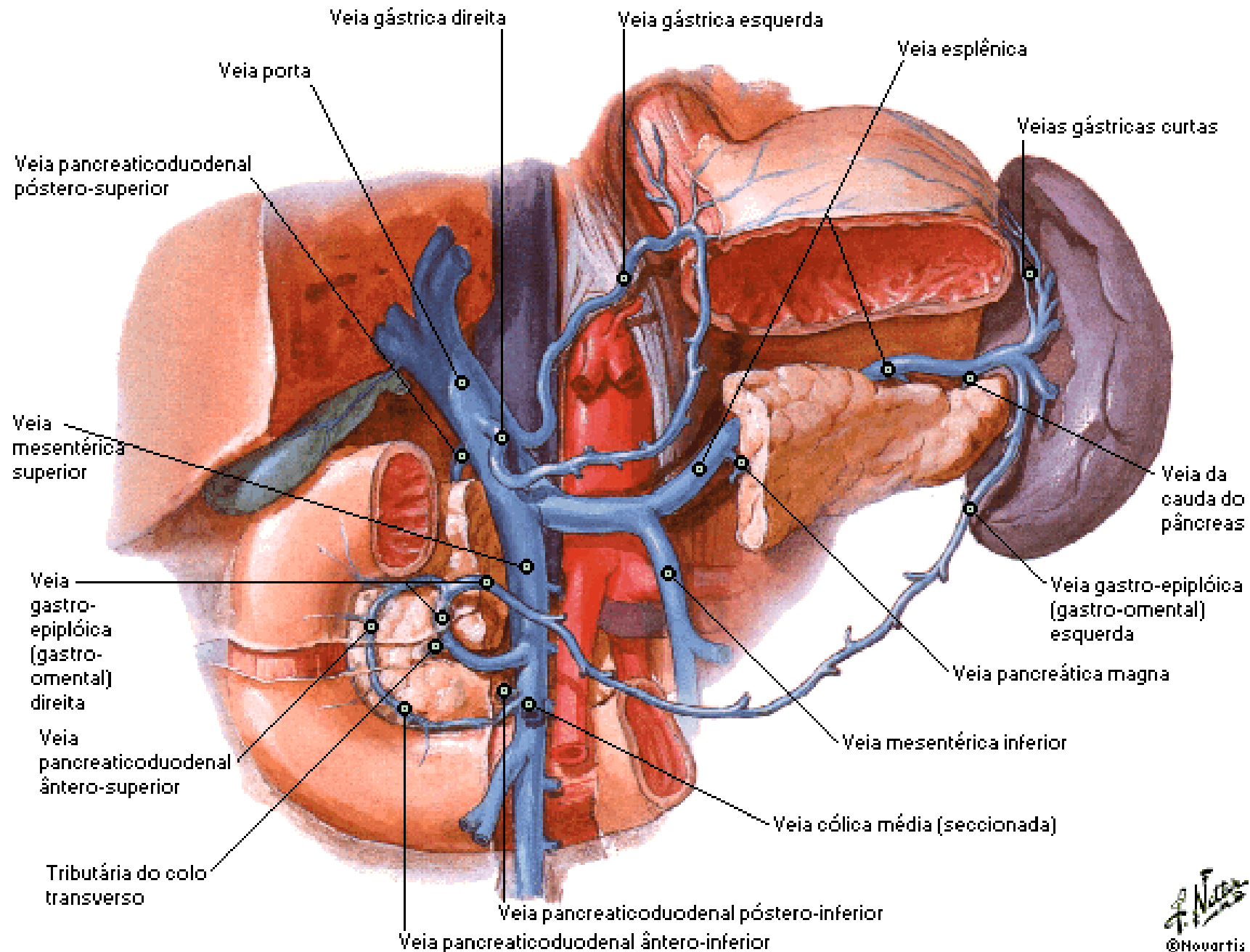
Artérias cecais anterior e posterior originam-se da arcada entre os ramos cólico e ileal da ileocólica; duas artérias apendiculares: uma, da arcada, e, a outra, do ramo ileal da artéria ileocólica

Variações nas Artérias Cecal e Apendicular 9



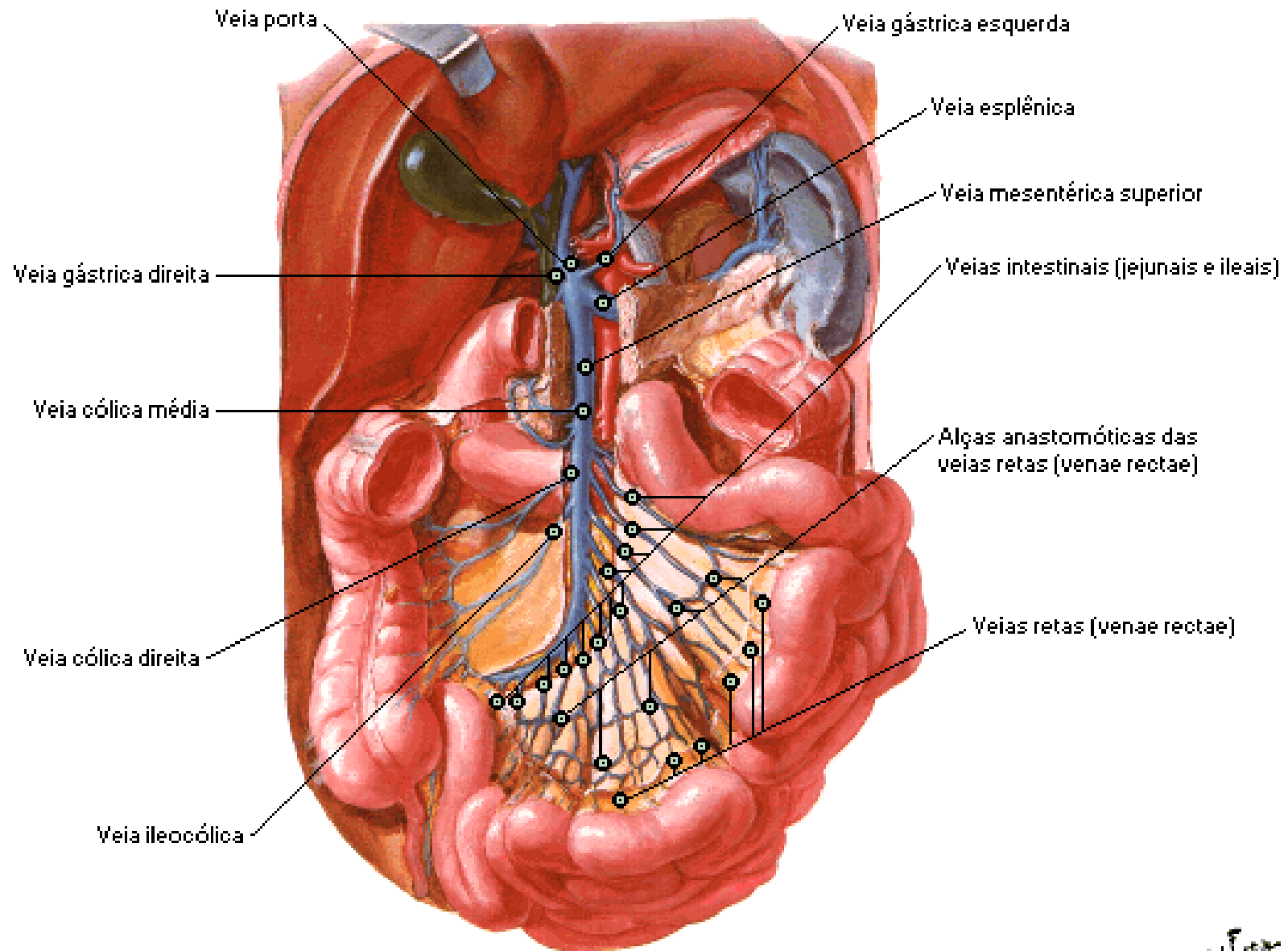
Artérias cecais anterior e posterior originam-se da arcada; duas artérias apendiculares: uma, da cecal anterior, e, a outra, da artéria cecal posterior

Veias do Estômago, Duodeno e Pâncreas [Continuação]



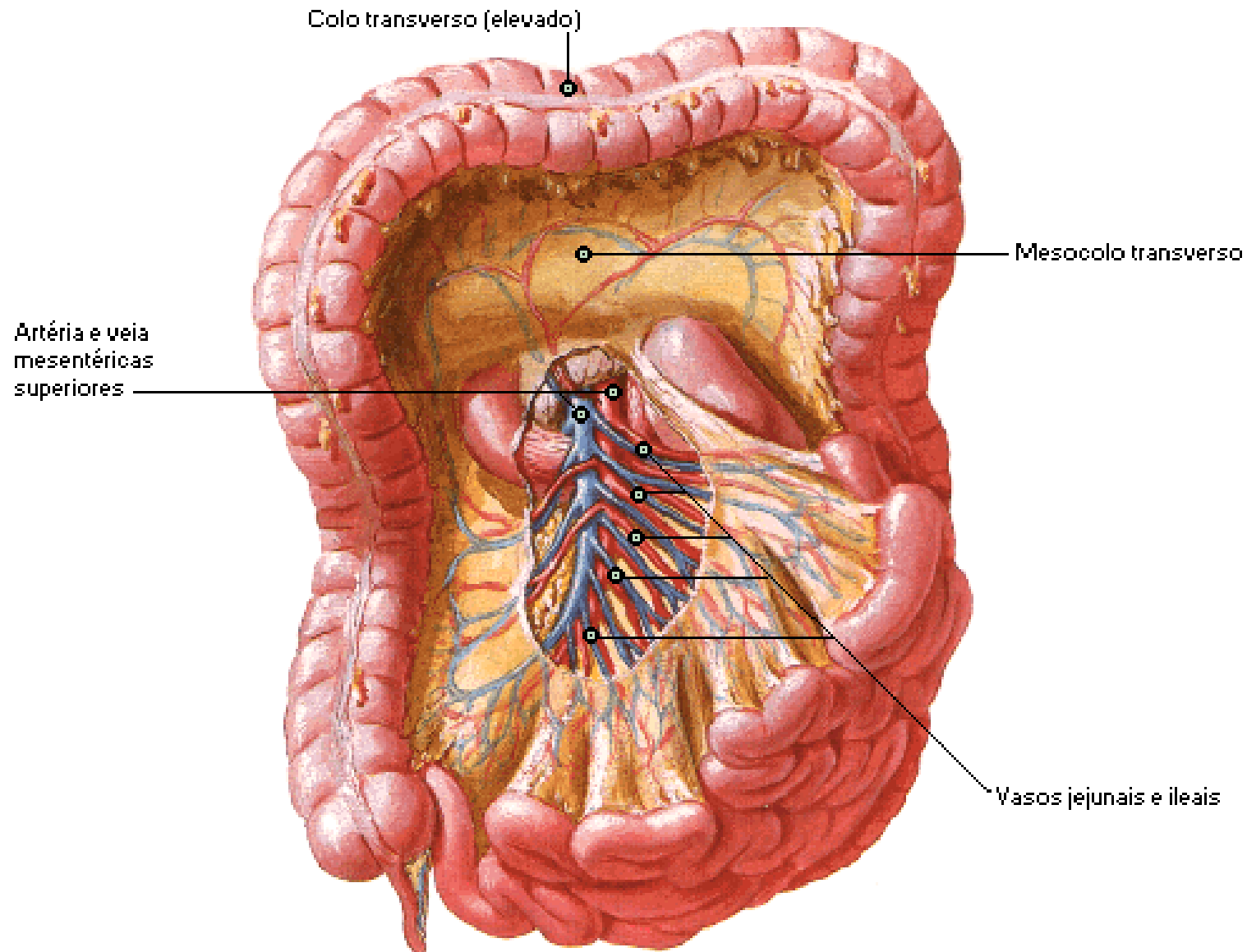
Veias do Intestino Delgado

Colo Transverso Seccionado



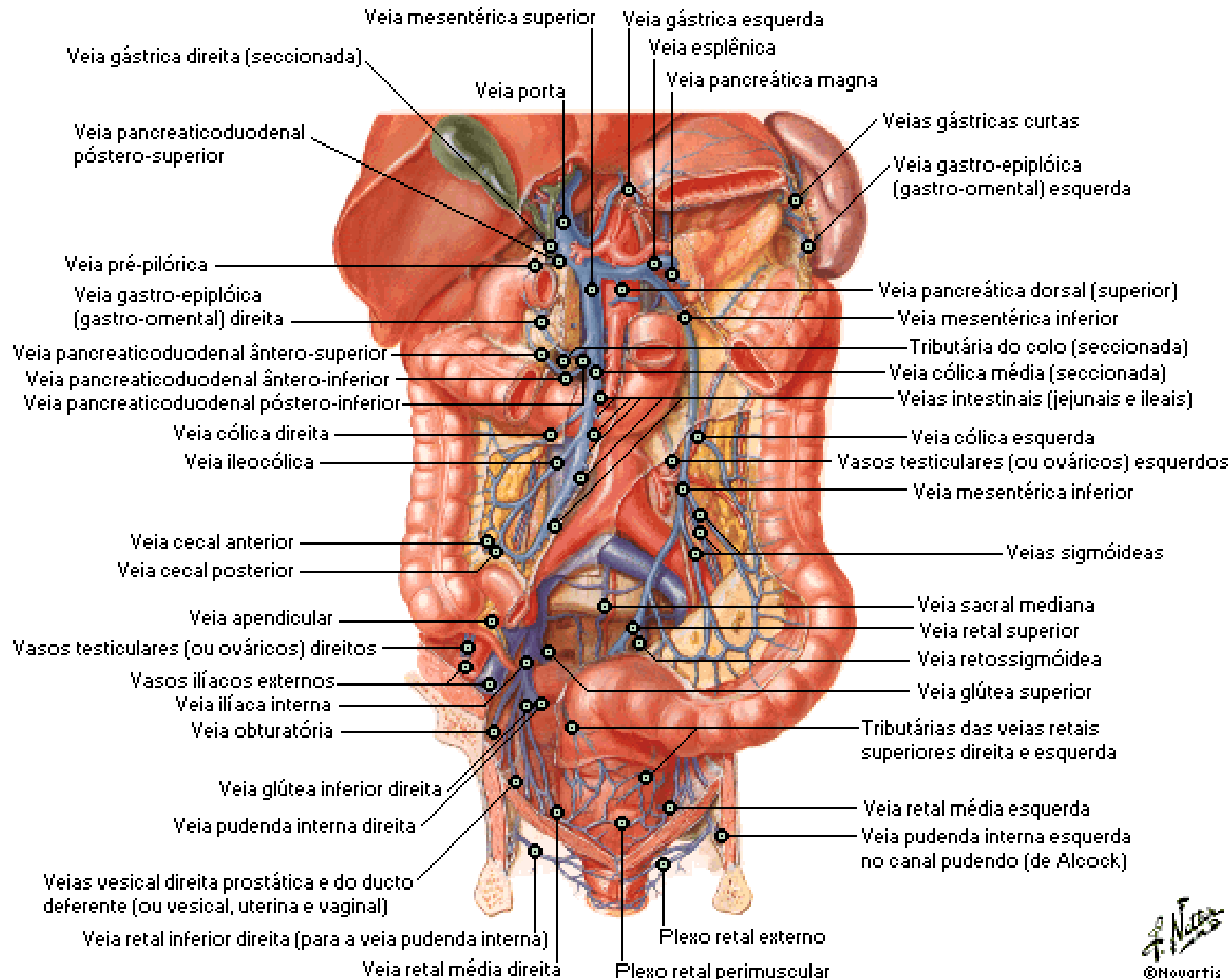
Veias do Intestino Delgado

Colo Transverso [Elevado]



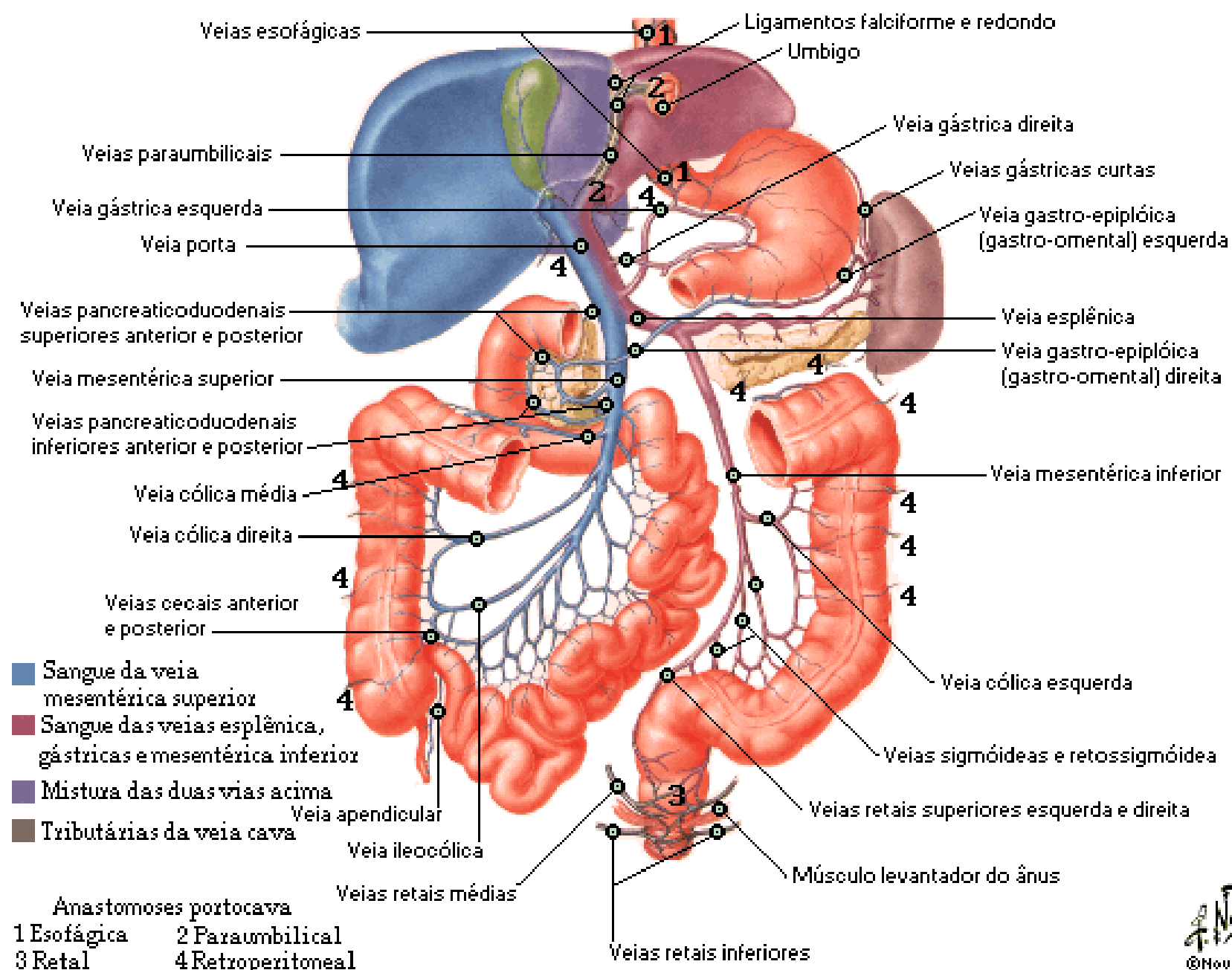
Relações da veia e artérias mesentéricas superiores na raiz do mesentério

Veias dos Intestinos Delgado e Grosso



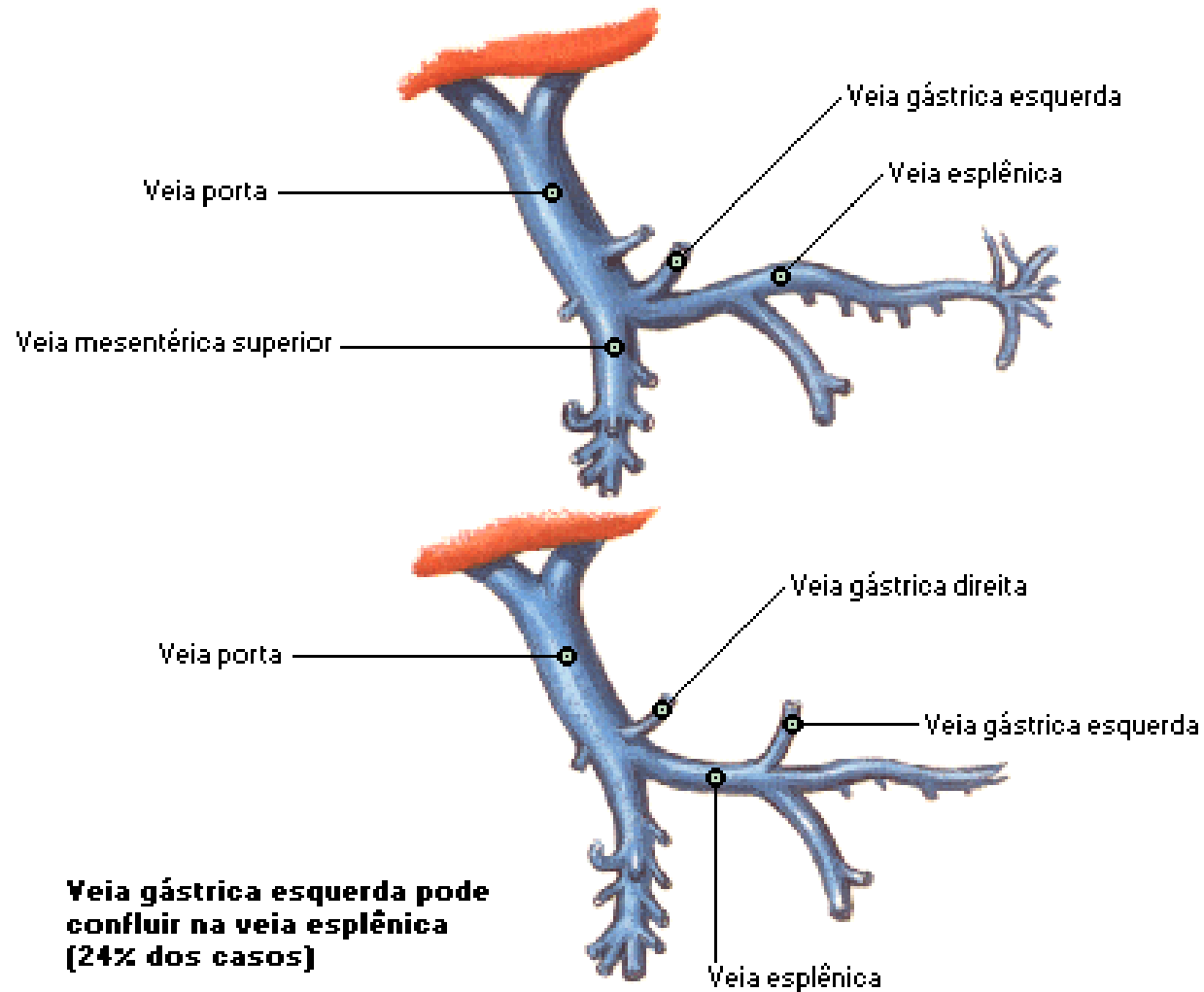
Tributárias da Veia Porta

Anastomoses Portocava



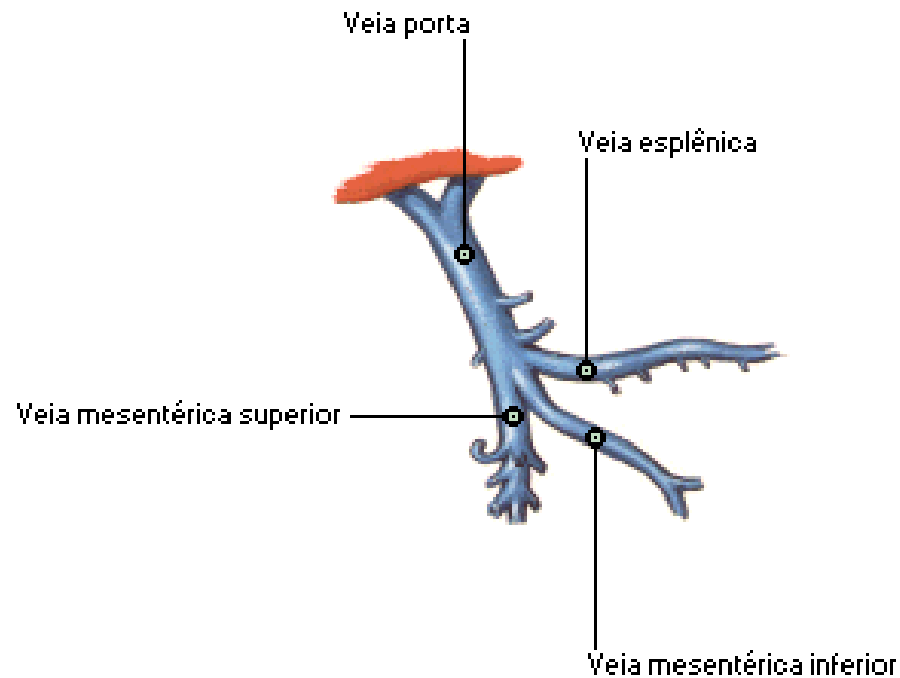
Variações da Veia Porta

Veia gástrica esquerda freqüentemente conflui na junção das veias esplênica e mesentérica superior

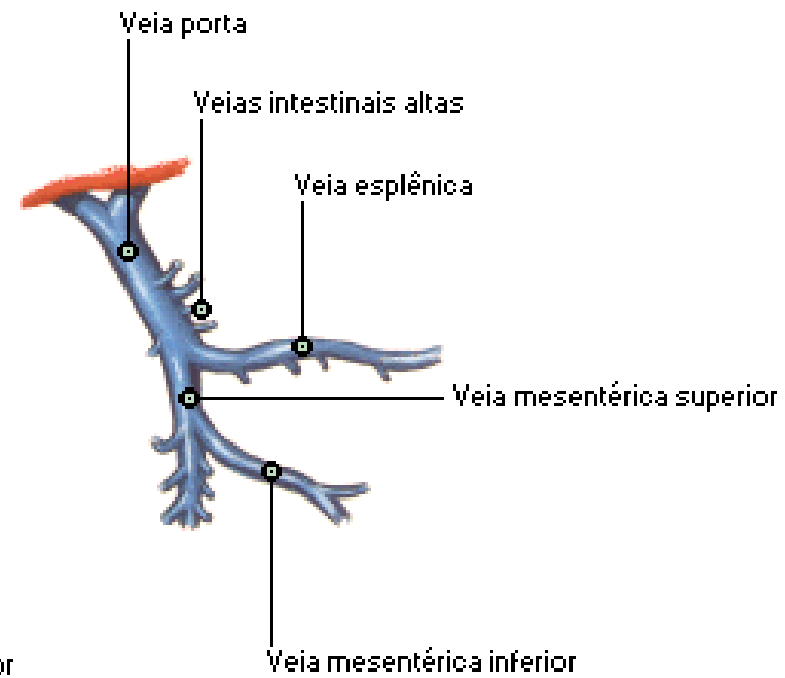


Veia gástrica esquerda pode confluir na veia esplênica (24% dos casos)

Variações da Veia Porta [Continuação]



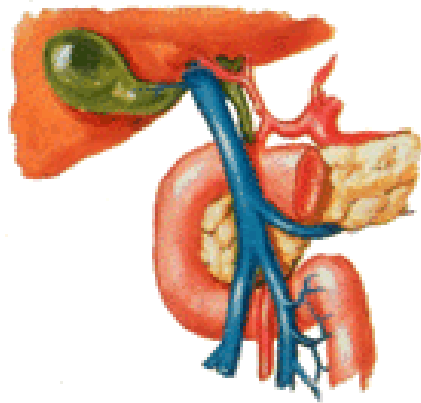
Veia mesentérica inferior pode confluir na junção das veias esplênica e mesentérica superior



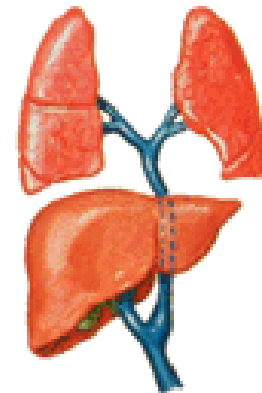
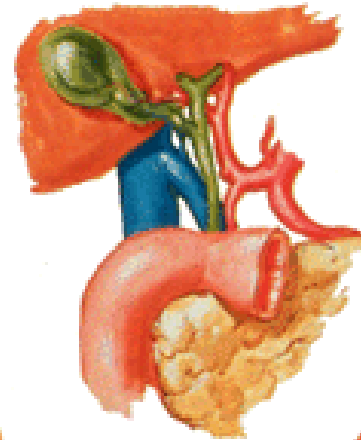
Veia mesentérica inferior pode confluir na veia mesentérica superior

Anomalias da Veia Porta


Veia porta anterior à cabeça do pâncreas e 1ª parte do duodeno



Veia porta pode confluir para veia cava inferior (artérias hepáticas aumentadas)

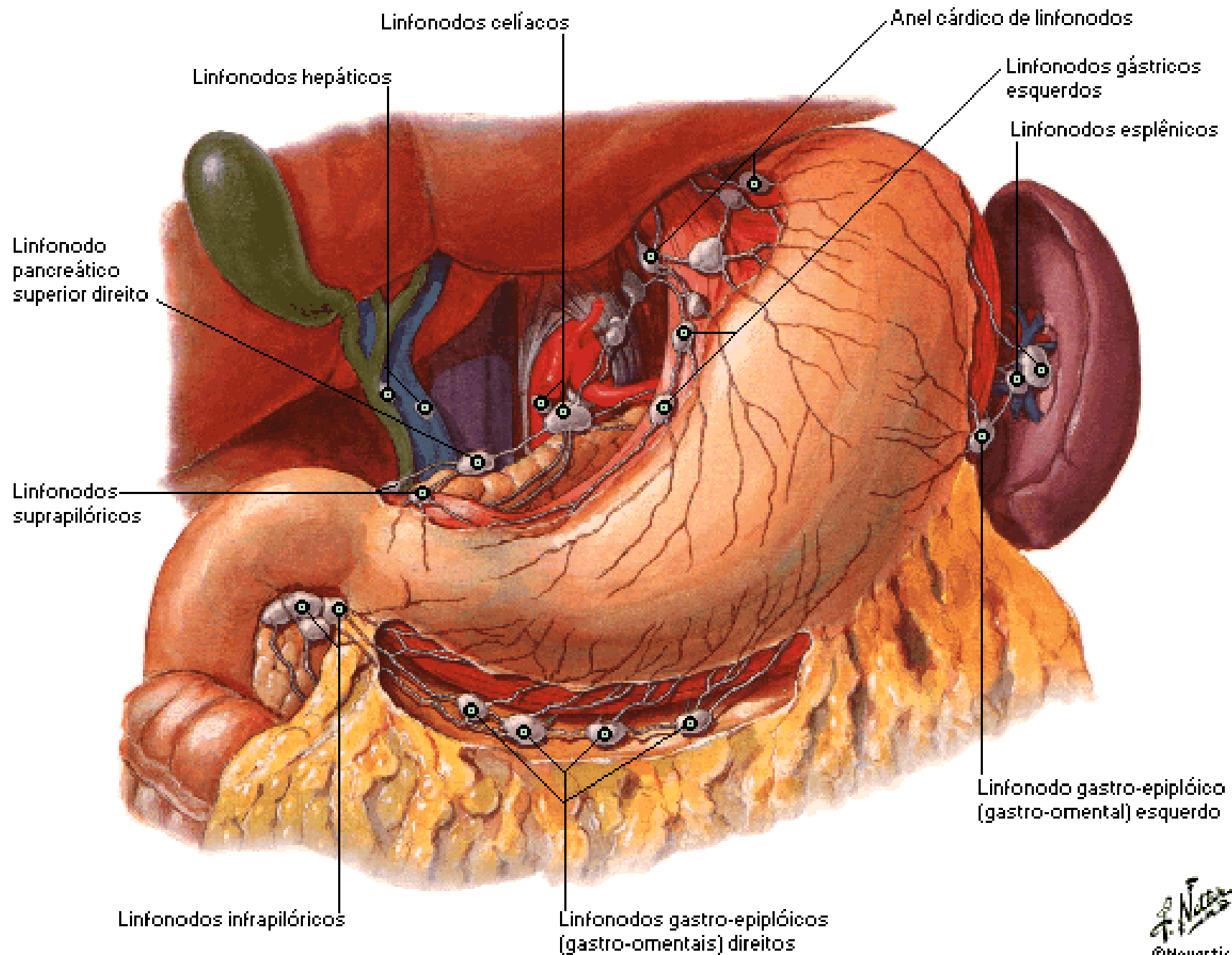


Veia pulmonar pode confluir para a veia porta



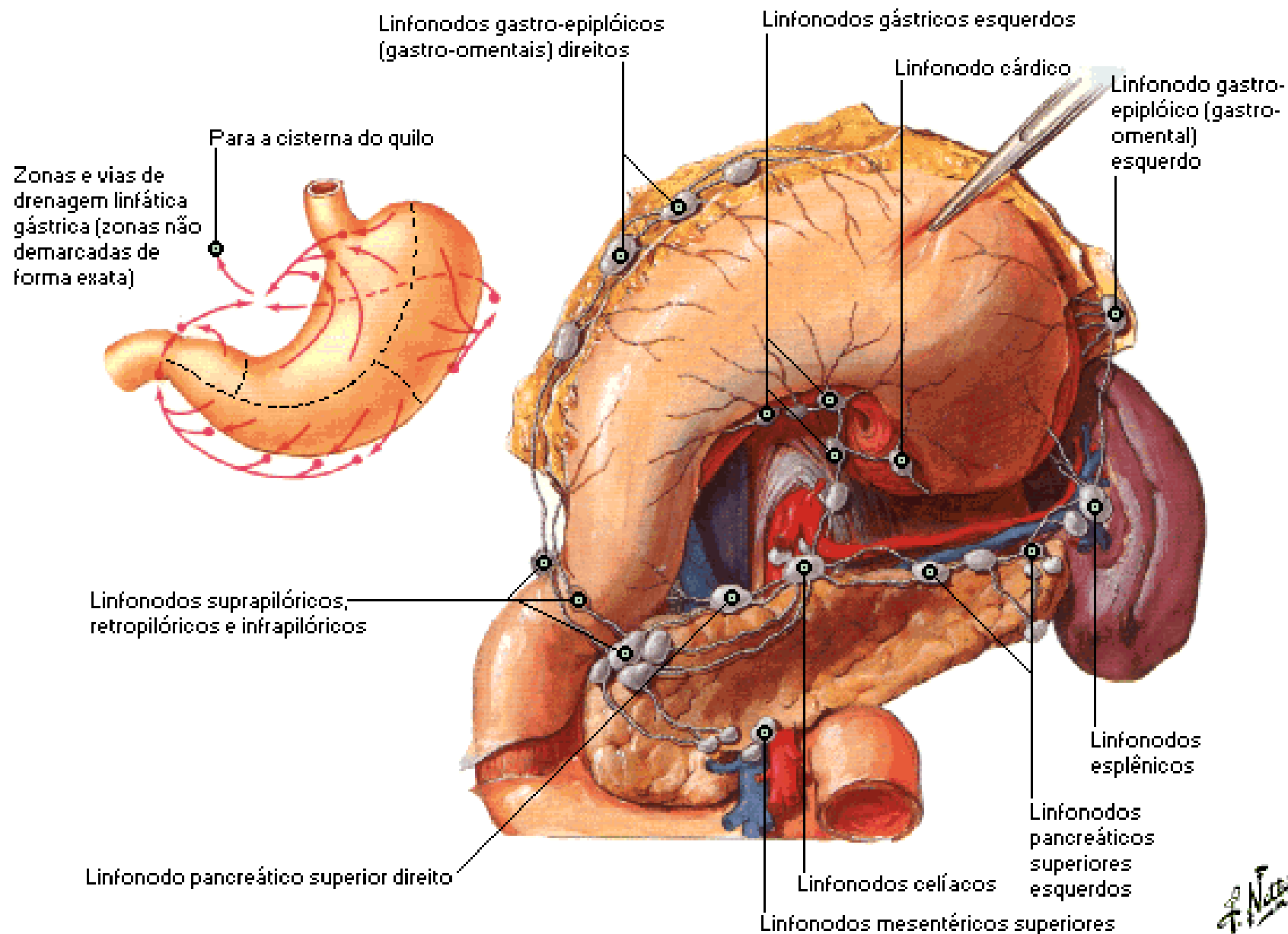
Estenose congênita da veia porta

Vasos Linfáticos e Linfonodos do Estômago

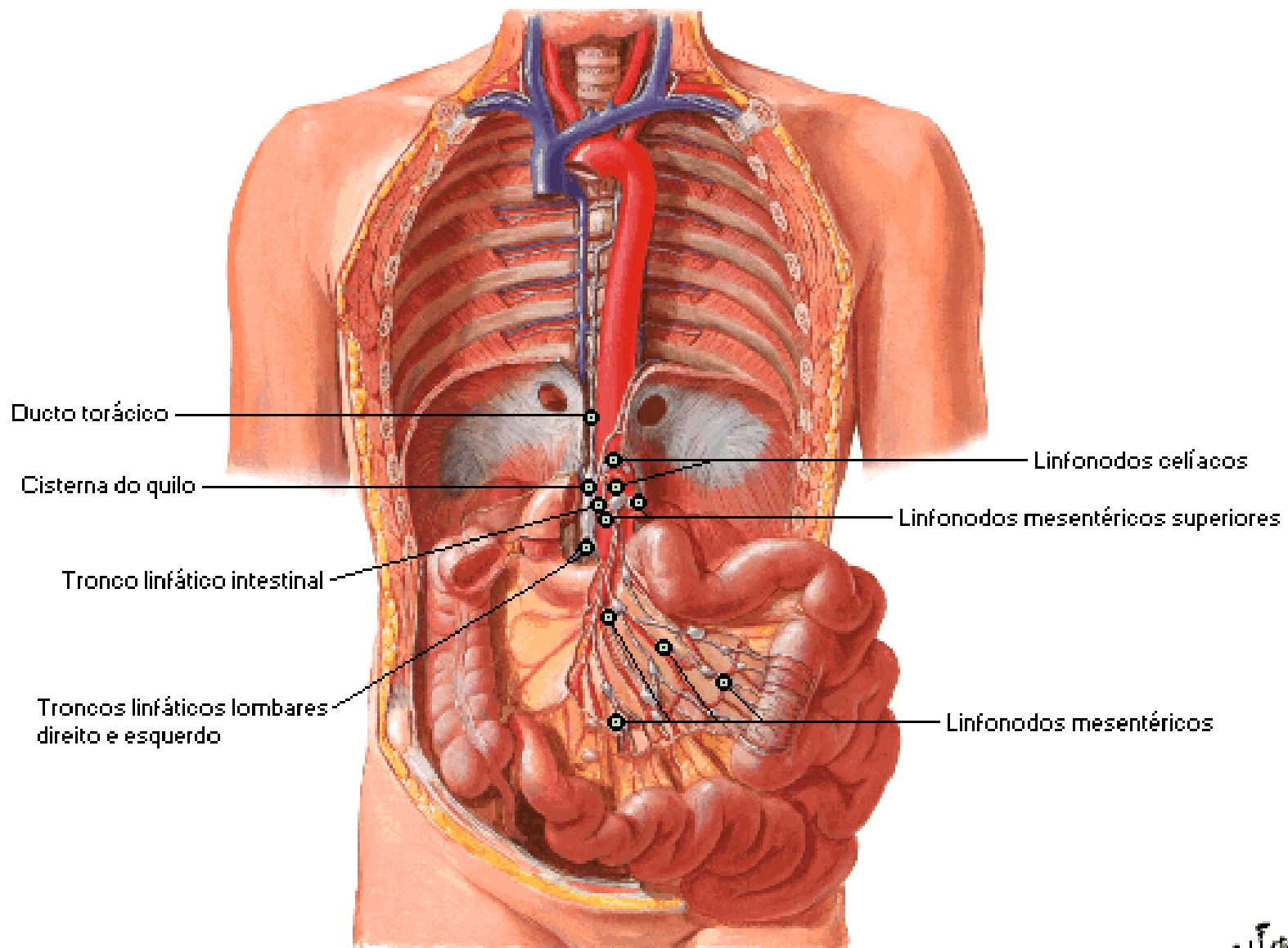


Vasos Linfáticos e Linfonodos do Estômago

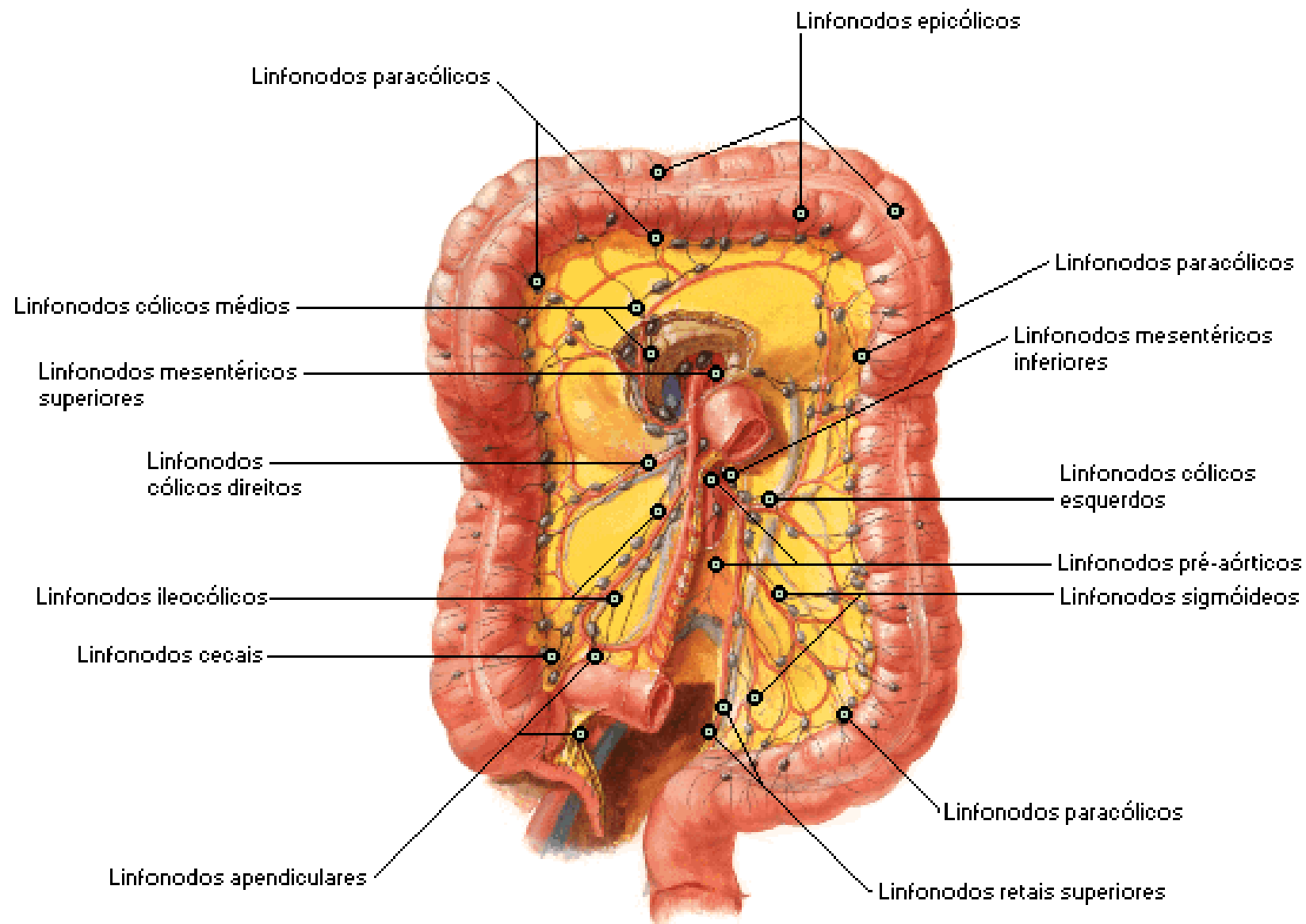
Estômago Refletido



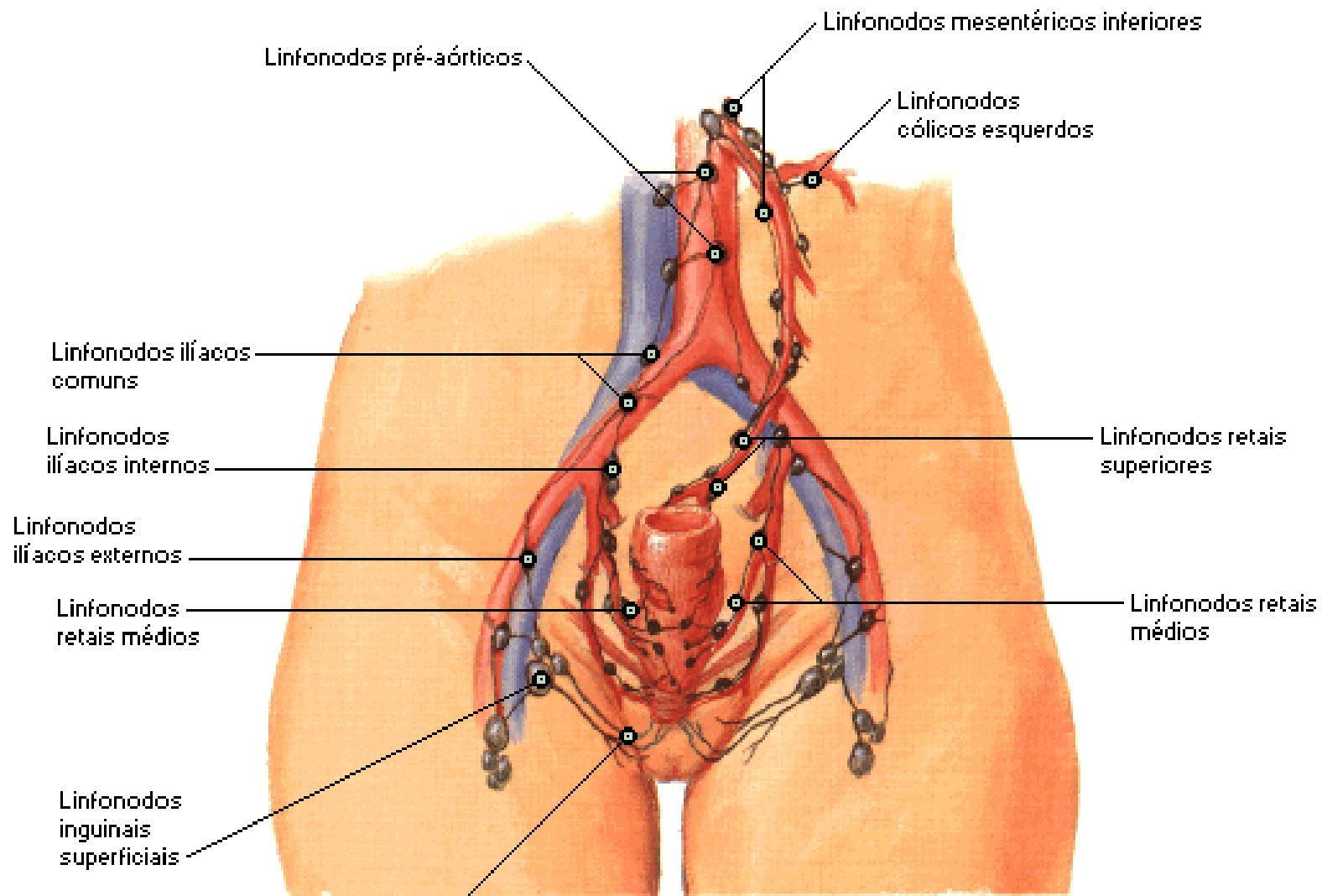
Vasos Linfáticos e Linfonodos do Intestino Delgado



Vasos Linfáticos e Linfonodos do Intestino Grosso



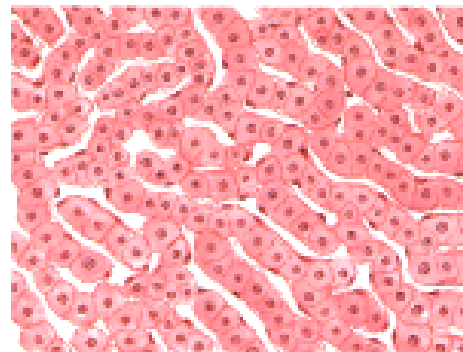
Vasos Linfáticos e Linfonodos do Intestino Grosso [Continuação]



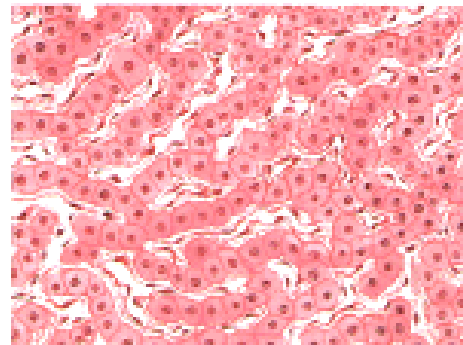
Vasos linfáticos anais e perianais
(drenam principalmente para os
linfonodos inguinais)

Vasos Linfáticos e Linfonodos do Fígado

Histologia

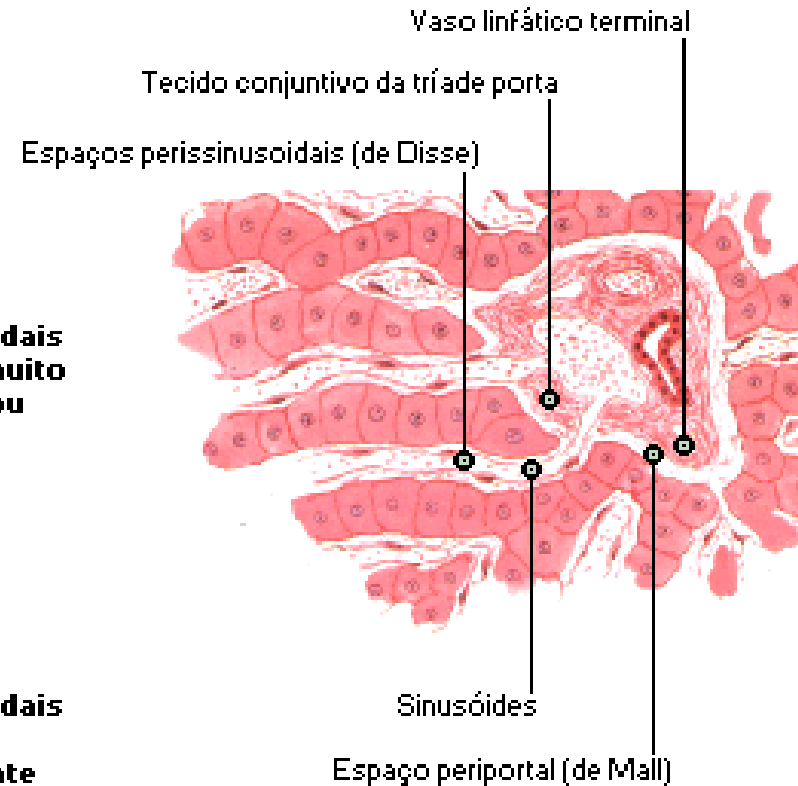


Espaços perissinusoidais (de Disse) muito estrelados ou obliterados

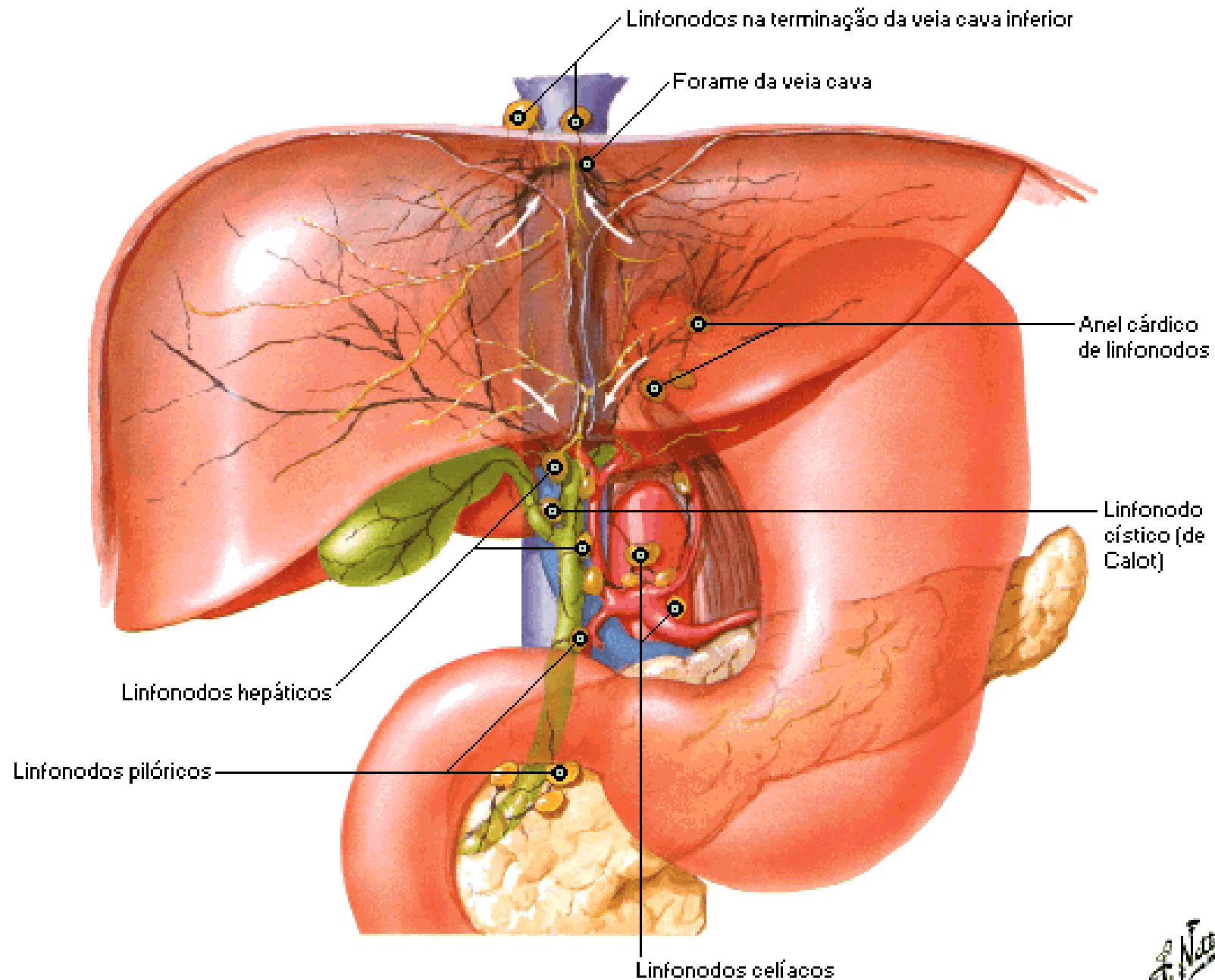


Espaços perissinusoidais (de Disse) marcadamente aumentados

Secções em pequeno aumento do fígado

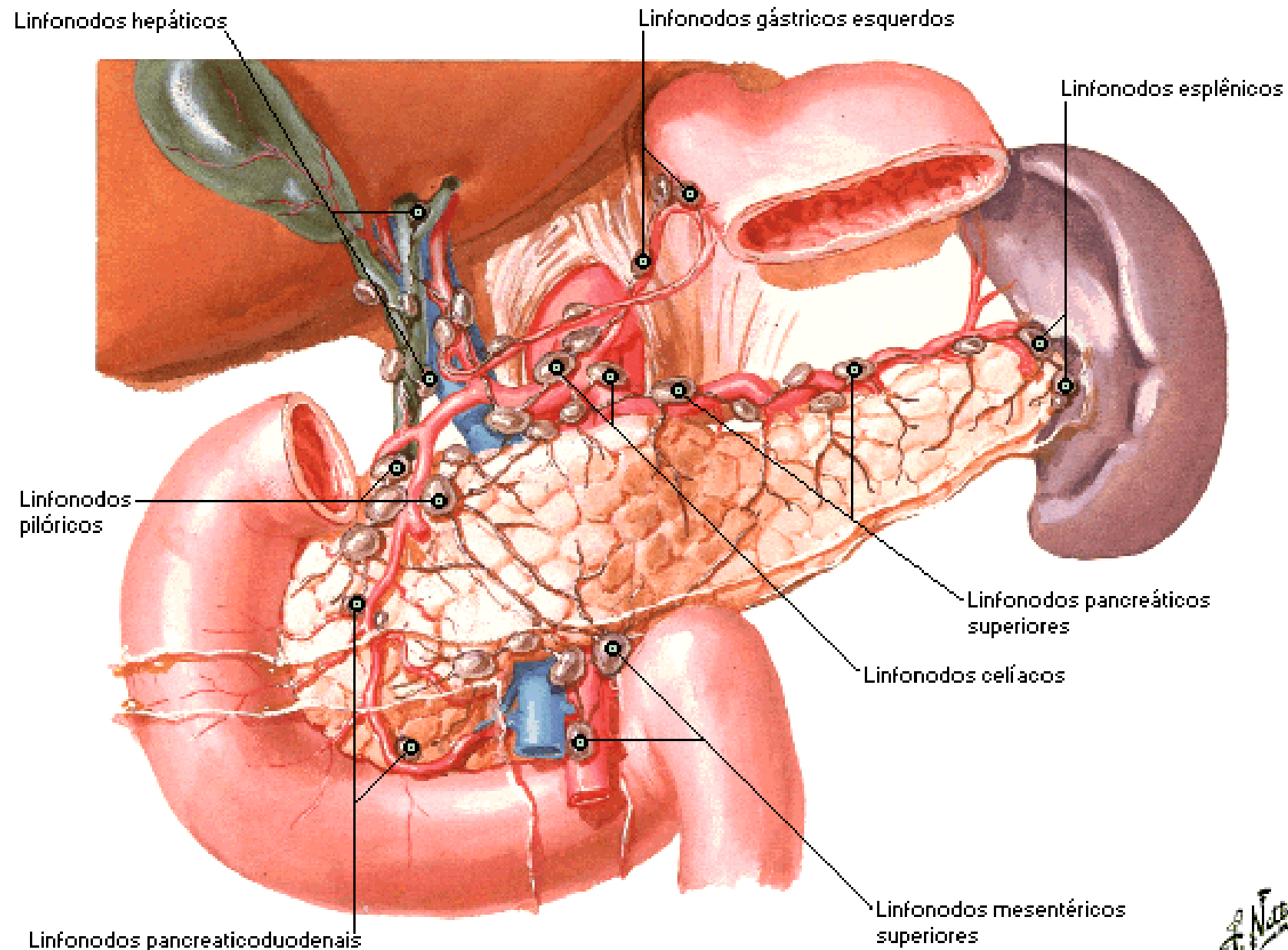


Vasos Linfáticos e Linfonodos do Pâncreas



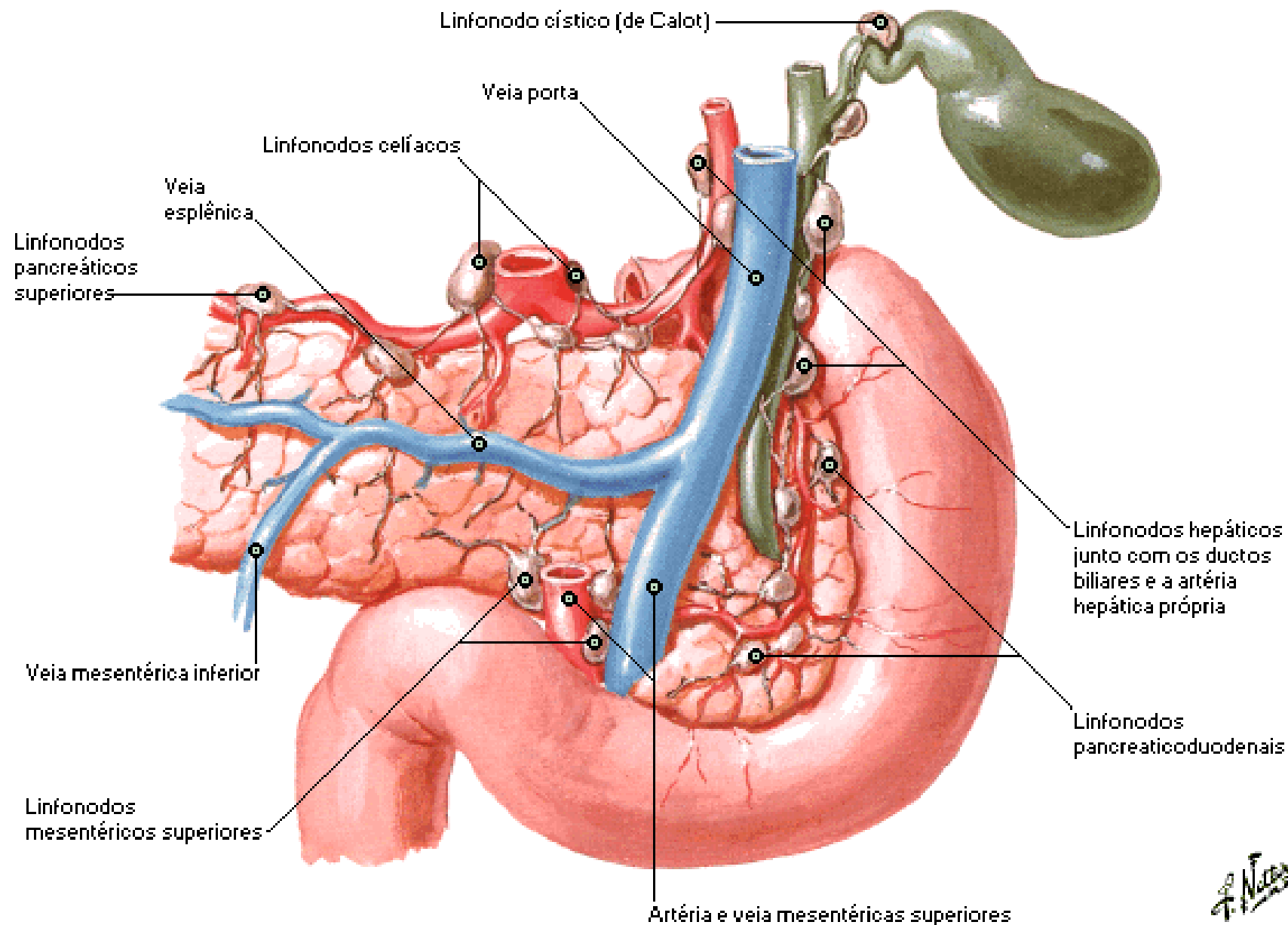
Vasos Linfáticos e Linfonodos do Pâncreas

Vista Anterior

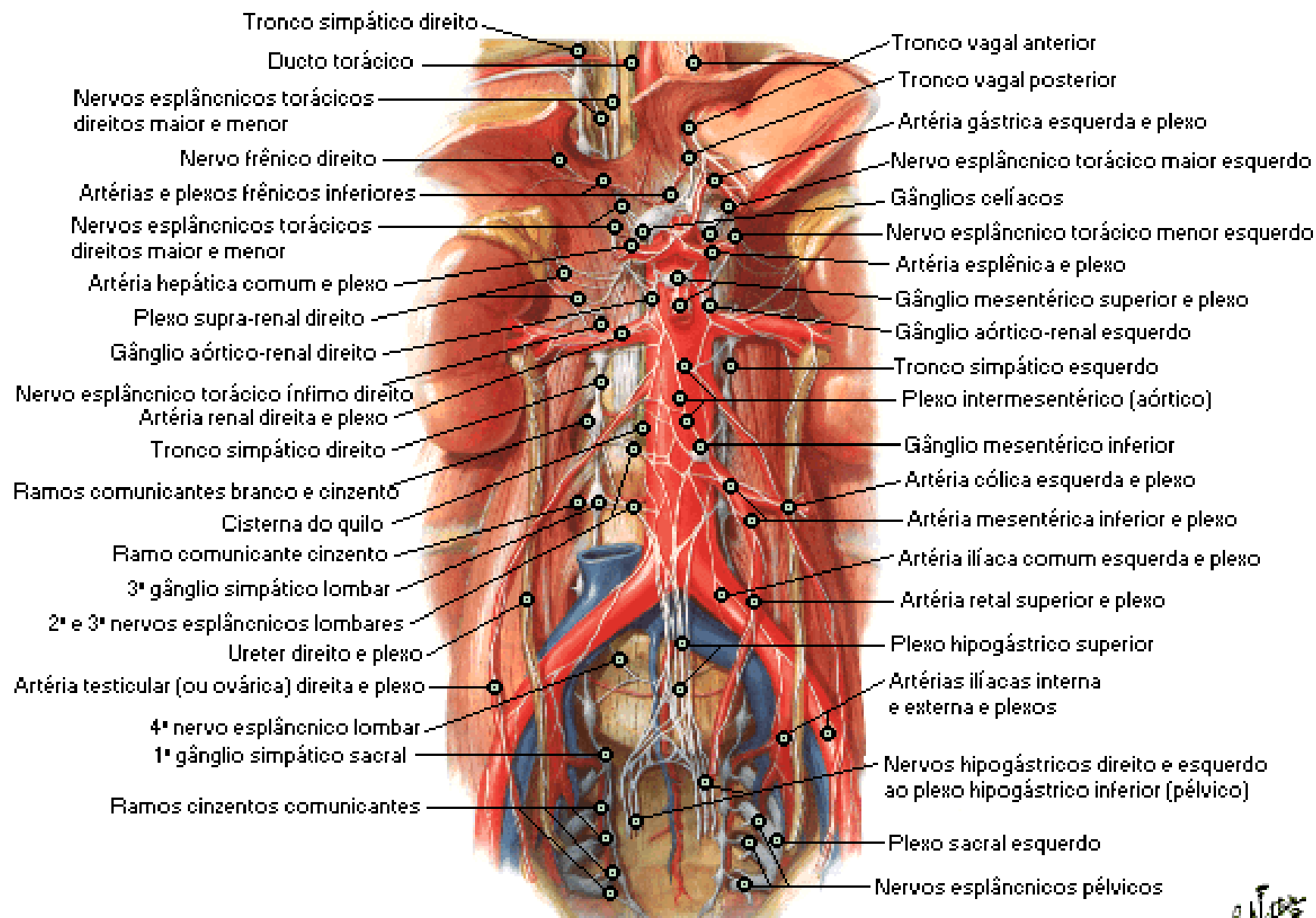


Vasos Linfáticos e Linfonodos do Pâncreas

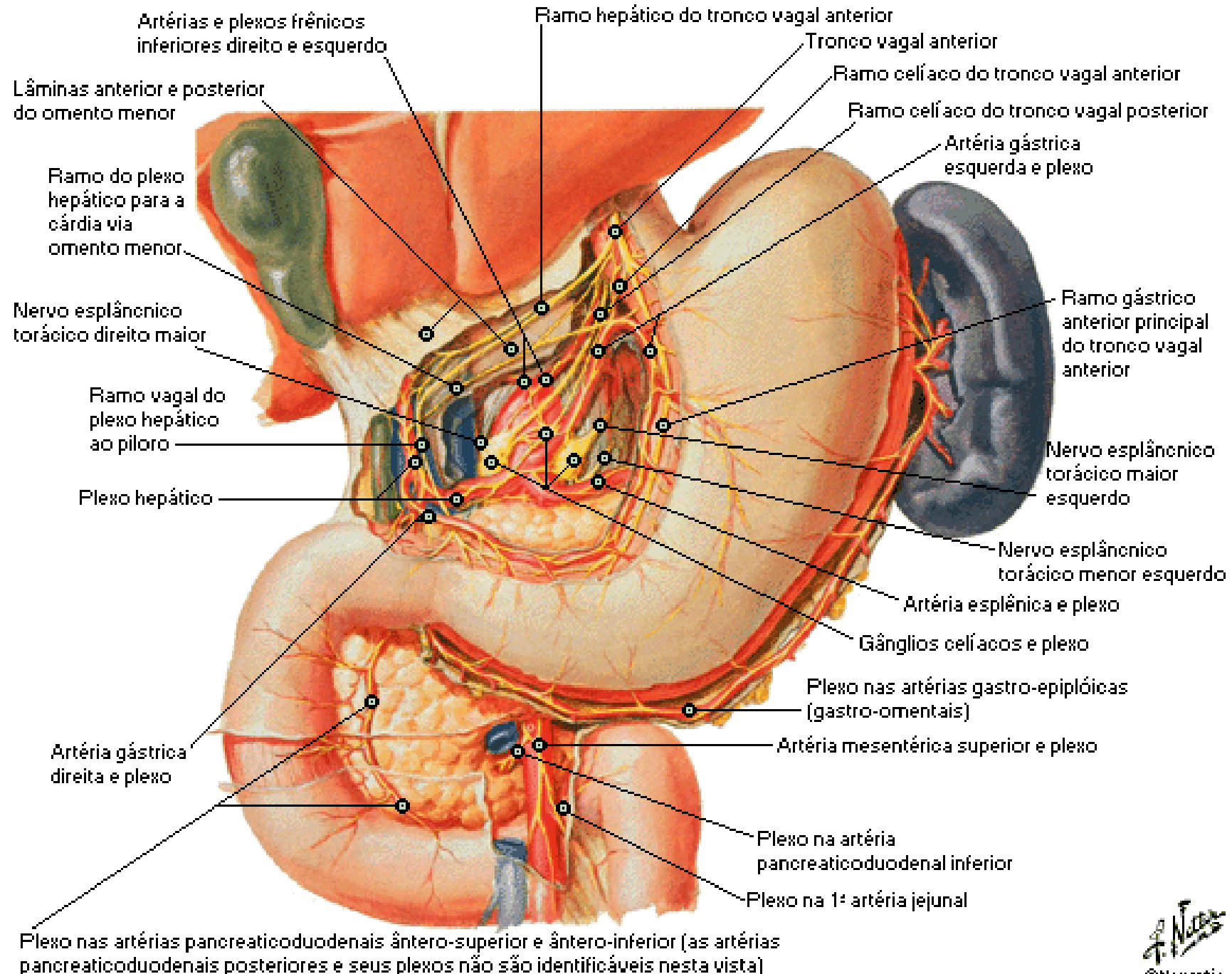
Vista Posterior



Nervos Autônomos e Gânglios do Abdomine

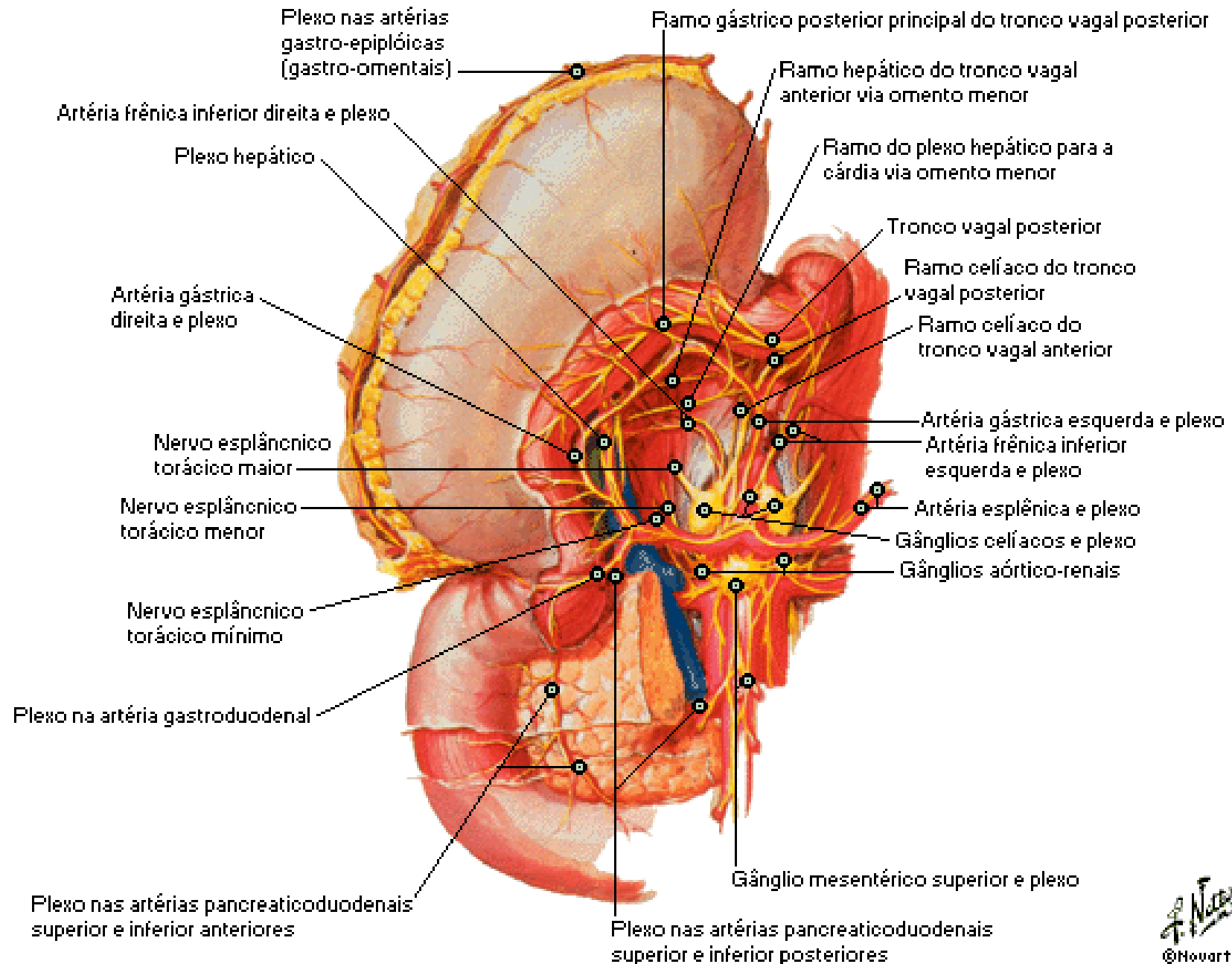


Nervos do Estômago e Duodeno



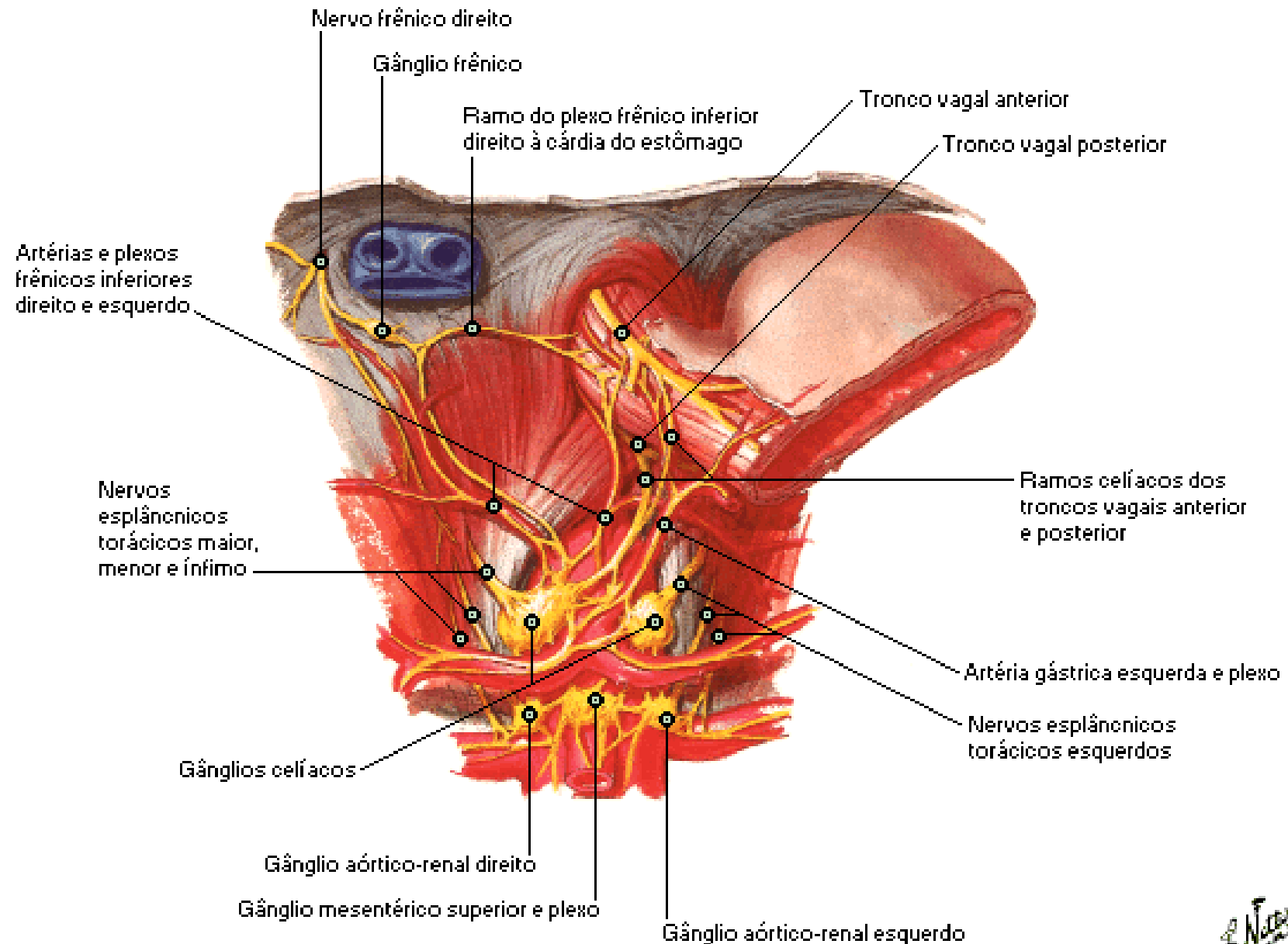
Nervos do Estômago e Duodeno

Vista com o Estômago Rebatido



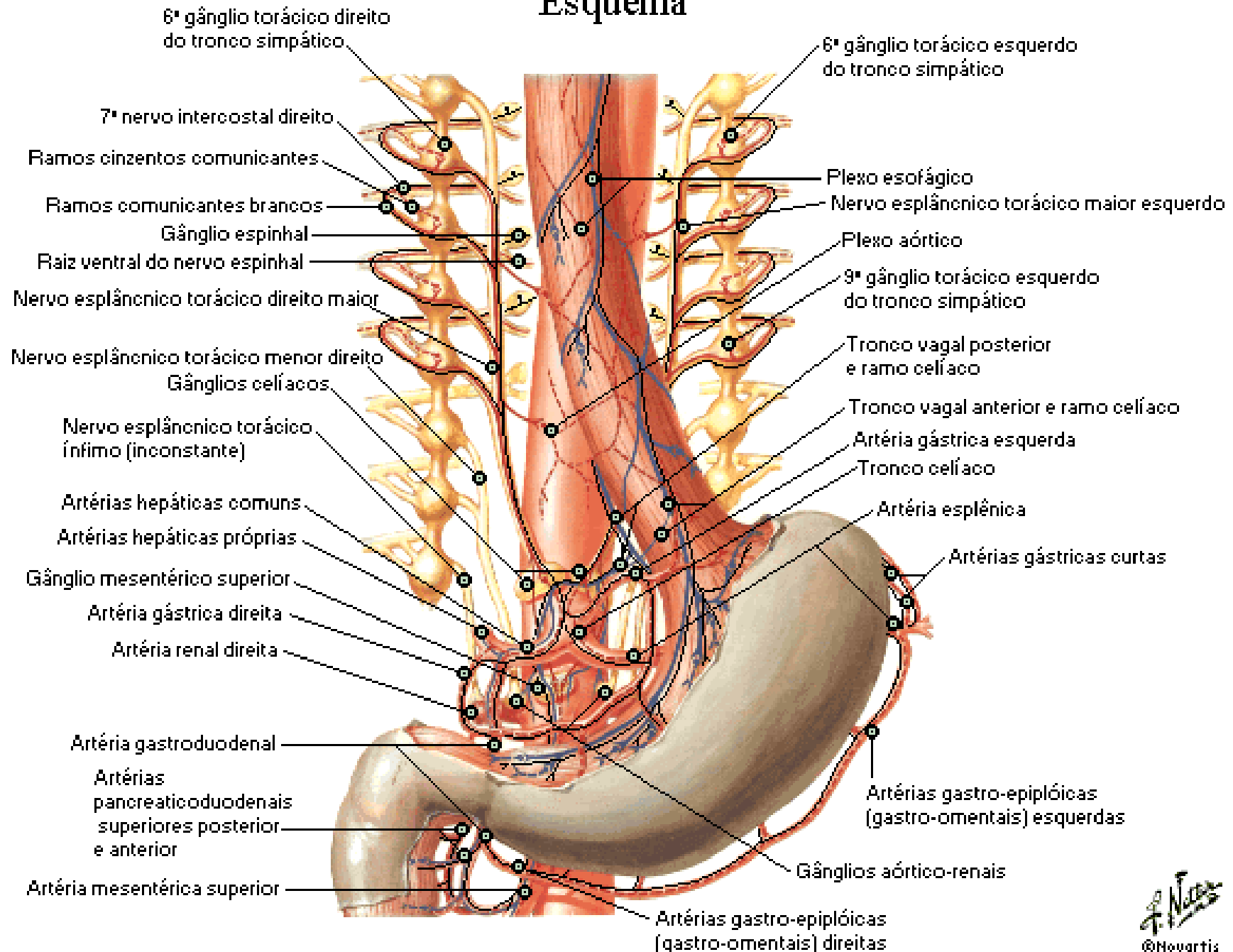
Nervos do Estômago e Duodeno

Região Hiatal

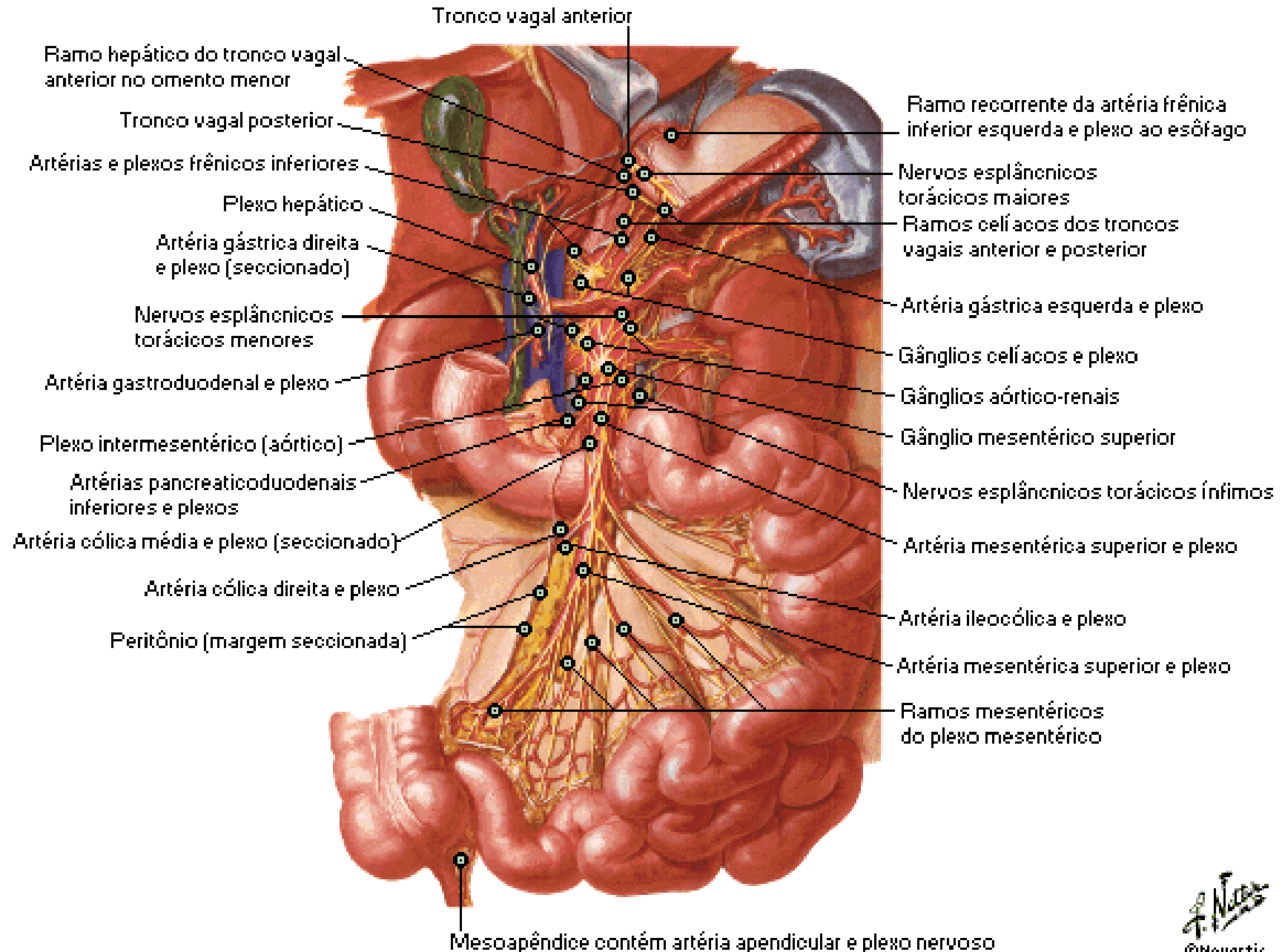


Inervação do Estômago e Duodeno

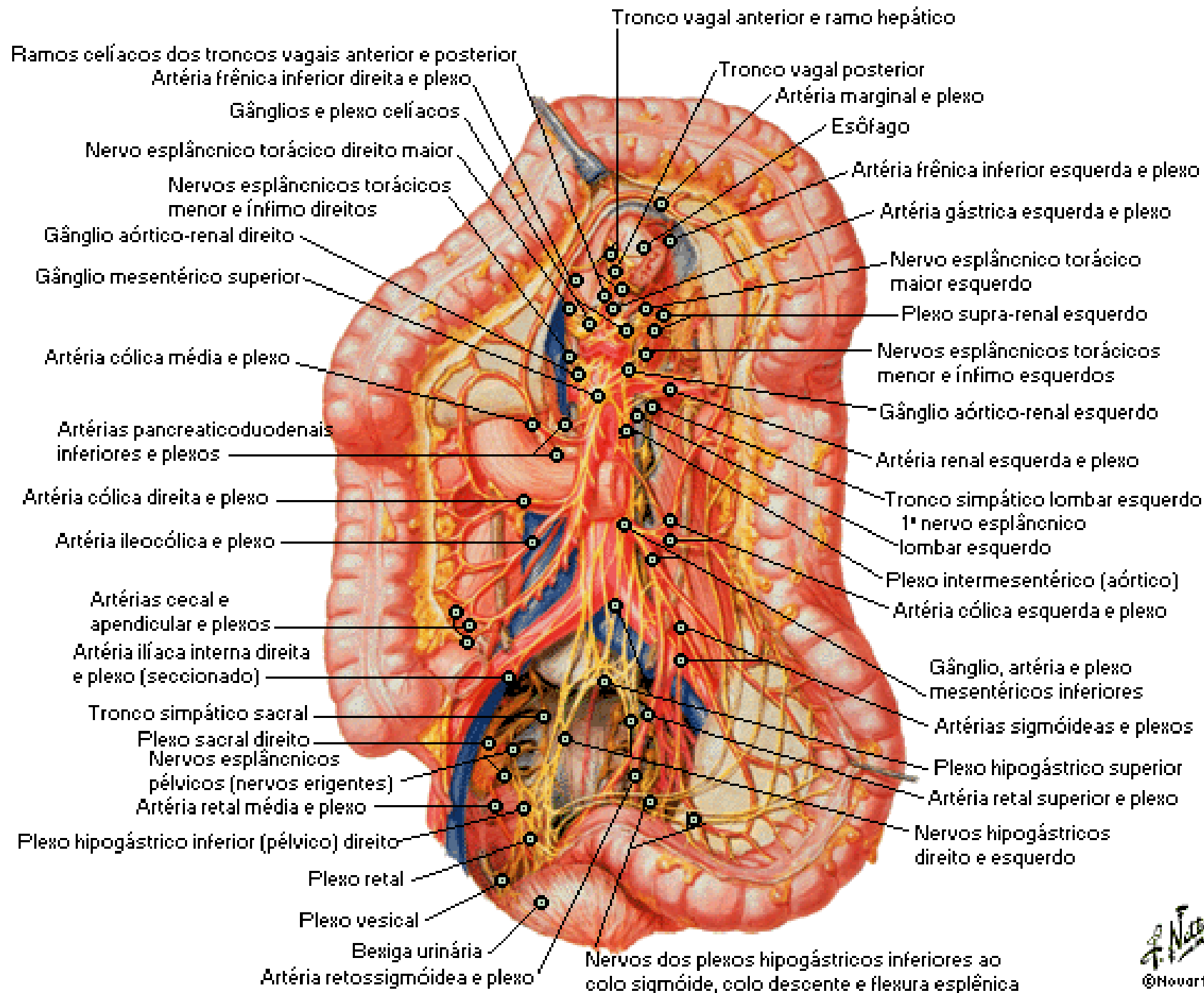
Esquema



Nervos do Intestino Delgado

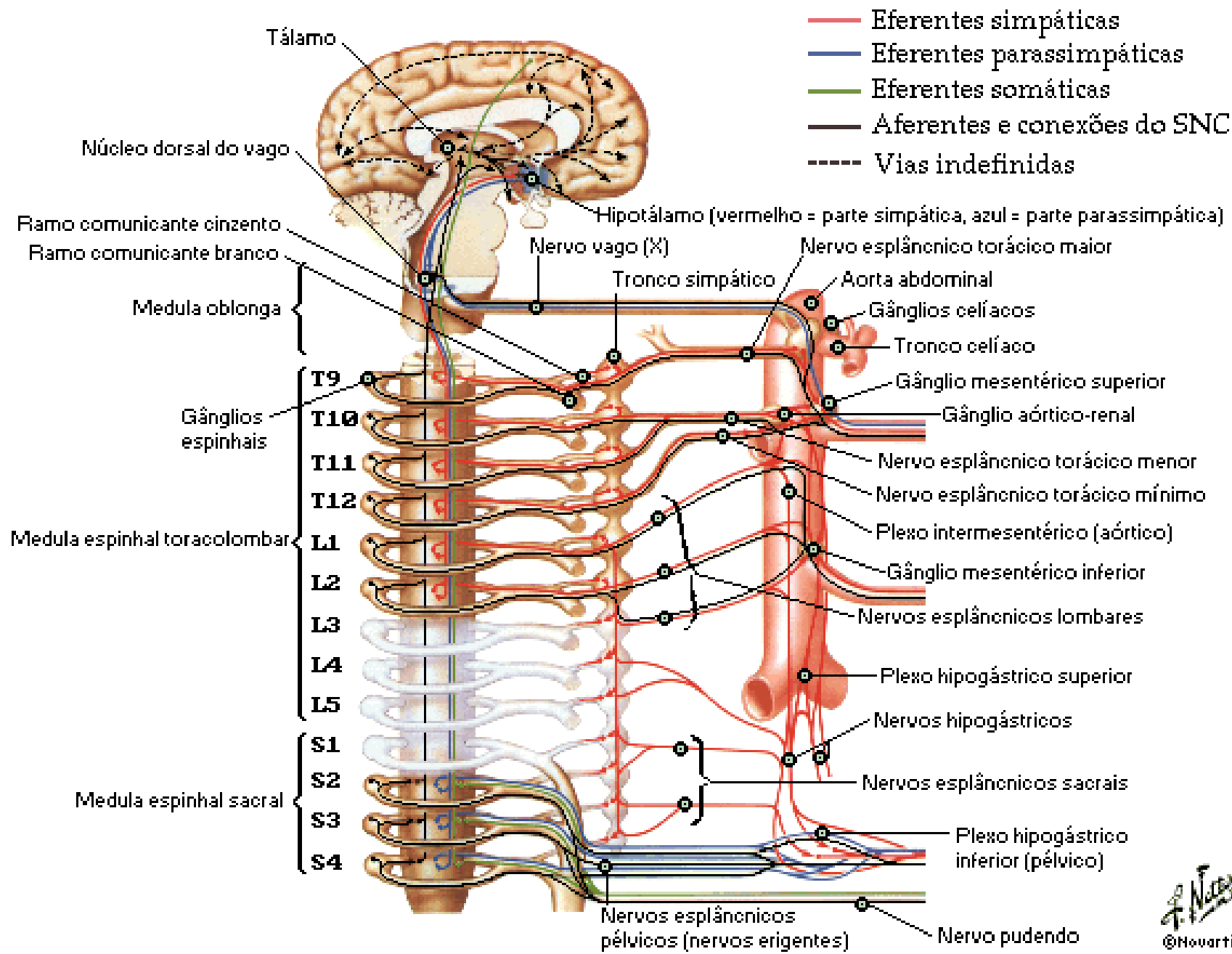


Nervos do Intestino Grosso



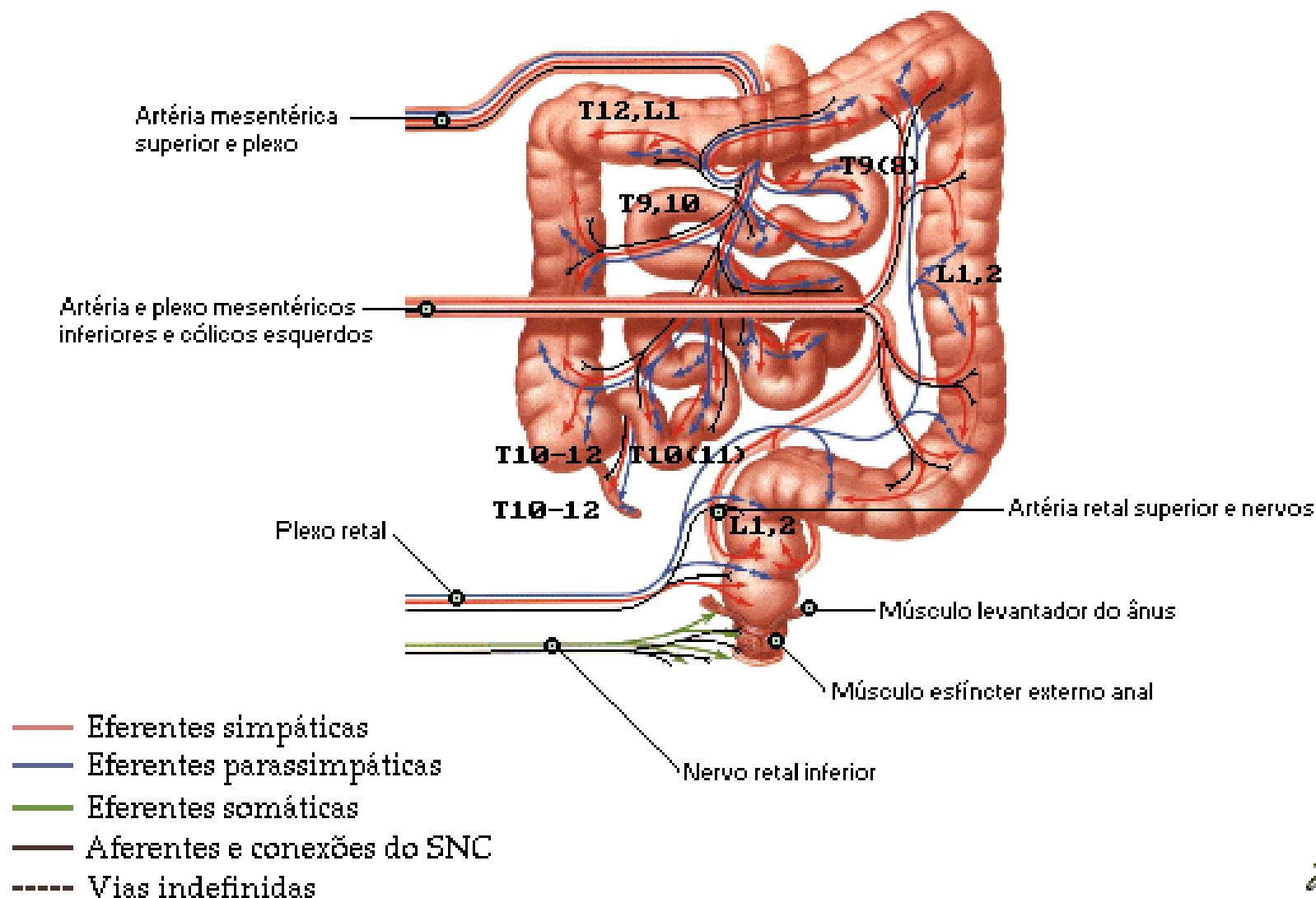
Inervação dos Intestinos Delgado e Grosso

Lado Esquerdo do Esquema



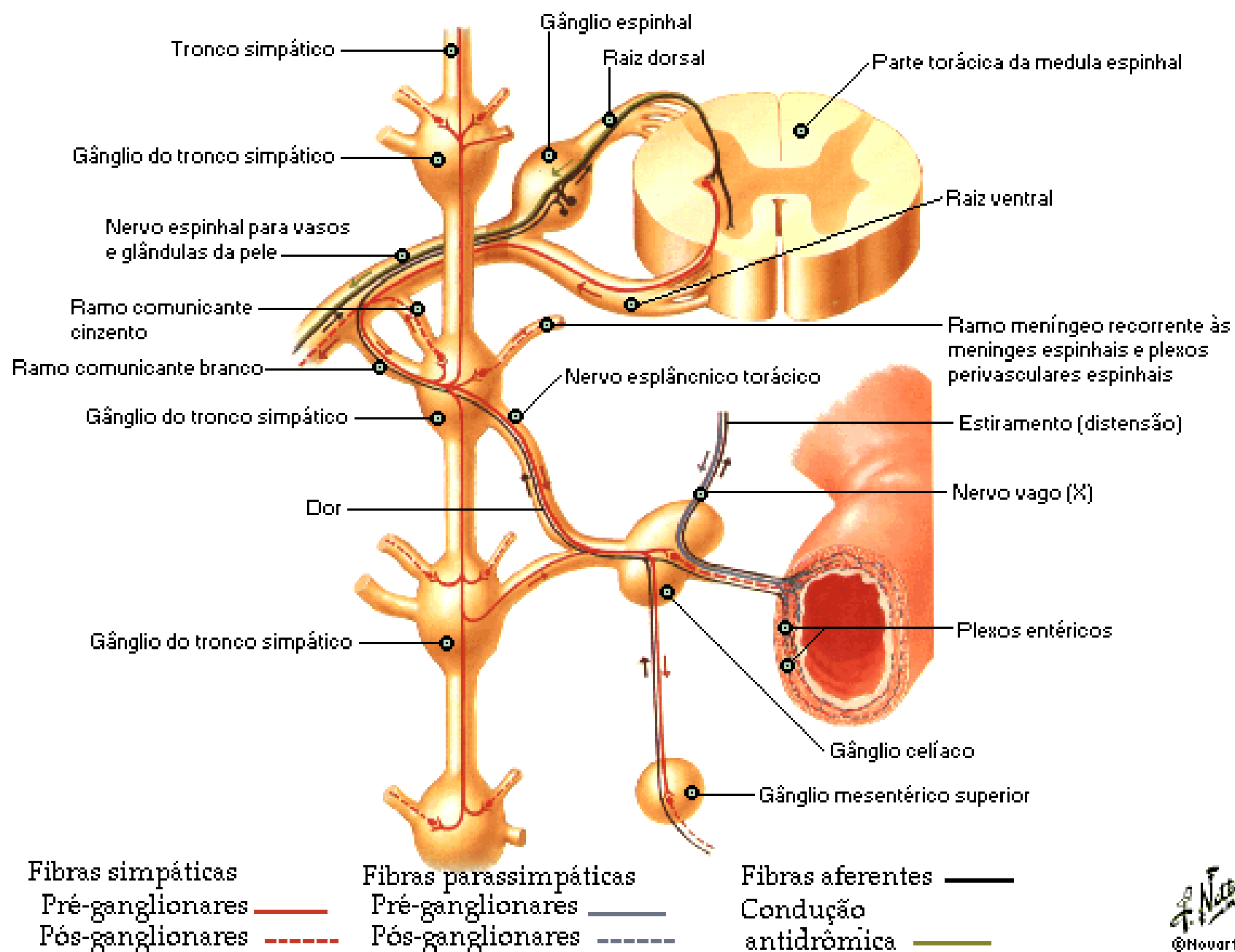
Inervação dos Intestinos Delgado e Grosso

Lado Direito do Esquema

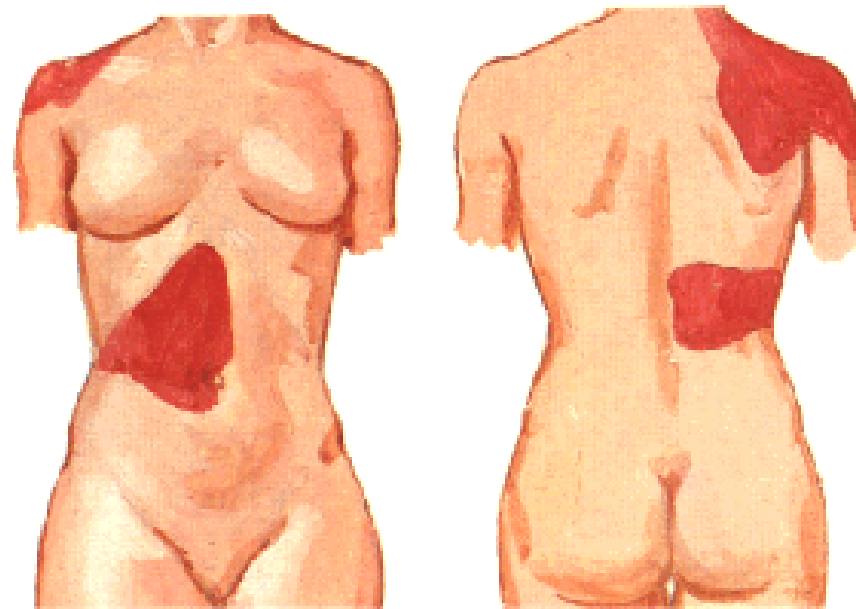


Vias Reflexas Autônomas

Esquema

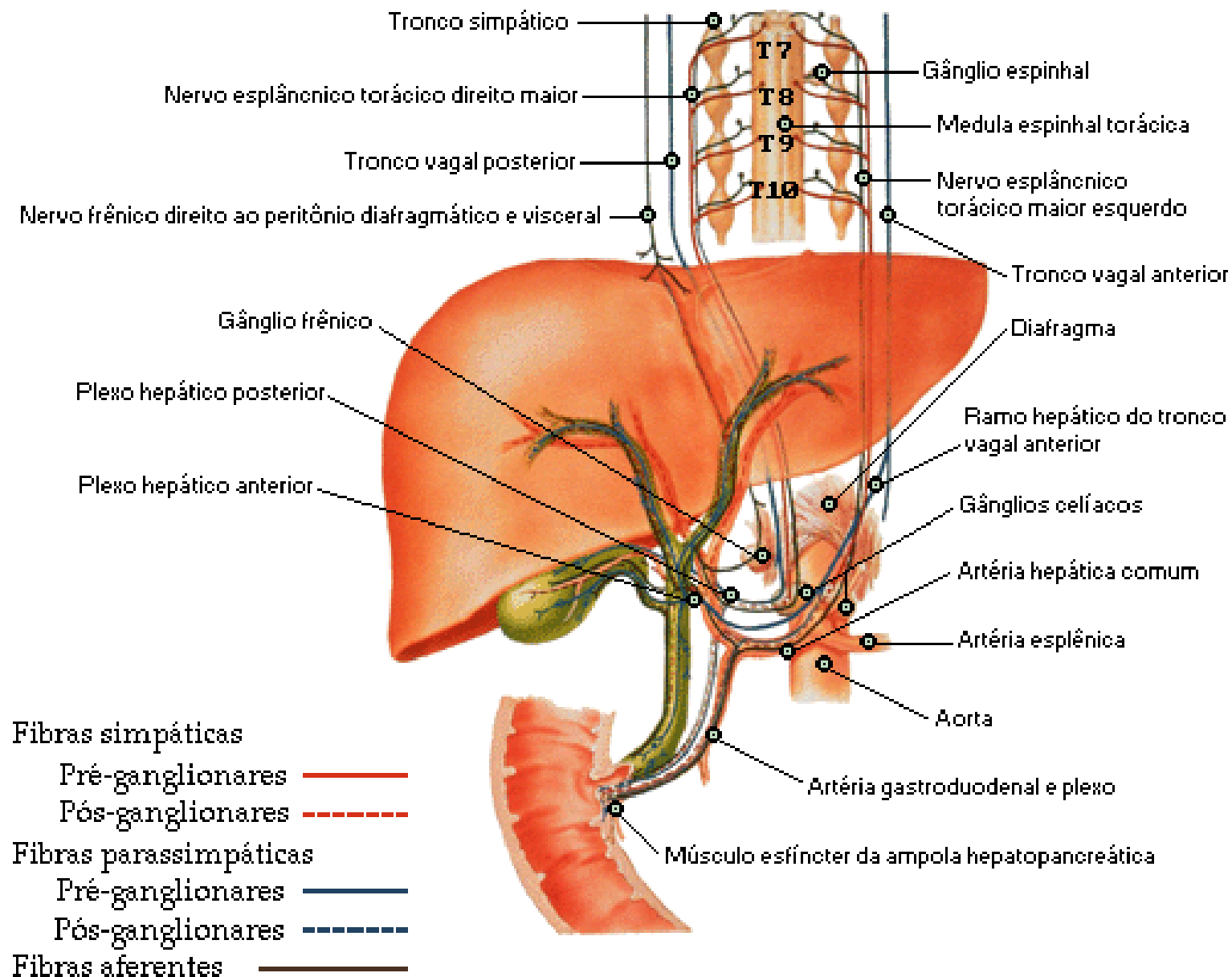


Áreas Comuns de Dor Referidas na Doença Biliar



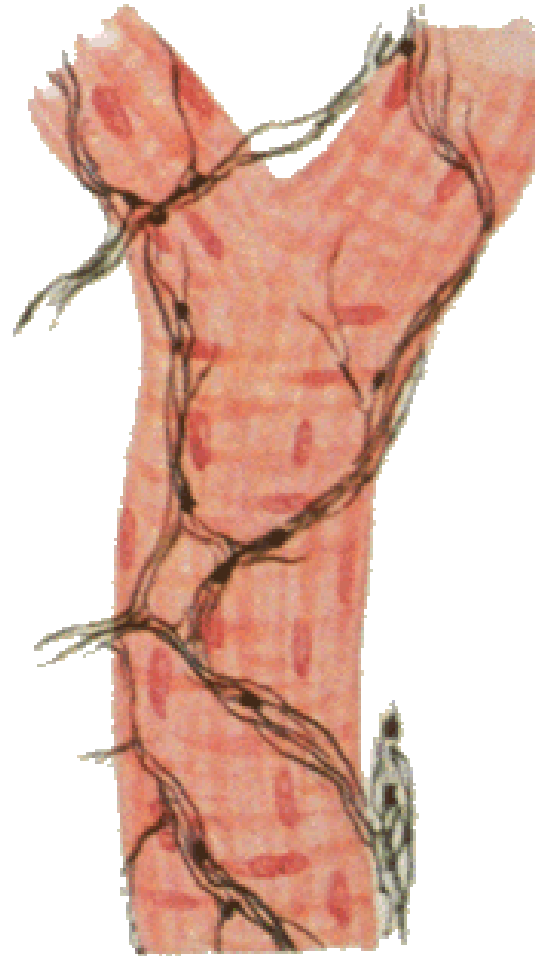
Inervação do Fígado e Trato Biliar

Esquema


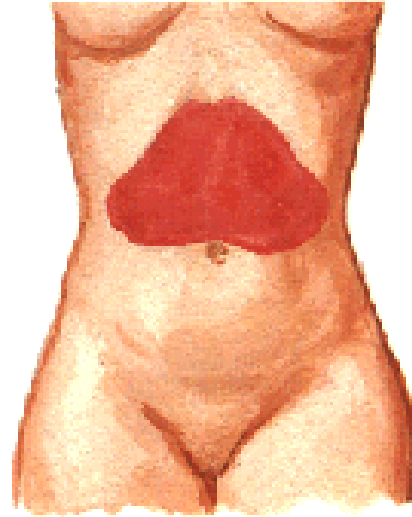


Inervação do Fígado

Ramificação das Fibras Nervosas ao Redor do Ramo da Artéria

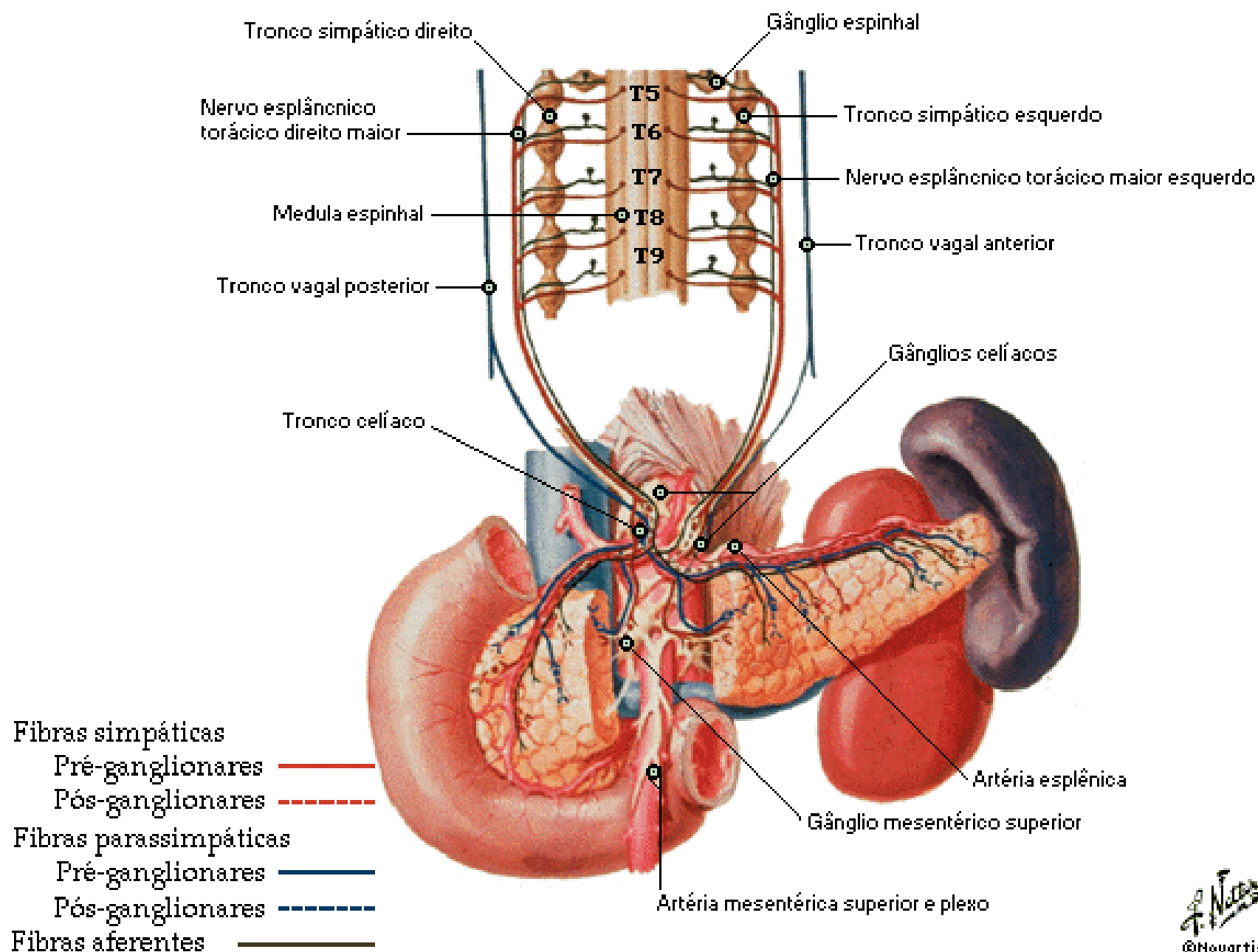


Áreas Comuns de Dor Pancreática



Inervação do Pâncreas

Esquema



Esquema do Suprimento Nervoso Intrínseco do Pâncreas

Fibras simpáticas

Pré-ganglionares ———

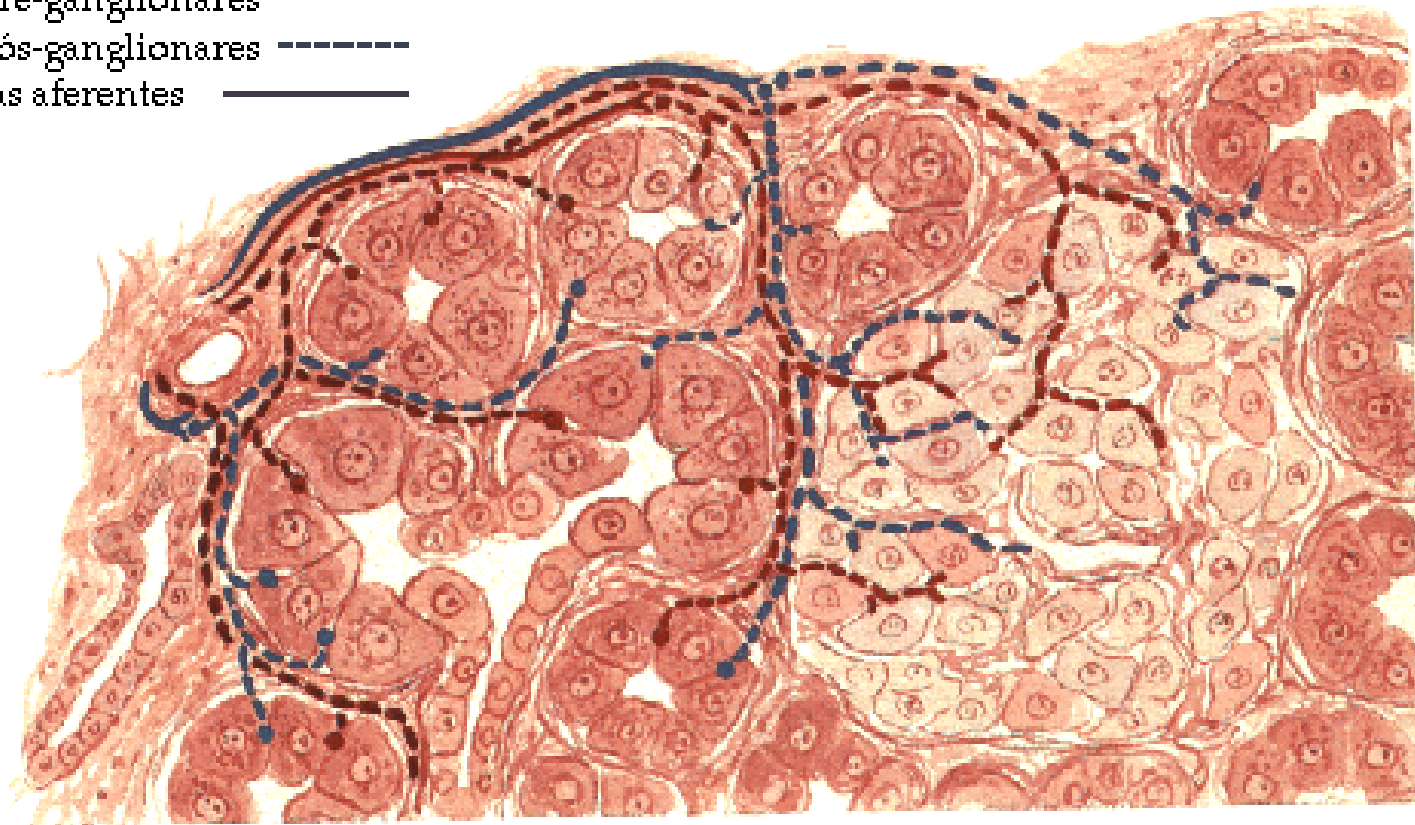
Pós-ganglionares - - - - -

Fibras parassimpáticas

Pré-ganglionares ———

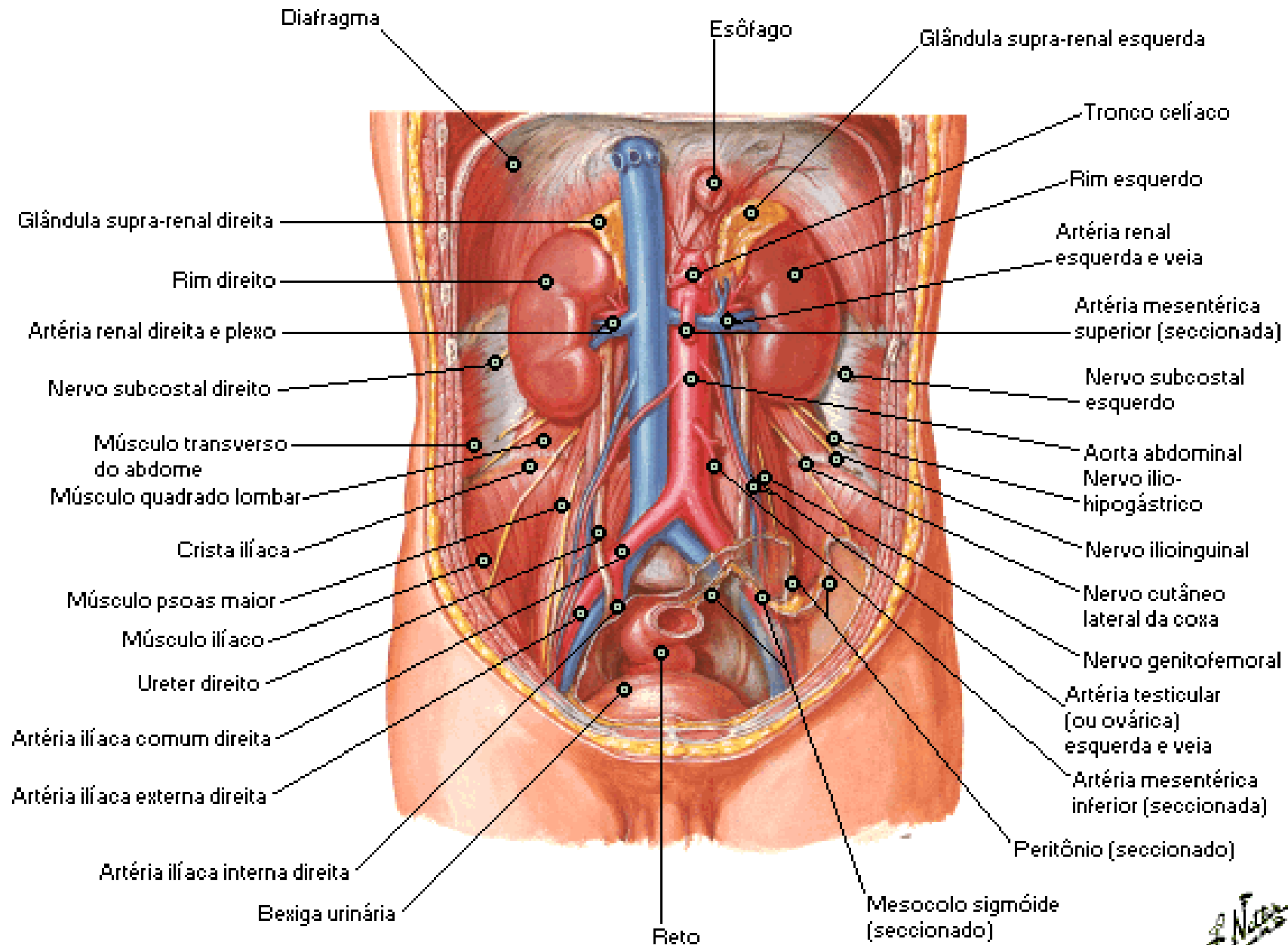
Pós-ganglionares - - - - -

Fibras aferentes ———



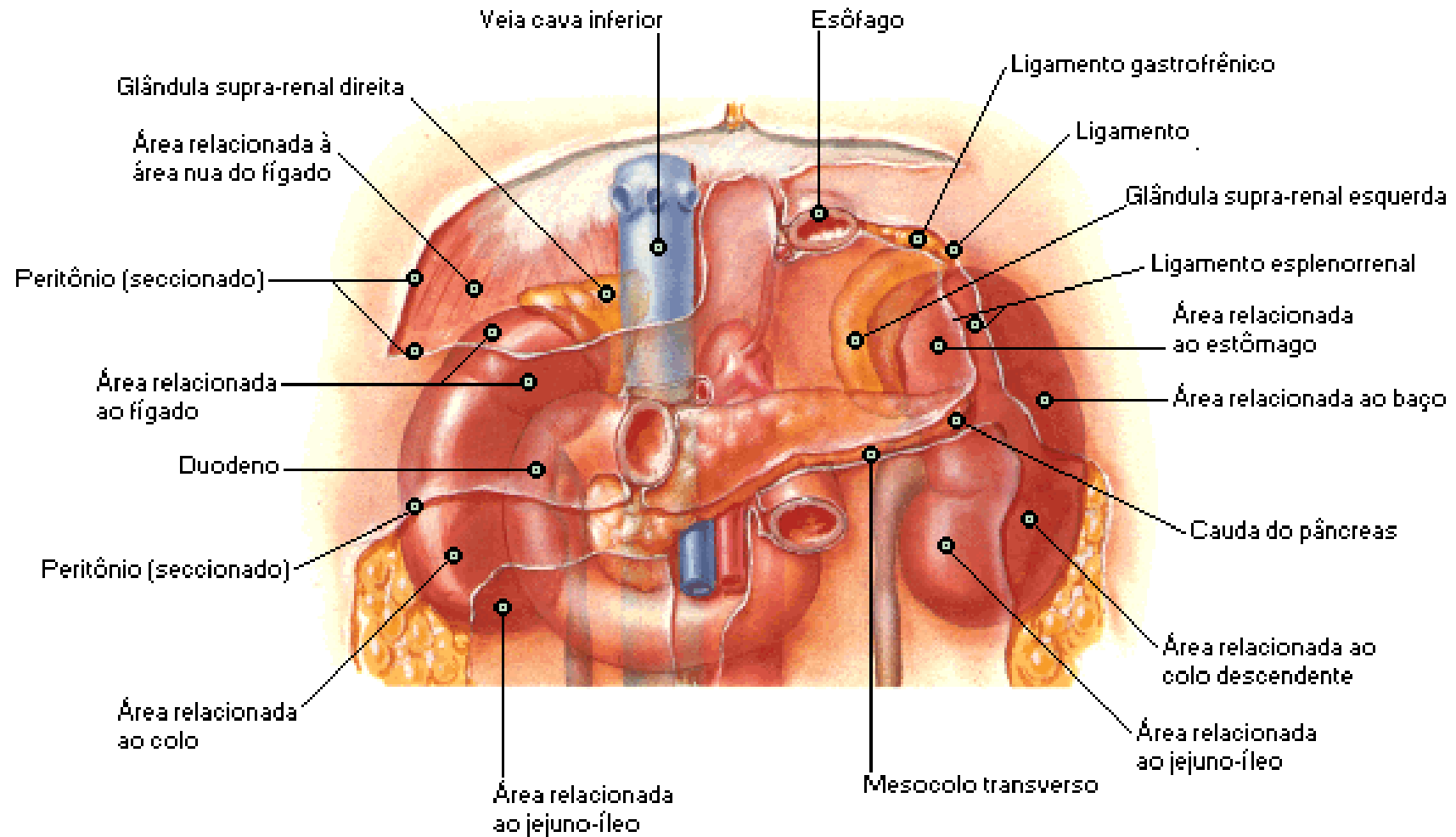
Rins in Situ

Vista Anterior



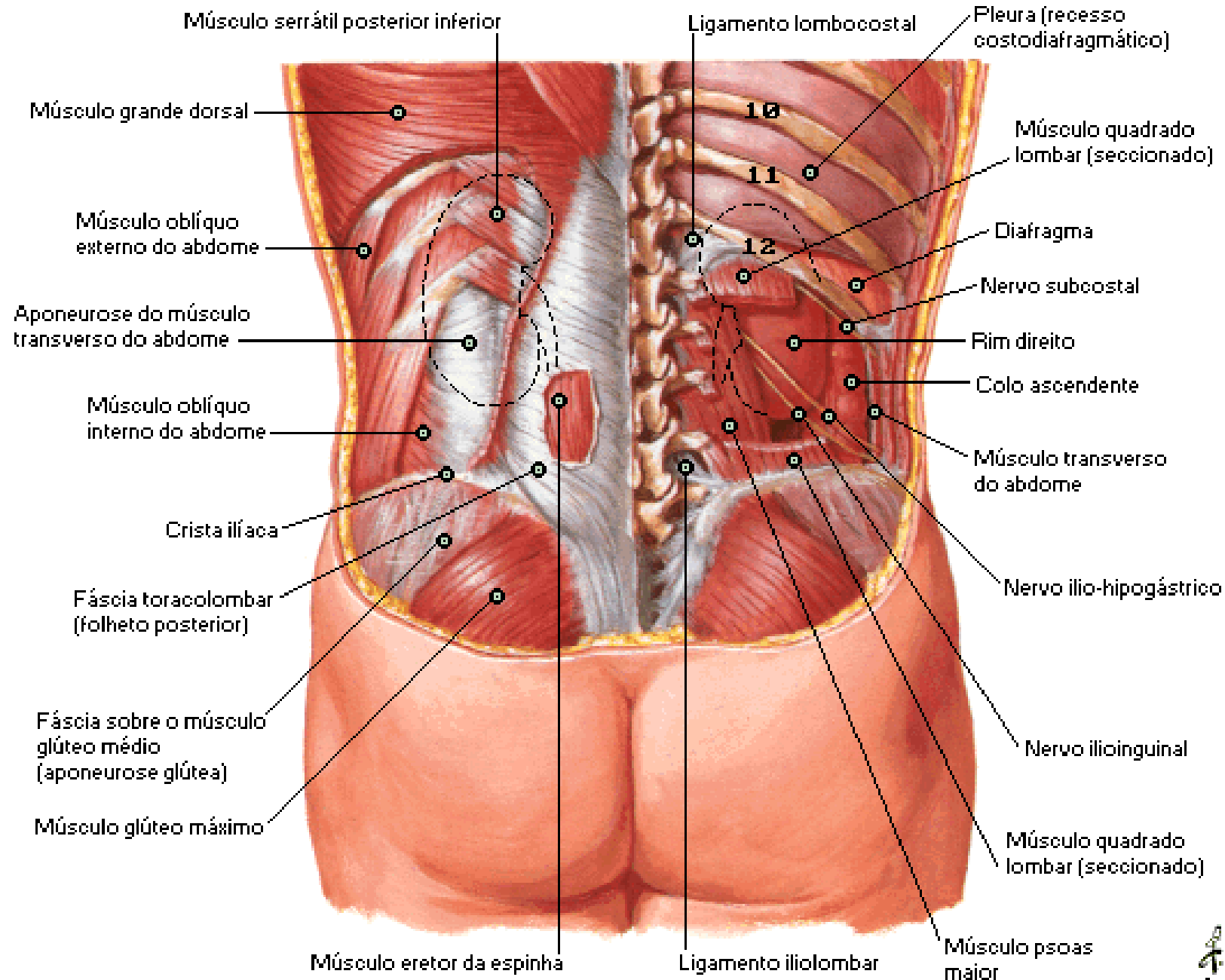
Rins in Situ

Relações Anteriores dos Rins



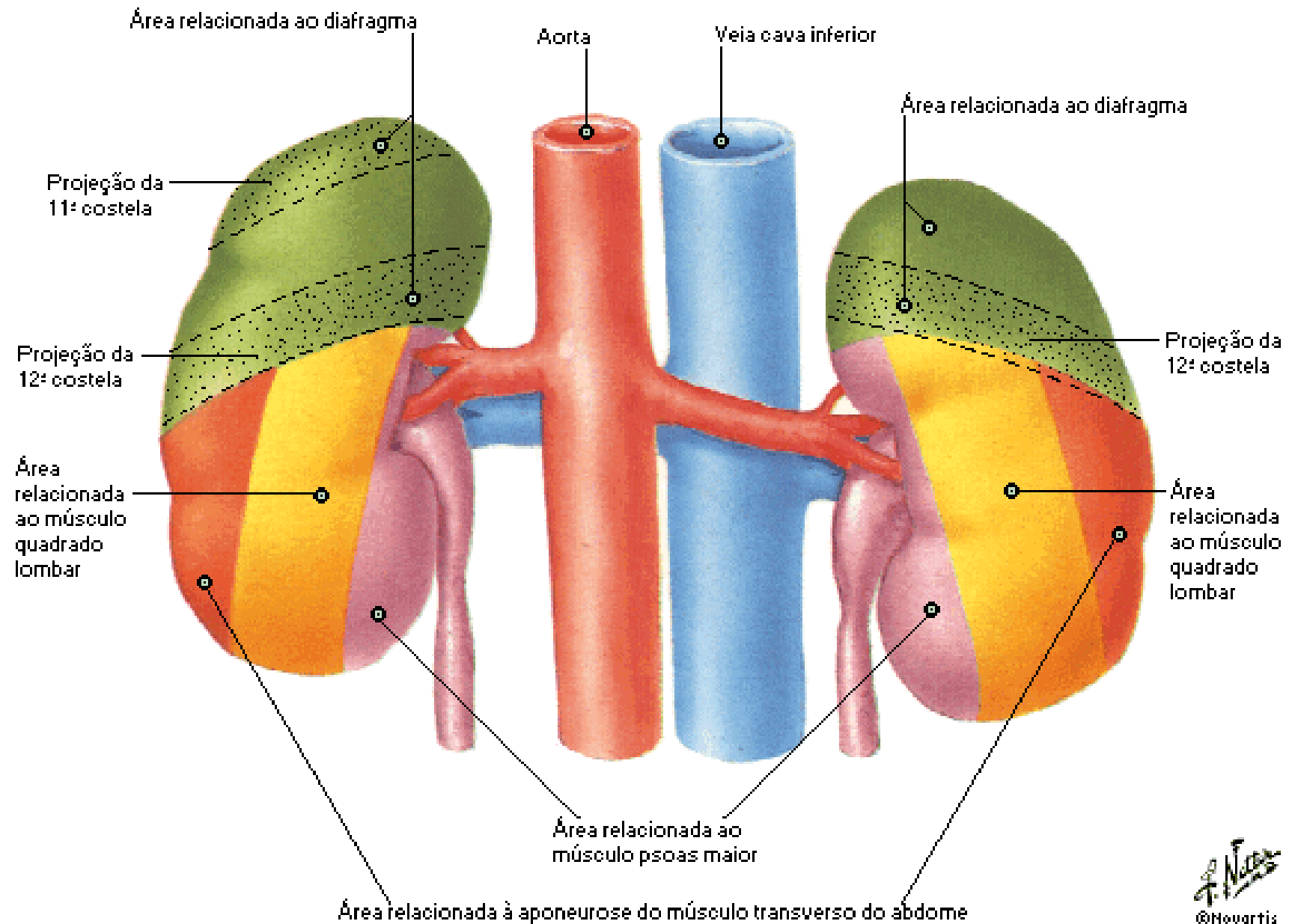
Rins in Situ

Vista Posterior

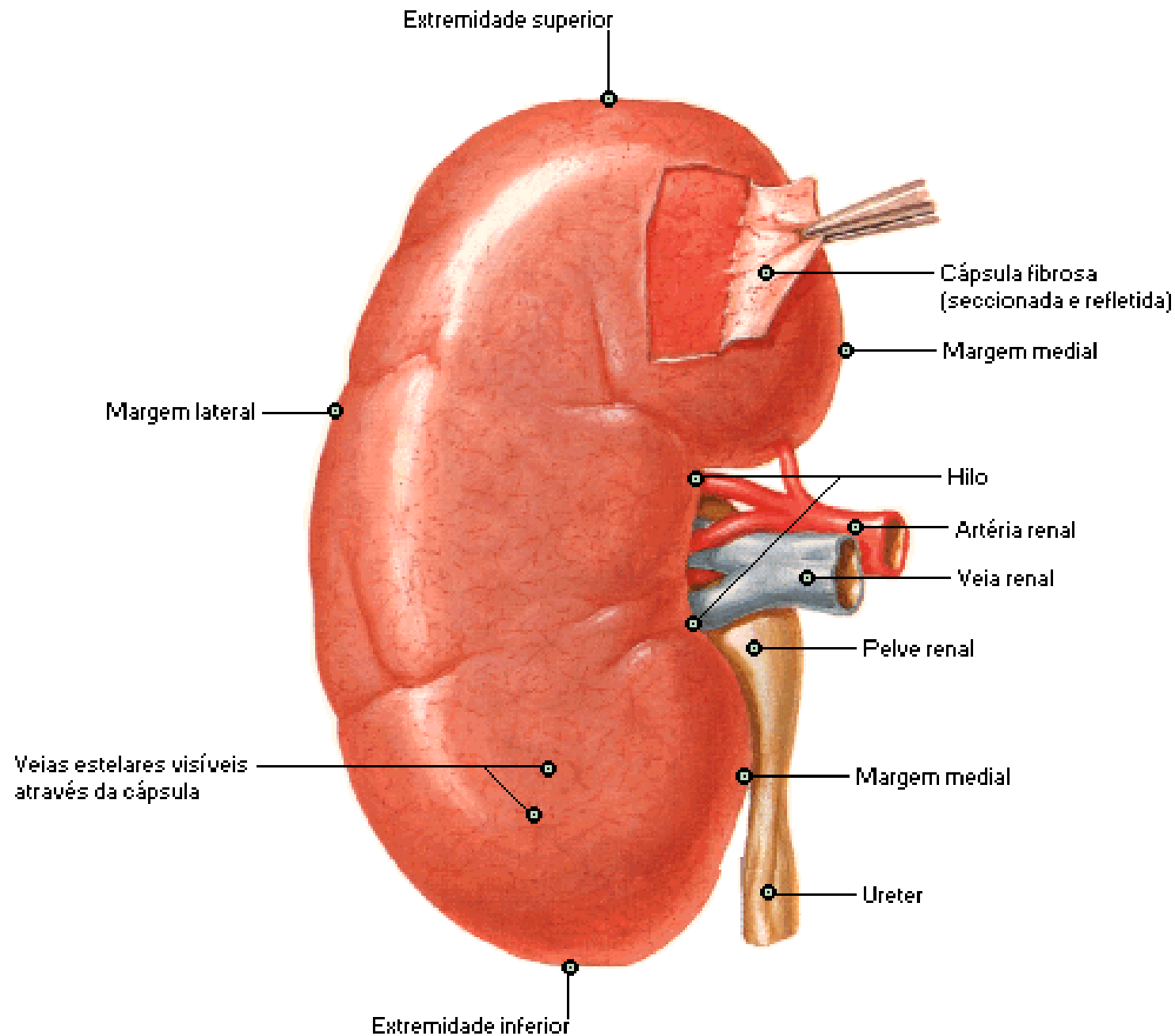


Rins in Situ

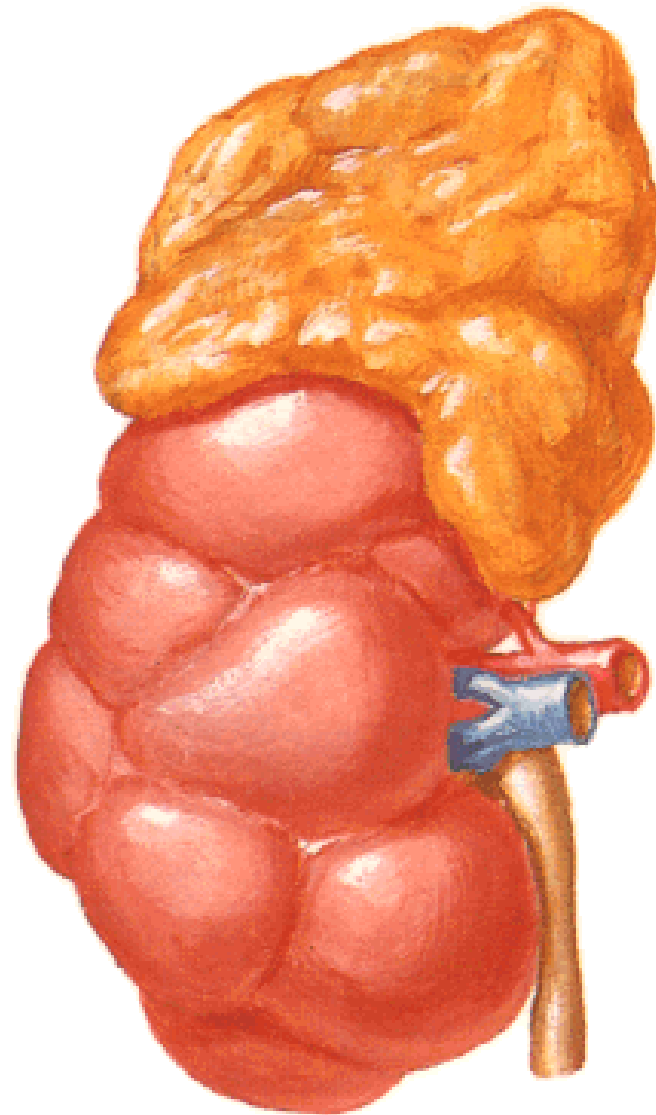
Relações Posteriores dos Rins



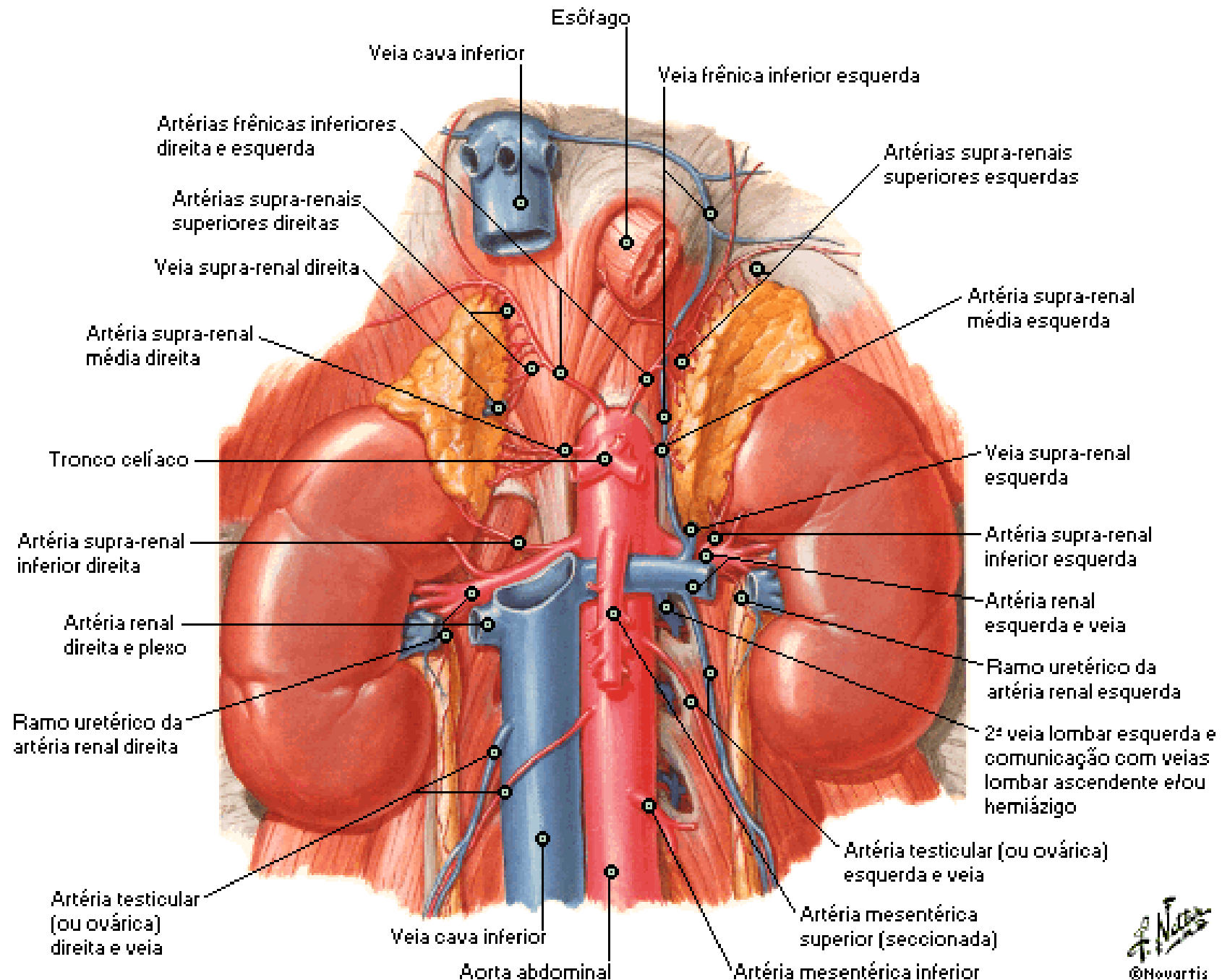
Face Anterior do Rim Direito



Glândula Supra-renal e Rim Lobado de Criança

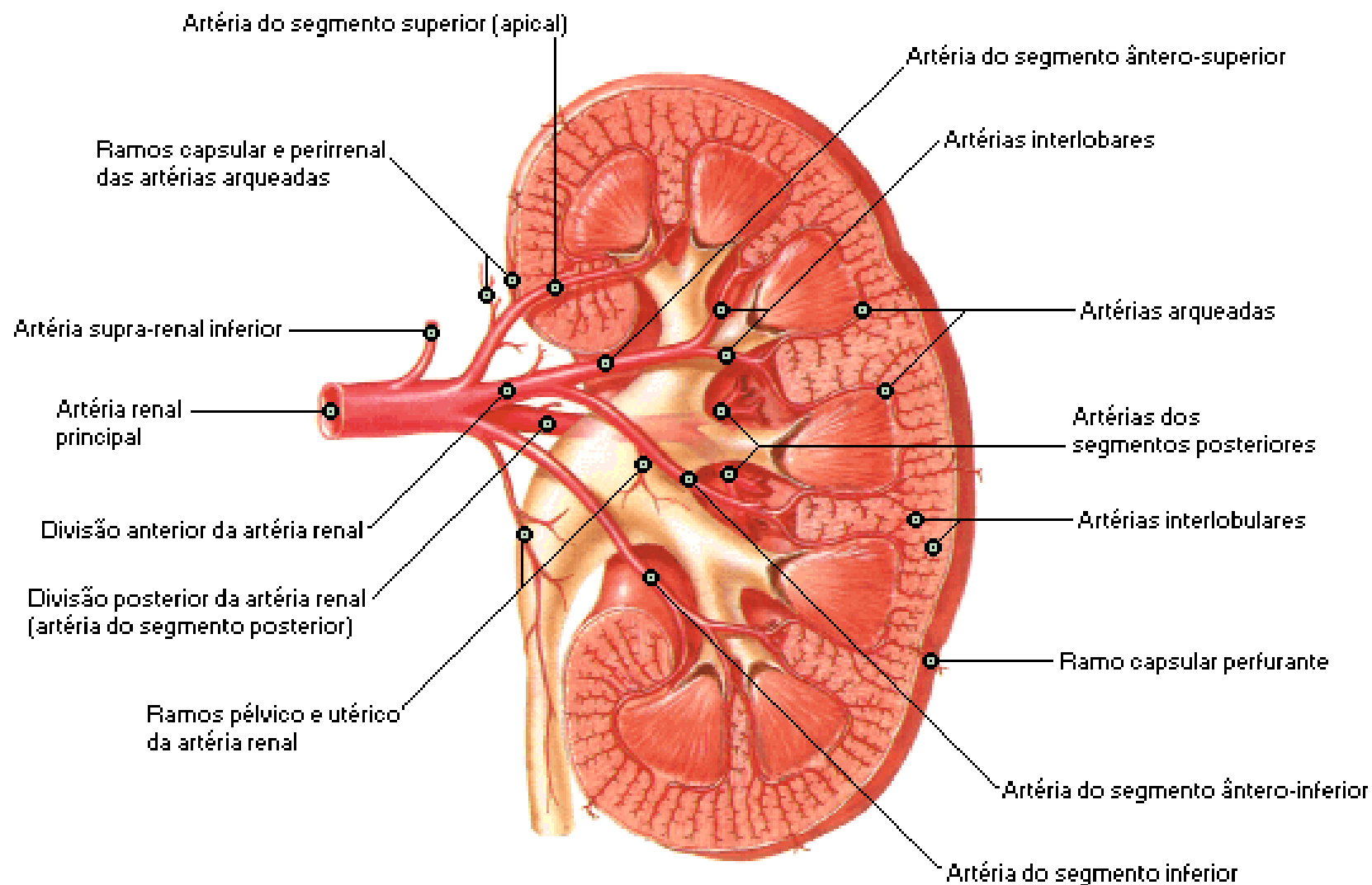


Artéria e Veia Renais in Situ

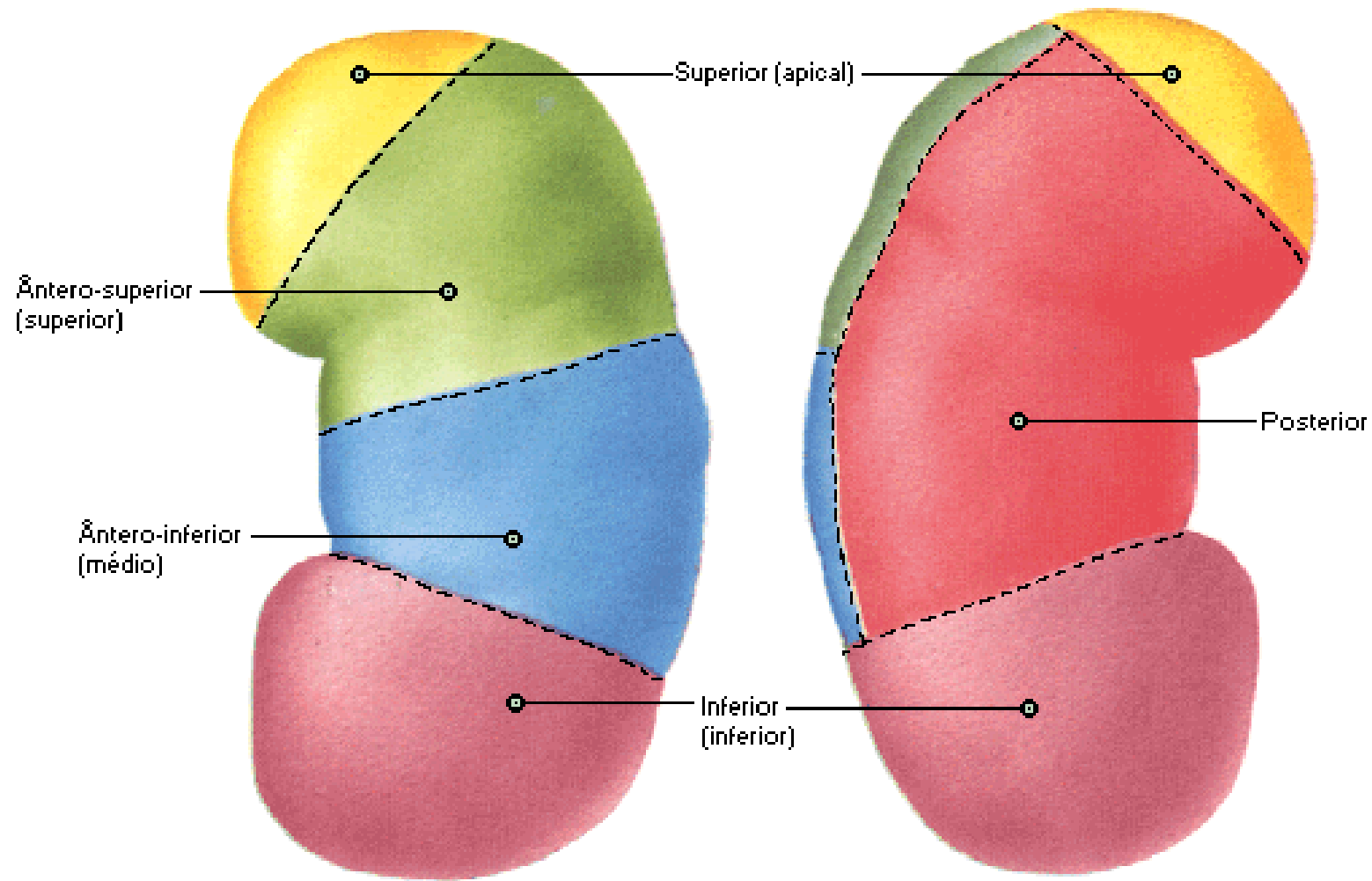


Artérias Intra-renais

Secção Frontal do Rim Esquerdo - Vista Anterior



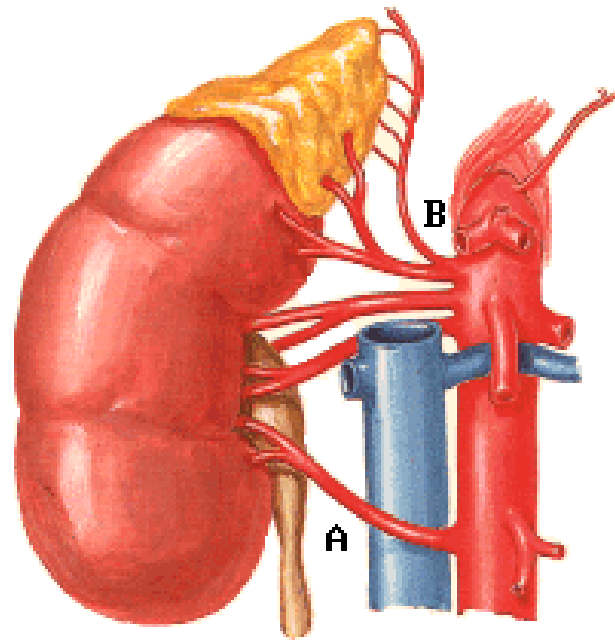
Segmentos [Vasculares] Renais



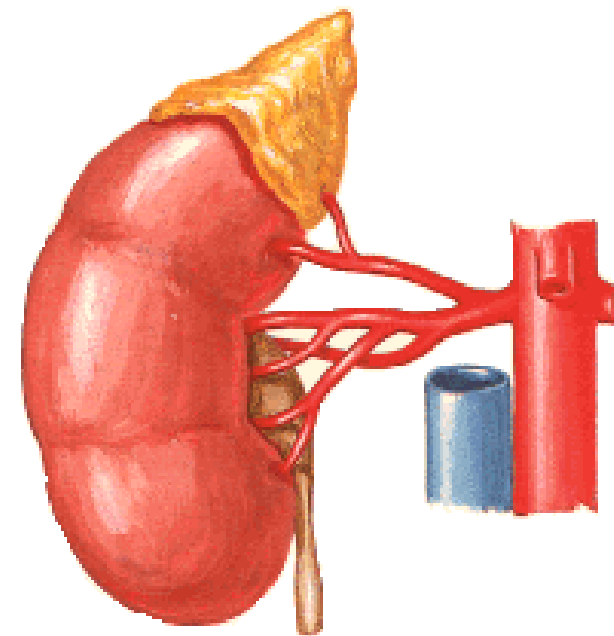
Face anterior do rim esquerdo

Face posterior do rim esquerdo

Variações da Artéria Renal

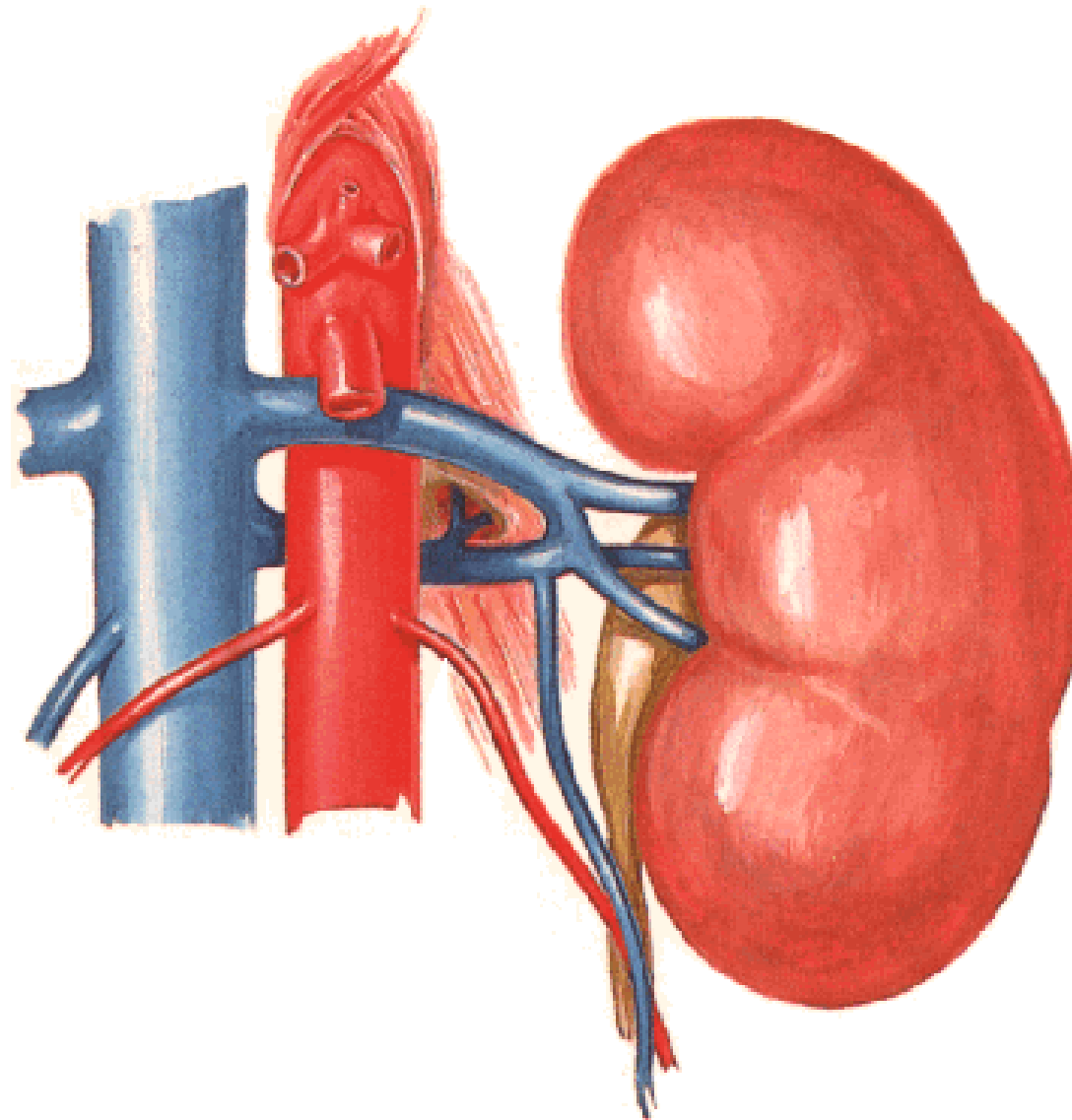


- A) Artéria renal direita acessória inferior pode passar anteriormente à veia cava inferior ao invés de posteriormente
- B) Artéria frênica inferior com as artérias supra-renais podem-se originar da artéria renal



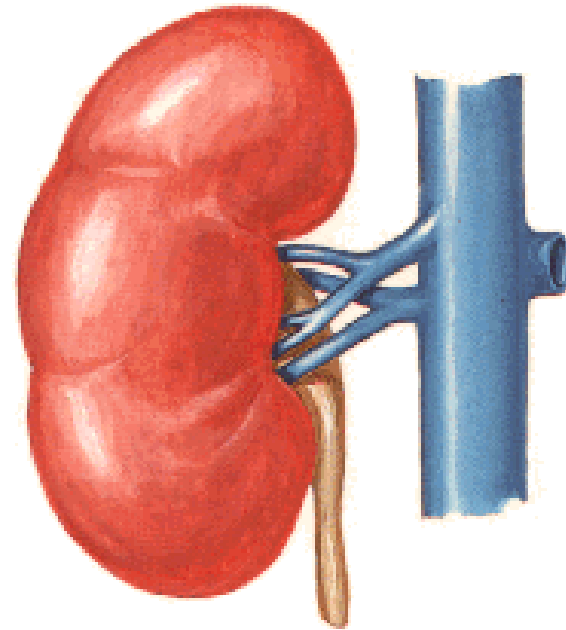
Subdivisão proximal da artéria renal

Variações da Veia Renal



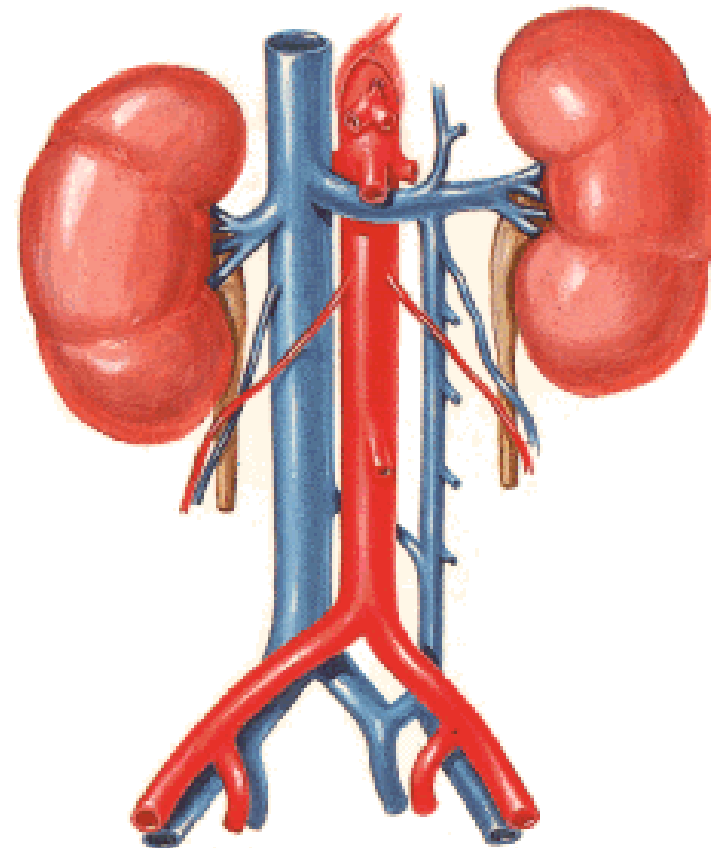
Veia renal dupla pode formar um anel ao redor da aorta

Variações da Veia Renal [Continuação]



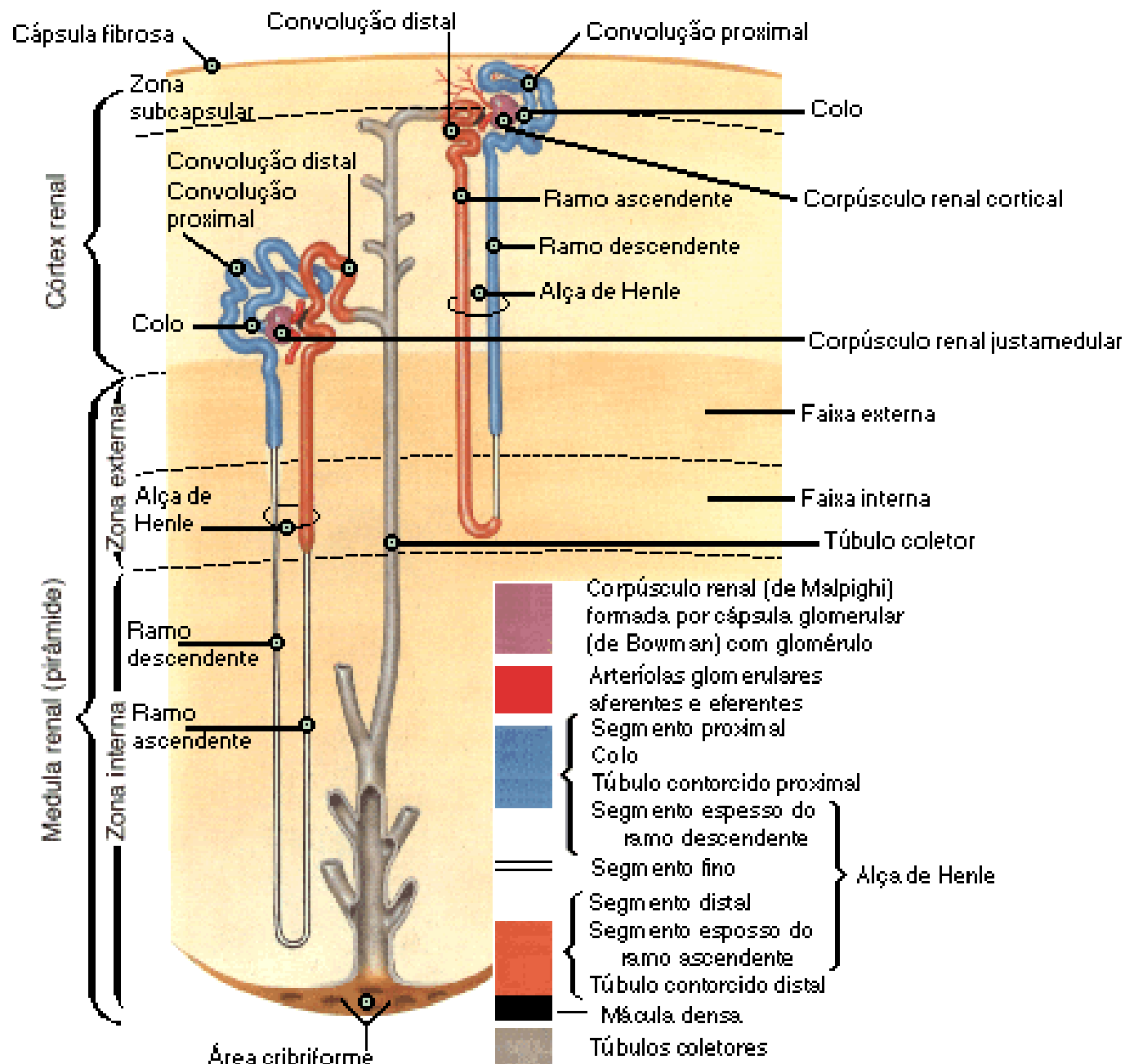
Múltiplas veias renais

Veia cava inferior esquerda persistente
pode unir-se à veia renal esquerda

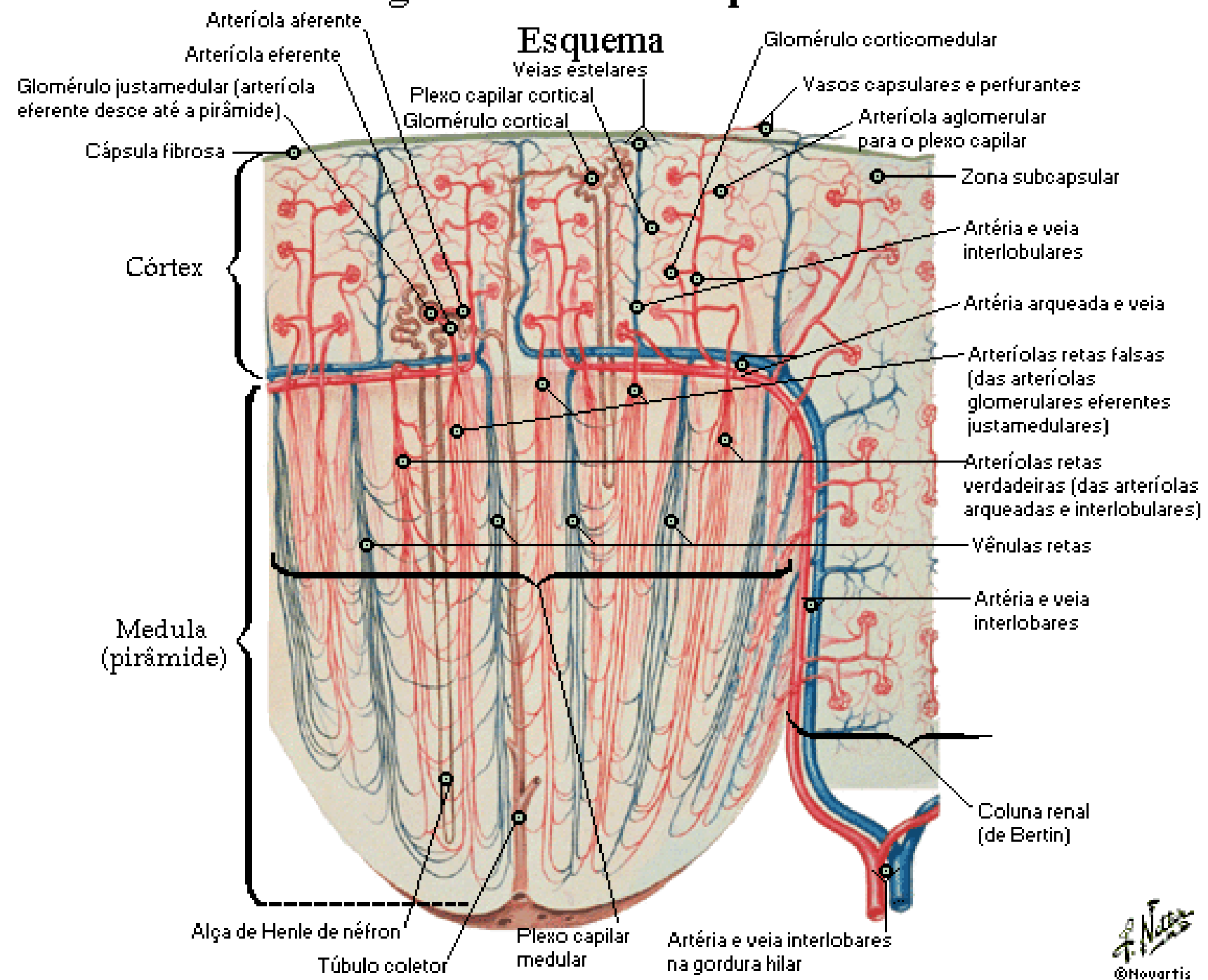


Néfron e Túbulo Coletor

Esquema

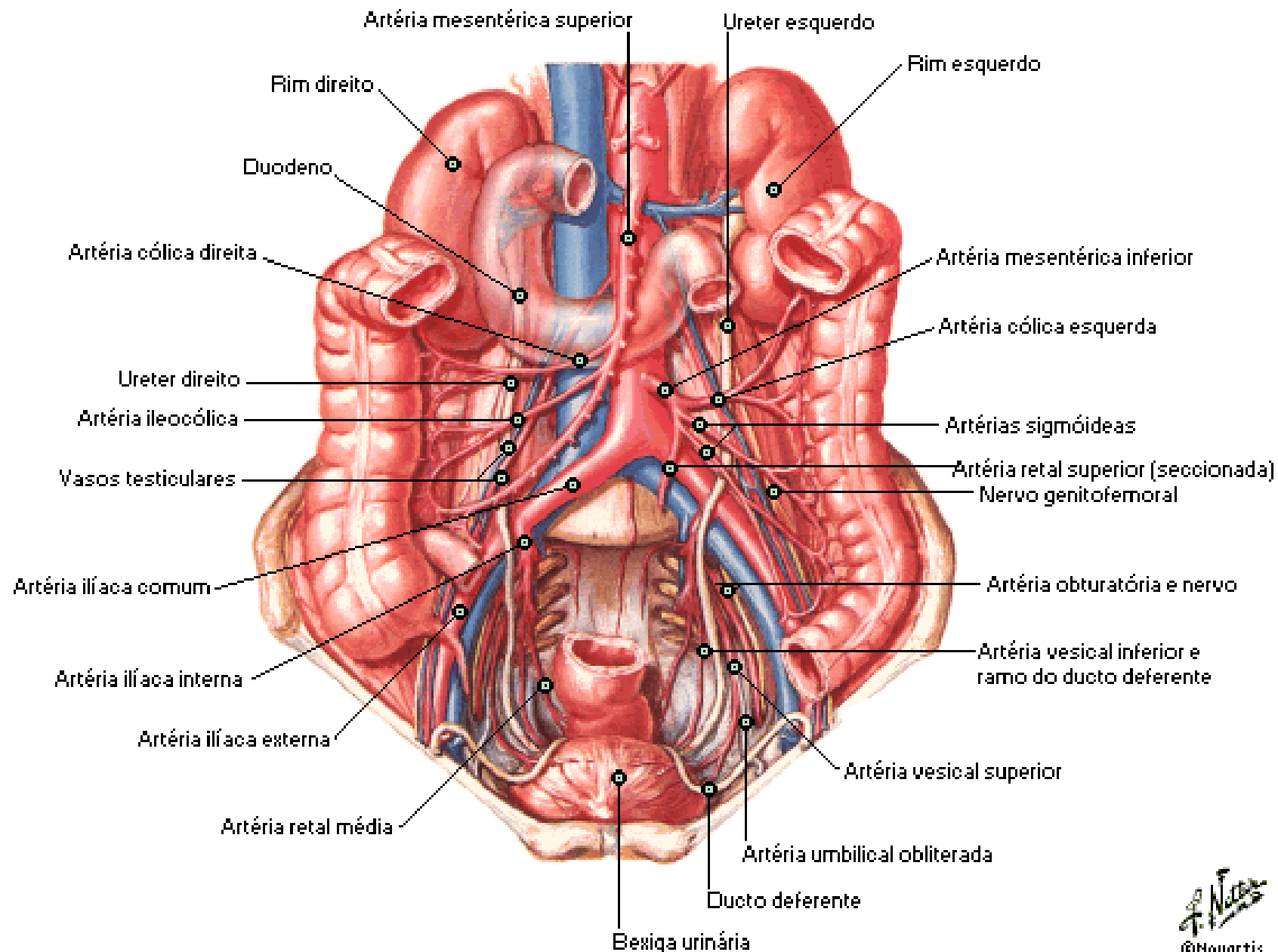


Vasos Sangüíneos no Parênquima do Rim

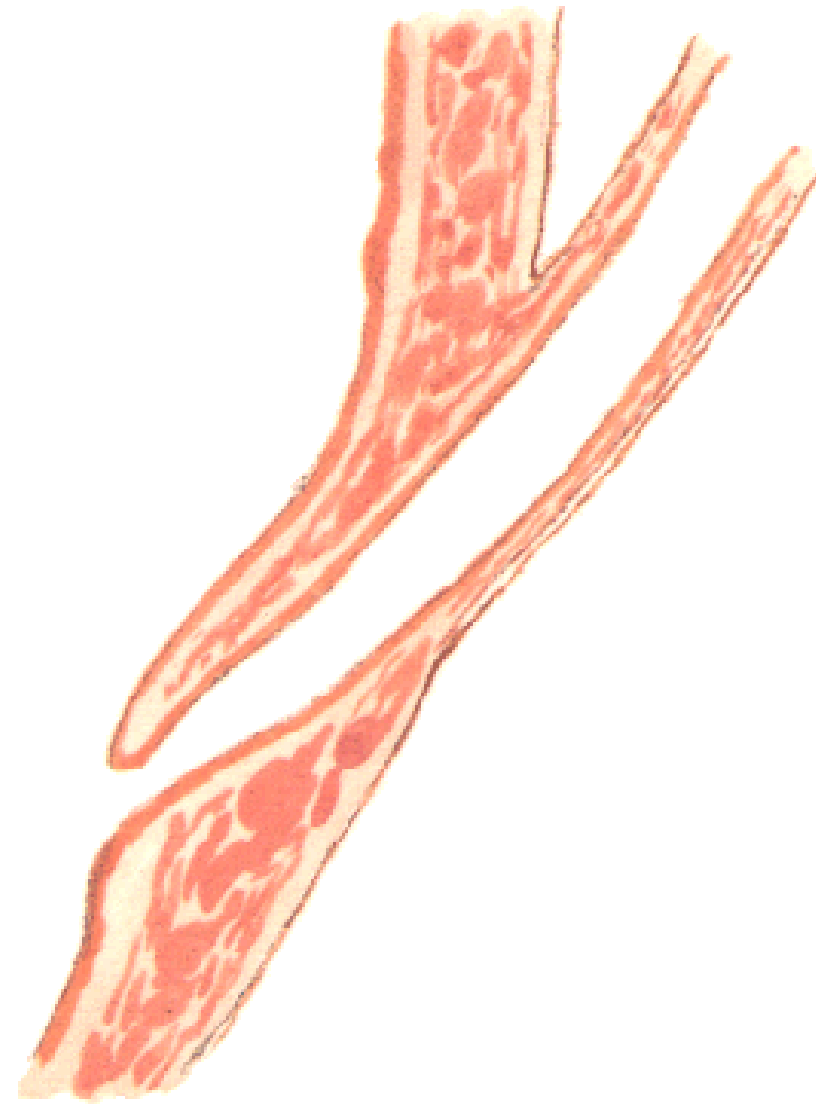


Ureteres no Homem

Vista Anterior

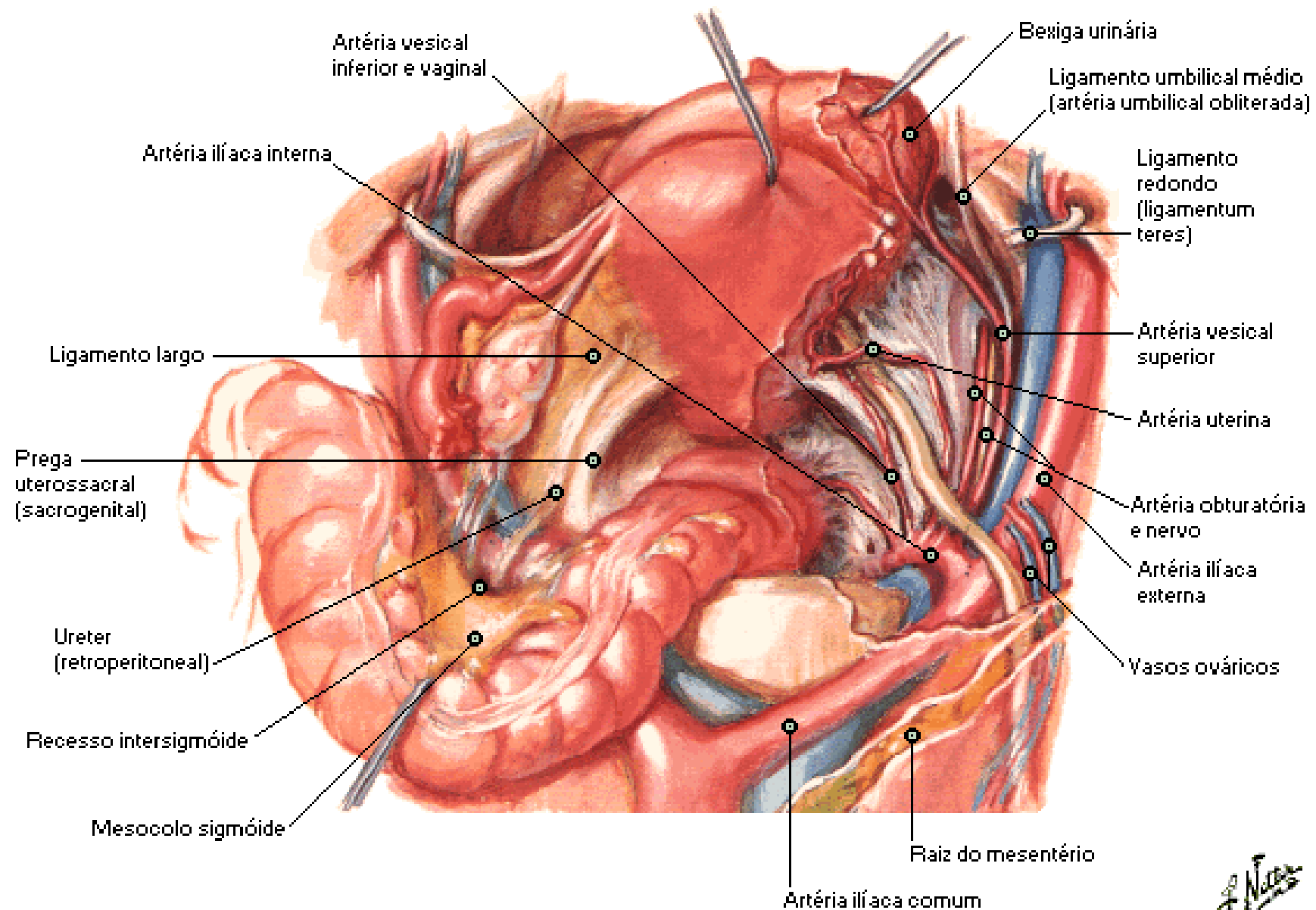


Curso Diagonal do Ureter Através da Parede da Bexiga

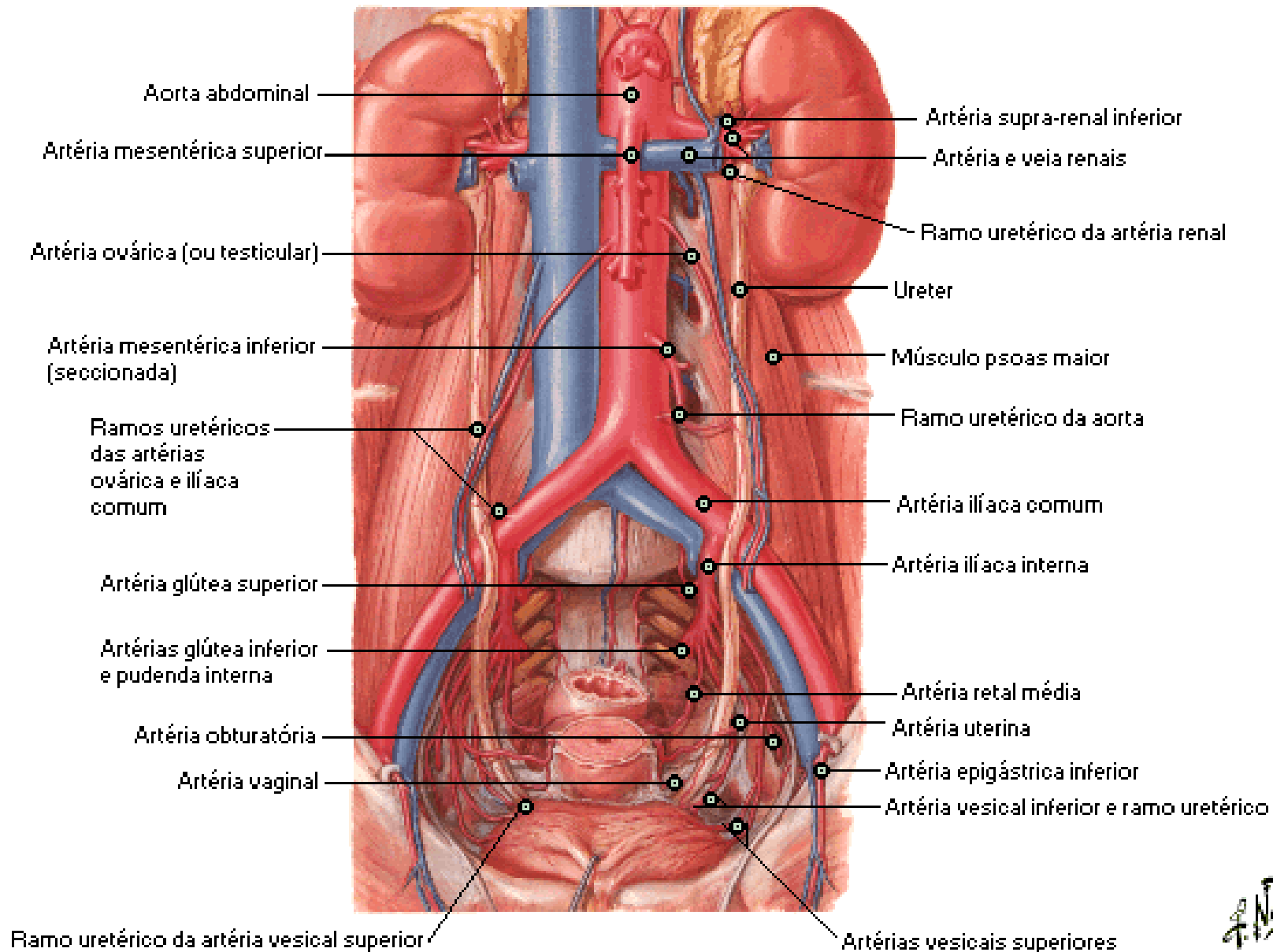


Ureteres na Mulher

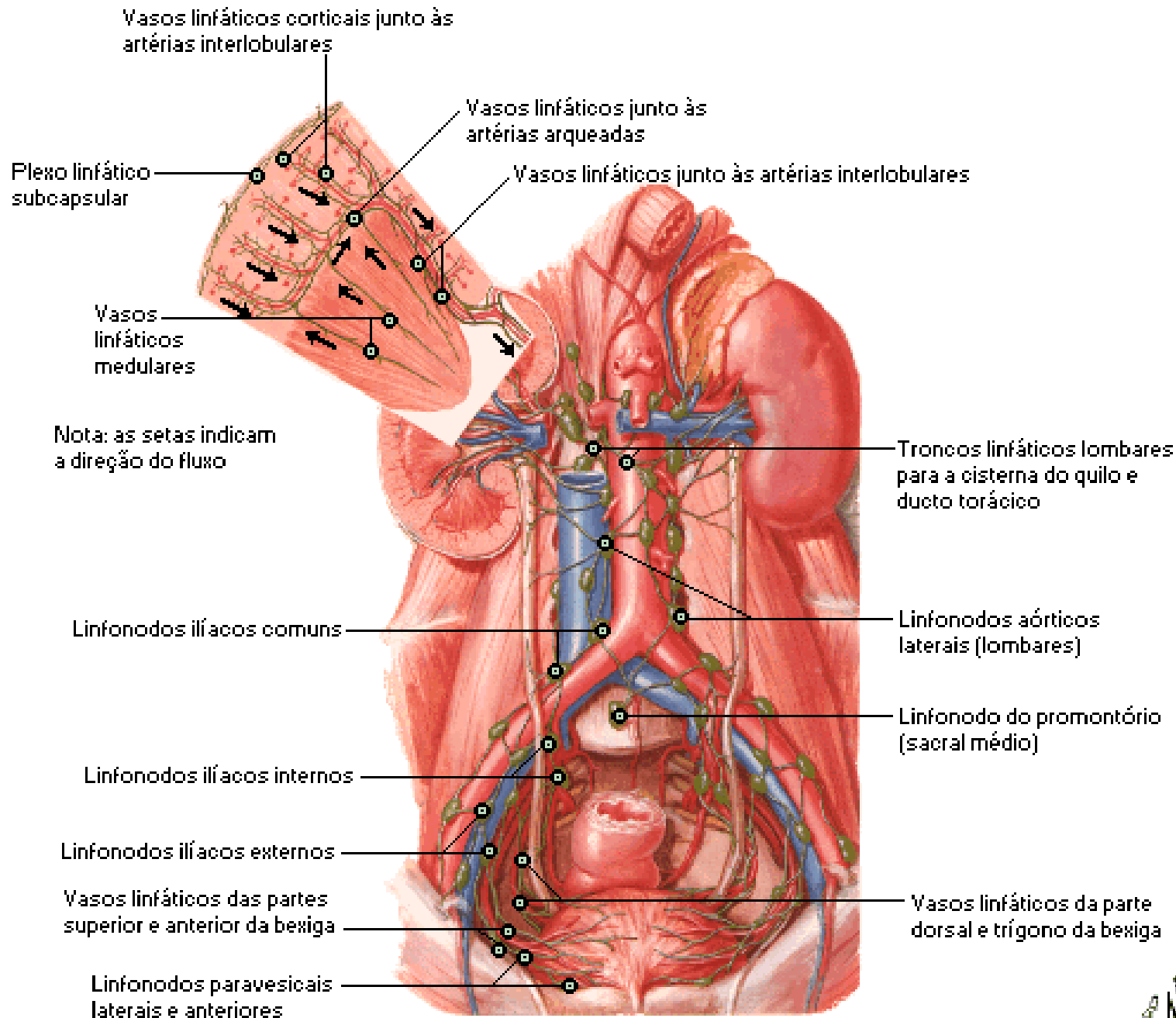
Vista Superior



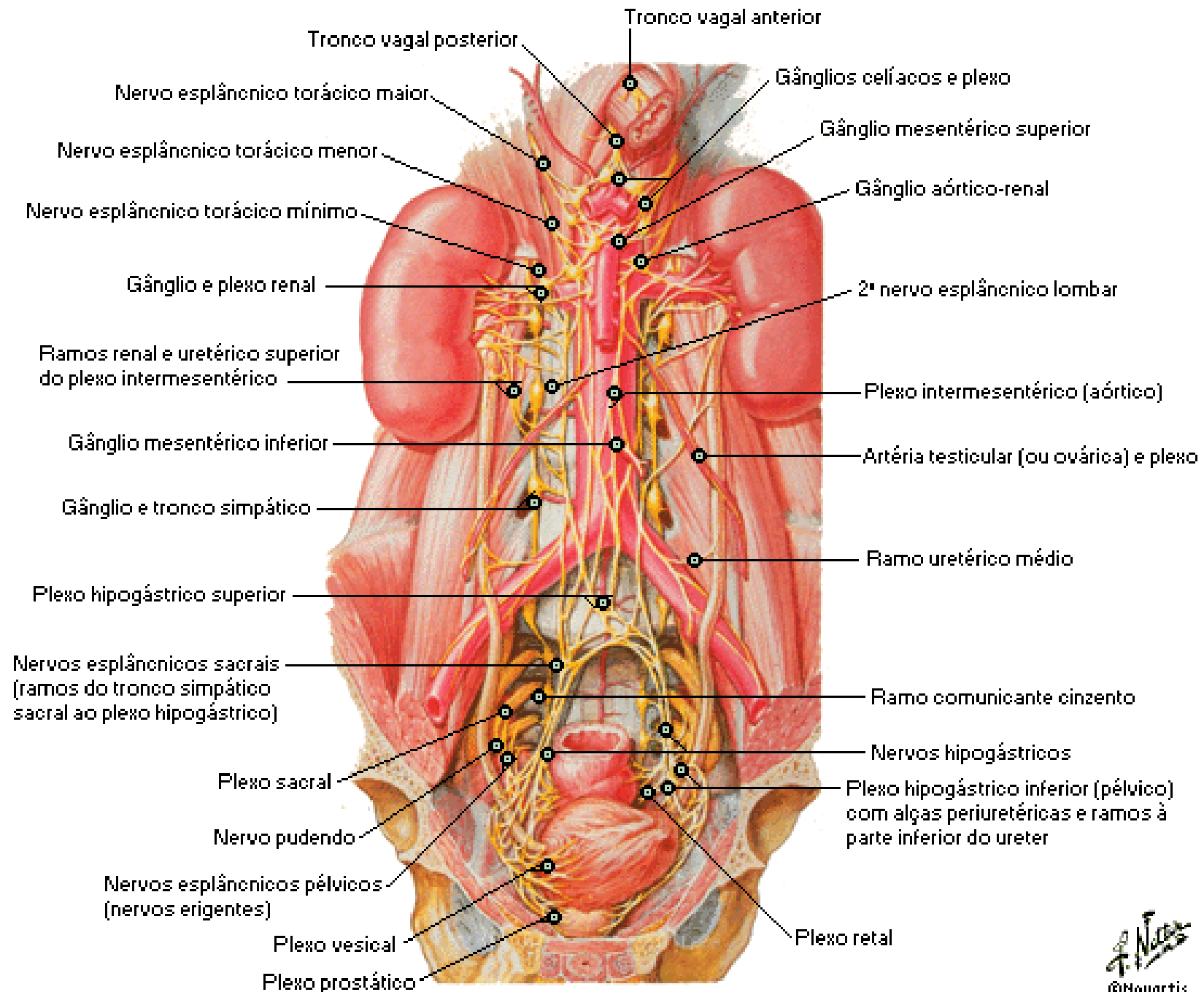
Artérias dos Ureteres e Bexiga Urinária



Vasos Linfáticos e Linfonodos dos Rins e Bexiga Urinária

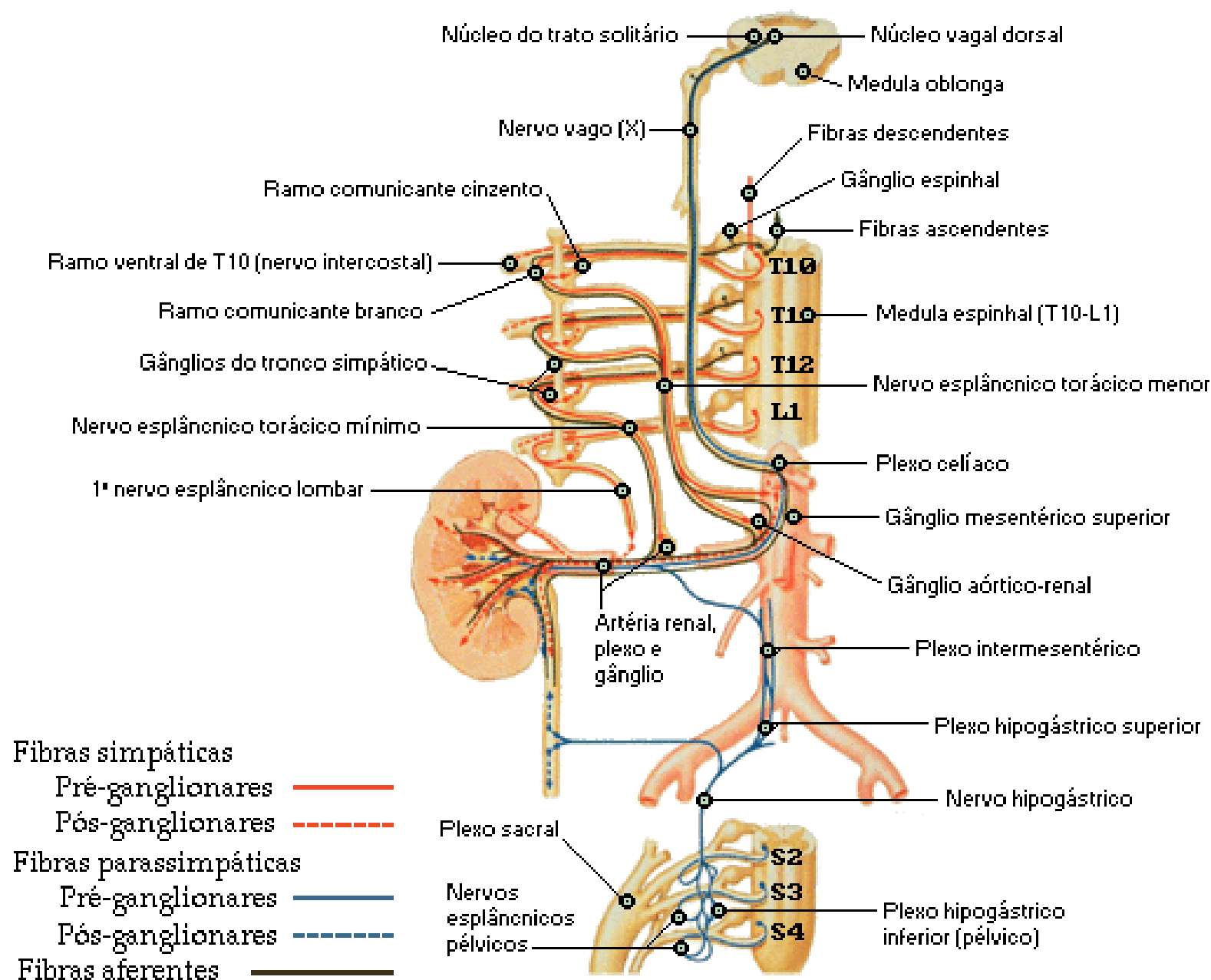


Nervos dos Rins, Ureteres e Bexiga Urinária



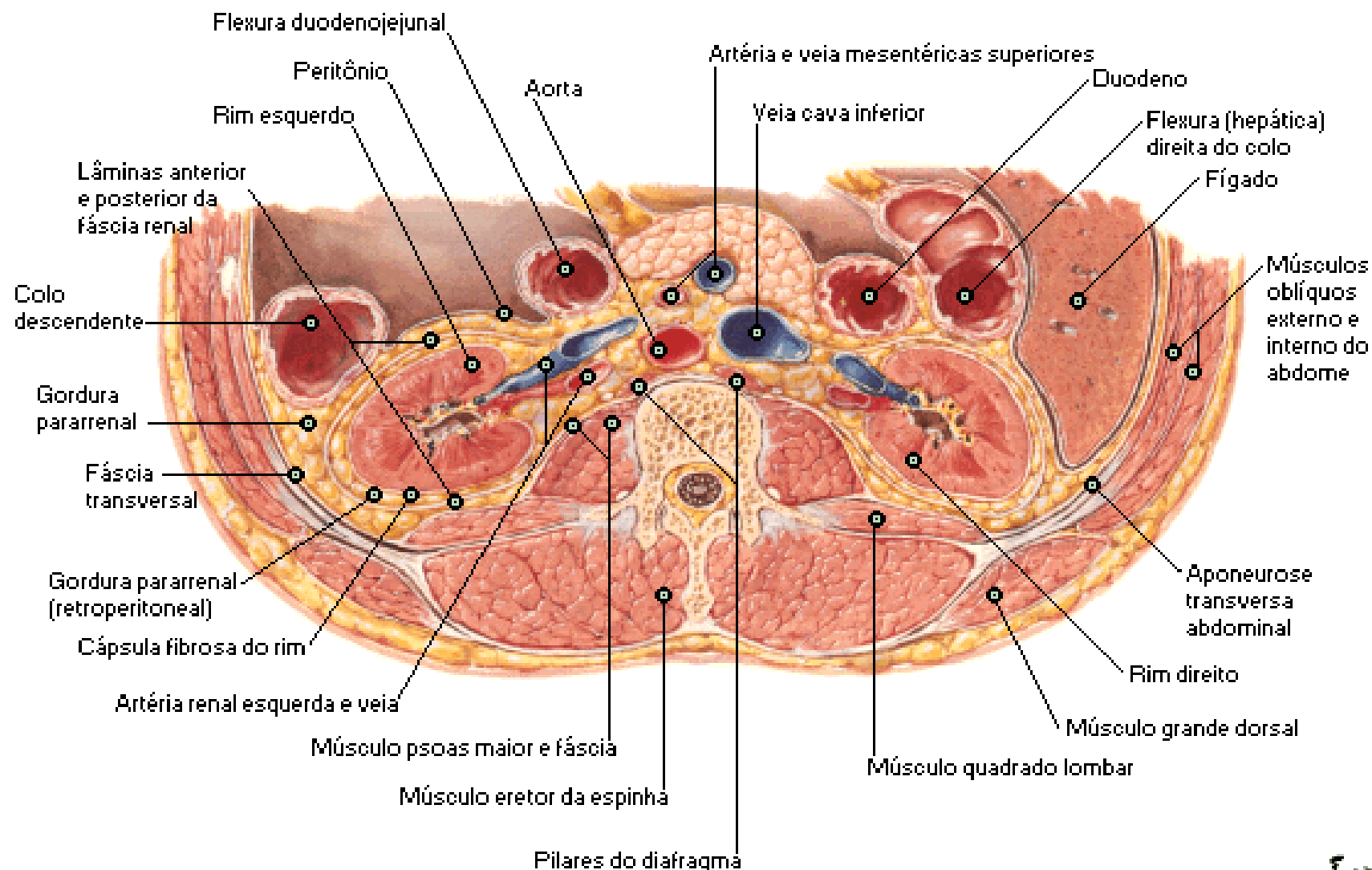
Inervação dos Rins e Parte Superior dos Ureteres

Esquema



Fáscia Renal

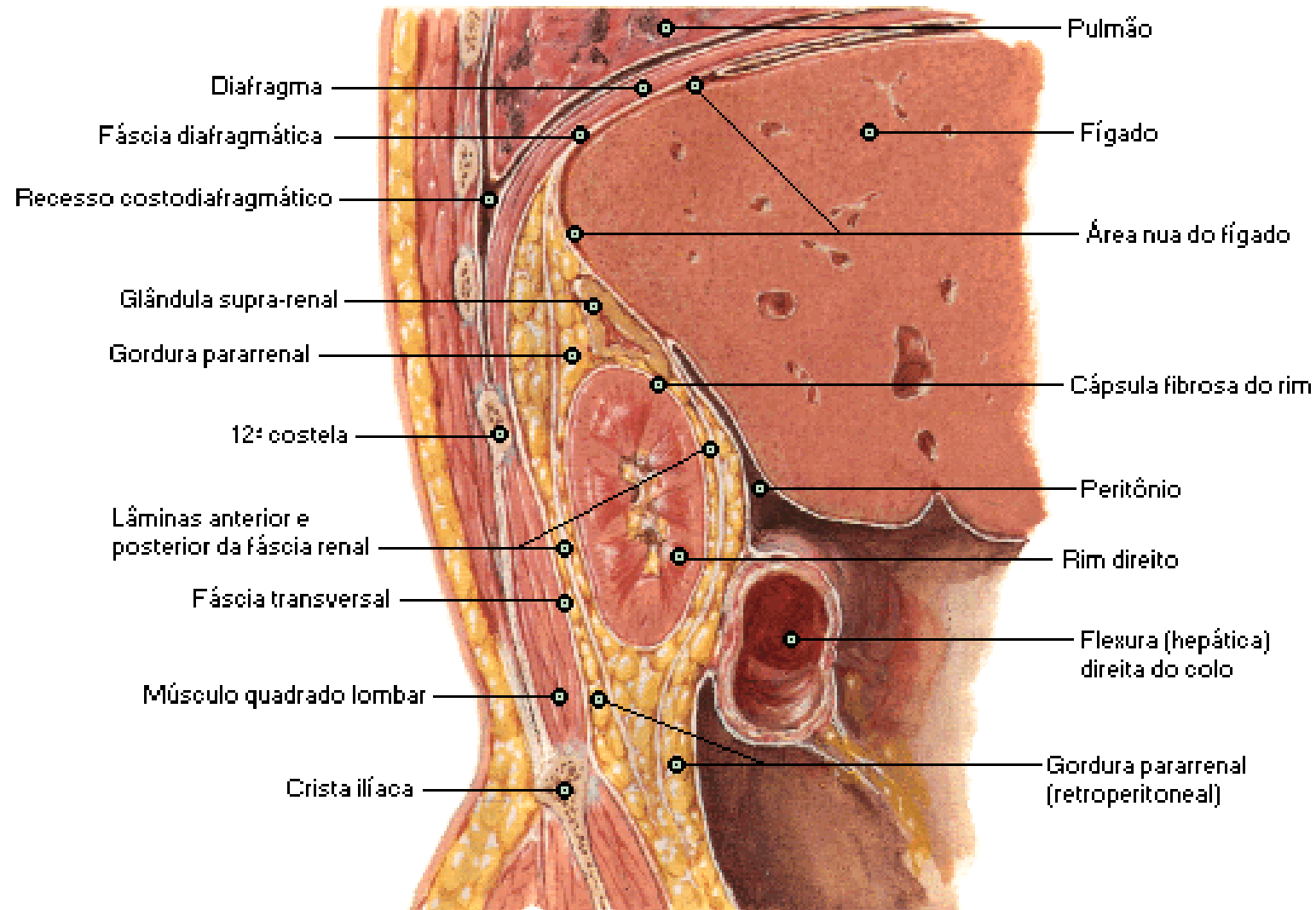
Secção Transversal Através da 2ª Vértebra Lombar



Secção transversal através da 2ª vértebra lombar demonstrando a disposição horizontal da fáscia renal

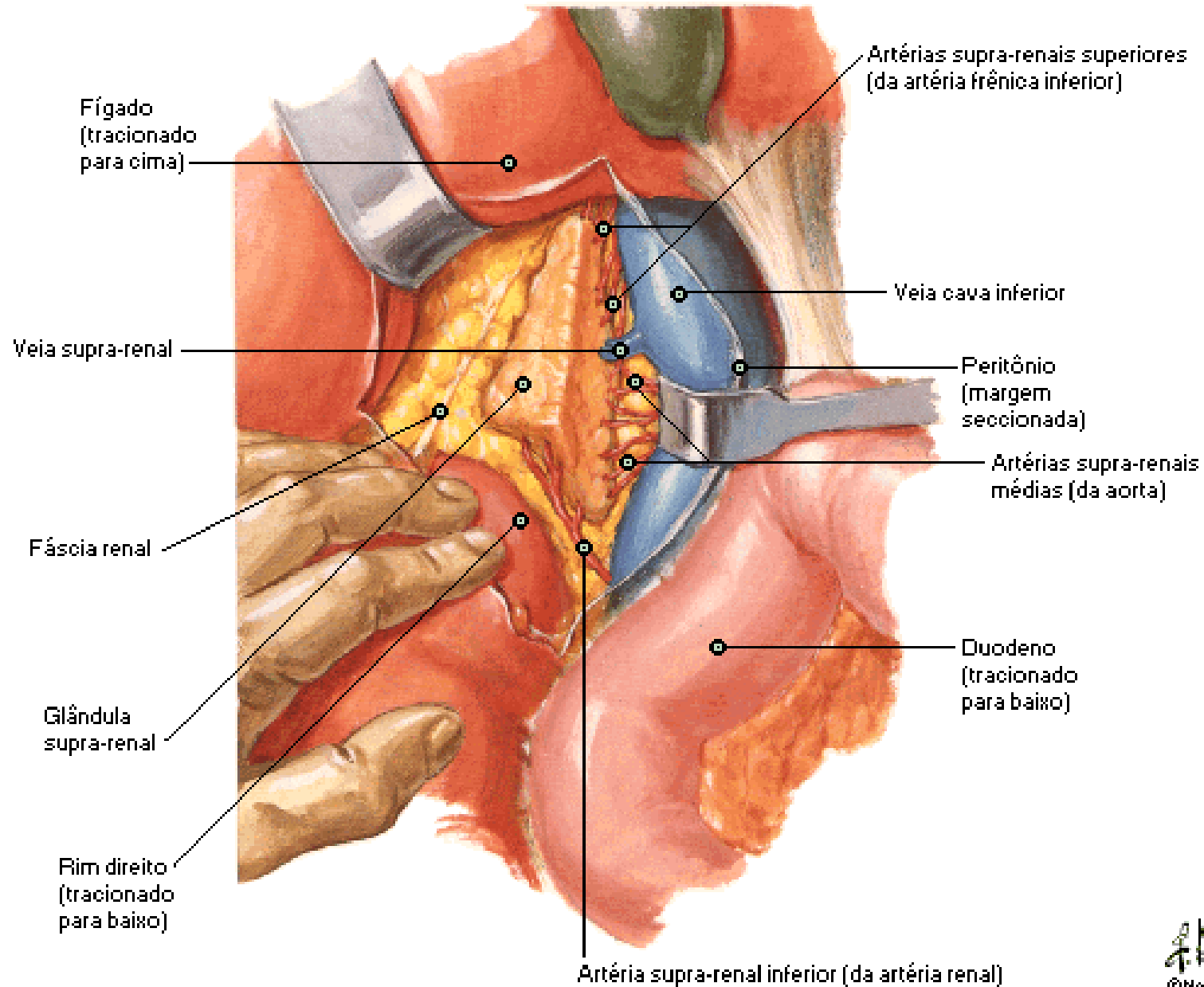
Fáscia Renal

Secção Sagital Através do Rim Direito

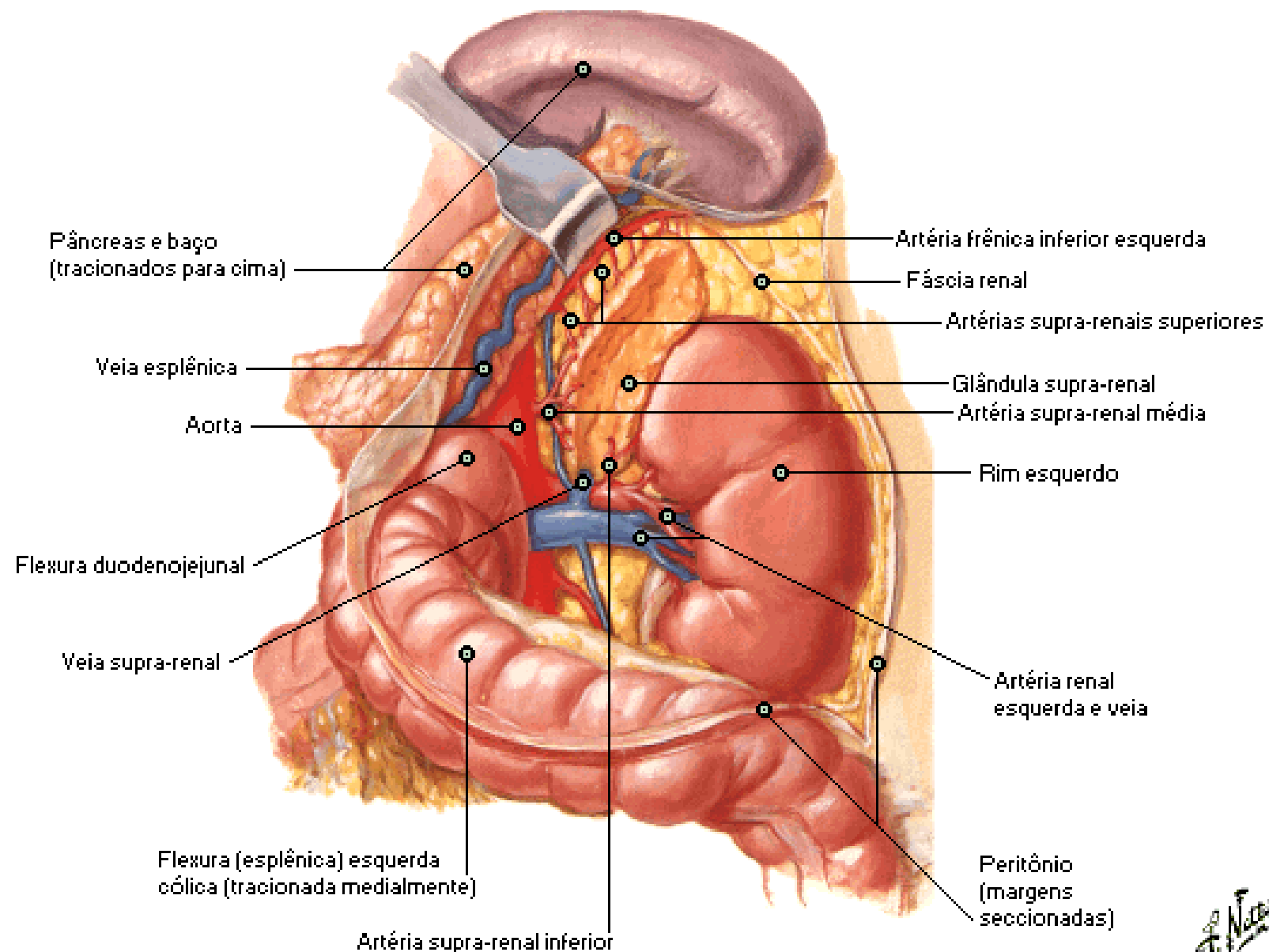


Secção sagital através do rim direito e região lombar demonstrando a disposição vertical da fáscia renal

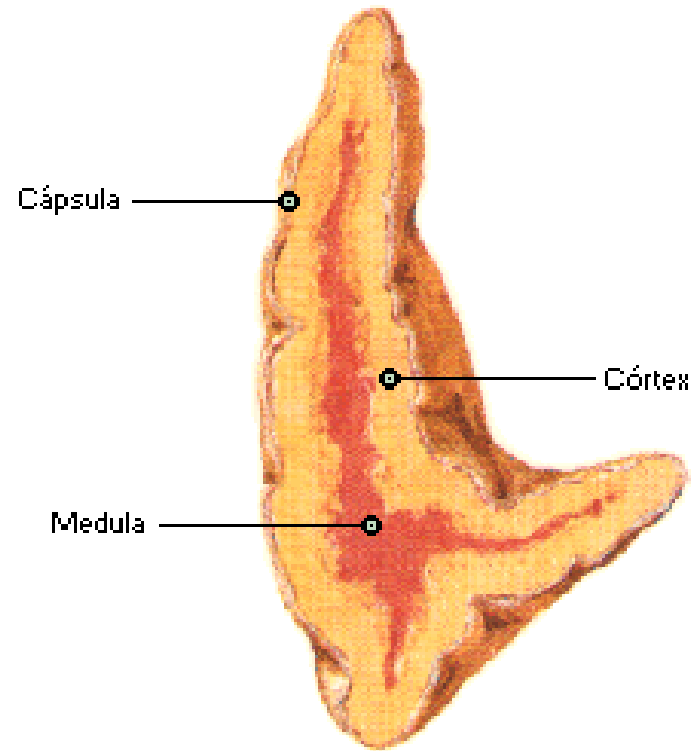
Artérias e Veias das Glândulas Supra-renais in Situ



Artérias e Veias das Glândulas Supra-renais in Situ

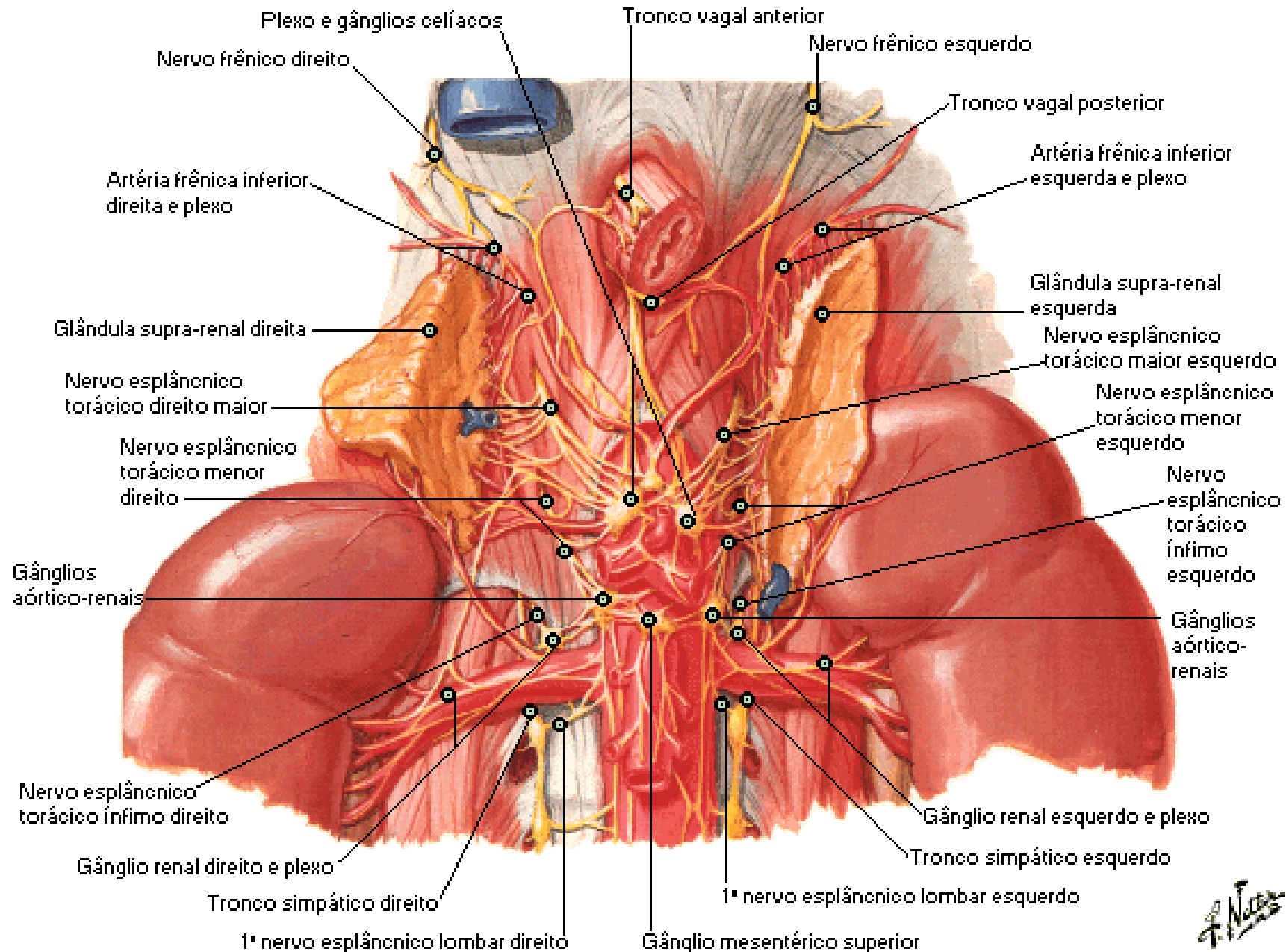


Secção Transversal da Glândula Supra-renal



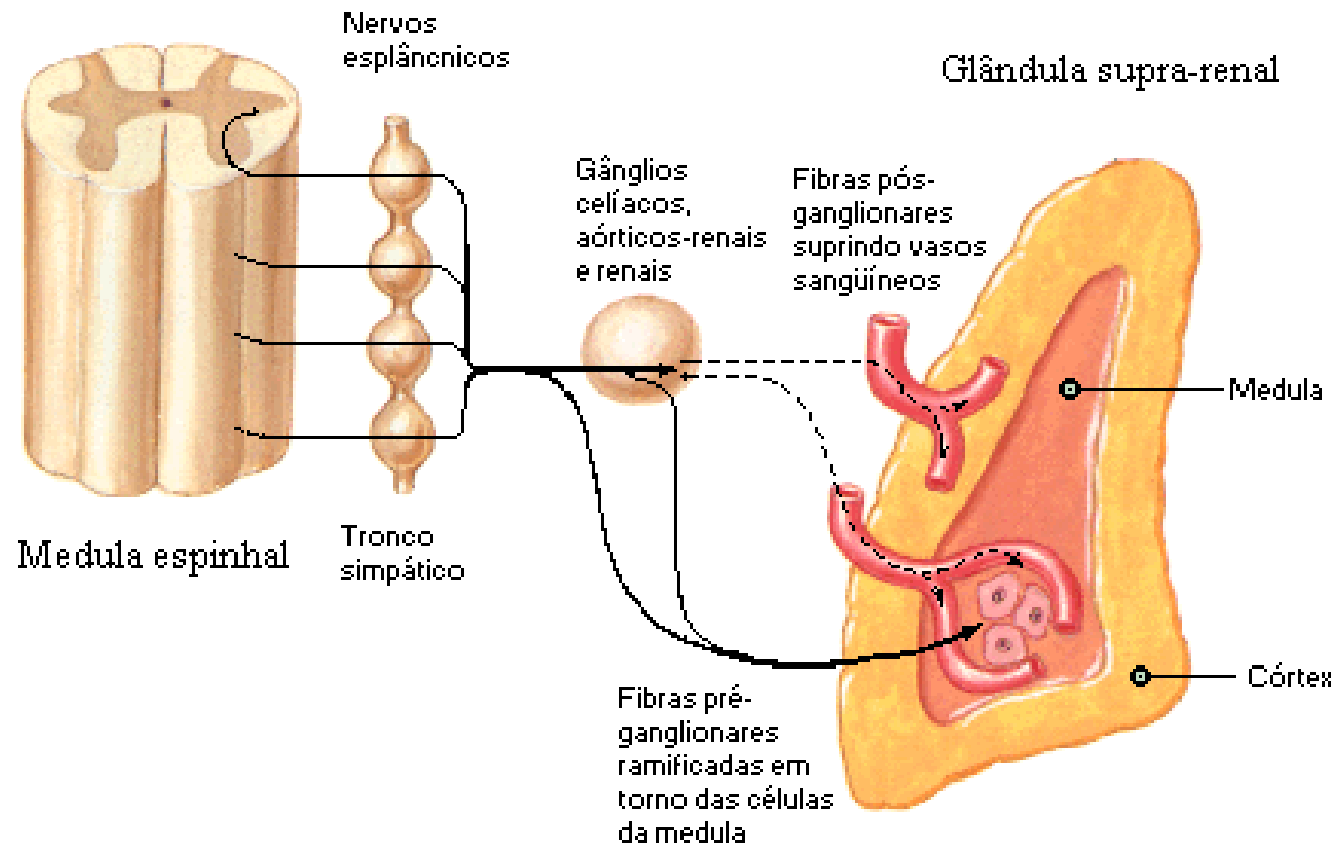
Nervos das Glândulas Supra-renais

Dissecação



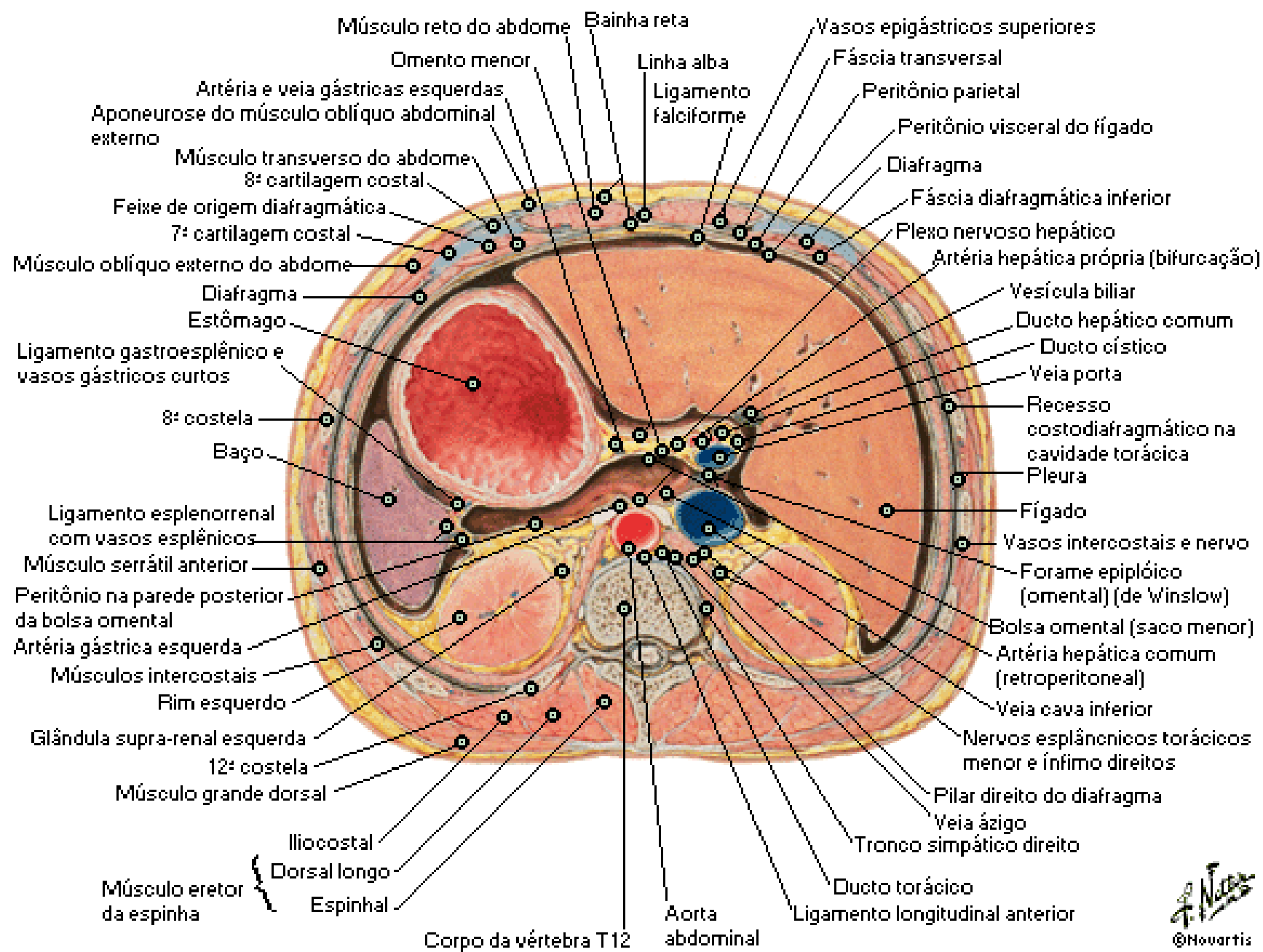
Nervos das Glândulas Supra-renais

Esquema



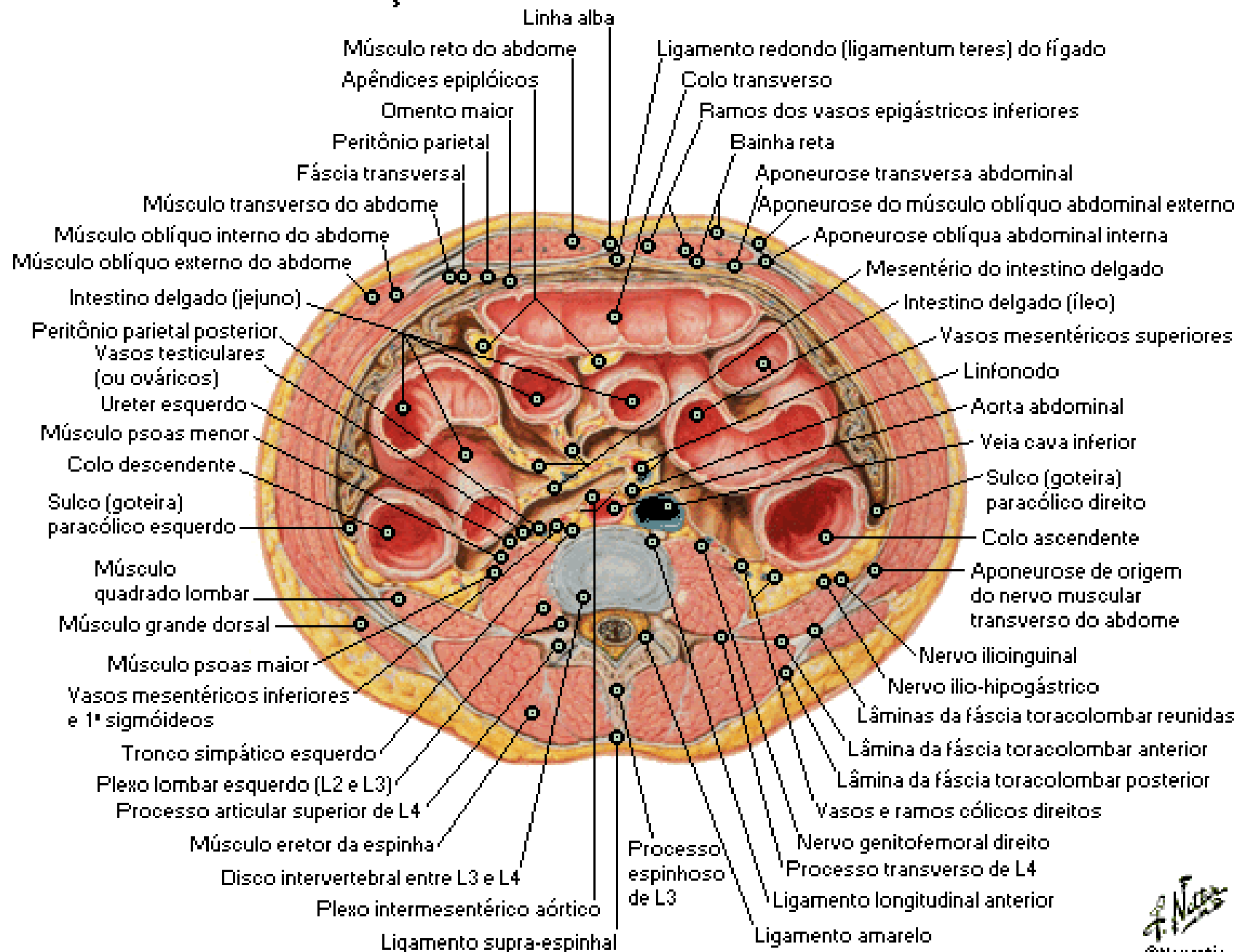
Parede Abdominal e Vísceras

Secção Transversal em T12



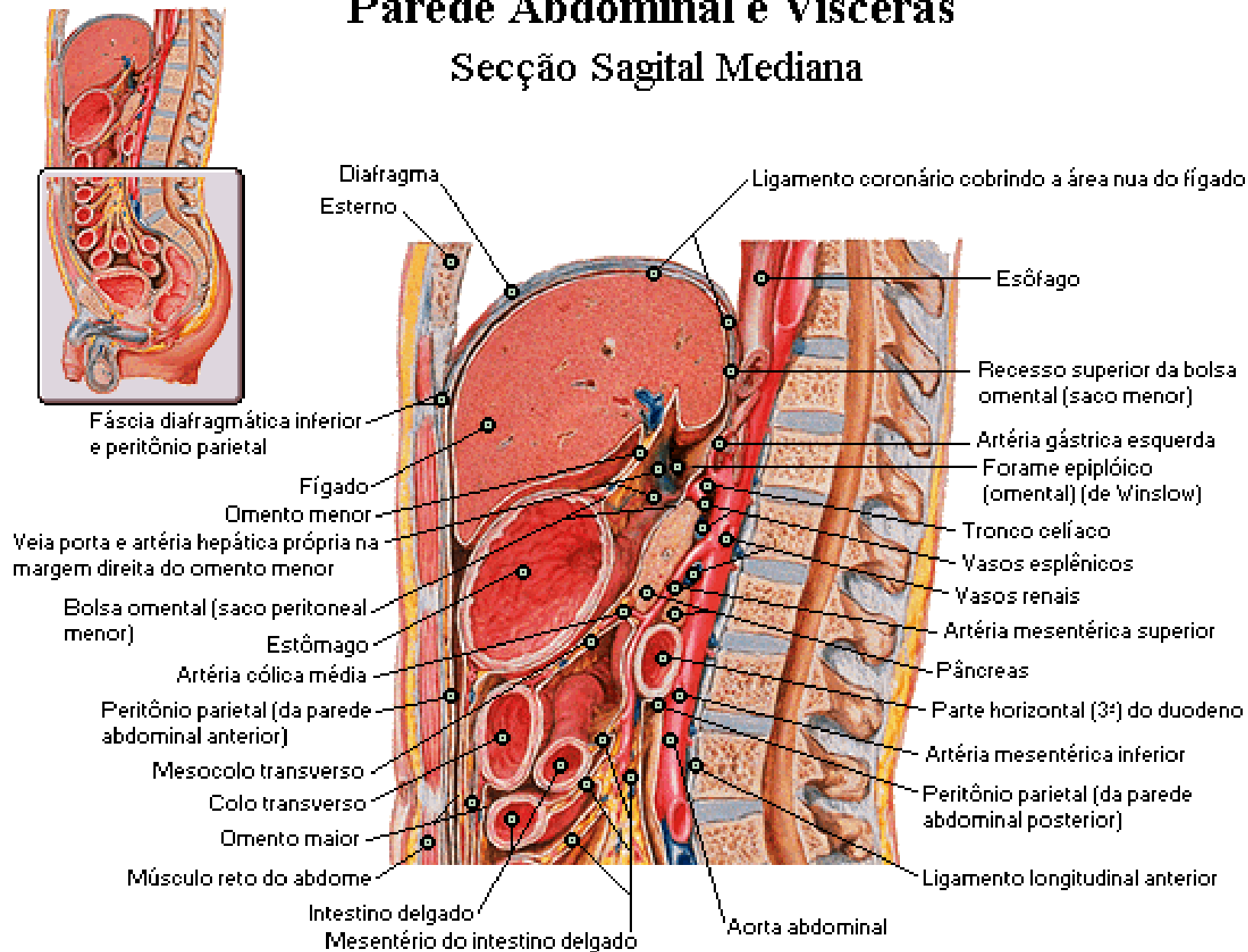
Parede Abdominal e Visceras

Secção Transversal entre L2 e L3



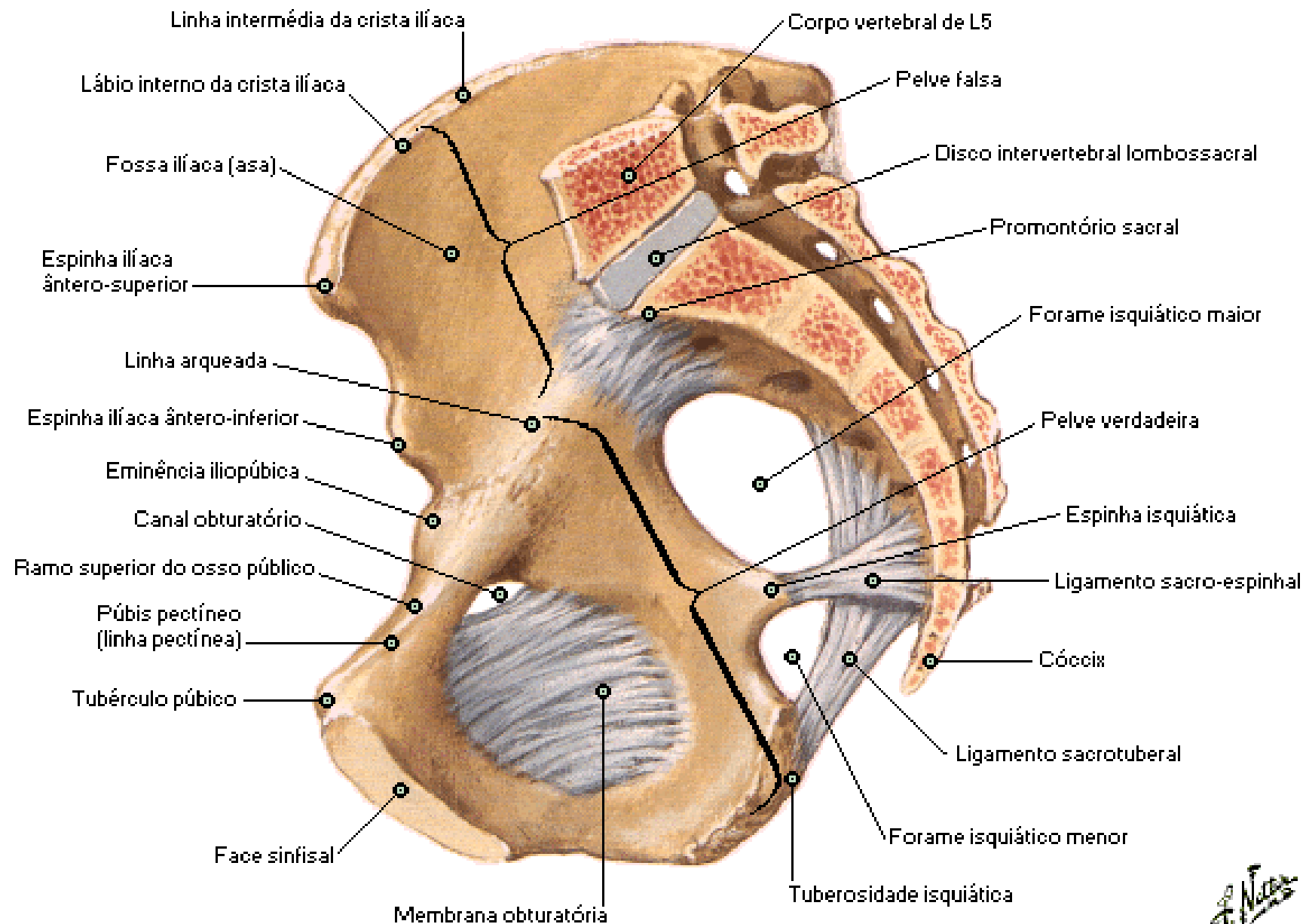
Parede Abdominal e Vísceras

Secção Sagital Mediana



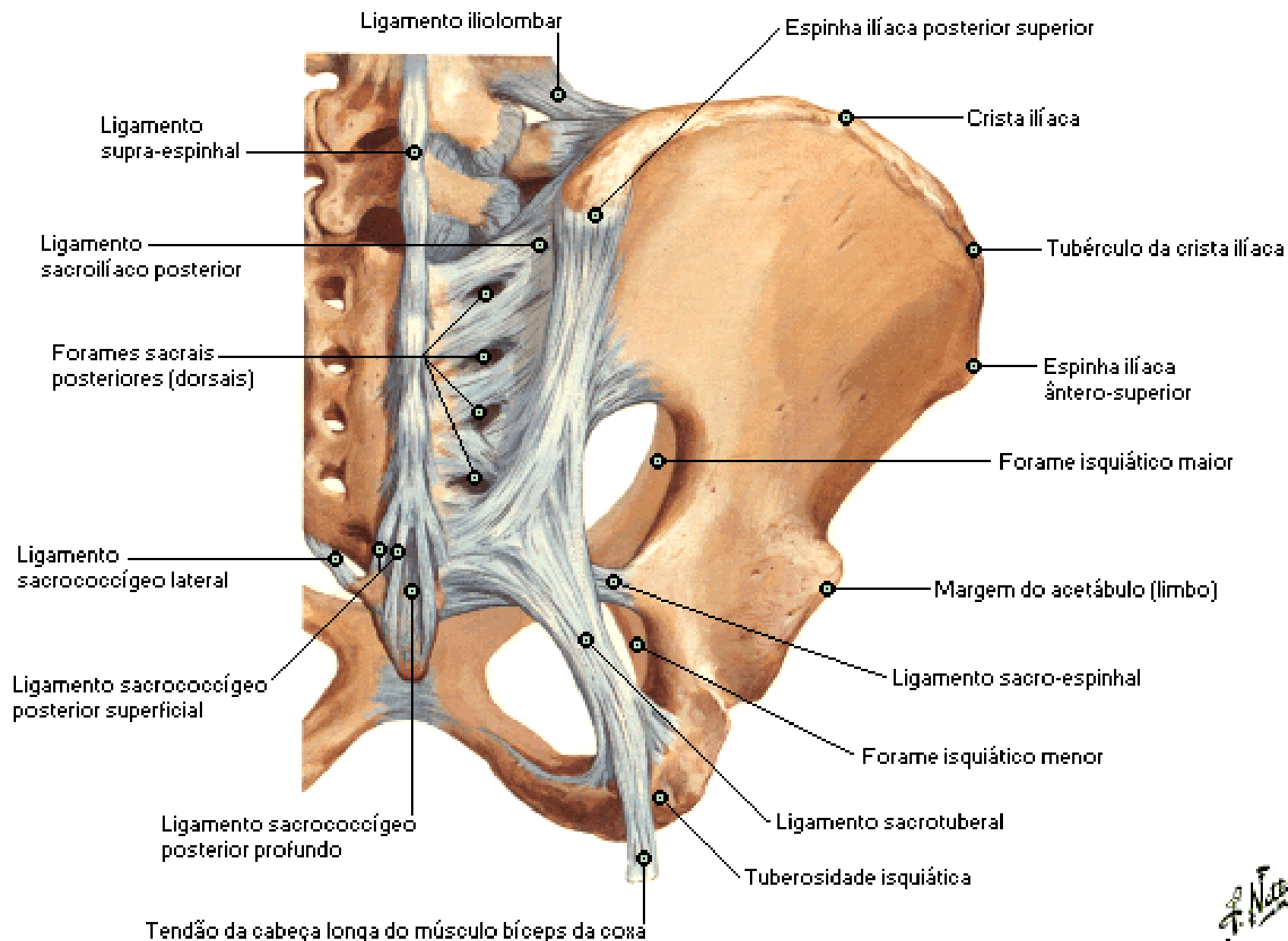
Ossos e Ligamentos da Pelve

Secção Sagital Mediana



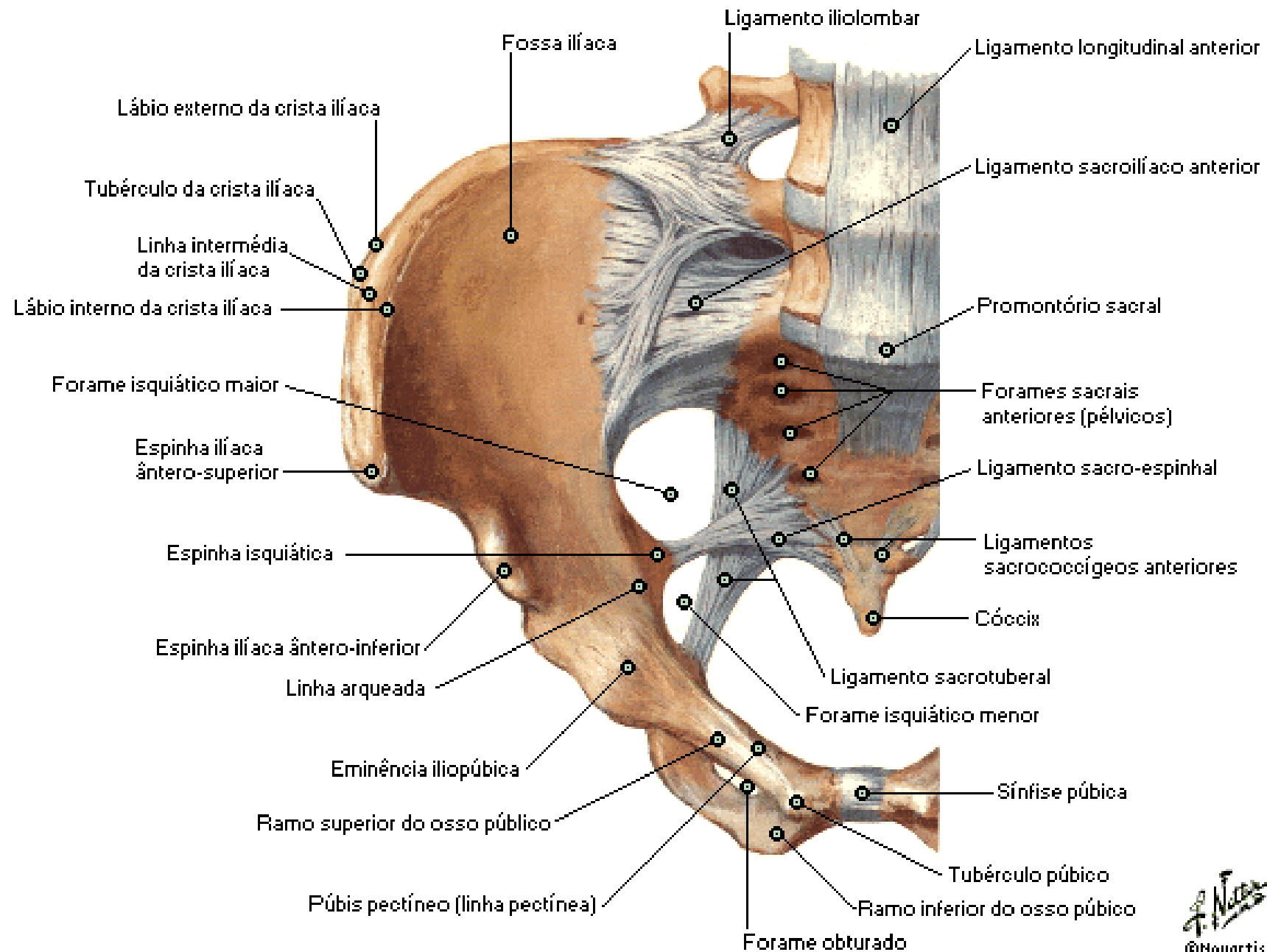
Ossos e Ligamentos da Pelve

Vista Posterior



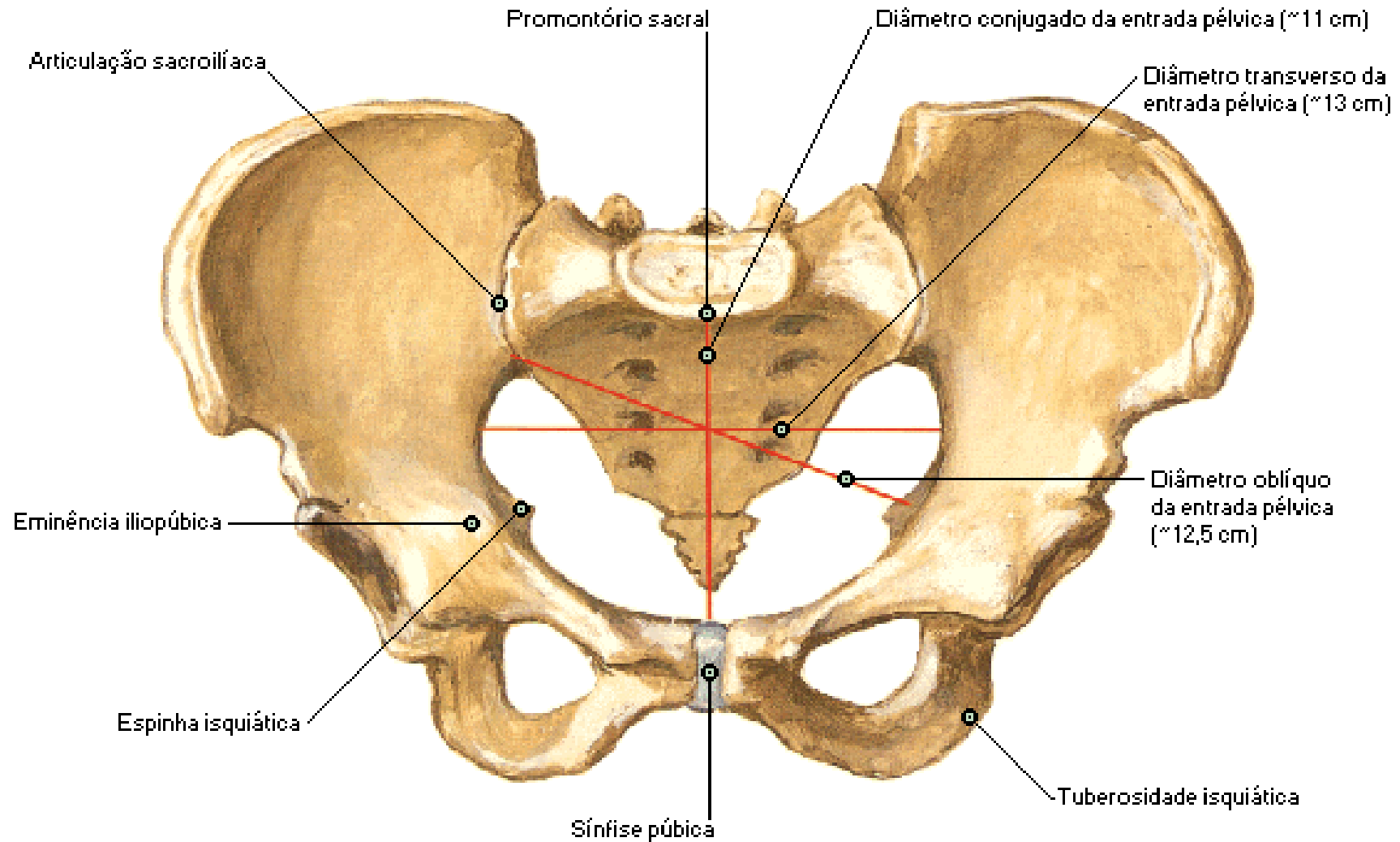
Ossos e Ligamentos da Pelve

Vista Anterior



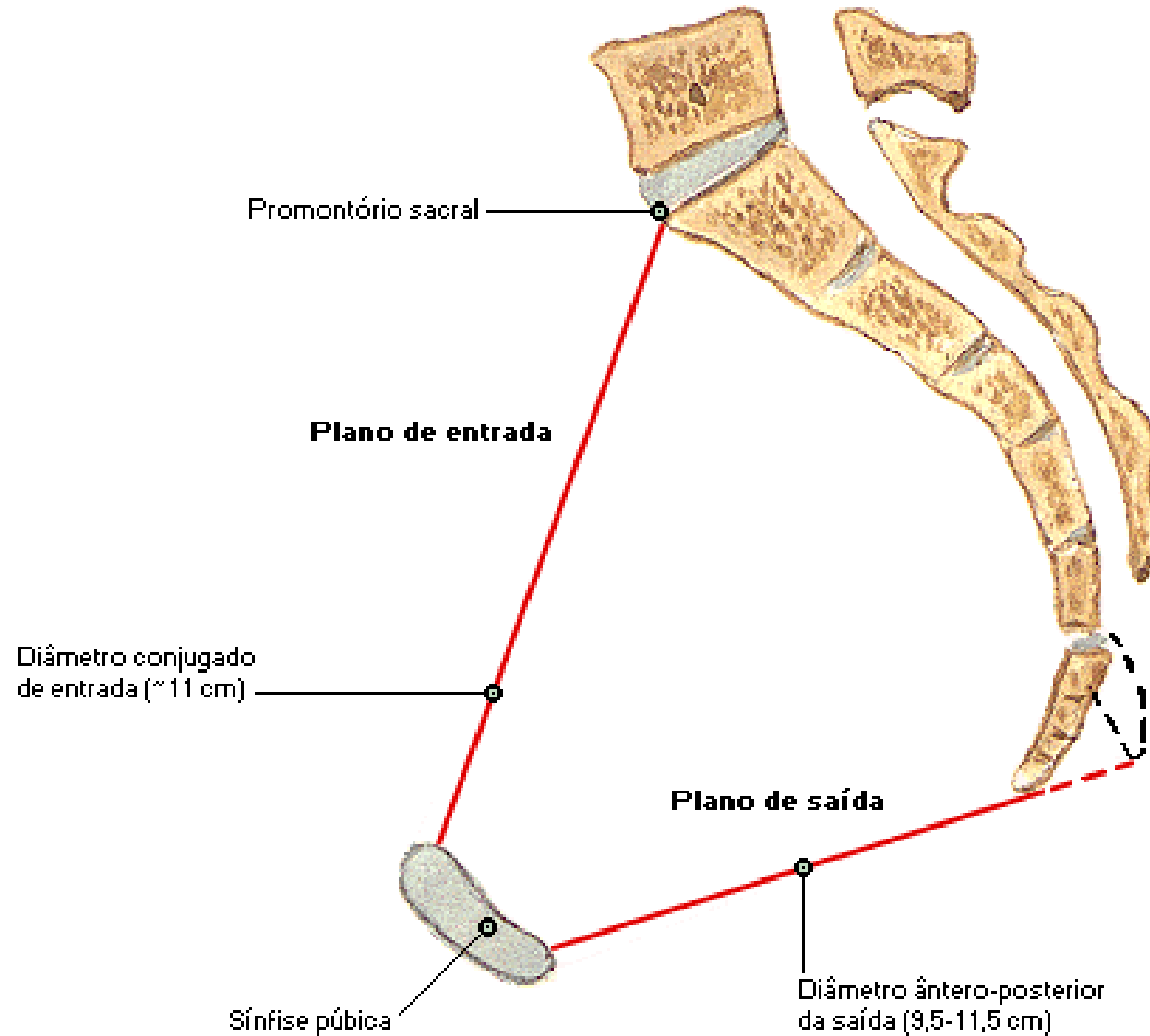
Pelve Feminina

Medidas - Vista Anterior



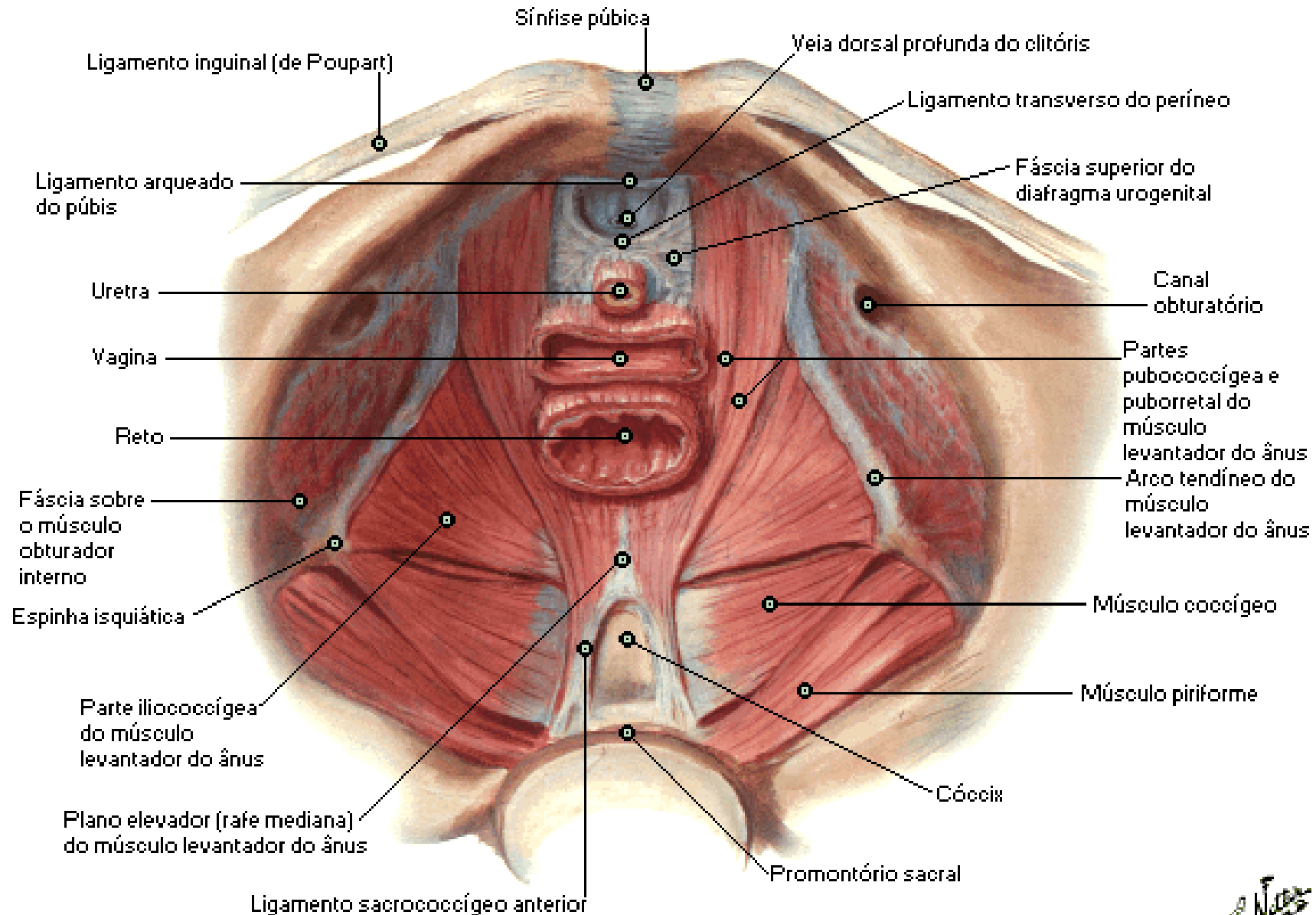
Pelve Feminina

Medidas - Secção Sagital



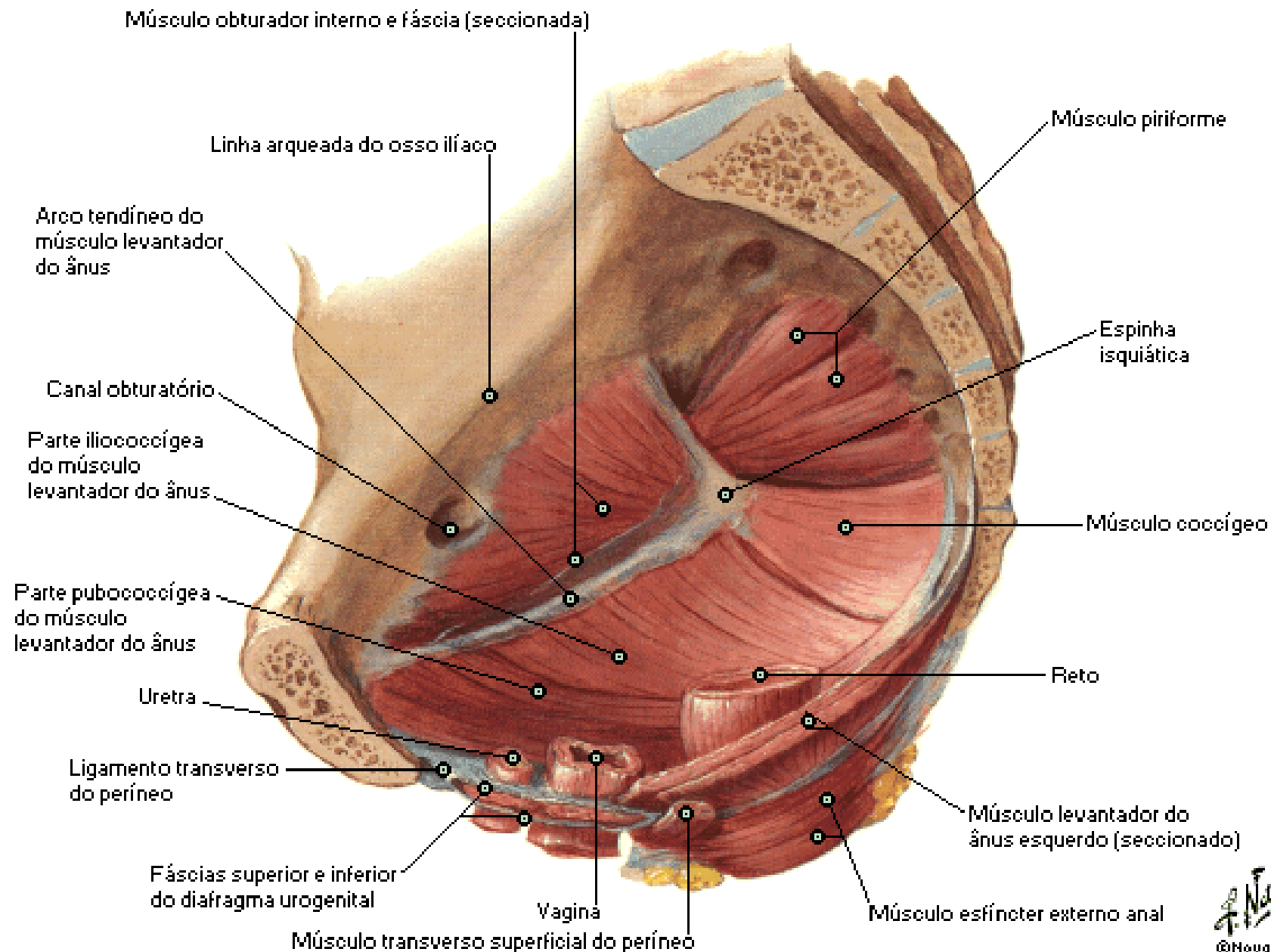
Diafragma Pélvico - Sexo Feminino

Vista Superior



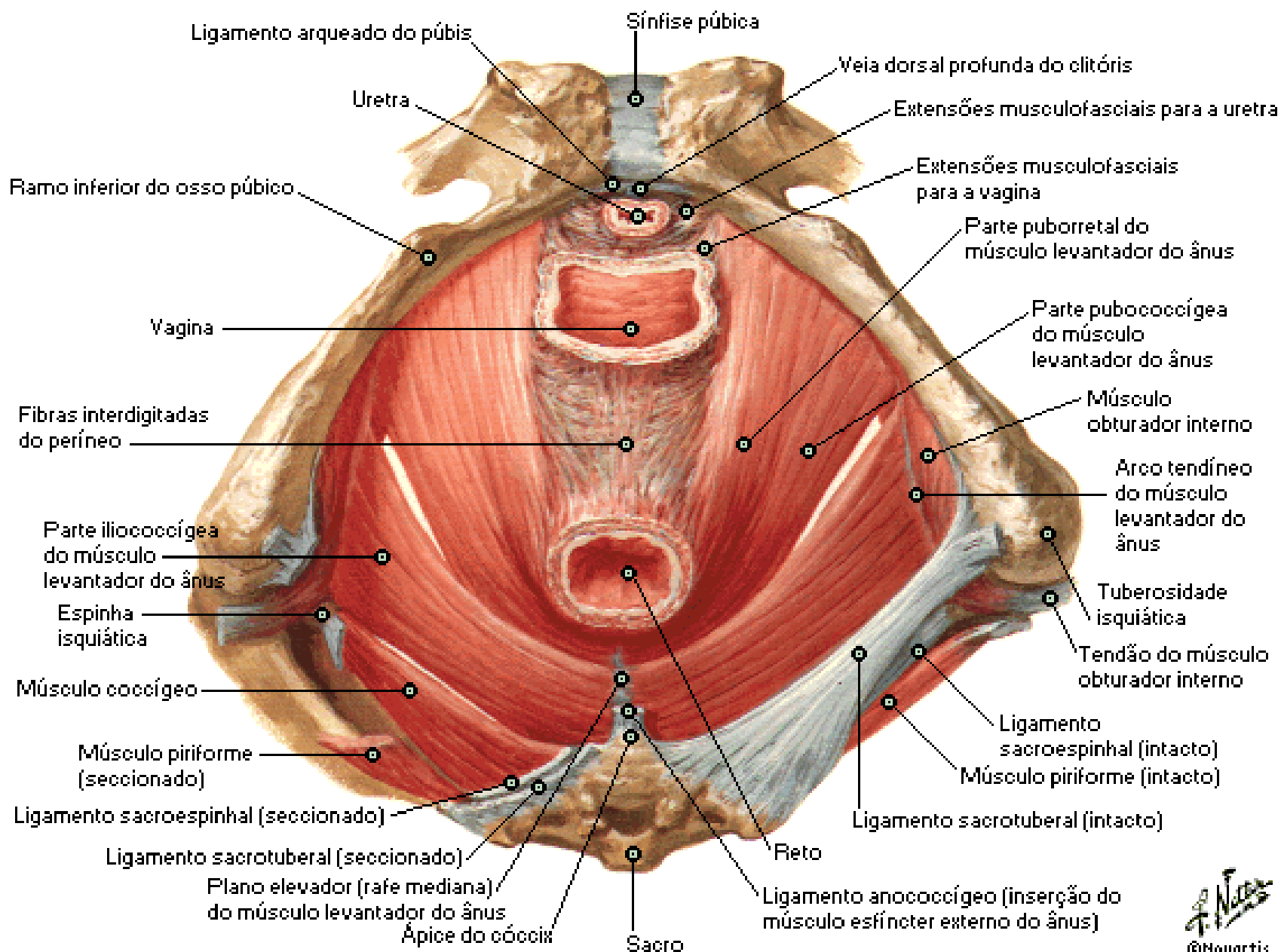
Diafragma Pélvico - Sexo Feminino

Vista Medial



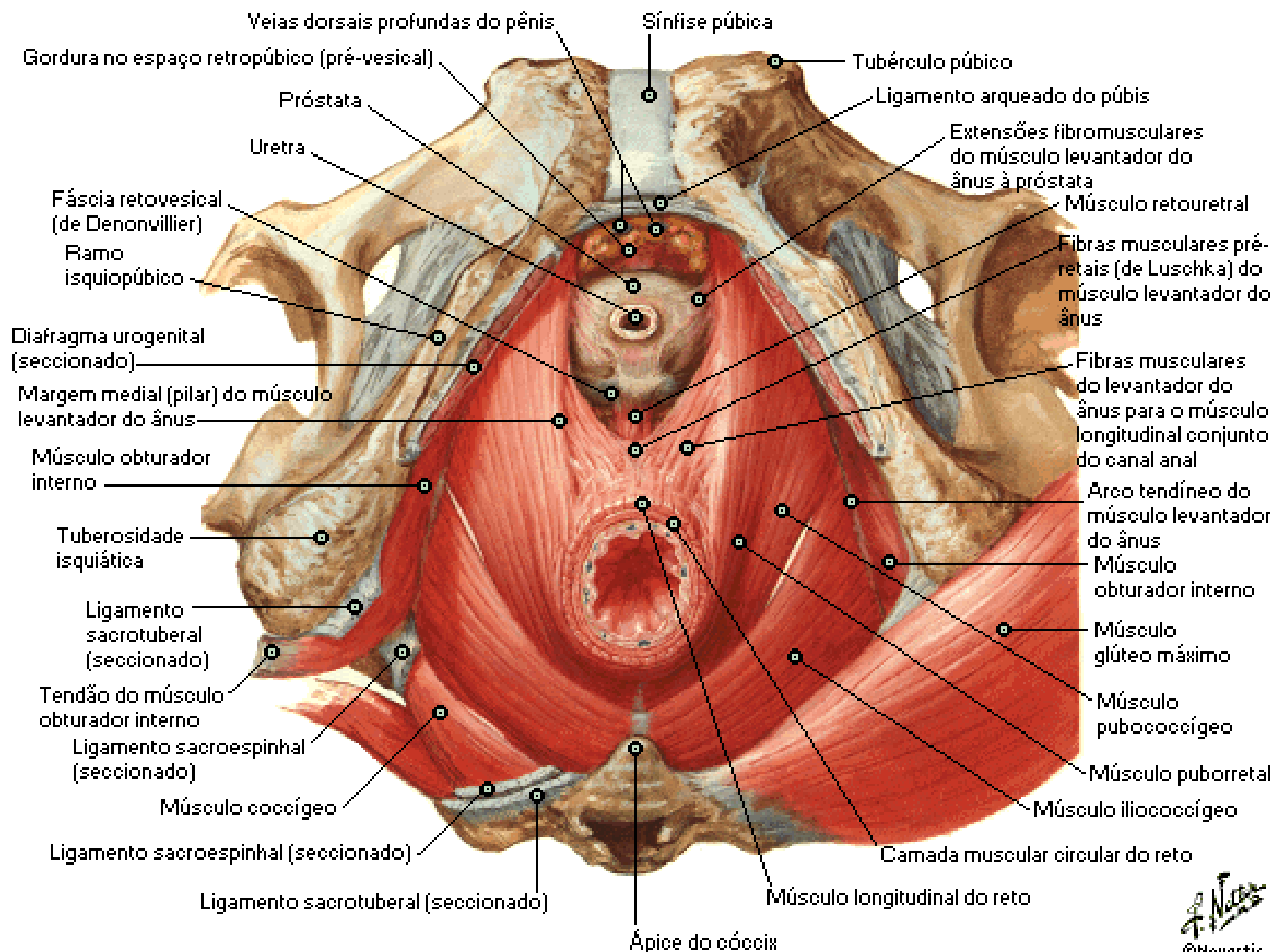
Diafragma Pélvico - Sexo Feminino

Vista Inferior



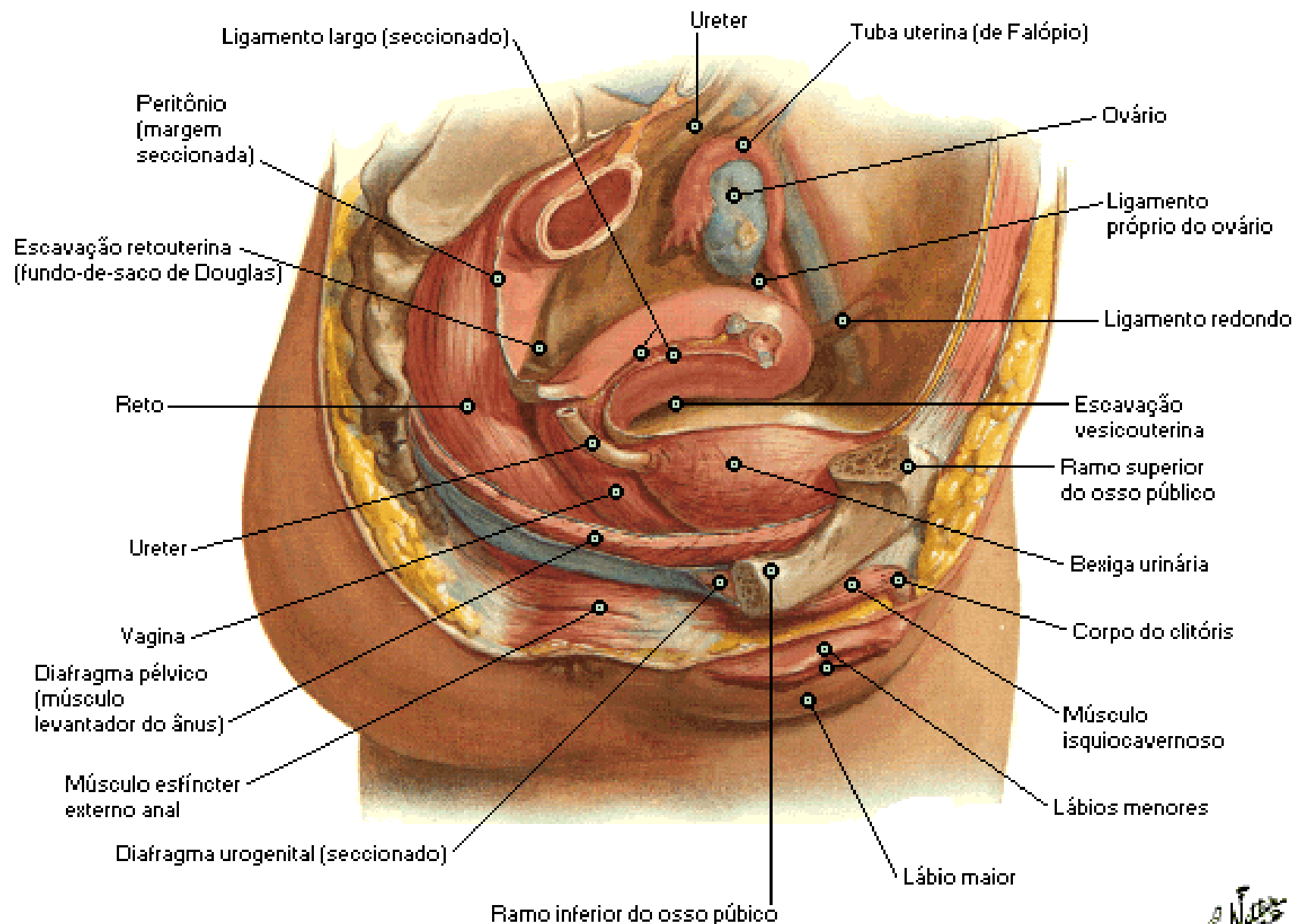
Diafragma Pélvico - Sexo Masculino

Vista Inferior



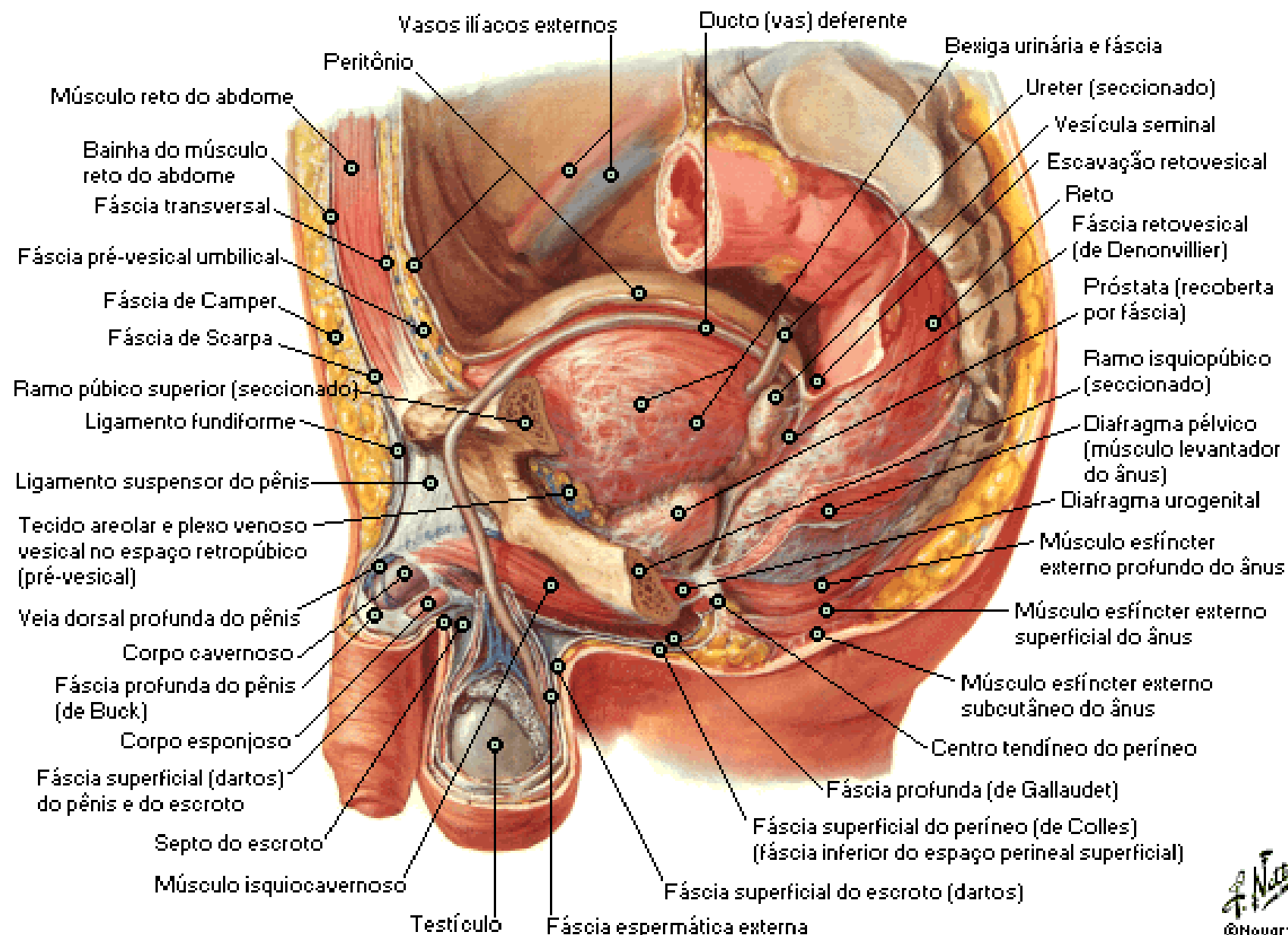
Vísceras Pélvicas e Períneo - Sexo Feminino

Secção Sagital Paramediana



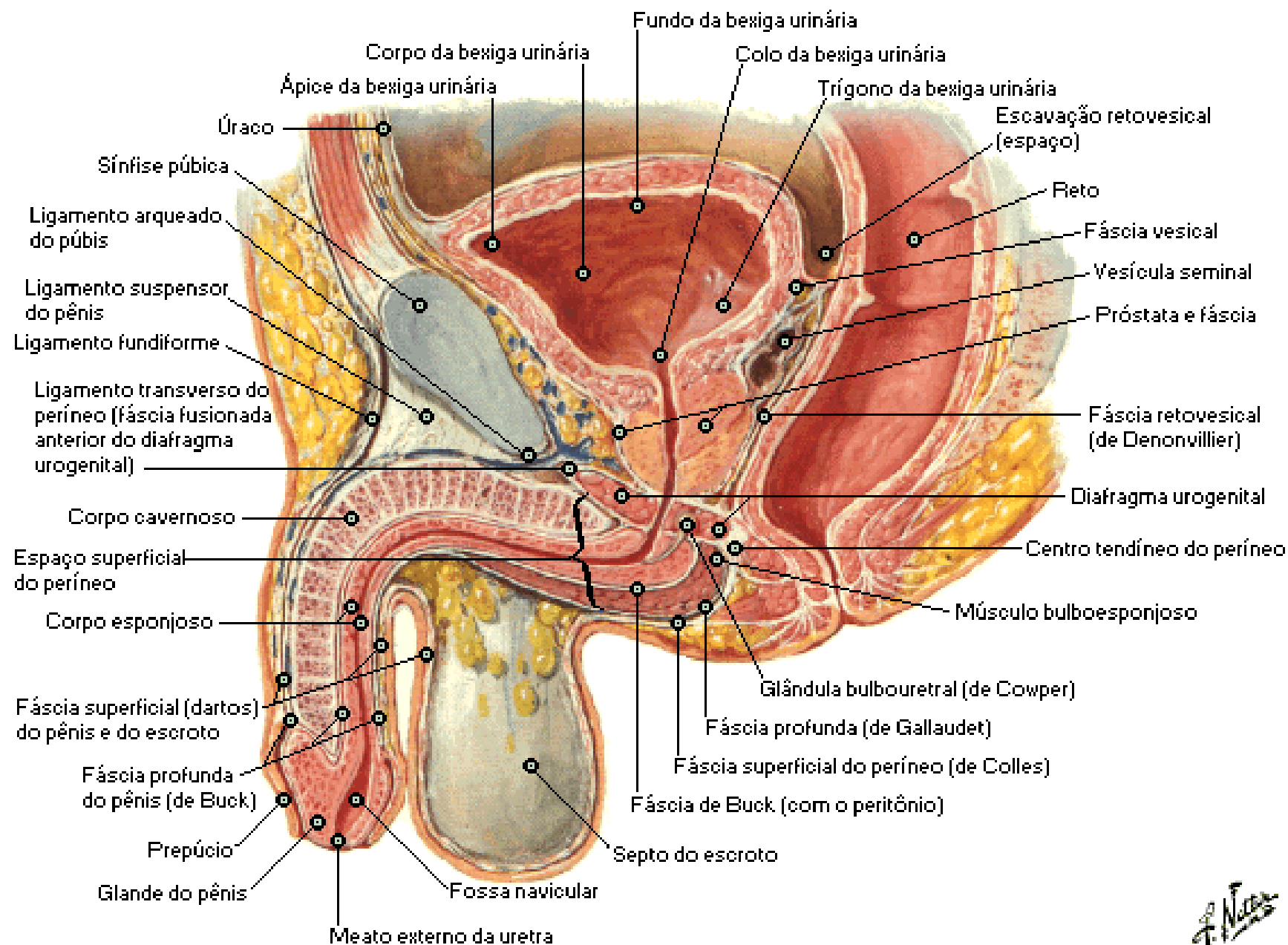
Visceras Pélvicas e Périneo - Sexo Masculino

Secção Sagital Paramediana



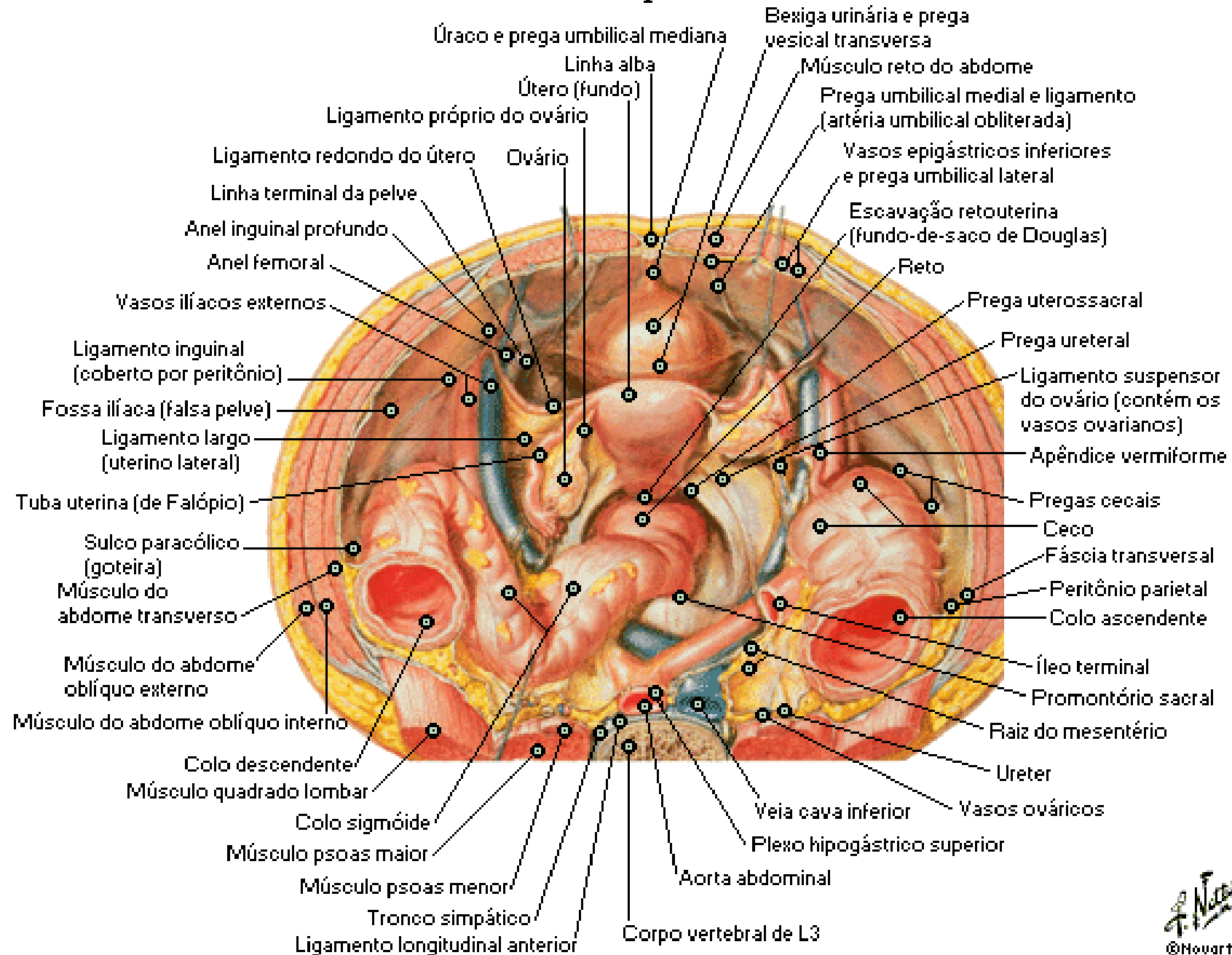
Visceras Pélvicas e Períneo - Sexo Masculino

Secção Sagital Mediana



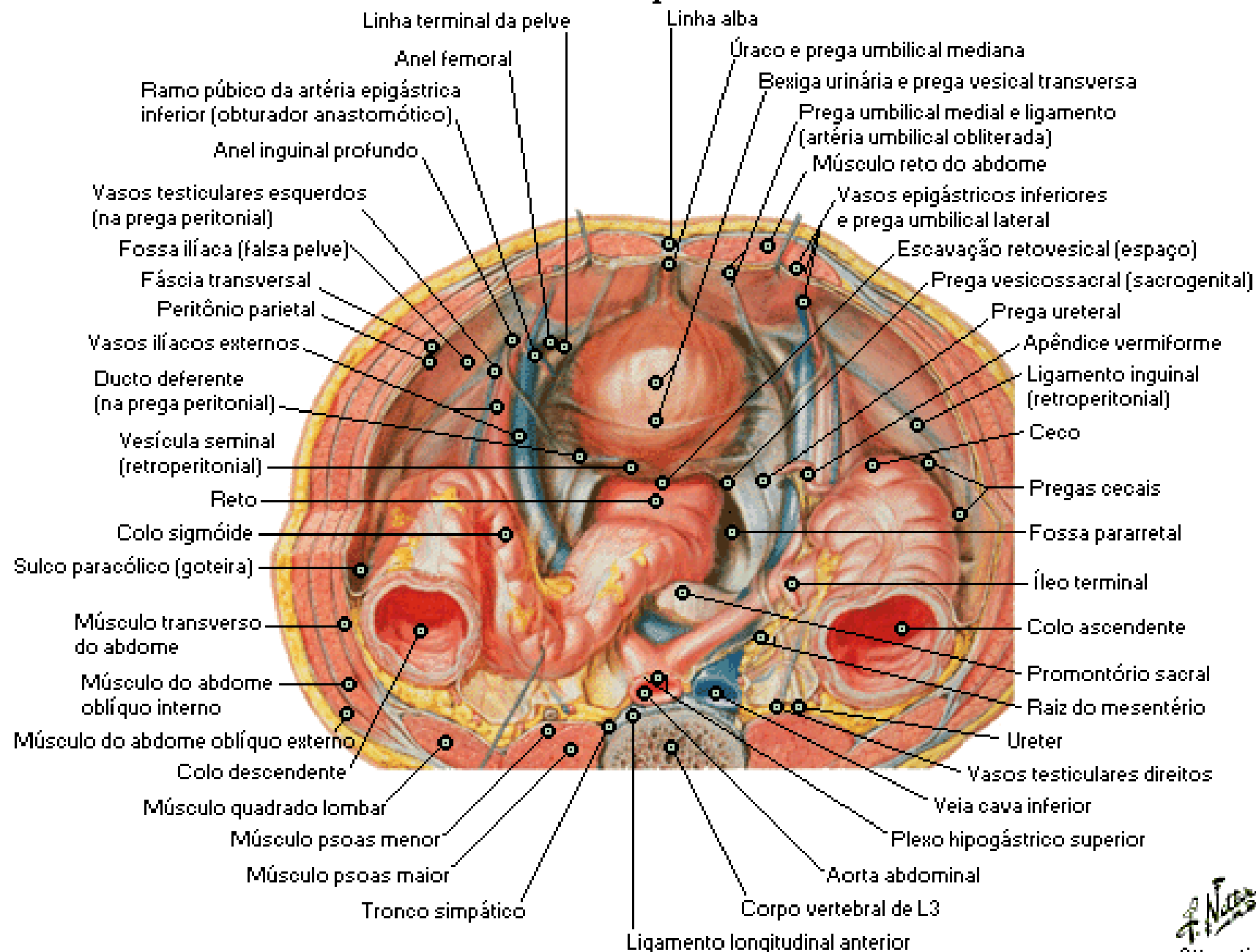
Conteúdo Pélvico - Sexo Feminino

Vista Superior



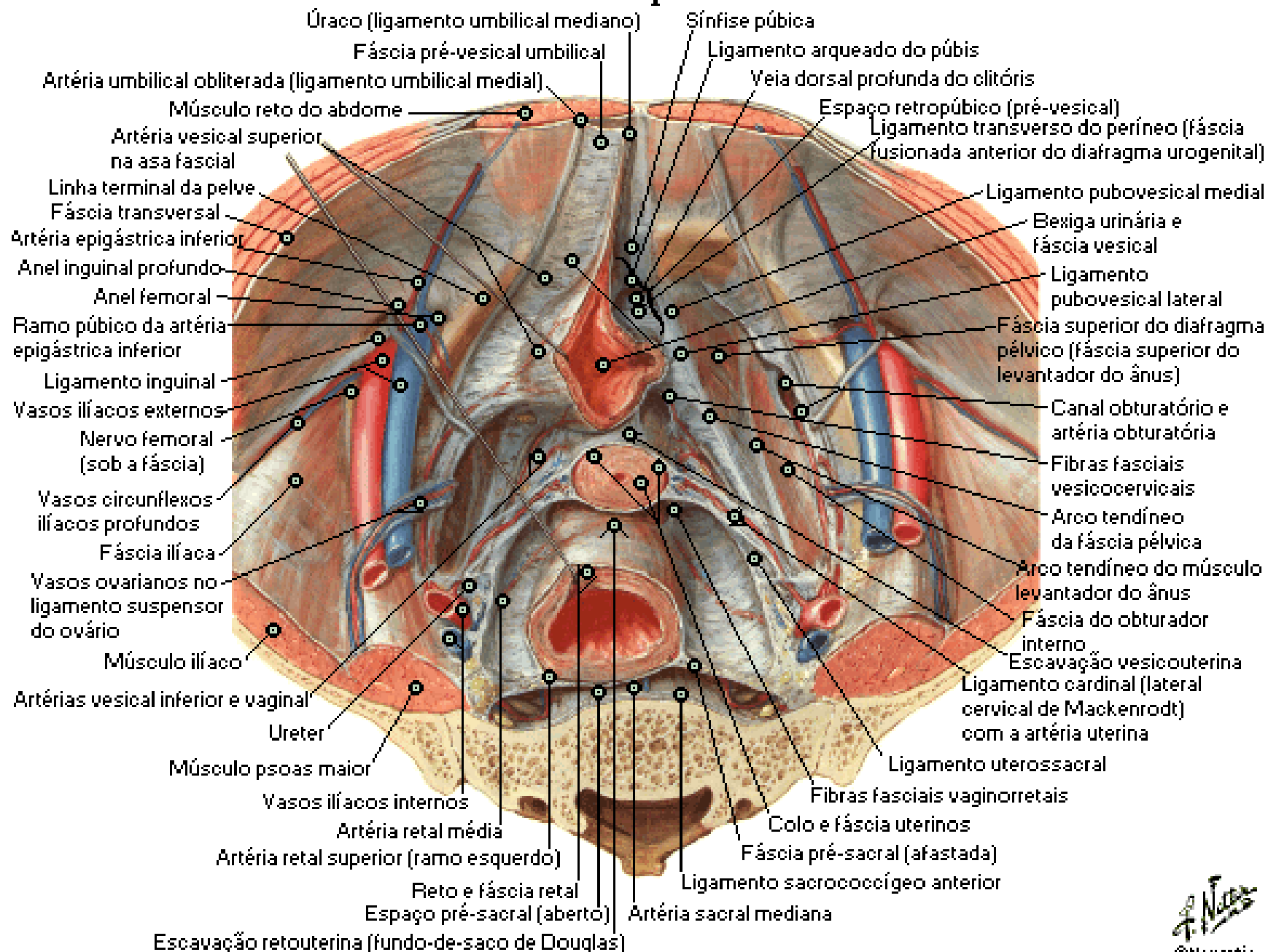
Conteúdo Pélvico - Sexo Masculino

Vista Superior



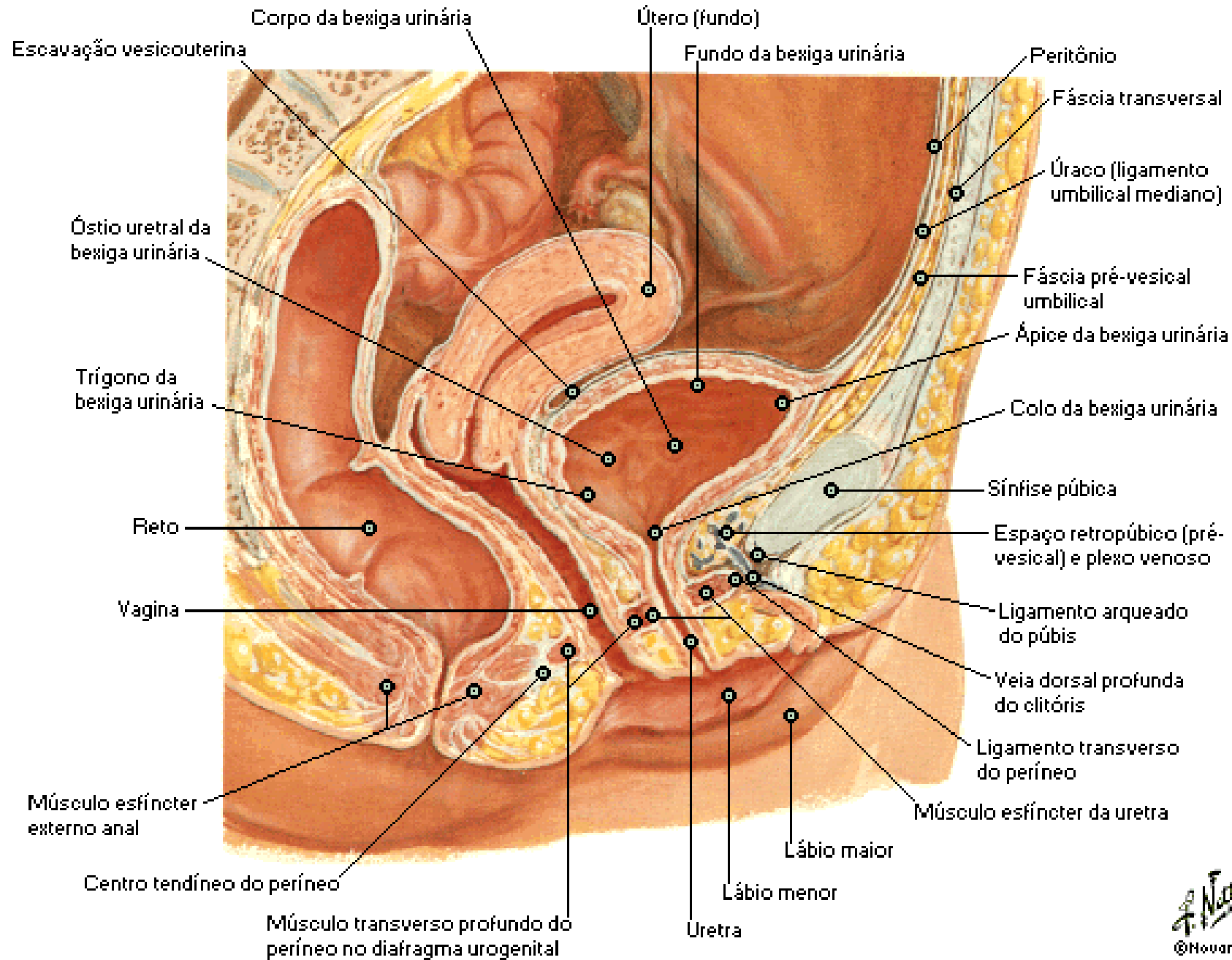
Fáscia e Espaços Endopélvicos - Sexo Feminino

Vista Superior



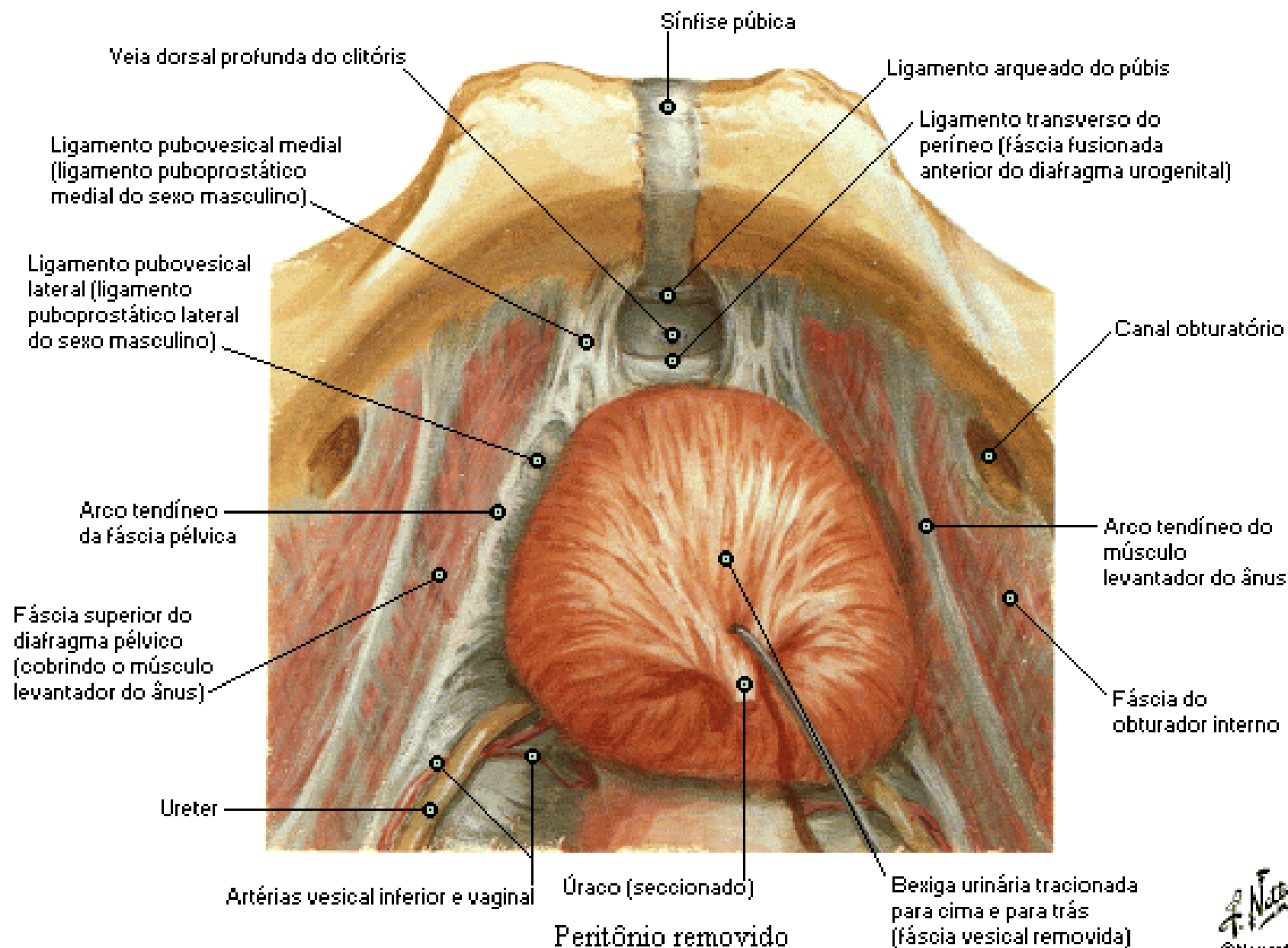
Bexiga Urinária - Orientação e Sustentação

Secção Sagital Mediana



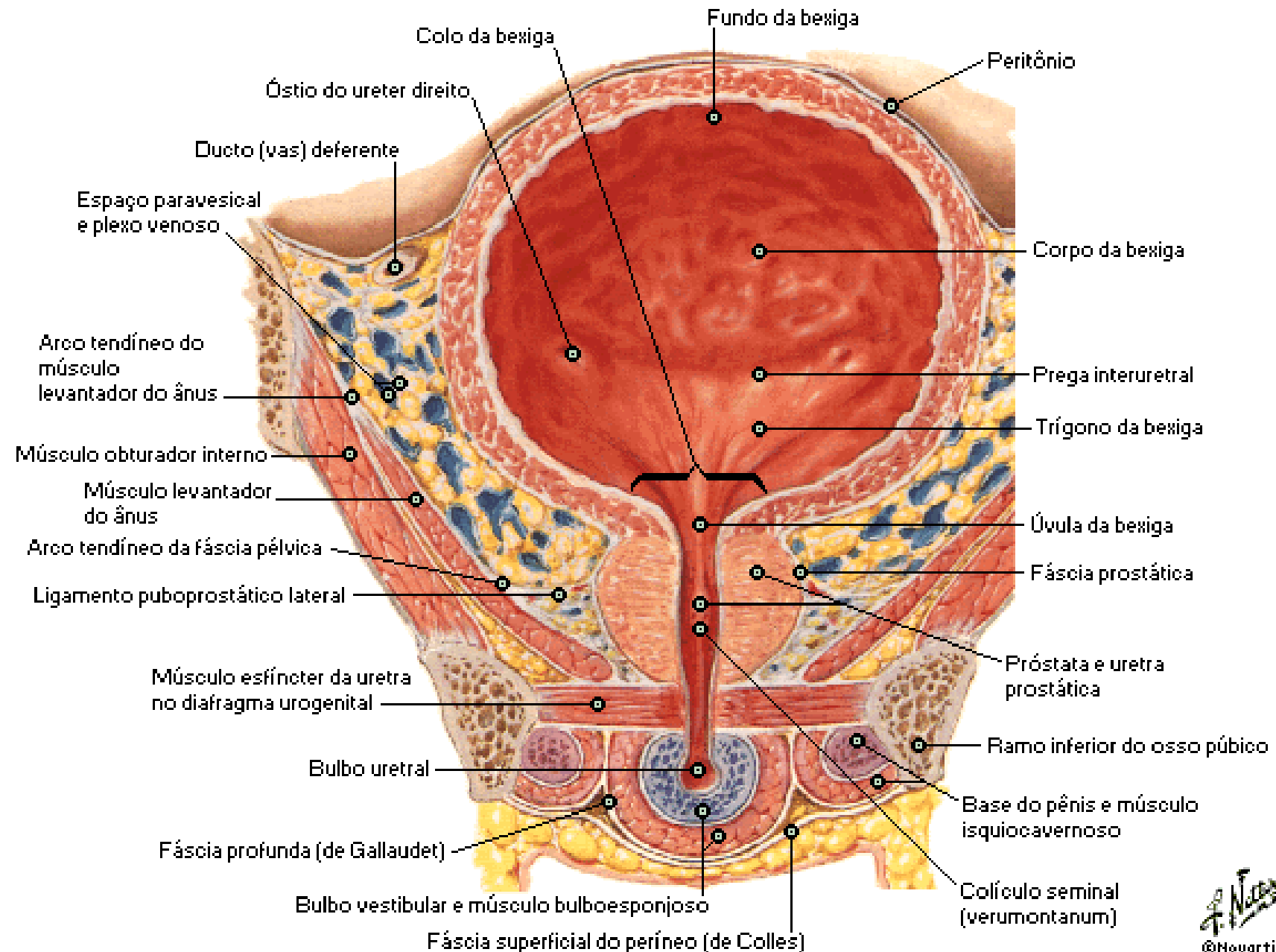
Bexiga Urinária - Orientação e Sustentação

Vista Superior



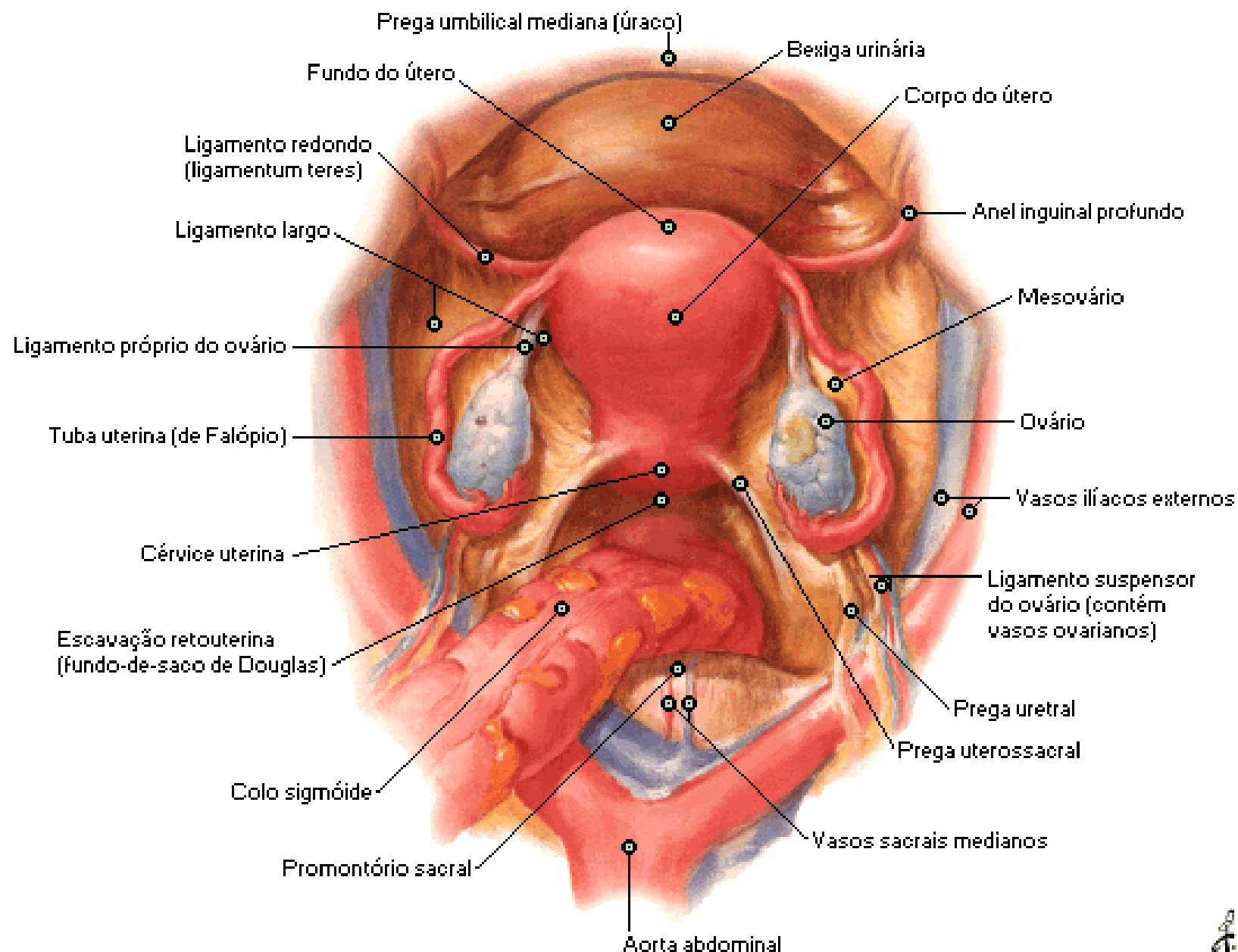
Bexiga Urinária - Masculina

Secção Frontal



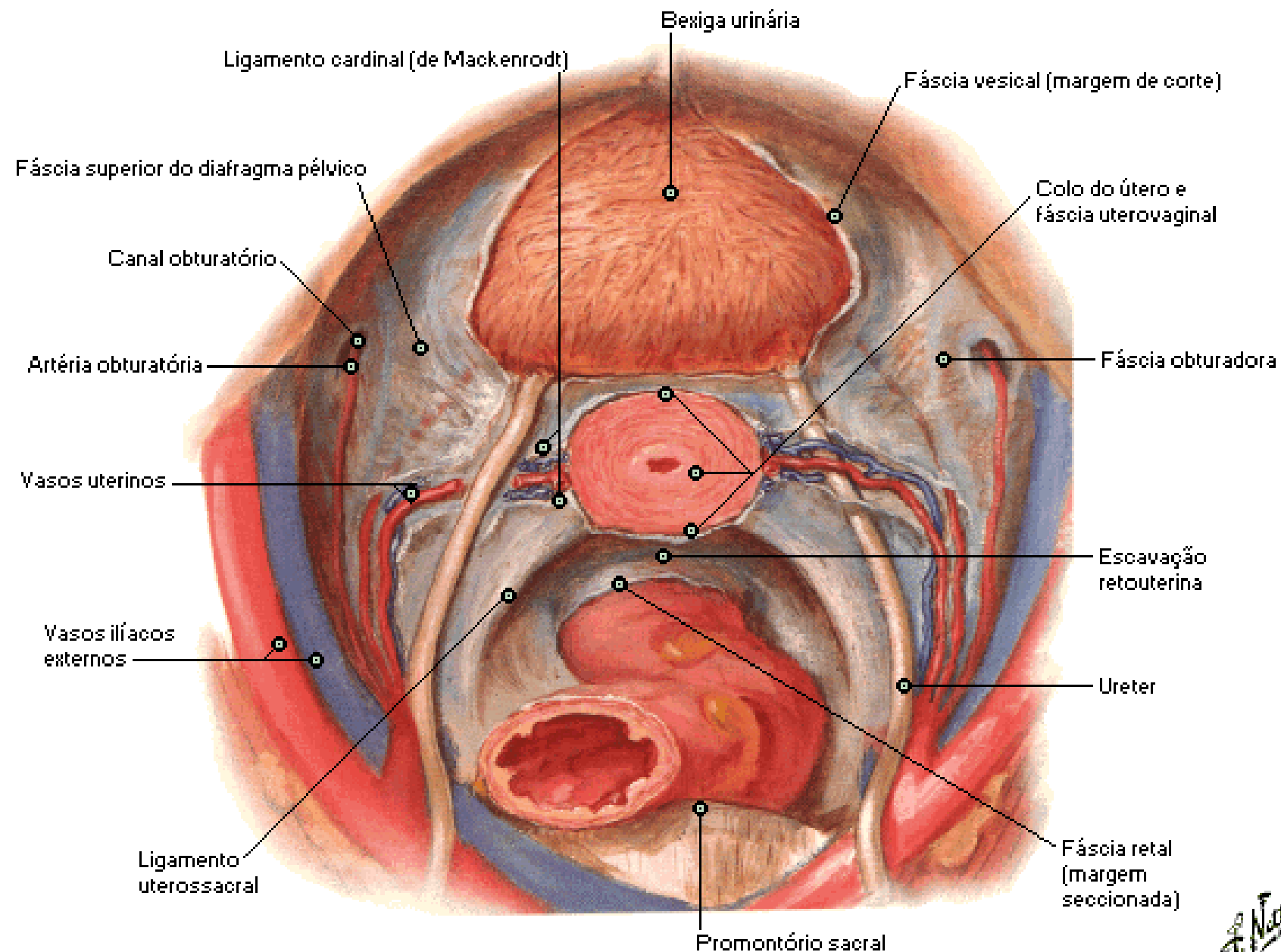
Vísceras Pélvicas - Sexo Feminino

Vista Superior com Peritônio Intacto

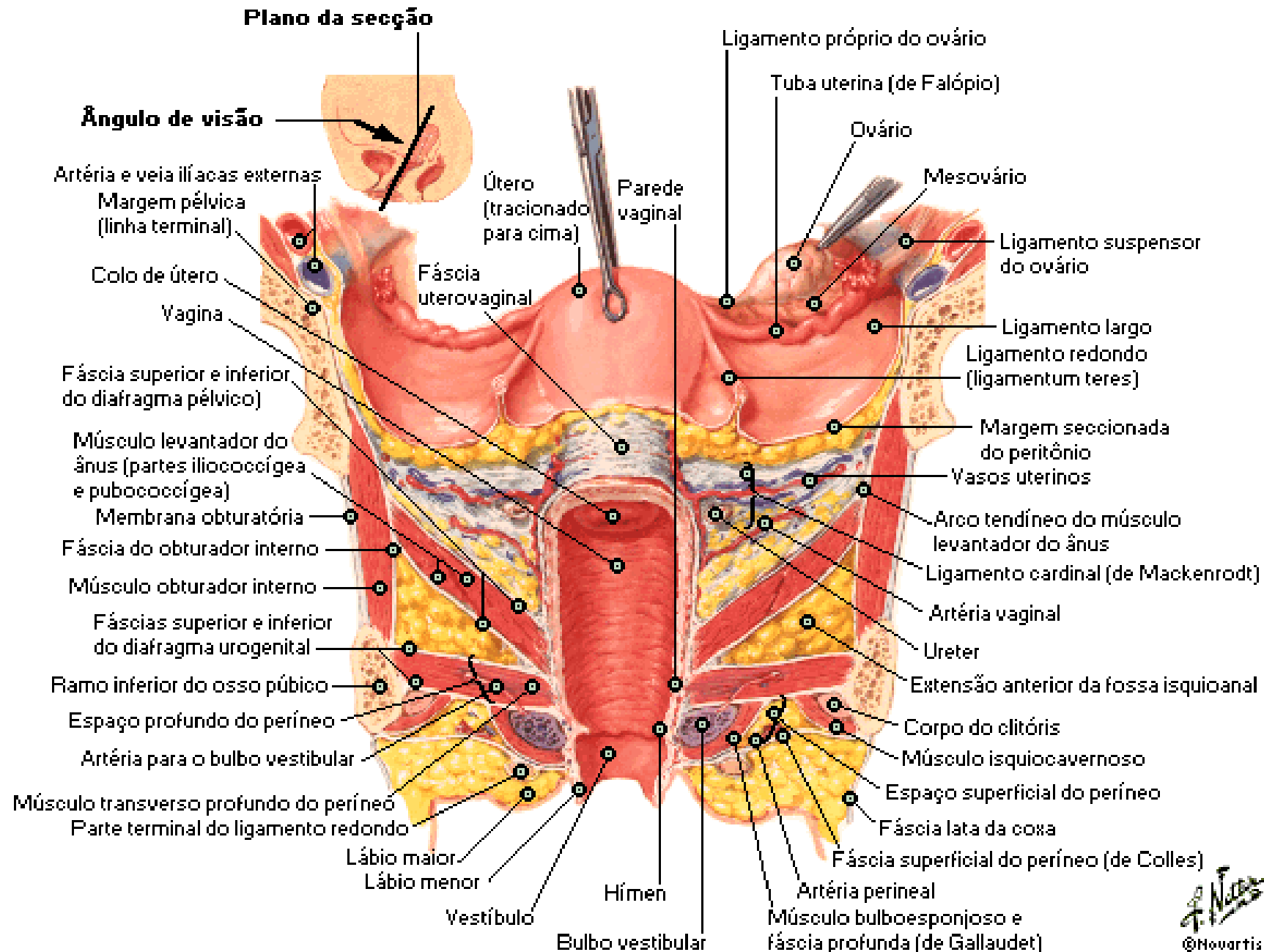


Visceras Pélvicas - Sexo Feminino

Vista Superior com Peritônio Removido

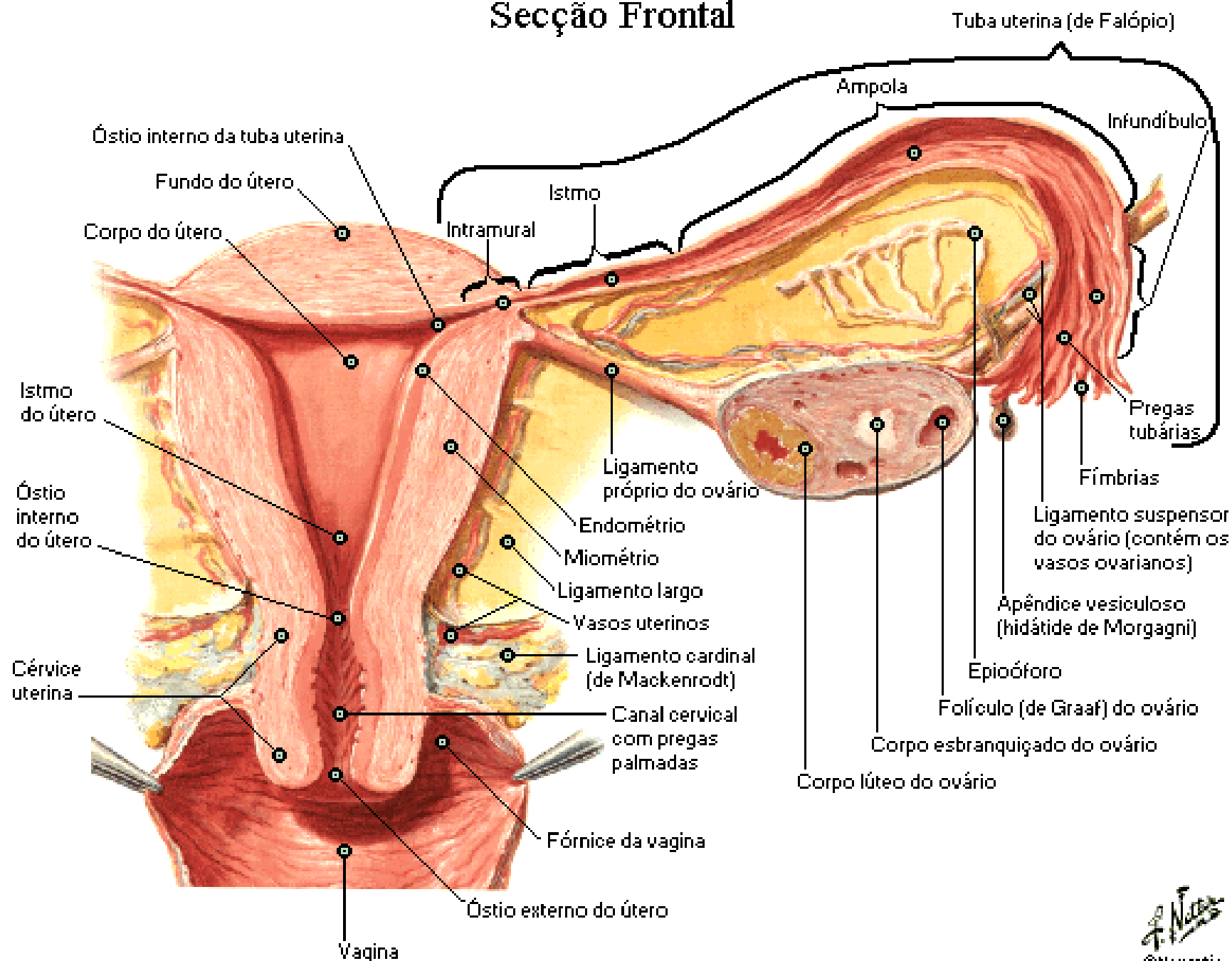


Útero, Vagina e Estruturas de Sustentação



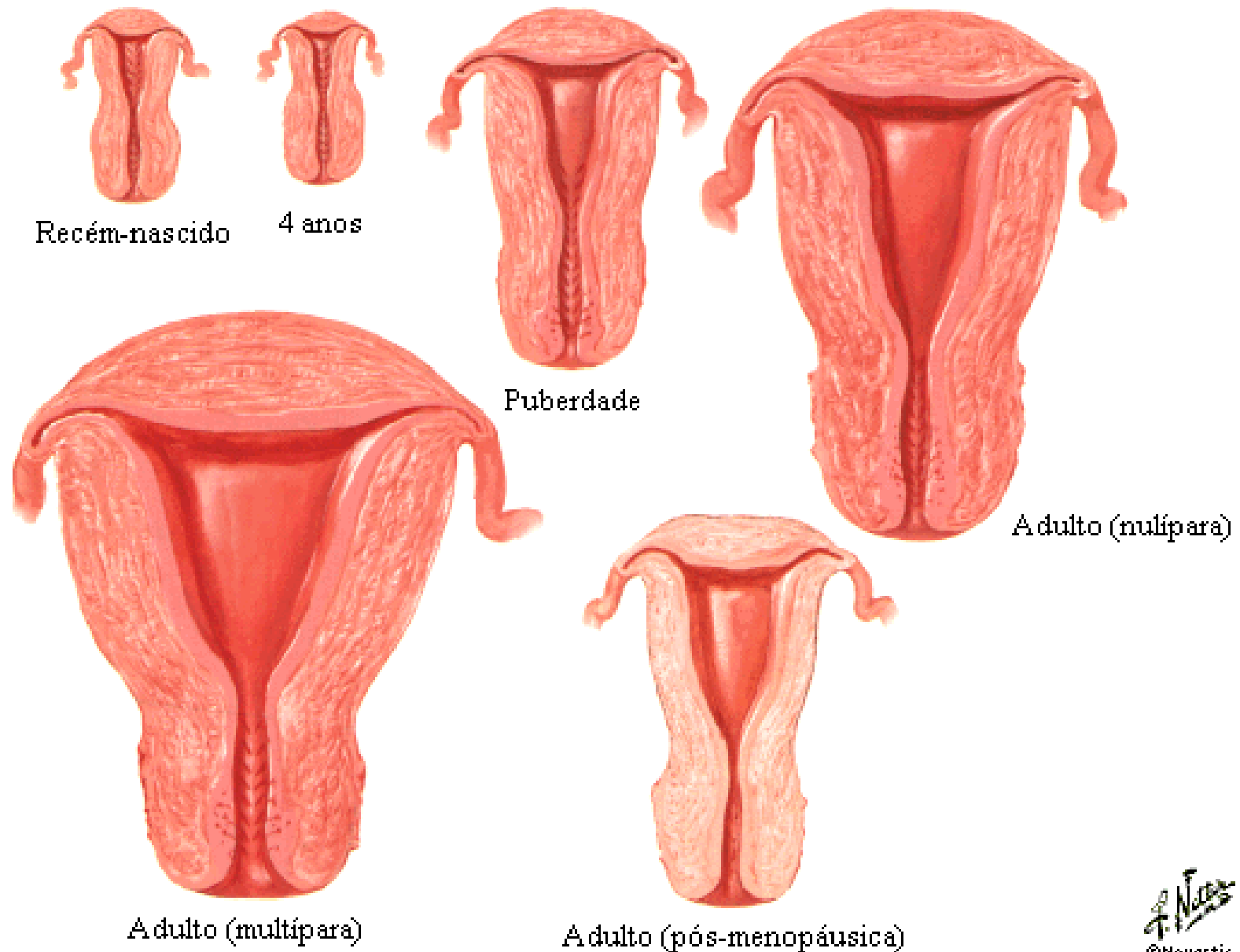
Útero e Anexos

Secção Frontal



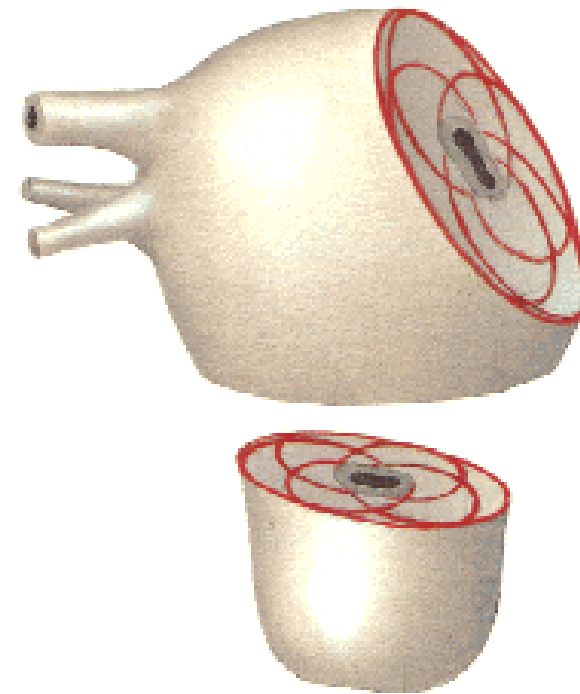
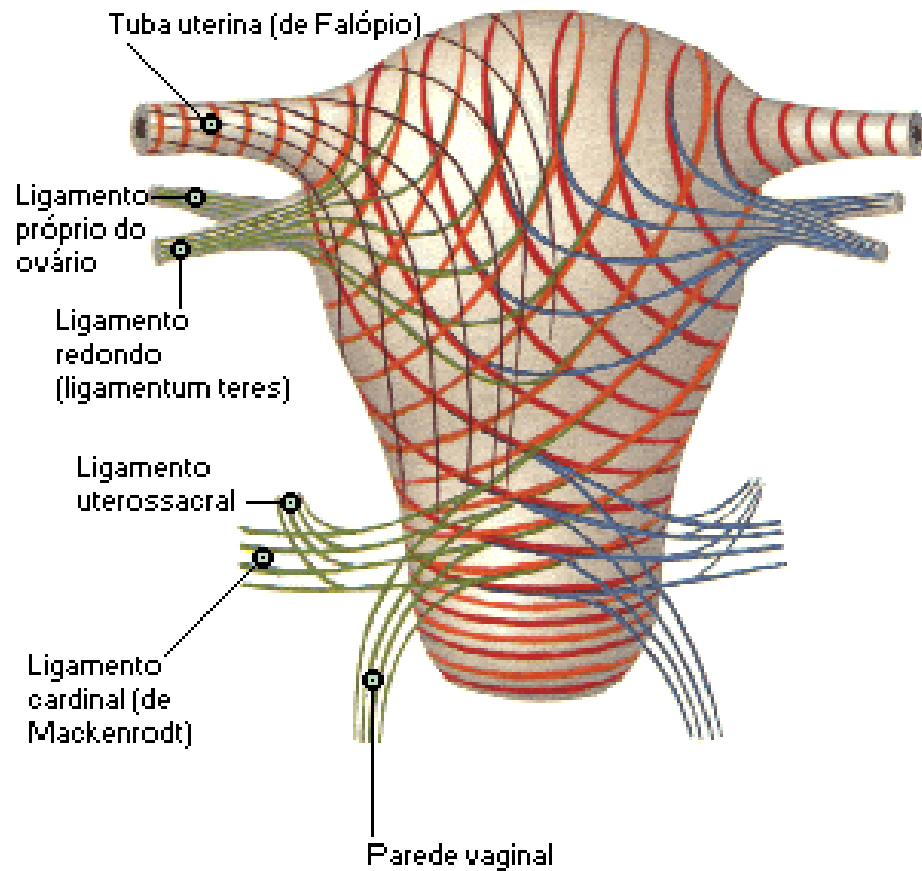
Útero

Alterações com a Idade



Útero

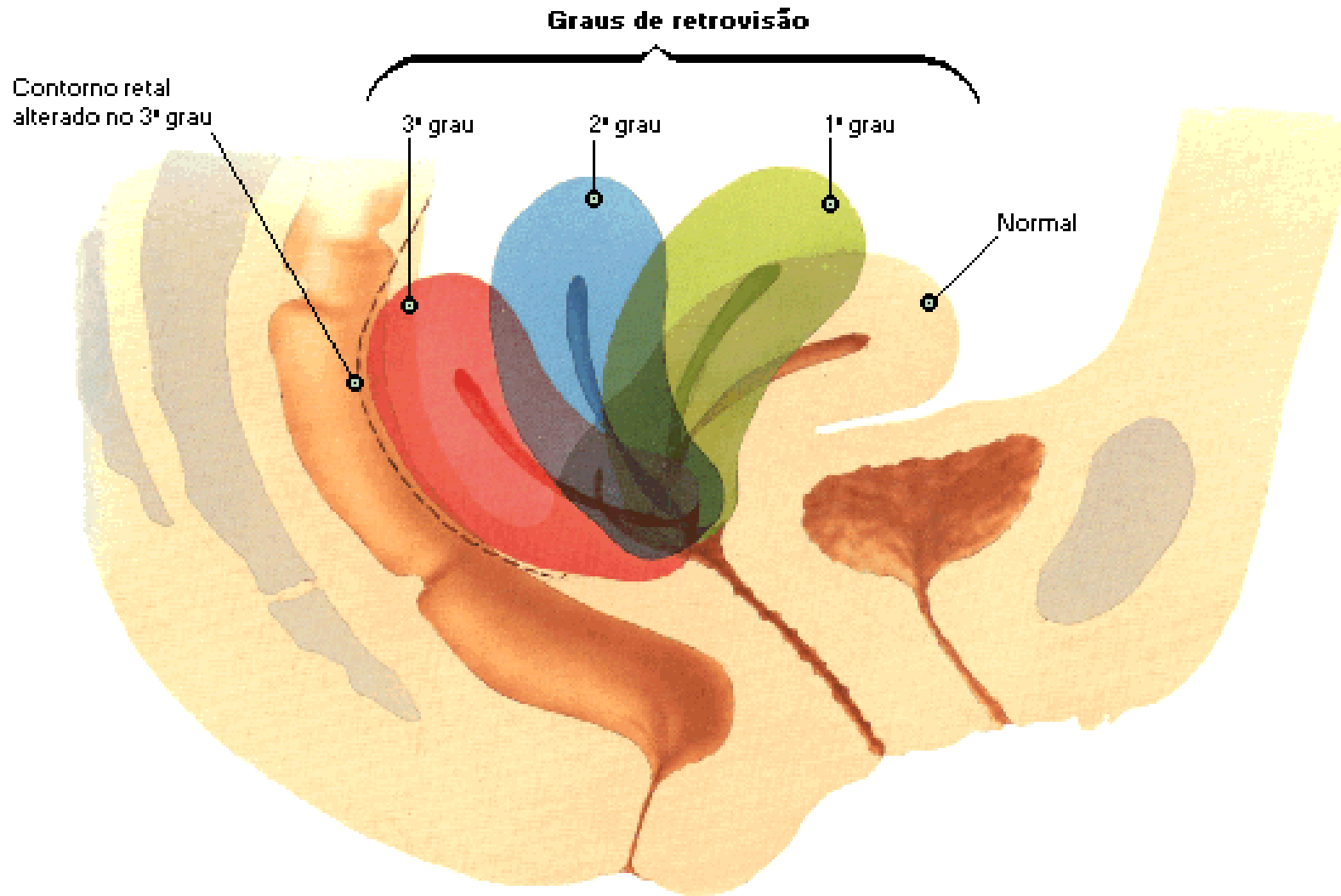
Esquema da Musculatura



Fibras espirais passam profundamente dentro da parede e se entrelaçam (esquema)

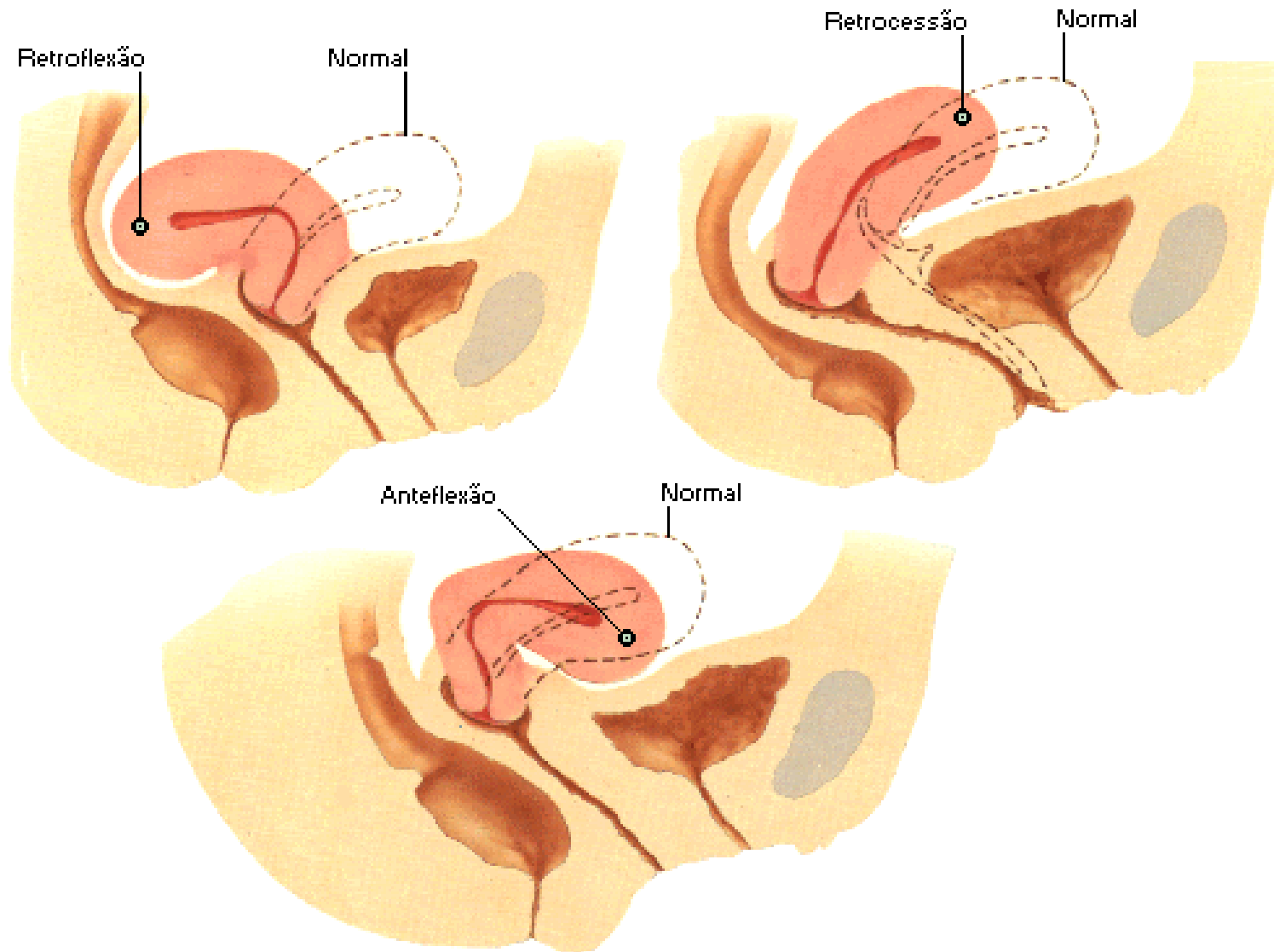
Útero

Variações na Posição



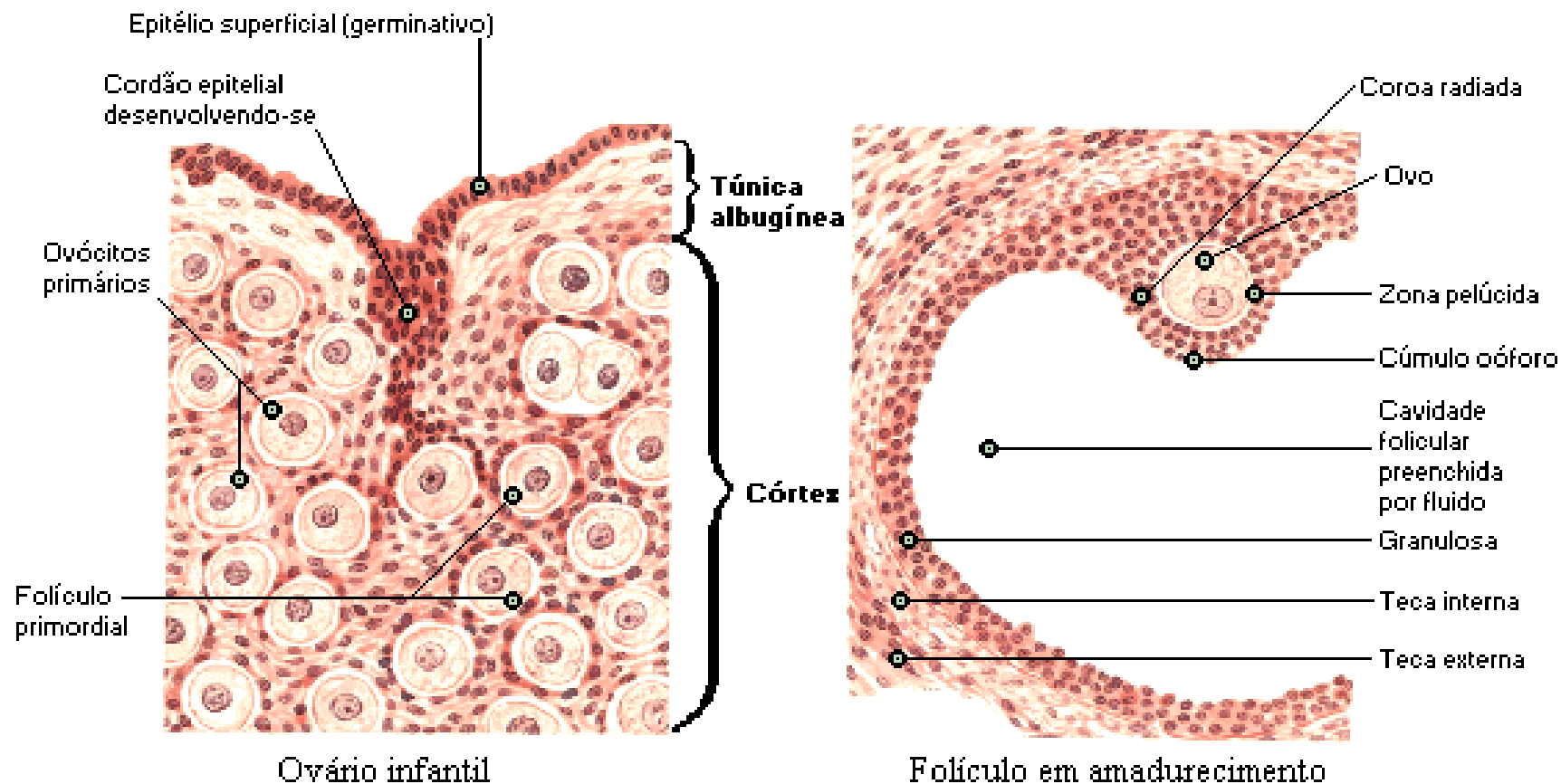
Útero [Continuação]

Variações na Posição

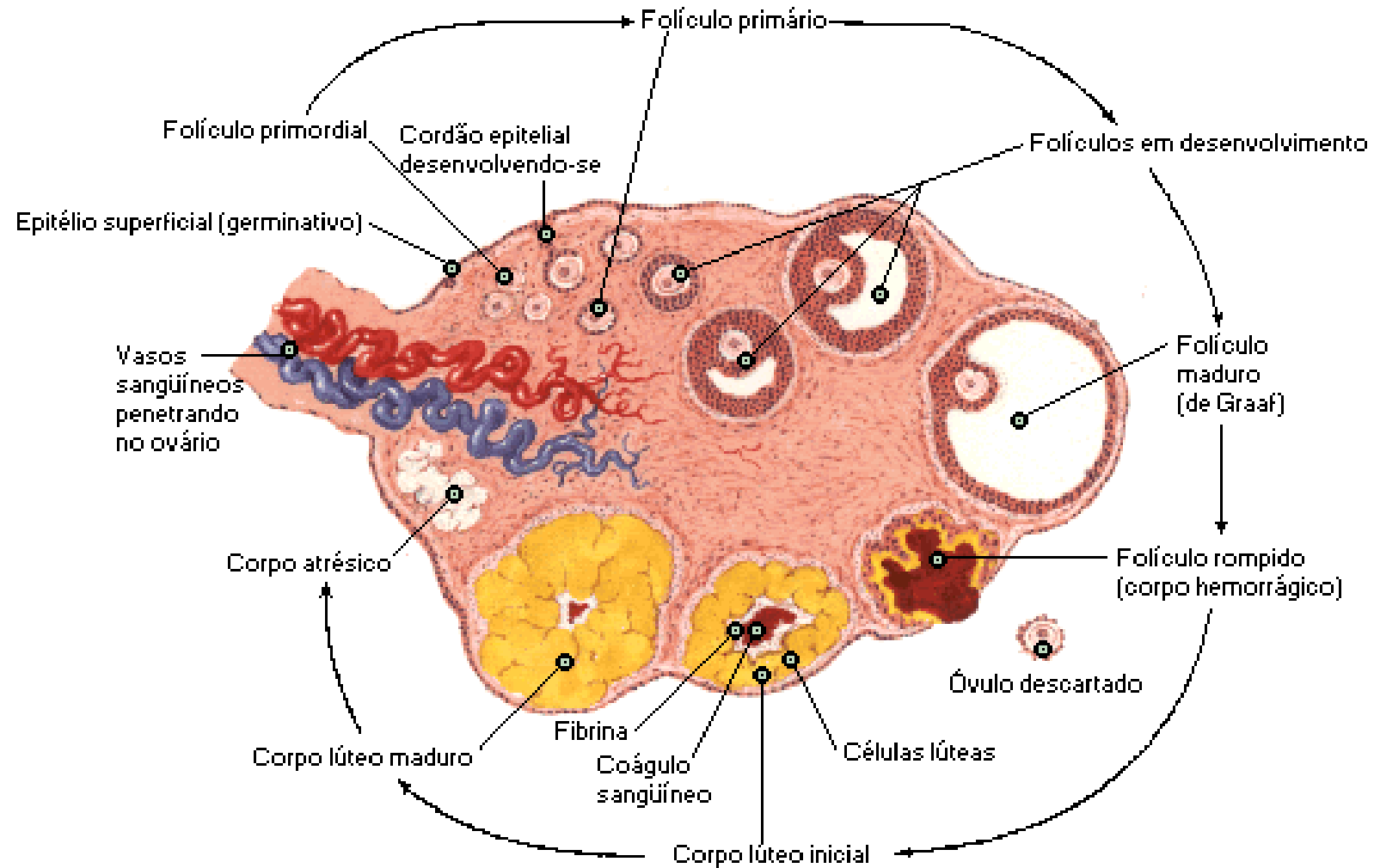


Ovário Infantil e Folículo em Amadurecimento

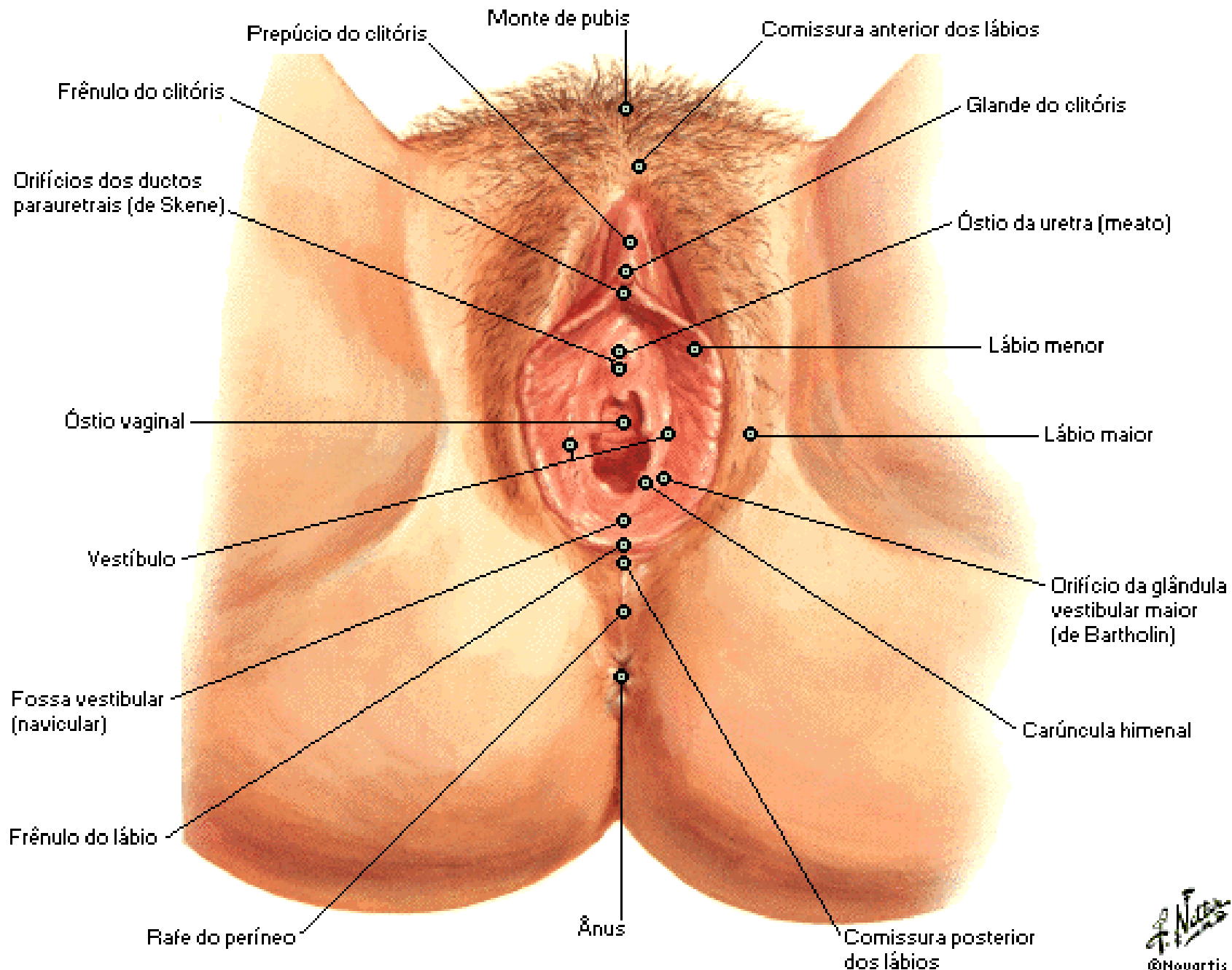
Histologia



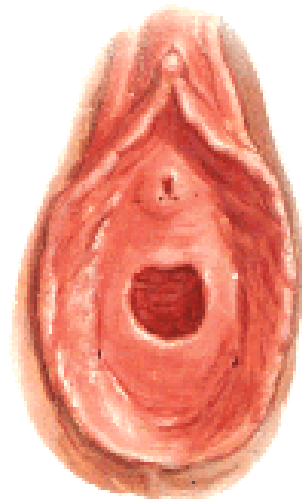
Estágios do Ovócitos e Folículo



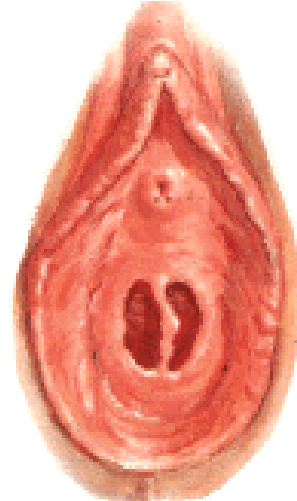
Períneo e Órgãos Genitais Externos - Sexo Feminino



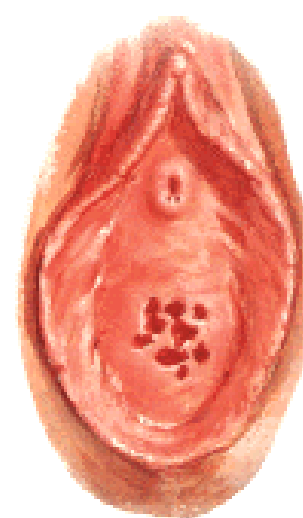
Períneo e Órgãos Genitais Externos - Sexo Feminino [Continuação]



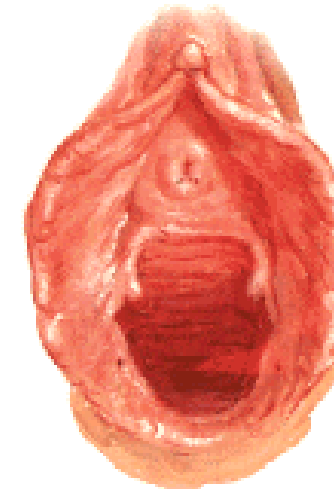
Hímen anular



Hímen septado



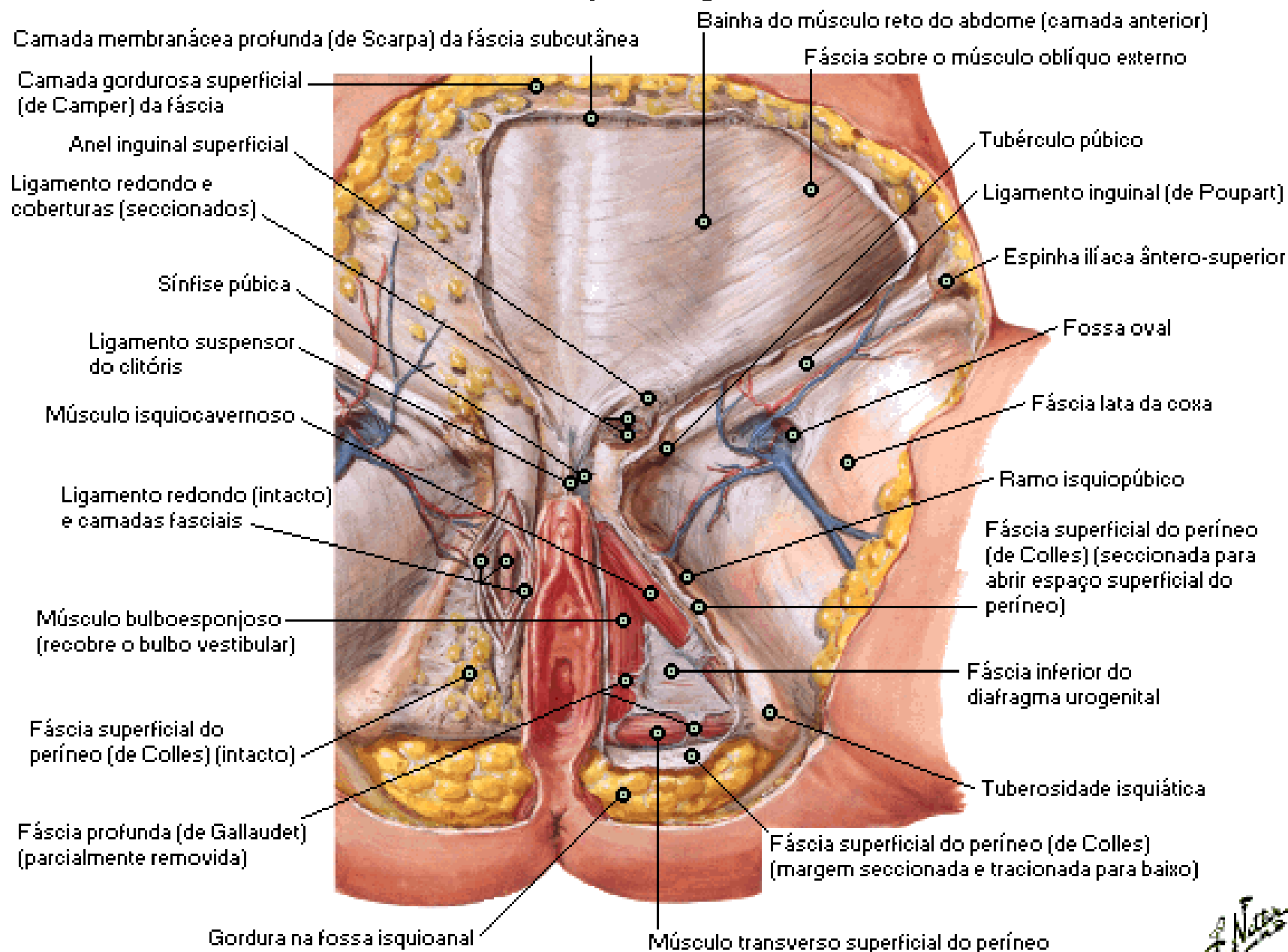
Hímen cribiforme



Intróito gestado

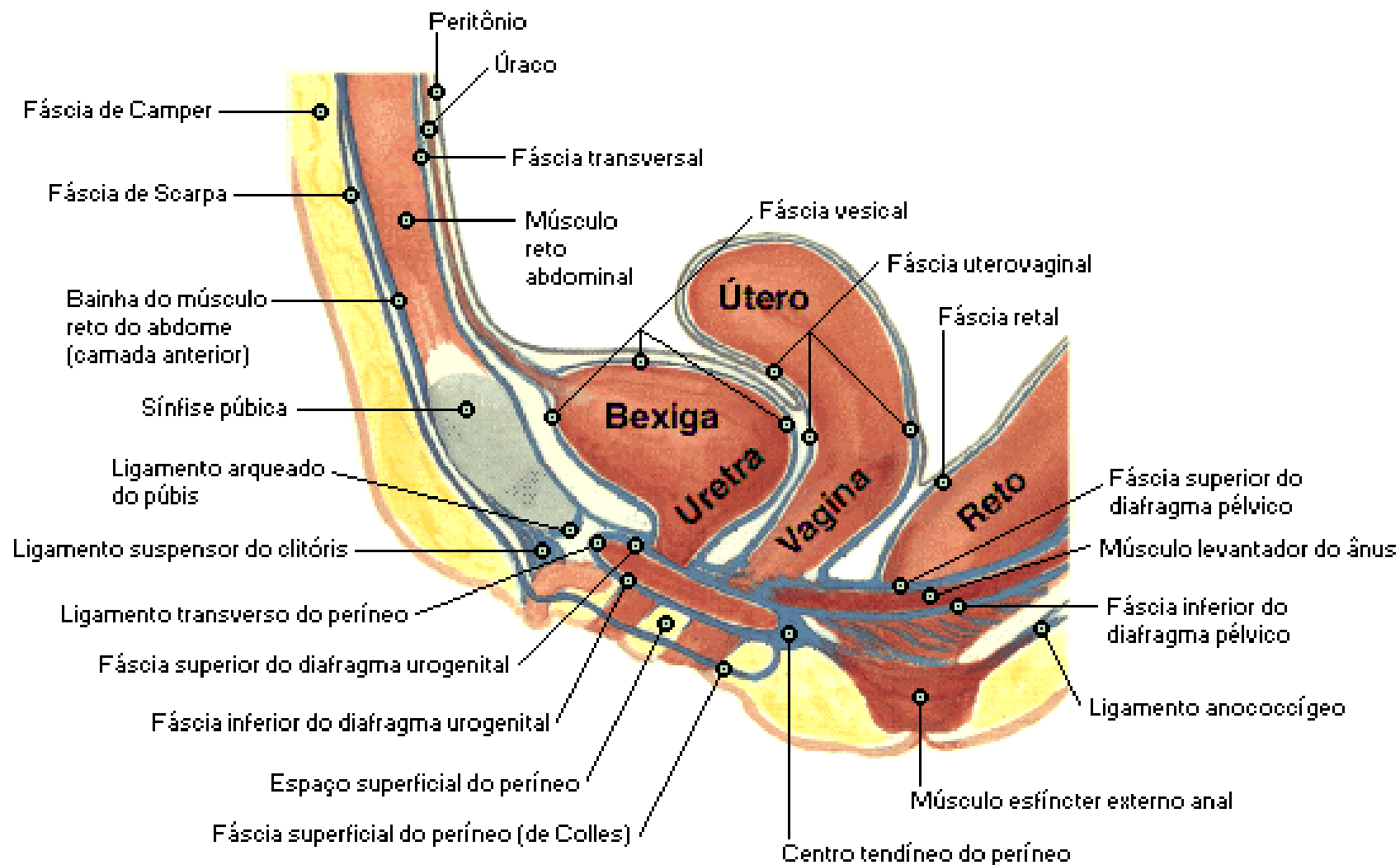
Períneo - Sexo Feminino

Dissecação Superficial

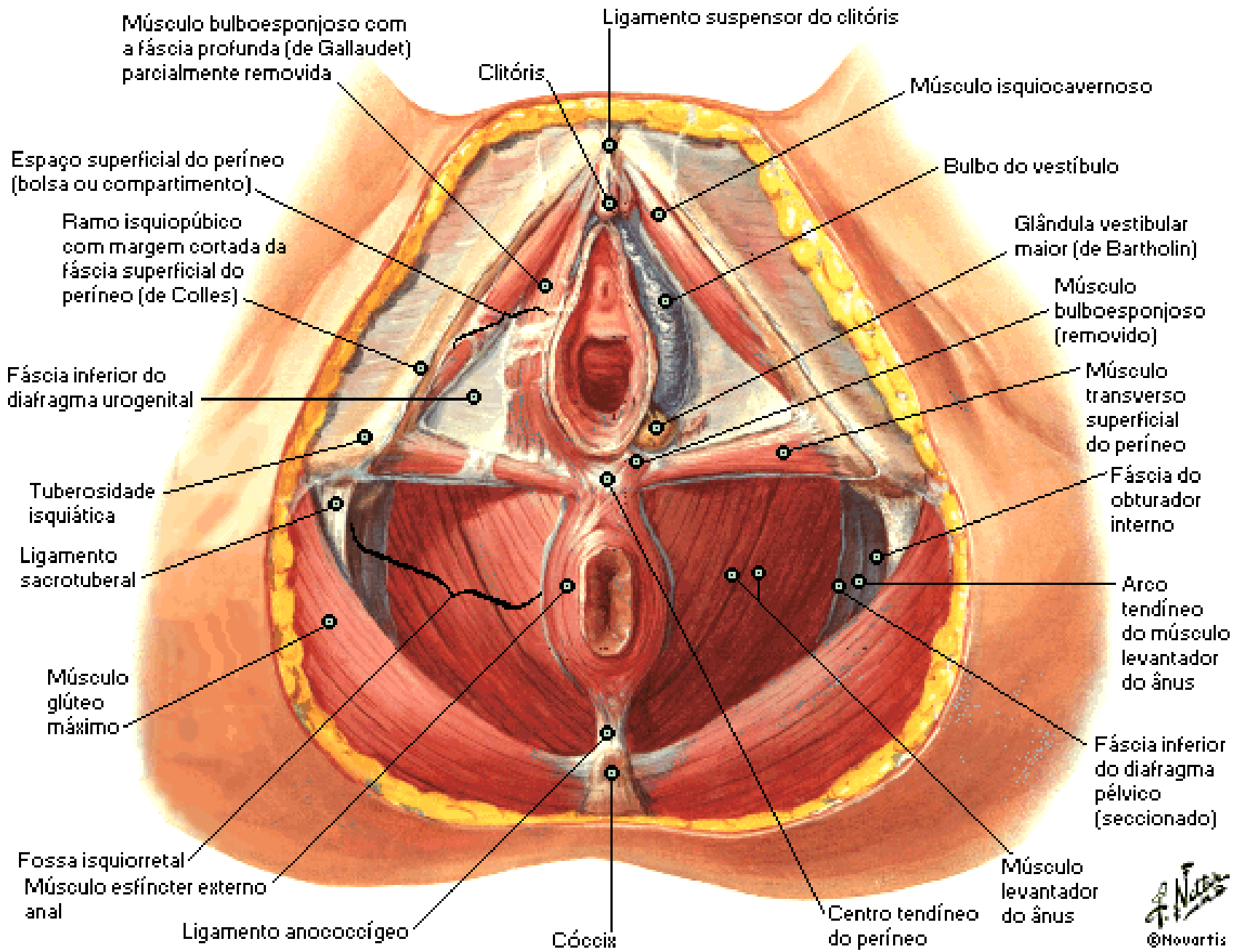


Períneo - Sexo Feminino

Secção Sagital Mediana

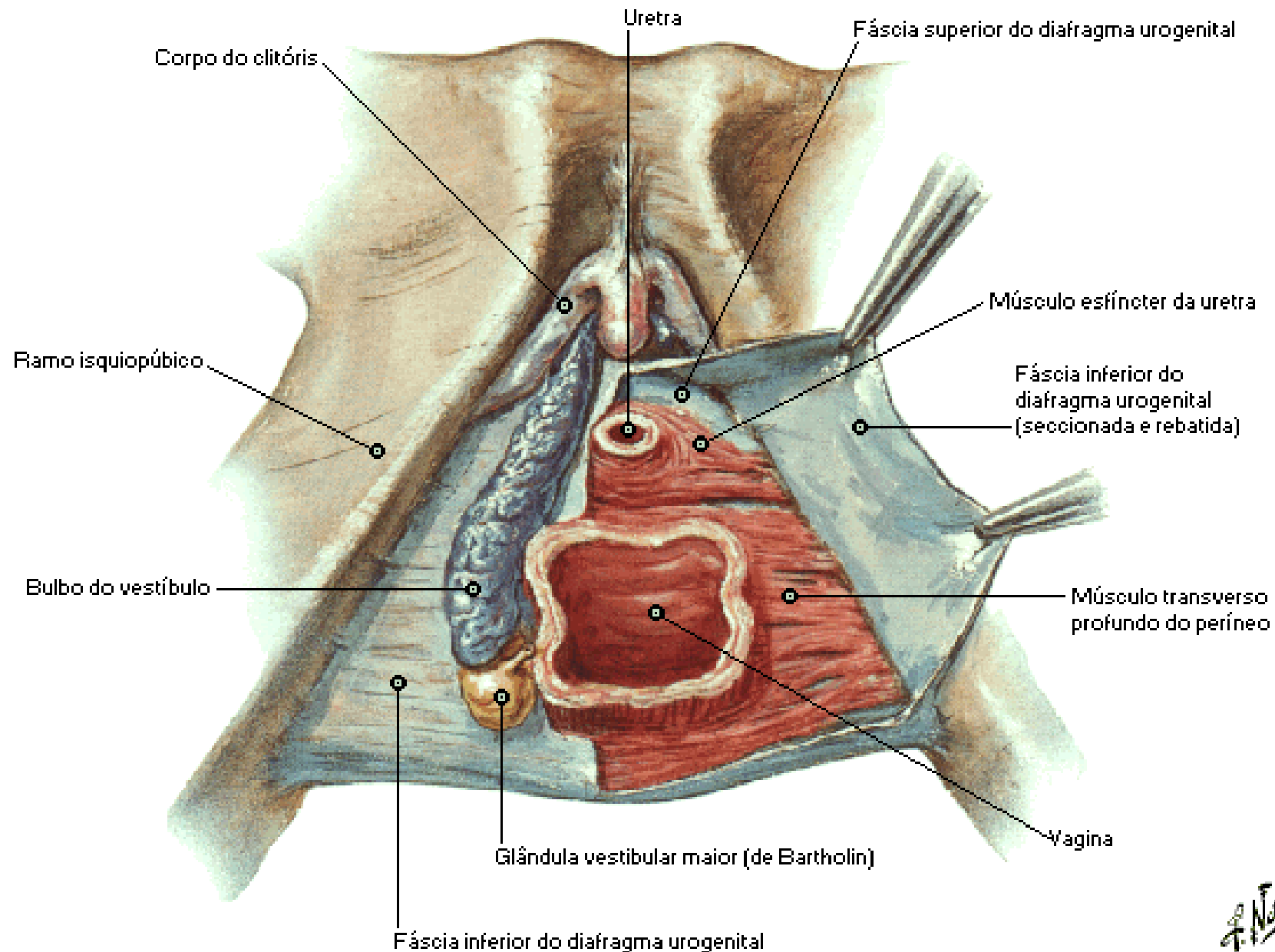


Períneo e Diafragma Urogenital - Sexo Feminino



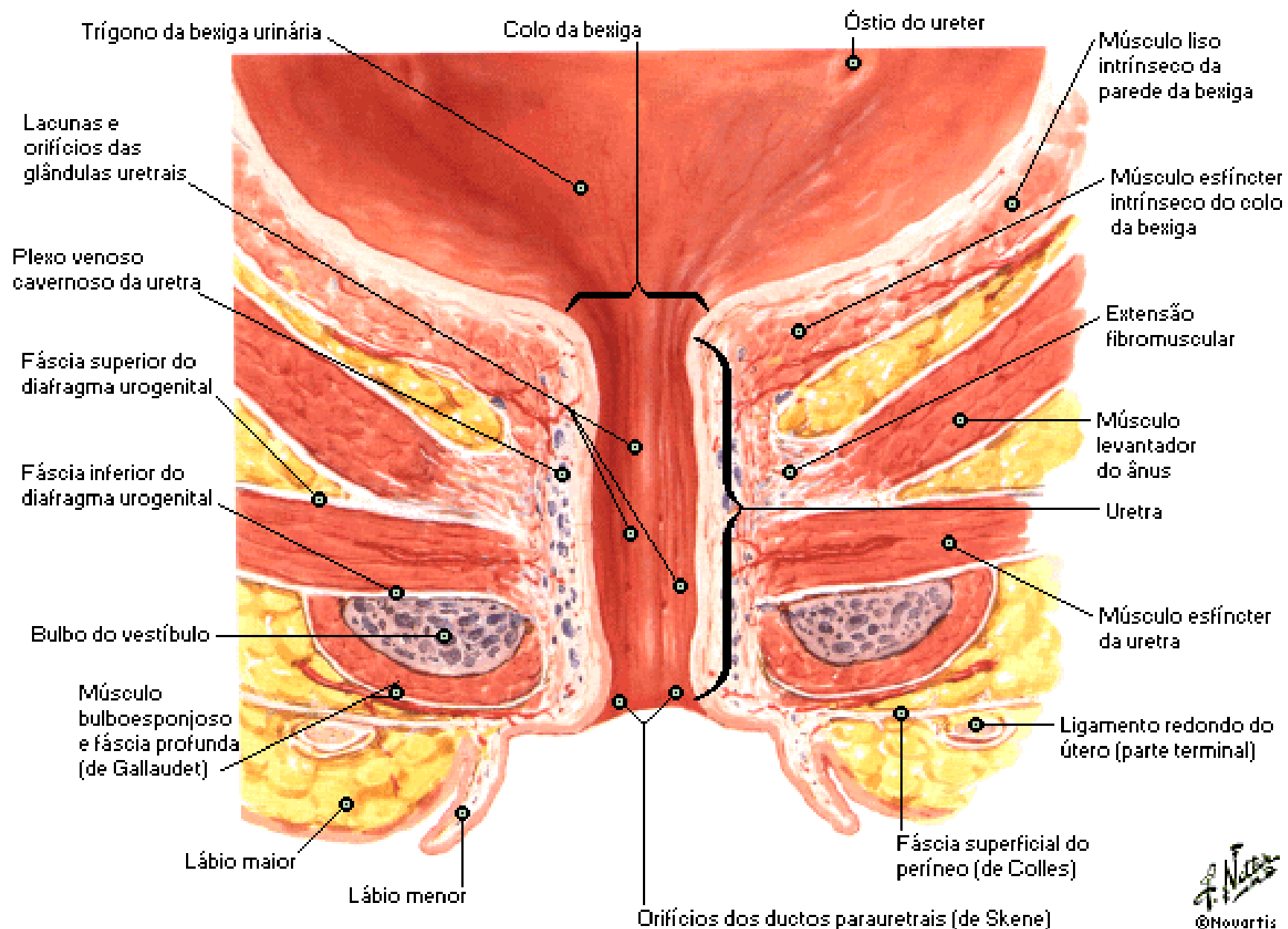
Períneo e Diafragma Urogenital - Sexo Feminino

Dissecação Profunda



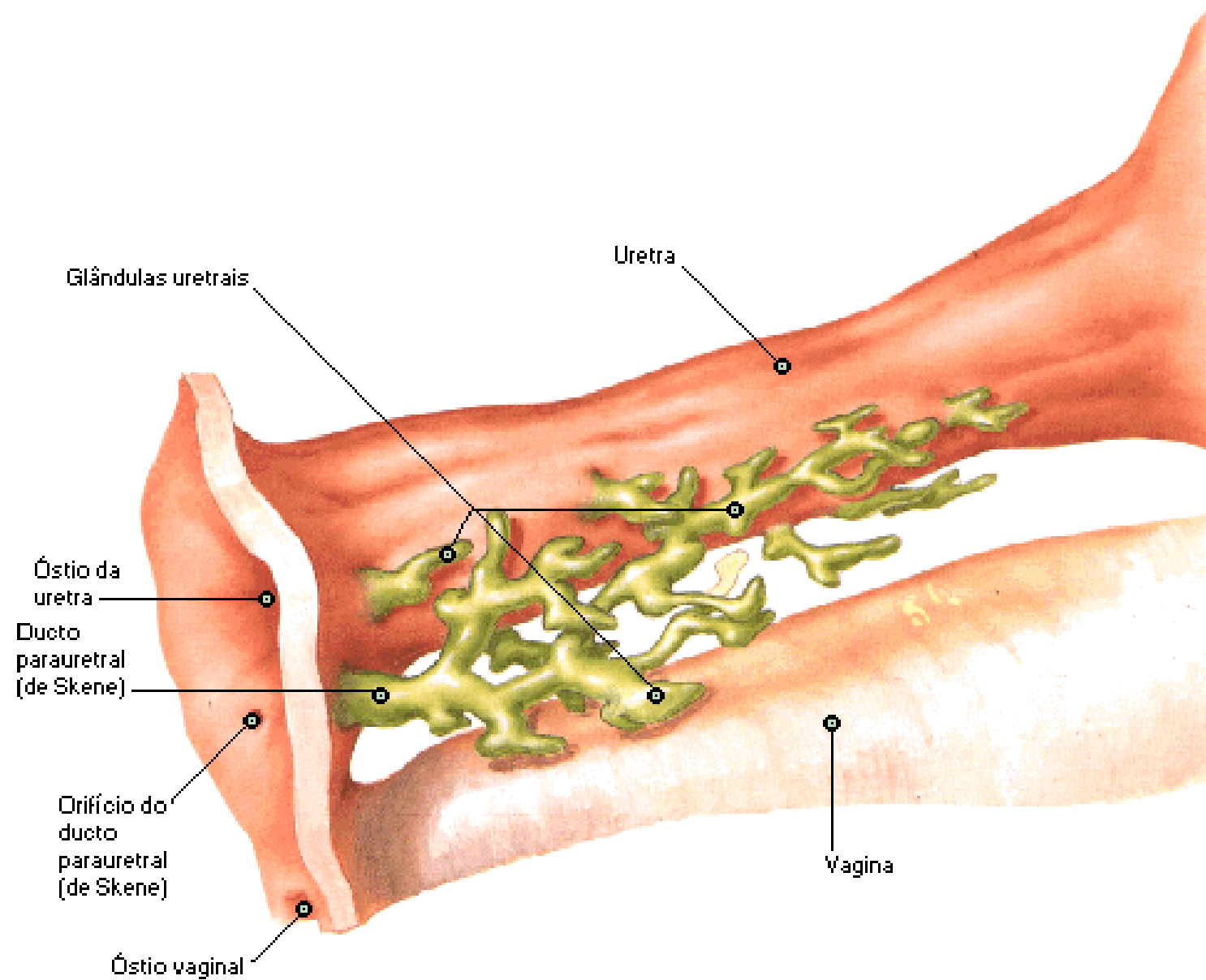
Uretra - Sexo Feminino

Secção Frontal



Uretra - Sexo Feminino

Reconstrução Esquemática



Períneo e Órgãos Genitais Externos - Sexo Masculino

Dissecação Profunda

Camada membranácea profunda (fáscia de Scarpa) da tela subcutânea

Camada gordurosa superficial (de Camper) da fáscia

Pele do pênis

Fáscia profunda do pênis (de Buck)

Fáscia superficial (dartos) do pênis e do escroto

Fossa oval e artéria e veias femorais

Veia safena magna

Fáscia superficial do períneo (de Colles)

Linha tracejada indica o ponto de inserção da fáscia de Colles em continuidade com a fáscia de Scarpa

Gordura na fossa isquioanal

Ânus

Ramo isquiopúbico

Fáscia de cobertura sobre o músculo oblíquo externo do abdome

Espinha ilíaca ântero-superior

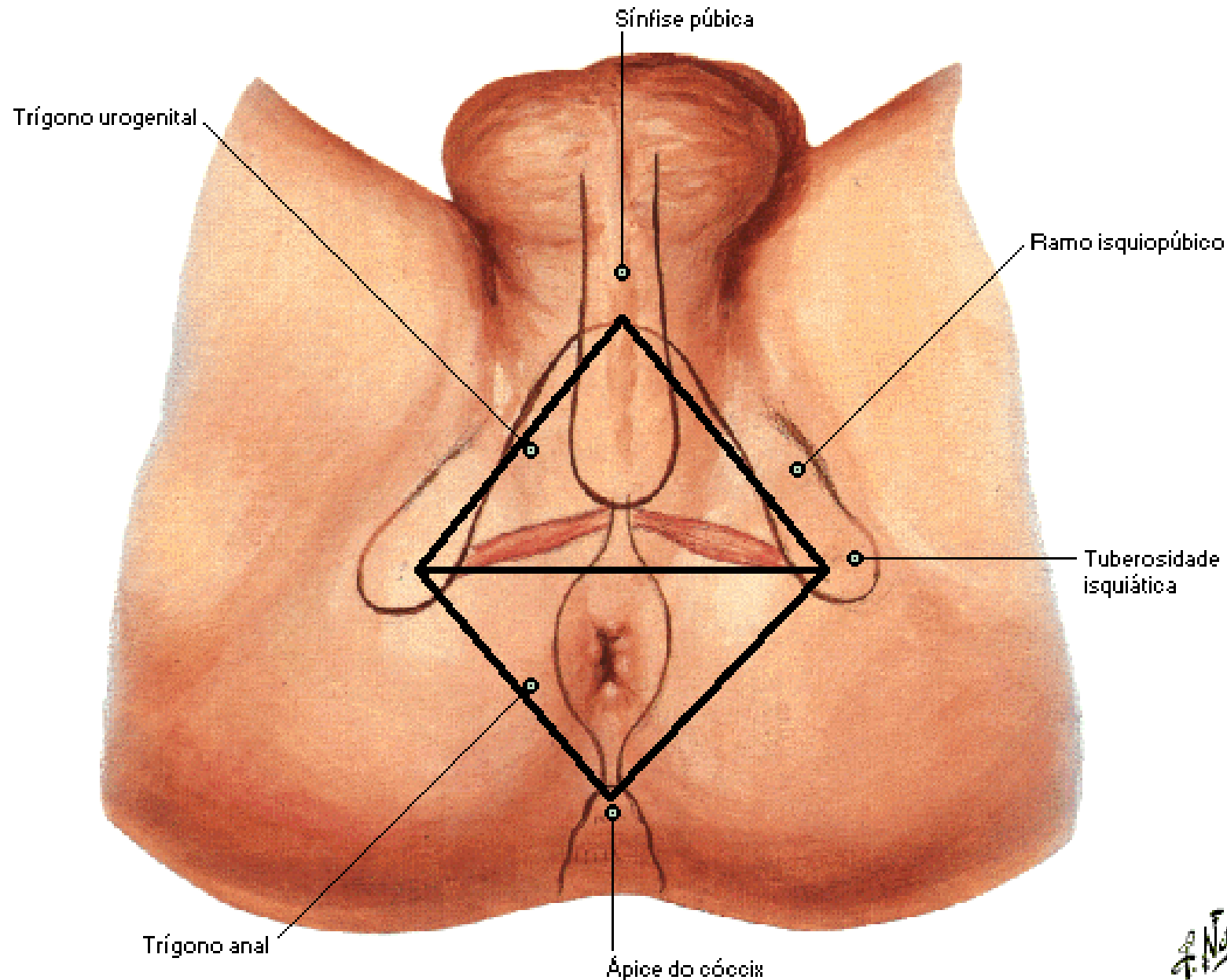
Ligamento inguinal (de Poupart)

Fáscia espermática externa

Fáscia lata da coxa

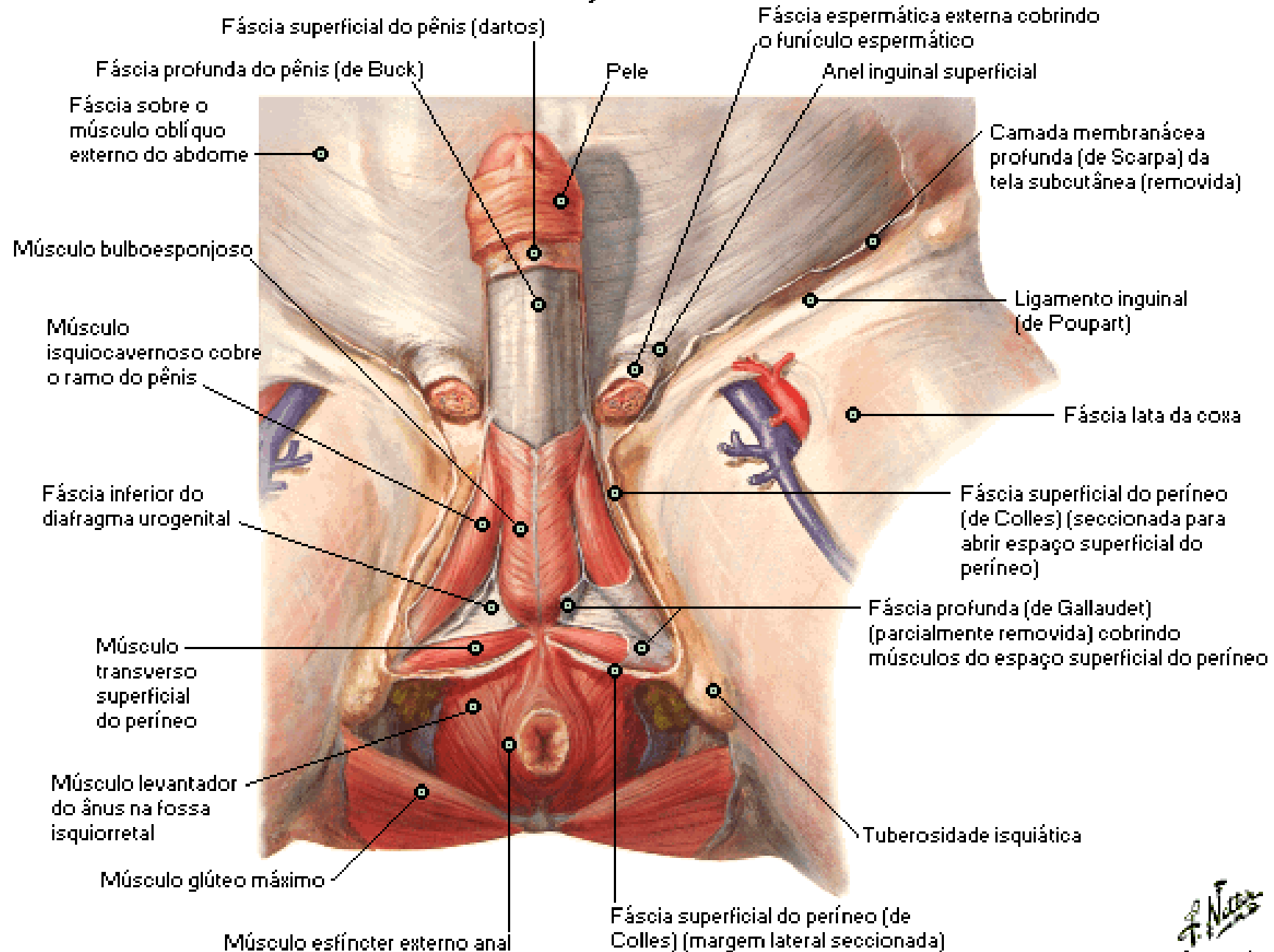
Períneo - Sexo Masculino

Regiões [Trígonos] do Períneo - Topografia de Superfície

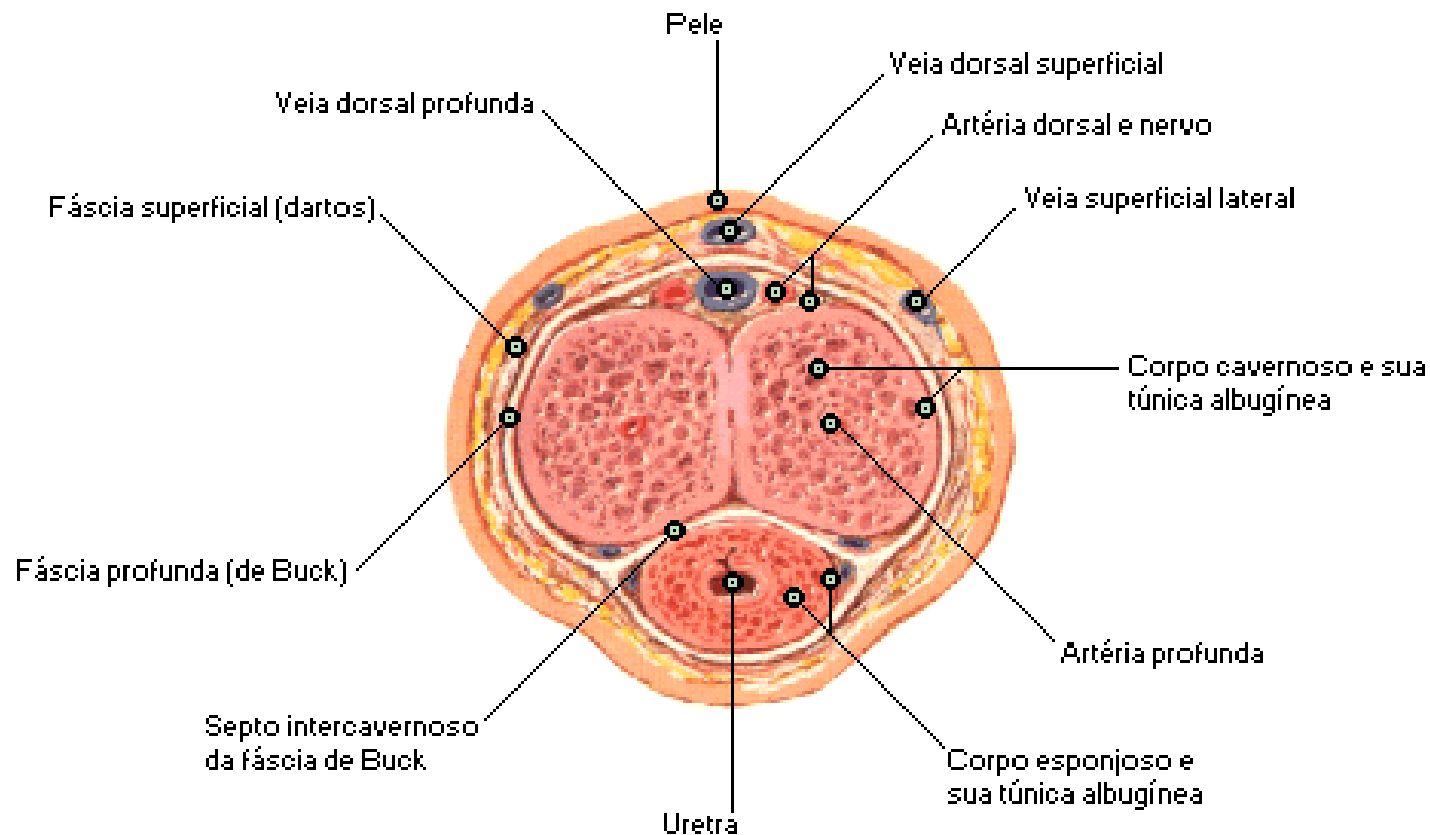


Períneo e Órgãos Genitais Externos - Sexo Masculino

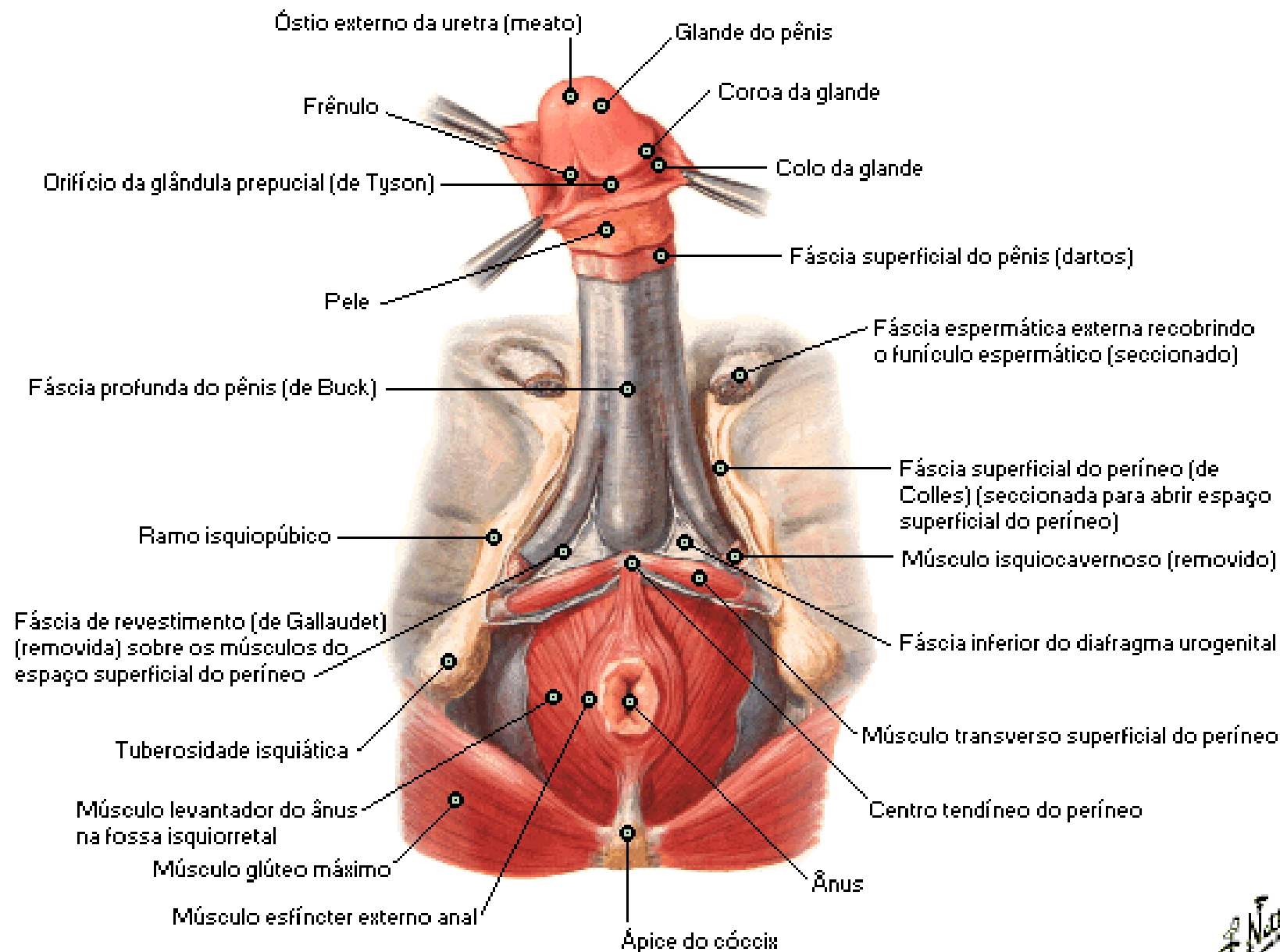
Dissecação Profunda



Secção Através do Corpo do Pênis

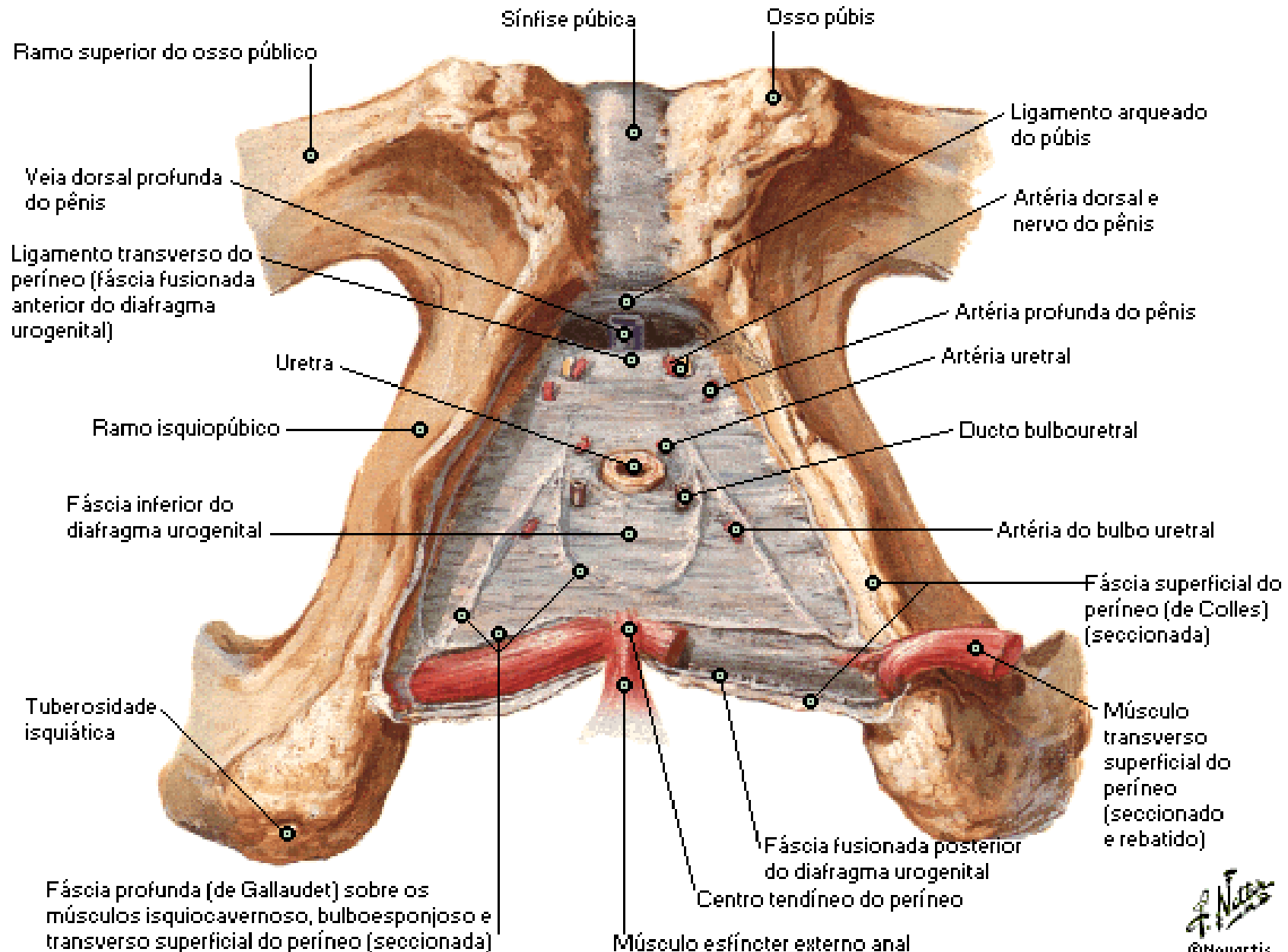


Pênis



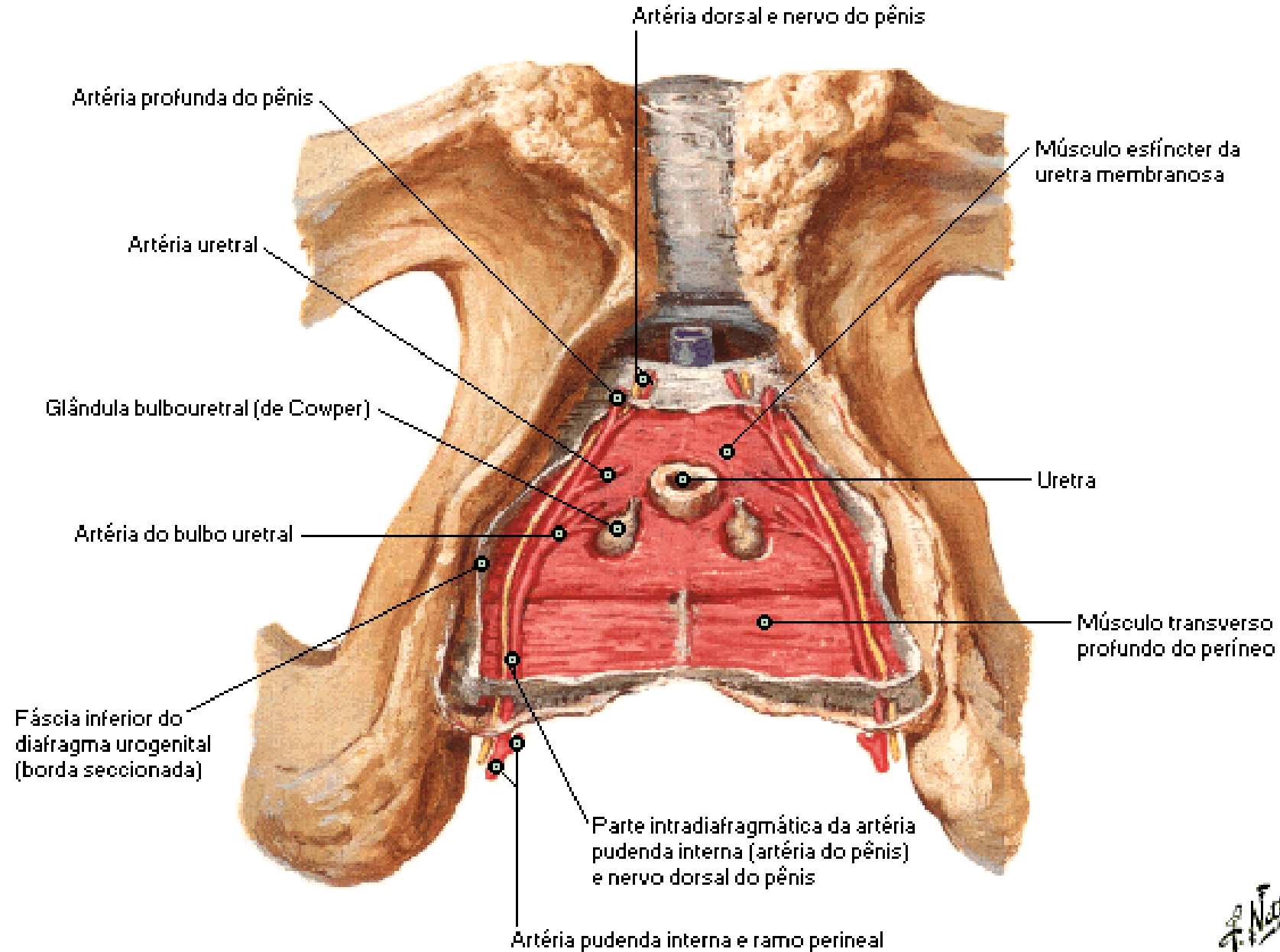
Diafragma Urogenital - Sexo Masculino

Dissecação



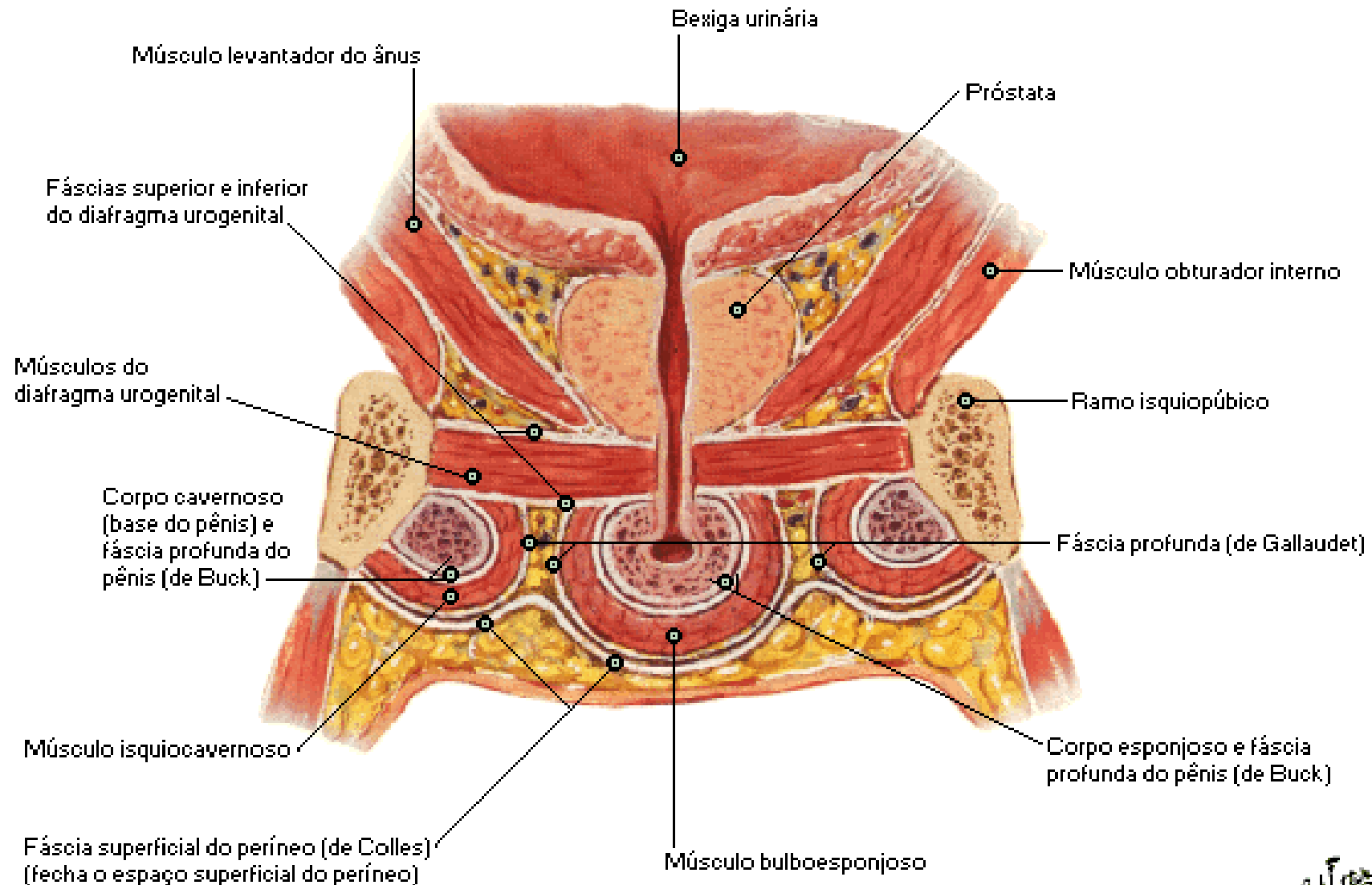
Diafragma Urogenital - Sexo Masculino

Dissecação Profunda



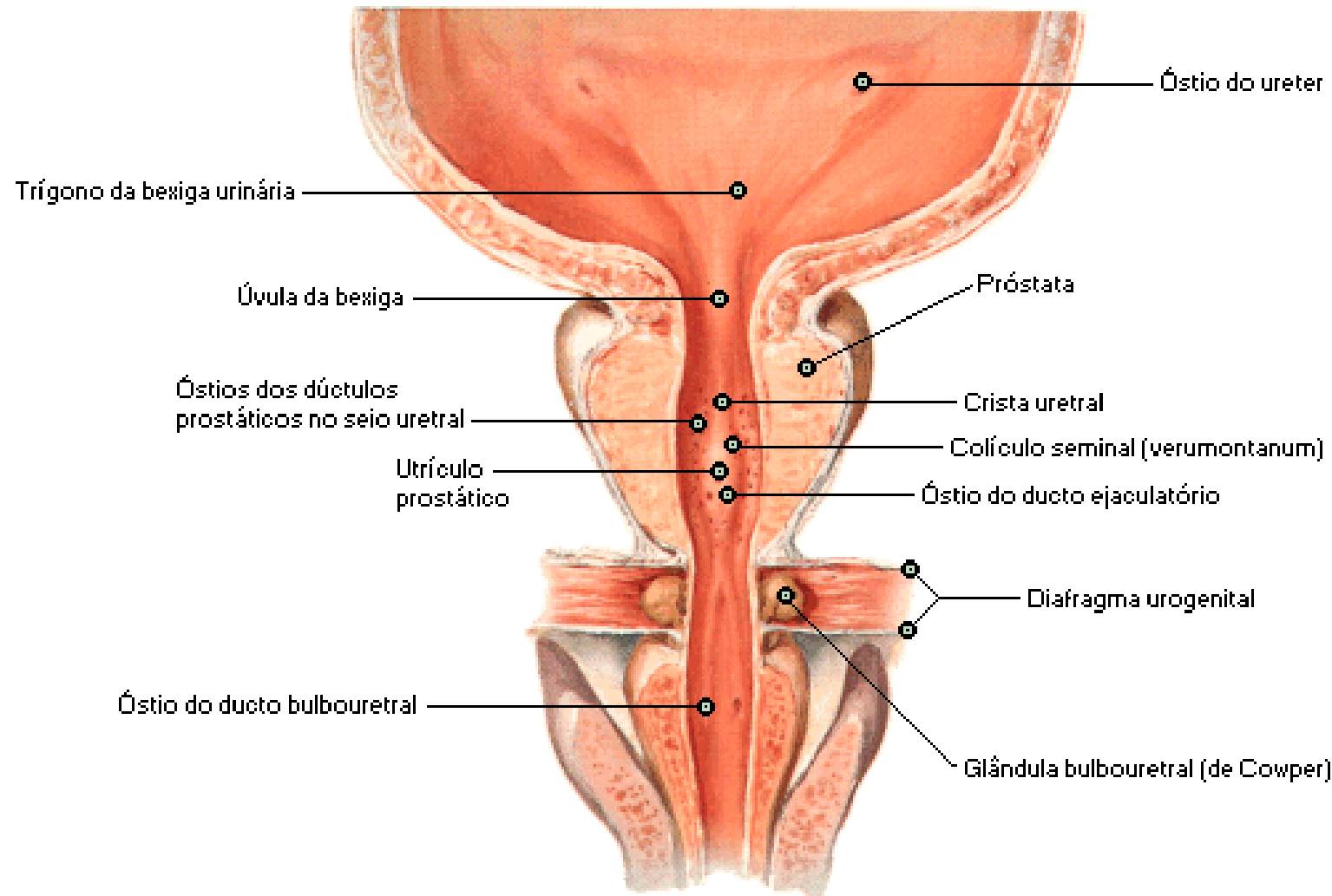
Diafragma Urogenital - Sexo Masculino

Secção frontal - Esquema



Próstata e Vesículos Seminais

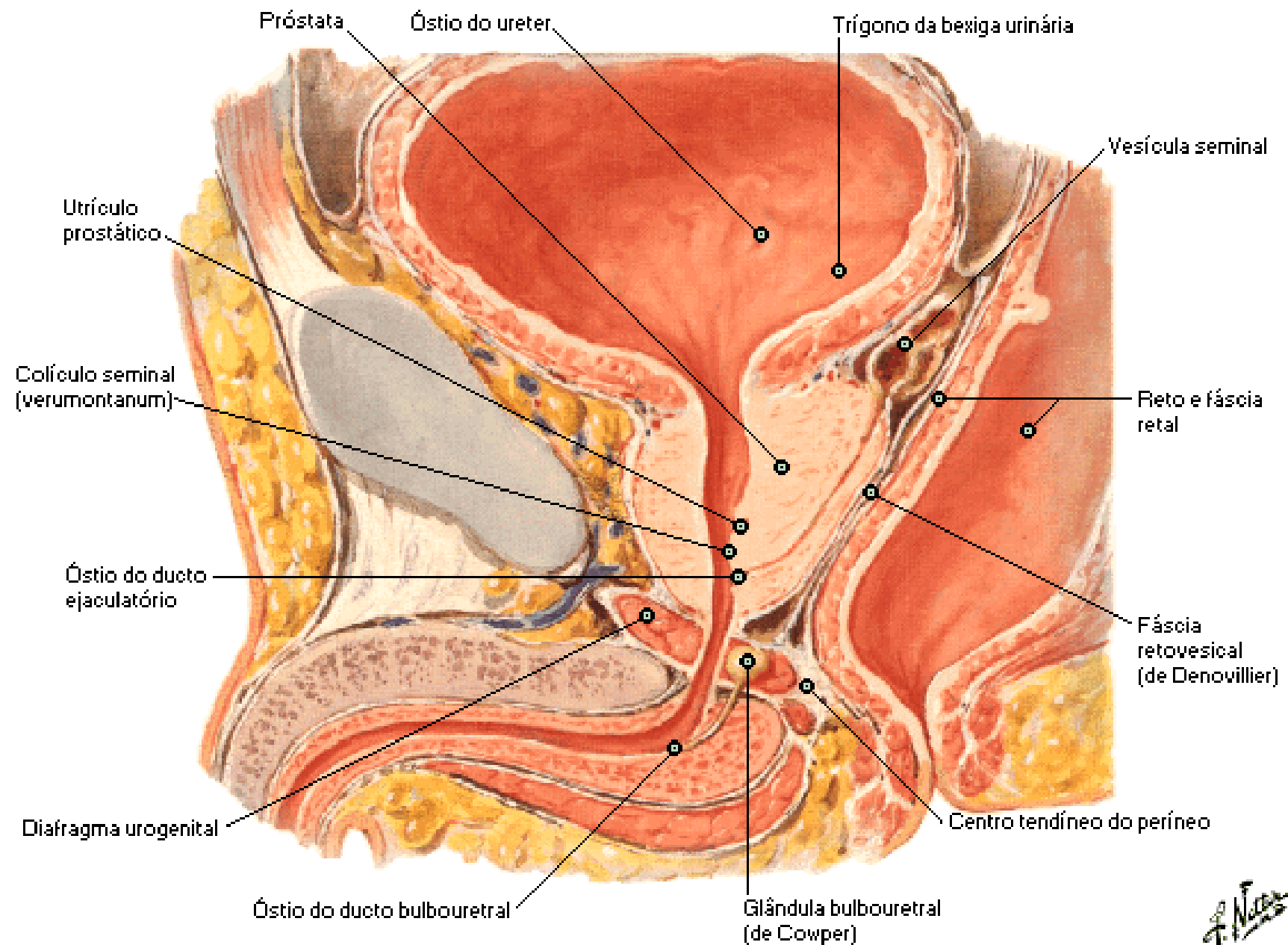
Secção Frontal



Bulbo uretral esquematicamente estendido

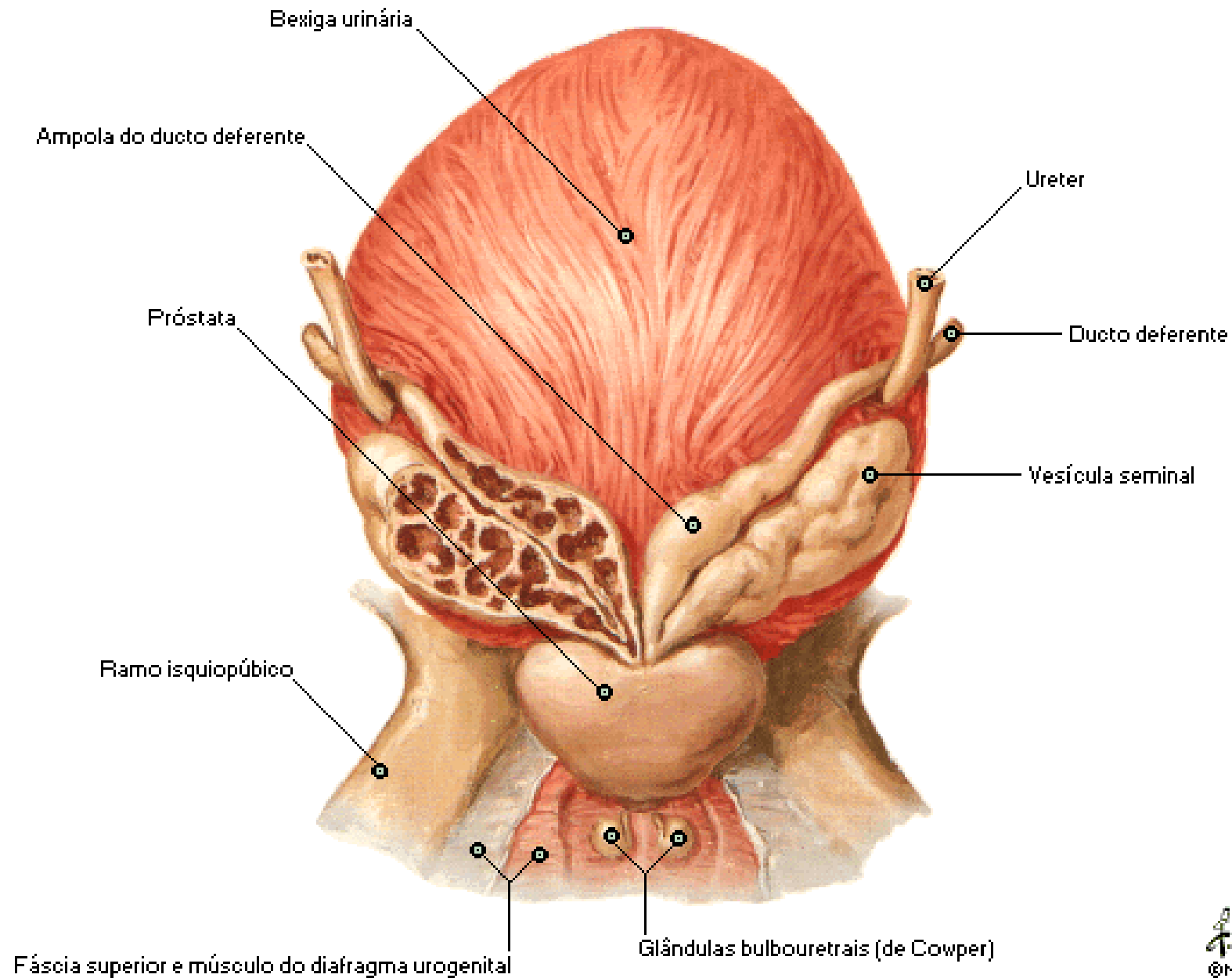
Próstata e Vesículas Seminais

Secção Sagital



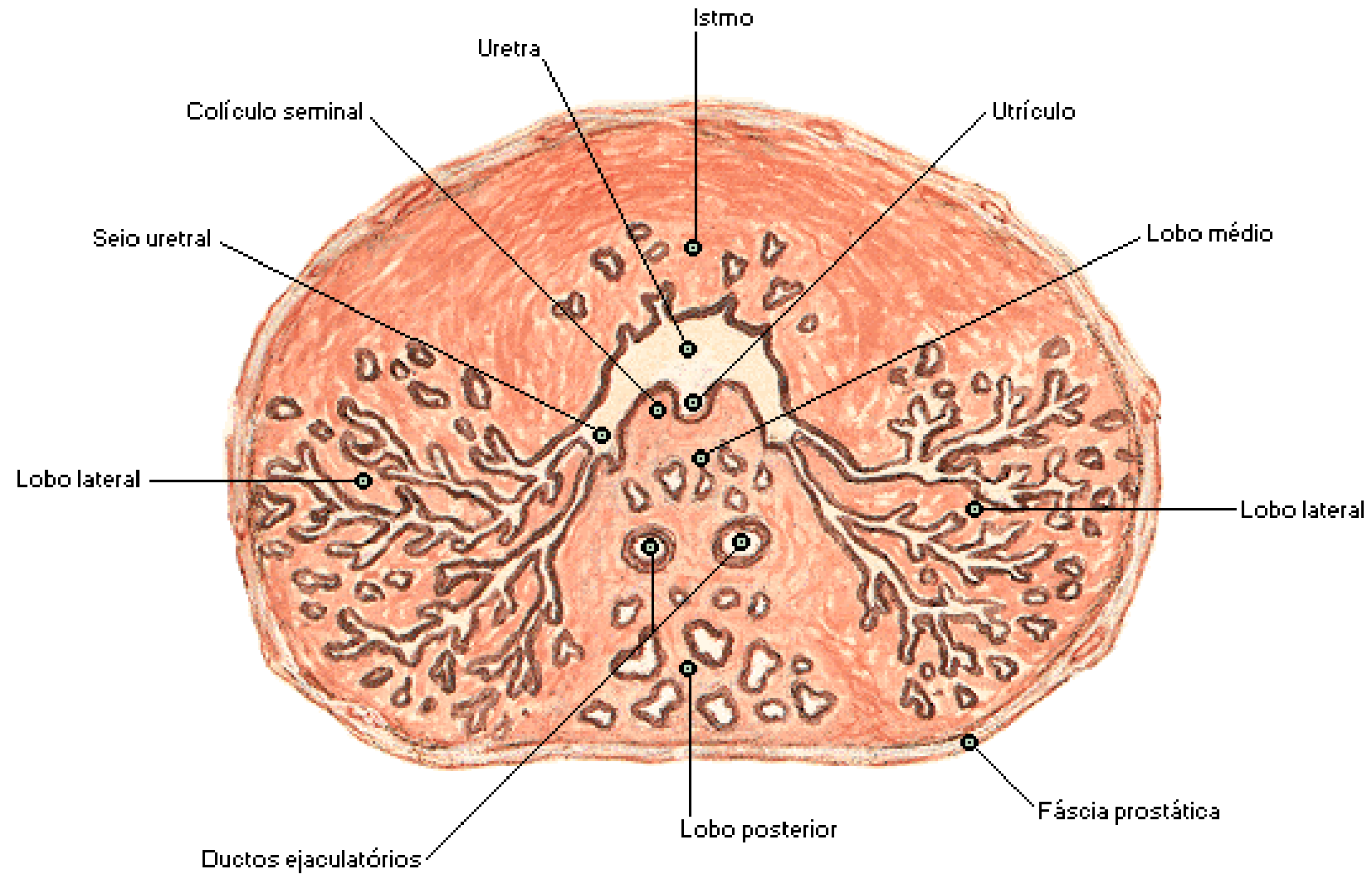
Próstata e Vesículas Seminais

Vista Posterior



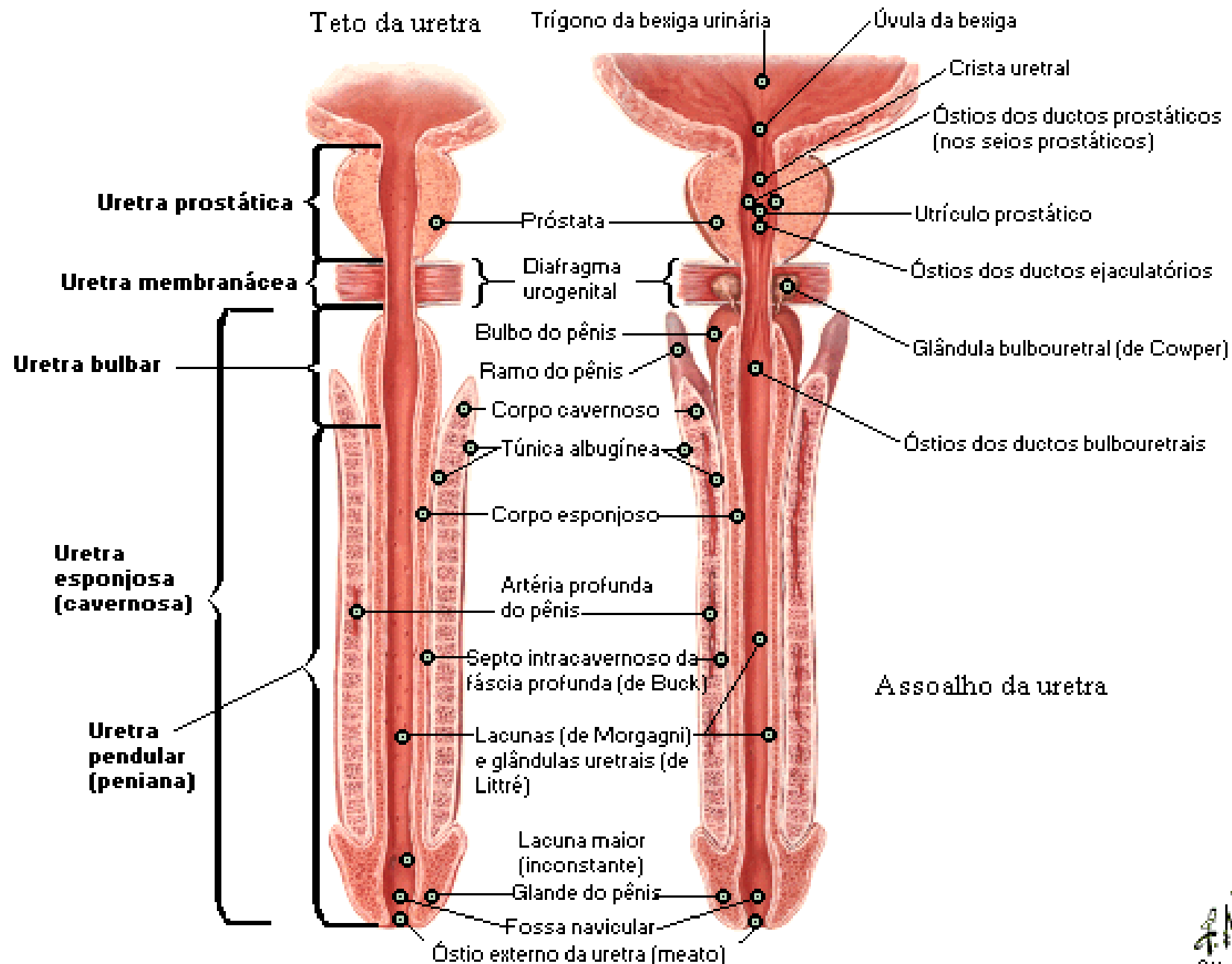
Próstata e Vesículas Seminais

Secção Transversal Através da Próstata



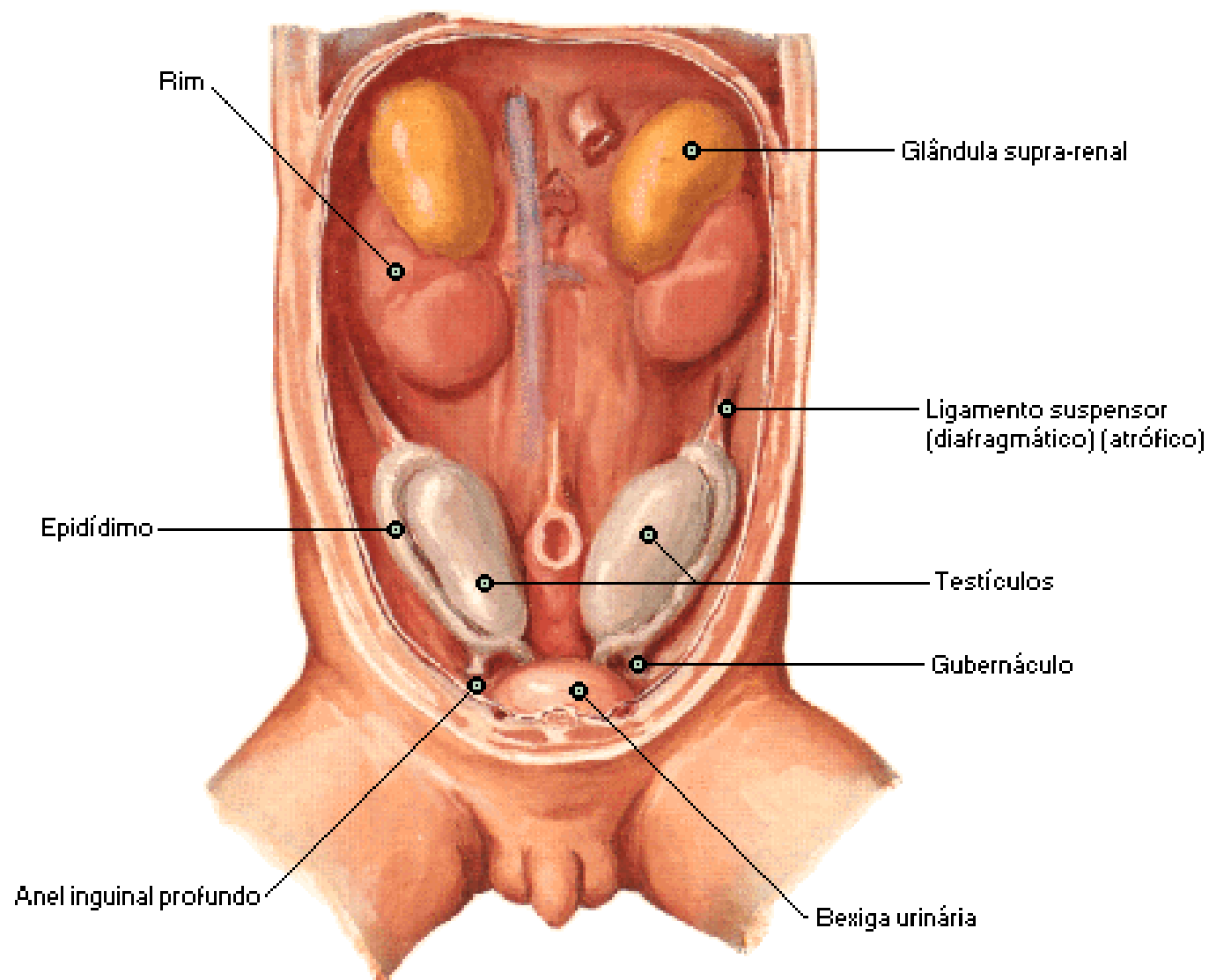
Uretra

Sexo Masculino



Descida dos Testículos

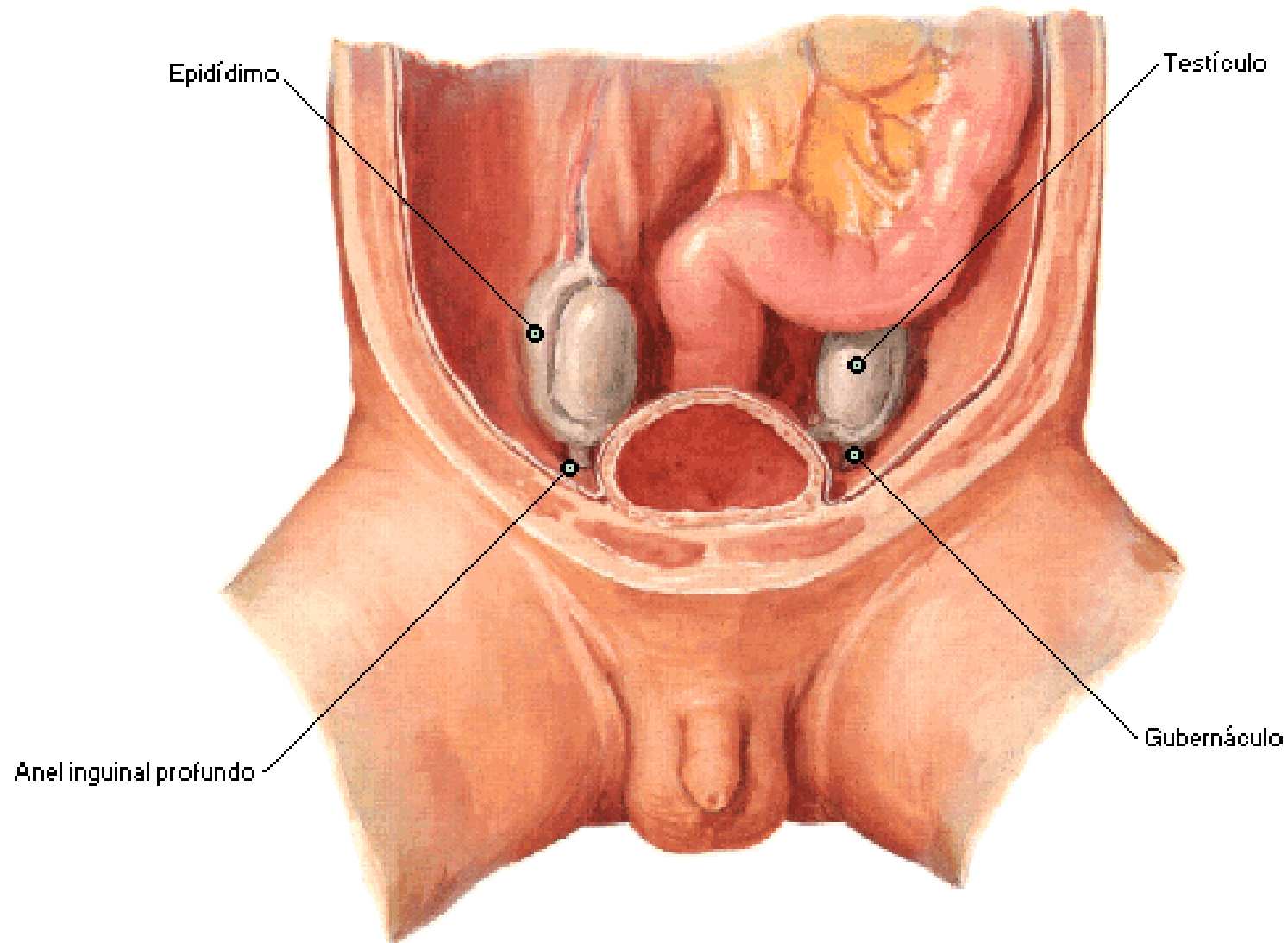
11 Semanas



43 mm topo da nádega

Descida dos Testículos

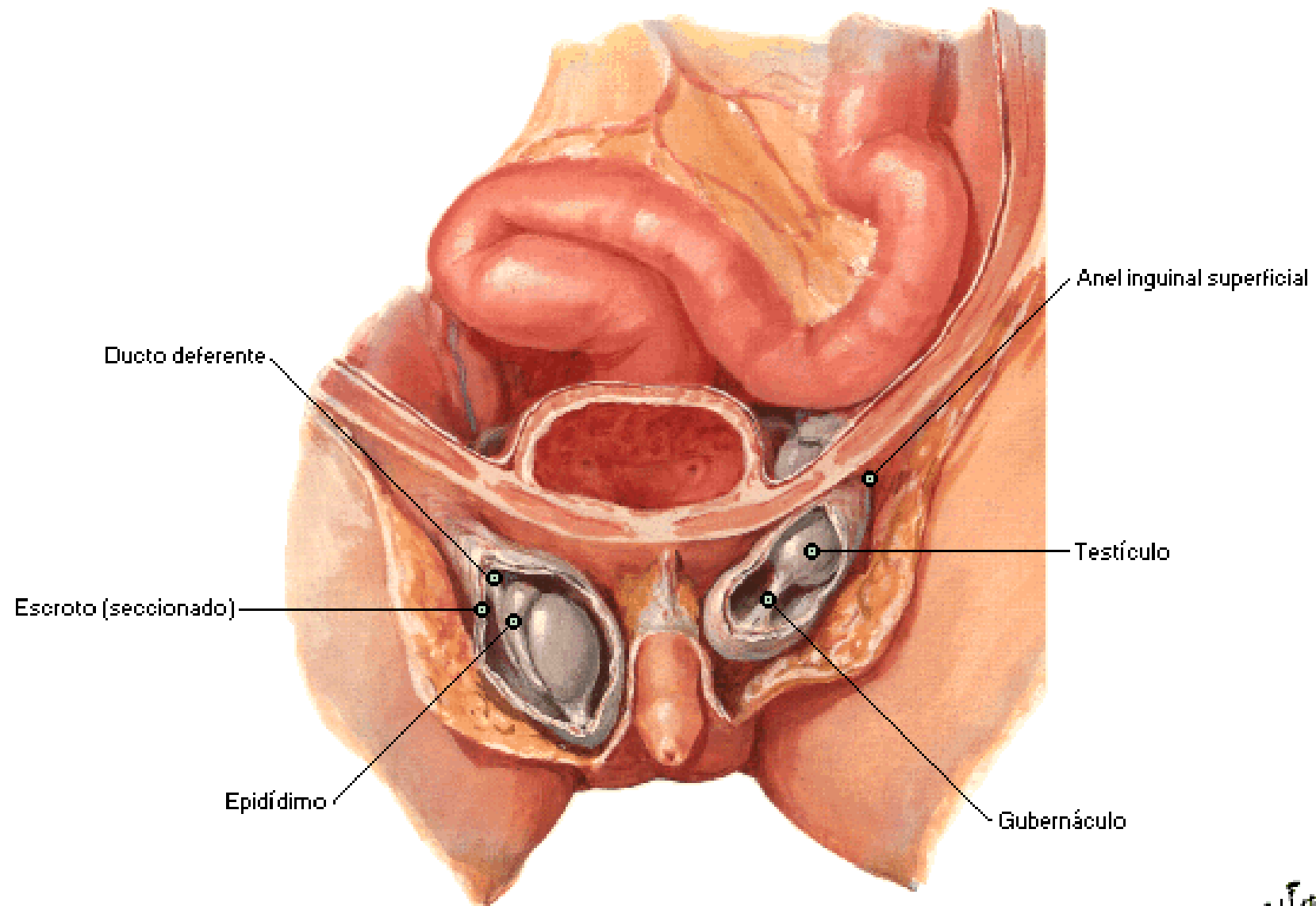
4 Meses Lunares



107 mm topo da nádega

Descida dos Testículos

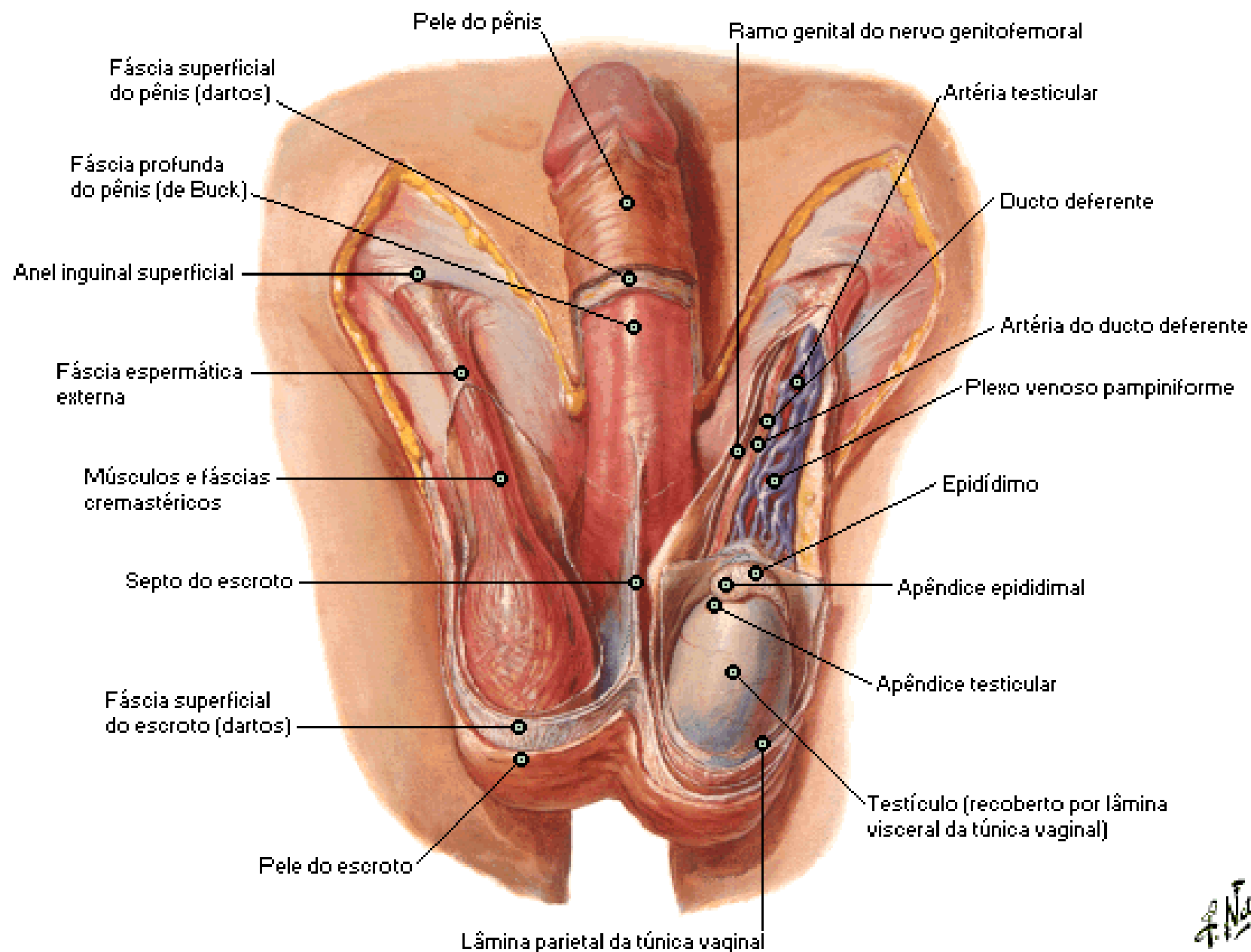
8 Meses Lunares



26 cm topo da nádega

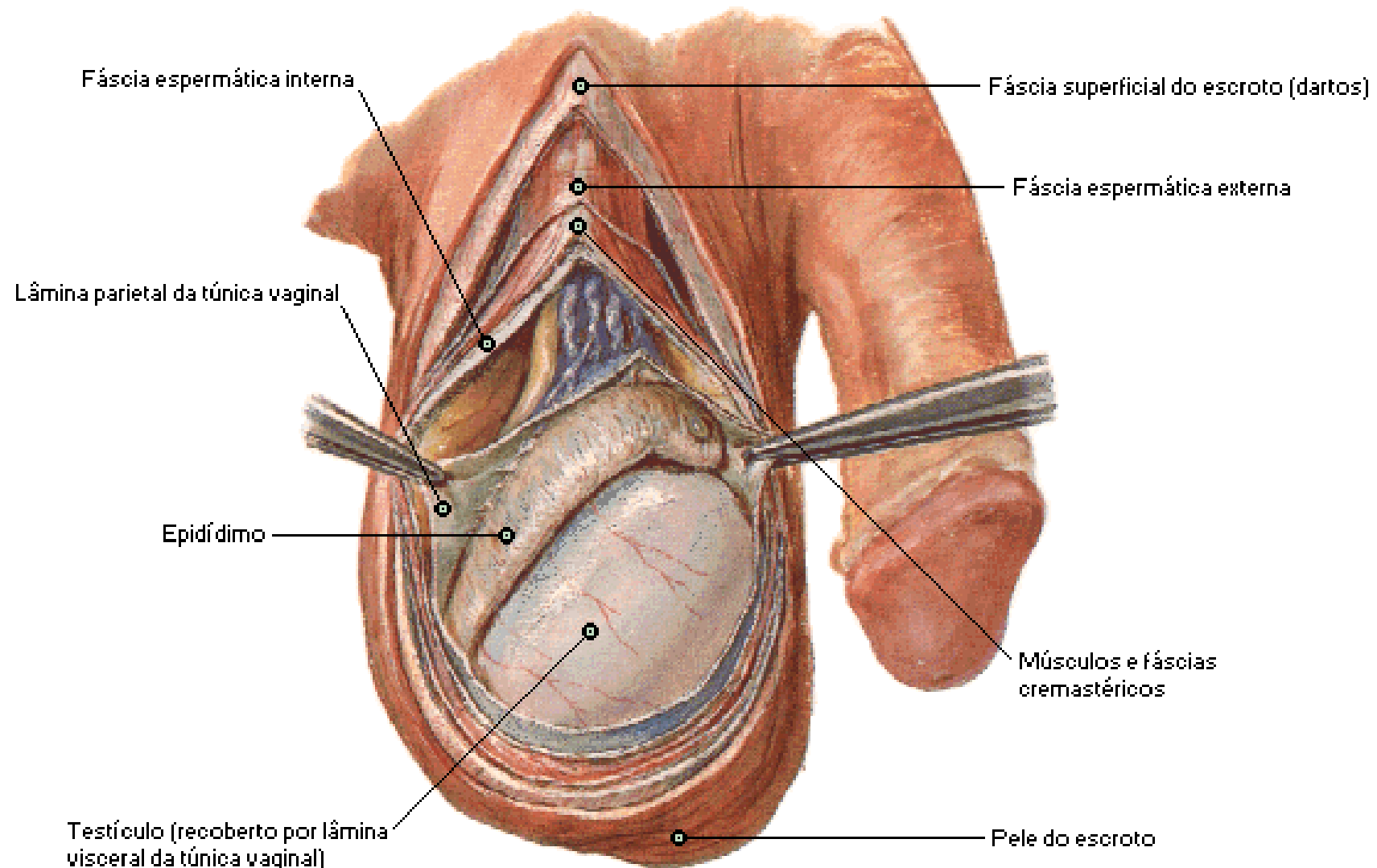
Escroto e Conteúdo

Vista Anterior



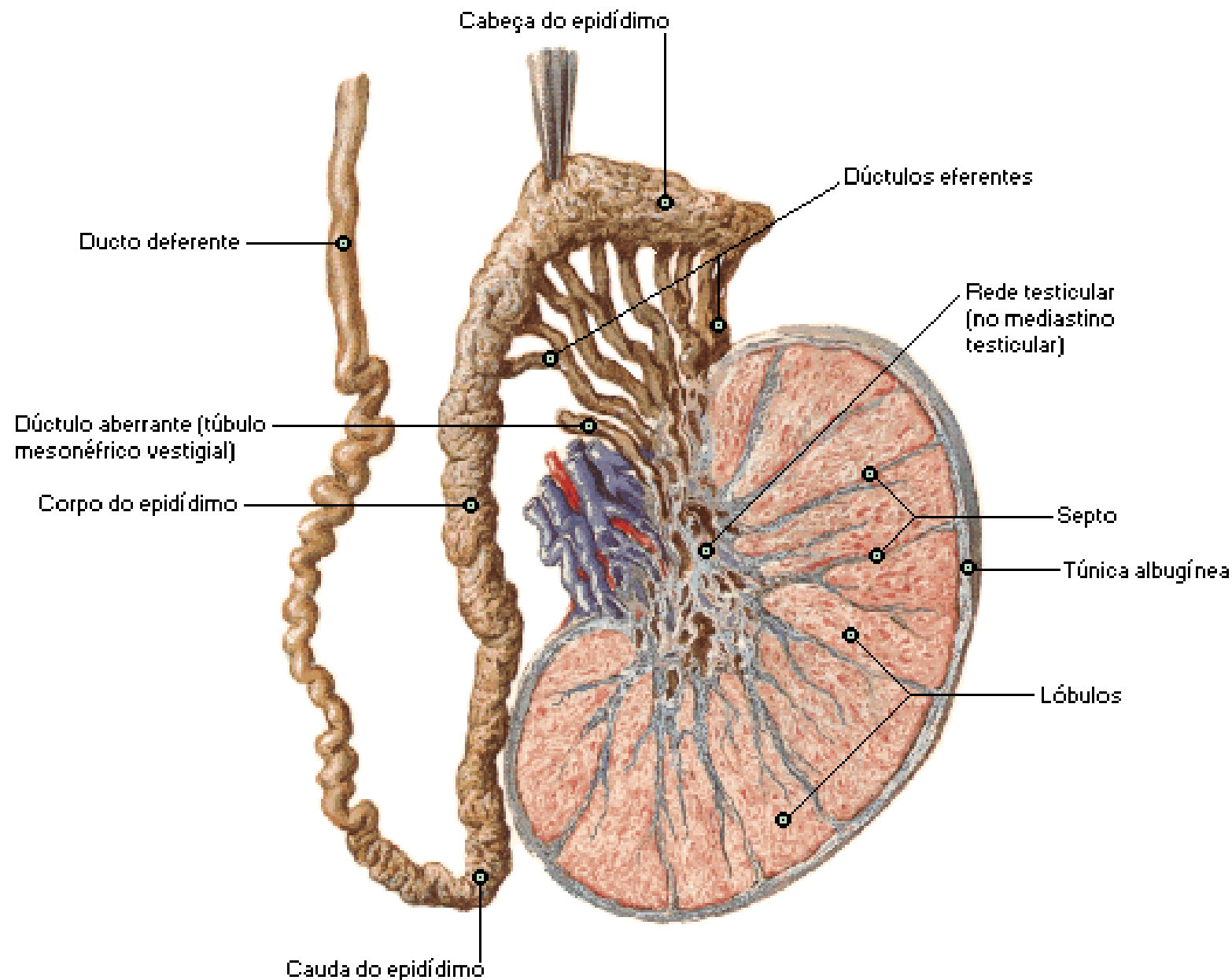
Escroto e Conteúdo

Vista Lateral



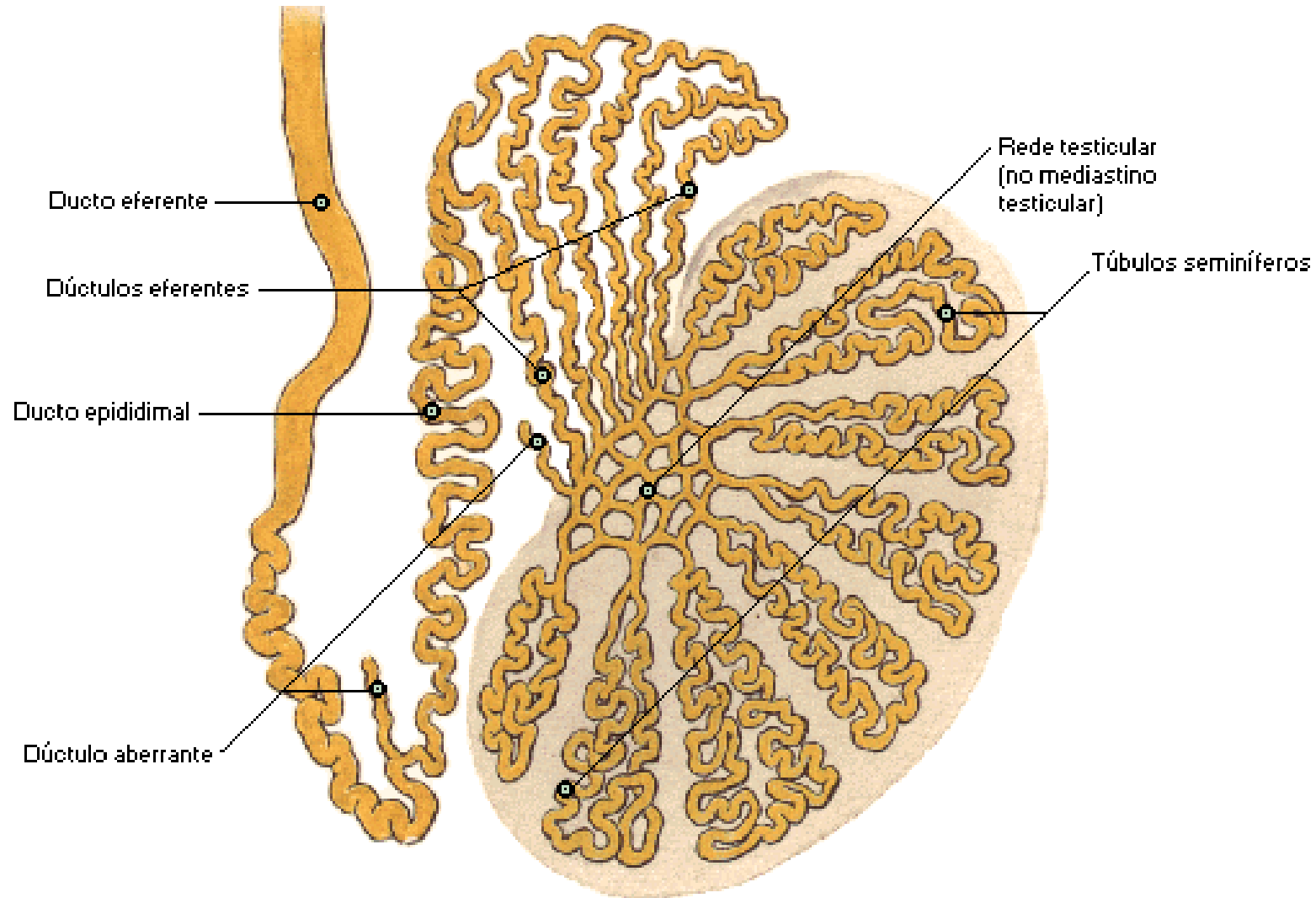
Testículo, Epidídimo e Ducto Deferente

Secção Frontal



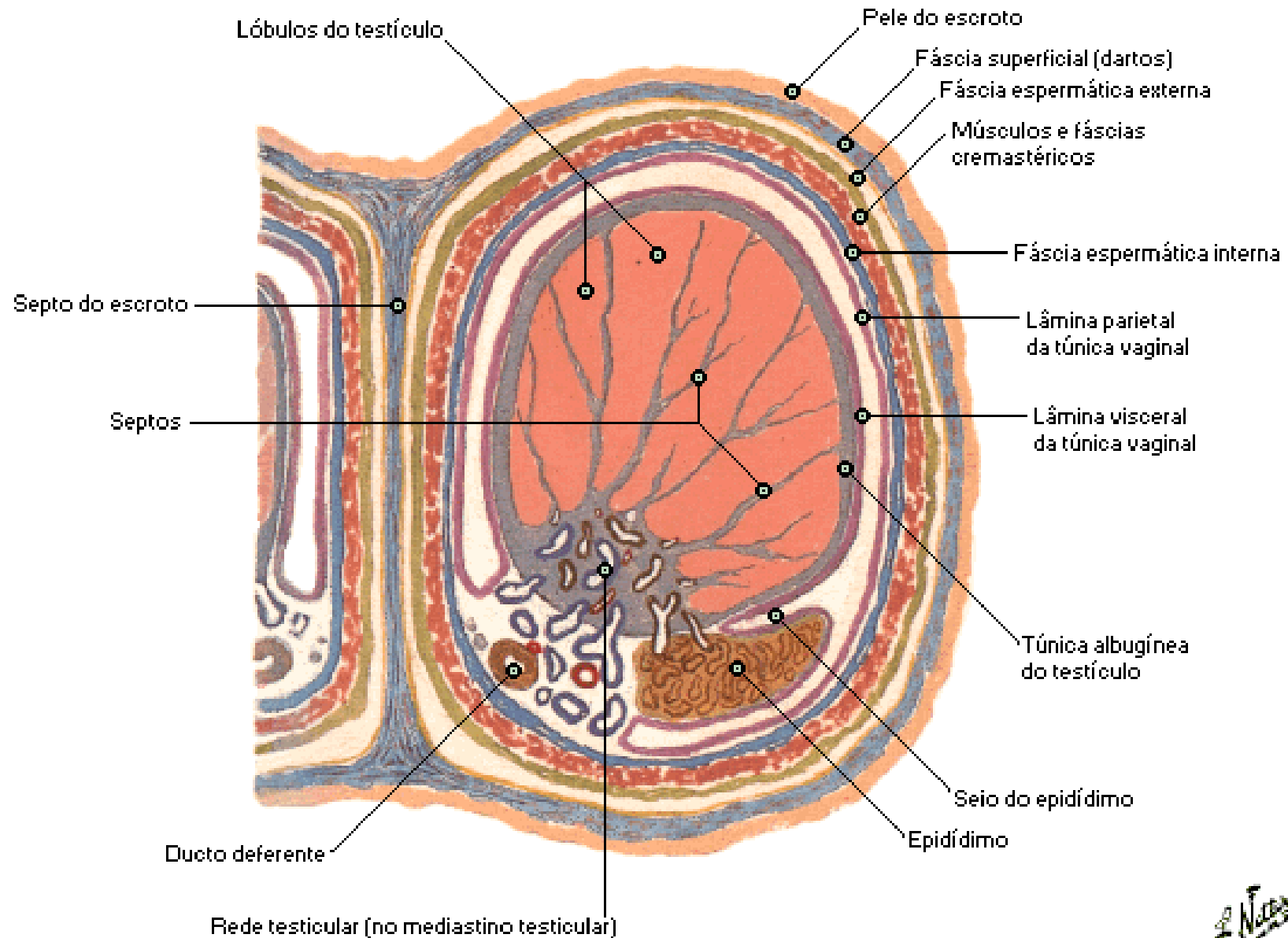
Testículo, Epidídimo e Ducto Deferente

Esquema

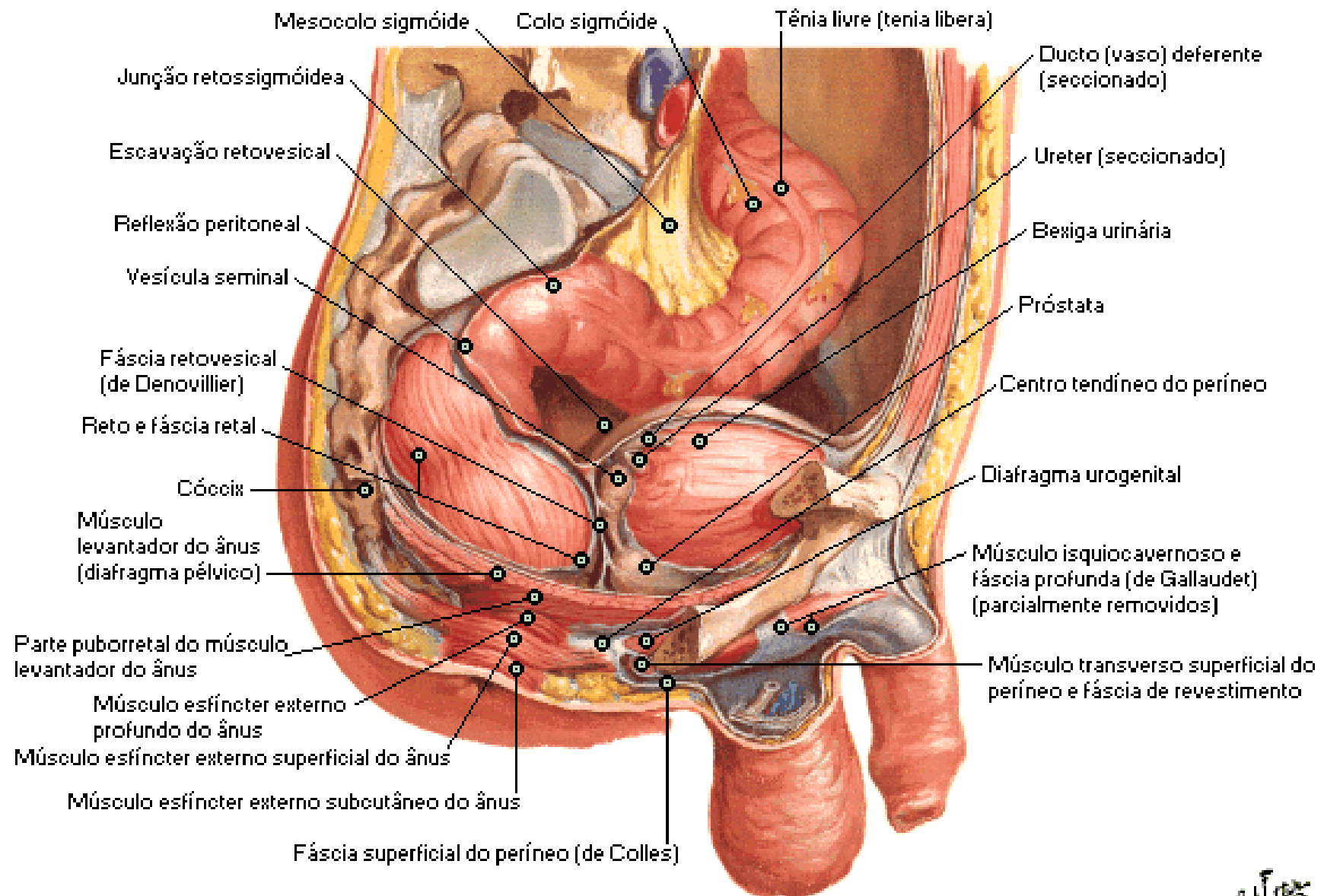


Testículo, Epidídimo e Ducto Deferente

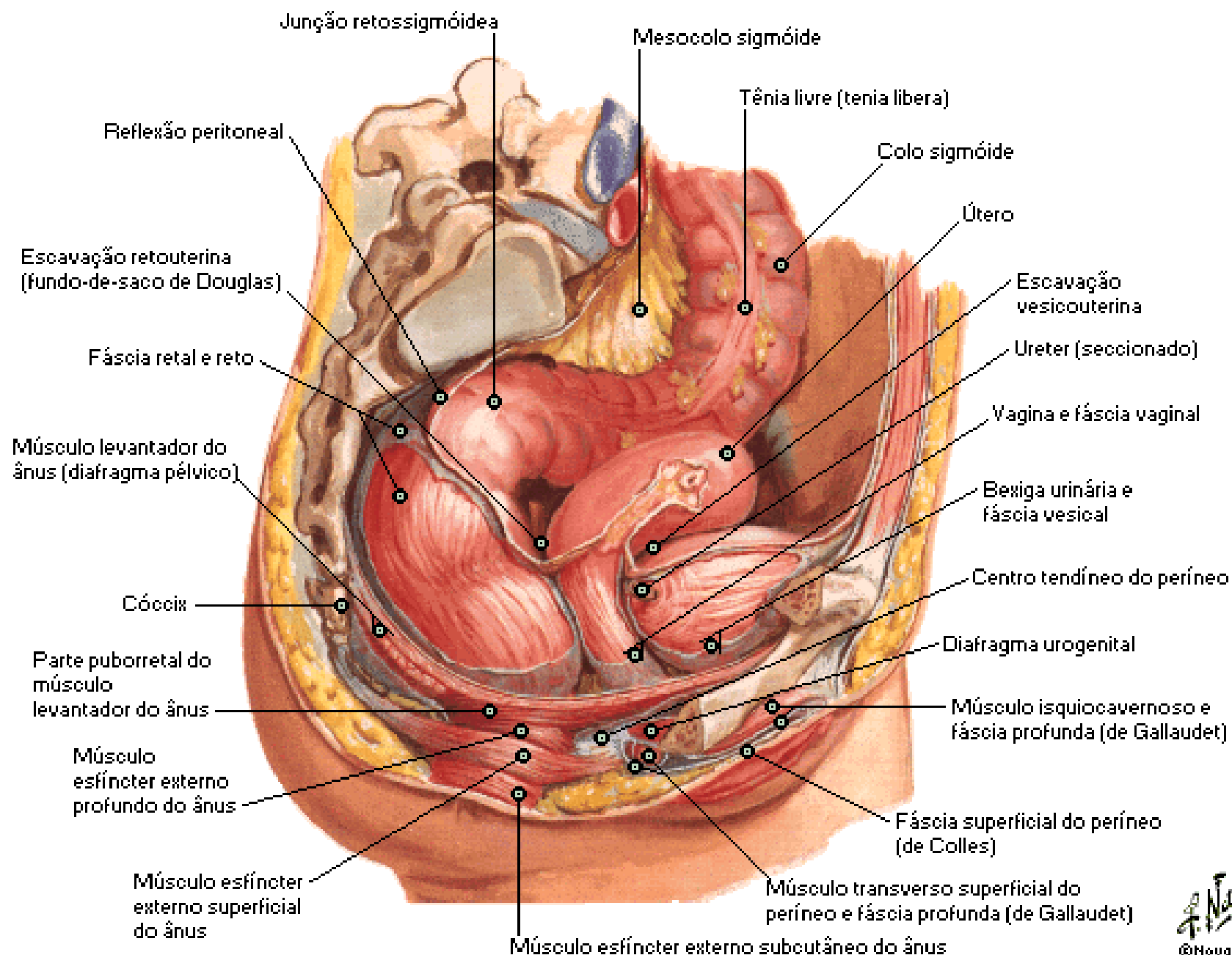
Secção Transversal



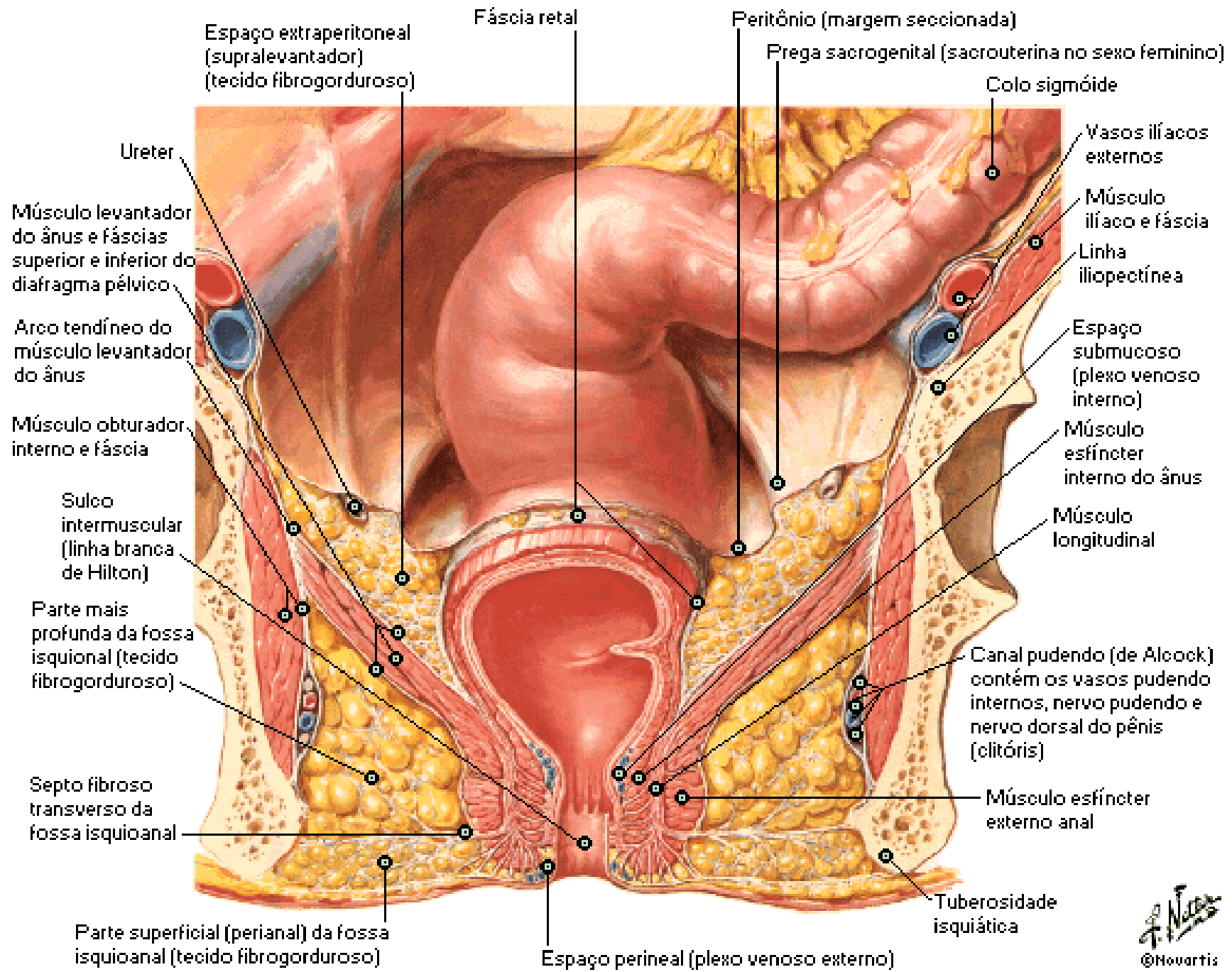
Reto in Situ - Sexo Masculino



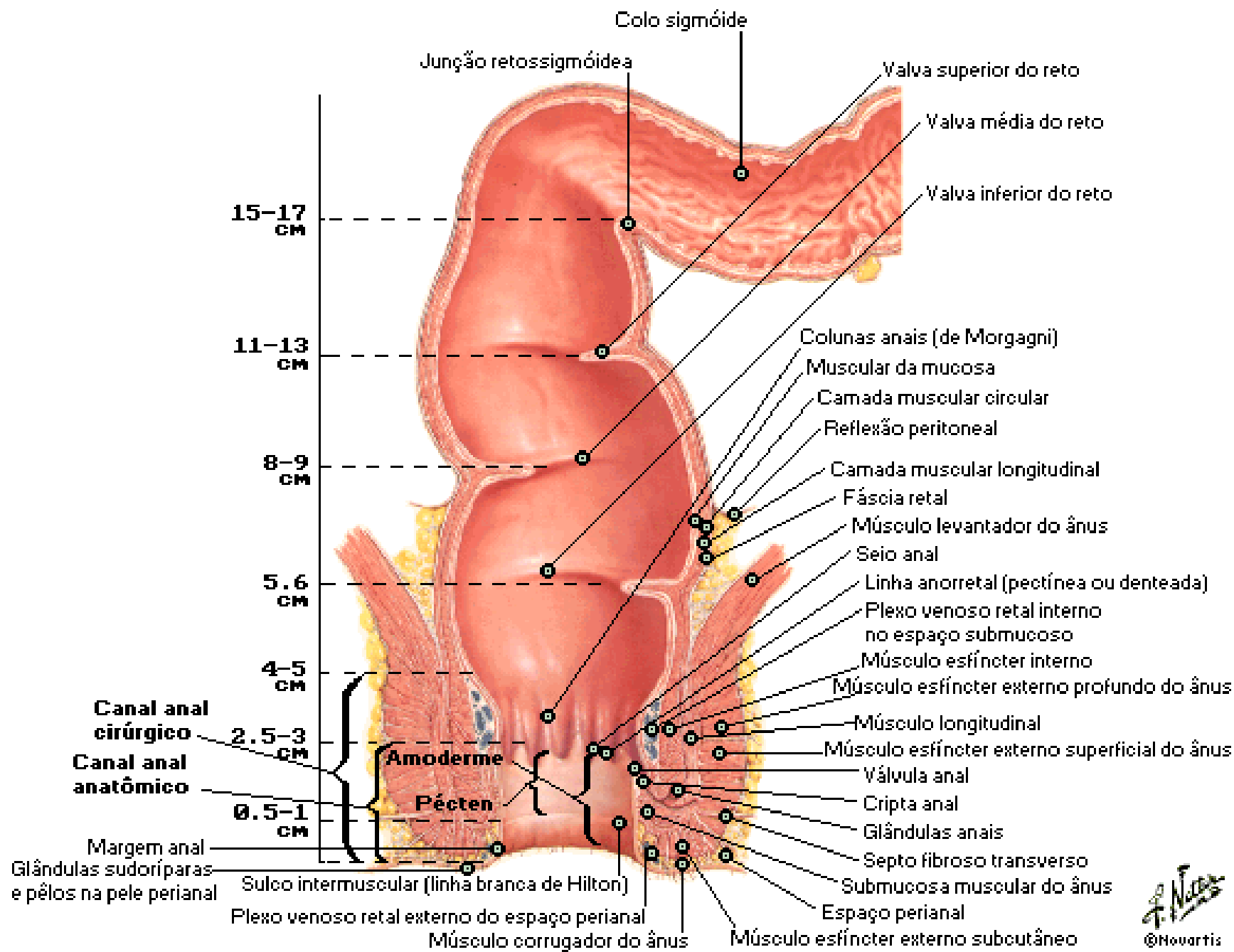
Reto in Situ - Sexo Feminino



Fossa Isquioanal

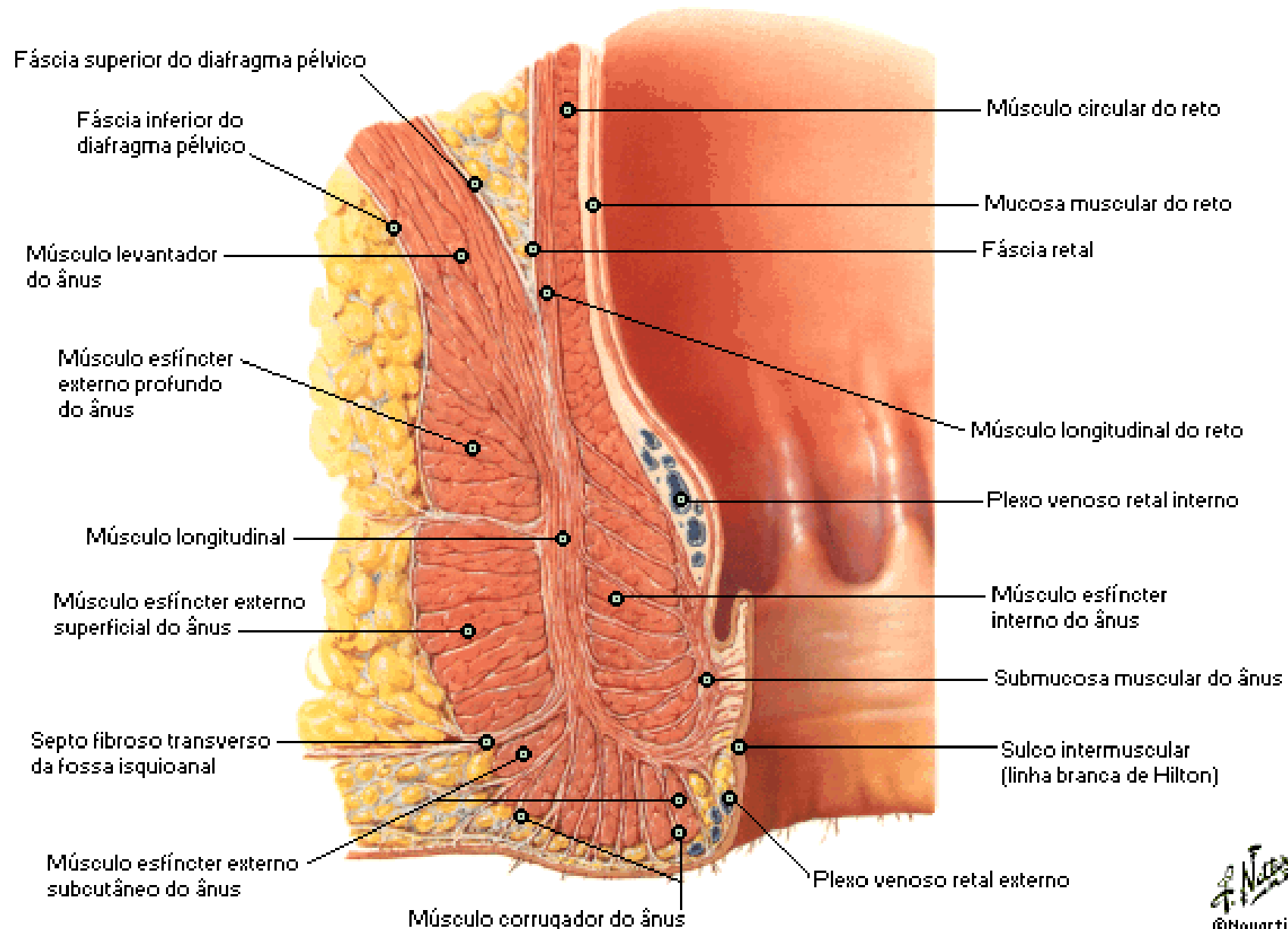


Reto e Canal Anal



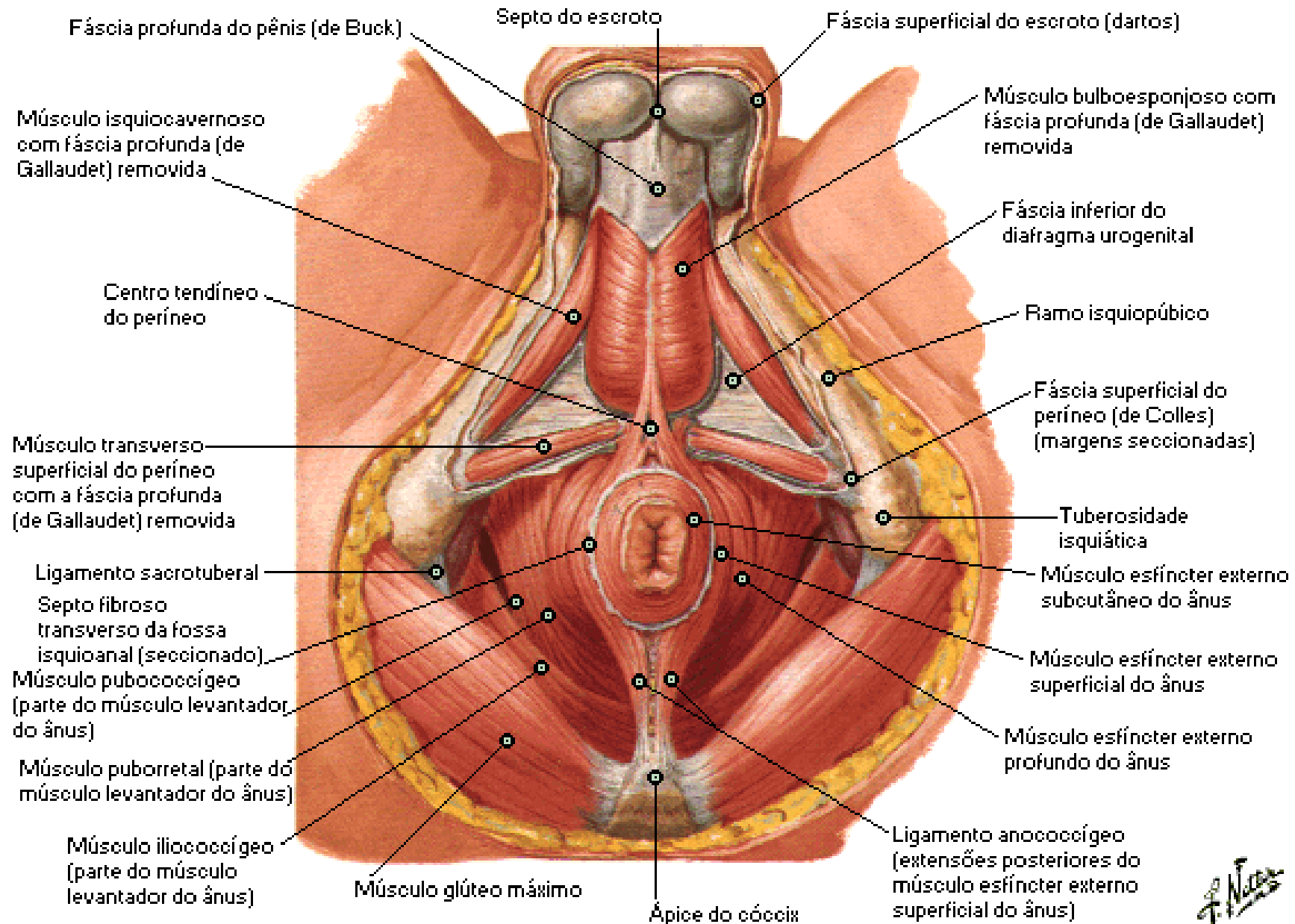
Musculatura Anorretal

Secção Frontal



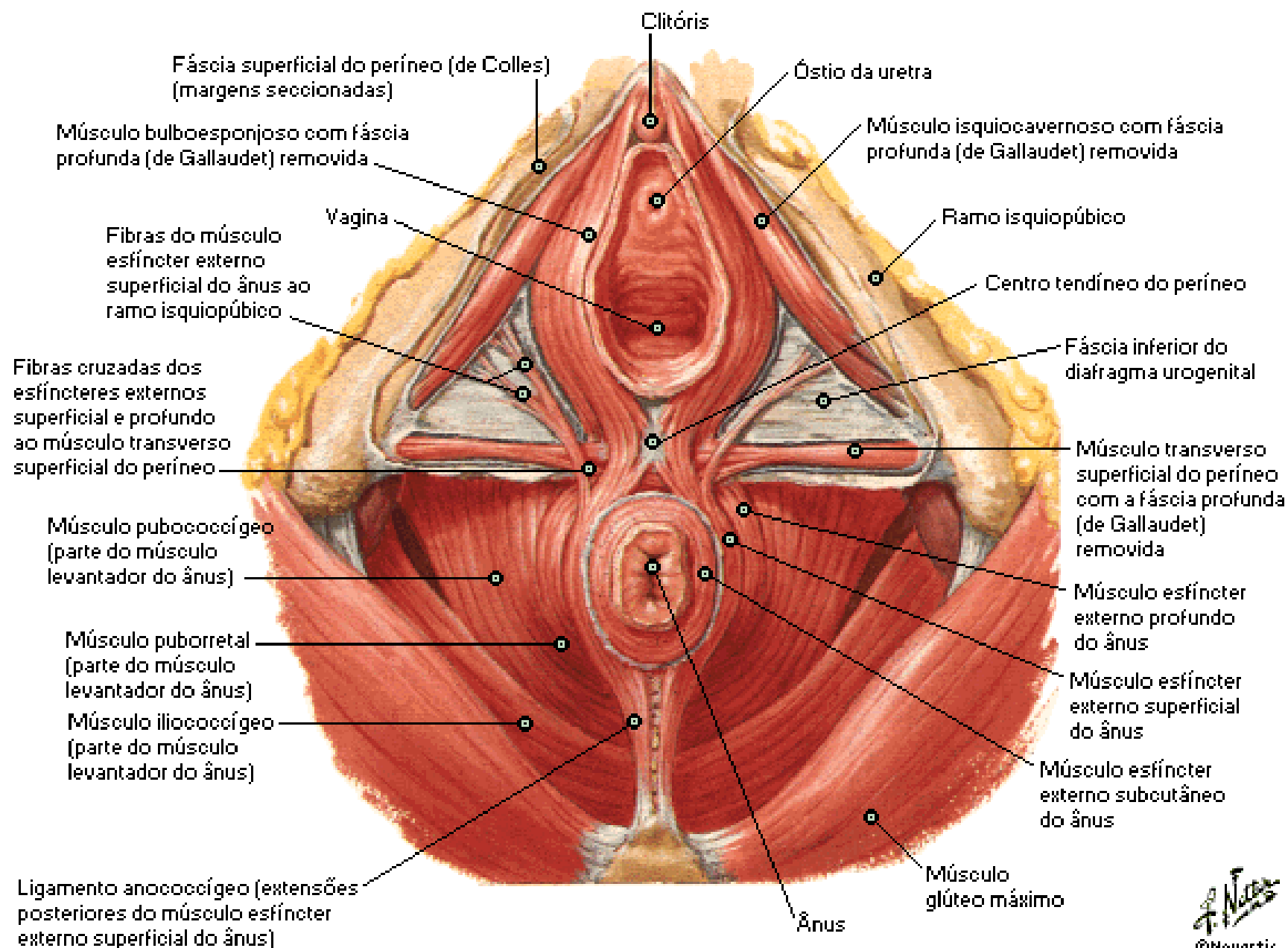
Músculo Esfíncter Externo do Ânus - Sexo Masculino

Vista Perineal



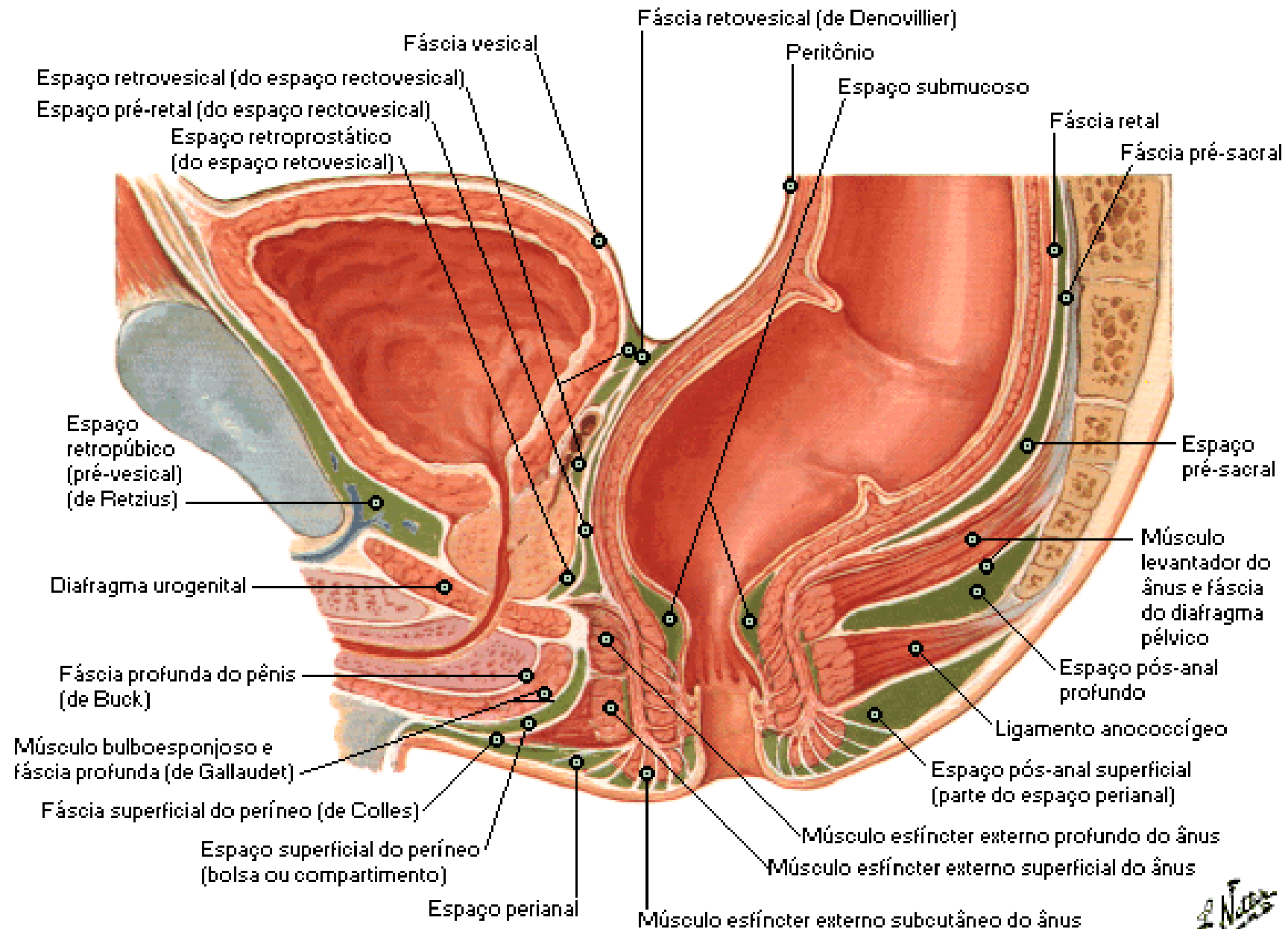
Músculo Esfíncter Externo do Ânus - Sexo Masculino

Vista Perineal



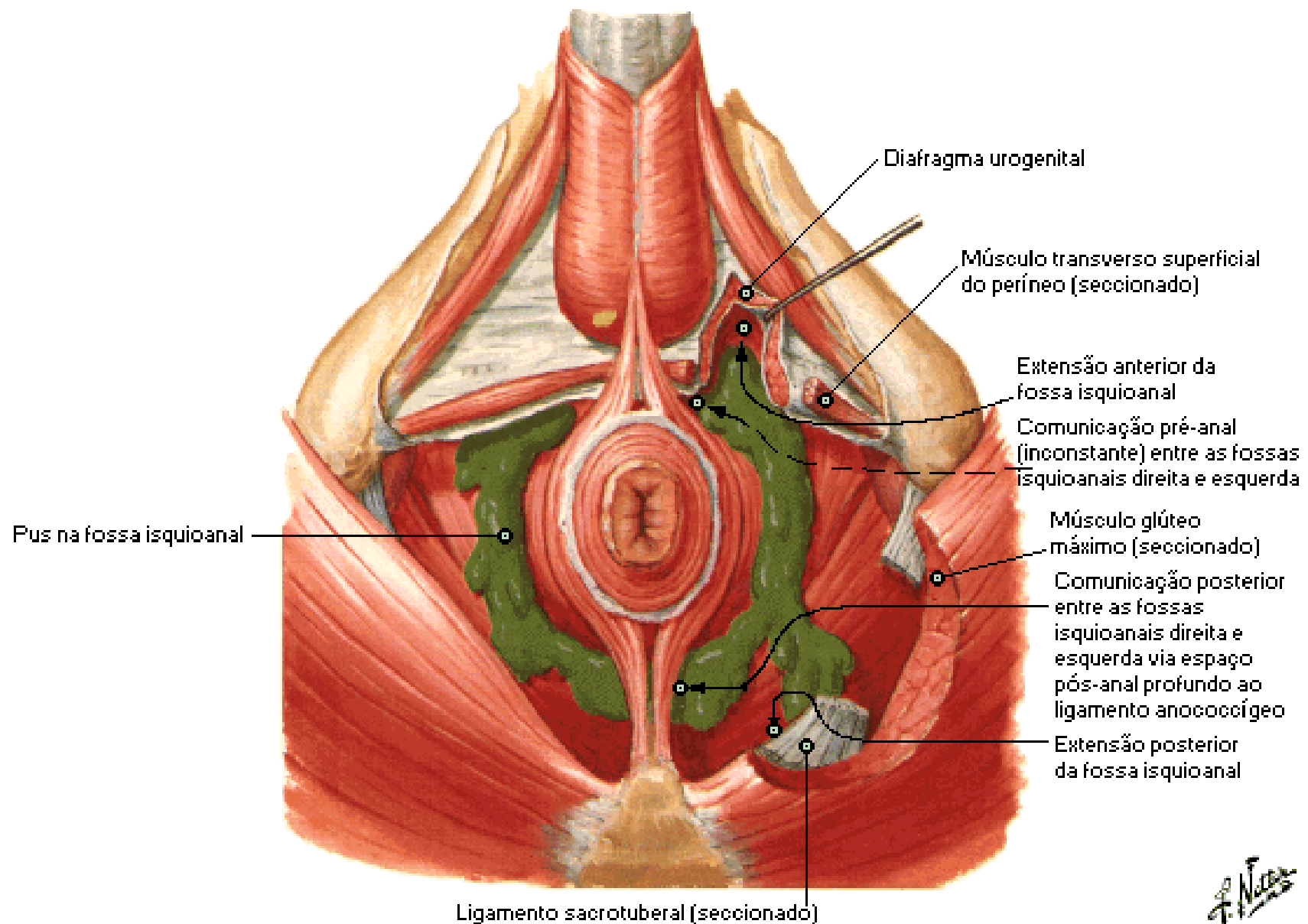
Espaços Perineopélvicos

Secção Sagital

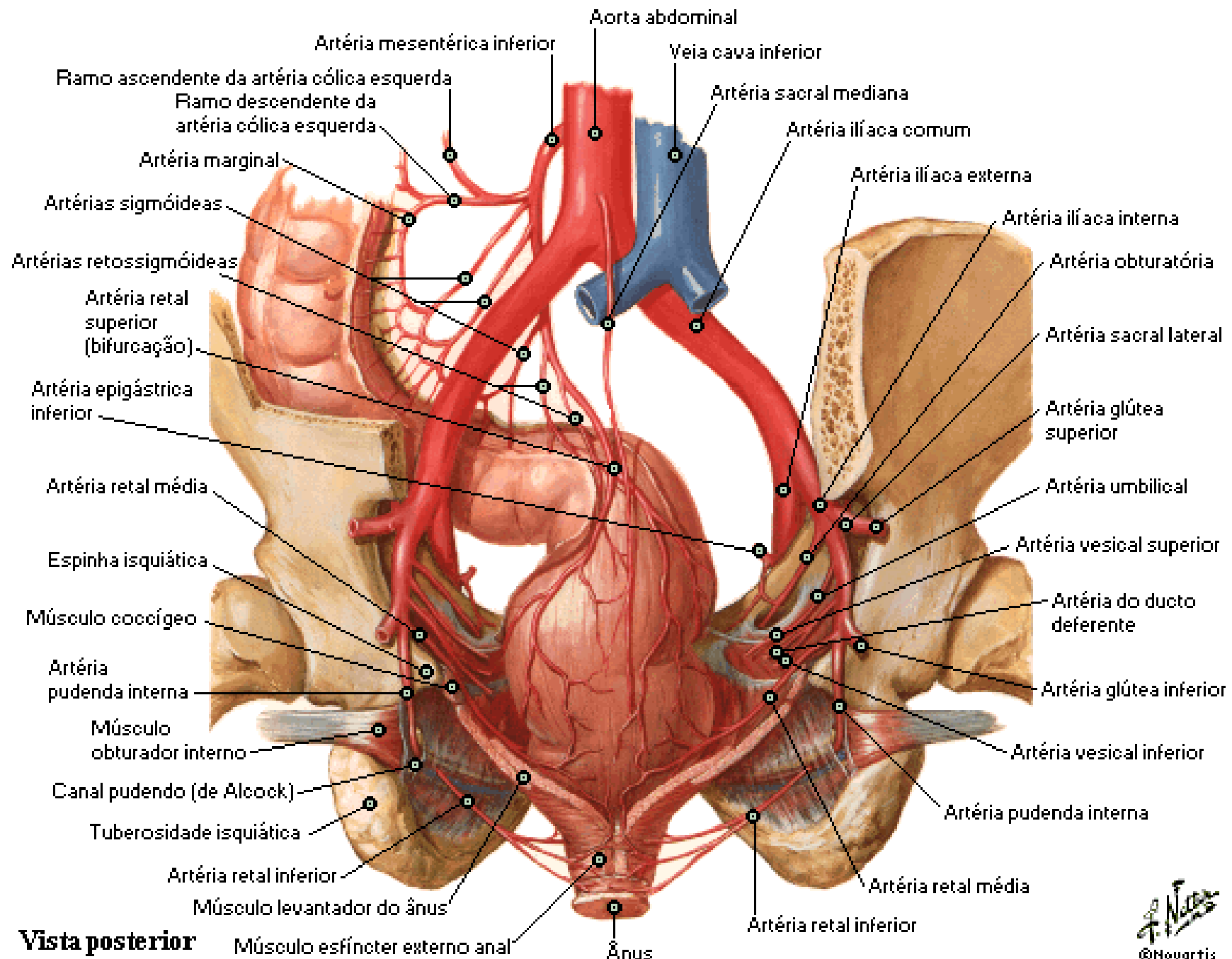


Espaços Perineopélvicos

Vista Perineal

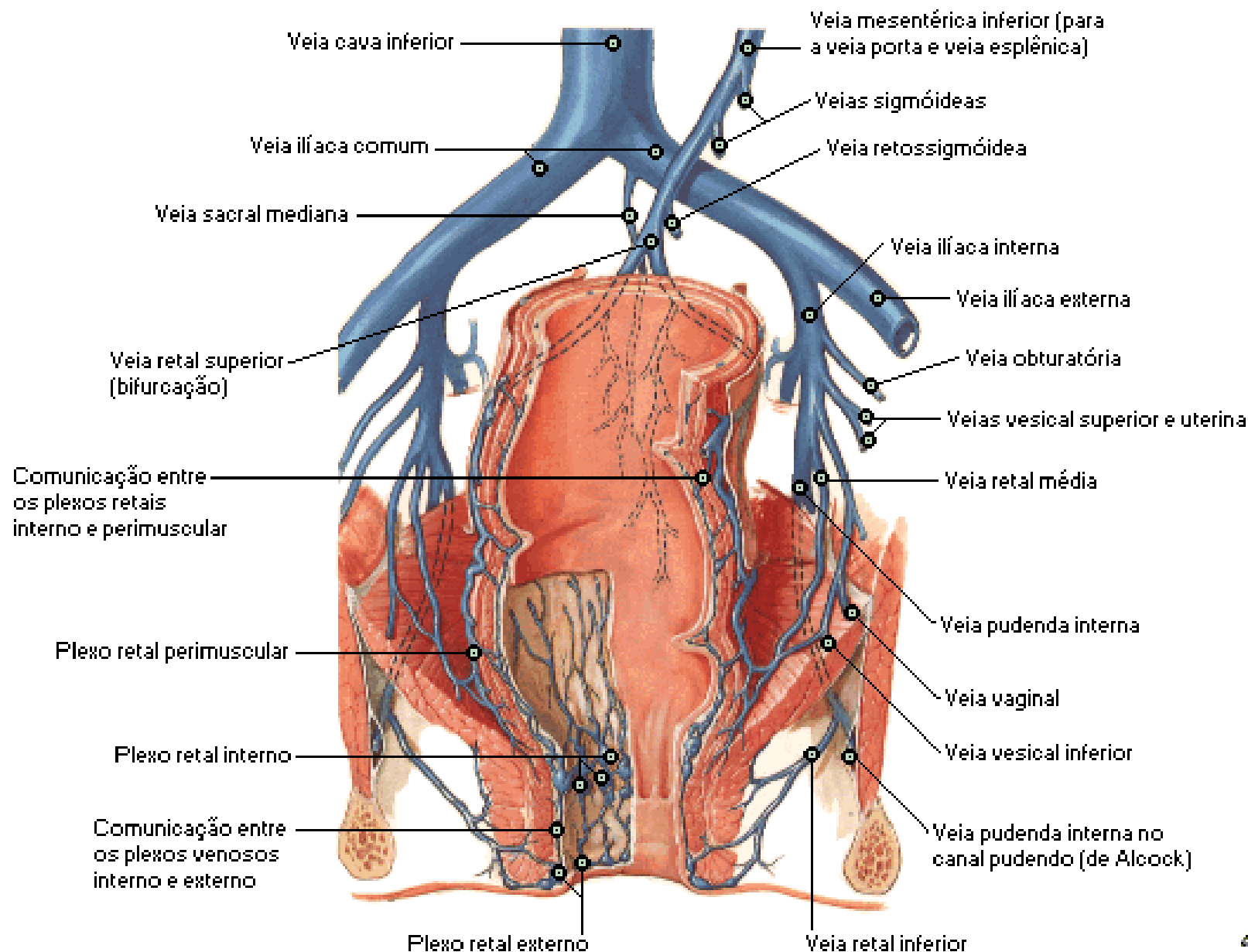


Artérias do Reto e Canal Anal



Veias do Reto e Canal Anal

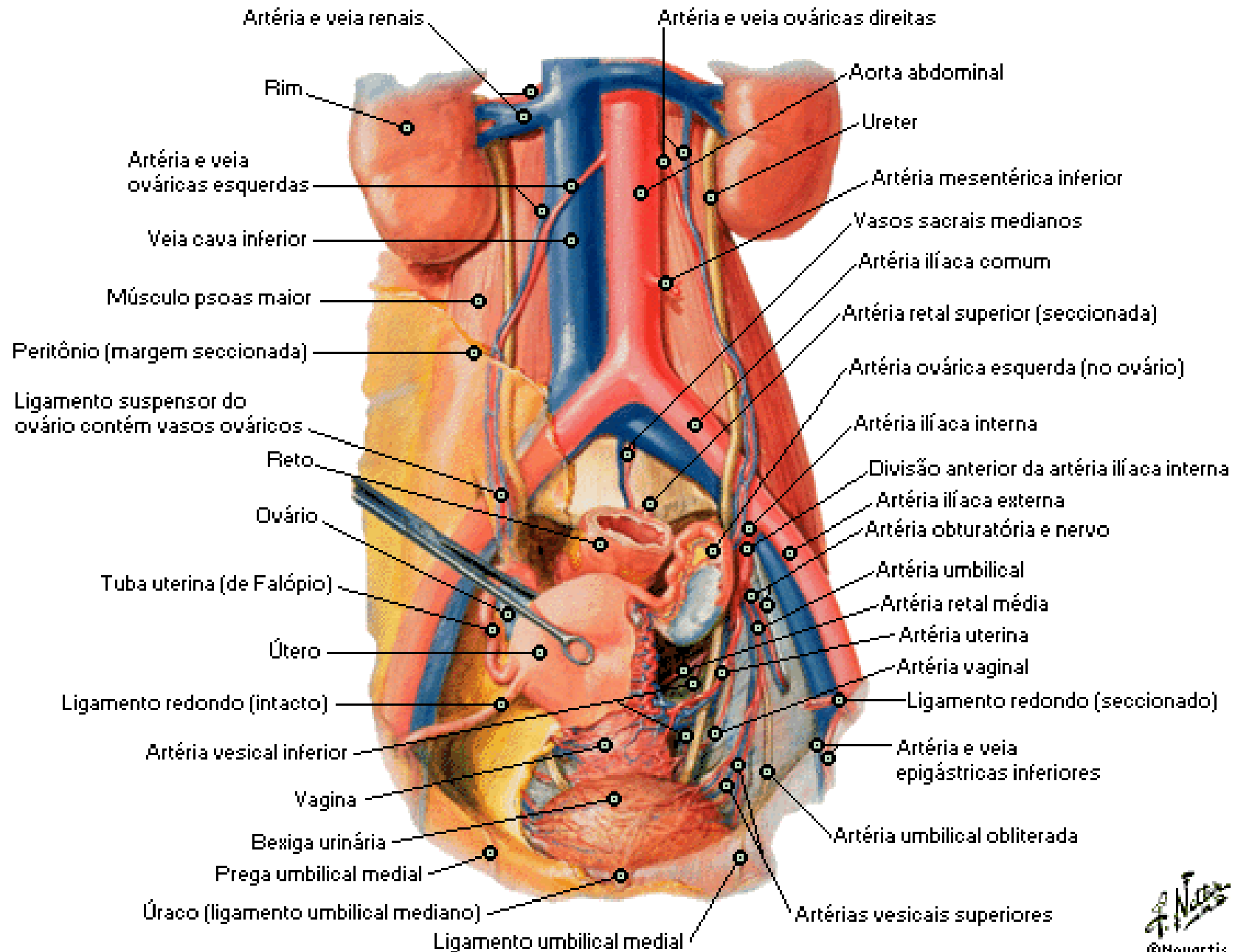
Vista anterior



Artérias e Veias dos Órgãos Pélvicos

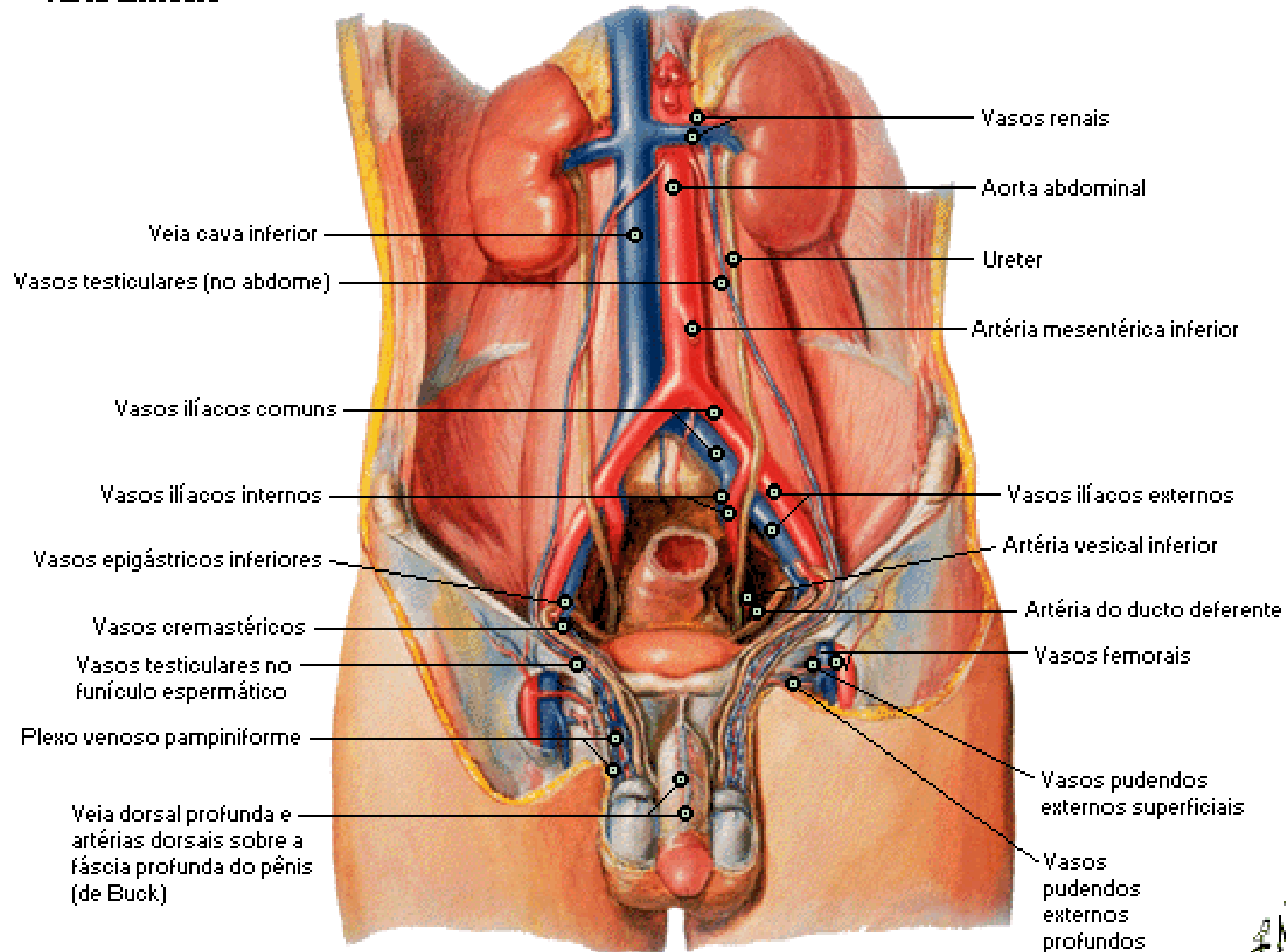
Vista anterior

Sexo Feminino



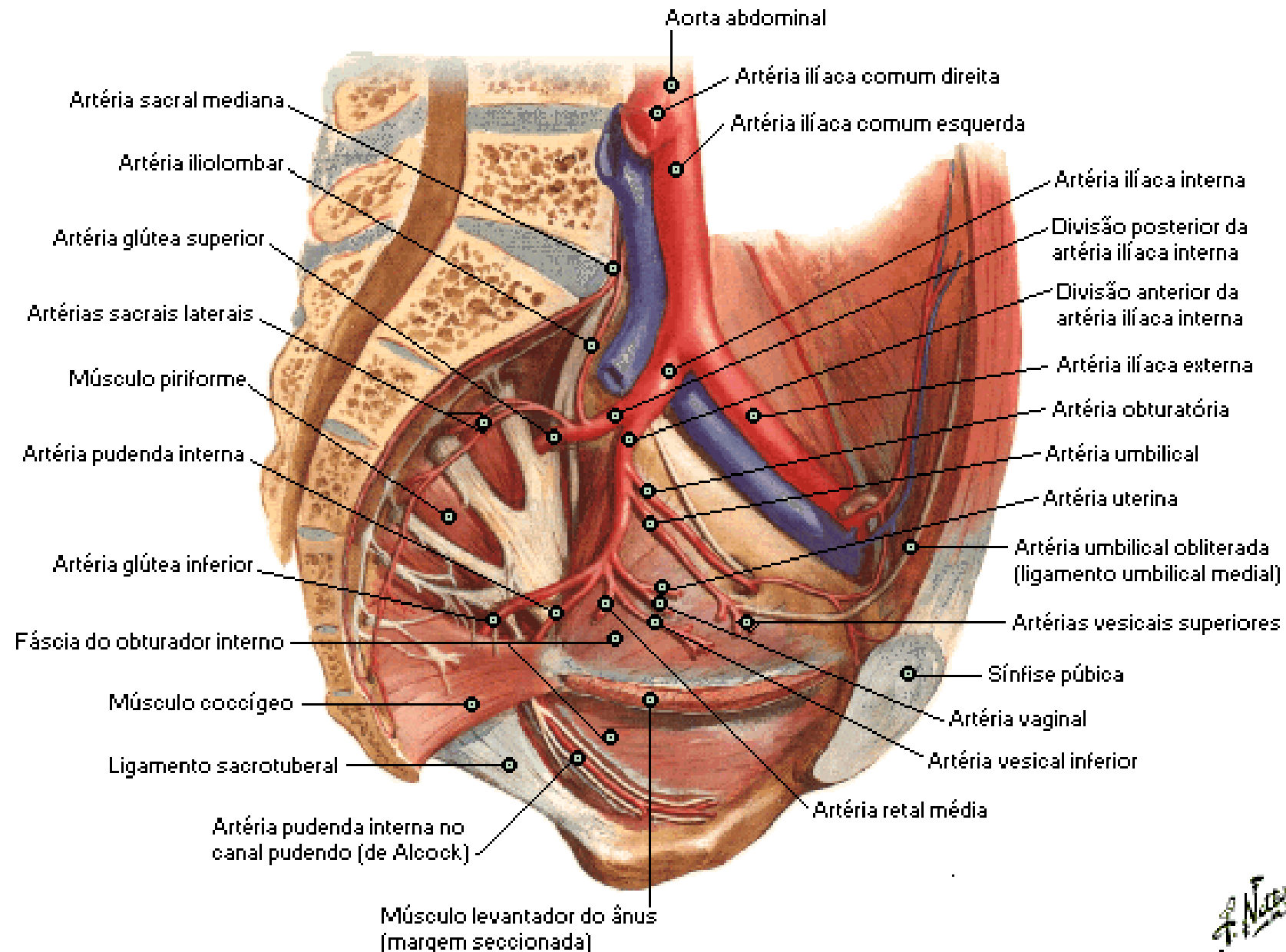
Artérias e Veias dos Testículos

Vista anterior



Artérias e Veias da Pelve

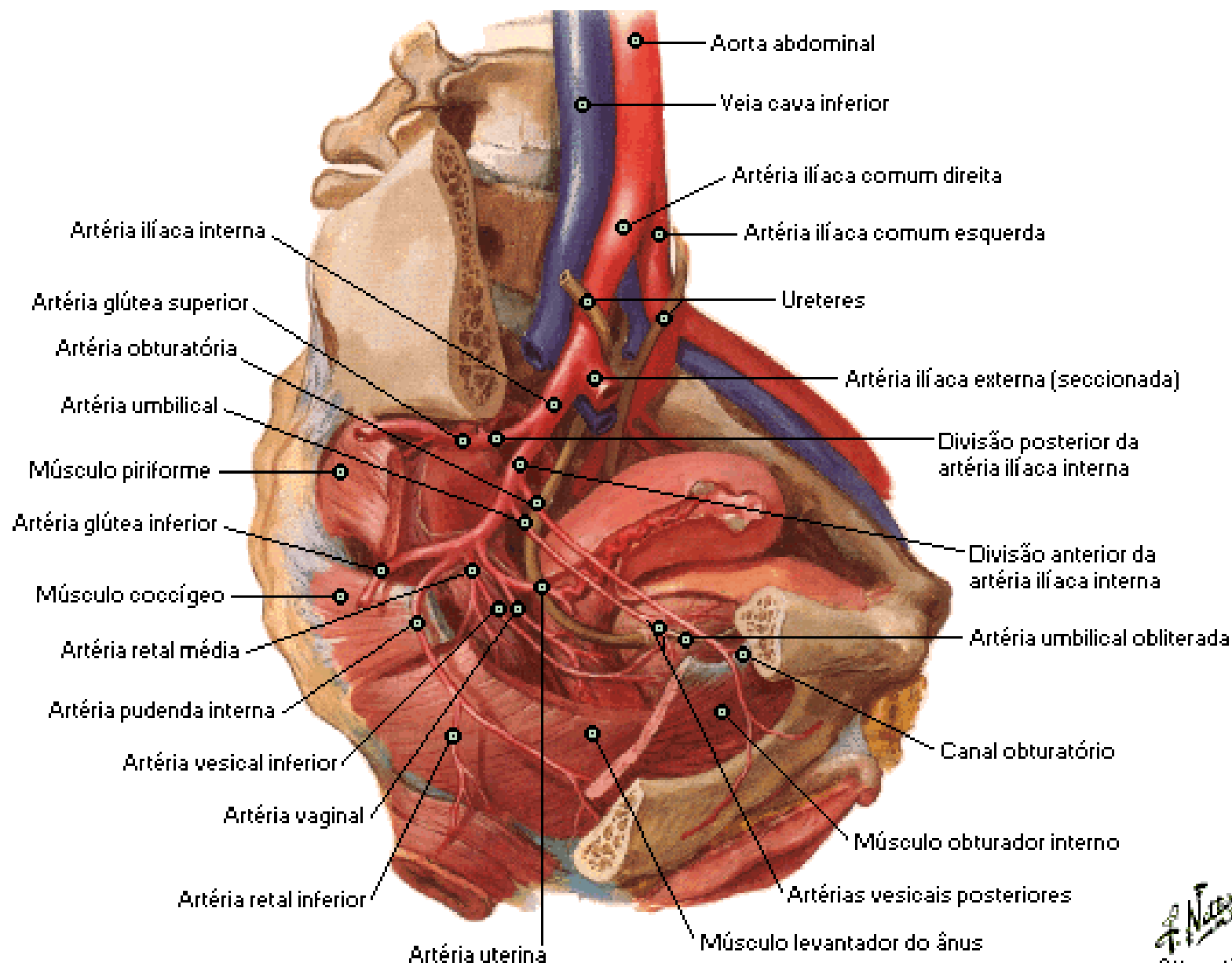
Sexo Feminino - Secção Sagital



Artérias e Veias da Pelve

Sexo Feminino - Secção Paramediana Direita

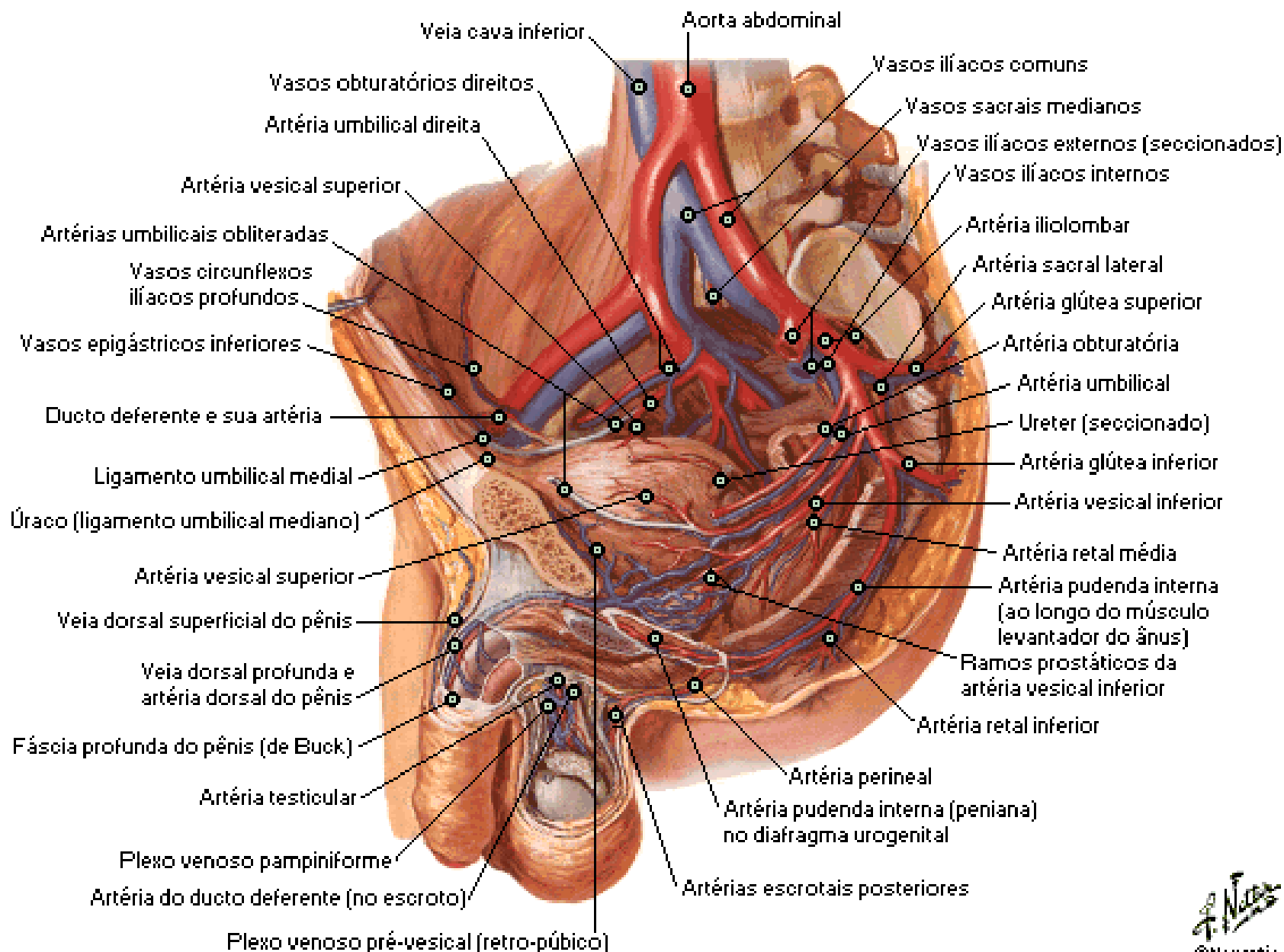
Vista lateral



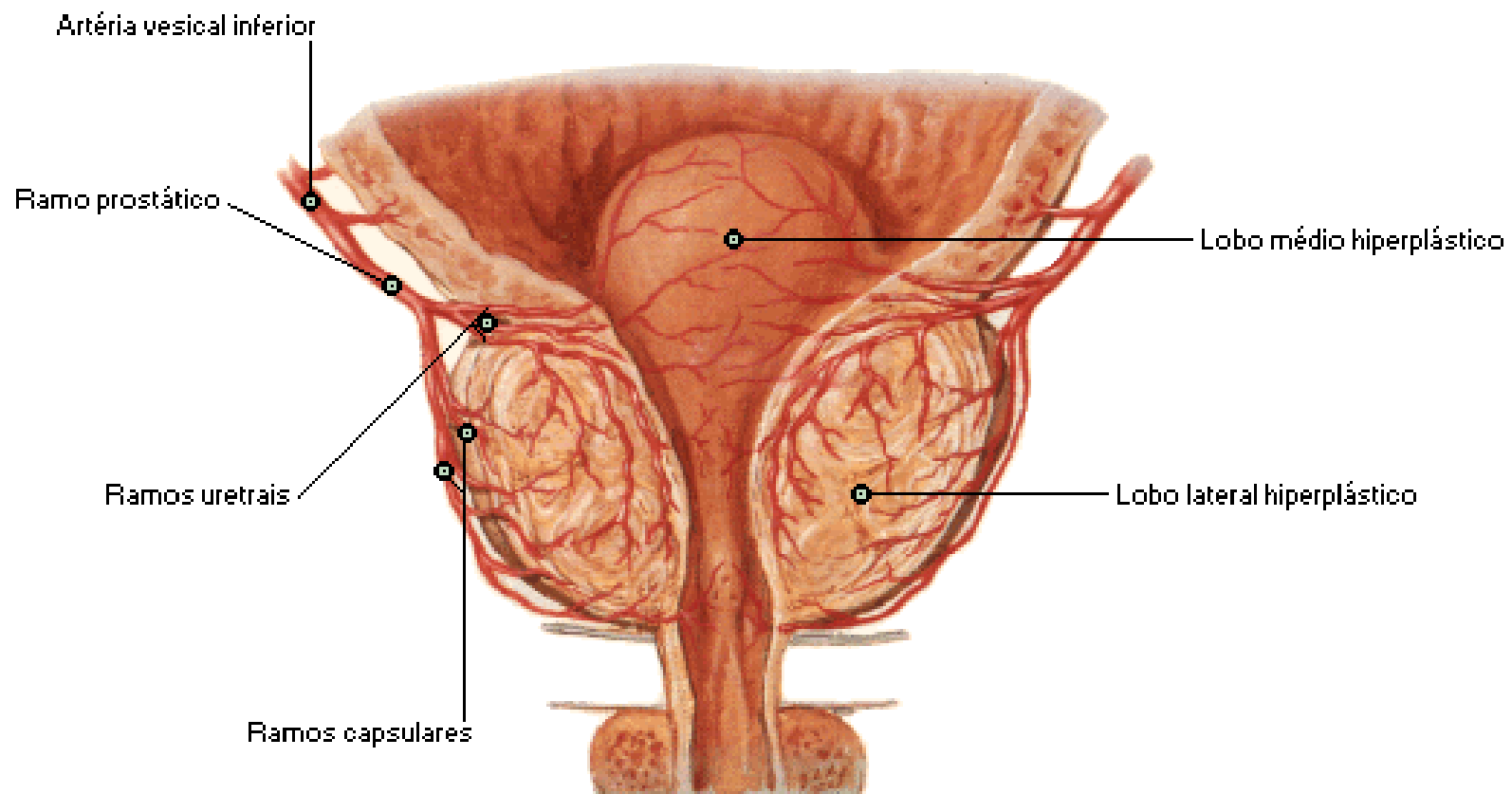
Artérias e Veias da Pelve

Sexo Masculino - Secção Paramediana Esquerda

Vista lateral



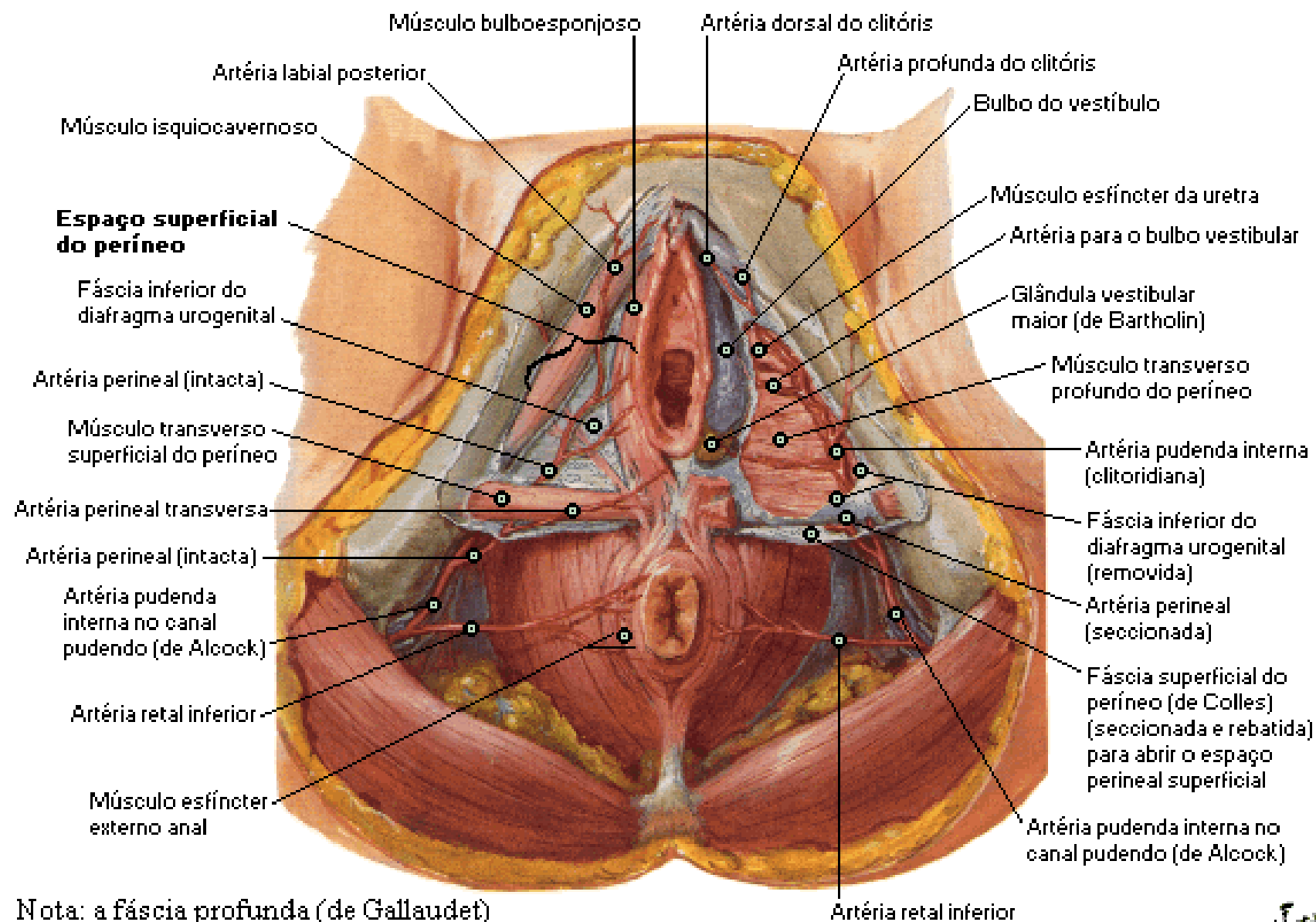
Suprimento Arterial da Próstata



Espécime com hiperplasia benigna

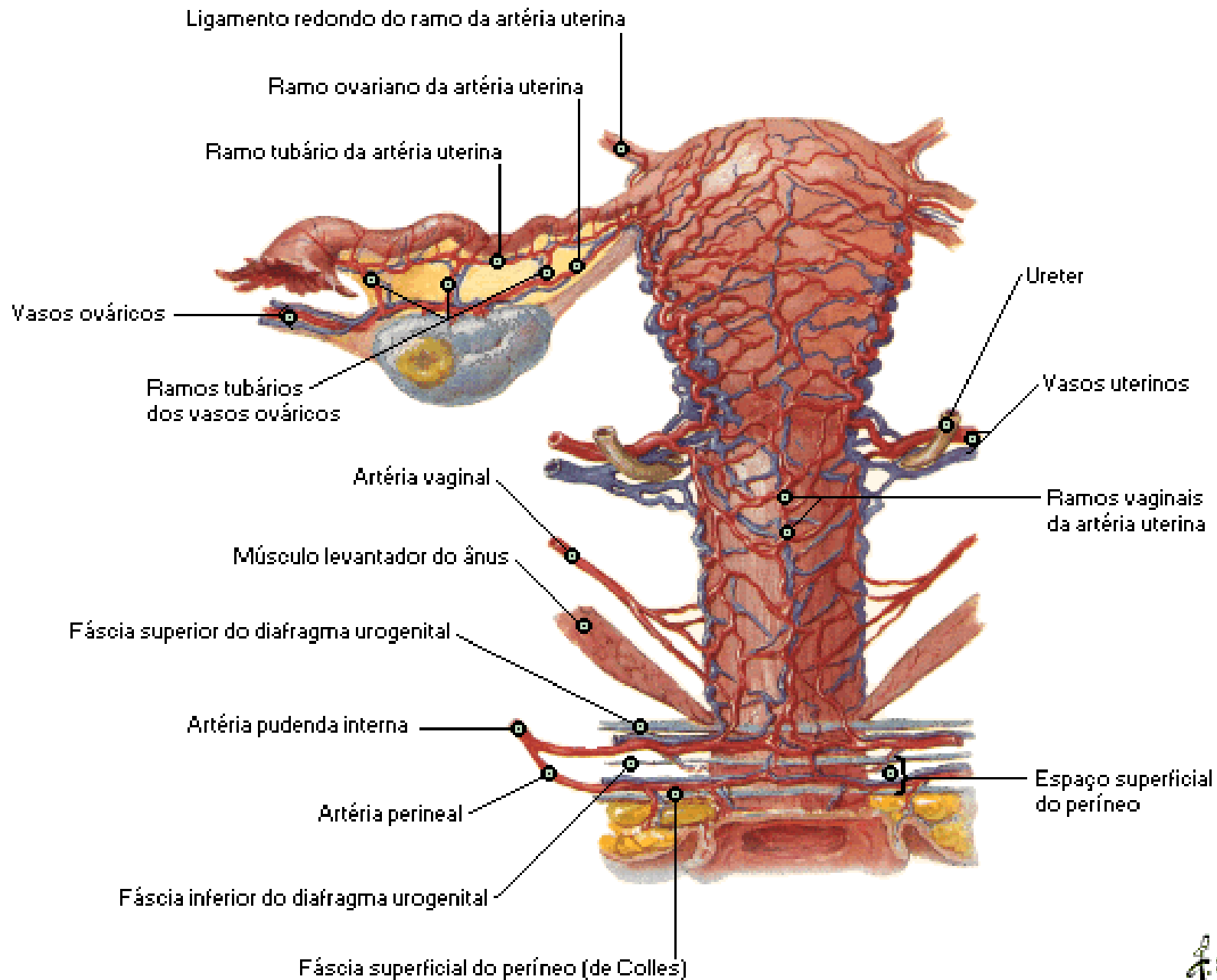
Artérias e Veias do Períneo

Sexo Feminino



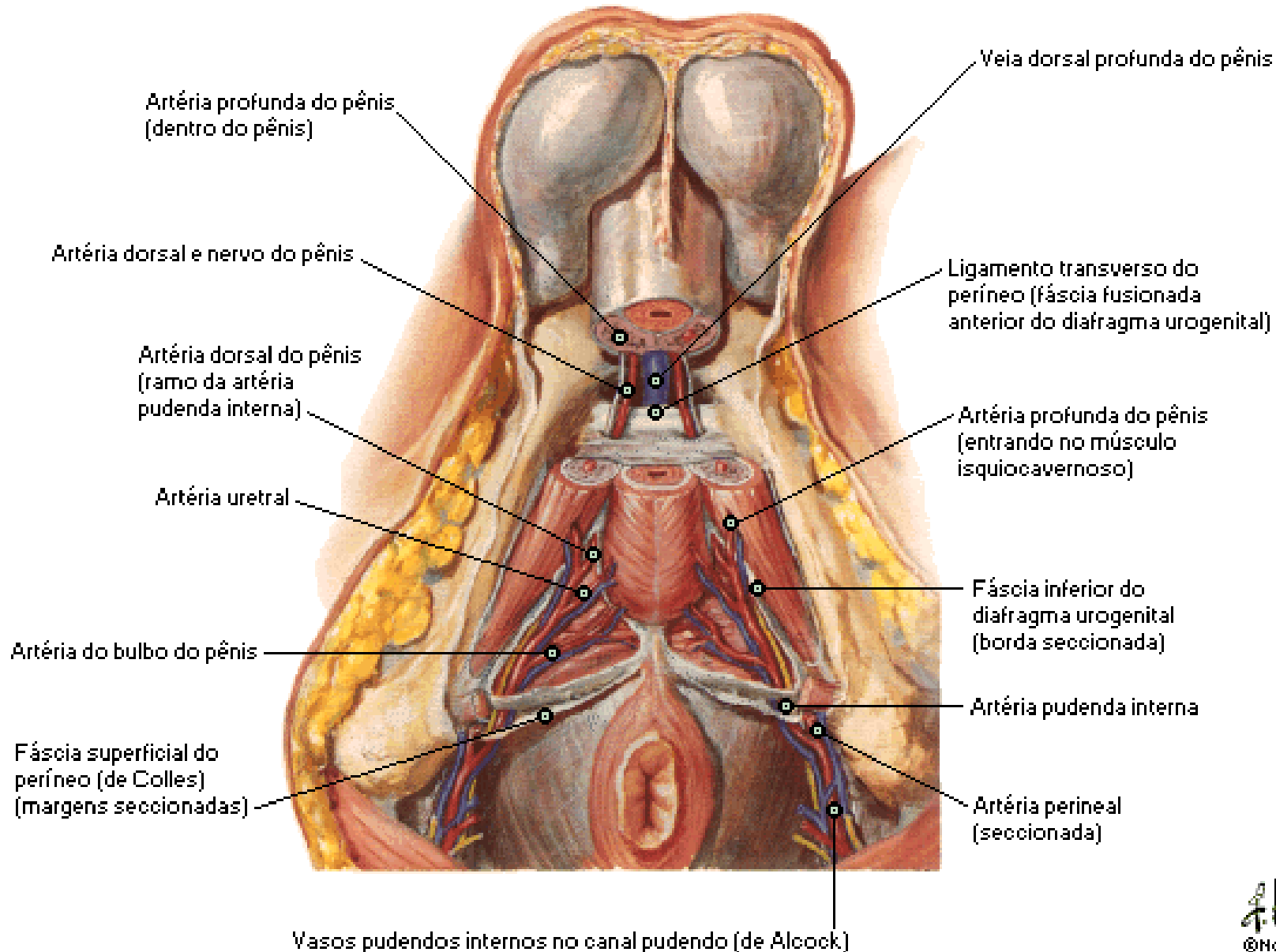
Nota: a fáscia profunda (de Gallaudet) foi removida dos músculos do espaço superficial do períneo

Artérias e Veias do Útero



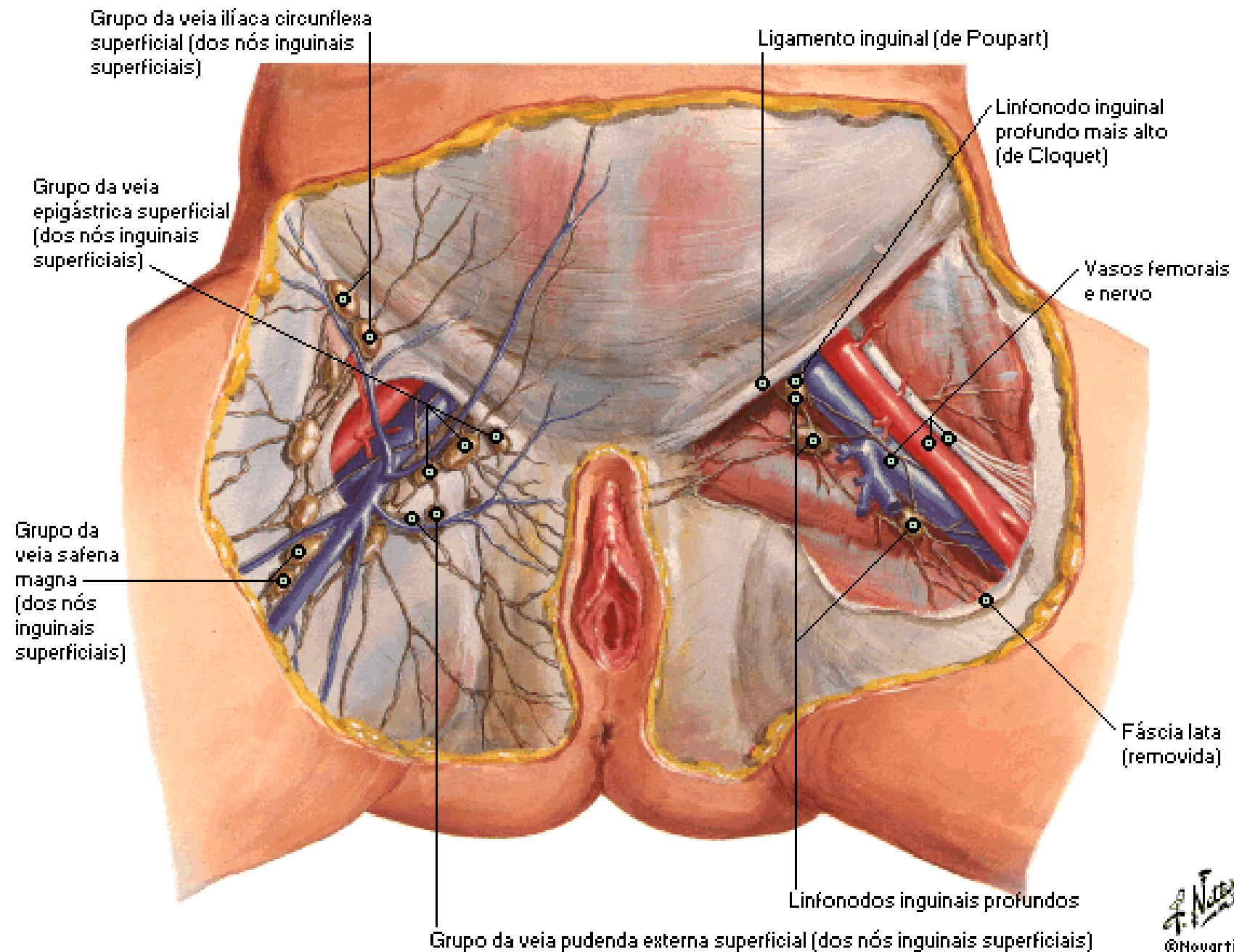
Artérias e Veias do Périneo [Continuação]

Sexo Masculino



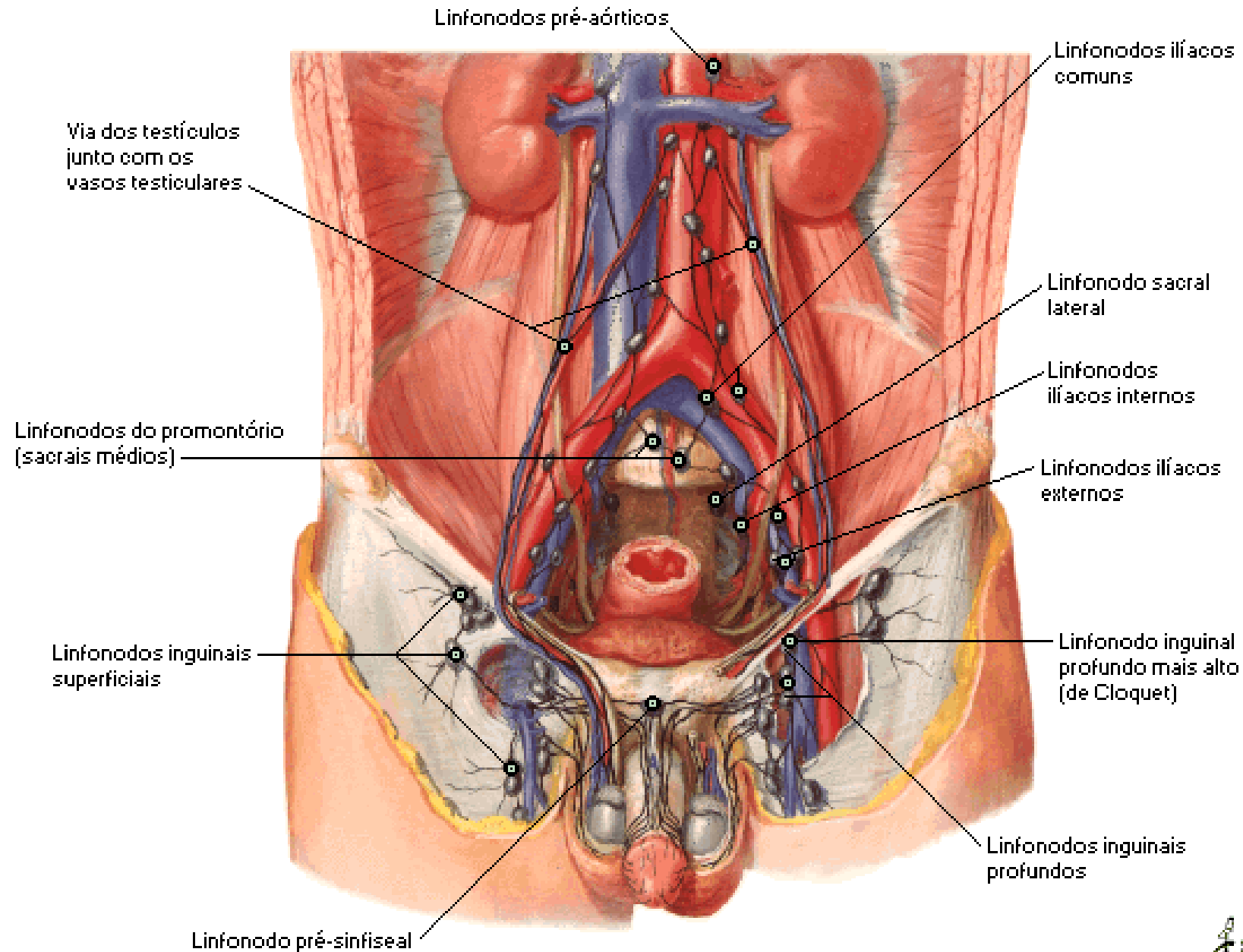
Vasos Linfáticos e Linfonodos do Períneo

Sexo Feminino

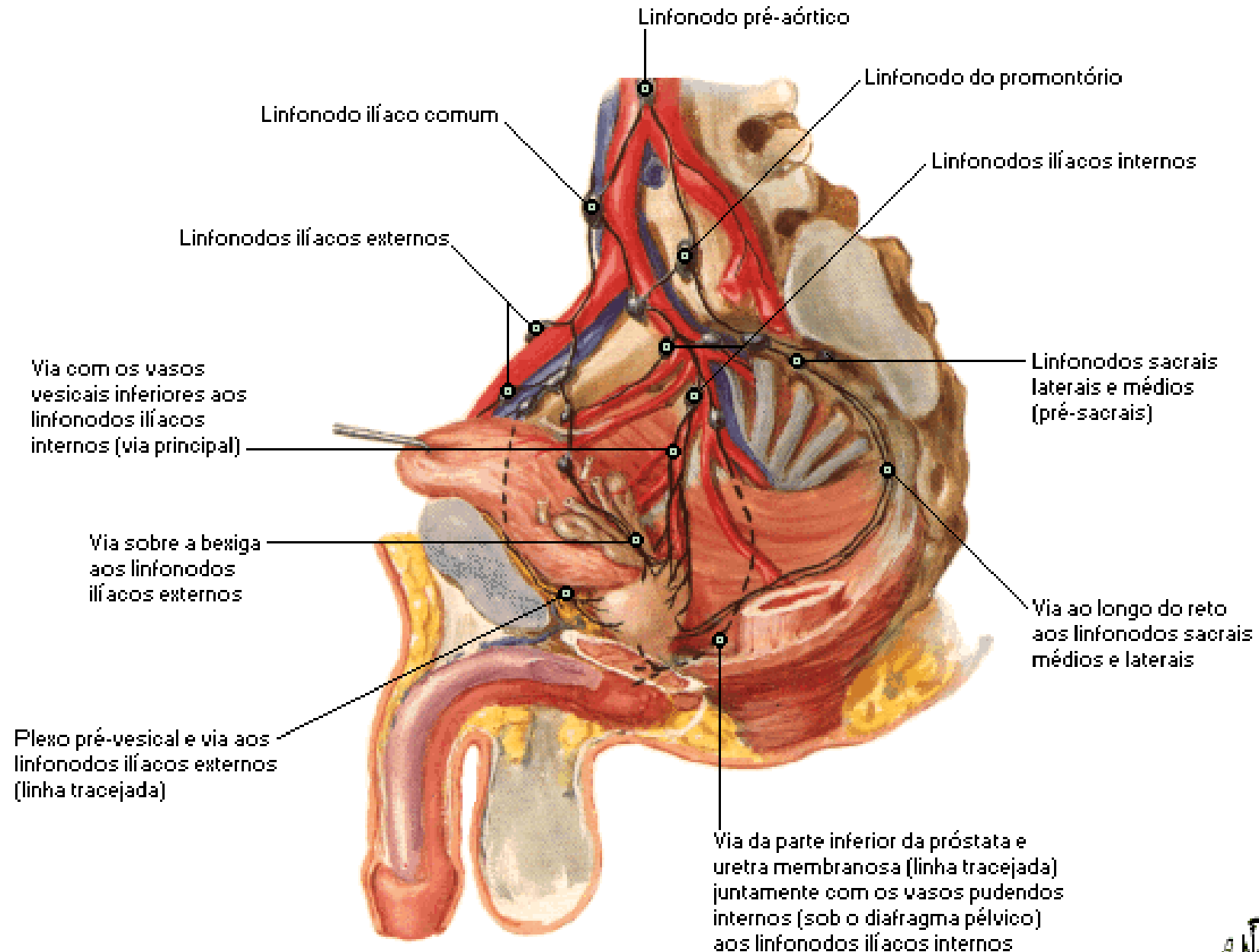


Vasos Linfáticos e Linfonodos da Pelve e Órgãos Genitais

Sexo Masculino

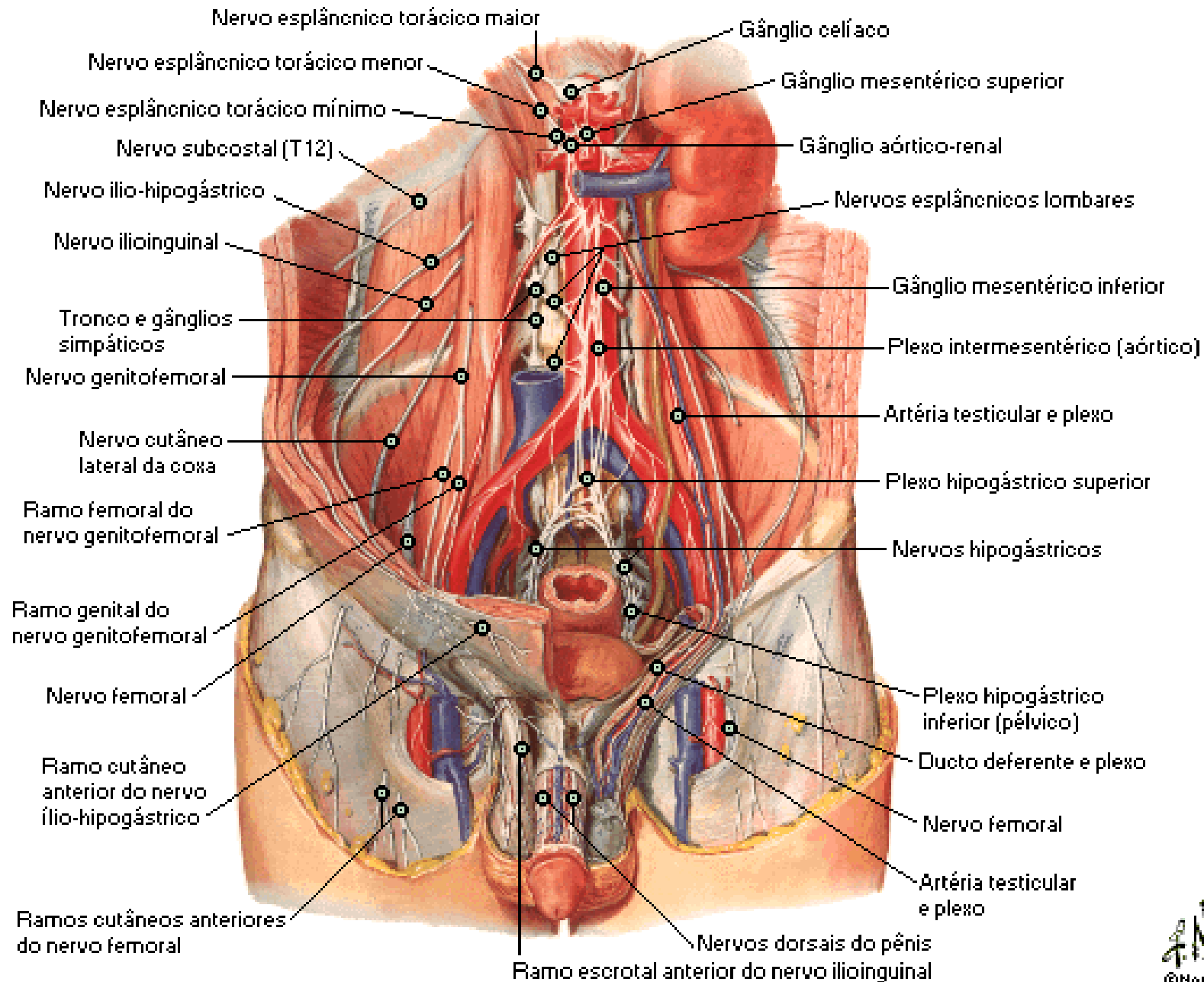


Drenagem Linfática da Próstata



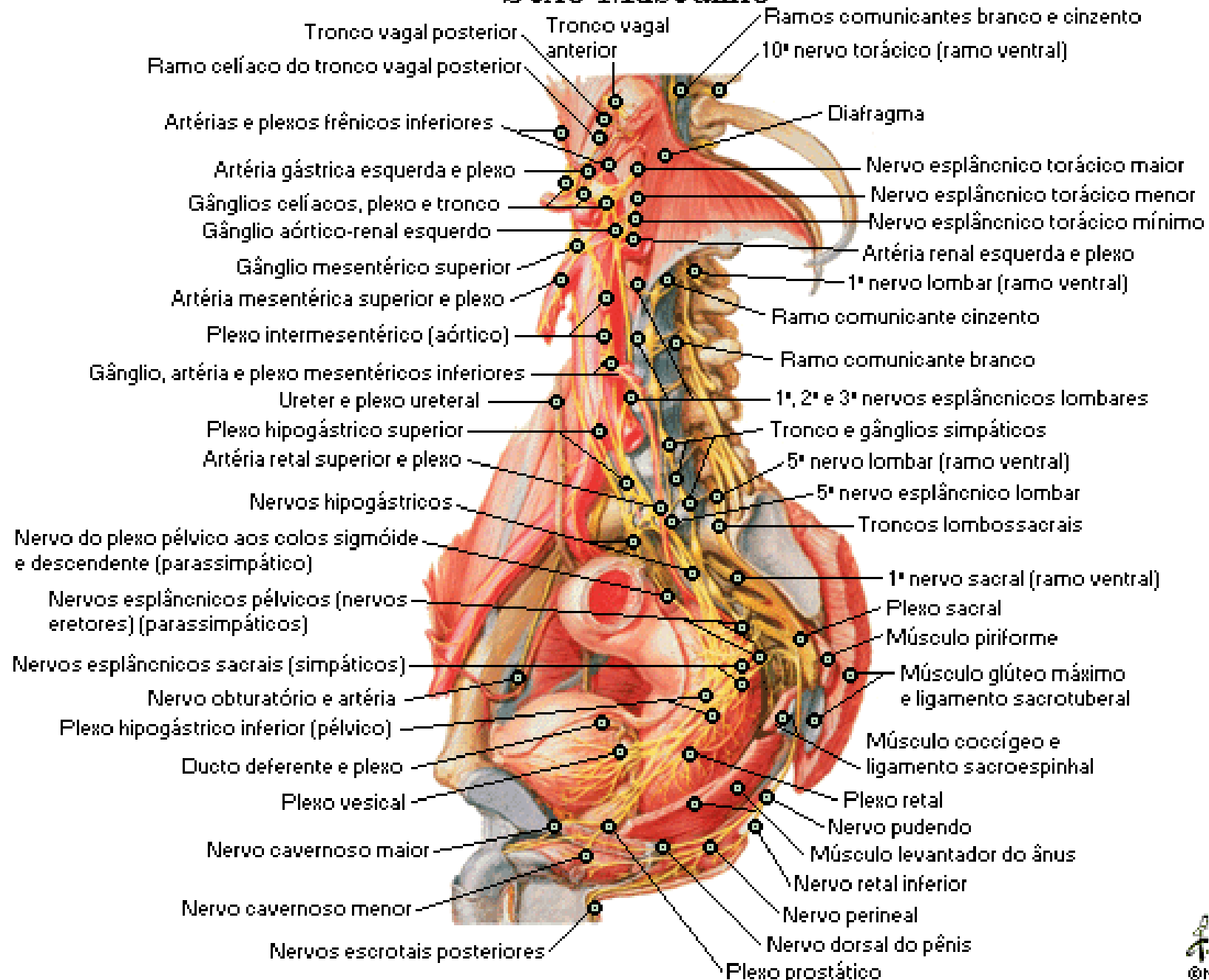
Nervos dos Órgãos Genitais Externos

Sexo Masculino



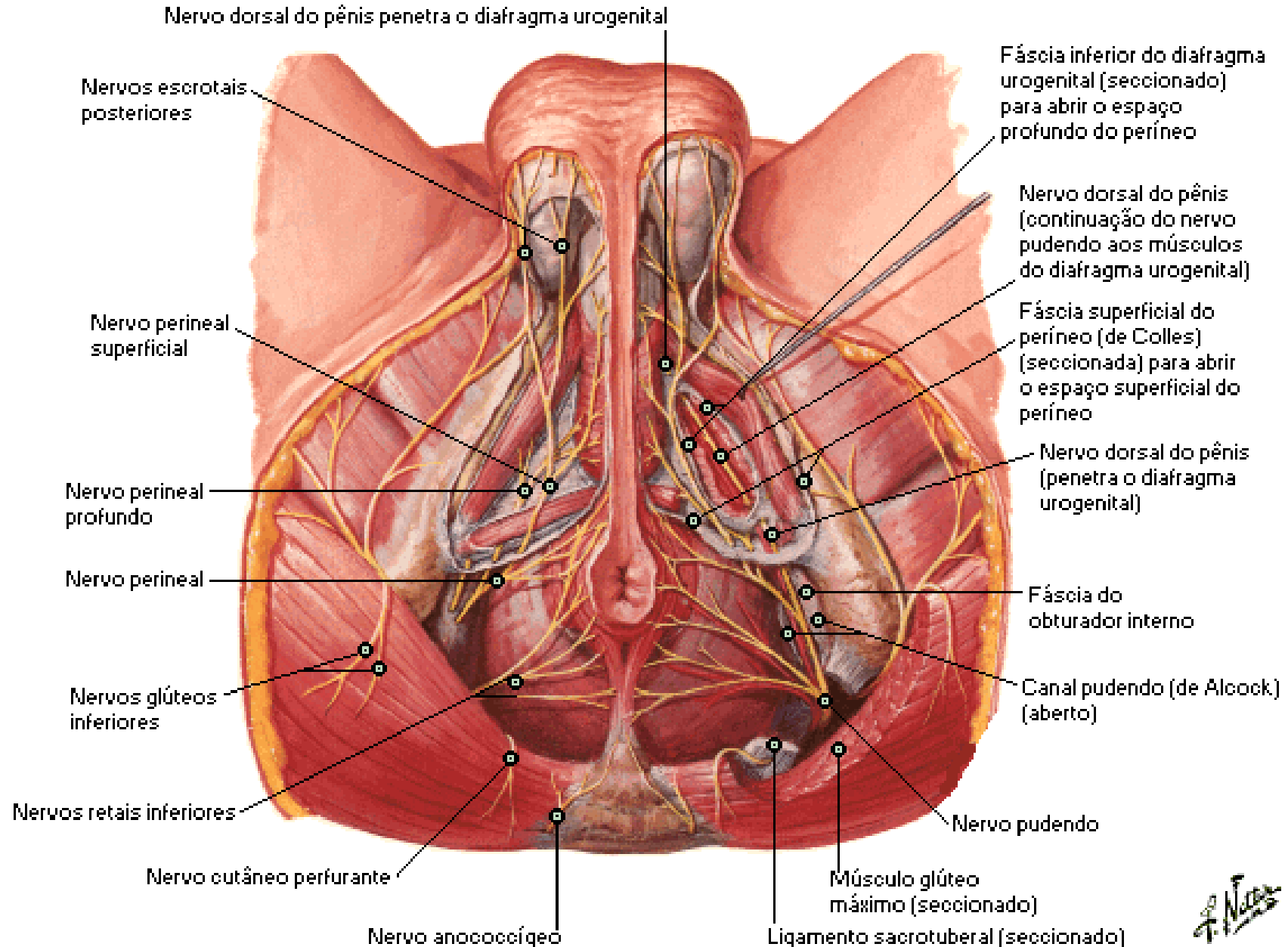
Nervos das Visceras Pélvicas

Sexo Masculino



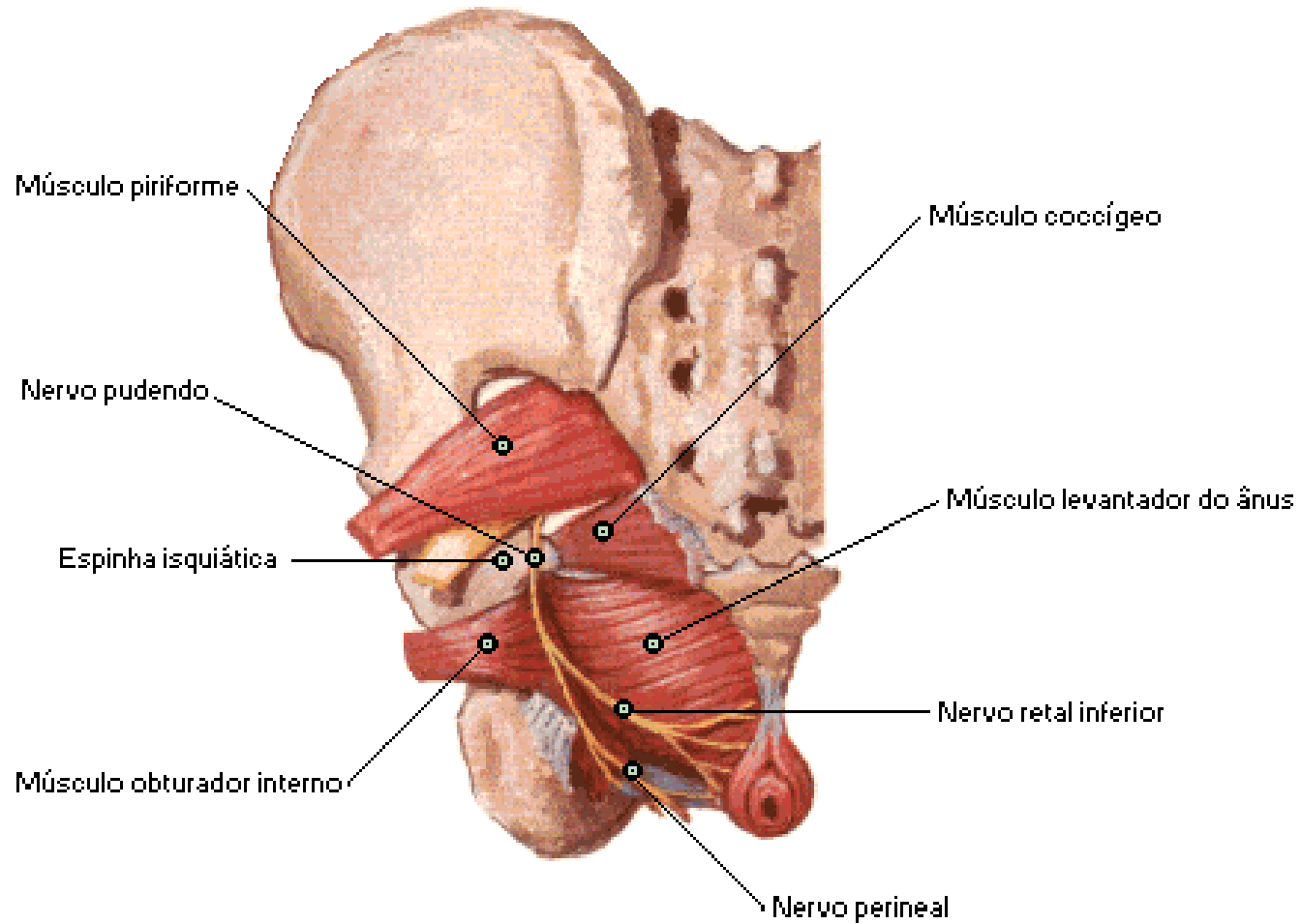
Nervos do Períneo

Sexo Masculino - Vista Perineal



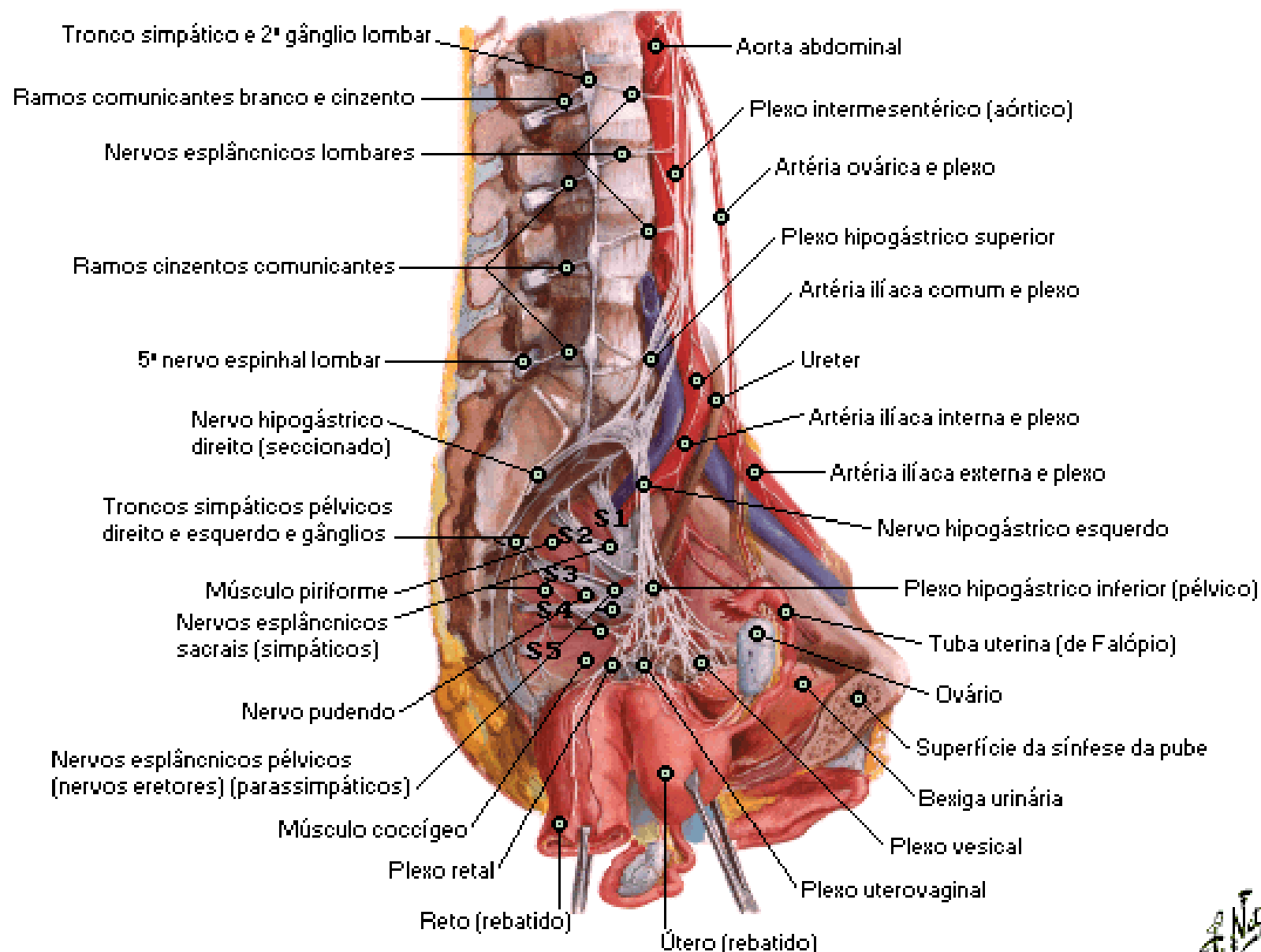
Nervos do Períneo

Sexo Masculino - Vista Inferior



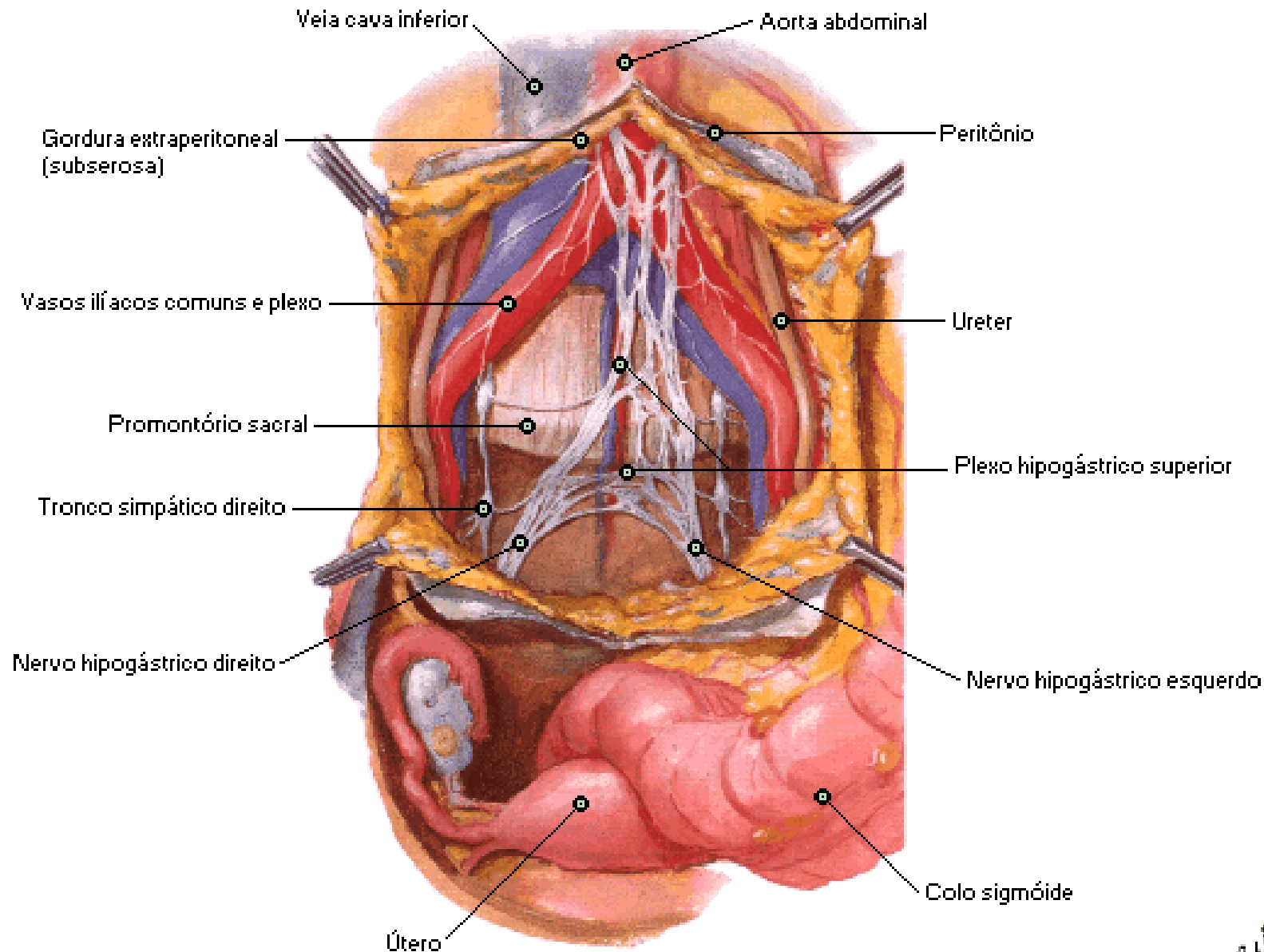
Nervos das Visceras Pélvicas

Sexo Feminino - Secção Sagital



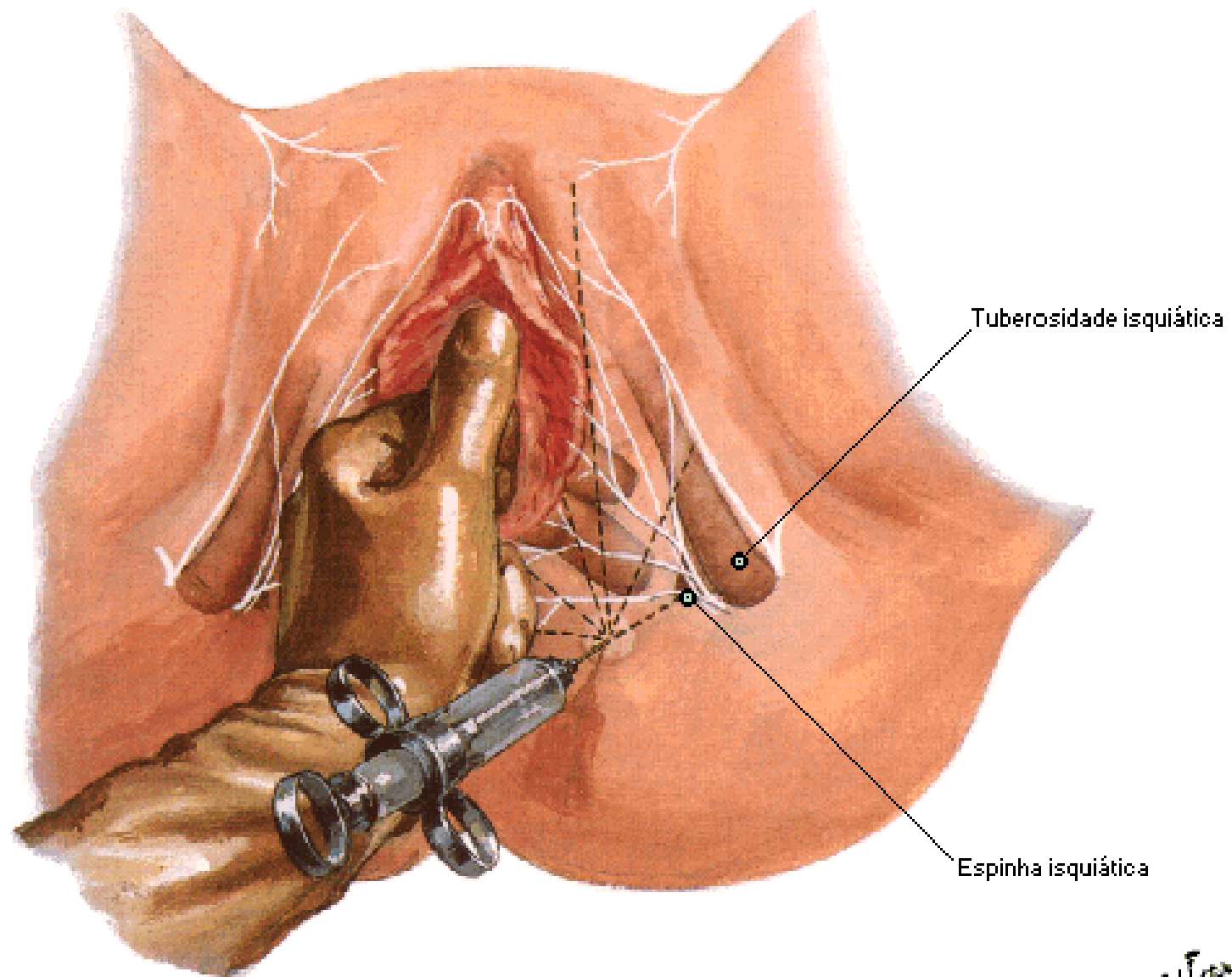
Nervos das Visceras Pélvicas

Sexo Feminino - Vista Superior

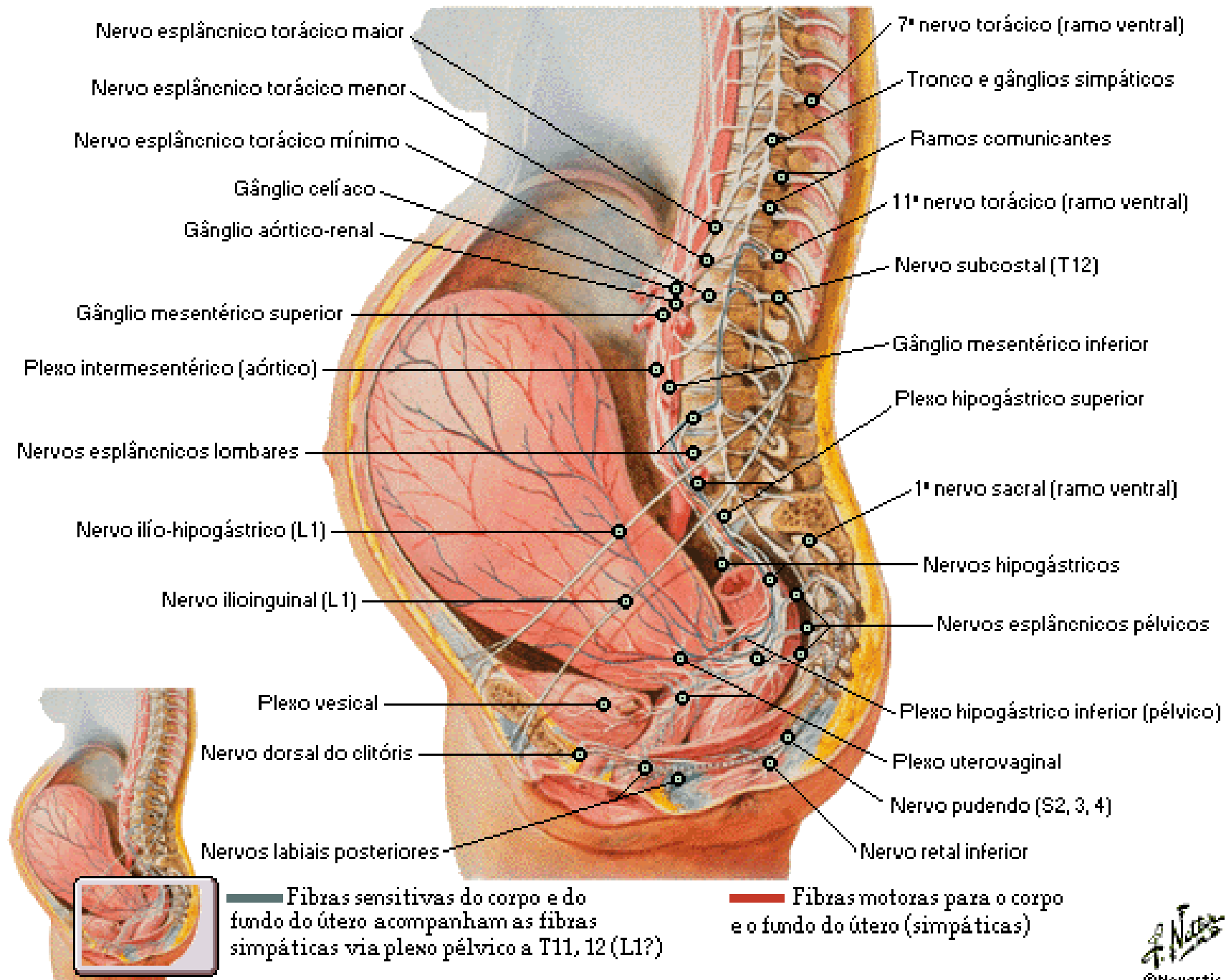


Bloqueio Anestésico da Área Perineal

Nervo Pudendo

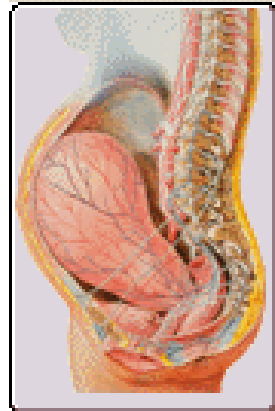


Vias Neurais no Parto



Vias Neurais no Parto

Área Pélvica Ampliada



Nervo ilio-hipogástrico (L1)

Nervo ilioinguinal (L1)

Plexo vesical

Nervo dorsal do clitóris

Nervos labiais posteriores

Nervos hipogástricos

Nervos esplâncnicos pélvicos

Flexo hipogástrico inferior (pélvico)

Plexo uterovaginal

Nervo pudendo (S2, 3, 4)

Nervo retal inferior

— Fibras sensitivas do corpo e do fundo do útero acompanham as fibras simpáticas via plexo pélvico a T11, 12 (L1?)

— Fibras motoras para o corpo e o fundo do útero (simpáticas)

— Fibras sensitivas do colo do útero e da parte superior da vagina acompanham os nervos esplâncnicos (parassimpáticos) a S2, 3, 4

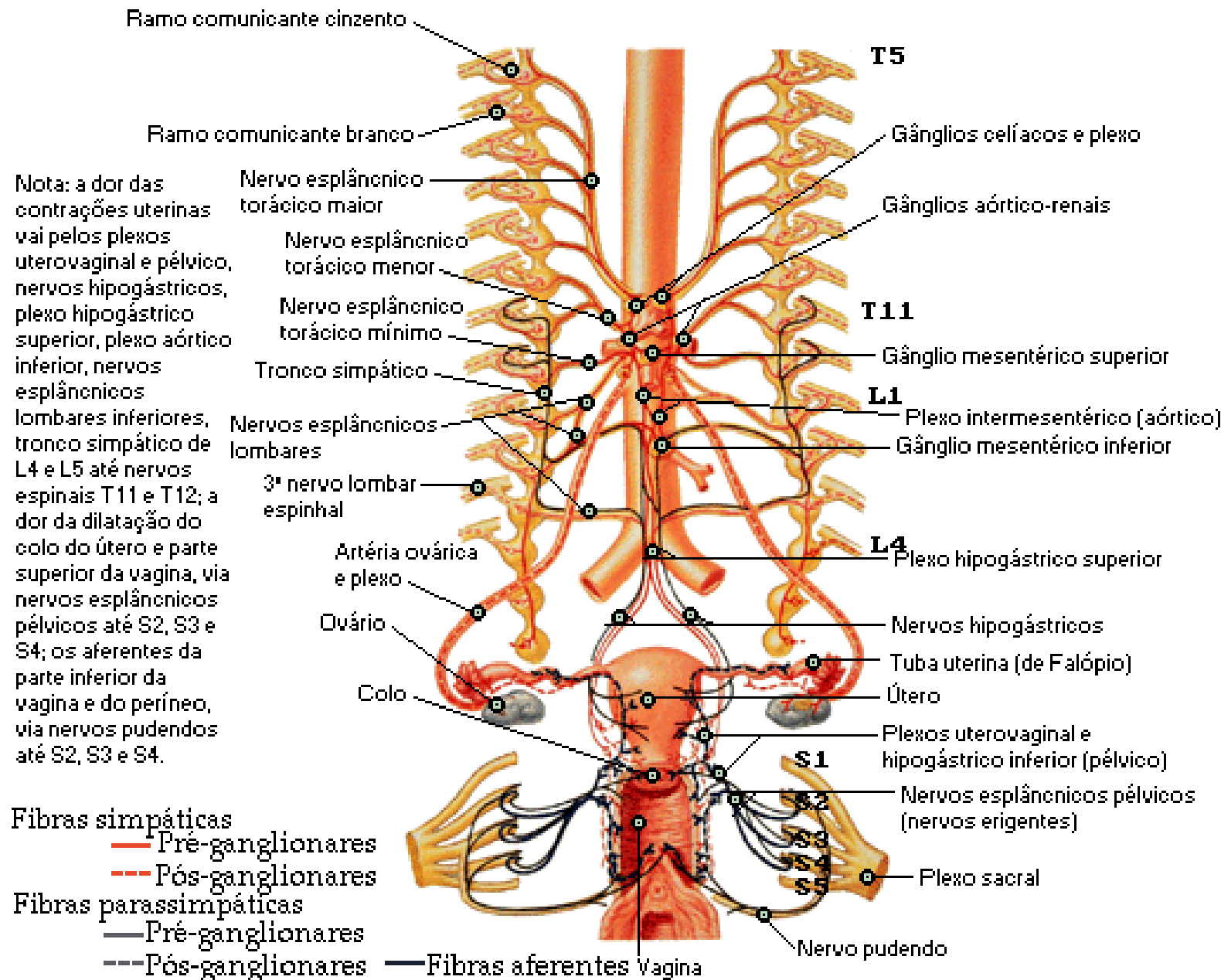
— Fibras motoras até o segmento inferior do útero, colo e parte superior da vagina (parassimpáticas)

— Fibras sensitivas da parte inferior da vagina e perineo acompanham as fibras motoras somáticas via nervo pudendo a S2, 3, 4

— Fibras motoras à parte inferior da vagina e perineo via nervo pudendo (somáticas)

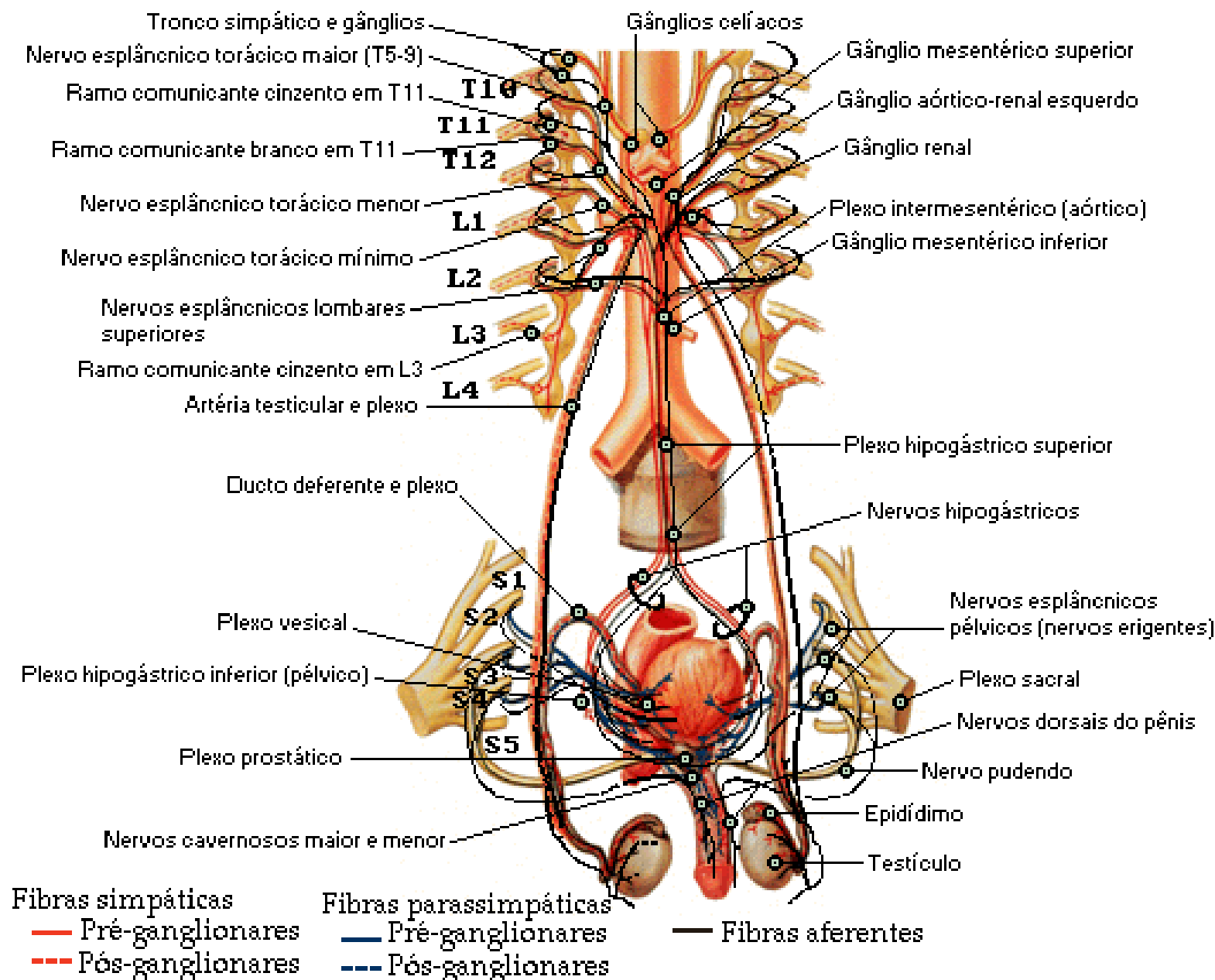
Inervação dos Órgãos Reprodutores Femininos

Esquema



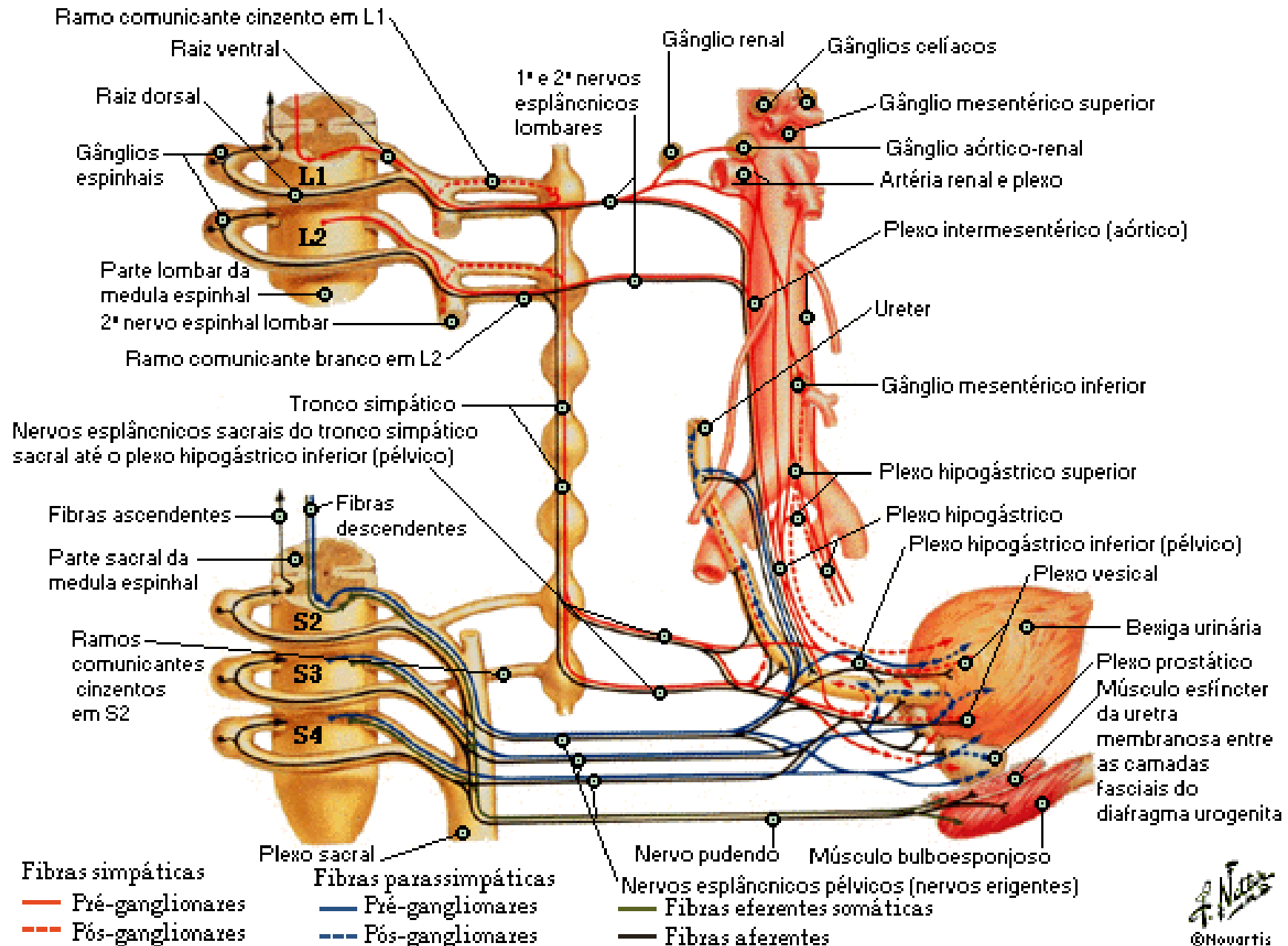
Inervação dos Órgãos Reprodutores Masculinos

Esquema



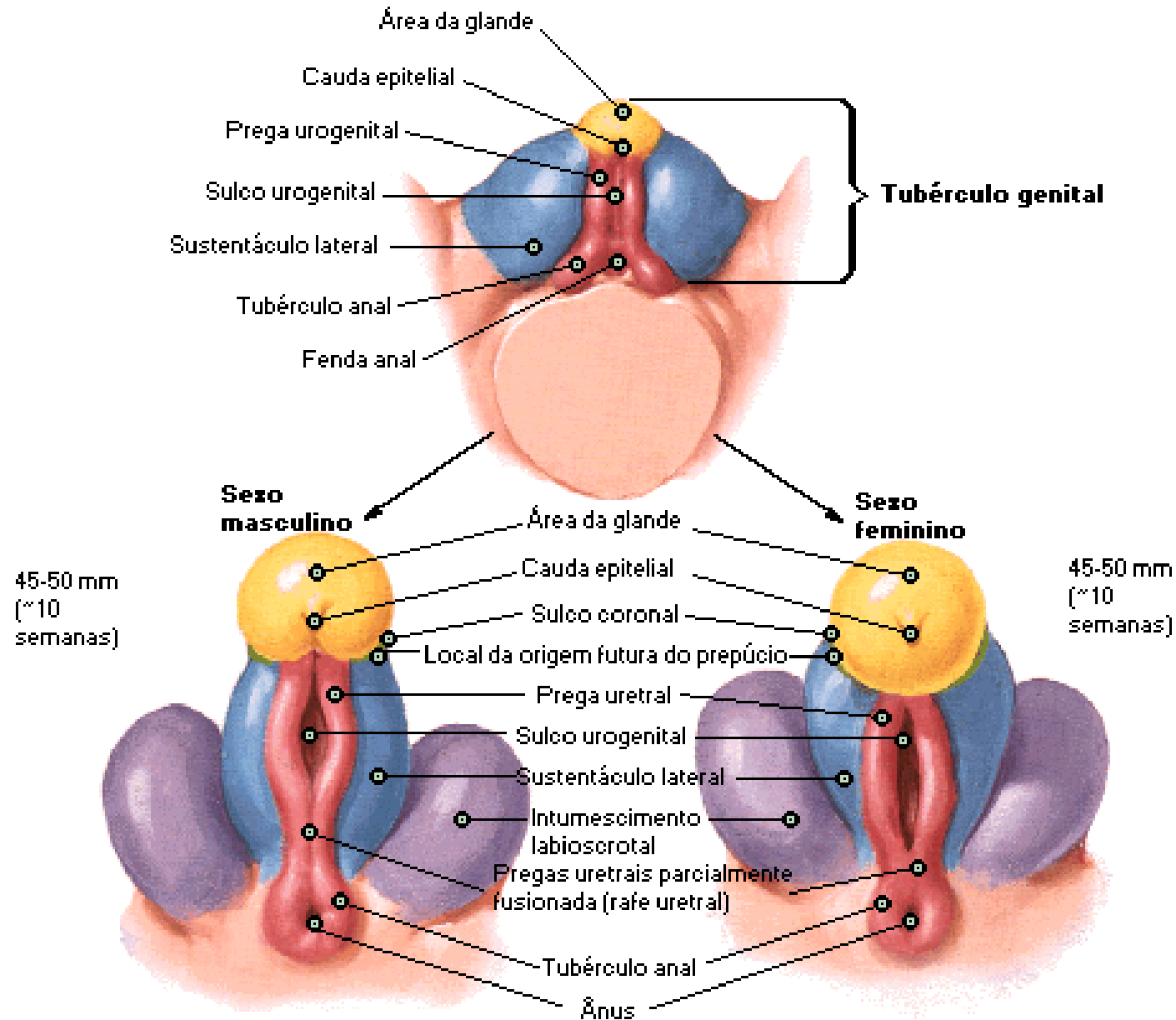
Inervação da Bexiga Urinária e Porção Inferior do Ureter

Esquema



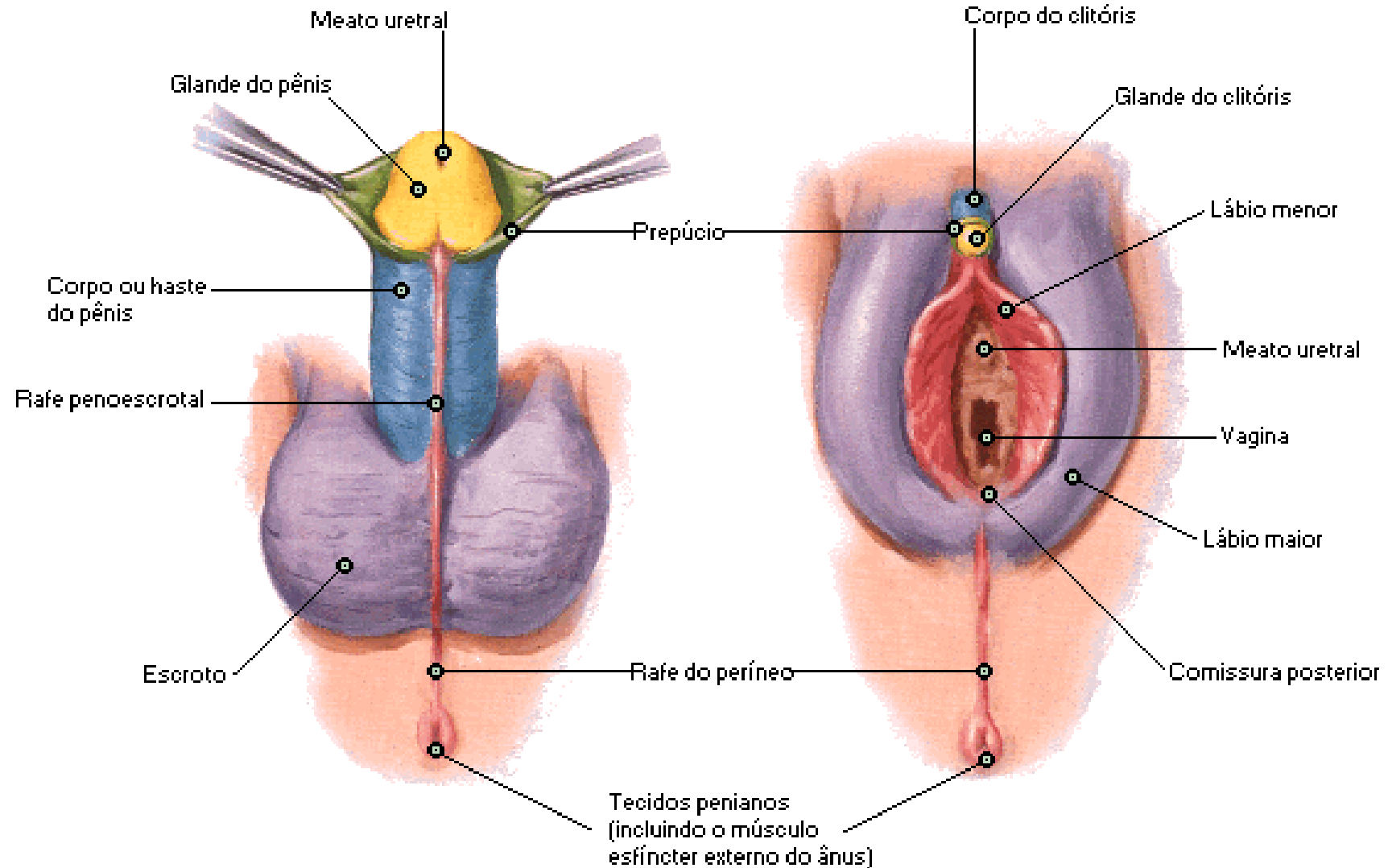
Homólogos dos Órgãos Genitais Externos

Indiferenciado



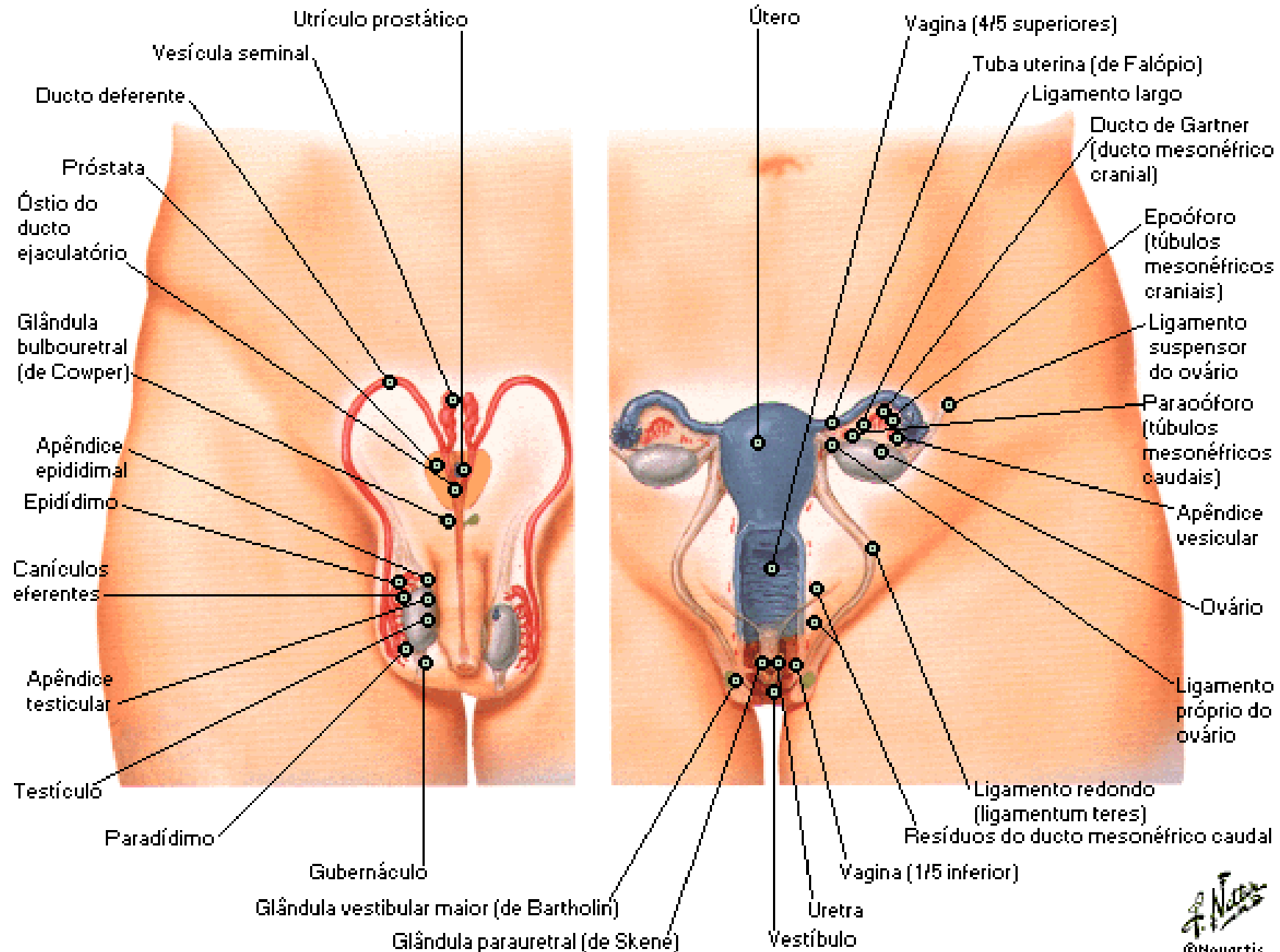
Homólogos dos Órgãos Genitais Externos

Sexos Masculino e Feminino Totalmente Desenvolvidos

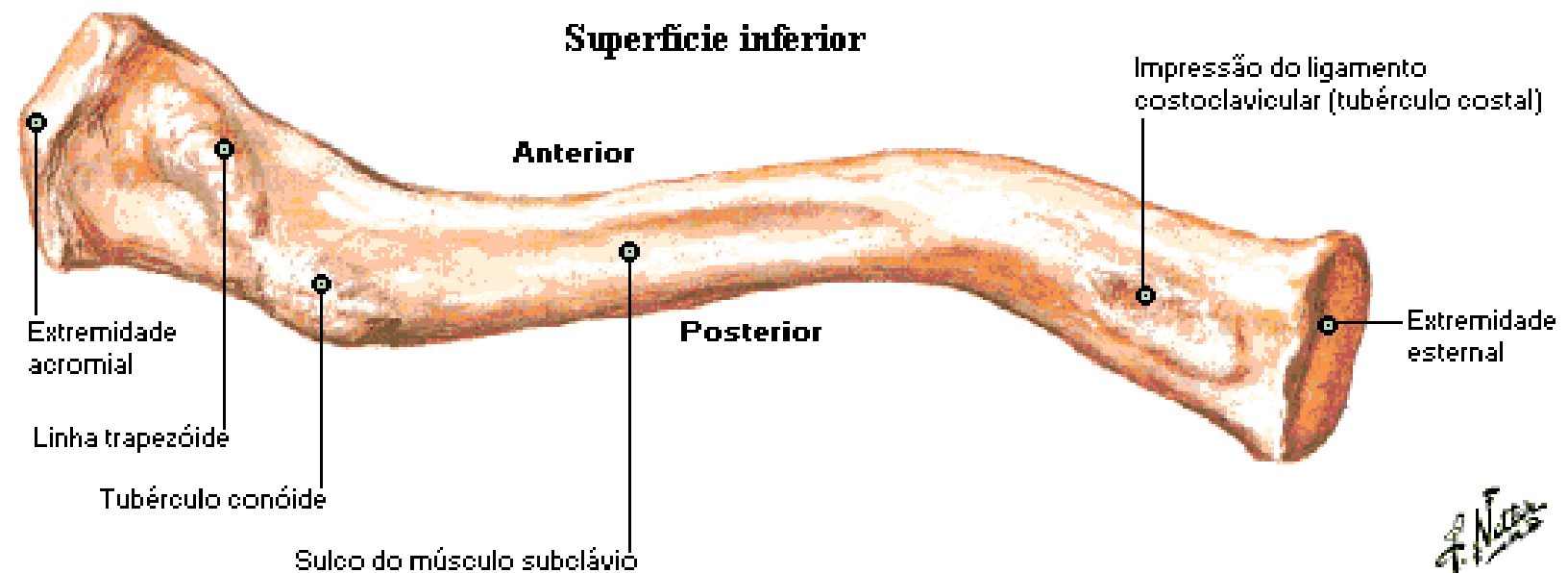
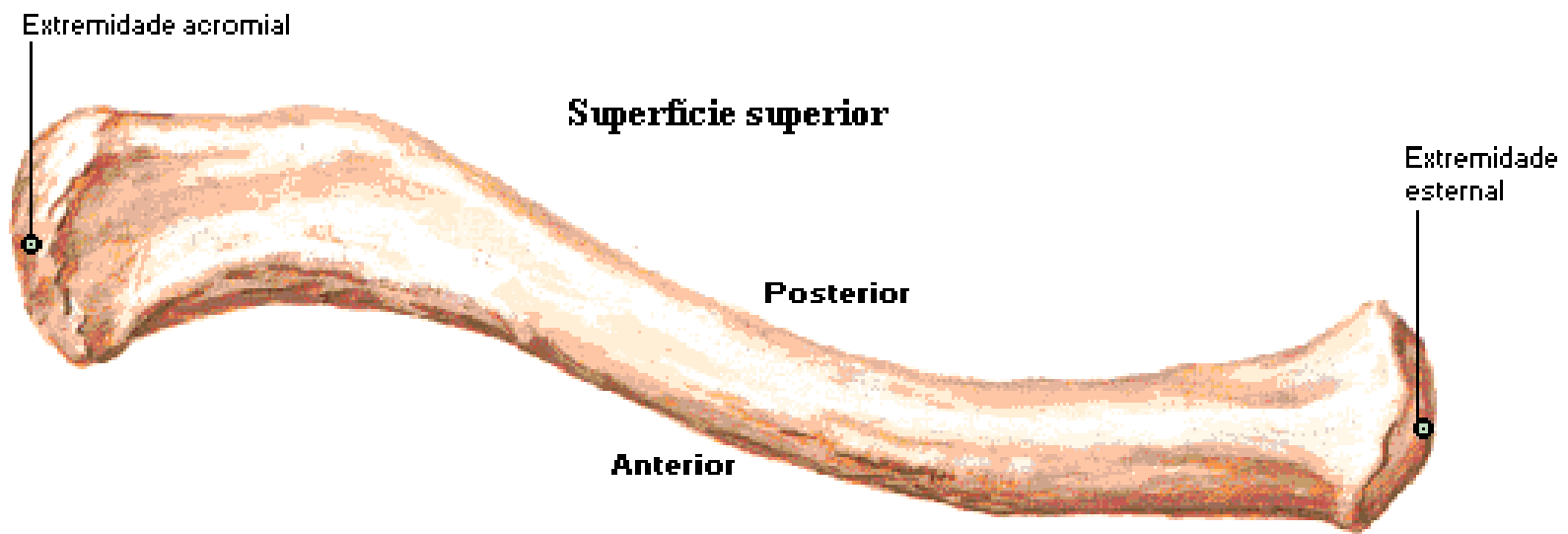


Homólogos dos Órgãos Genitais Internos

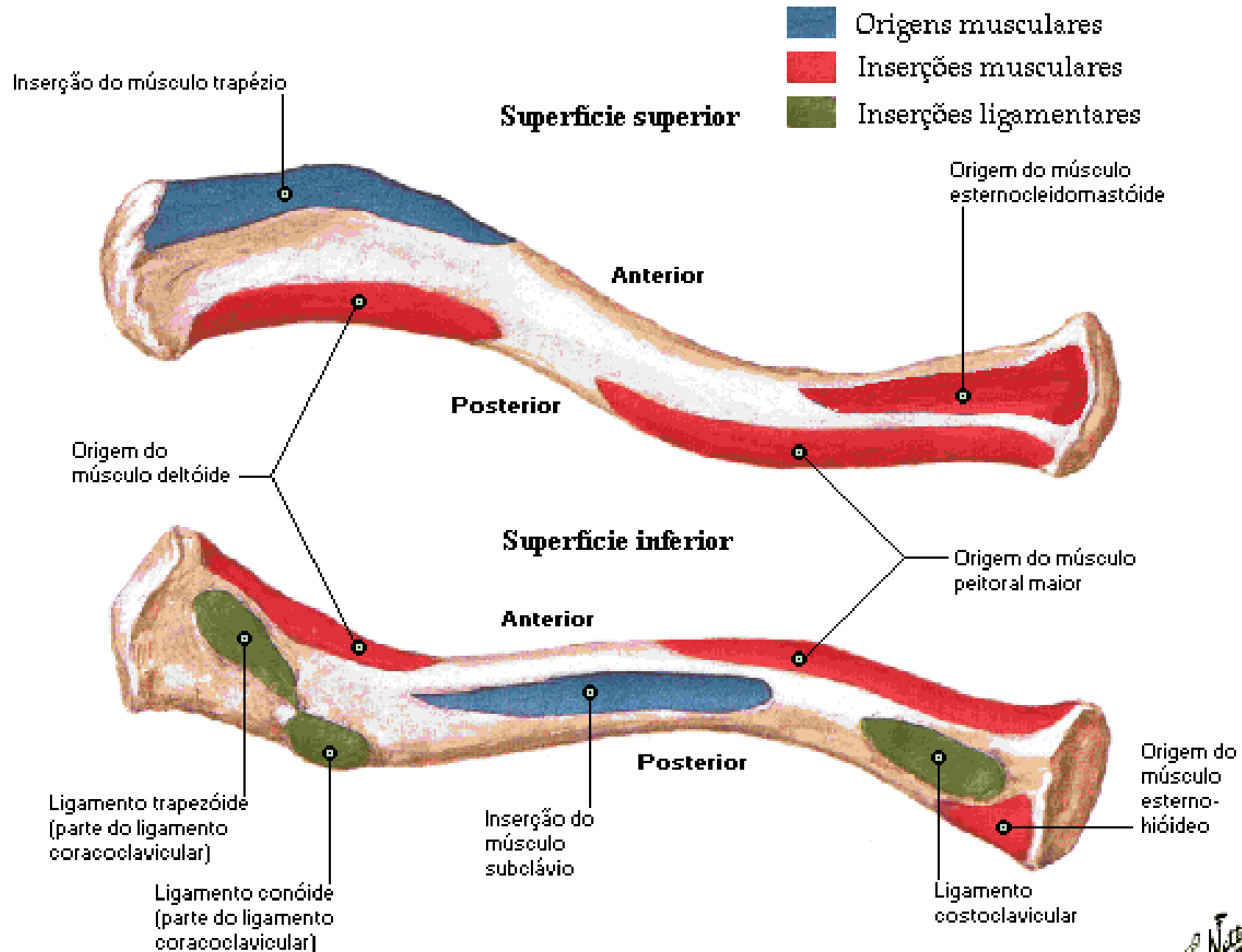
Sexos Masculino e Feminino Totalmente Desenvolvidos



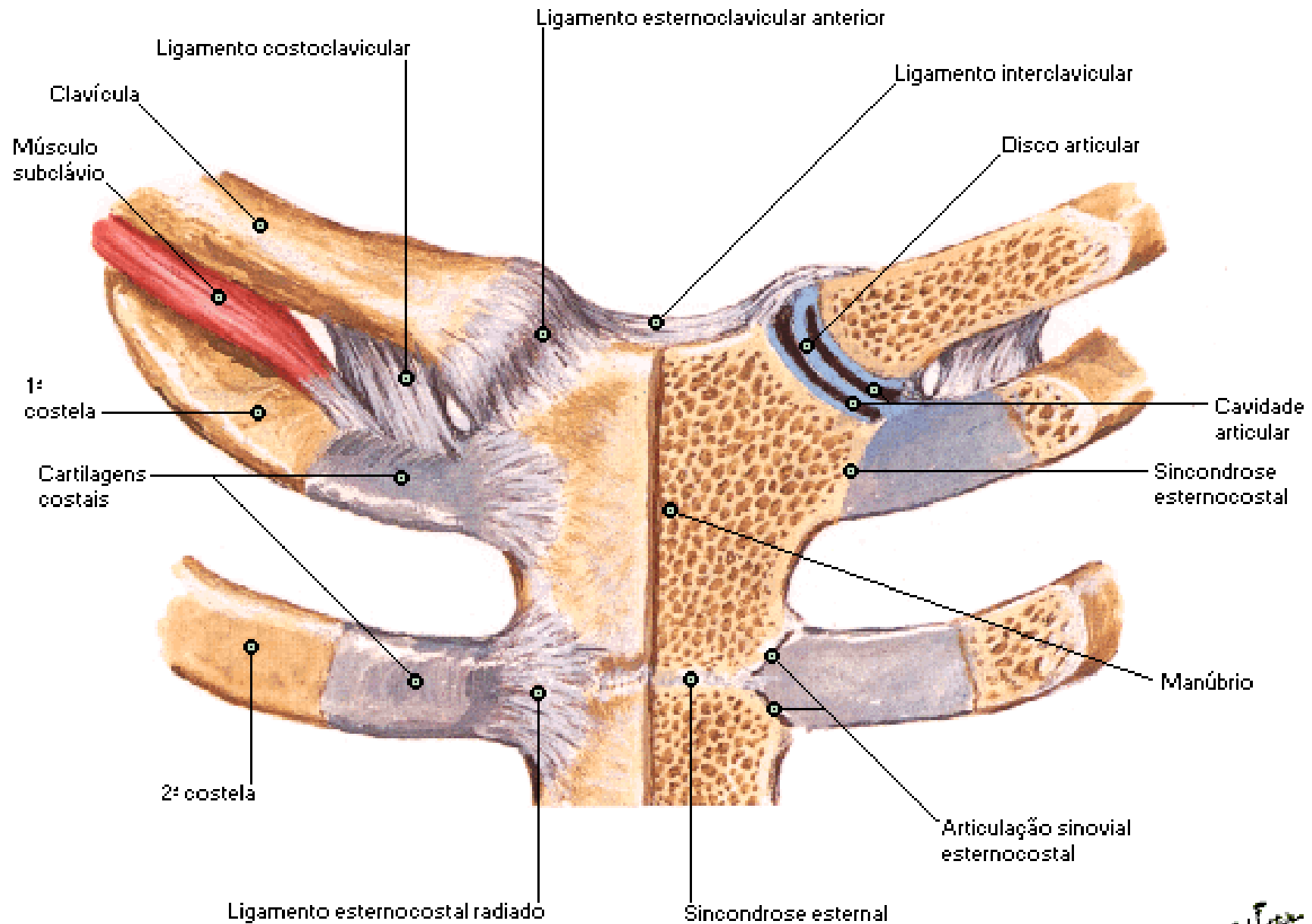
Clavícula Direita



Clavícula Direita

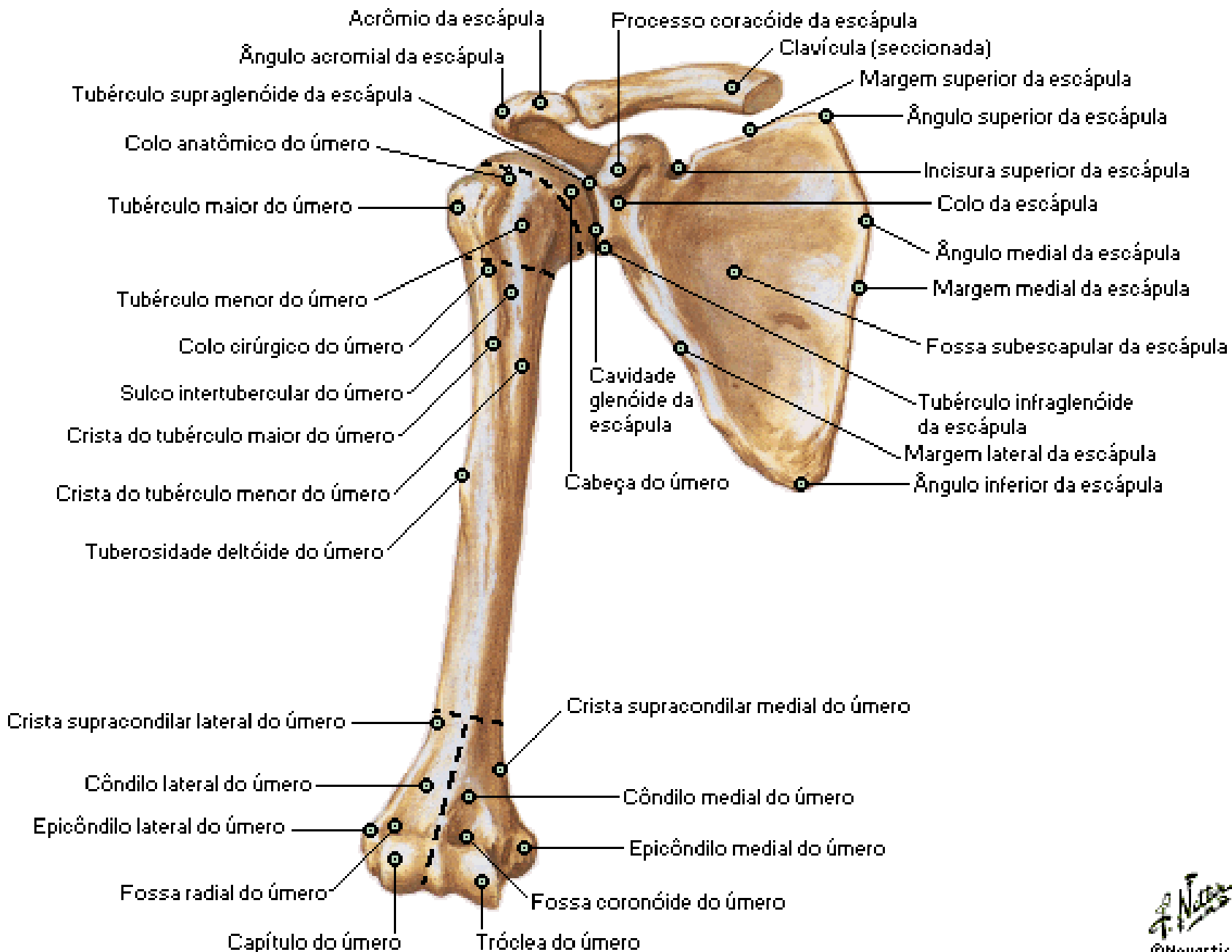


Articulação Esternoclavicular



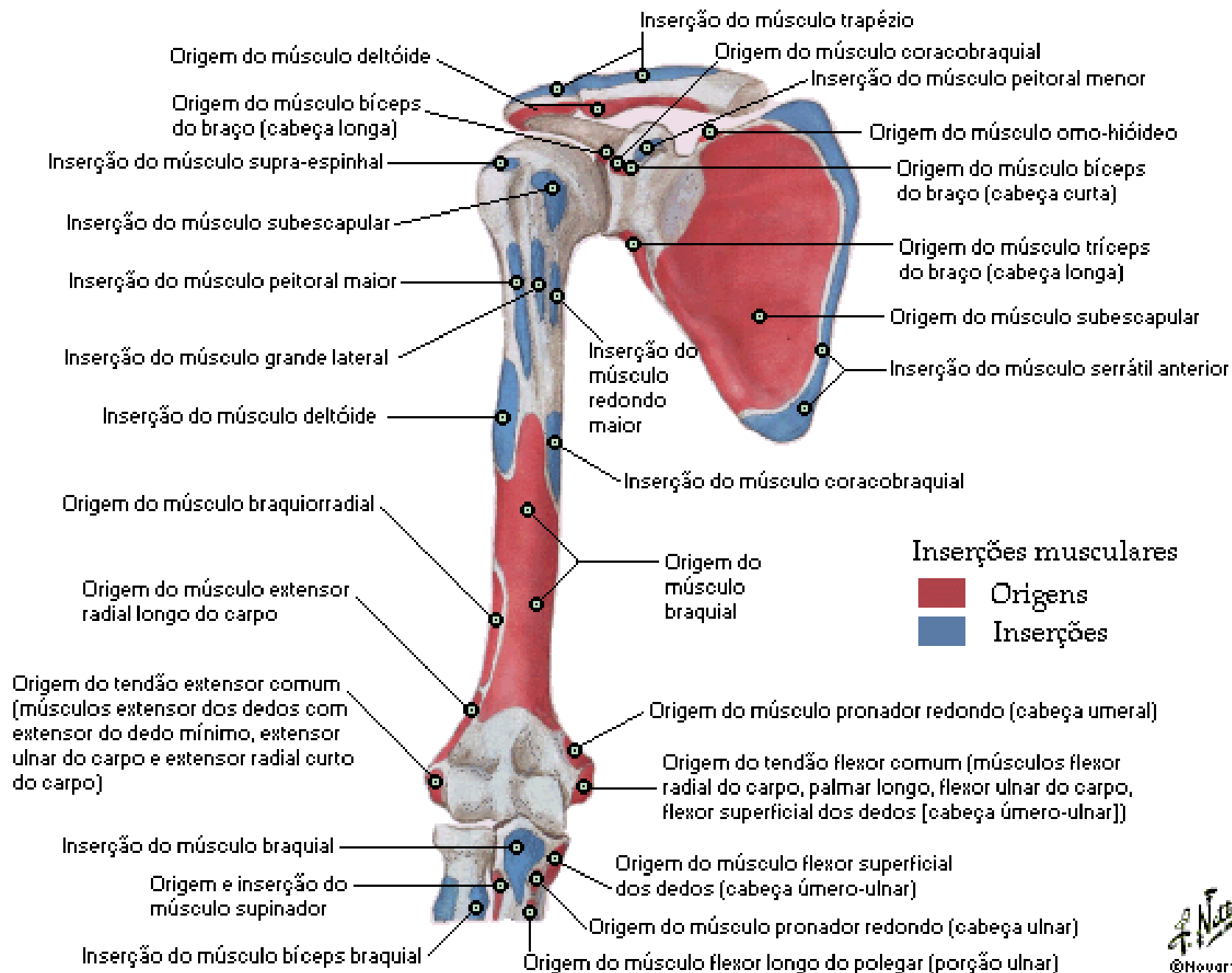
Úmero e Escápula

Vista Anterior



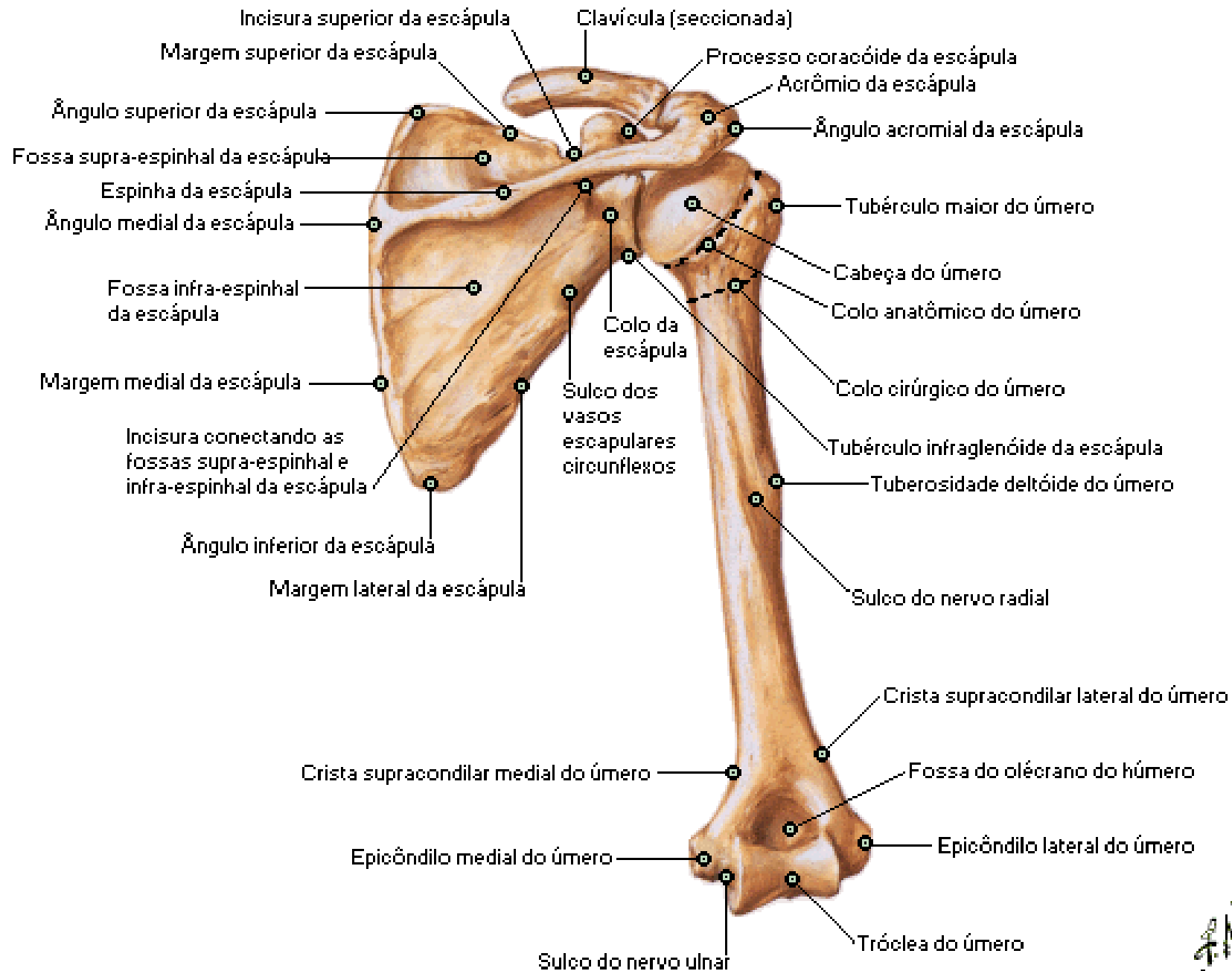
Úmero e Escápula

Vista Anterior



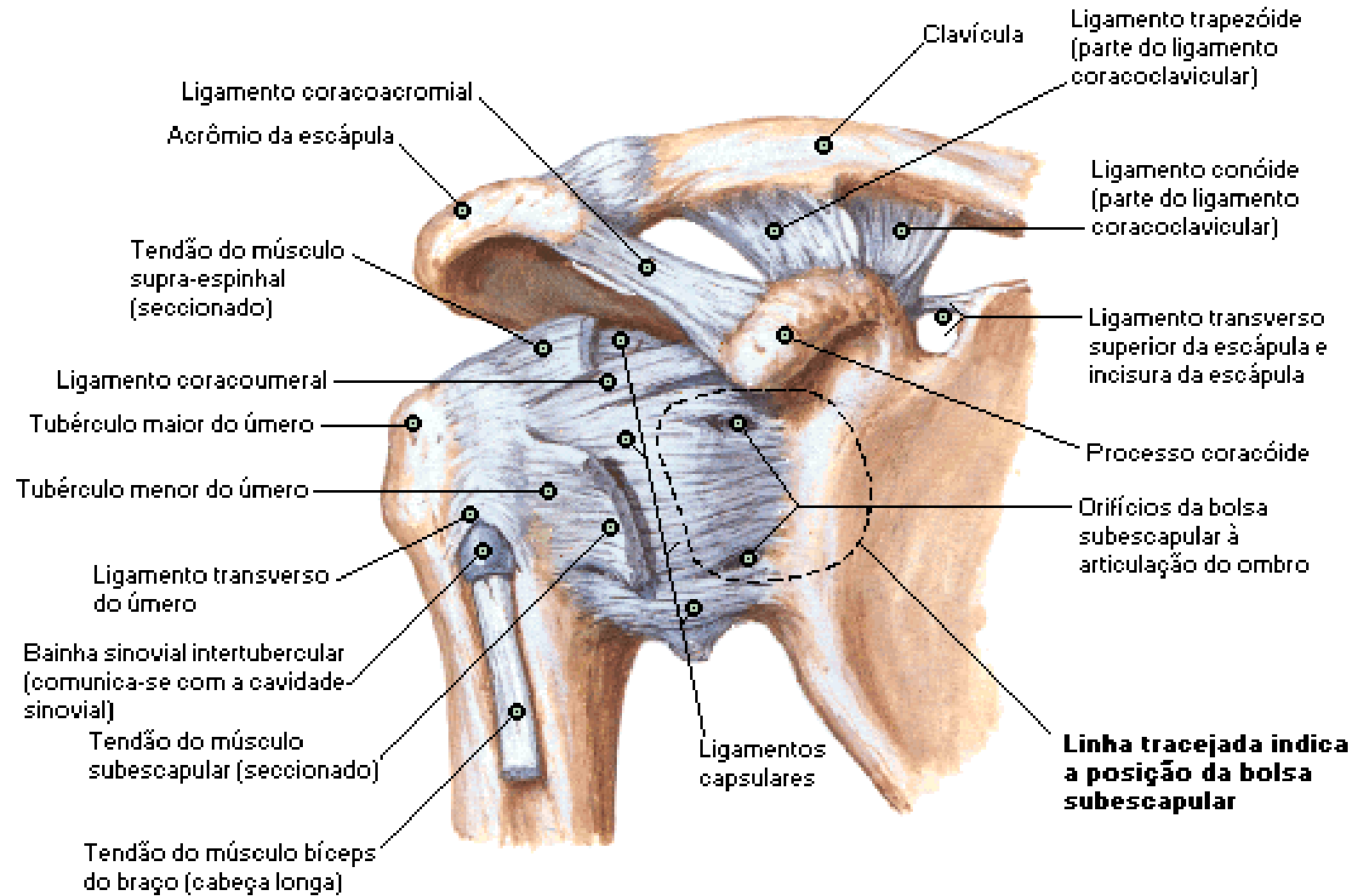
Úmero e Escápula

Vista Posterior



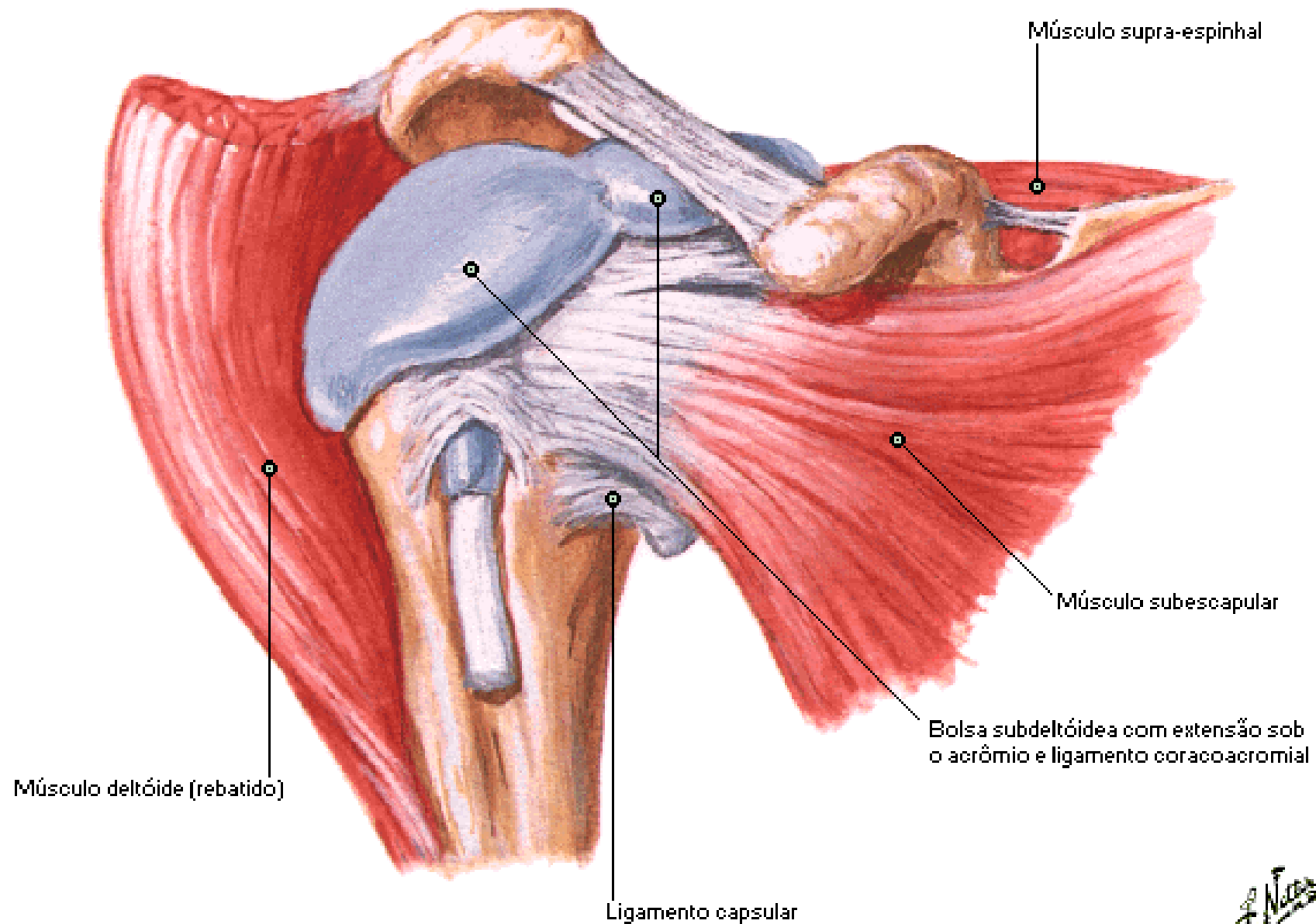
Articulação Glenoumeral

Vista Anterior - Tendões e Ligamentos



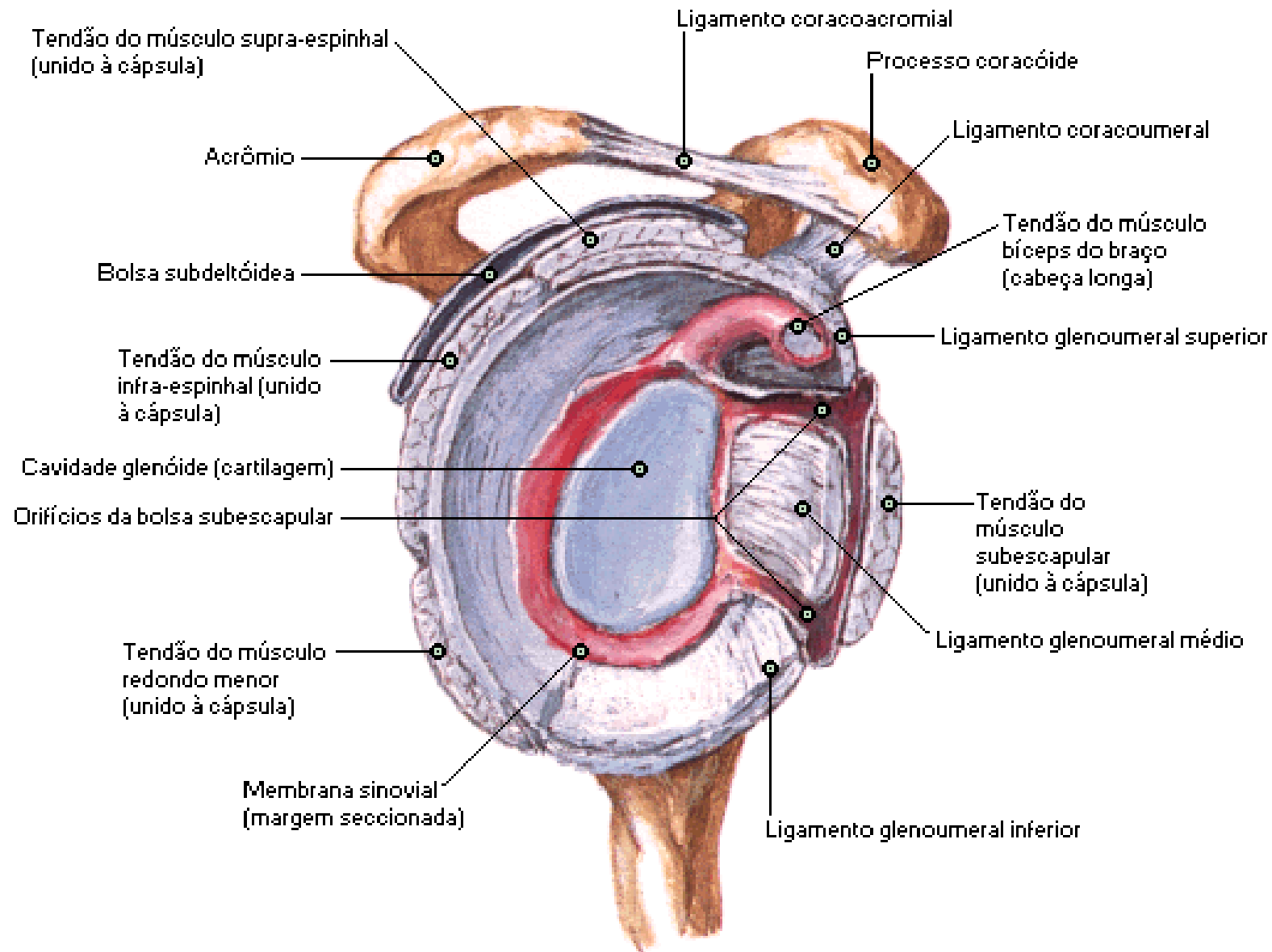
Articulação Glenoumeral

Vista Anterior



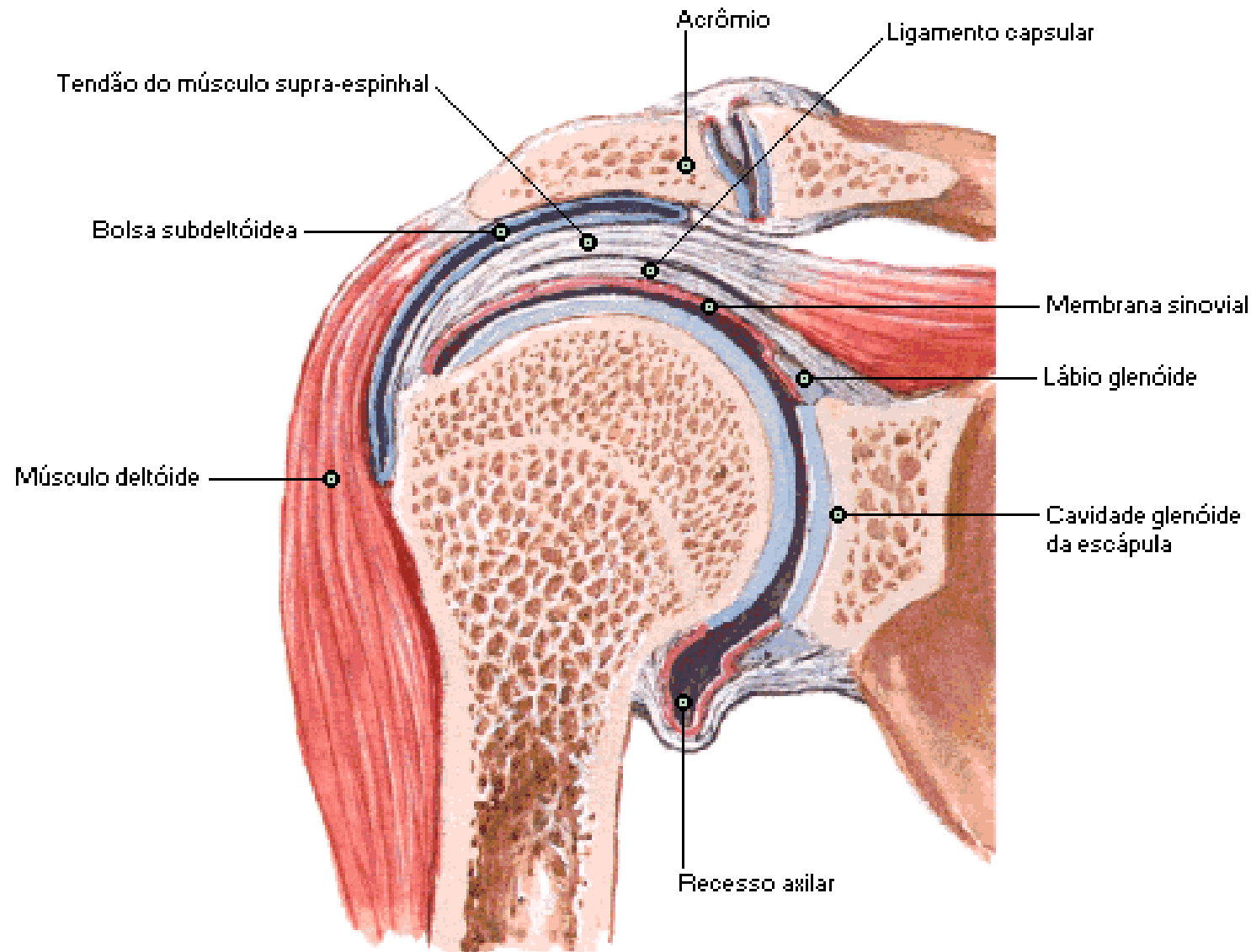
Articulação Glenoumeral [Aberta]

Vista Lateral



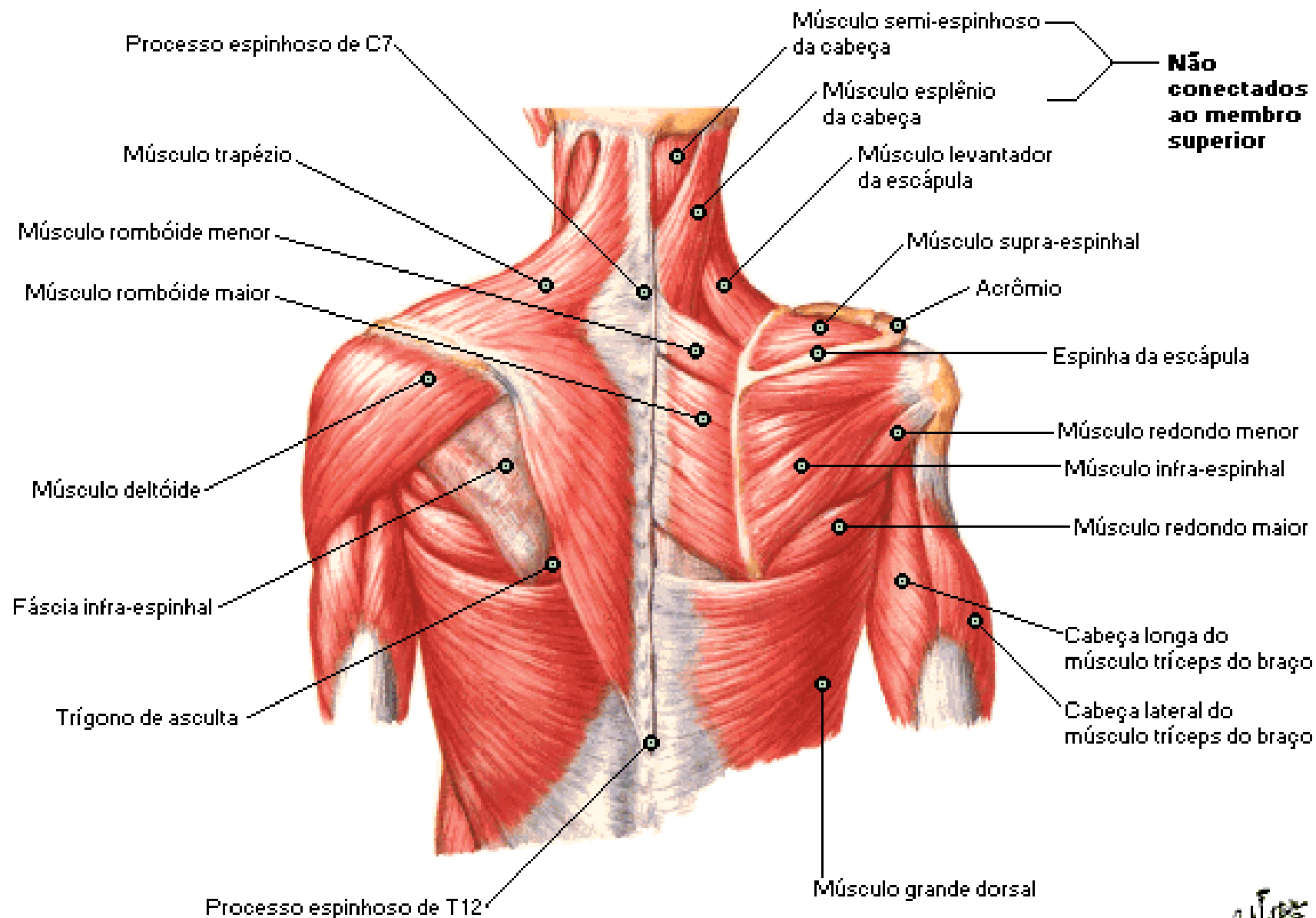
Articulação Glenoumeral

Secção Coronal Através da Articulação



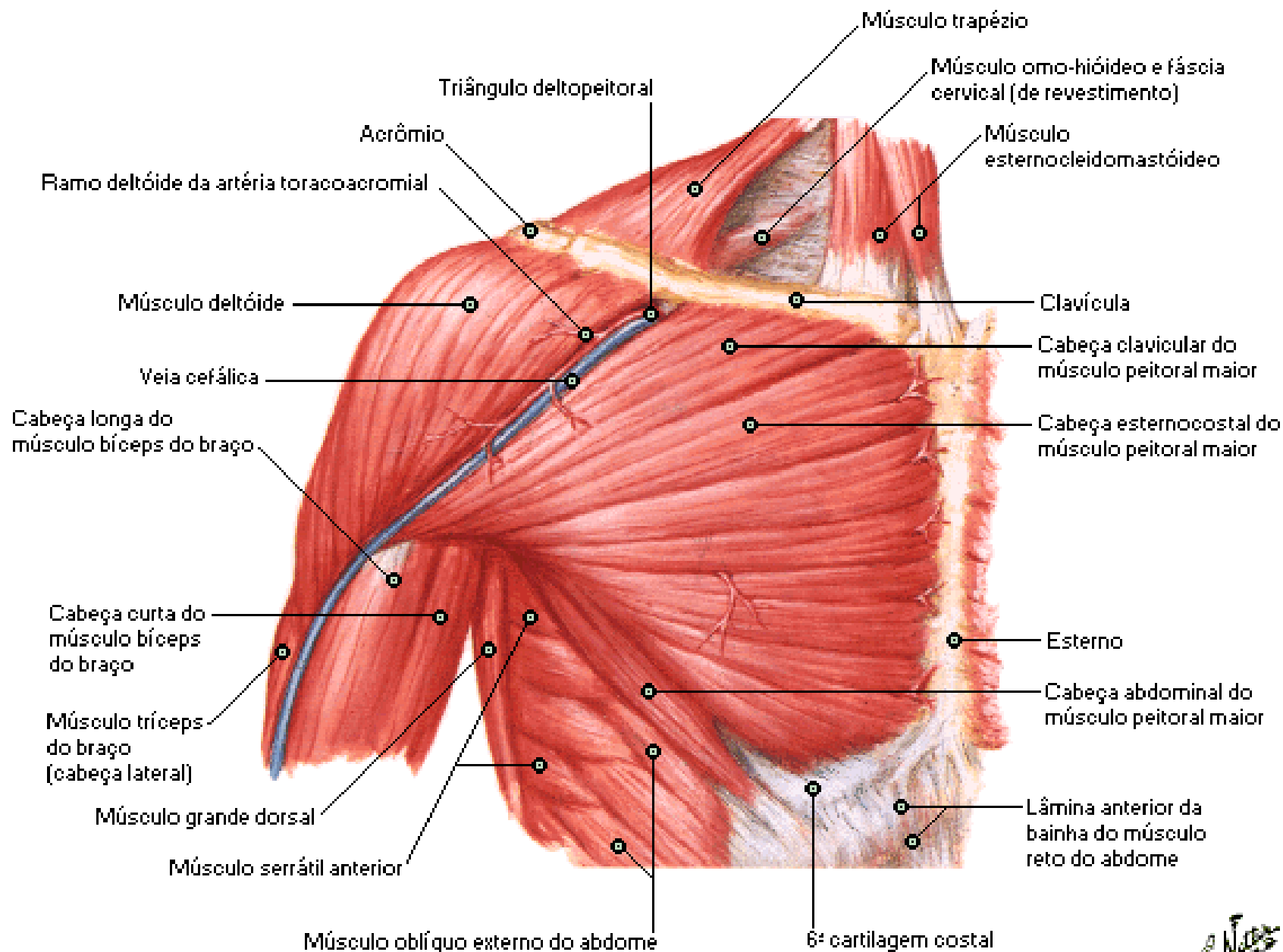
Músculos do Ombro

Vista Posterior



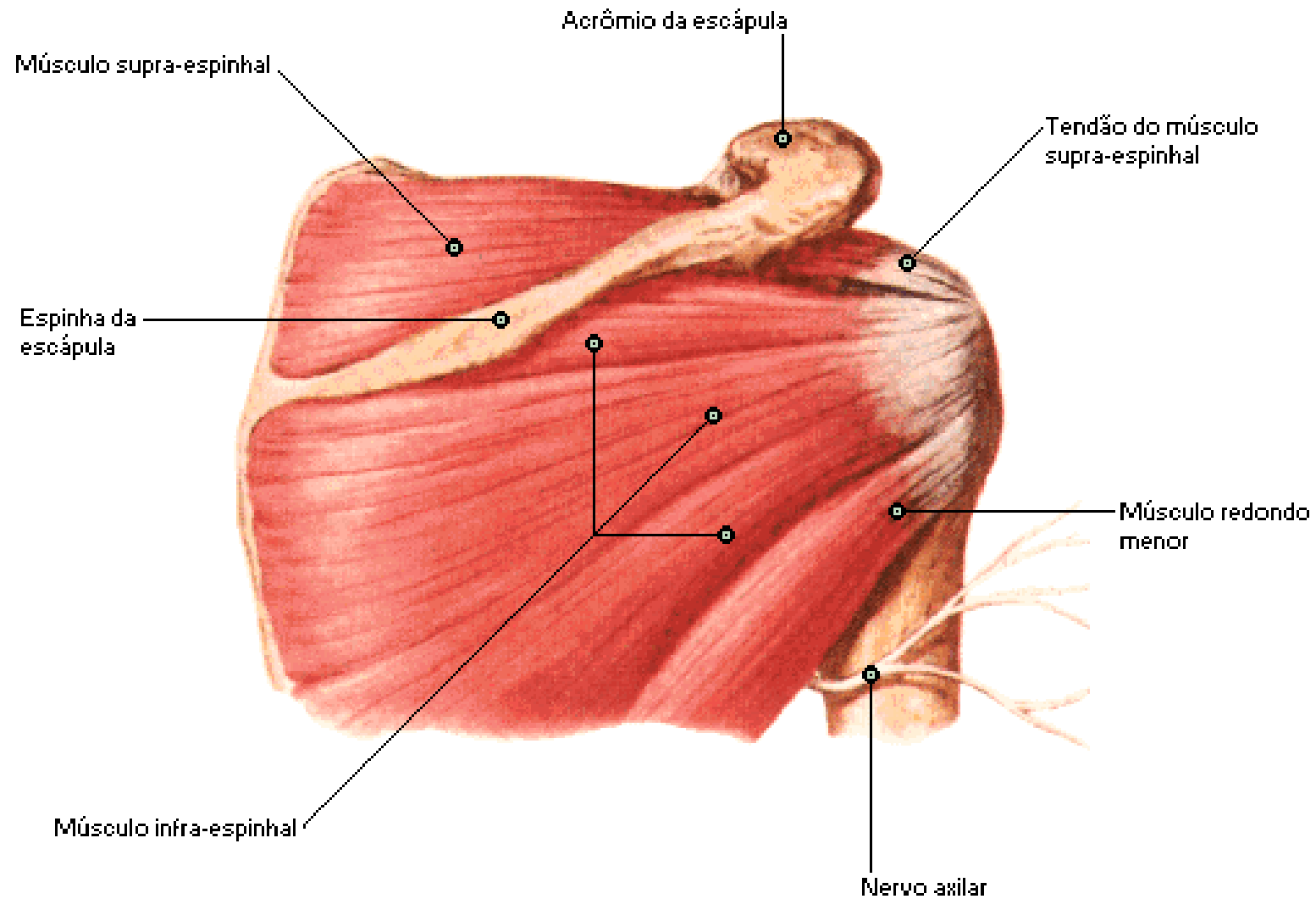
Músculos do Ombro

Vista Anterior



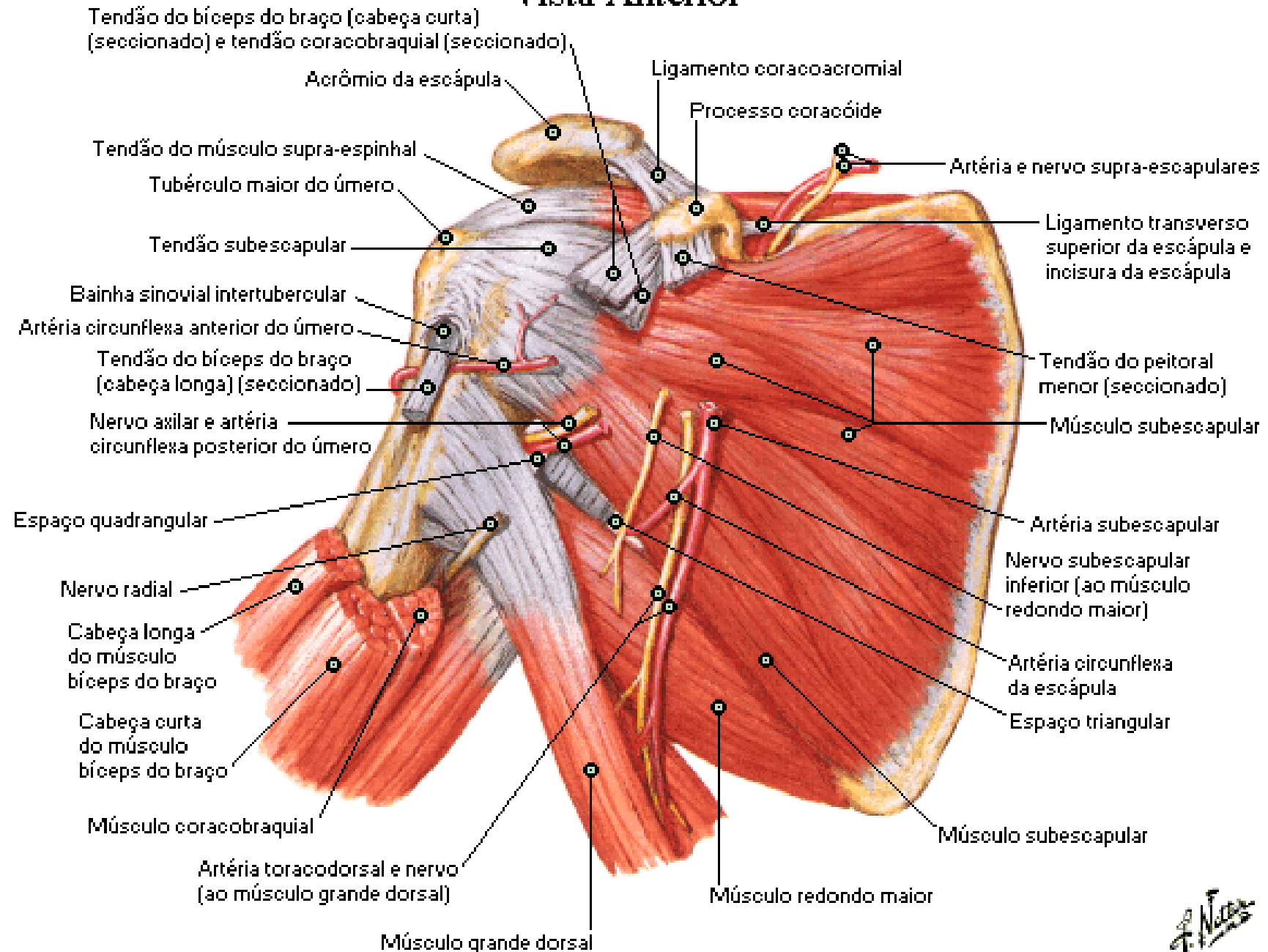
Músculos do Manguito Rotador

Vista Posterior



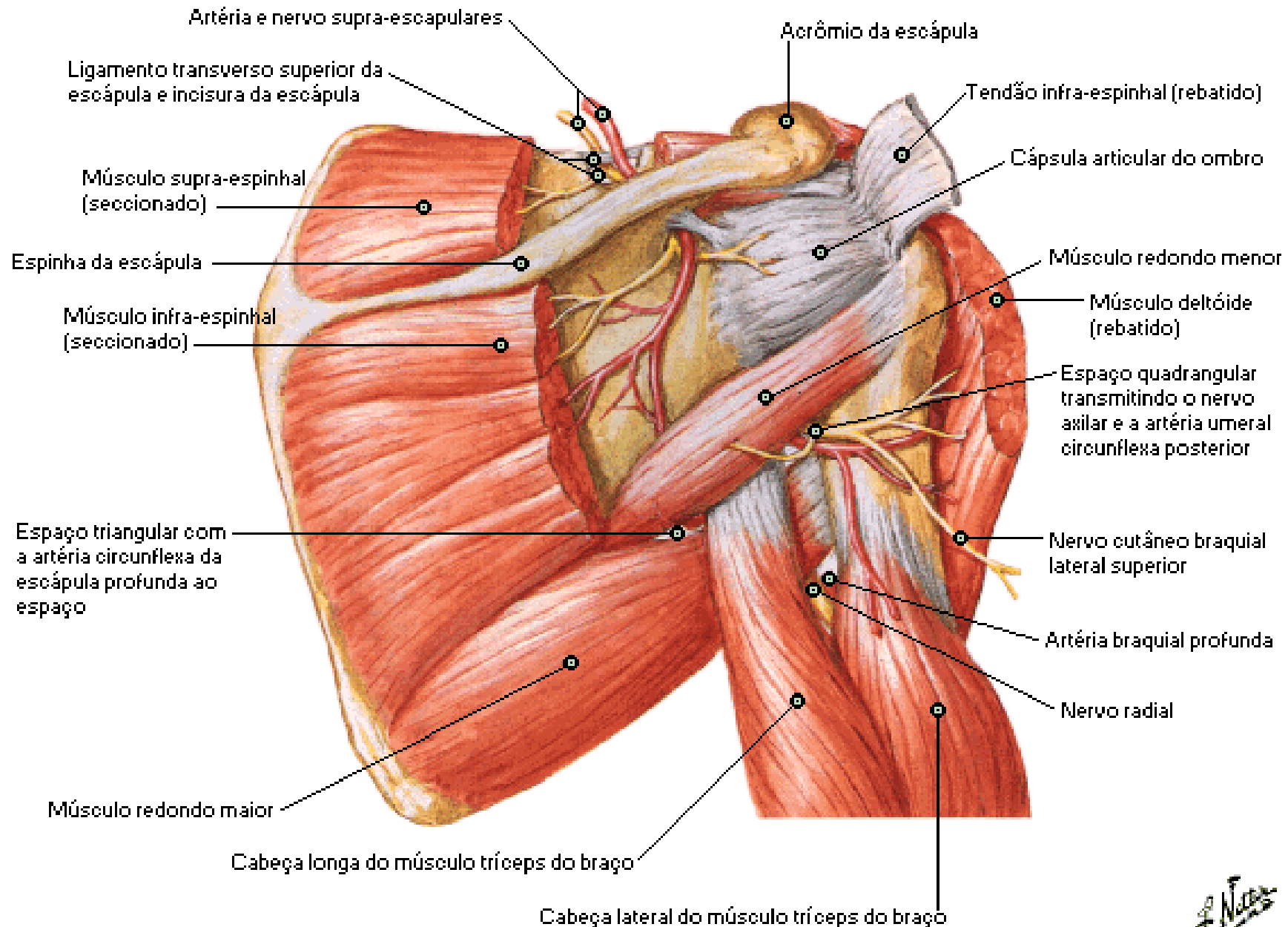
Dissecação Escapuloumeral

Vista Anterior



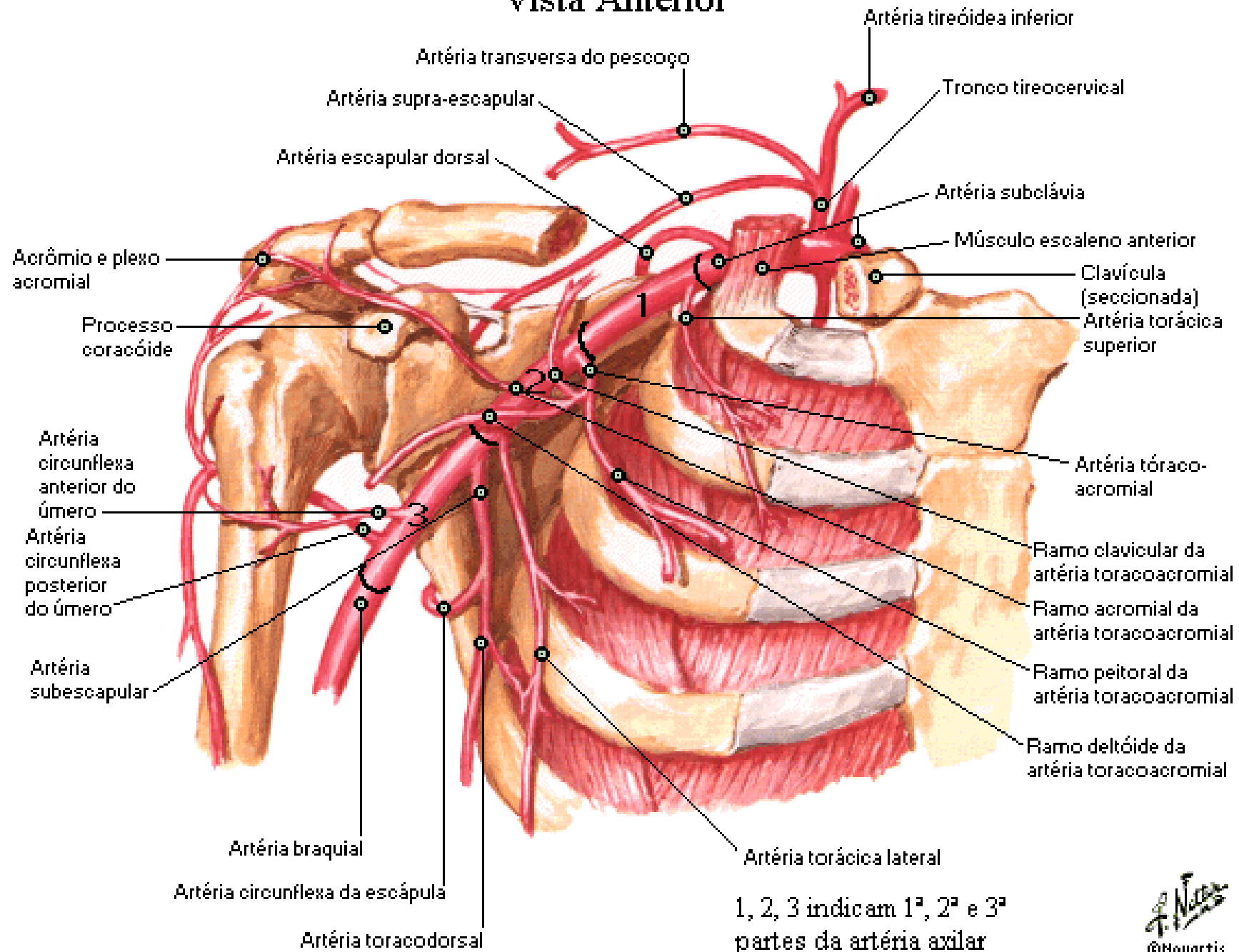
Dissecação Escapuloumeral

Vista Posterior



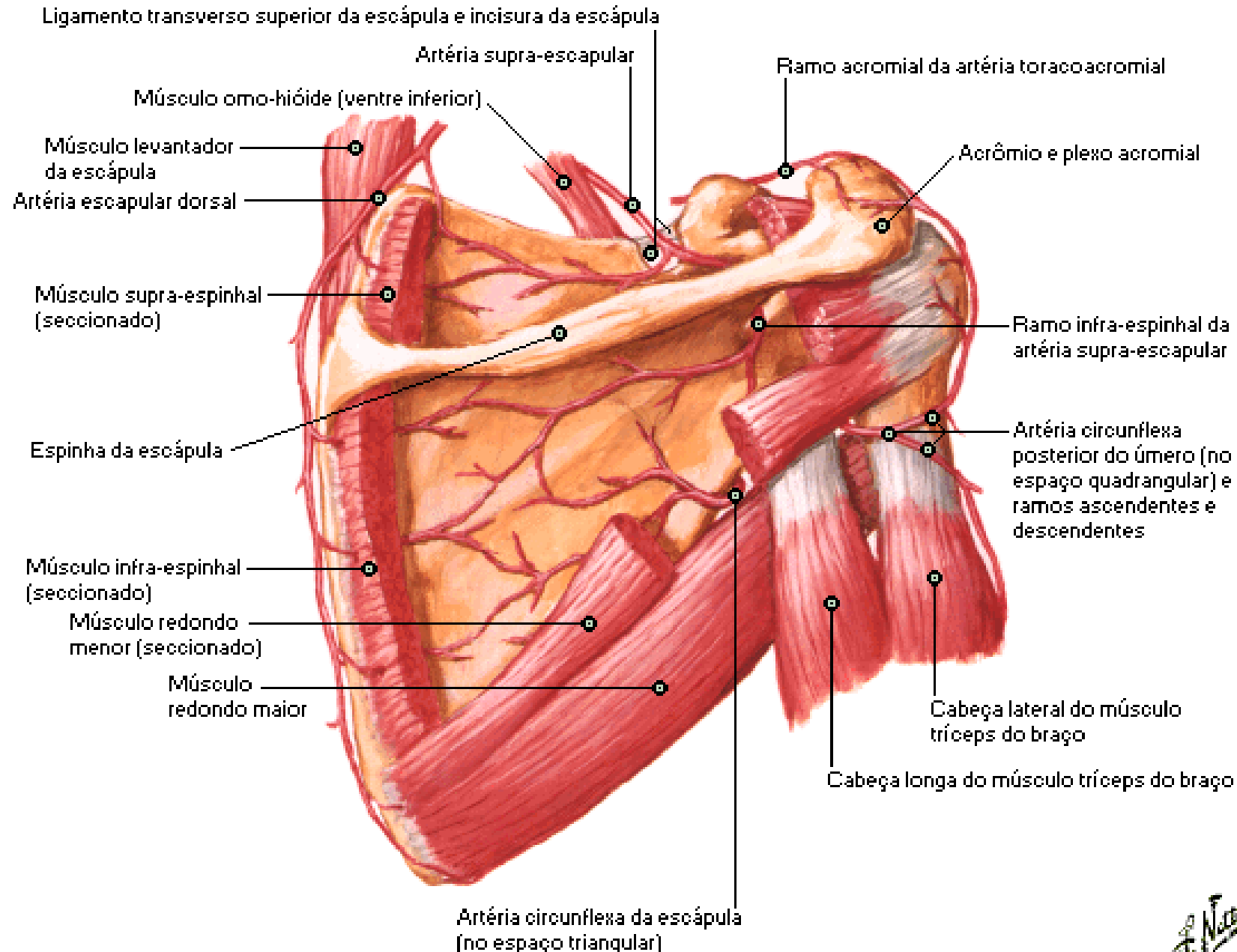
Artéria Axilar e Anastomoses ao Redor da Escápula

Vista Anterior



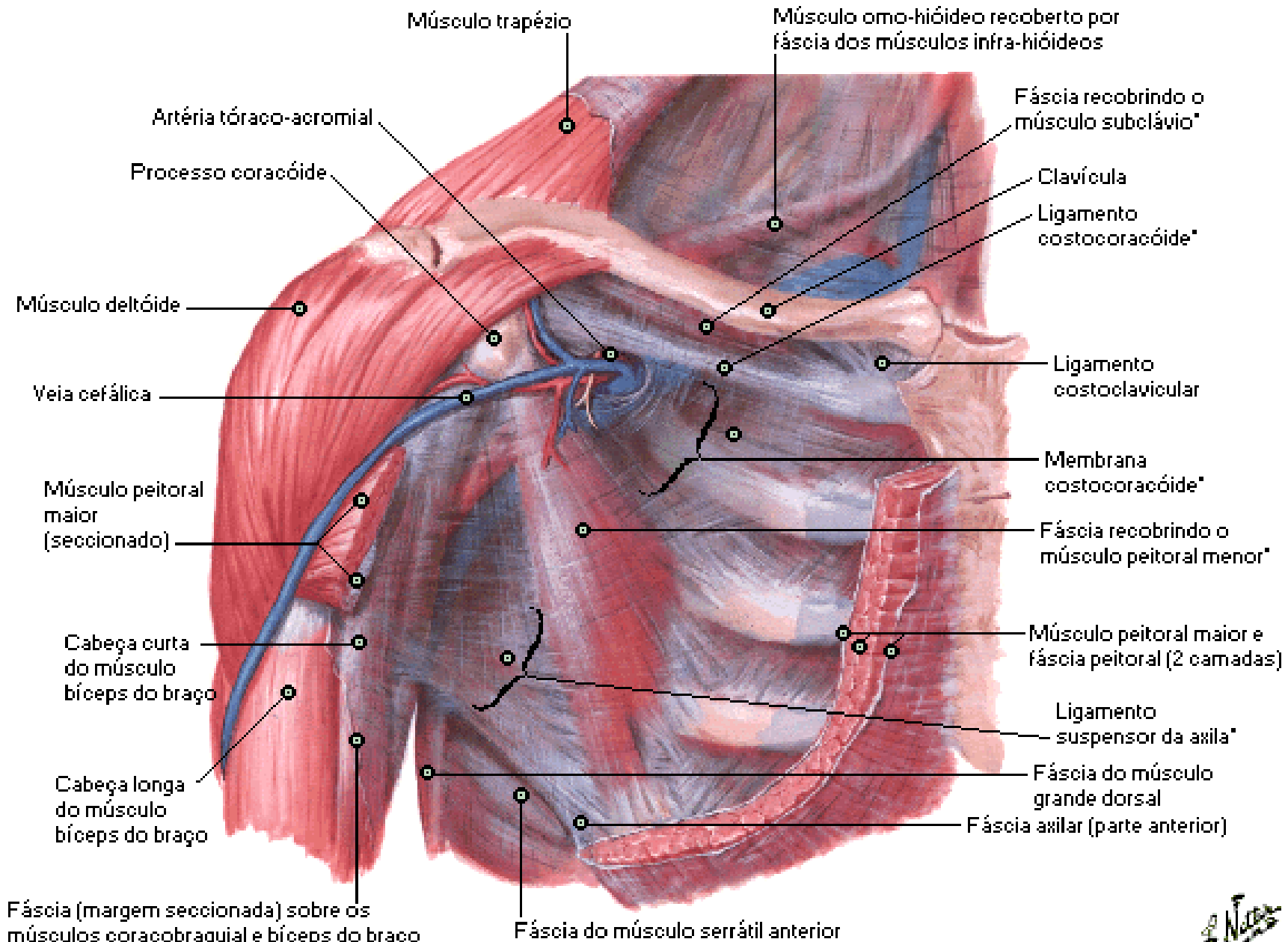
Artéria Axilar e Anastomoses ao Redor da Escápula

Vista Posterior



Fáscias Peitoral, Clavipeitoral e Axilar

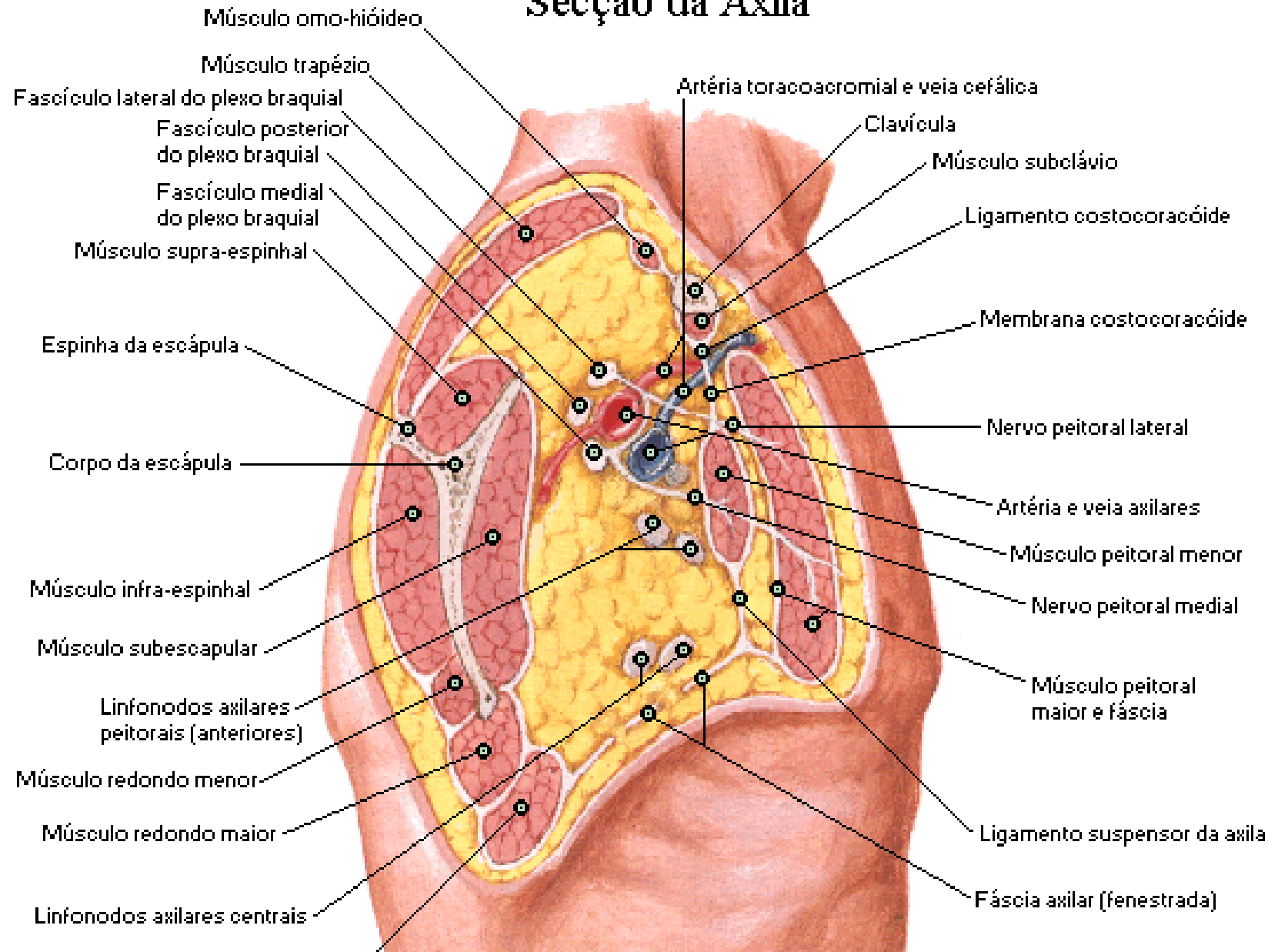
Vista Anterior



*Componentes da fáscia clavipeitoral

Fáscias Peitoral, Clavipeitoral e Axilar

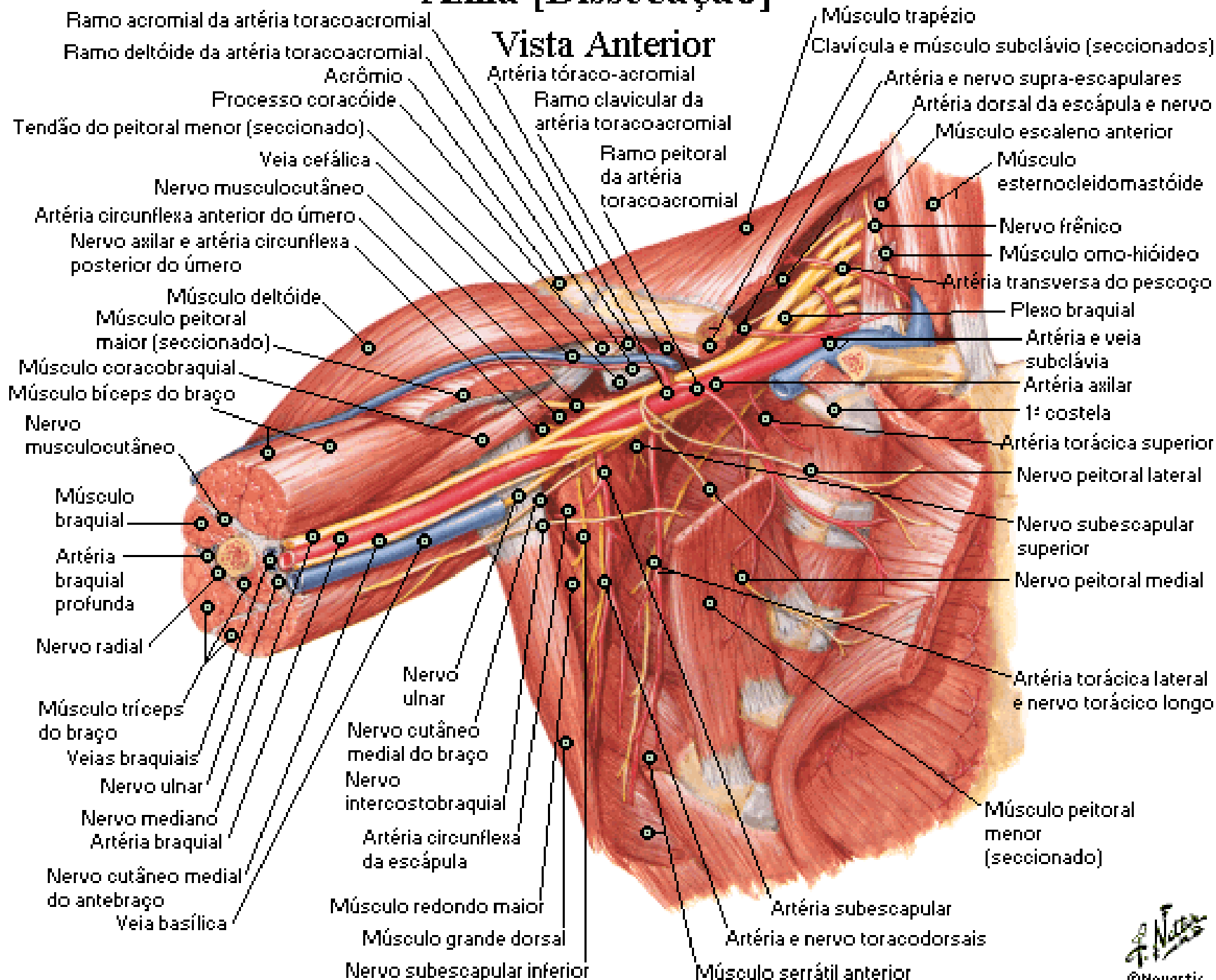
Secção da Axila



Secção oblíqua parassagital

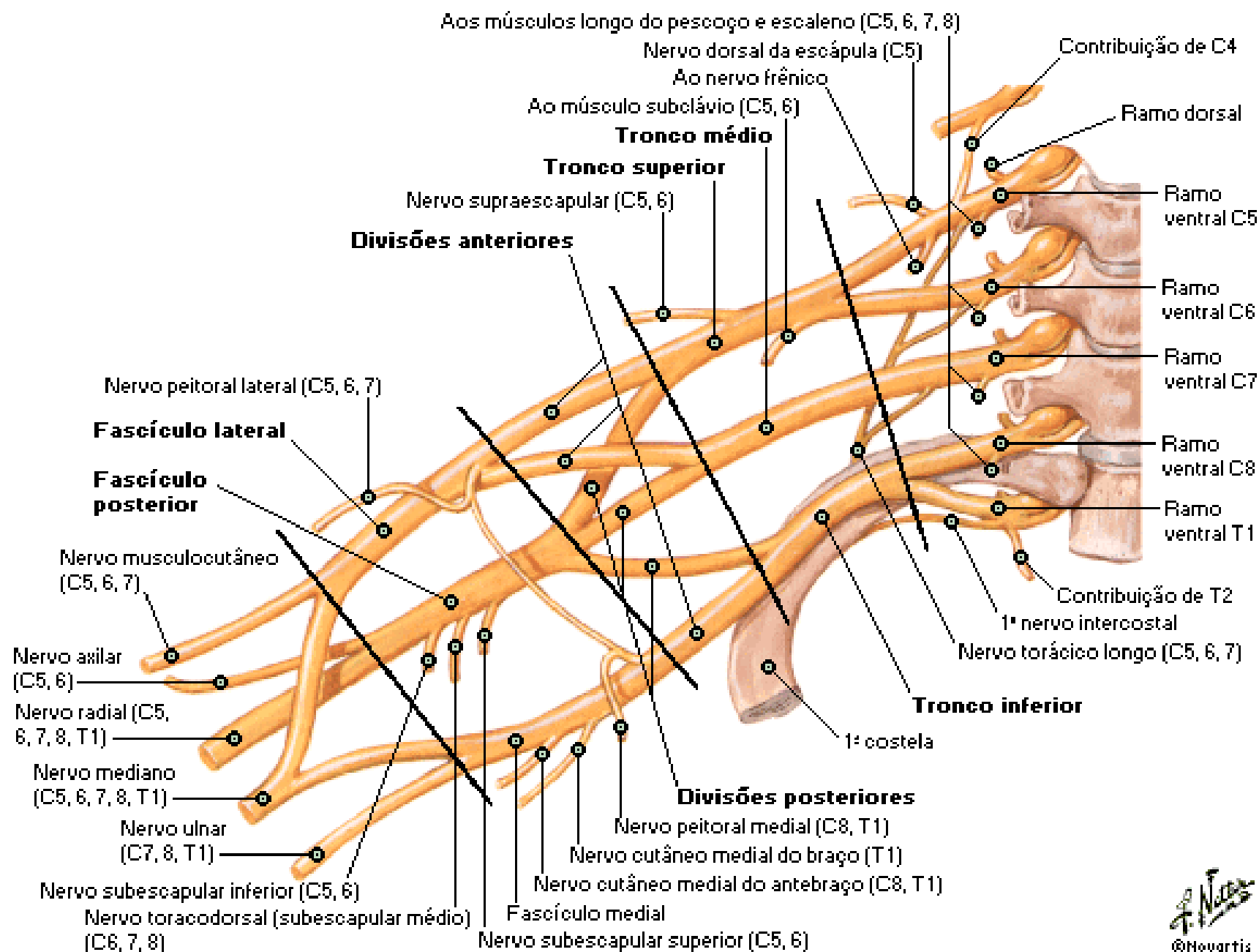
Axila [Dissecação]

Vista Anterior



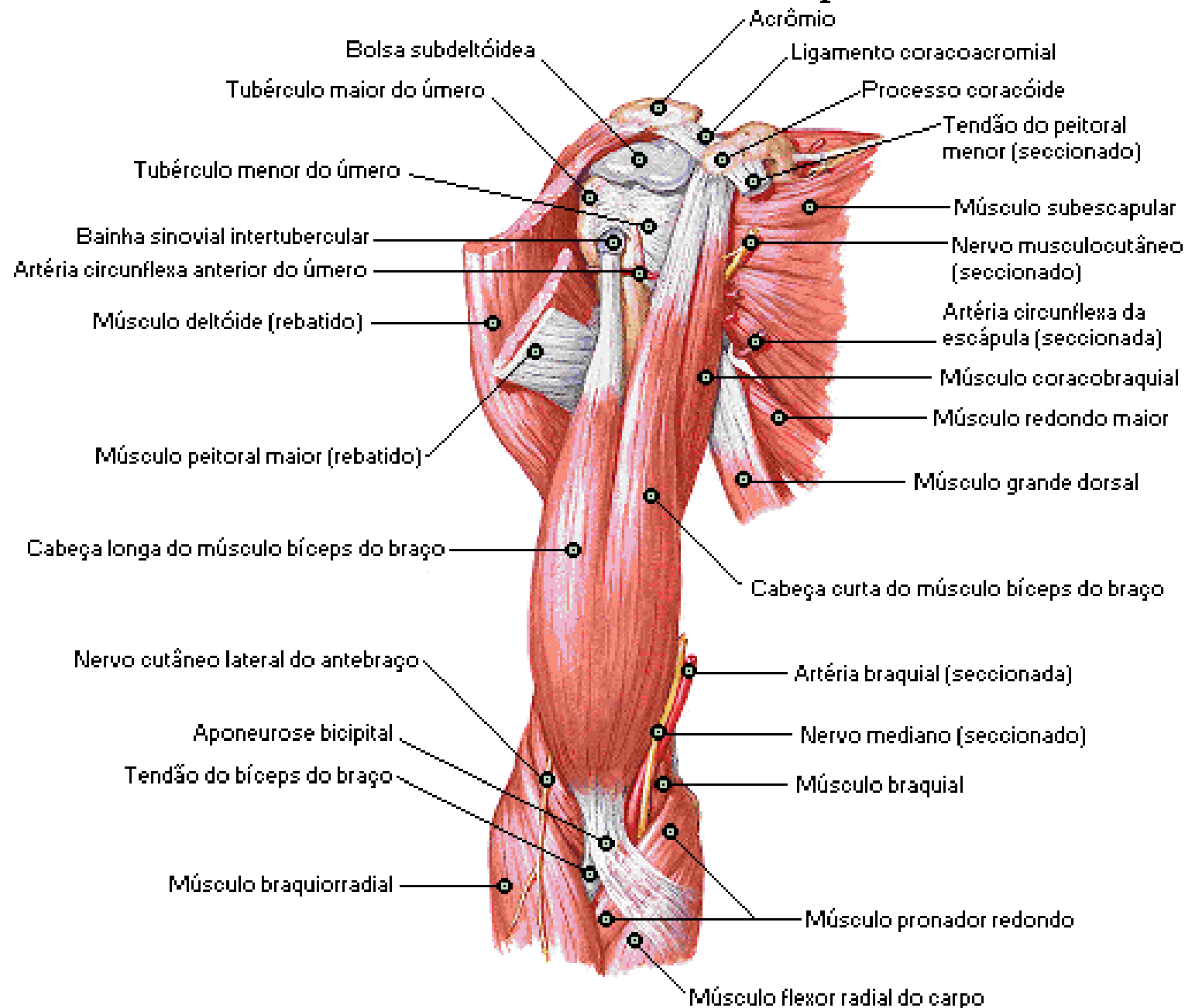
Plexo Braquial

Esquema



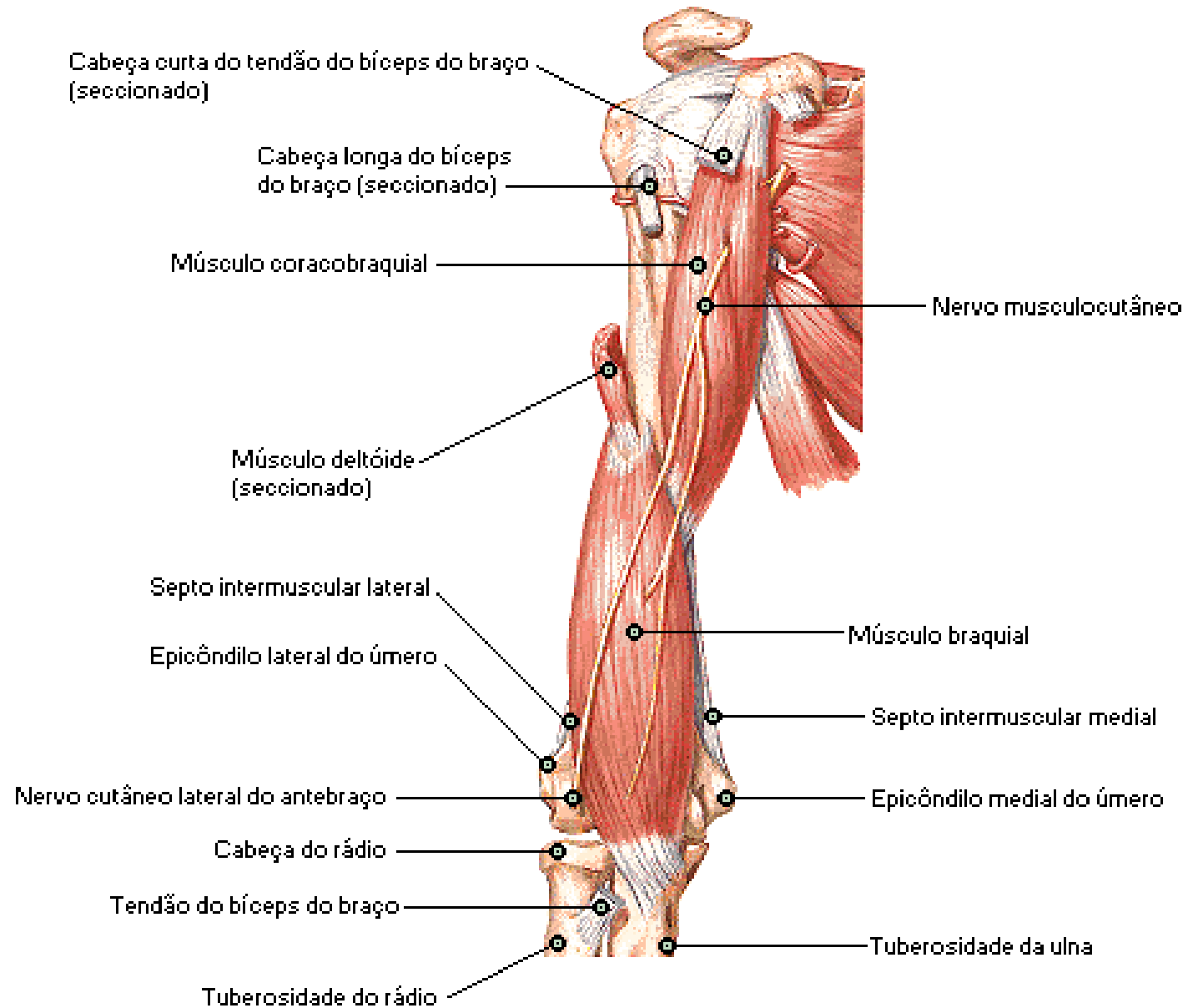
Músculos do Braço

Vista Anterior - Camada Superficial



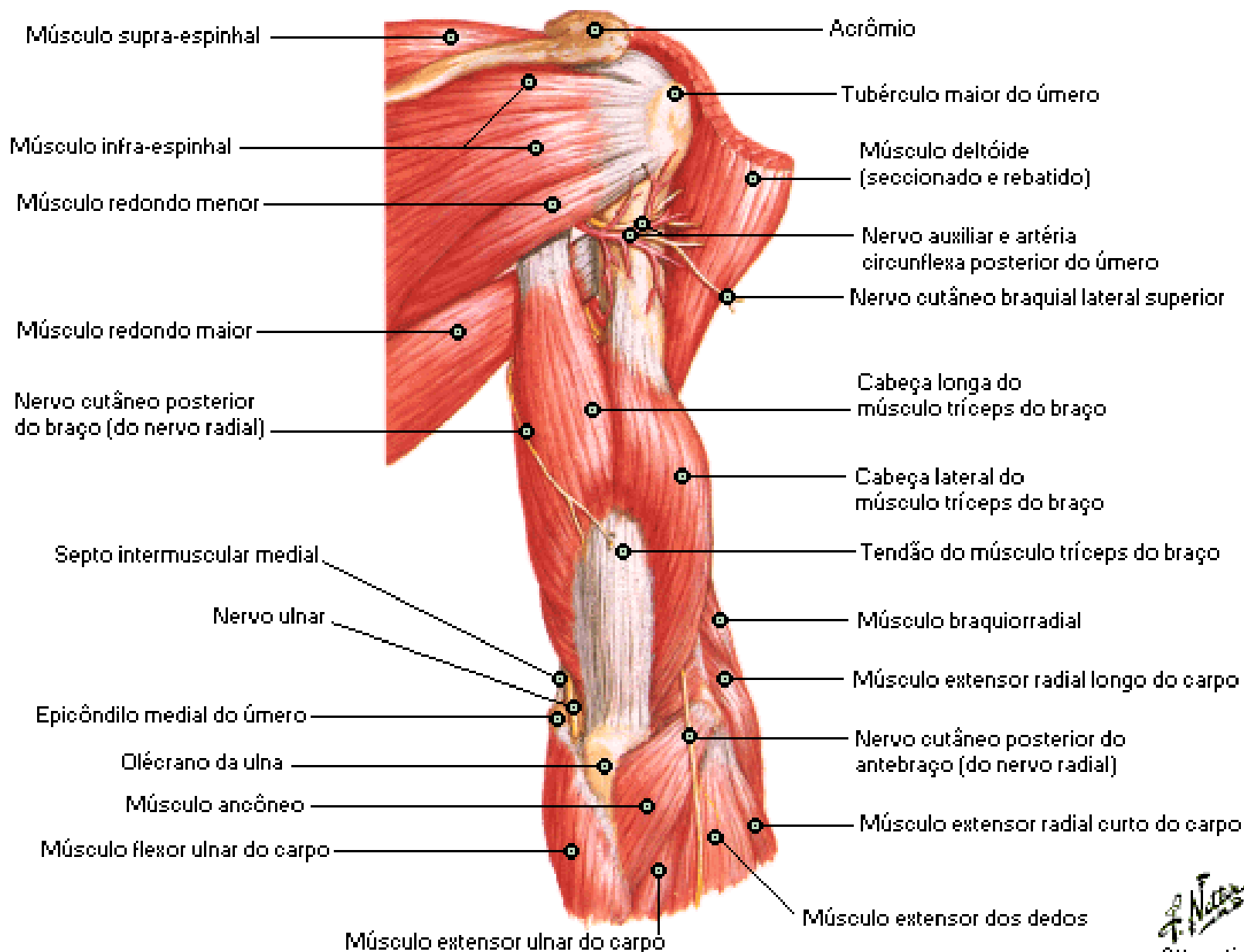
Músculos do Braço

Vista Anterior - Camada Profunda



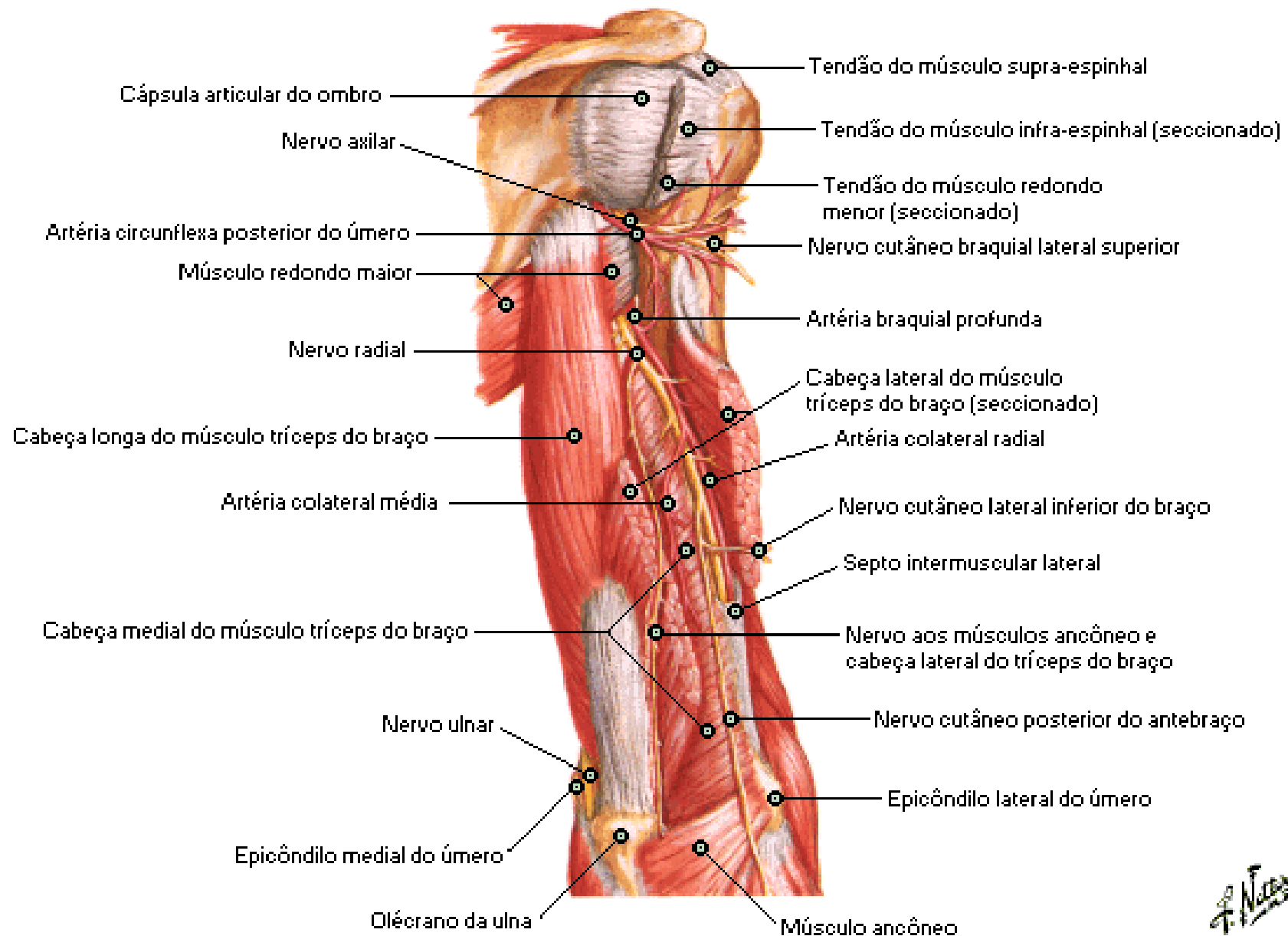
Músculos do Braço

Vista Posterior - Camada Superficial

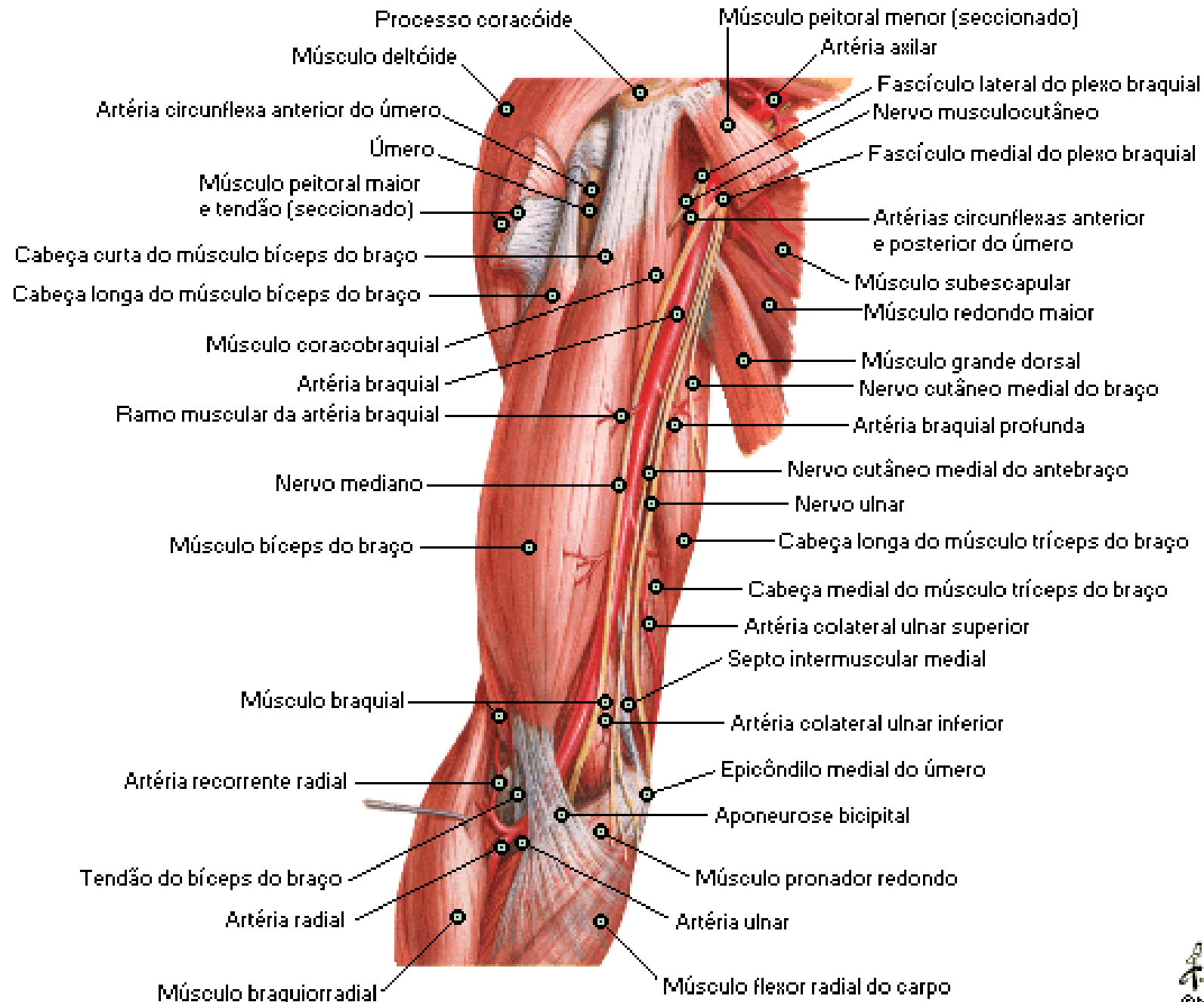


Músculos do Braço

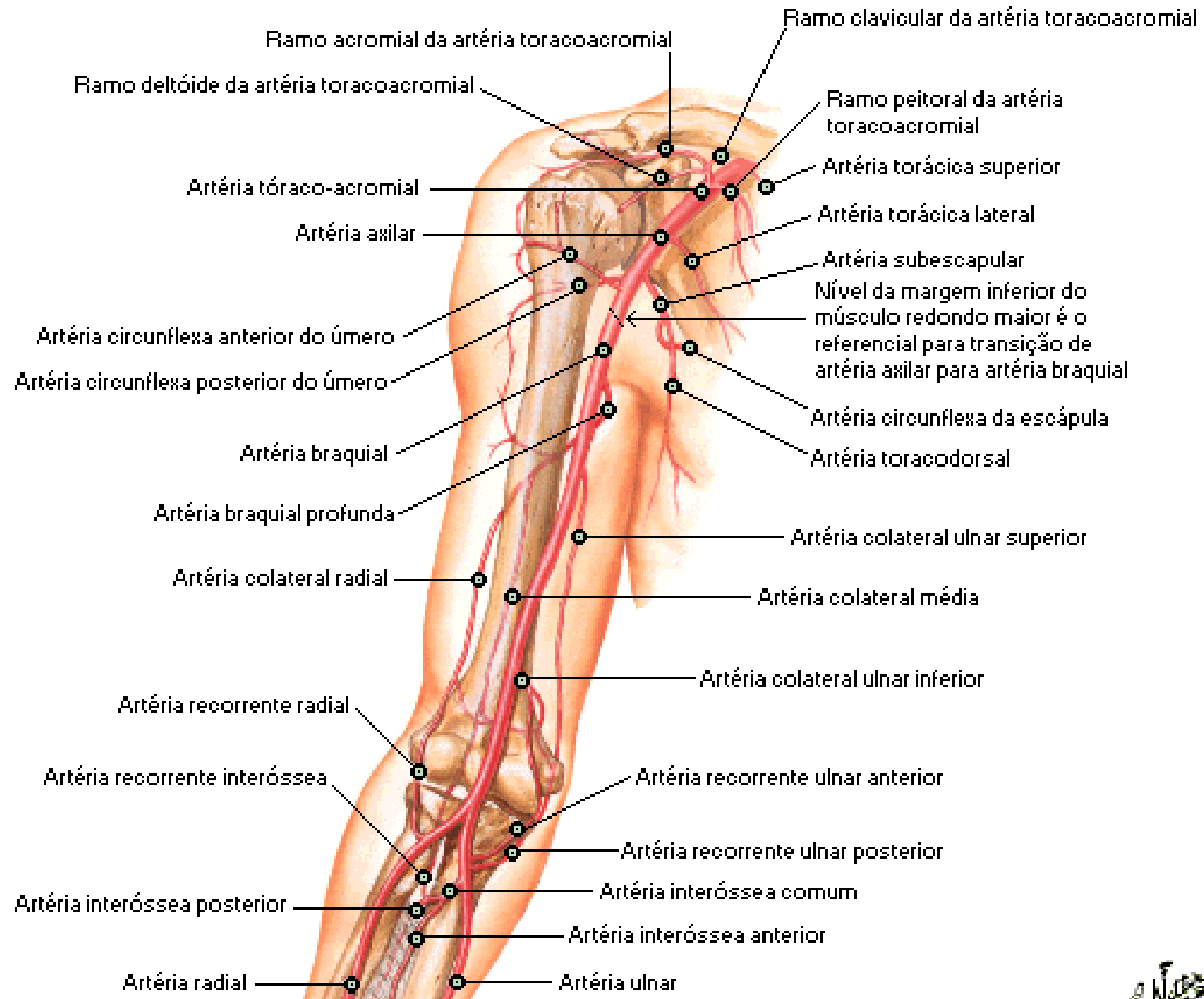Vista Posterior - Camada Profunda



Artéria Braquial in Situ

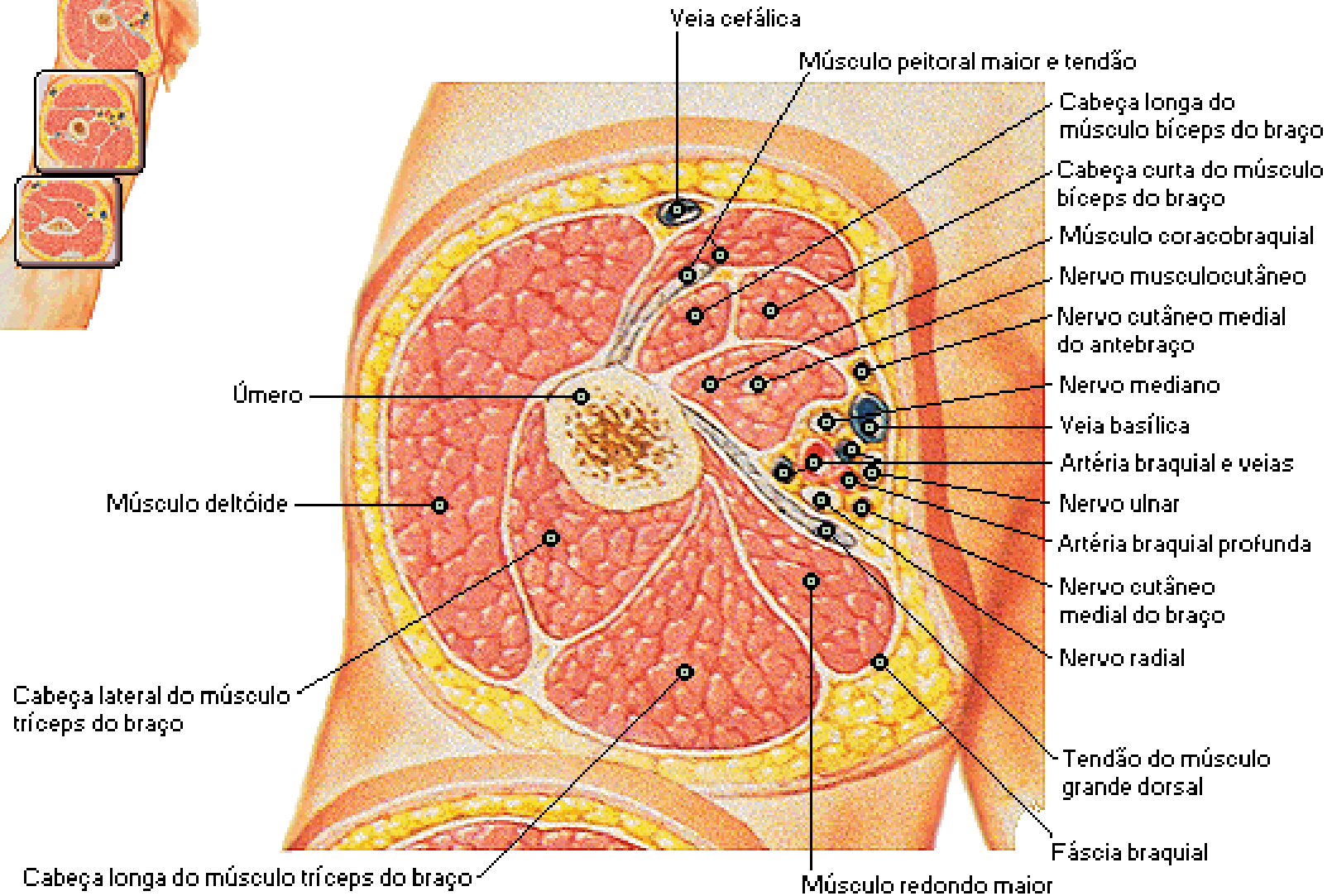
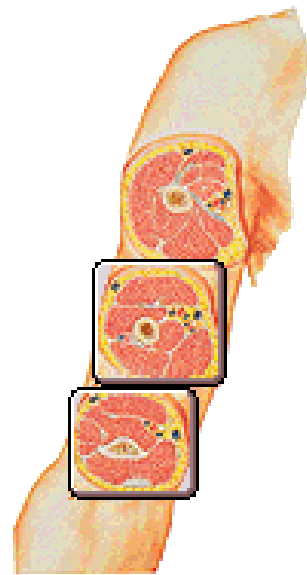

Artéria Braquial e Anastomoses ao Redor do Cotovelo



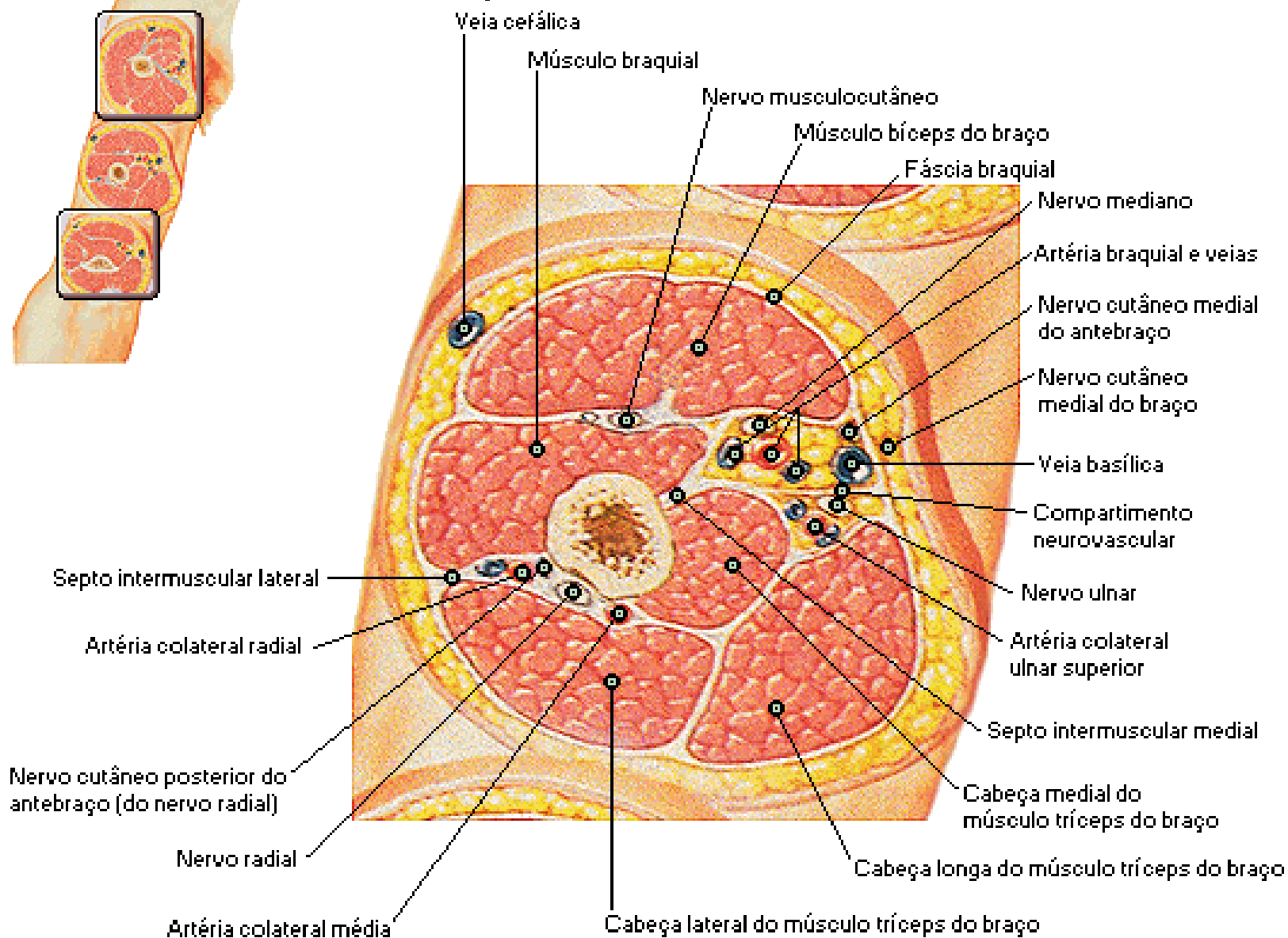
Braço

Secção Proximal Transversal



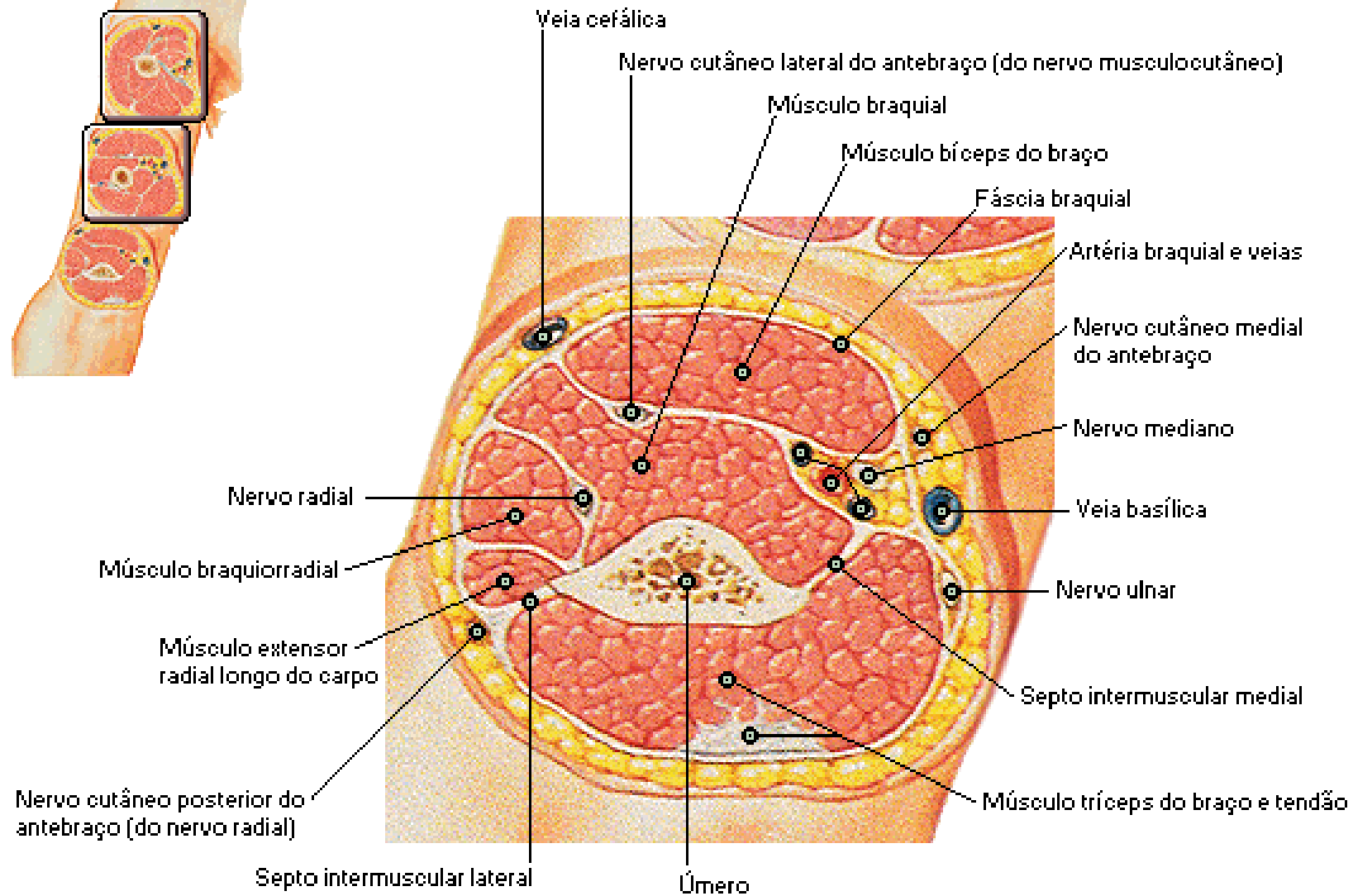
Braço

Secção Medial Transversal



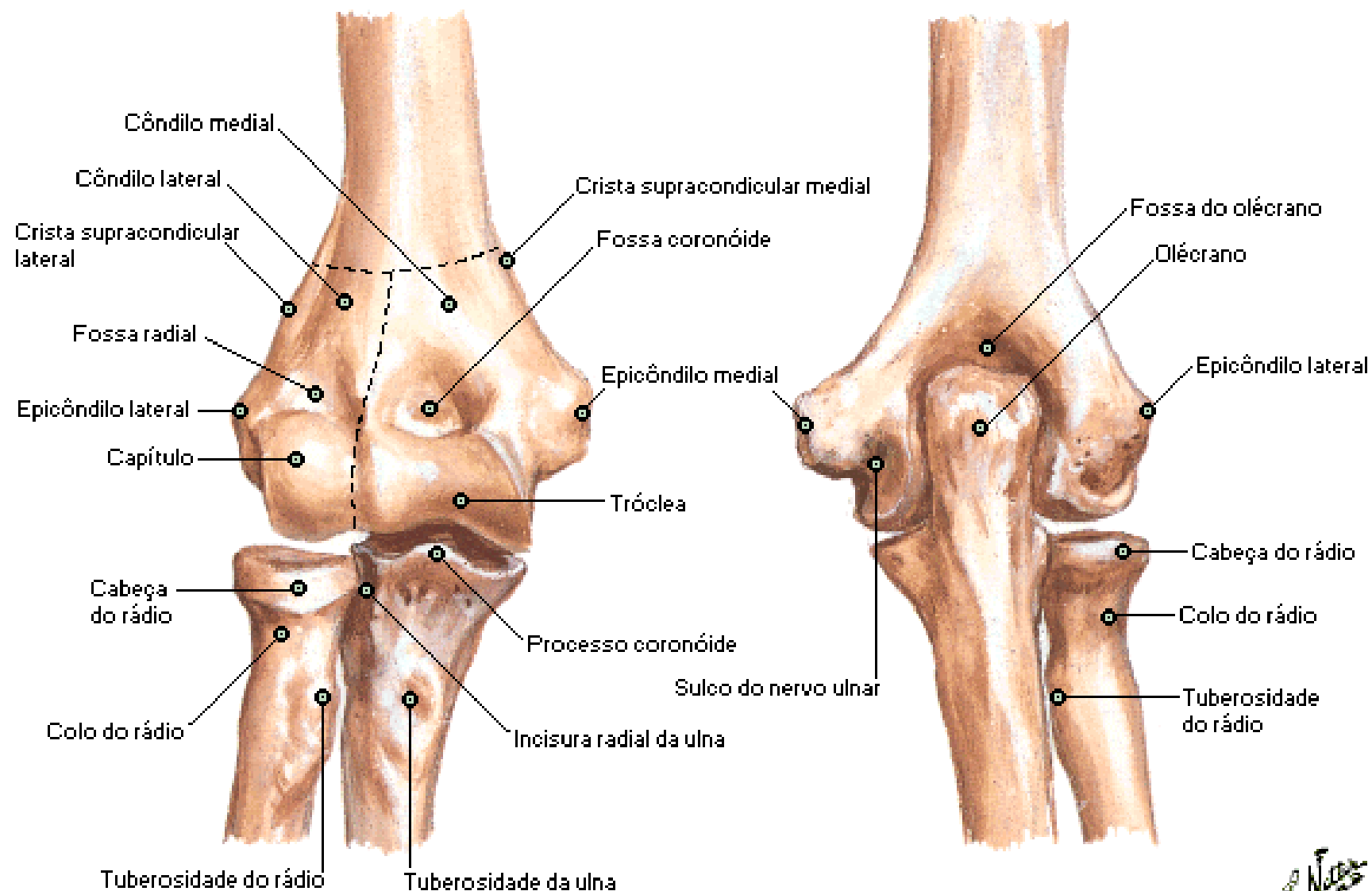
Braço

Secção Distal Transversal



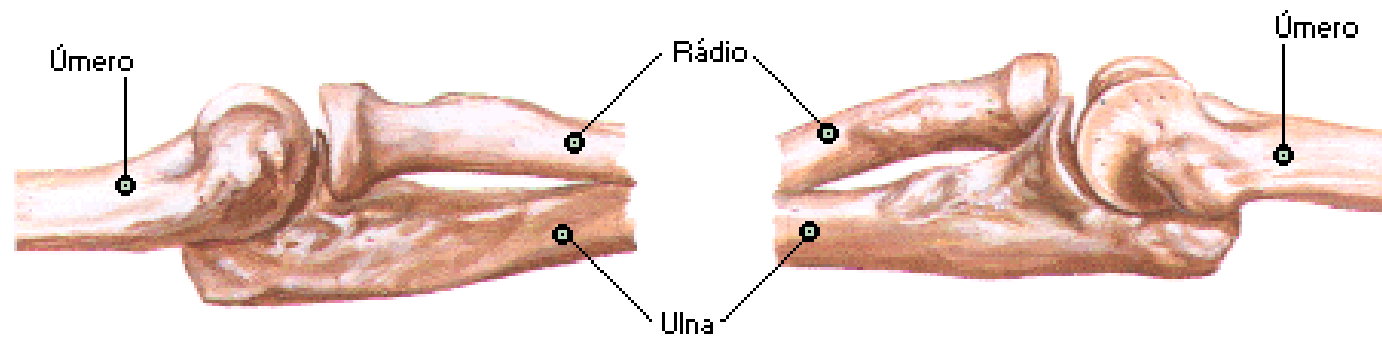
Ossos do Cotovelo em Extensão

Vistas Anterior e Posterior



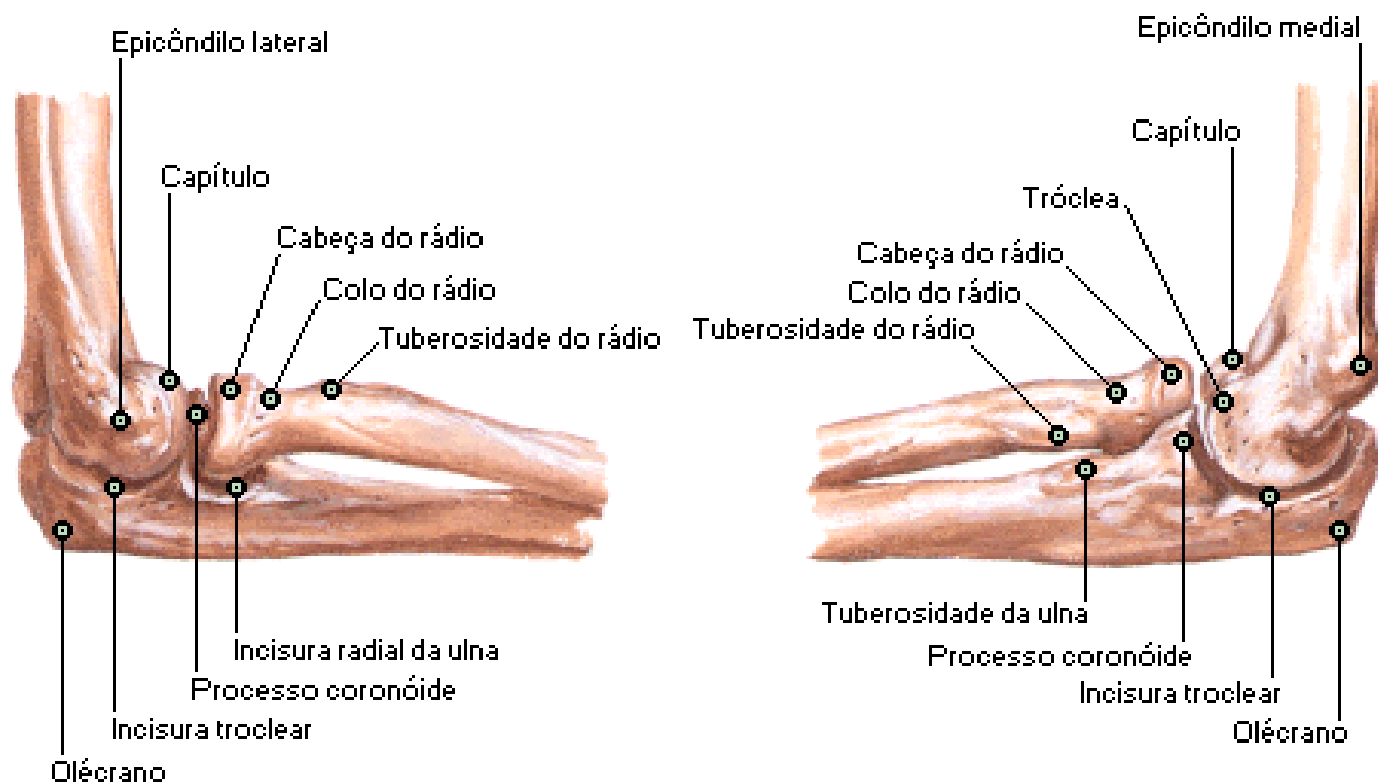
Ossos do Cotovelo em Extensão

Vistas Lateral e Medial



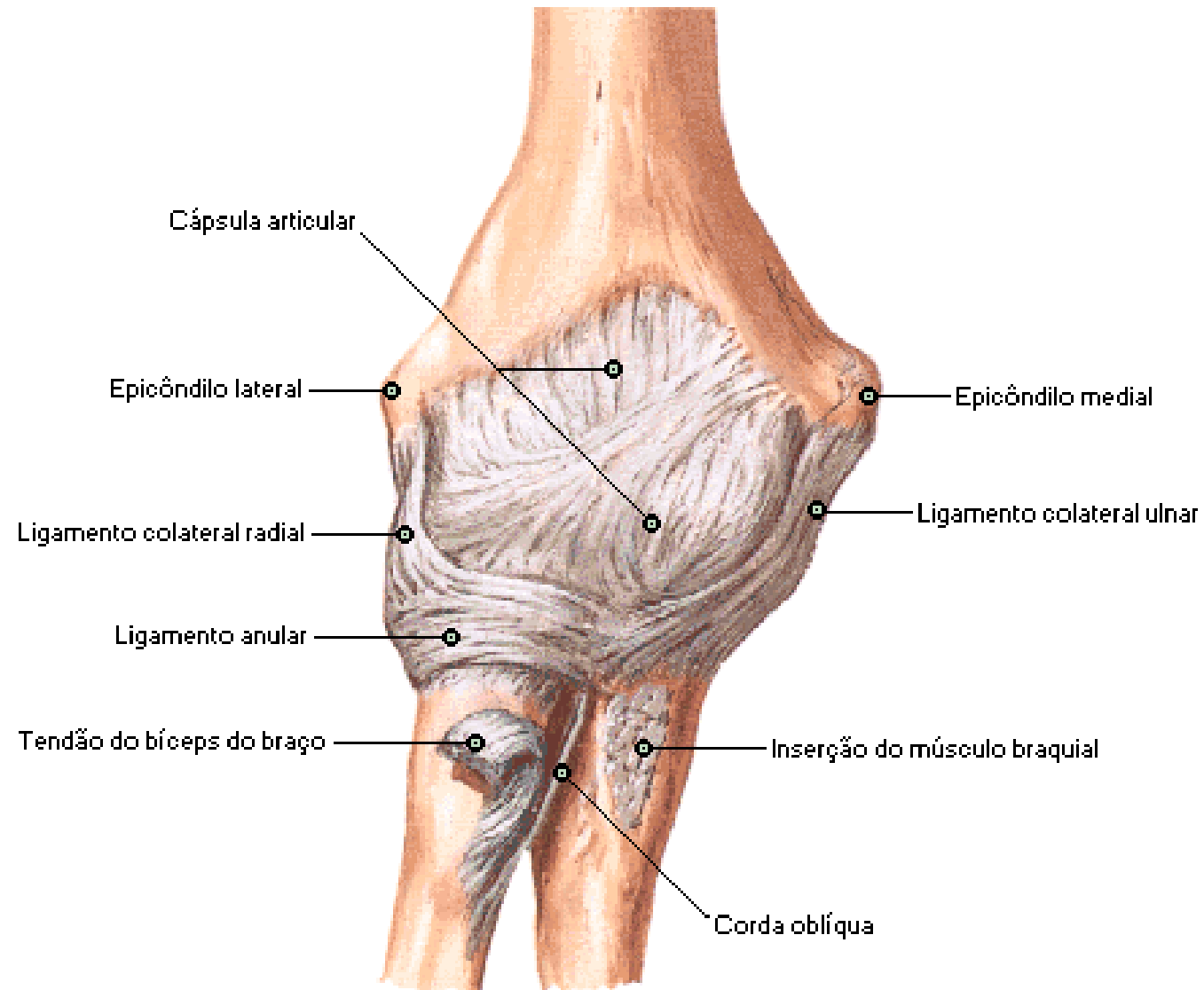
Ossos do Cotovelo em 90° de Flexão

Vistas Lateral e Medial



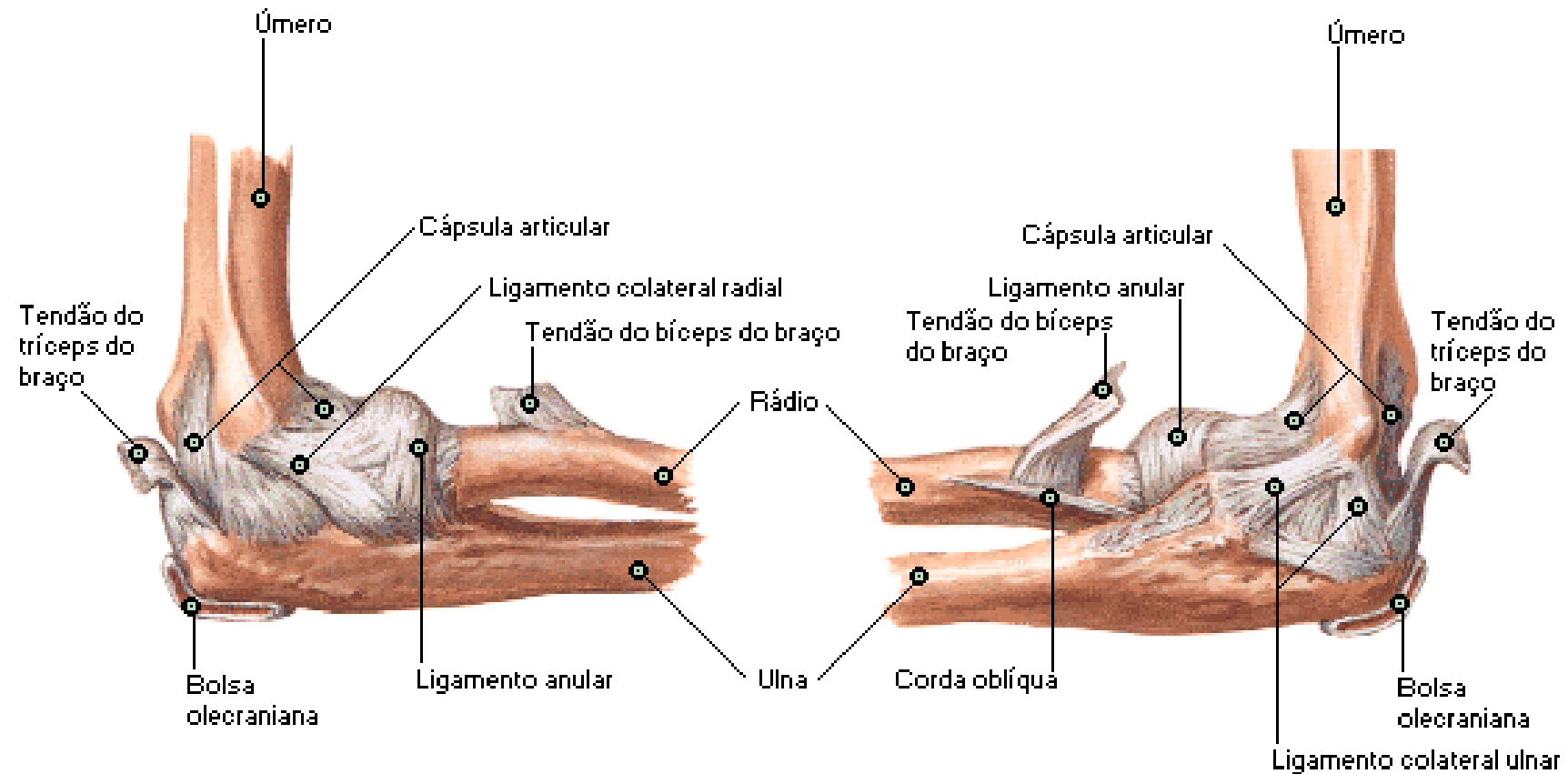
Ligamentos do Cotovelo

Cotovelo Direito - Vista Anterior



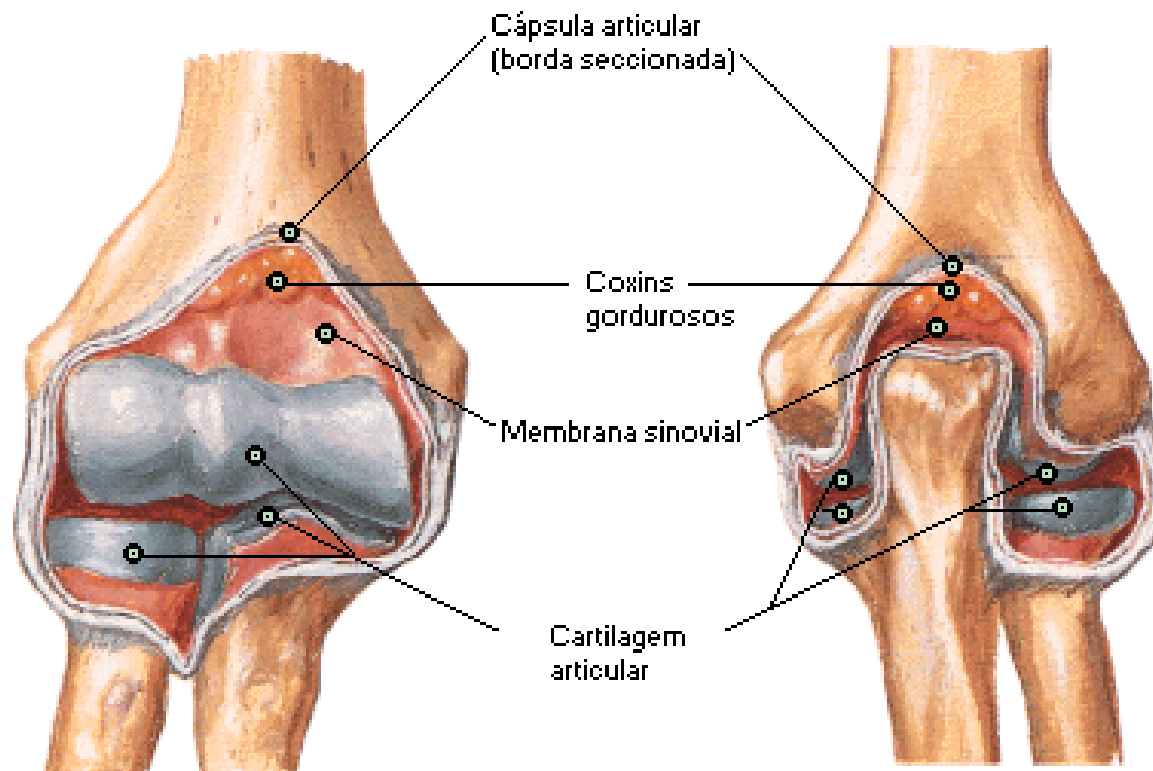
Ligamentos do Cotovelo em 90° de Flexão

Vistas Lateral e Medial



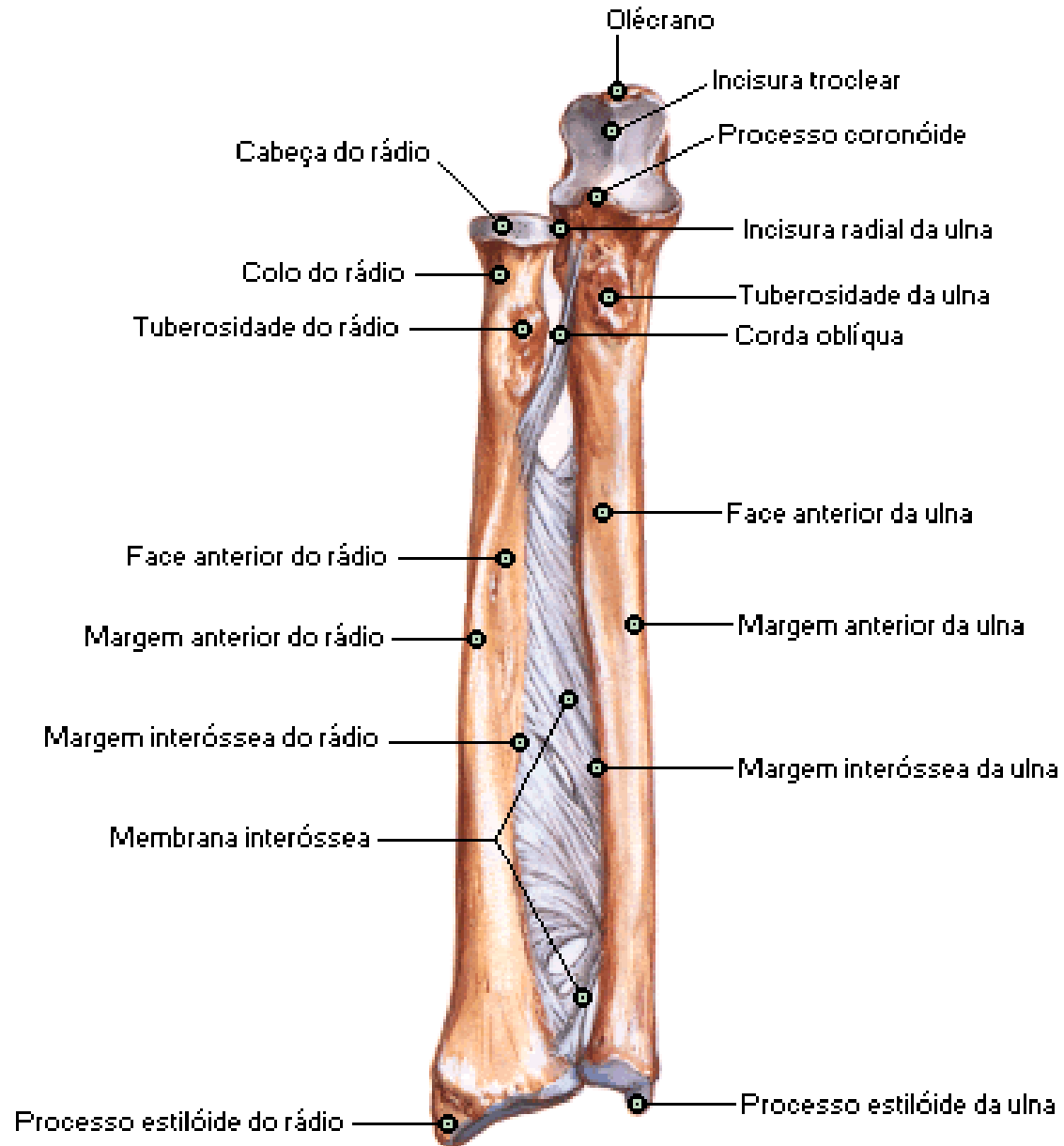
Ligamentos do Cotovelo [Aberto]

Vistas Anterior e Posterior




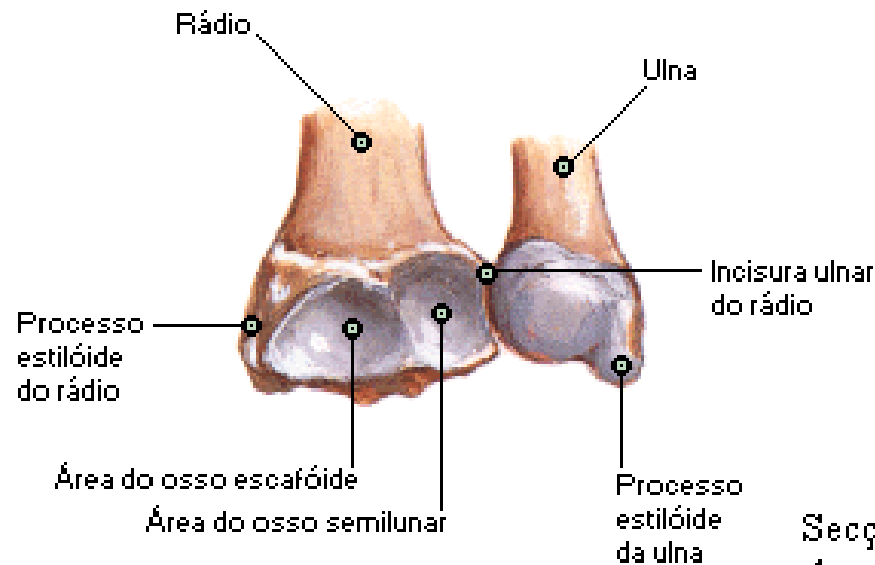
Rádio e Ulna Direitos em Supinação

Vista Anterior



Ossos do Antebraço

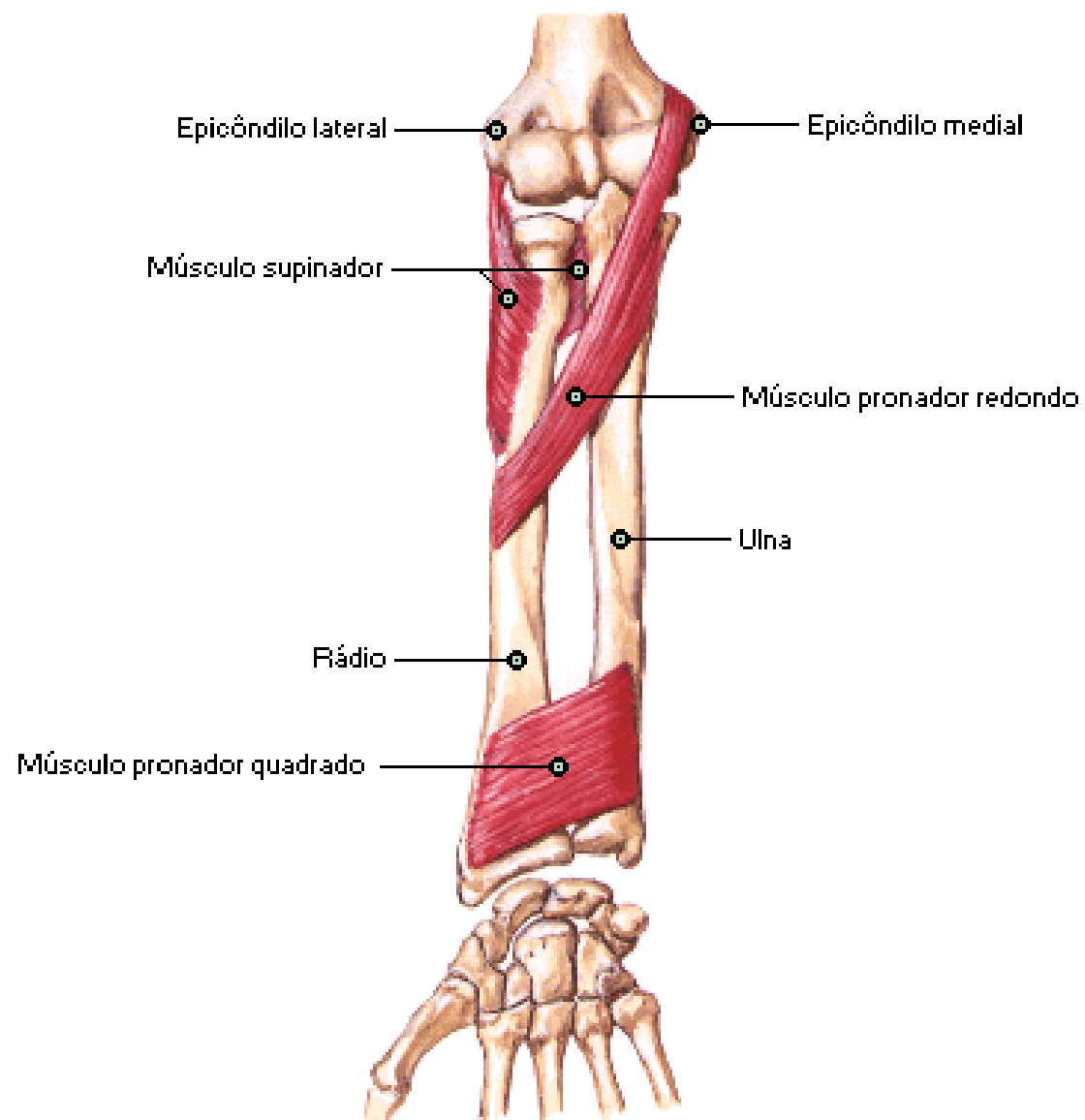
Face Articular do Carpo e Secção do Rádio



Secção coronal do rádio demonstra como a espessura do osso cortical da diáfise diminui até uma delgada camada sobre o osso esponjoso na extremidade distal

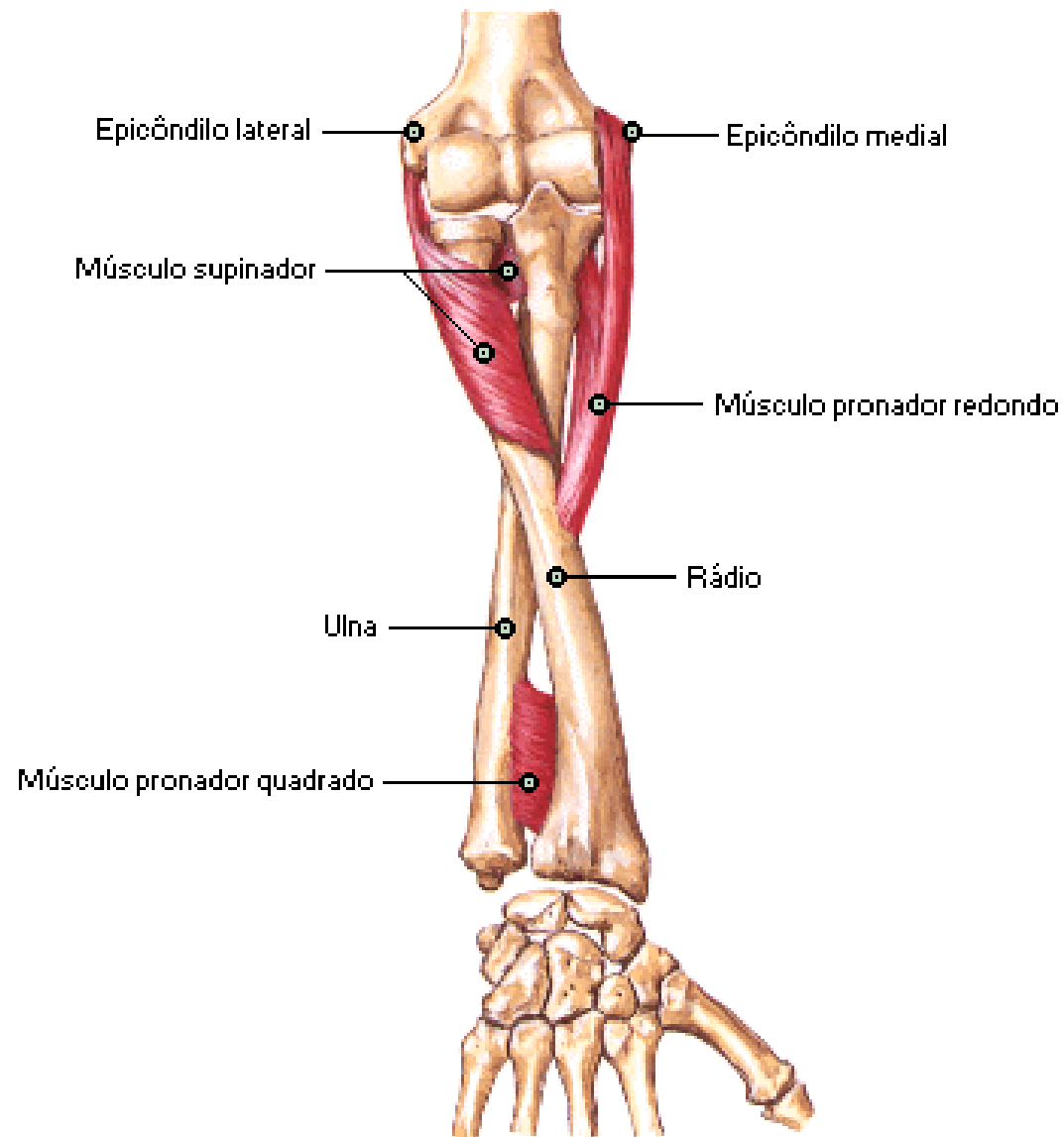
Músculos Individualizados do Antebraço

Rotadores do Rádio - Supinação



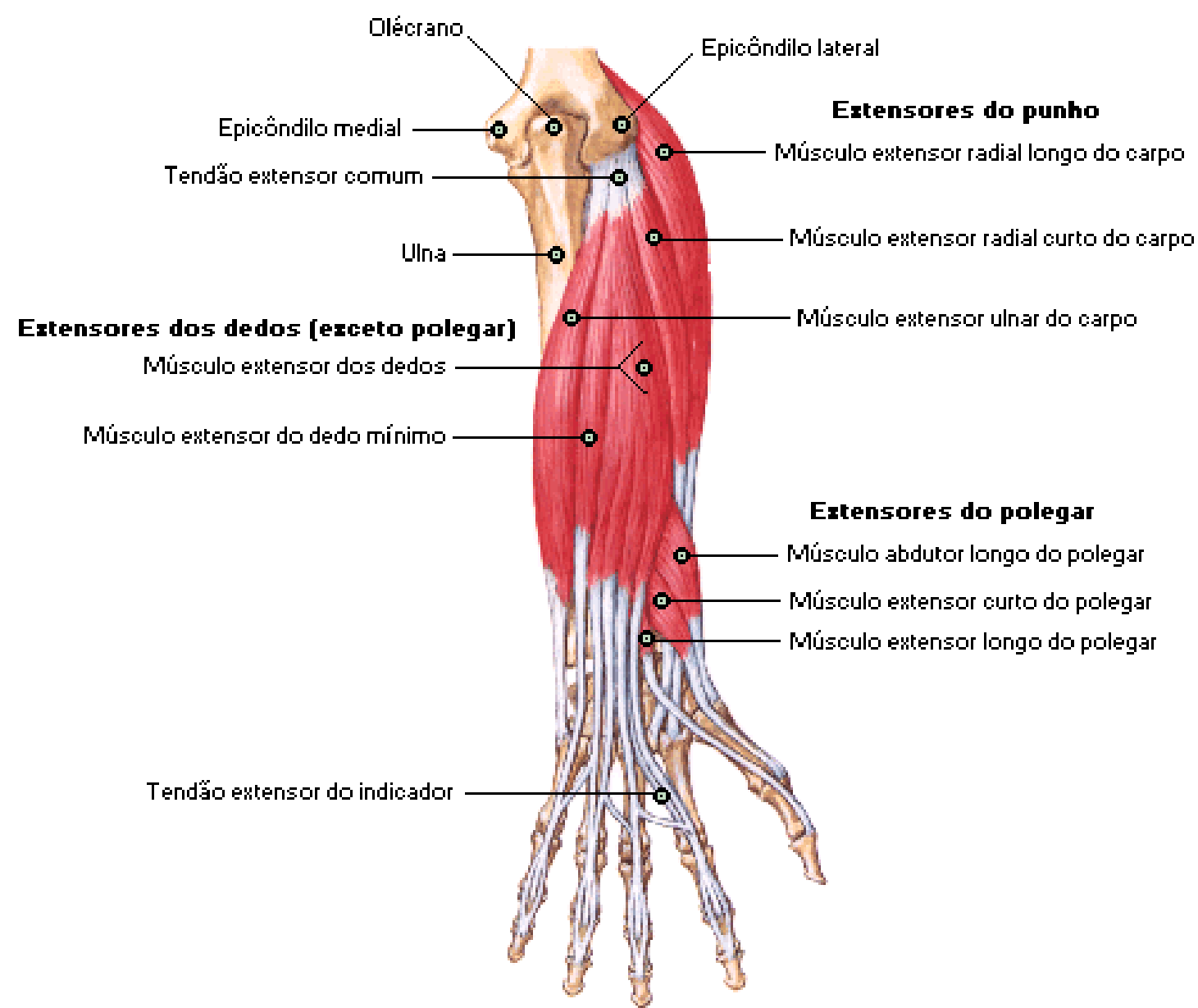
Músculos Individualizados do Antebraço

Rotadores do Rádio - Pronação



Músculos Individualizados do Antebraço

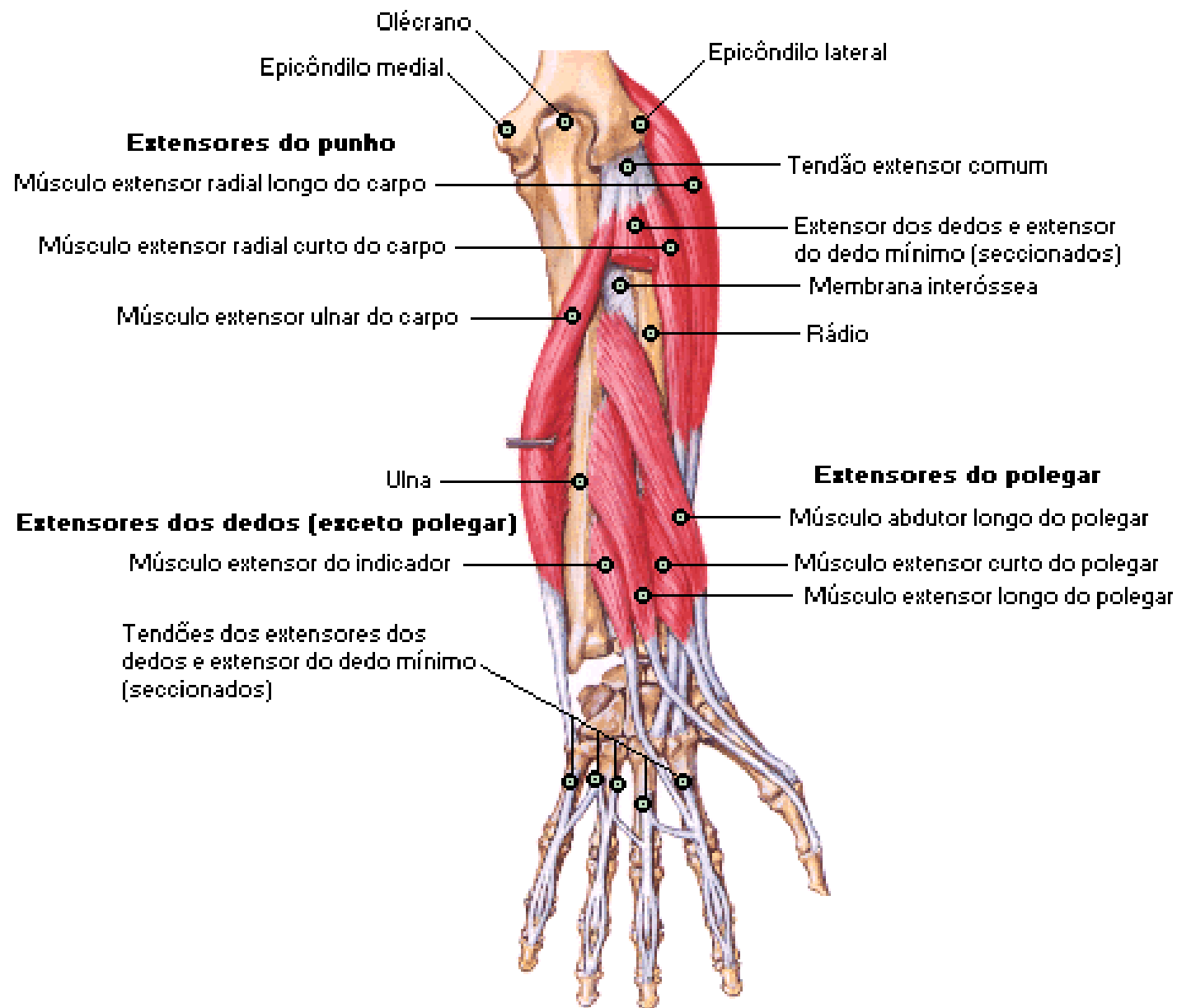
Extensores do Punho e Dedos



Nota: músculo ancônio não é mostrado por ser um extensor do antebraço

Músculos Individualizados do Antebraço [Continuação]

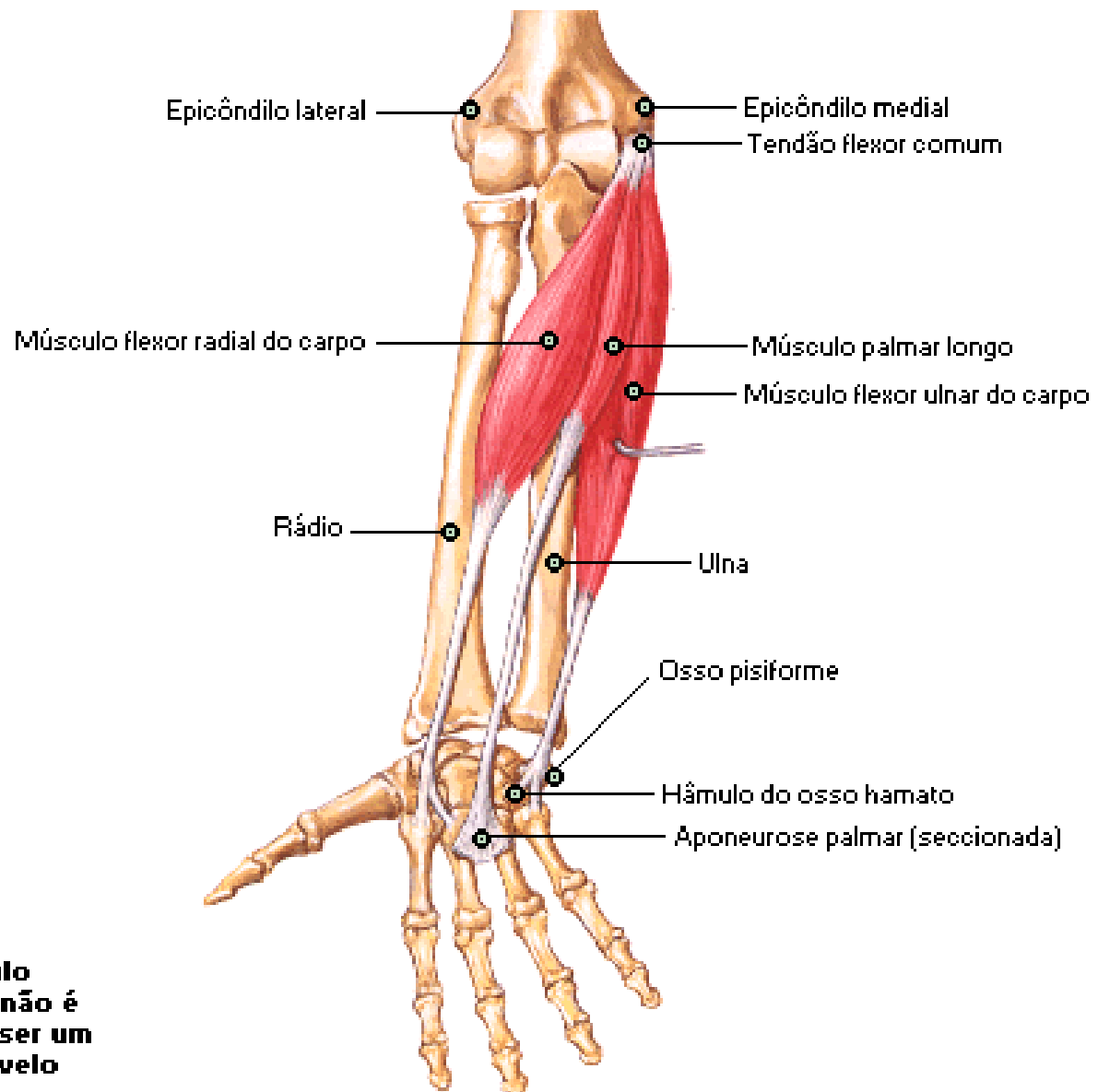
Extensores do Punho e Dedos



Nota: músculo ancôneo não é mostrado por ser um extensor do antebraço

Músculos Individualizados do Antebraço

Flexores do Punho

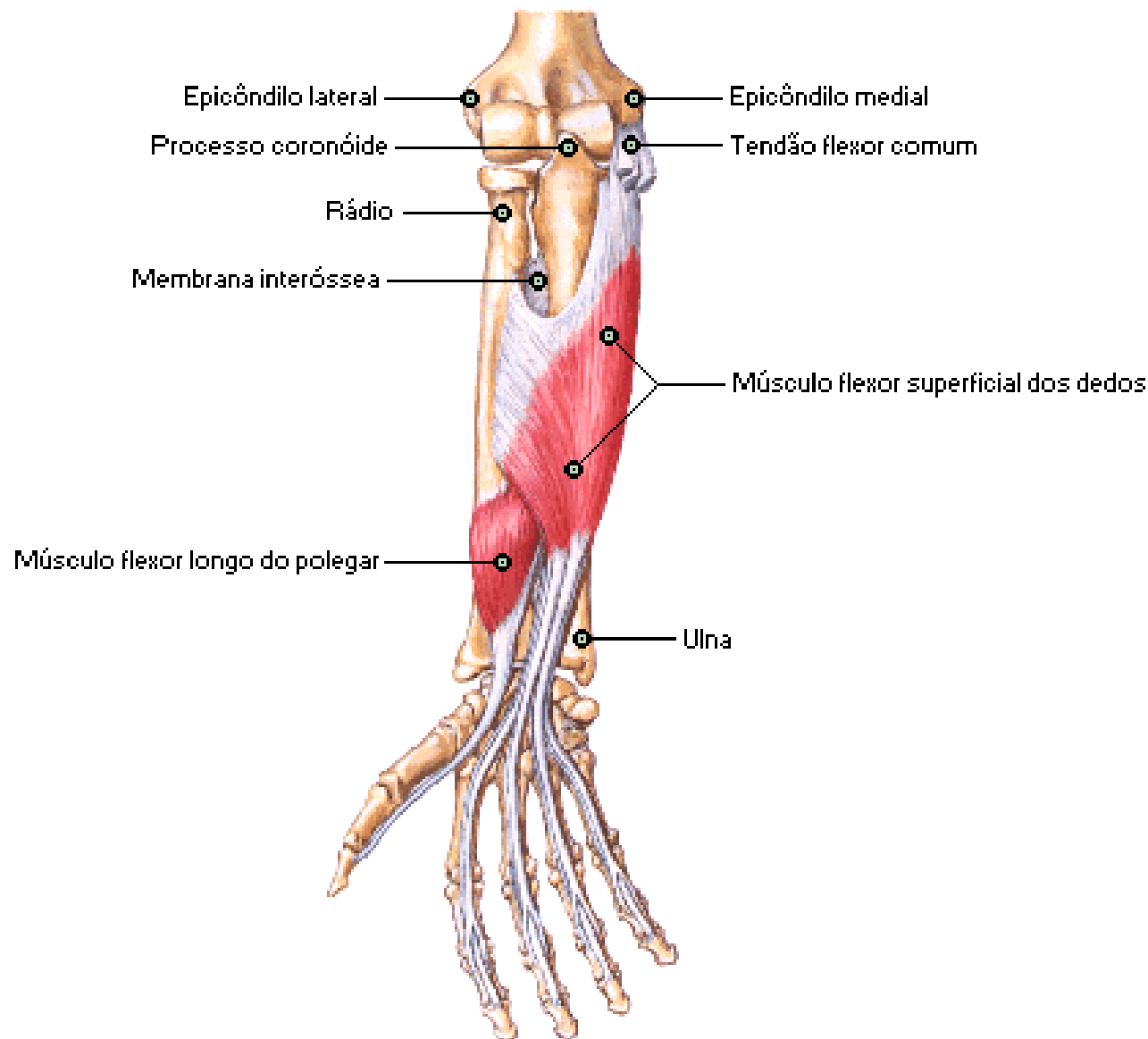


Nota: o músculo braquiorradial não é mostrado por ser um flexor do cotovelo

Antebraço direito: vista anterior [palmares]

Músculos Individualizados do Antebraço

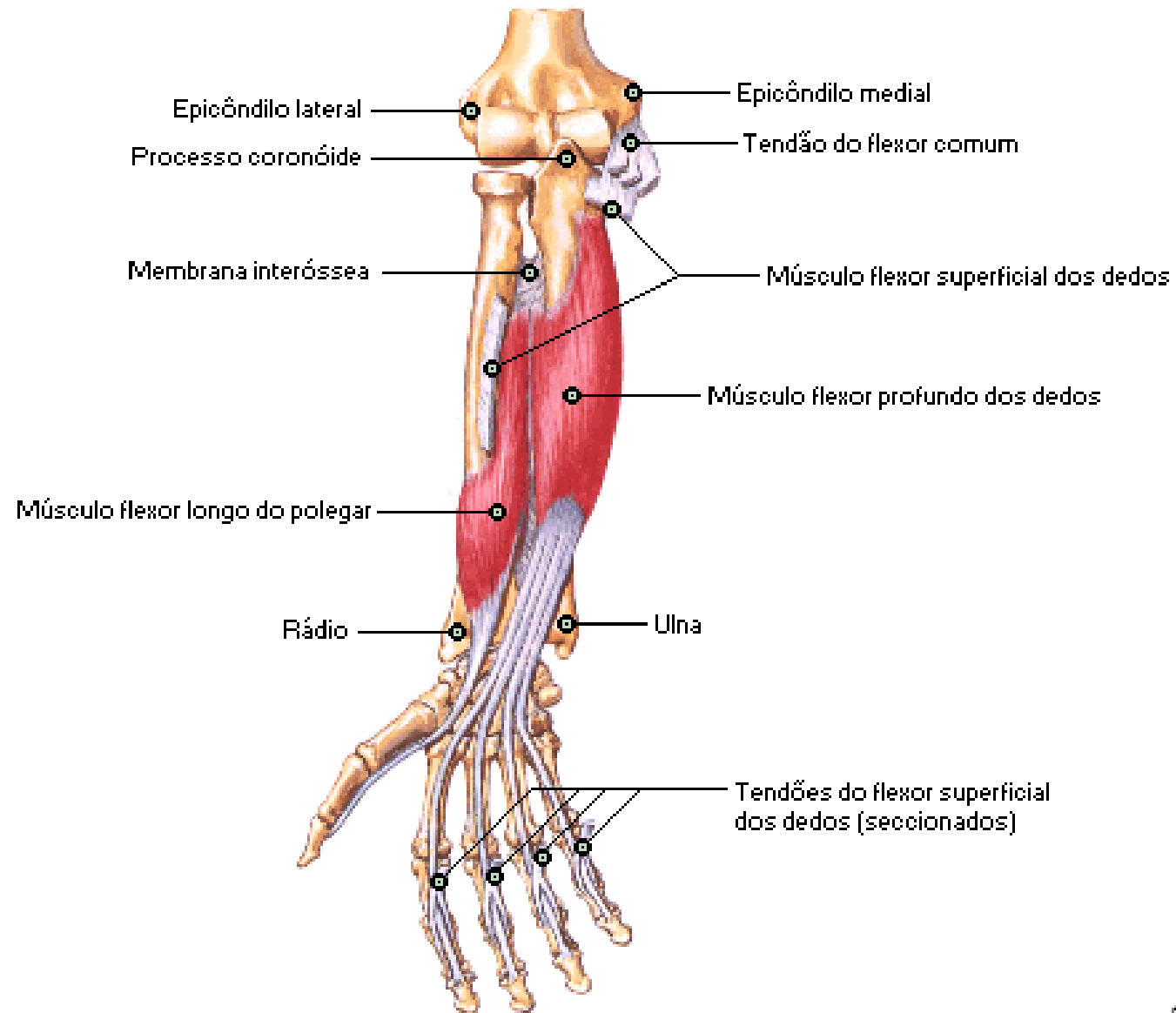
Flexores dos Dedos



Antebraço direito: vista anterior [palmares]

Músculos Individualizados do Antebraço [Continuação]

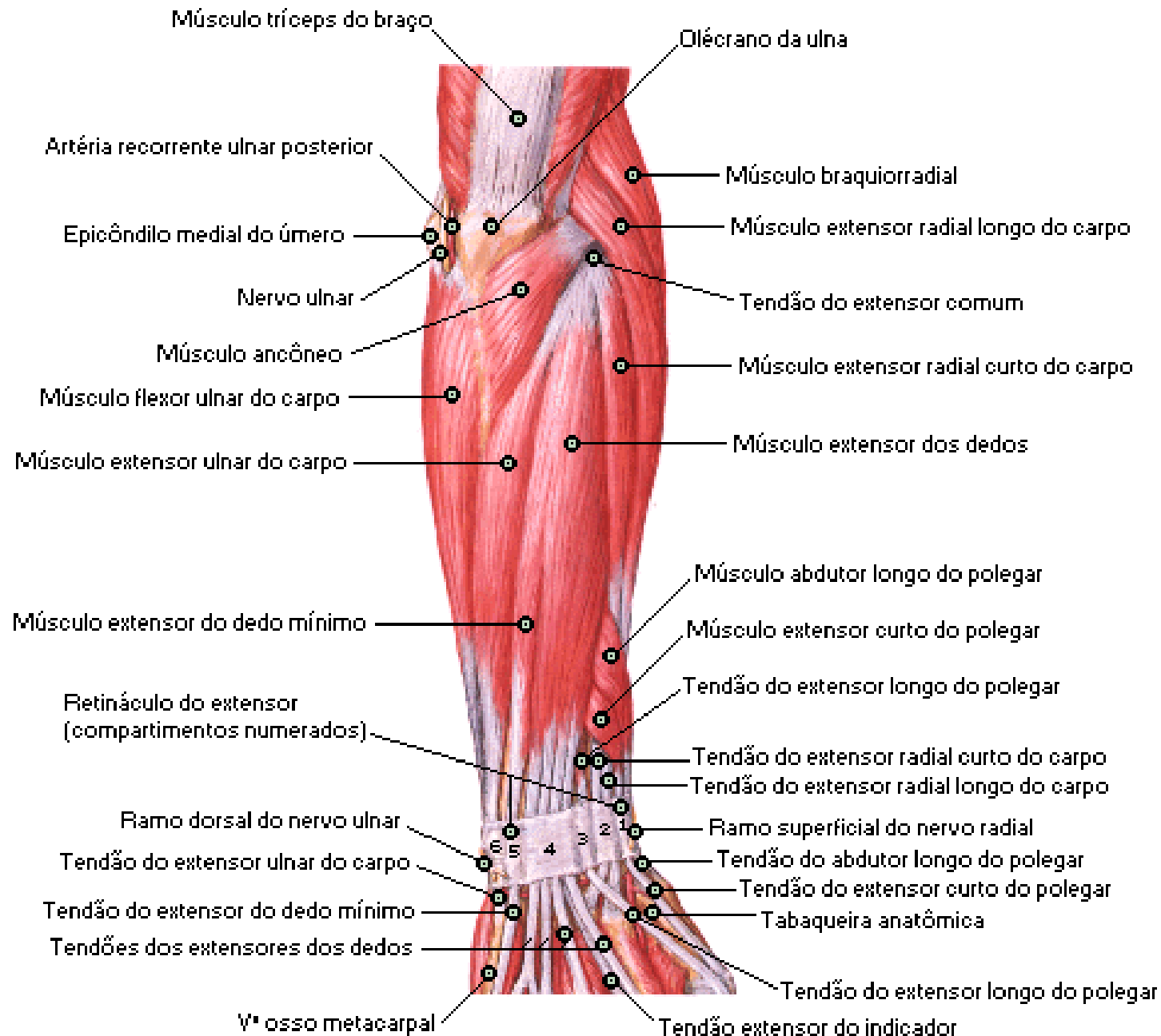
Flexores dos Dedos



Antebraço direito: vista anterior [palmares]

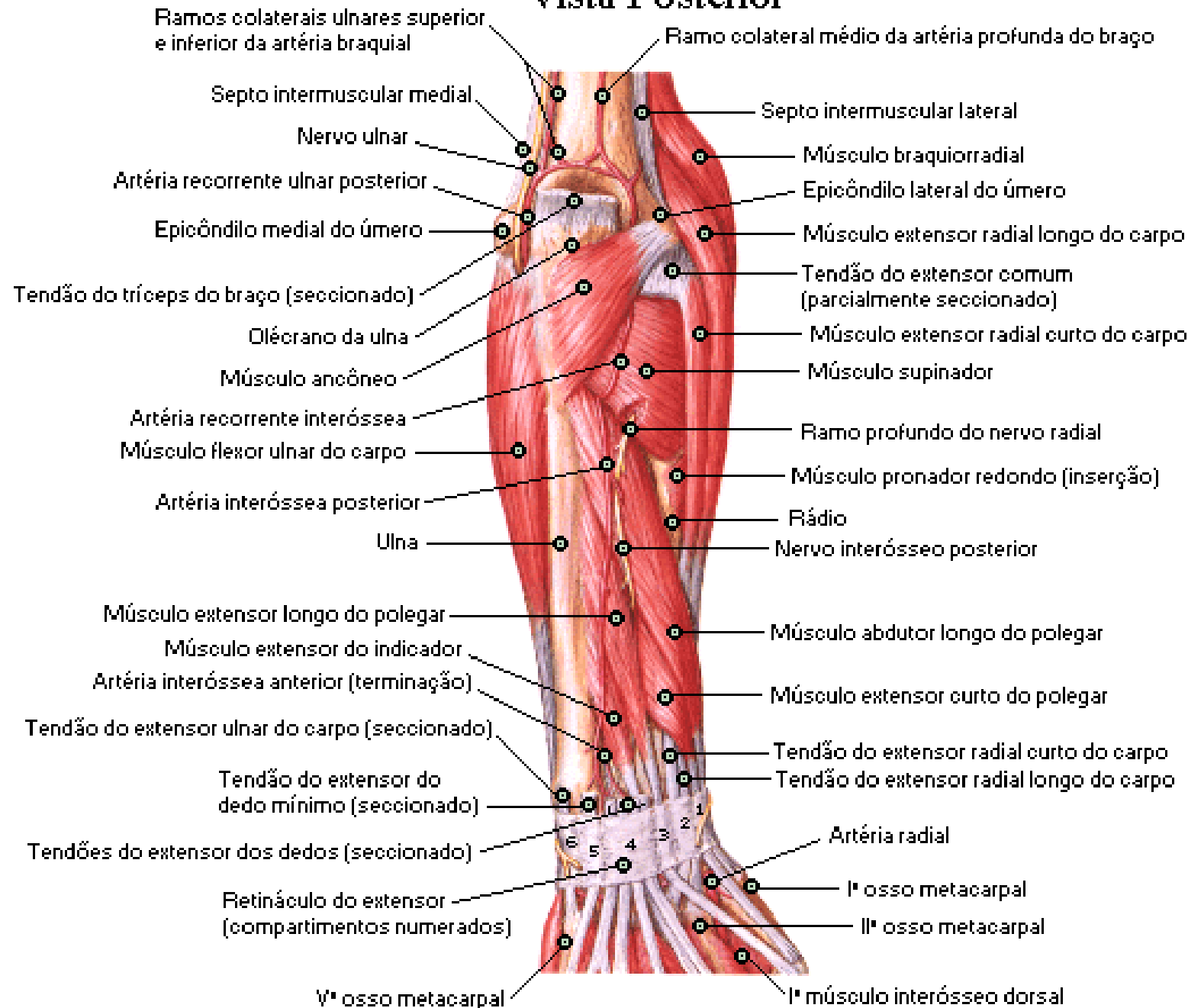
Músculos do Antebraço [Camada Superficial]

Vista Posterior



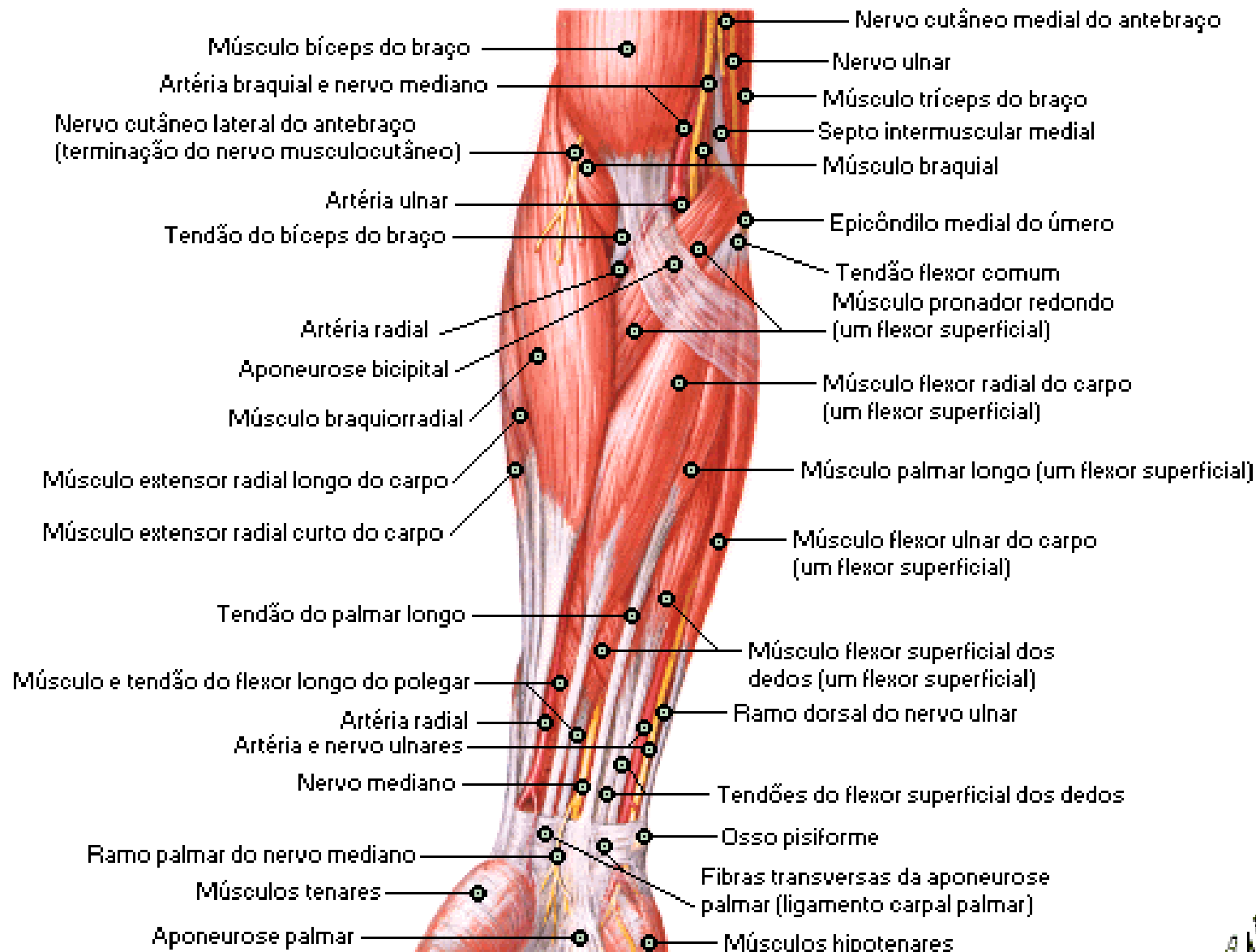
Músculos do Antebraço [Camada Profunda]

Vista Posterior



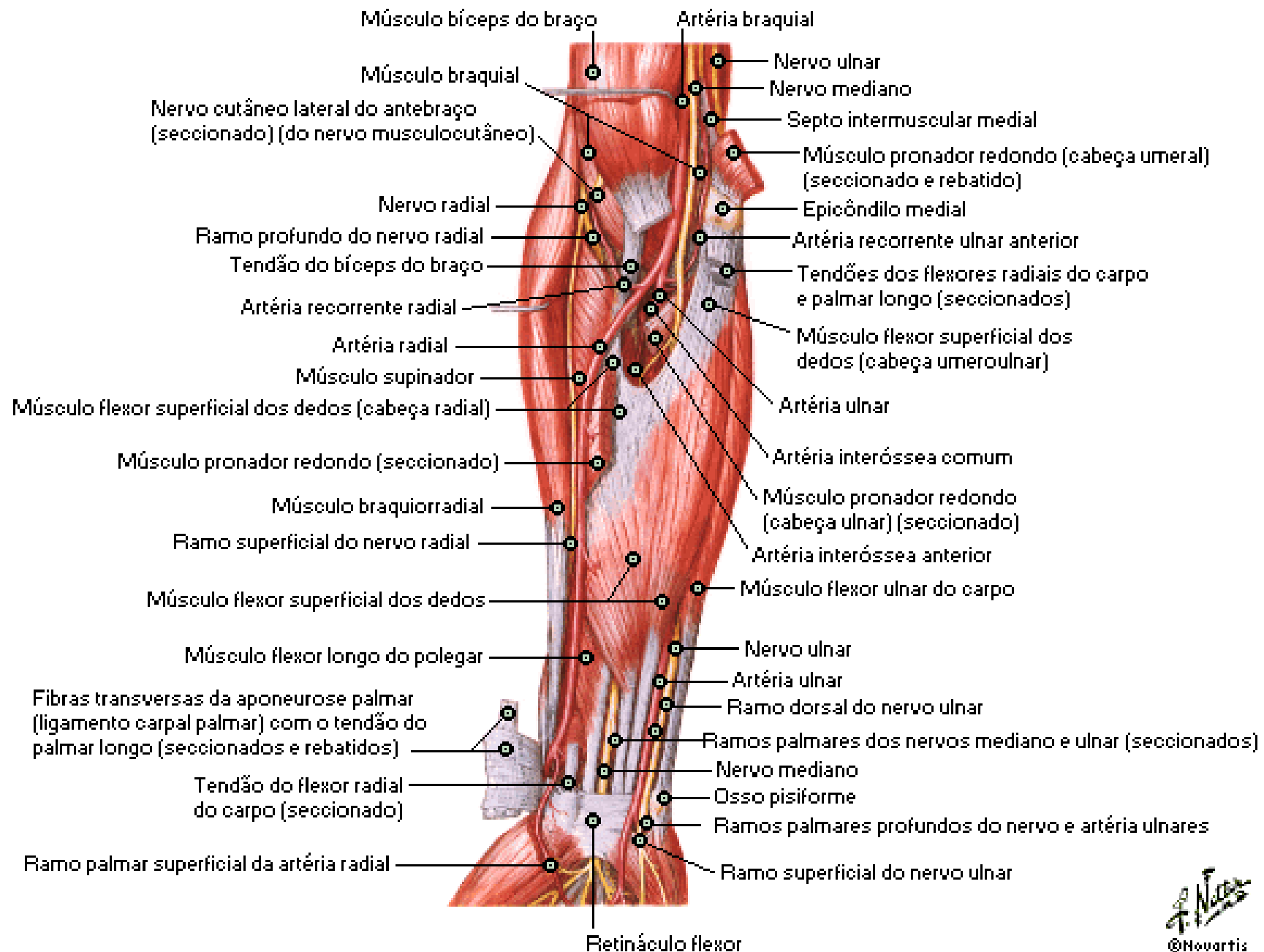
Músculos do Antebraço [Camada Superficial]

Vista Anterior



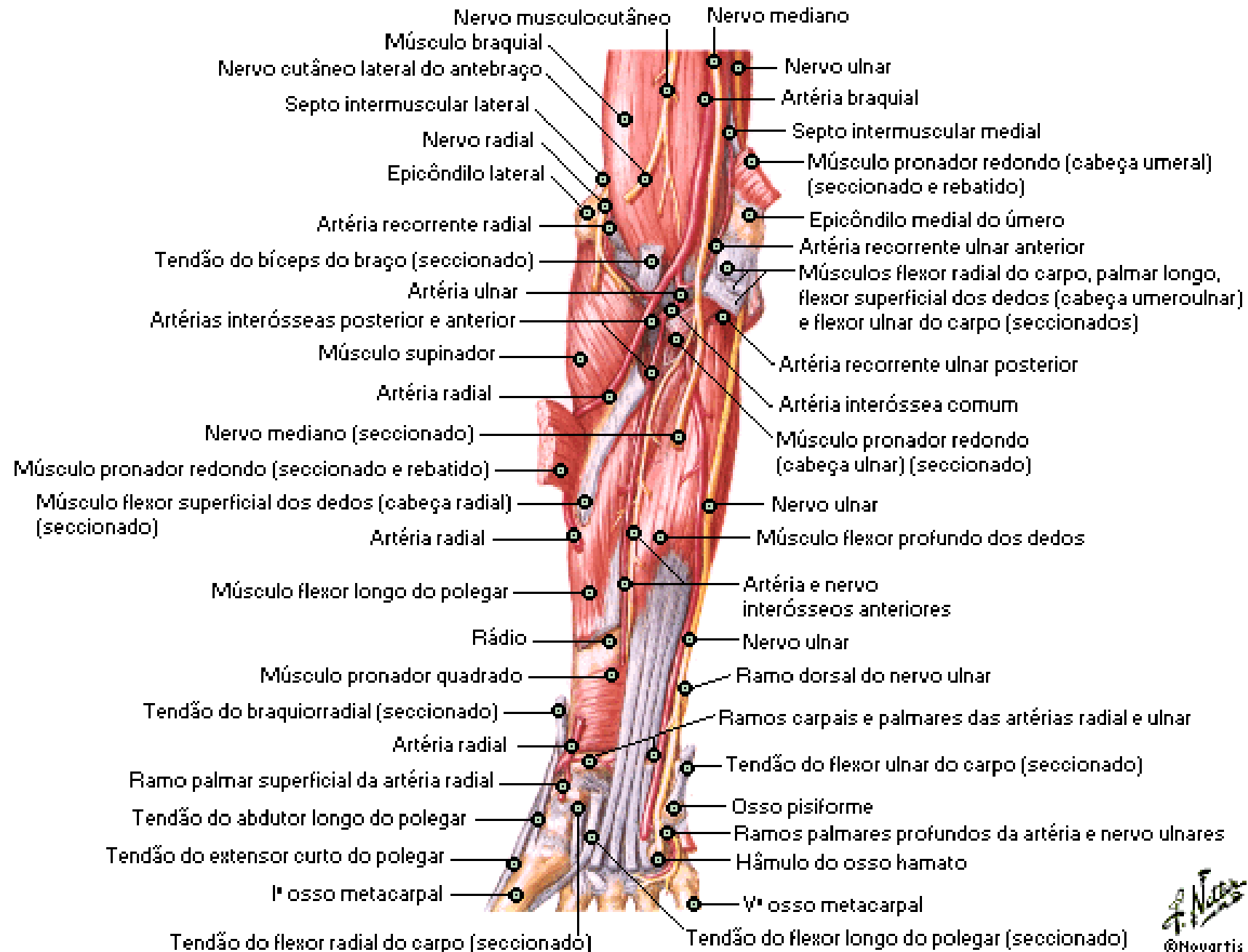
Músculos do Antebraço [Camada Intermediária]

Vista Anterior



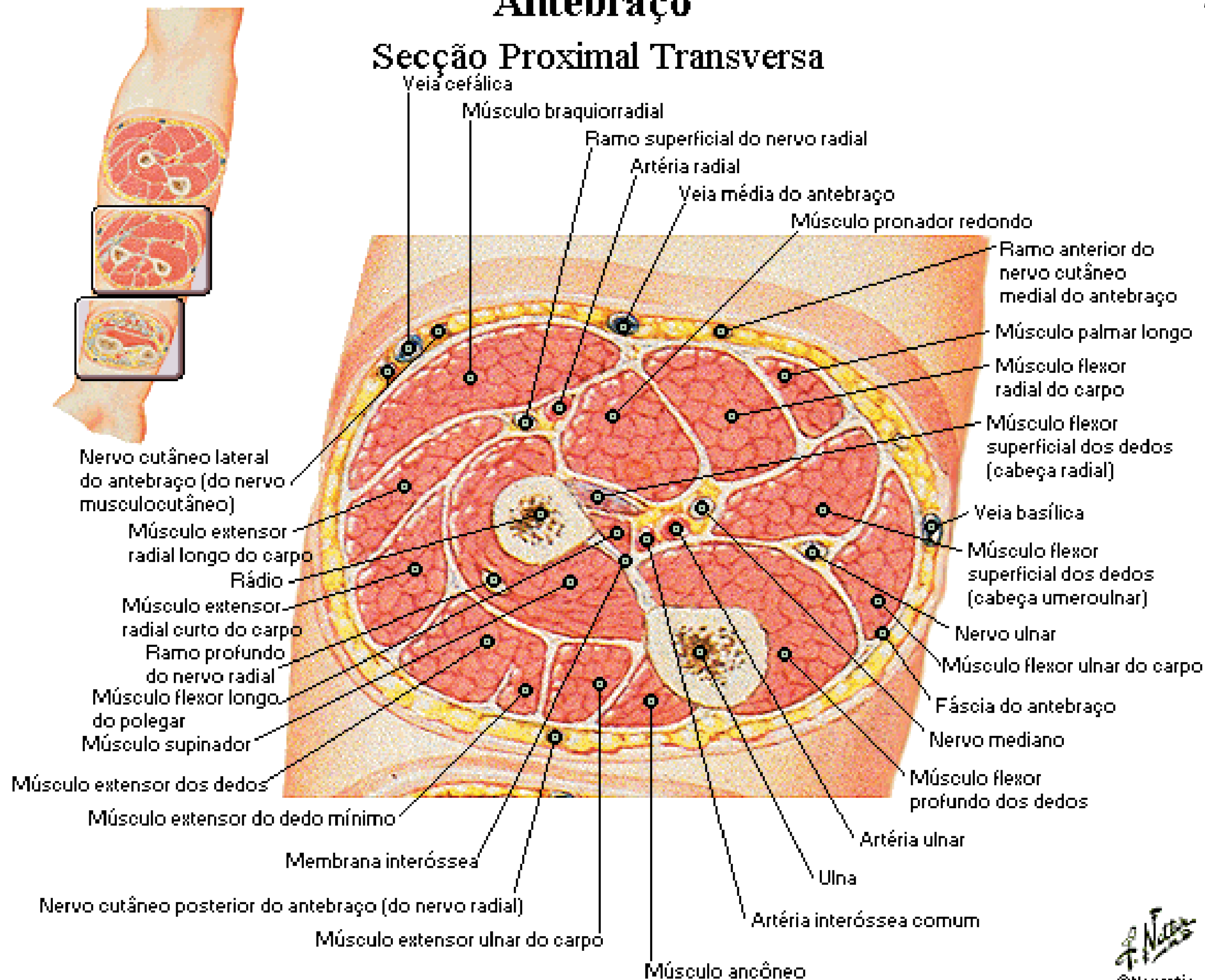
Músculos do Antebraço [Camada Profunda]

Vista Anterior



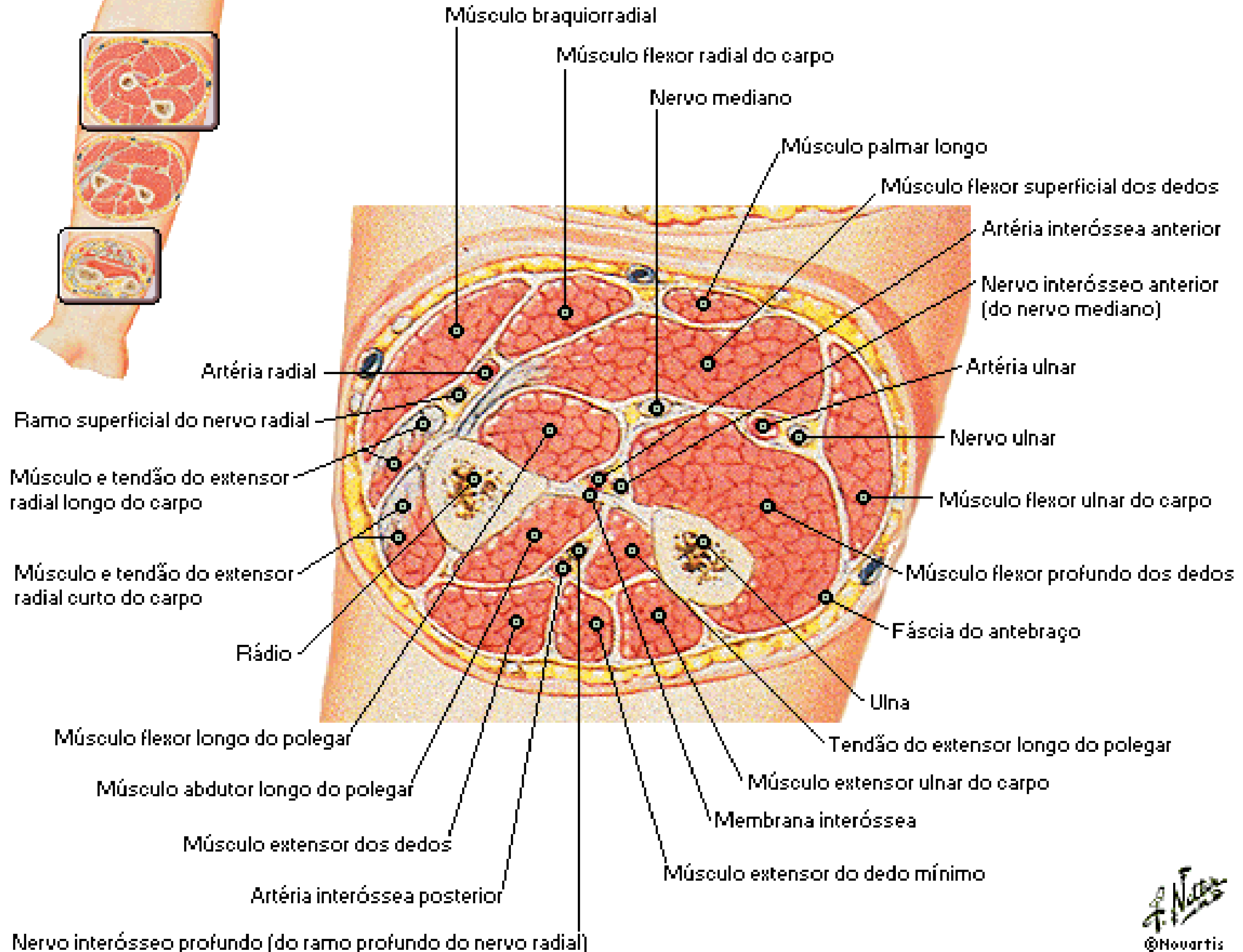
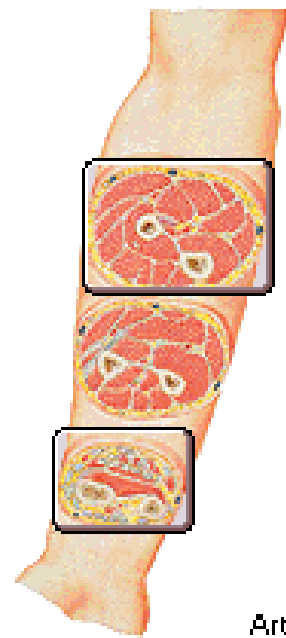
Antebraço

Secção Proximal Transversal



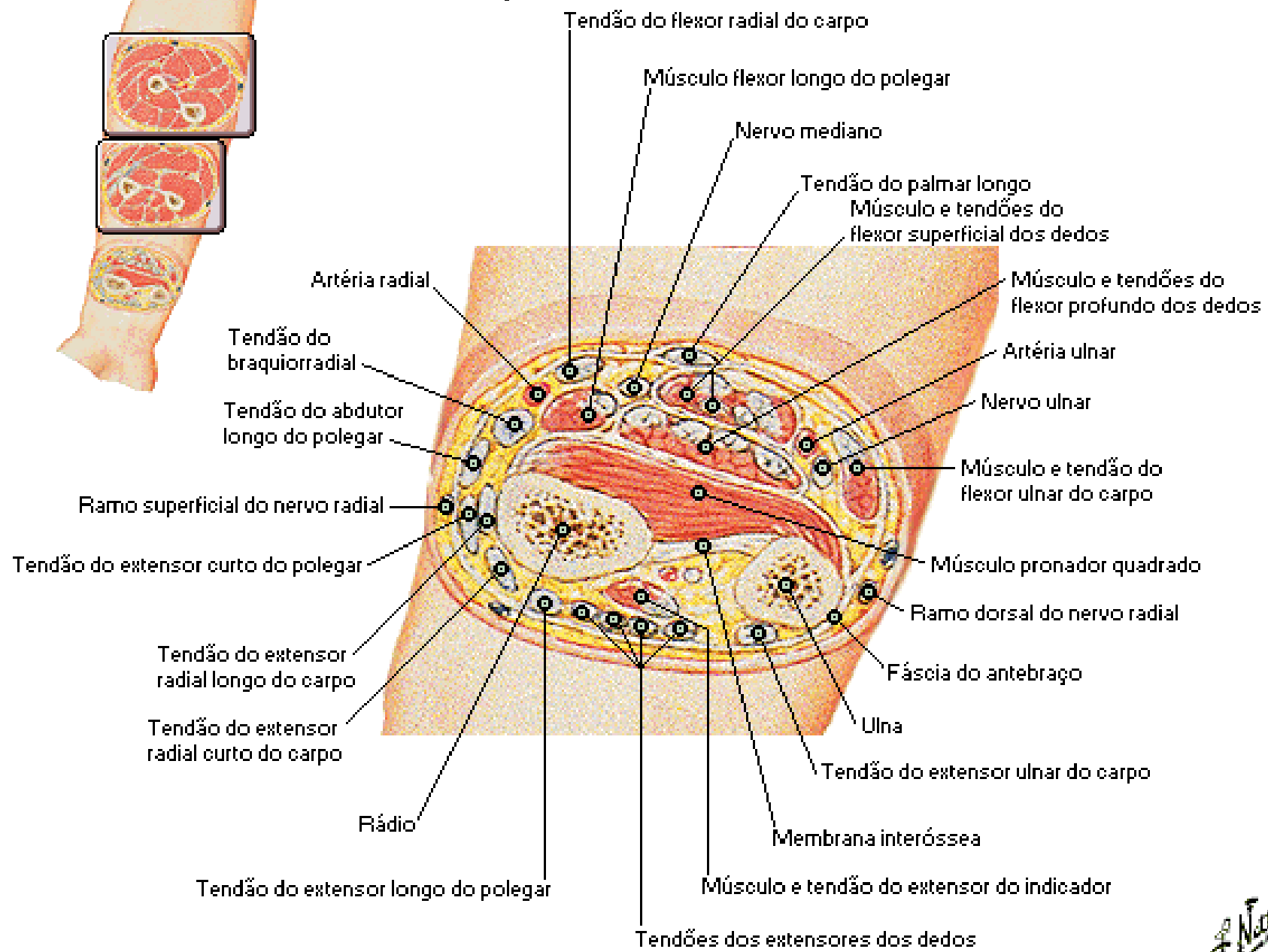
Antebraço

Secção Medial Transversal



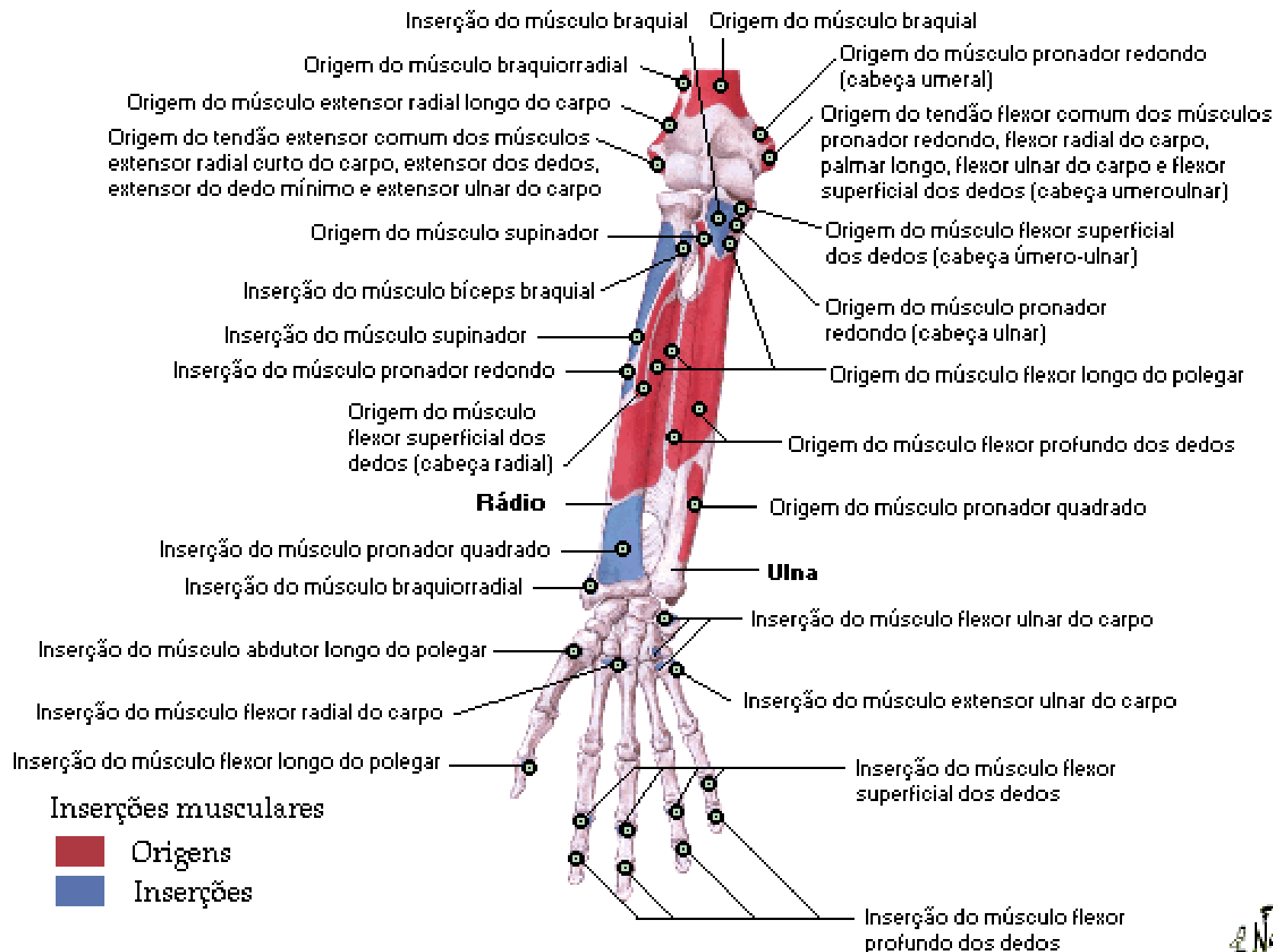
Antebraço

Secção Distal Transversal



Inserções Ósseas dos Músculos do Antebraço

Vista Anterior



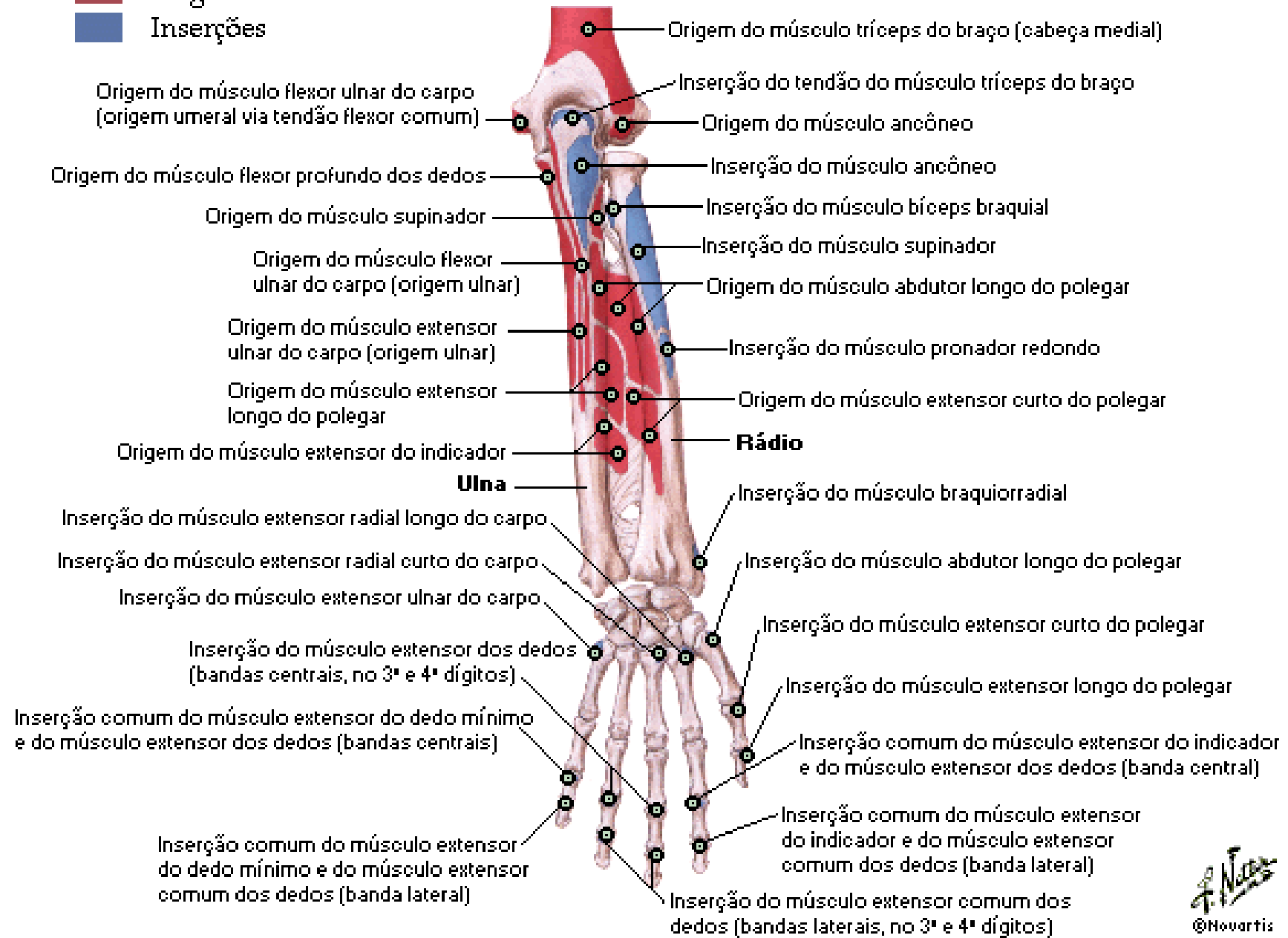
Nota: não são mostradas as inserções dos músculos intrínsecos da mão

Inserções Ósseas dos Músculos do Antebraço

Vista Posterior

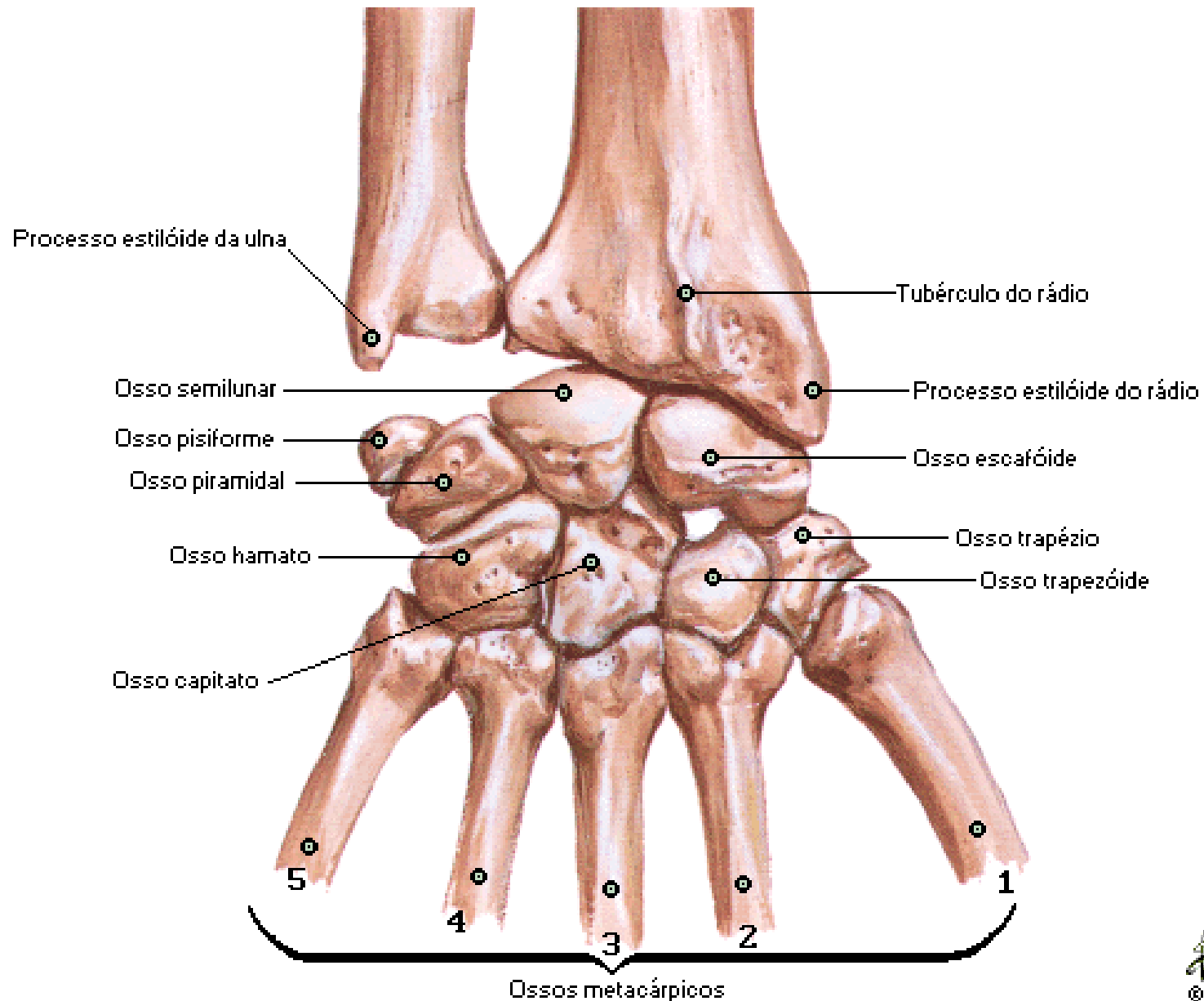
Inserções musculares

■ Origens
■ Inserções



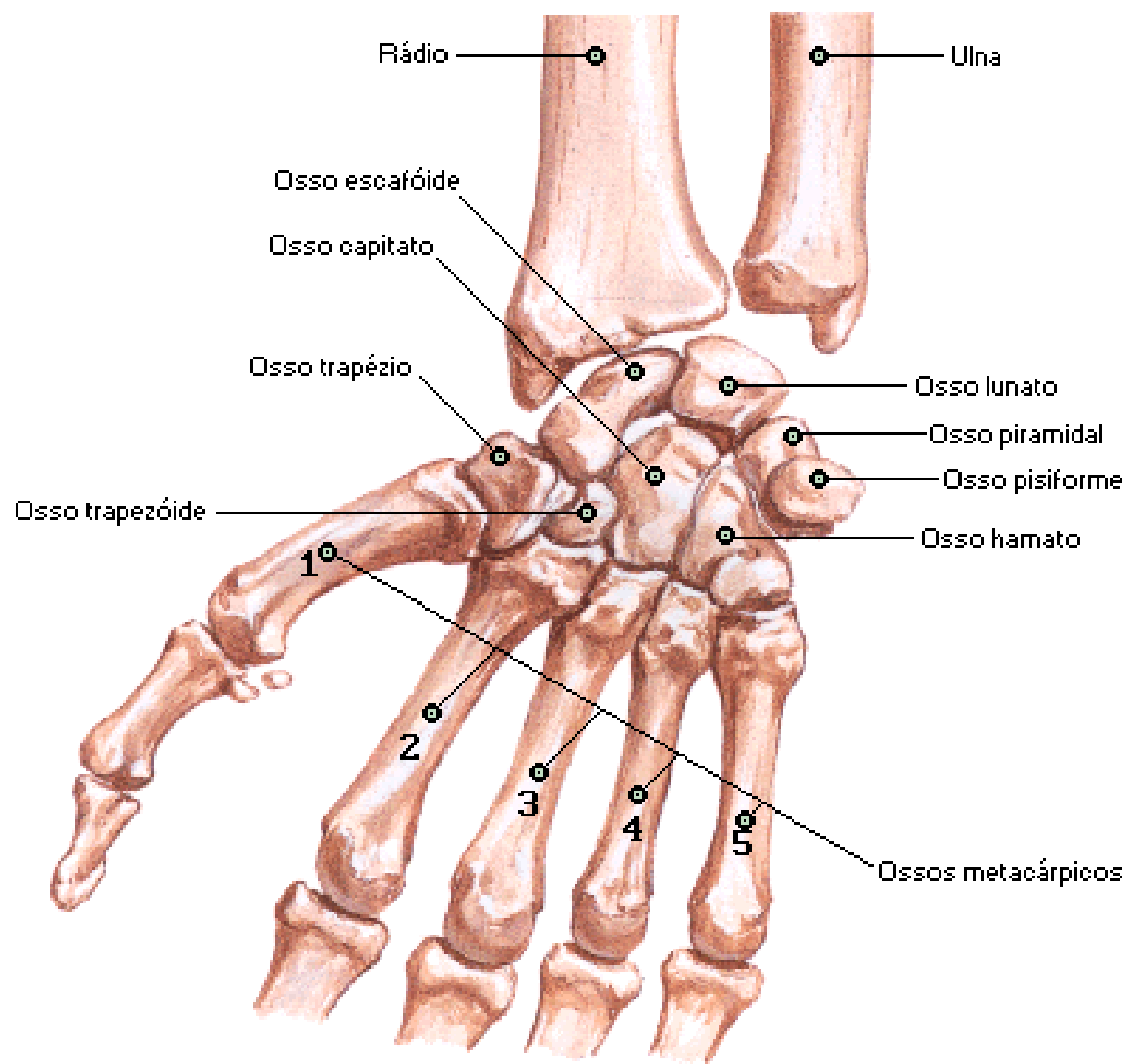
Ossos do Carpo

Vista Posterior [Dorsal]



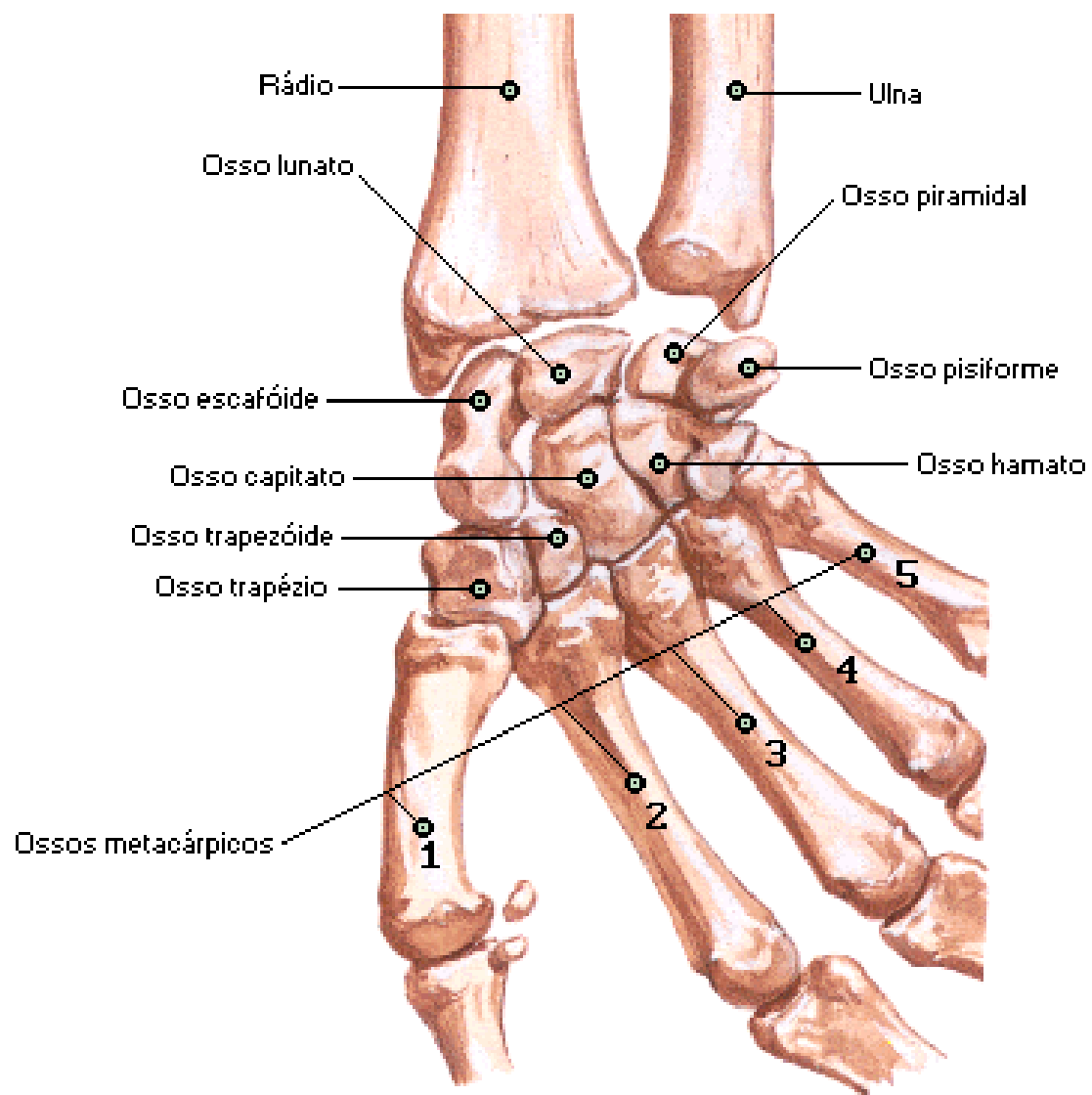
Movimentos do Punho

Mão em Abdução - Vista Anterior [Palmar]



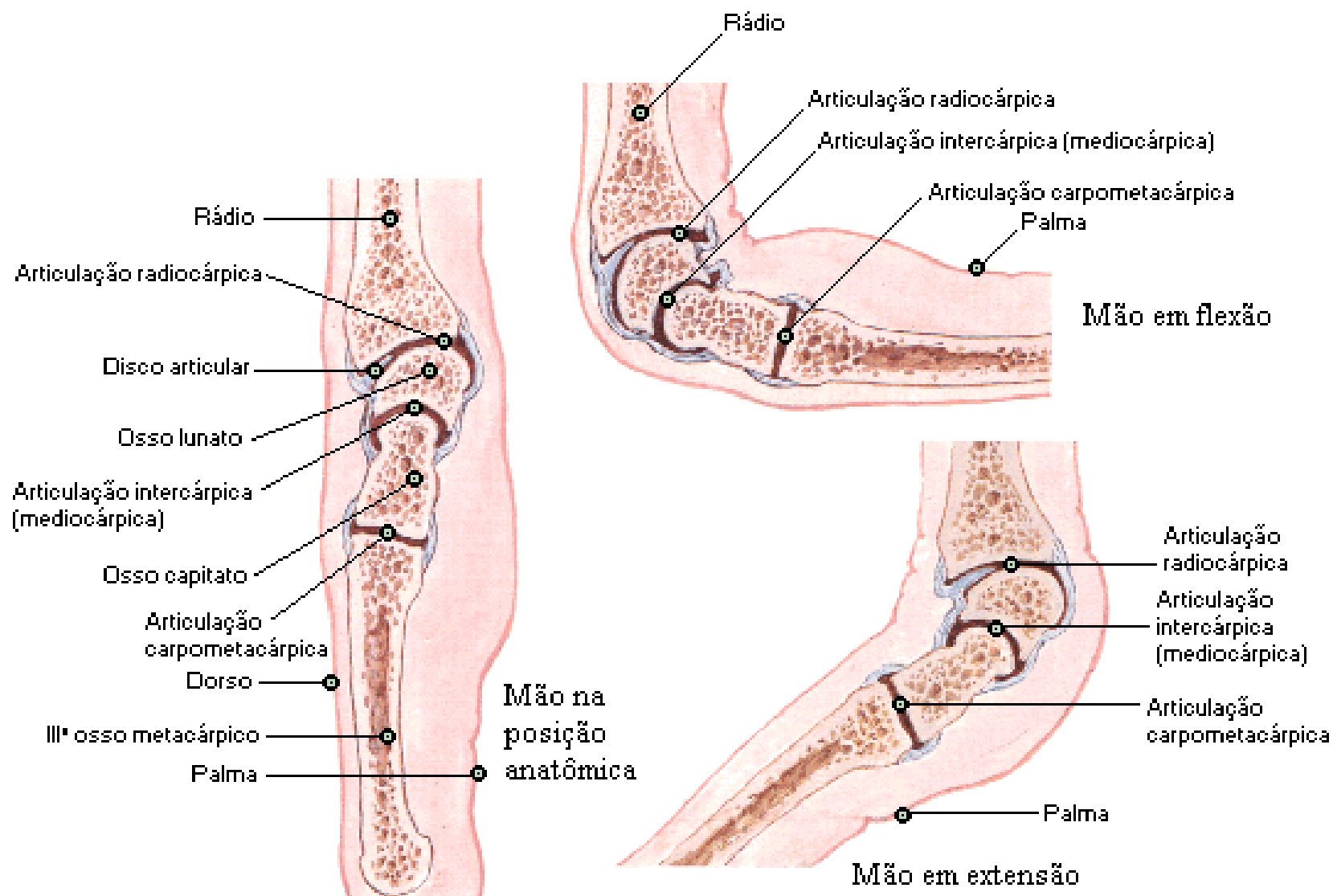
Movimentos do Punho

Mão em Adução - Vista Anterior [Palmar]



Movimentos do Punho

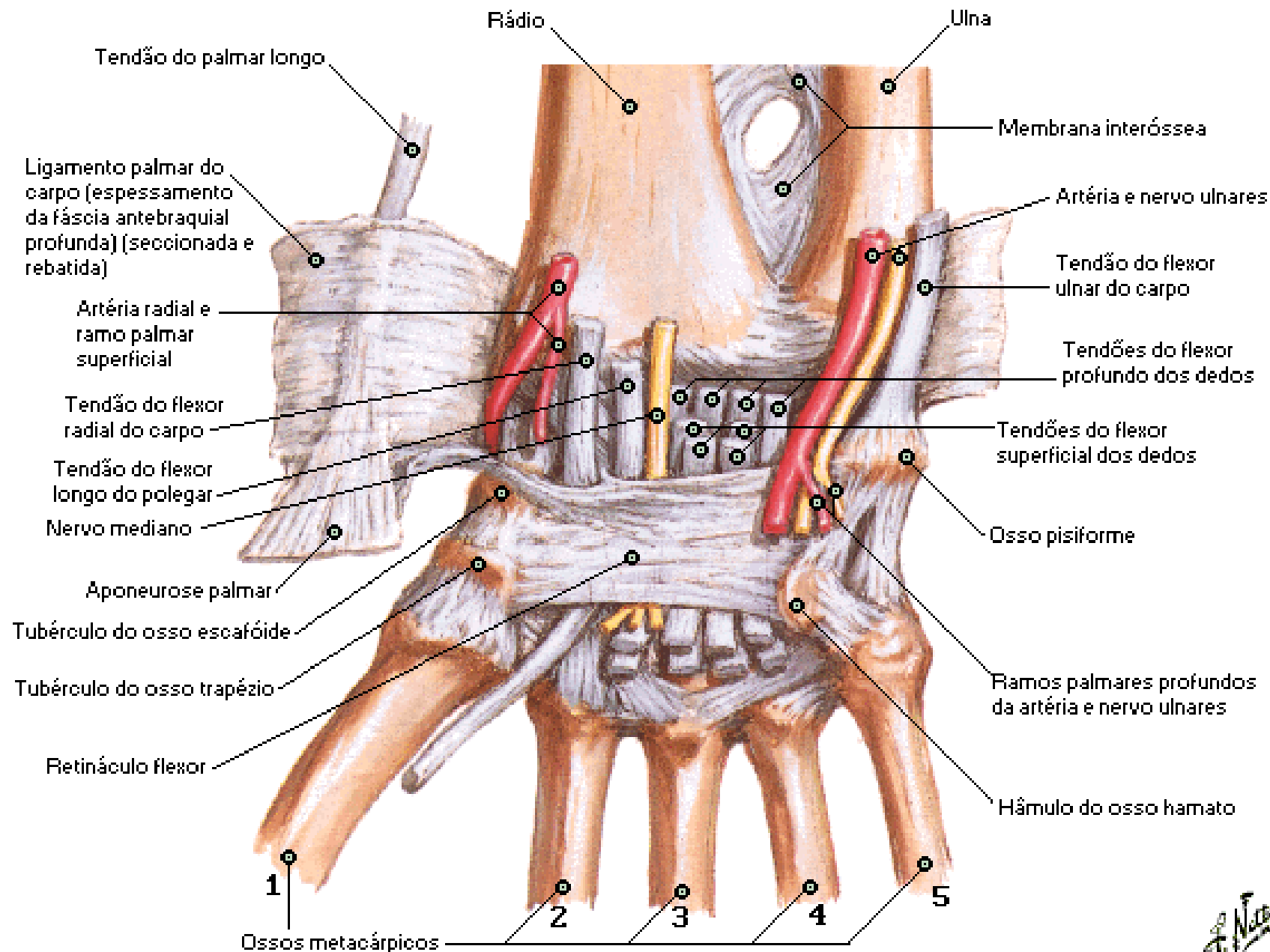
Secções Sagitais



Secções sagitais através do punho e dedo médio

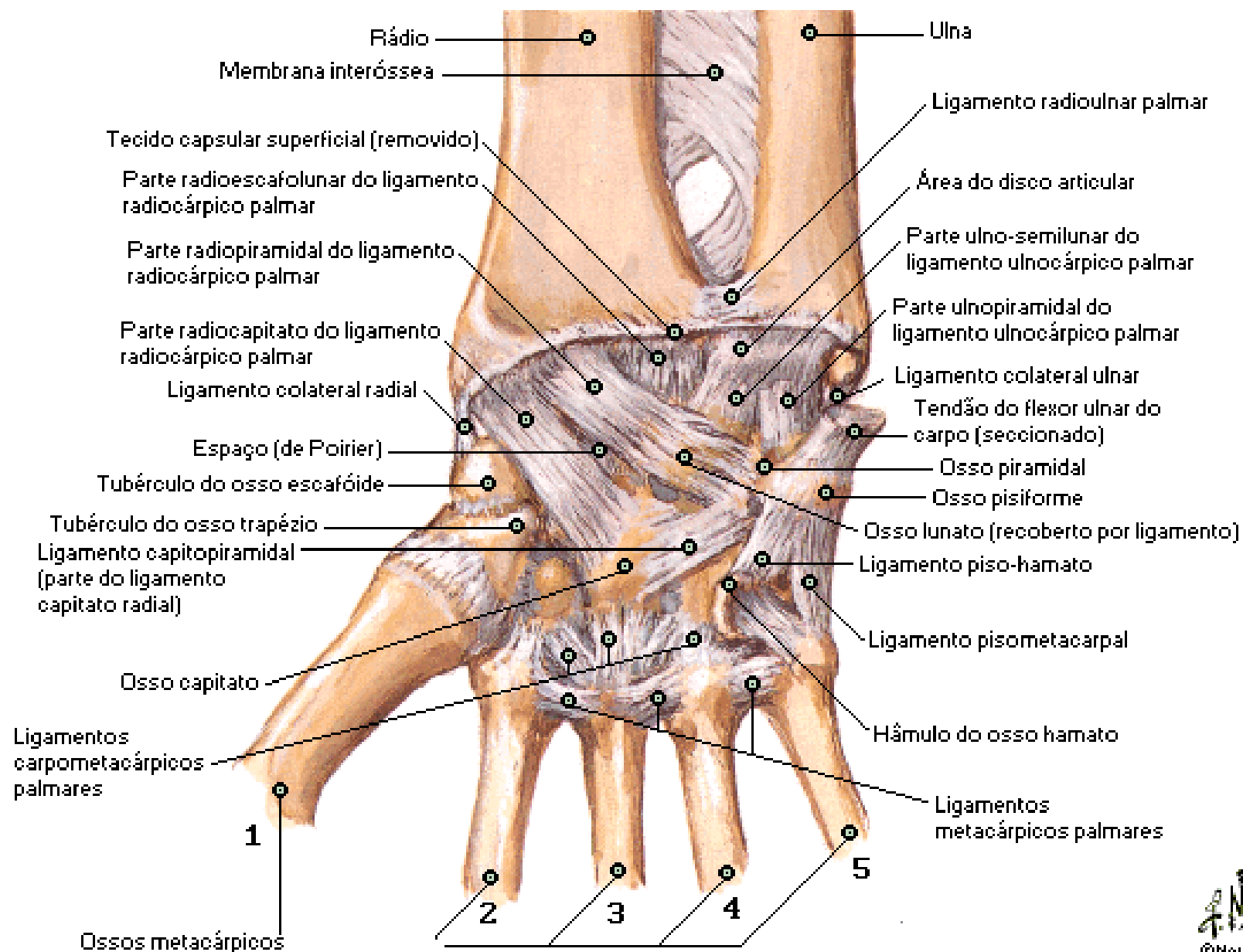
Ligamentos do Punho

Túnel do Carpo - Vista Palmar



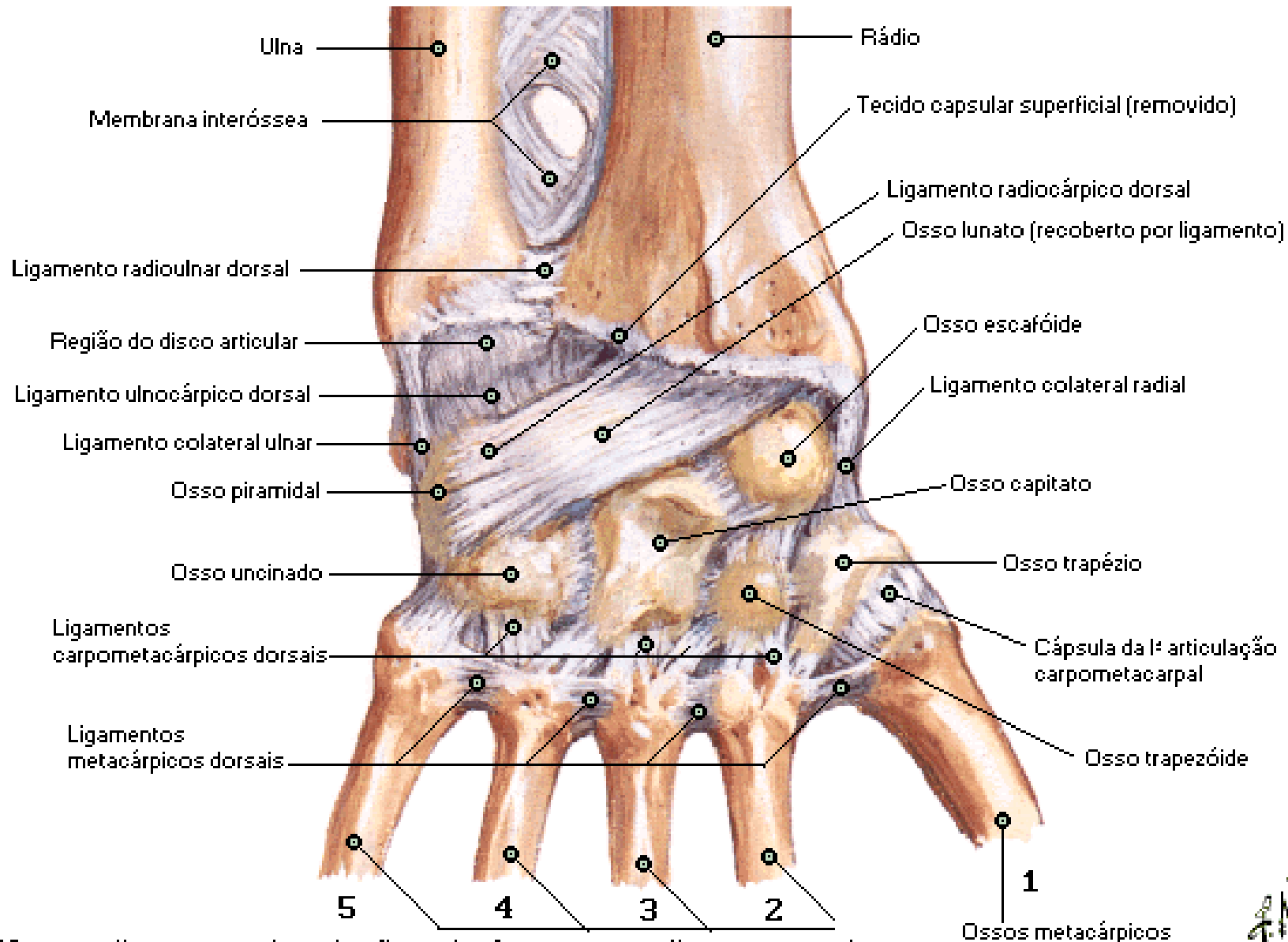
Ligamentos do Punho

Retináculo Flexor Removido - Vista Palmar



Ligamentos do Punho

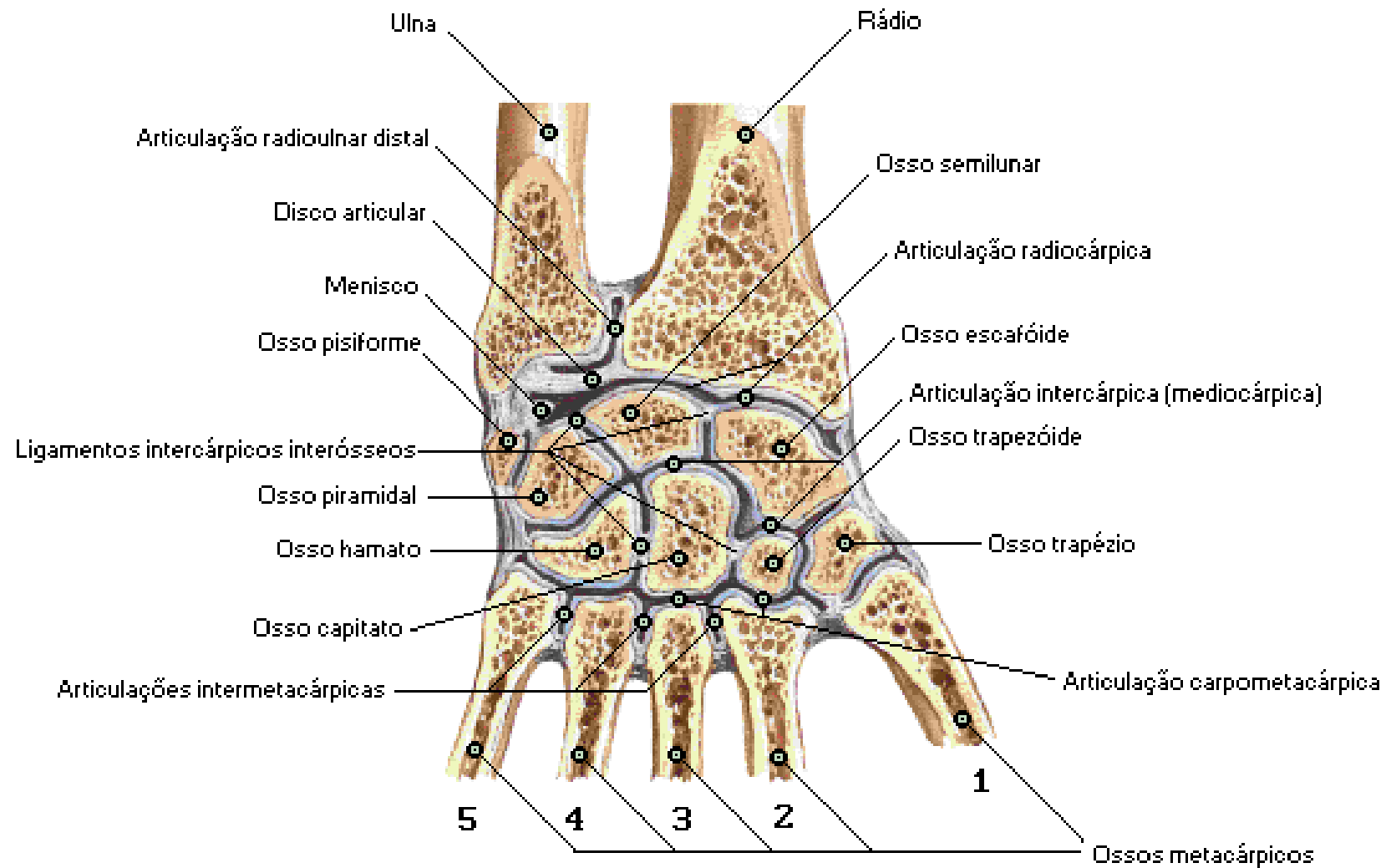
Vista Posterior [Dorsal]



Nota: os ligamentos dorsais são mais tênues que os ligamentos palmares

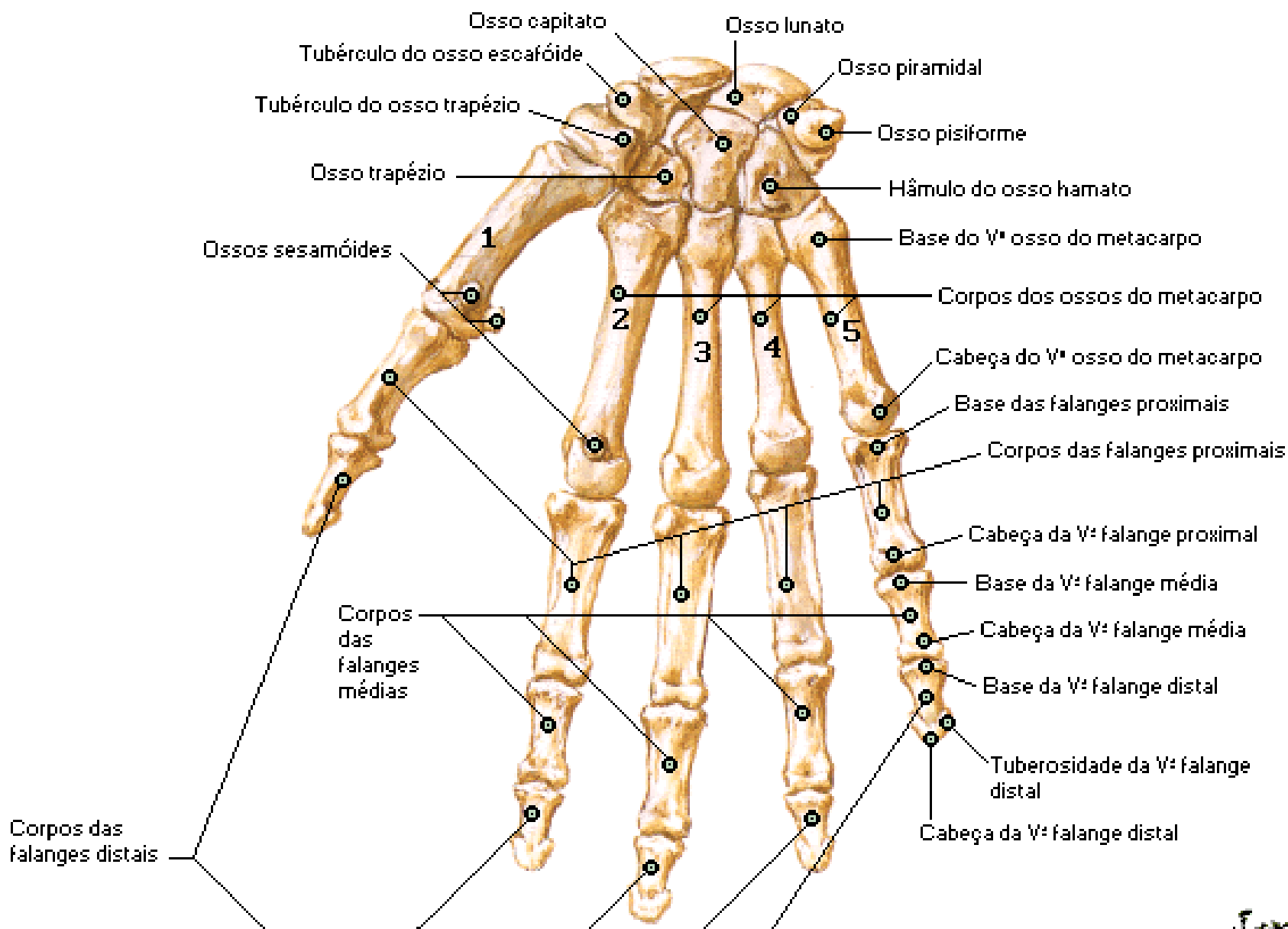
Ligamentos do Punho

Secção Coronal - Vista Dorsal



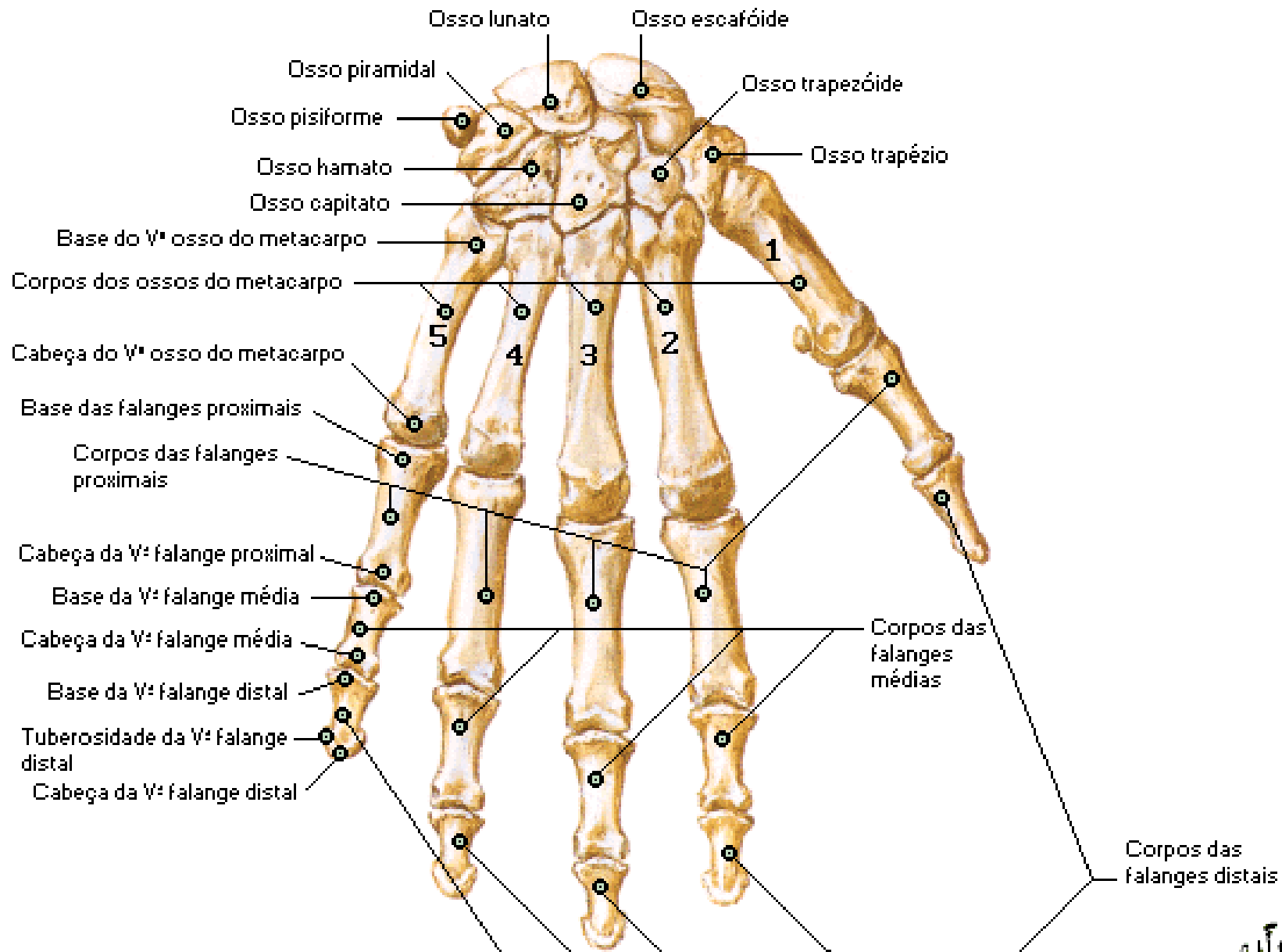
Ossos do Punho e da Mão

Vista Anterior [Palmar]



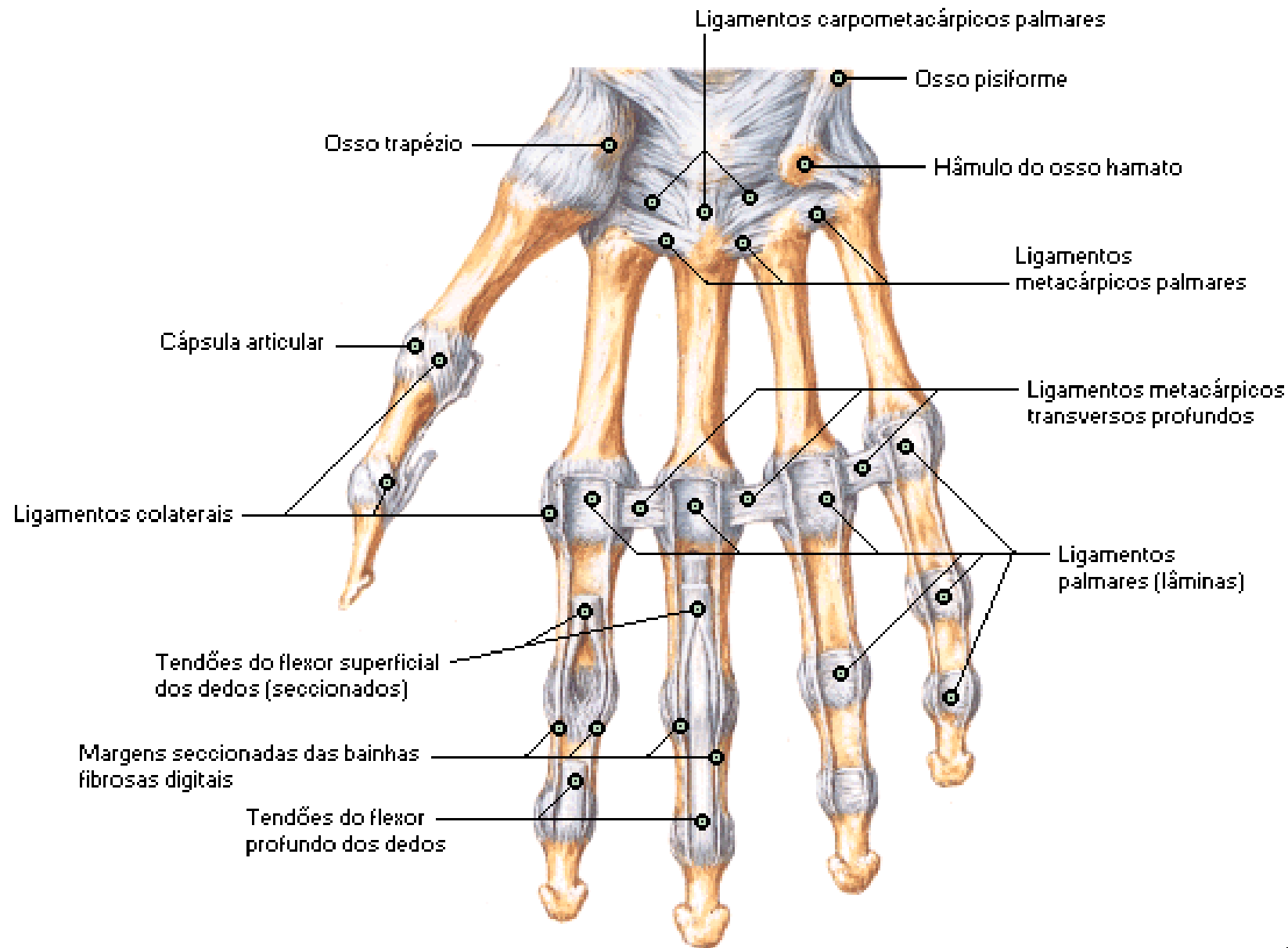
Ossos do Punho e da Mão

Vista Posterior [Dorsal]



Ligamentos Metacarpofalângicos e Interfalângicos

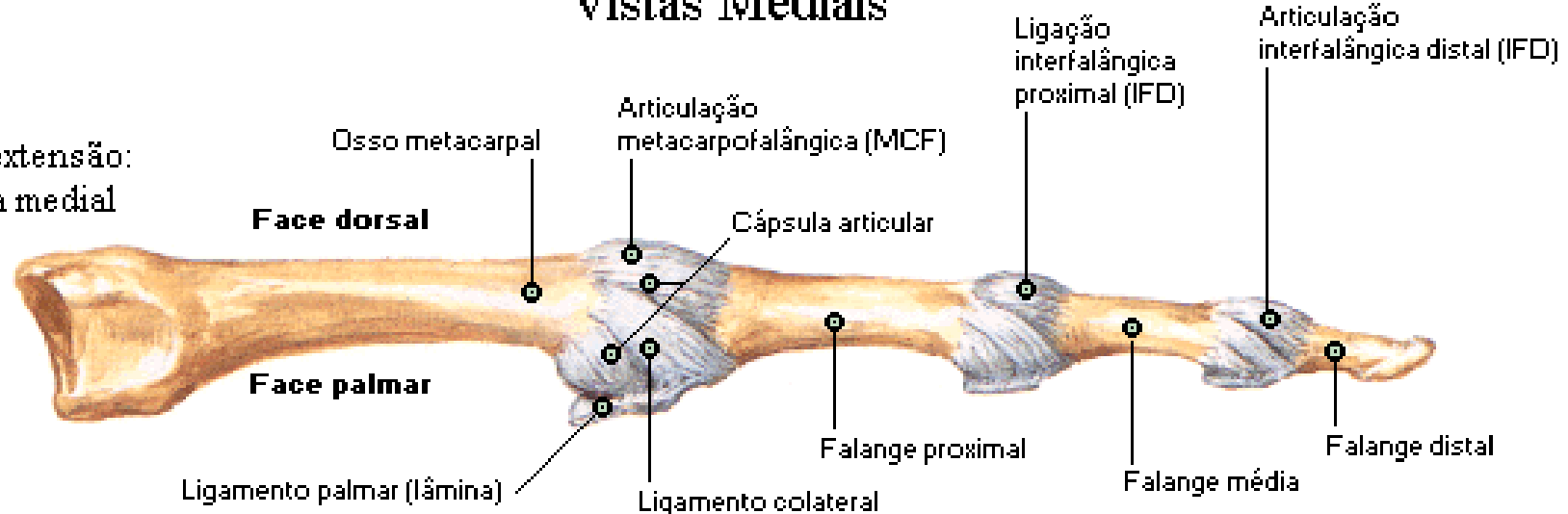
Vista Anterior [Palmar]



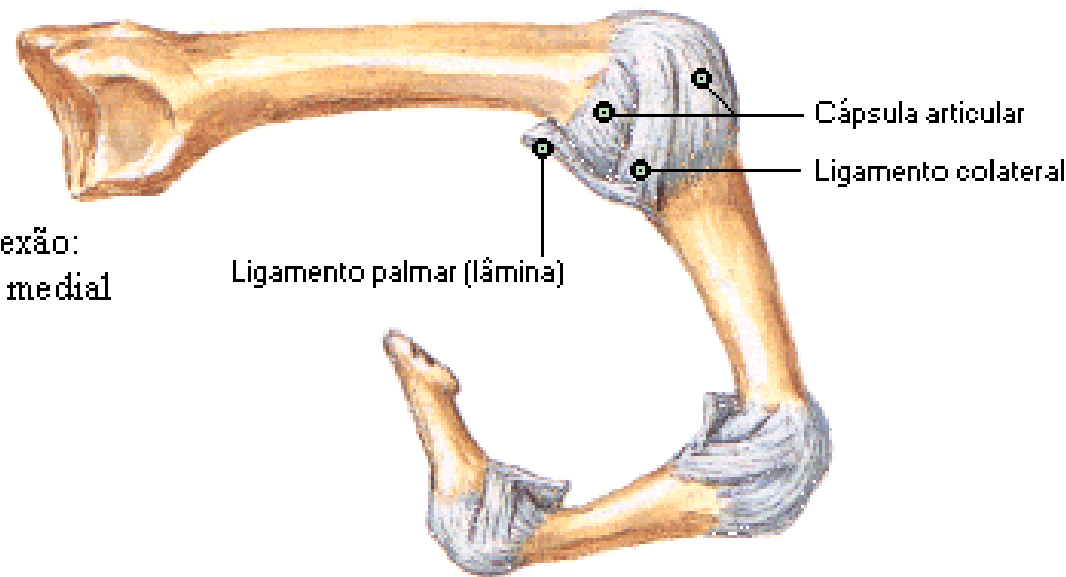
Ligamentos Metacarpofalângicos e Interfalângicos

Vistas Mediais

Em extensão:
vista medial



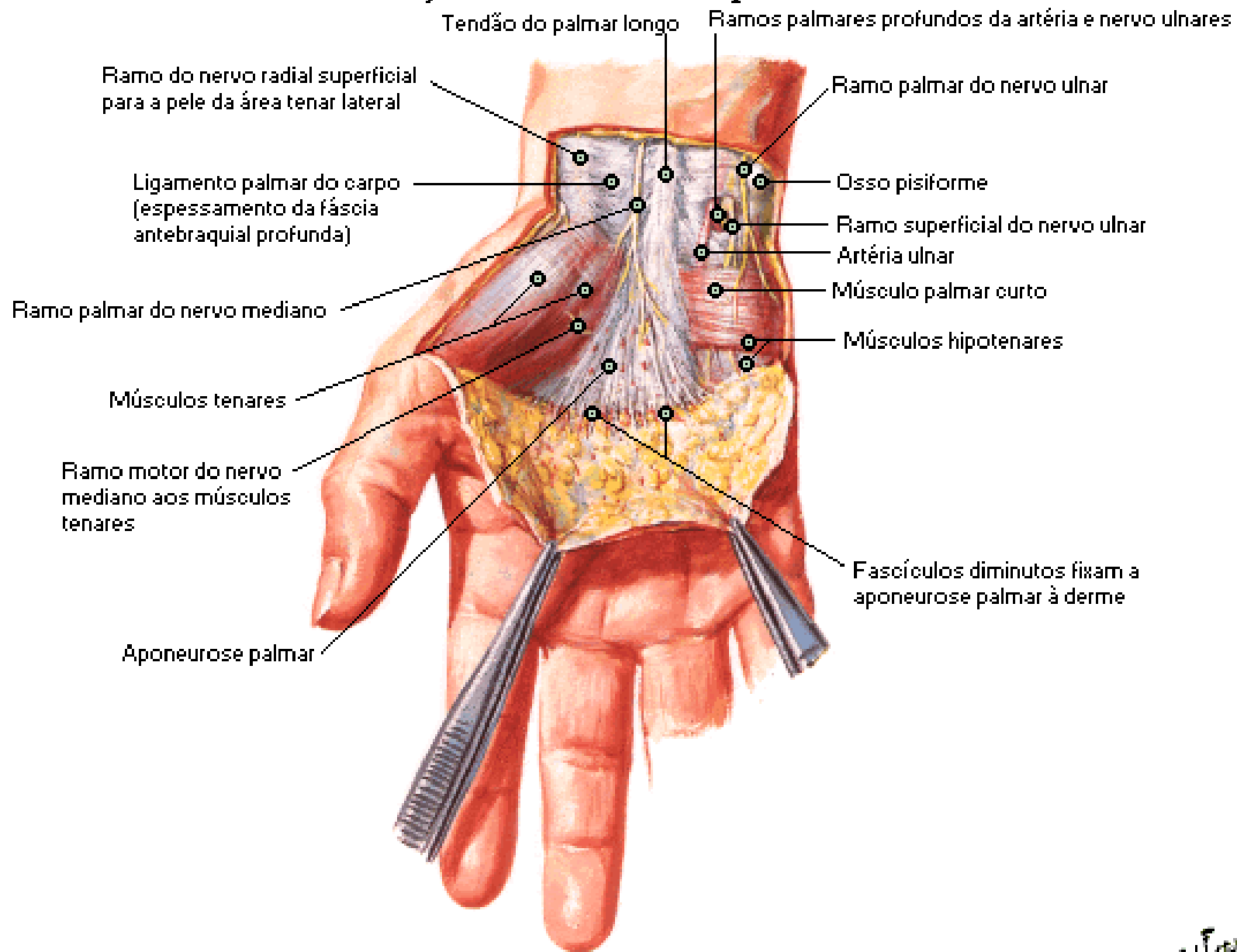
Em flexão:
vista medial



Nota: os ligamentos das articulações metacarpofalângicas e interfalângicas são similares

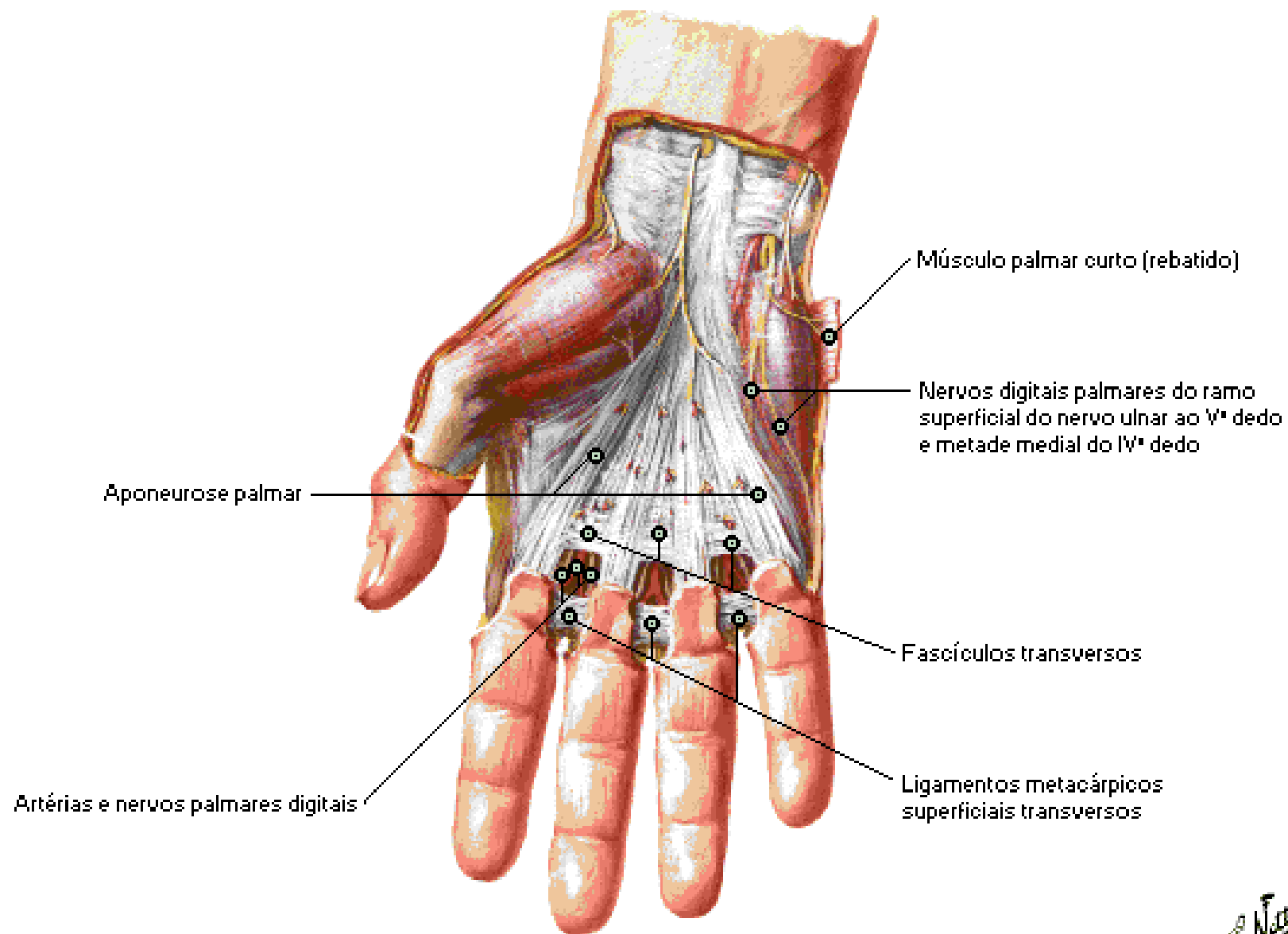
Punho e Mão

Dissecações Palmares Superficiais



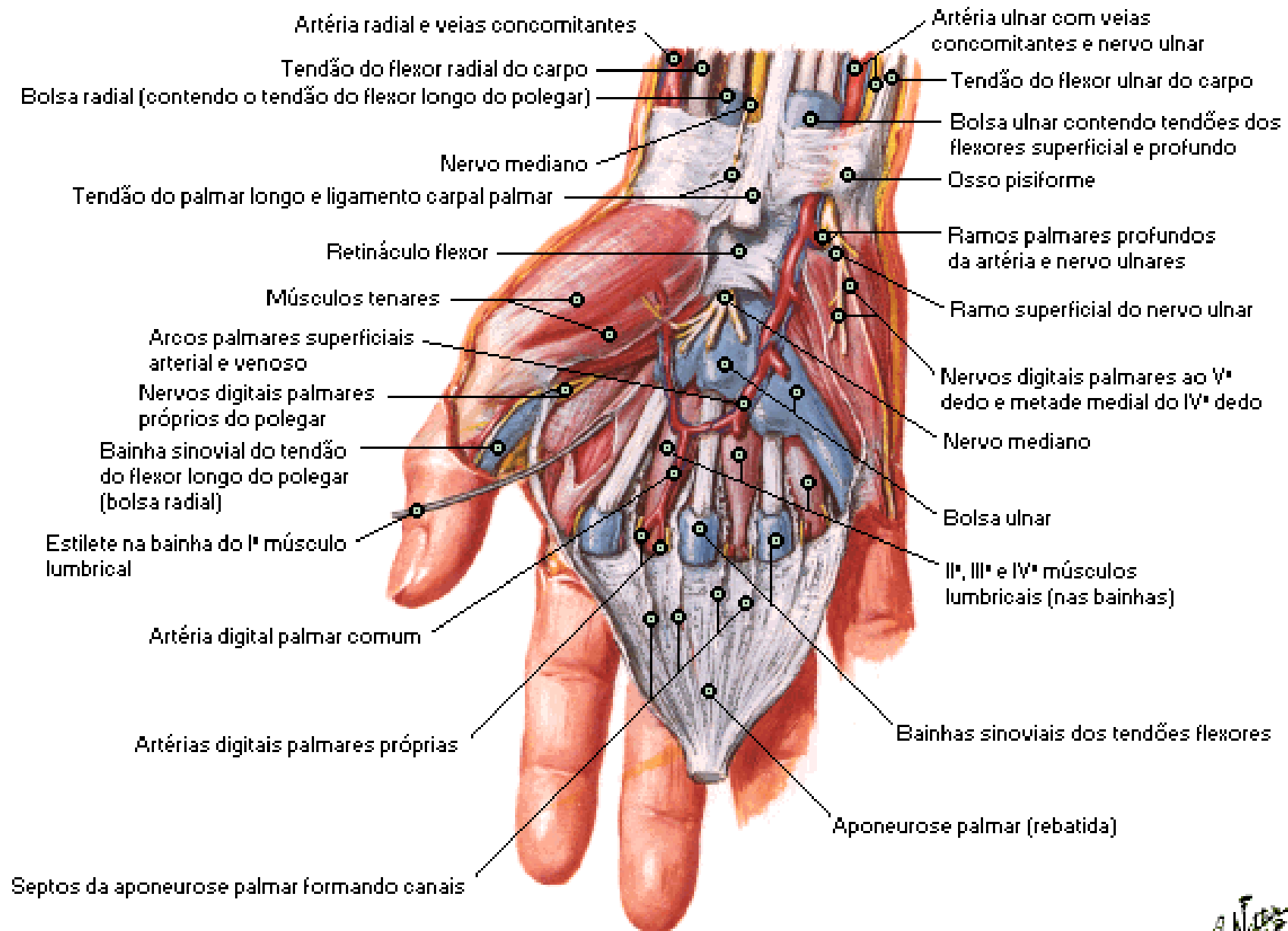
Punho e Mão

Dissecações Palmares Superficiais [Continuação]



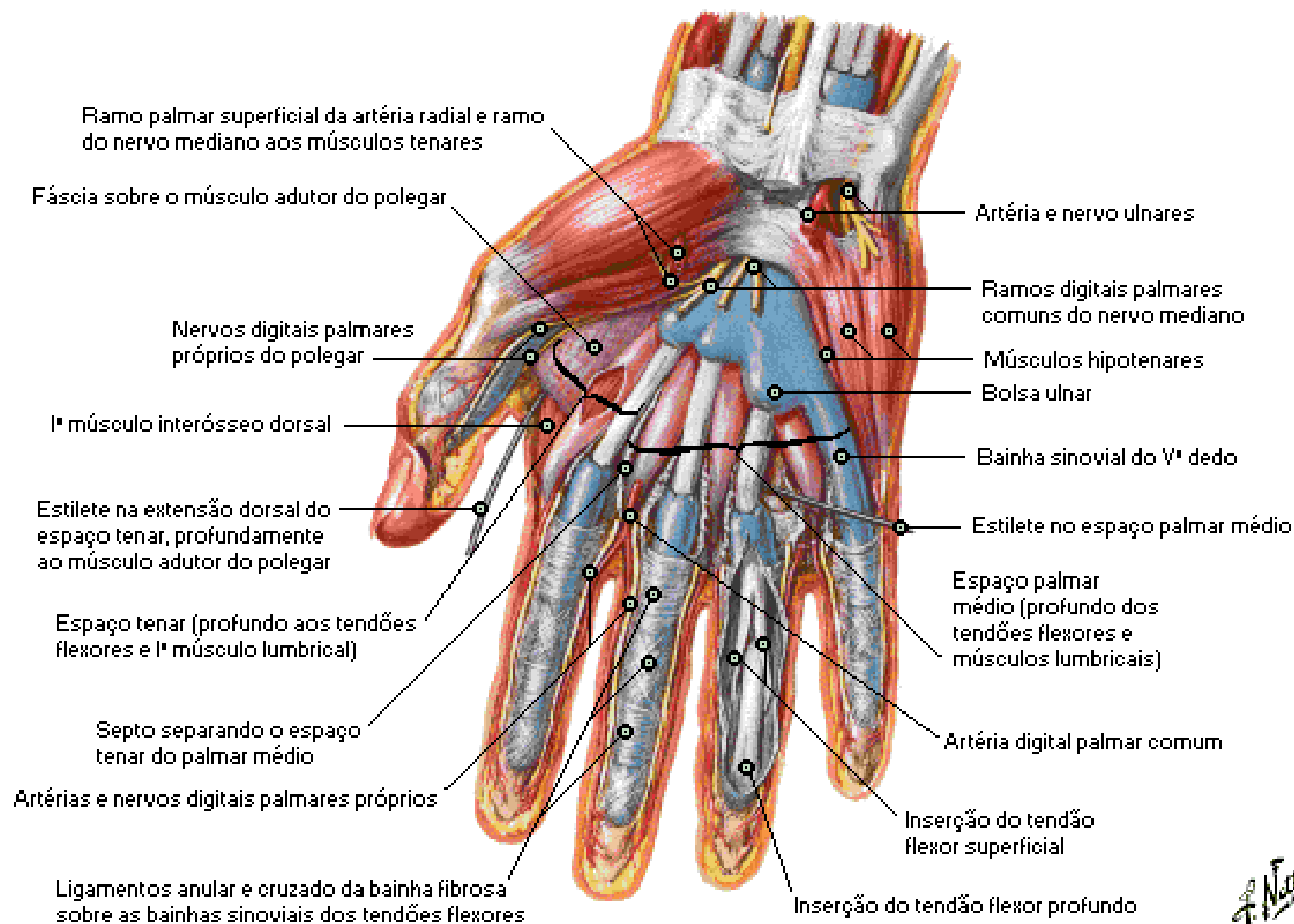
Punho e Mão

Dissecações Palmares Mais Profundas



Punho e Mão

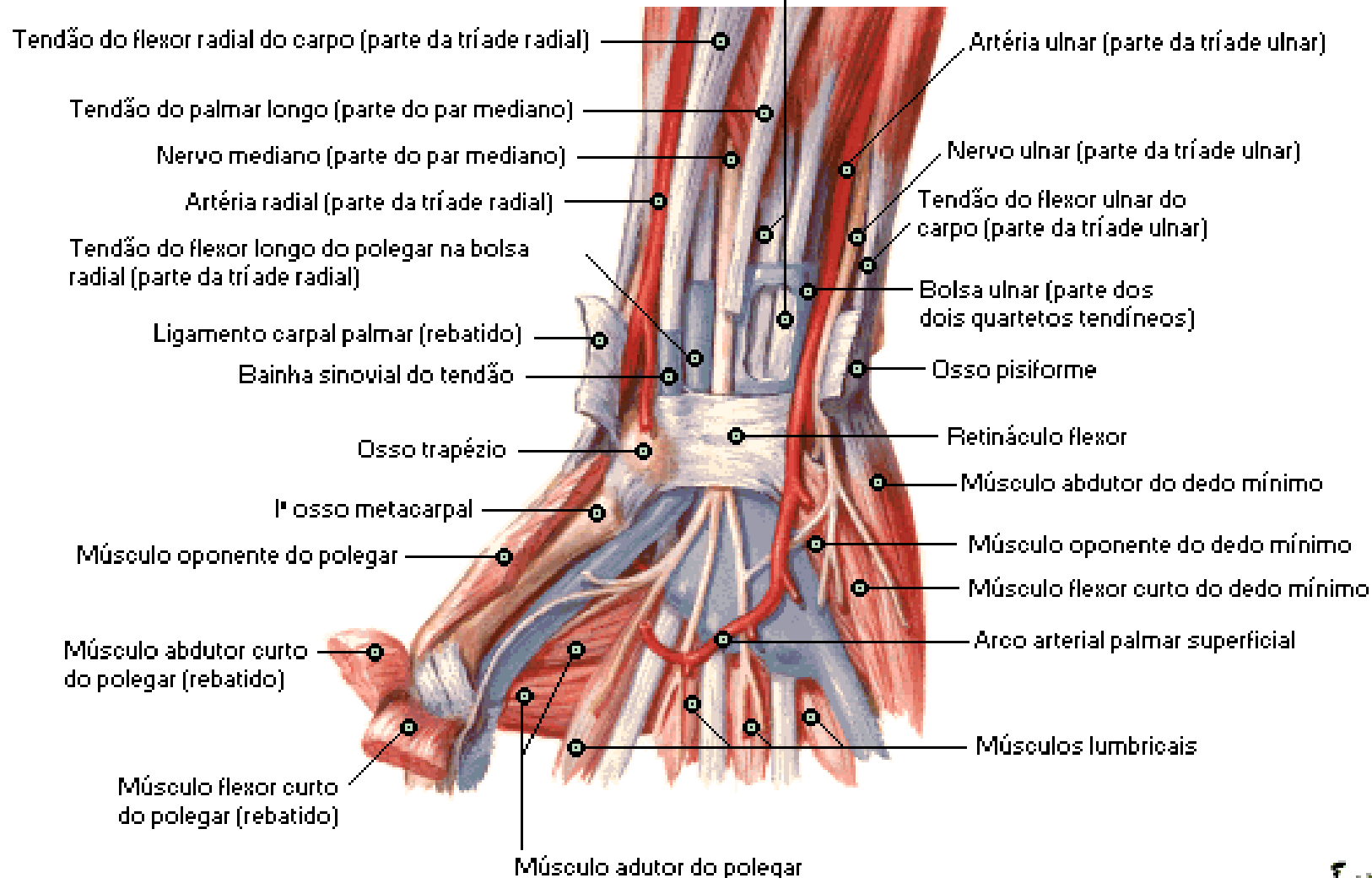
Dissecações Palmares Mais Profundas



Tendões Flexores, Artérias e Nervos no Punho

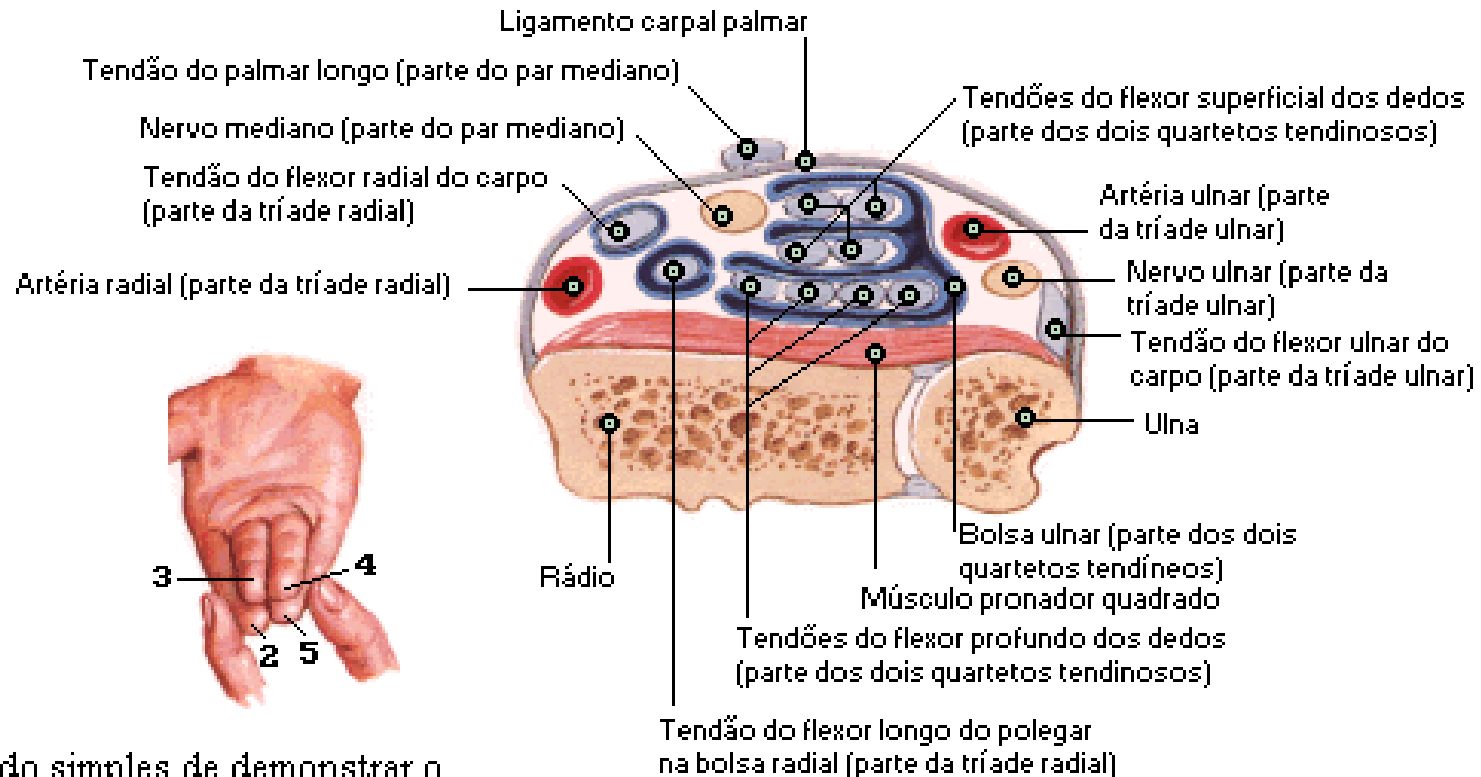
Vista Palmar

Tendões do flexor superficial dos dedos e tendões do flexor profundo dos dedos (dois quartetos tendíneos)



Tendões Flexores, Artérias e Nervos no Punho

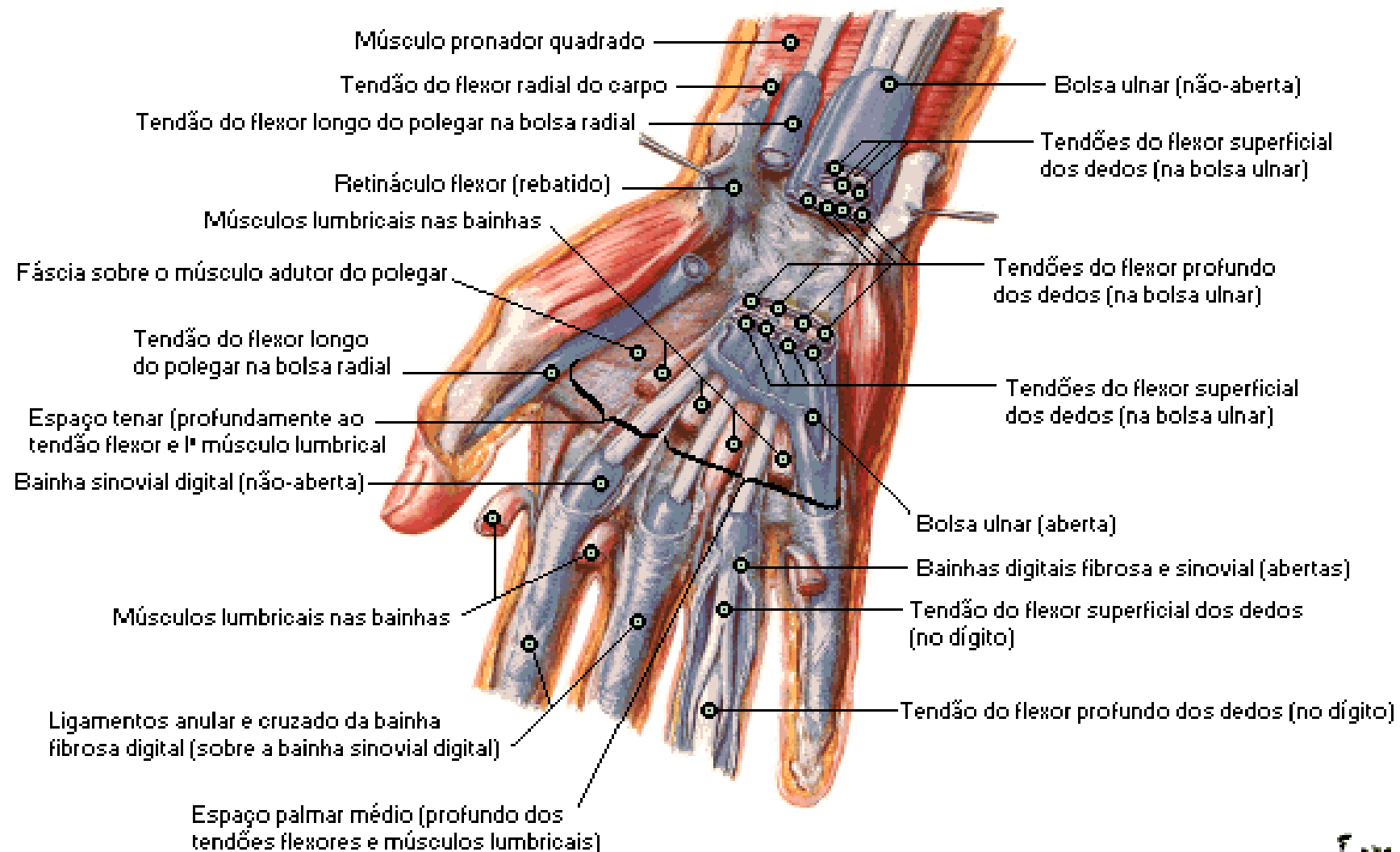
Secção Transversal



Método simples de demonstrar o arranjo dos tendões do flexor superficial dos dedos ao nível do punho

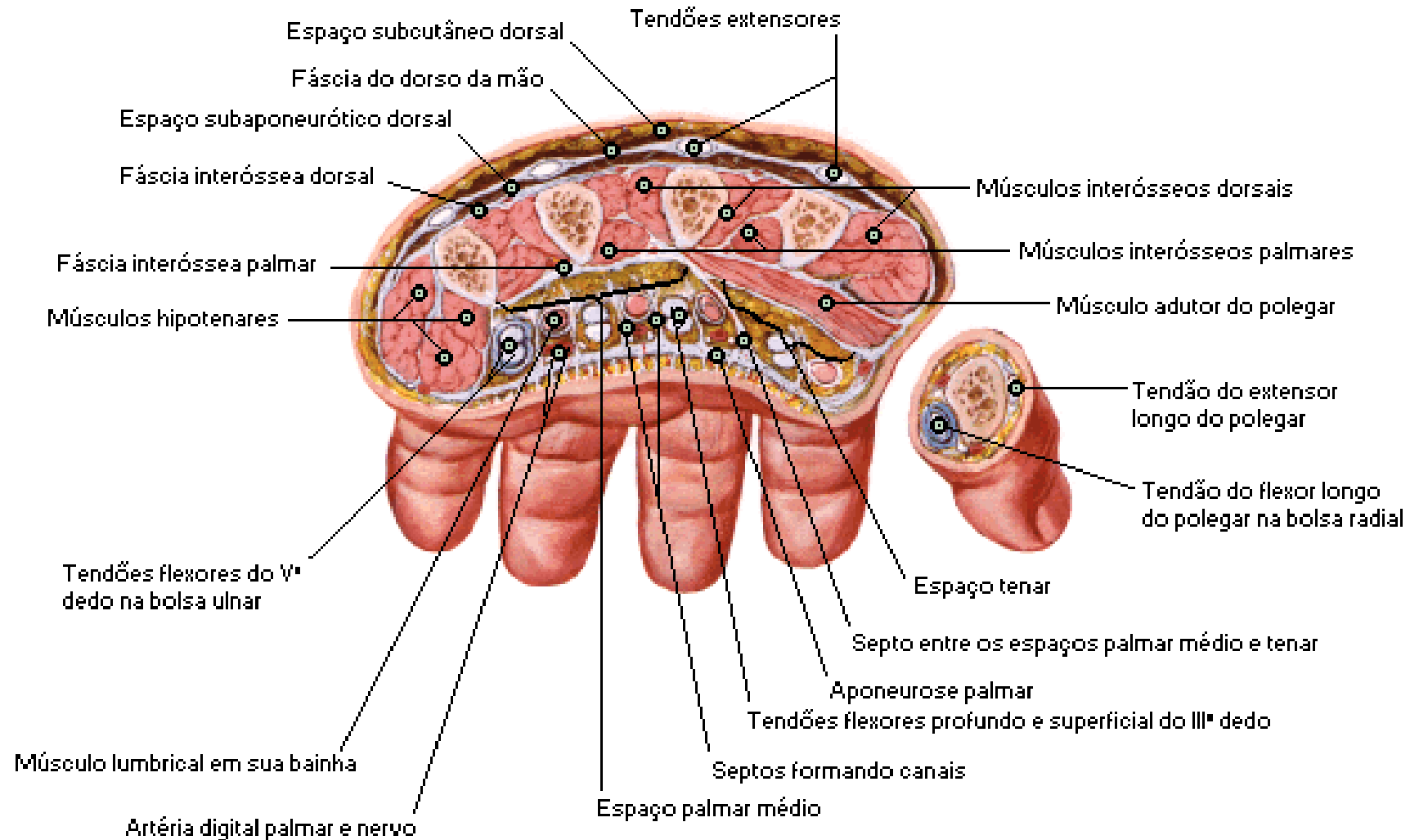
Bolsas, Espaços e Bainhas Tendíneas da Mão

Vista Palmar



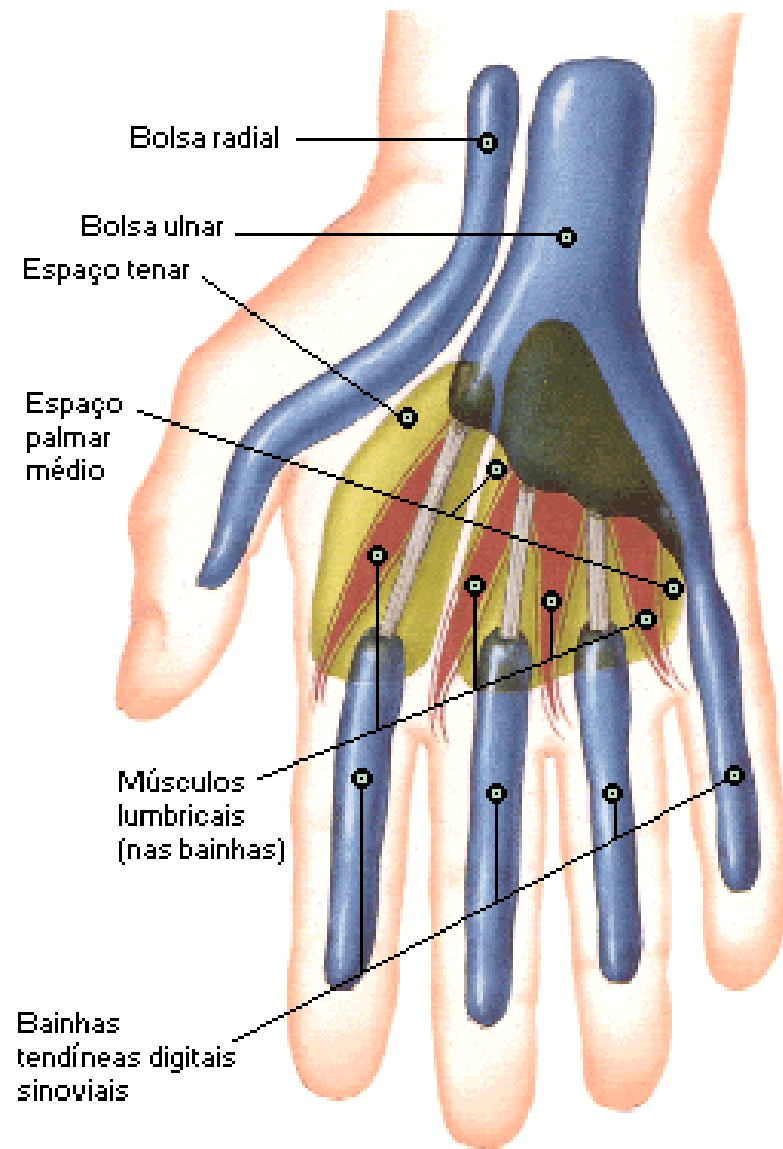
Bolsas, Espaços e Bainhas Tendíneas da Mão

Secção Transversal

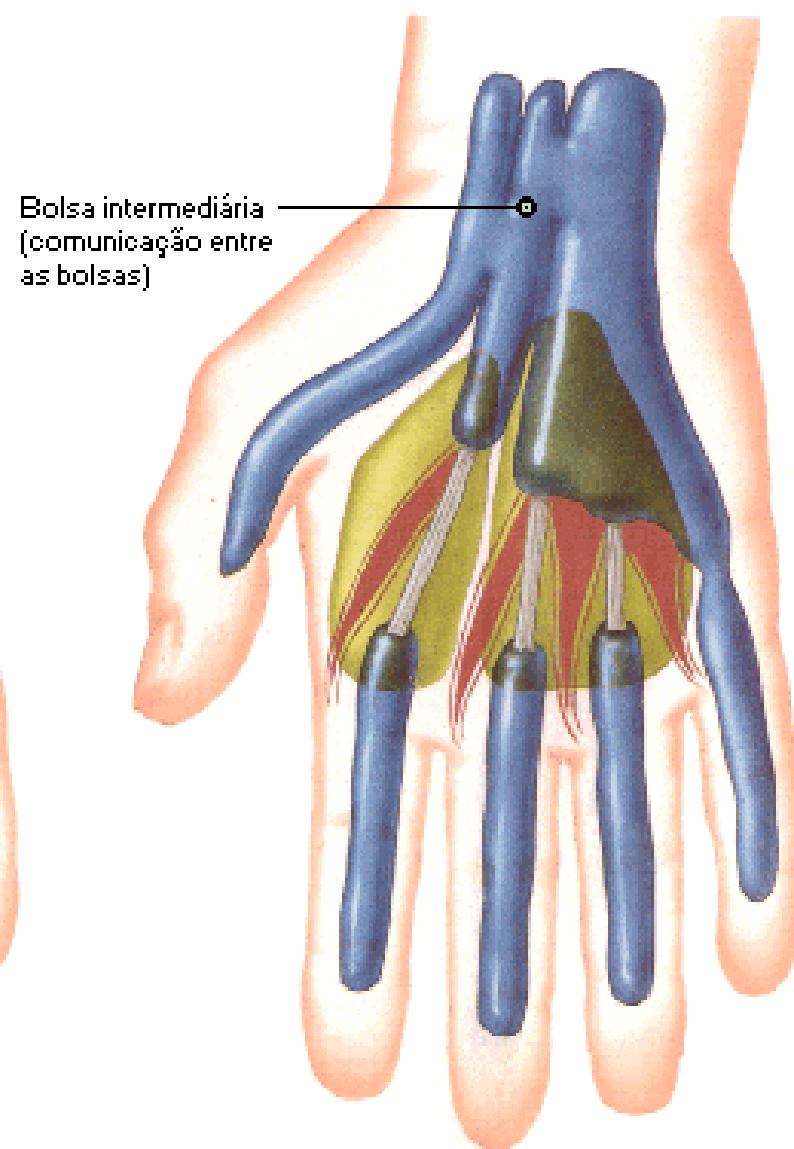


Músculos Lumbricais e Bolsas, Espaços e Bainhas

Esquema



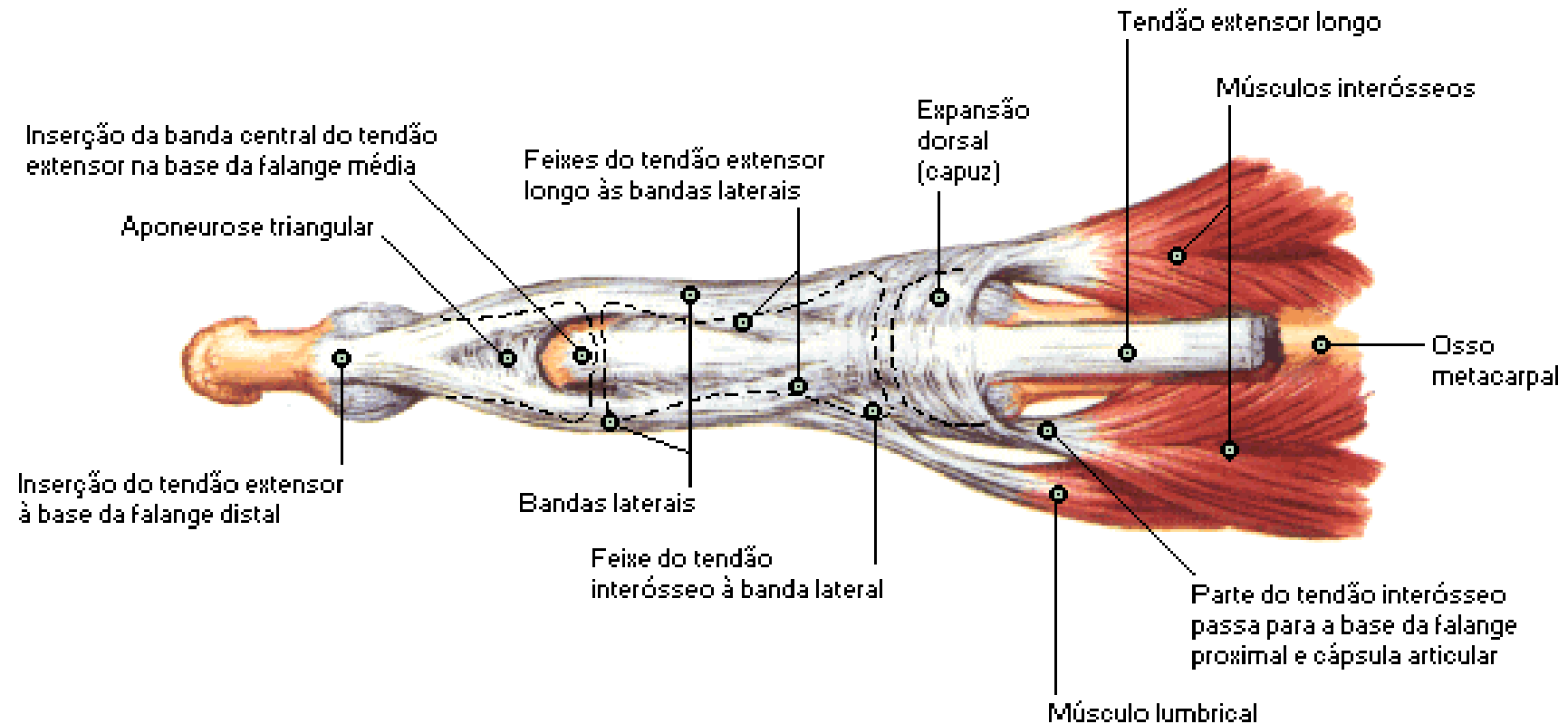
Arranjo habitual



Variação comum

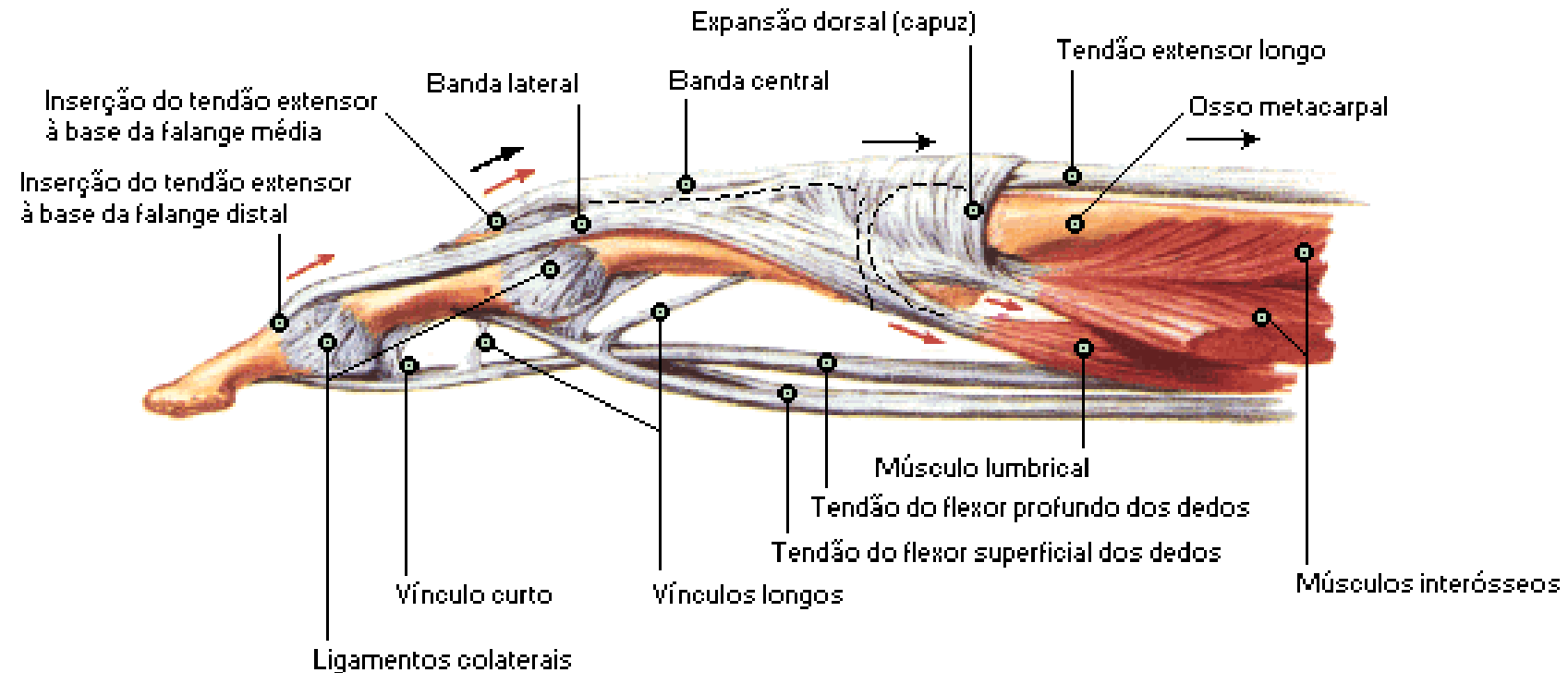
Tendões Flexores e Extensores nos Dedos

Vista Posterior [Dorsal]



Tendões Flexores e Extensores nos Dedos

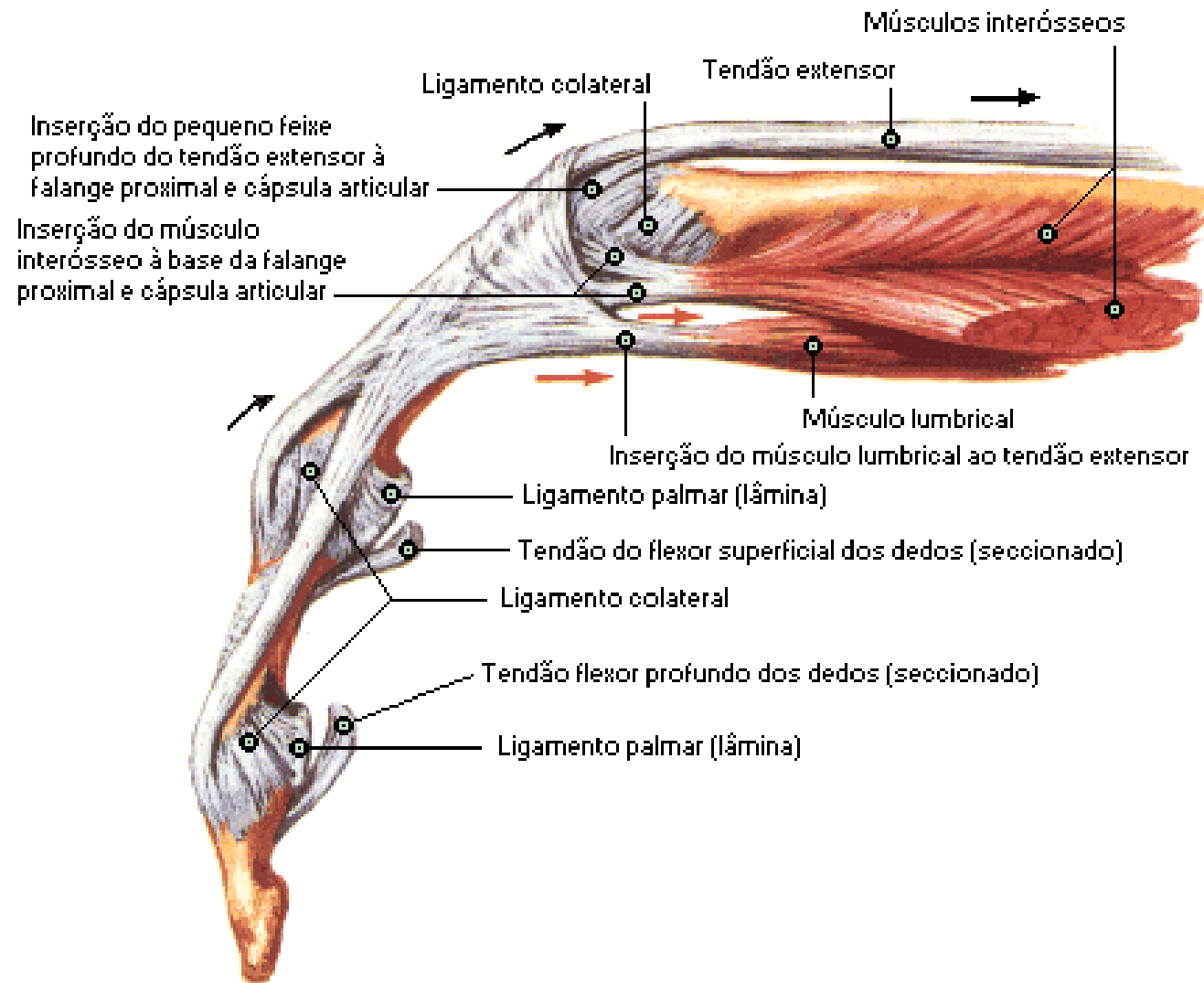
Dedo em Extensão - Vista Lateral



Nota: as setas pretas indicam o tendão extensor longo sendo tracionado; as setas vermelhas indicam a tração dos músculos interósseos e lumbricais

Tendões Flexores e Extensores nos Dedos

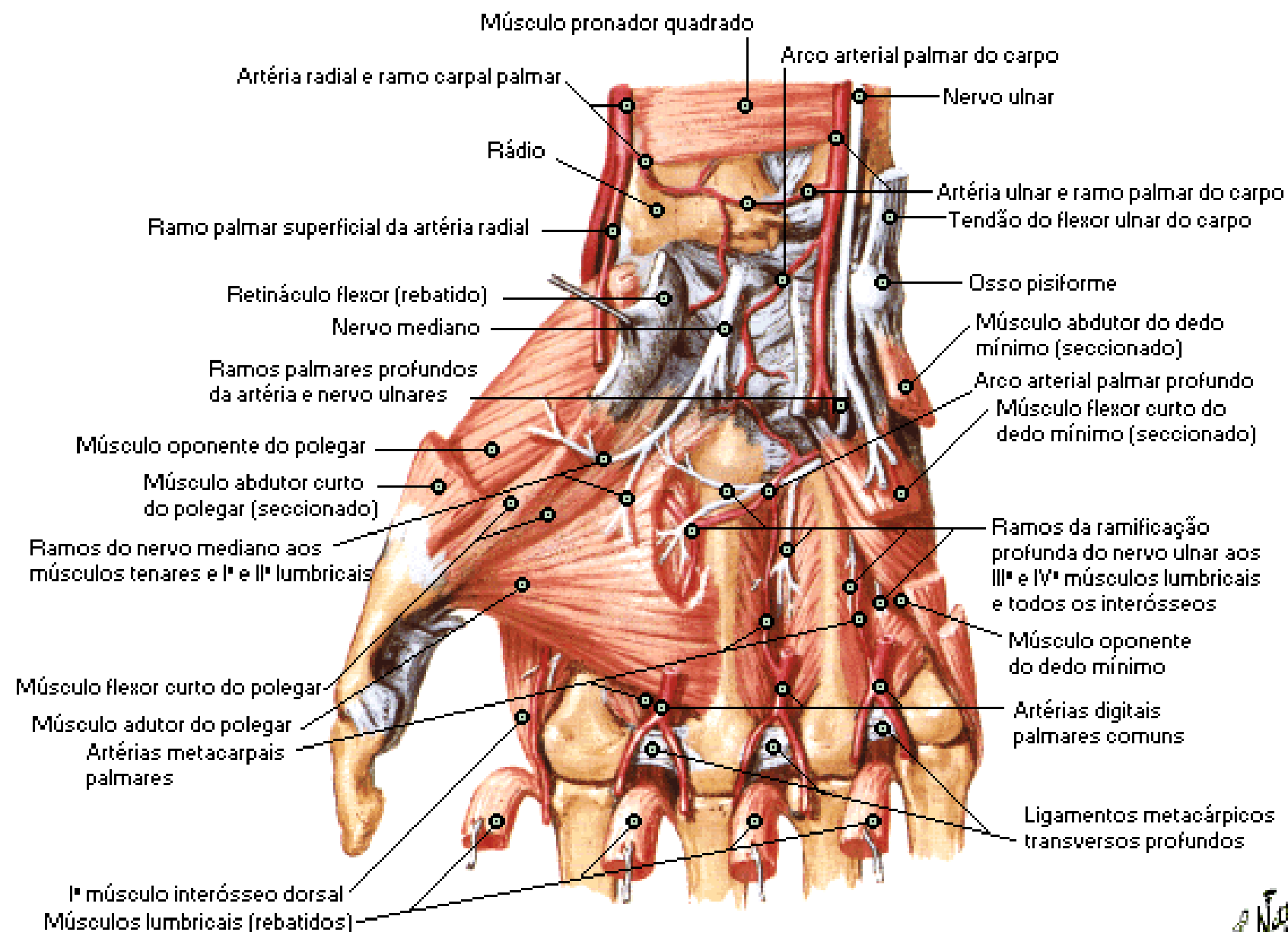
Dedo em Flexão - Vista Lateral



Nota: as setas pretas indicam o tendão extensor longo sendo tracionado; as setas vermelhas indicam a tração dos músculos interósseos e lumbricais

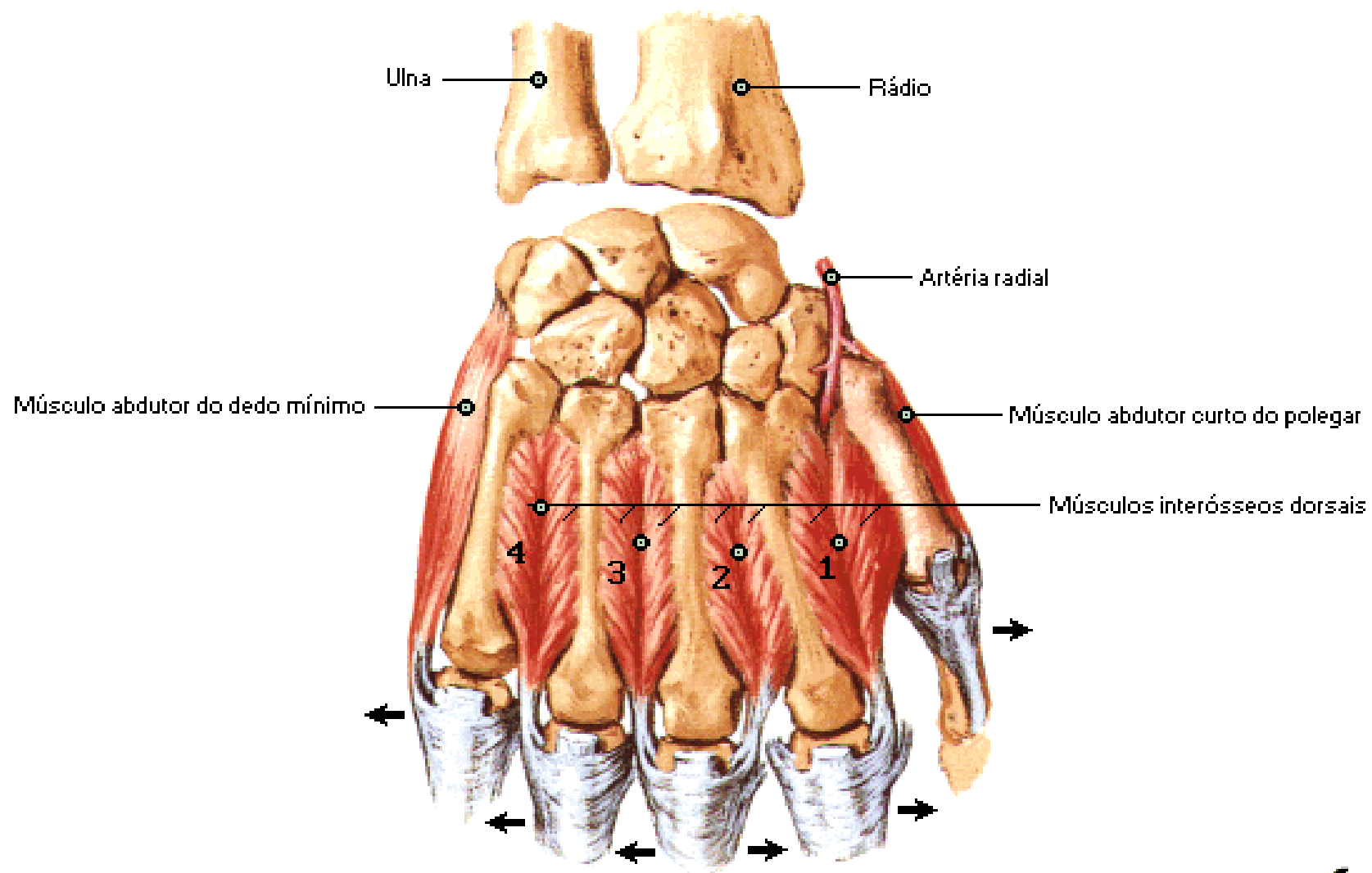
Músculos Intrínsecos da Mão

Vista Anterior [Palmar]



Músculos Intrínsecos da Mão

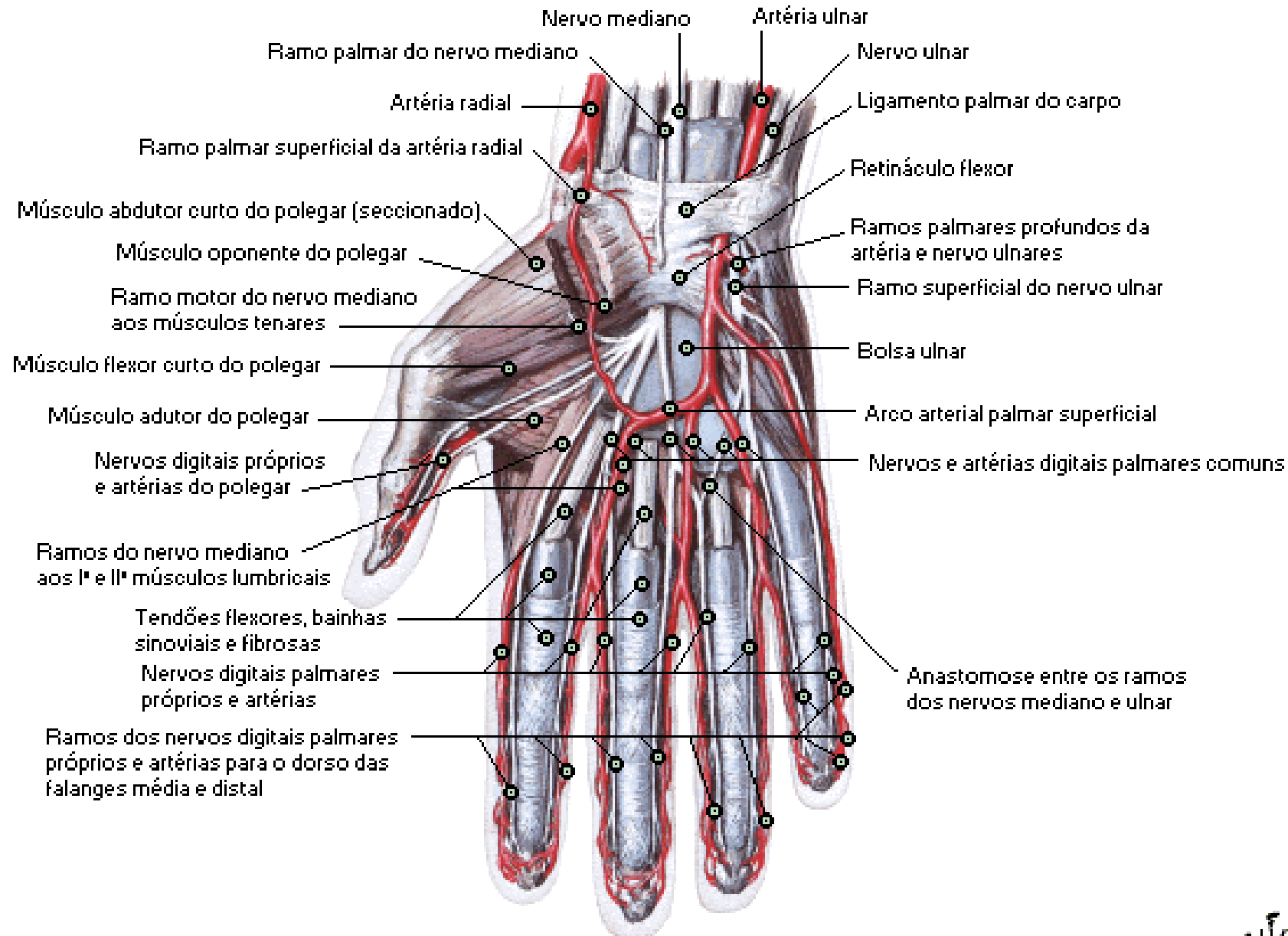
Vista Posterior [Dorsal]



Nota: as setas indicam a ação dos músculos

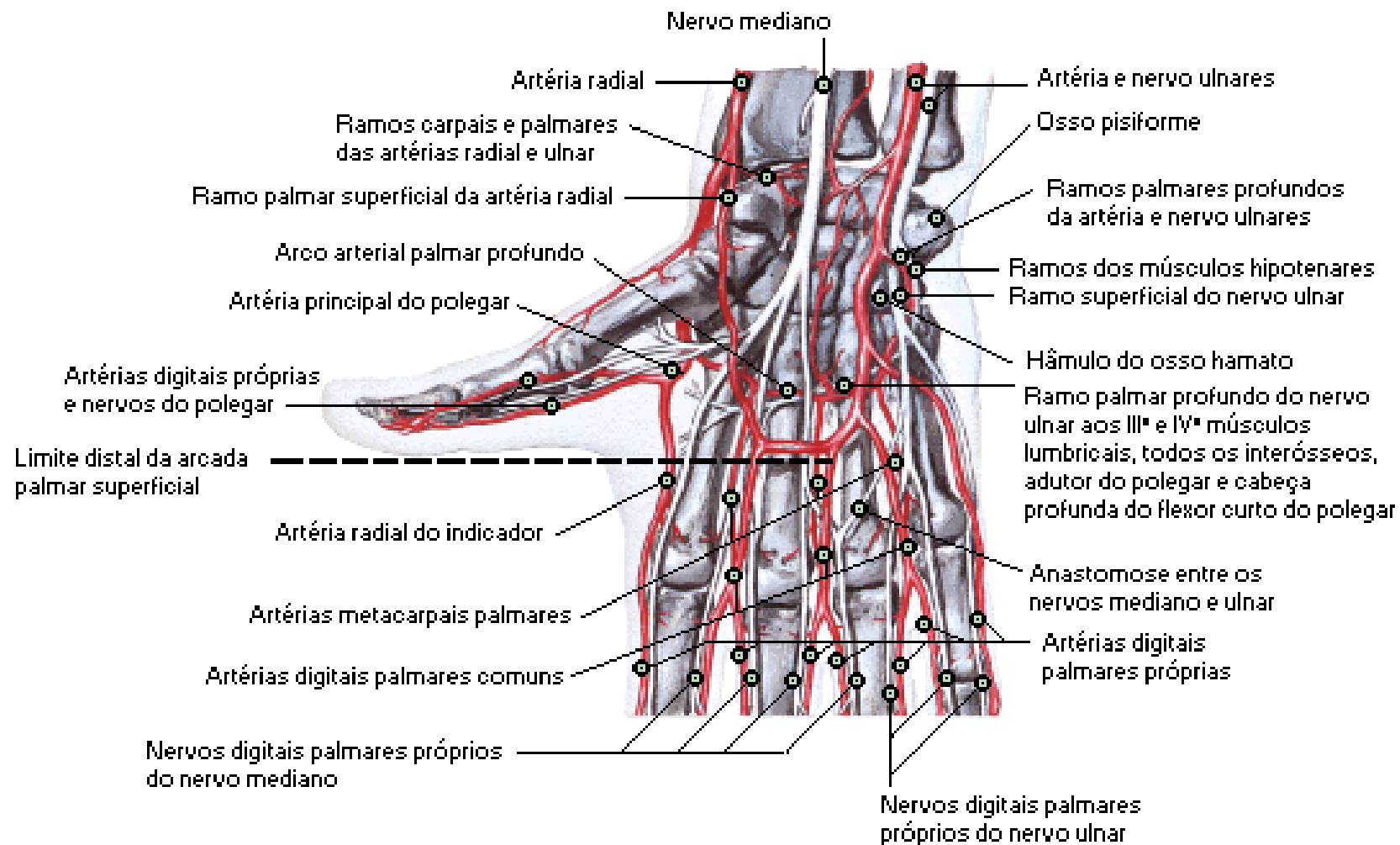
Artérias e Nervos da Mão

Vista Palmar



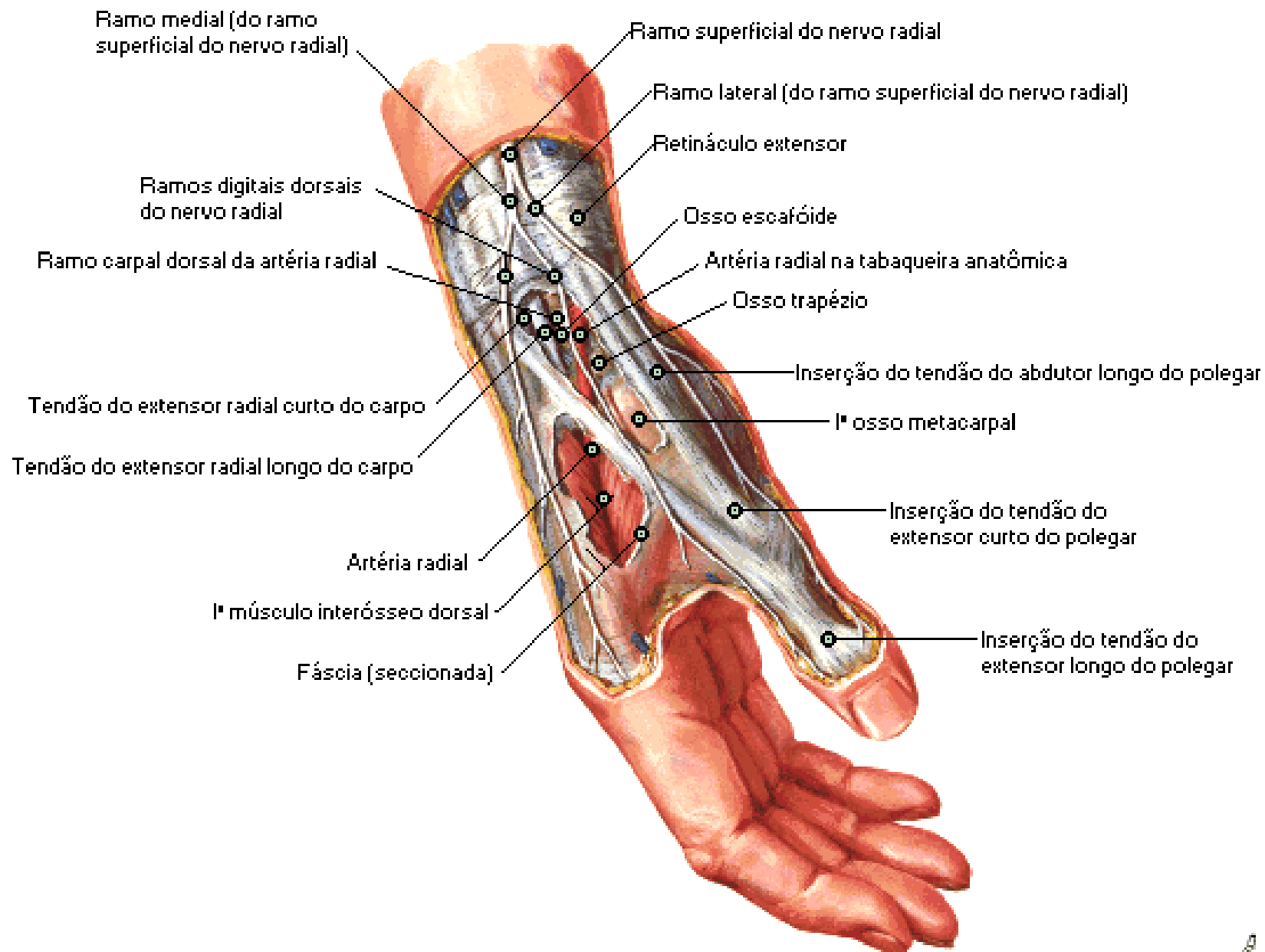
Artérias e Nervos da Mão

Vista Palmar



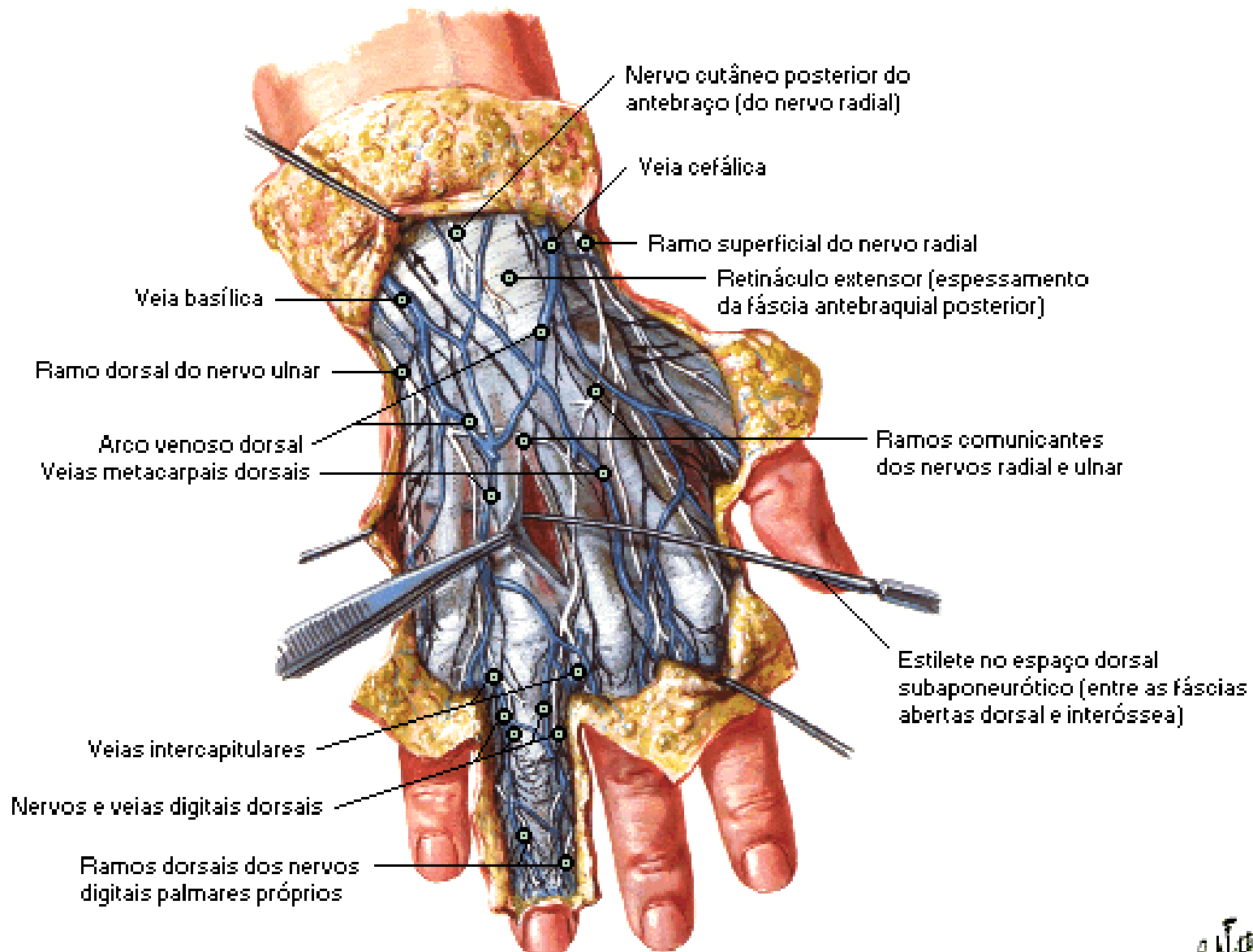
Punho e Mão

Dissecação Radial Superficial



Punho e Mão

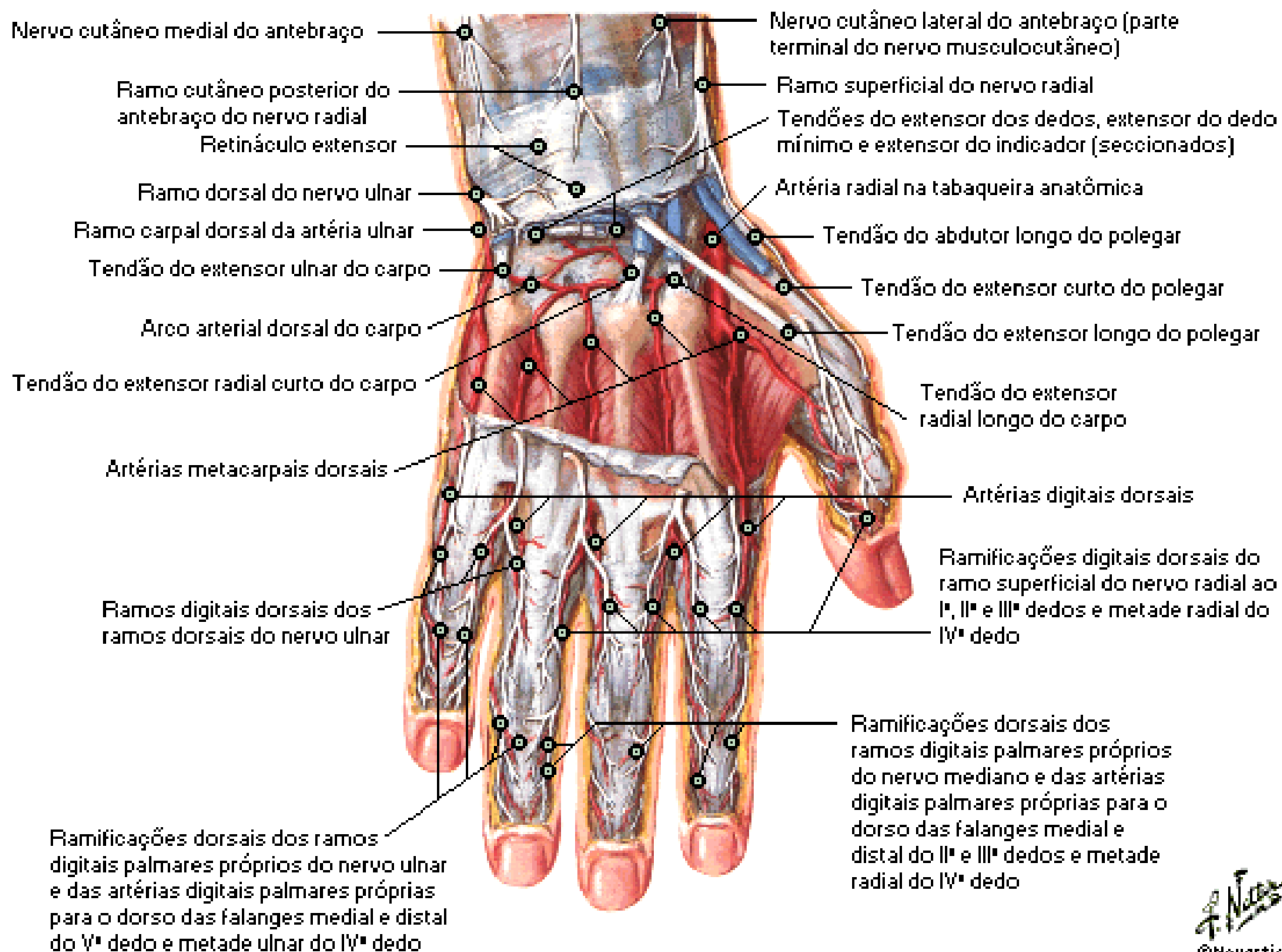
Dissecação Dorsal Superficial



Nota: as vias linfáticas são mostradas em preto; as setas indicam a direção da drenagem

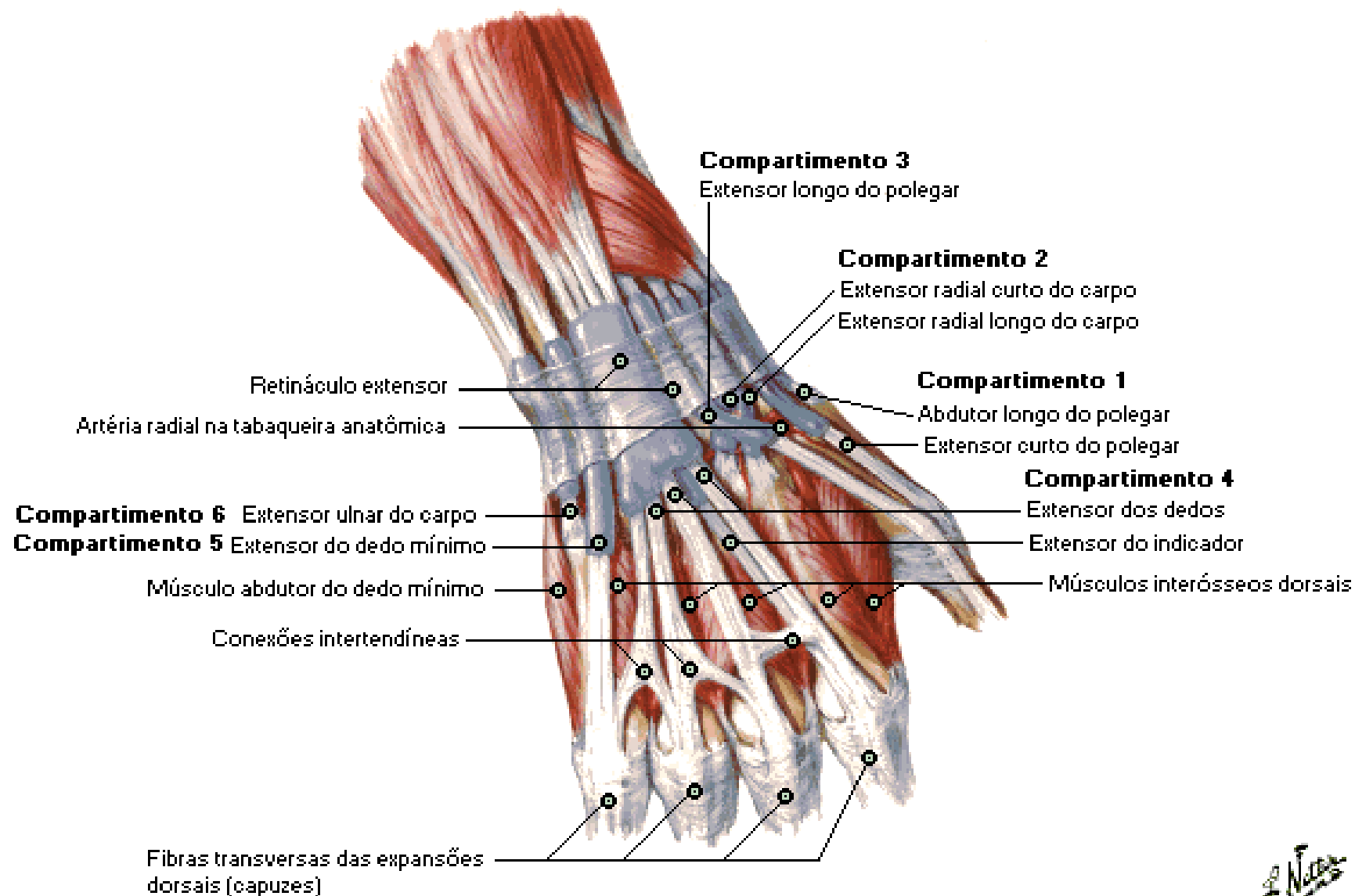
Punho e Mão

Dissecação Dorsal Profunda



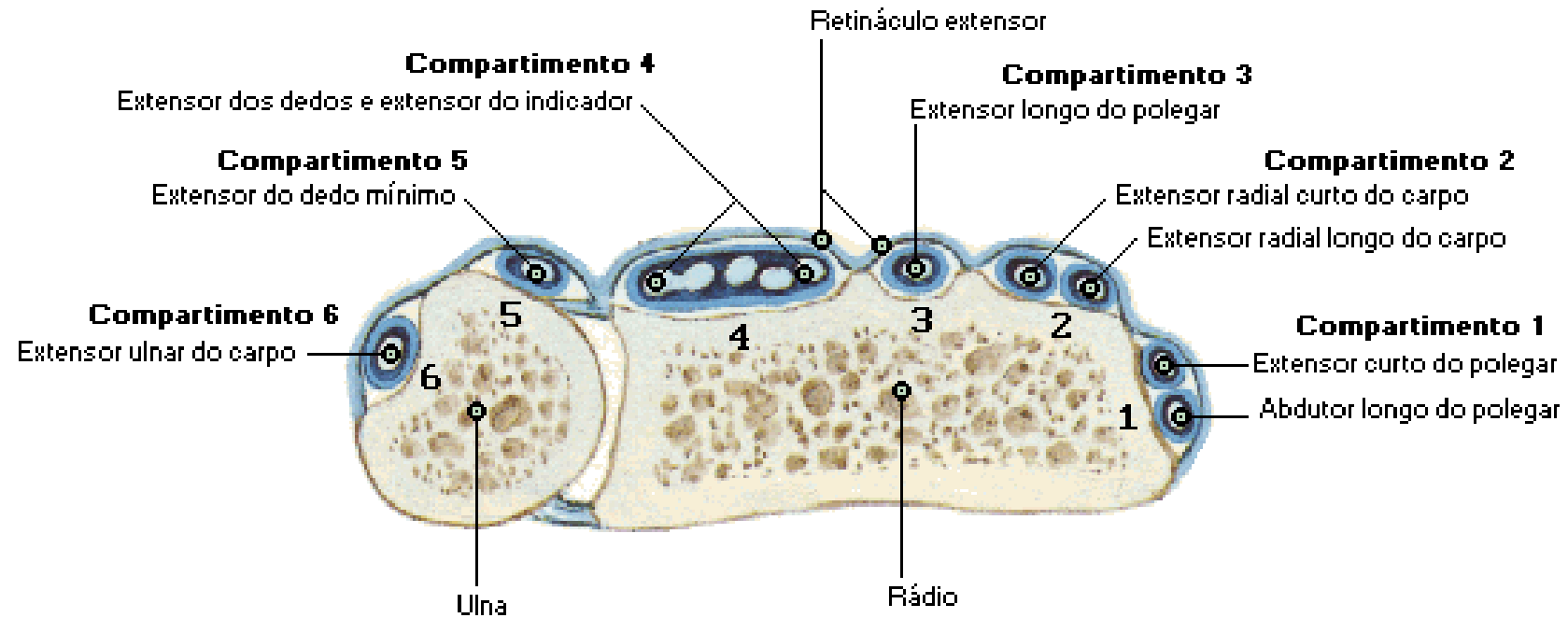
Tendões Extensores do Punho

Vista Posterior [Dorsal]



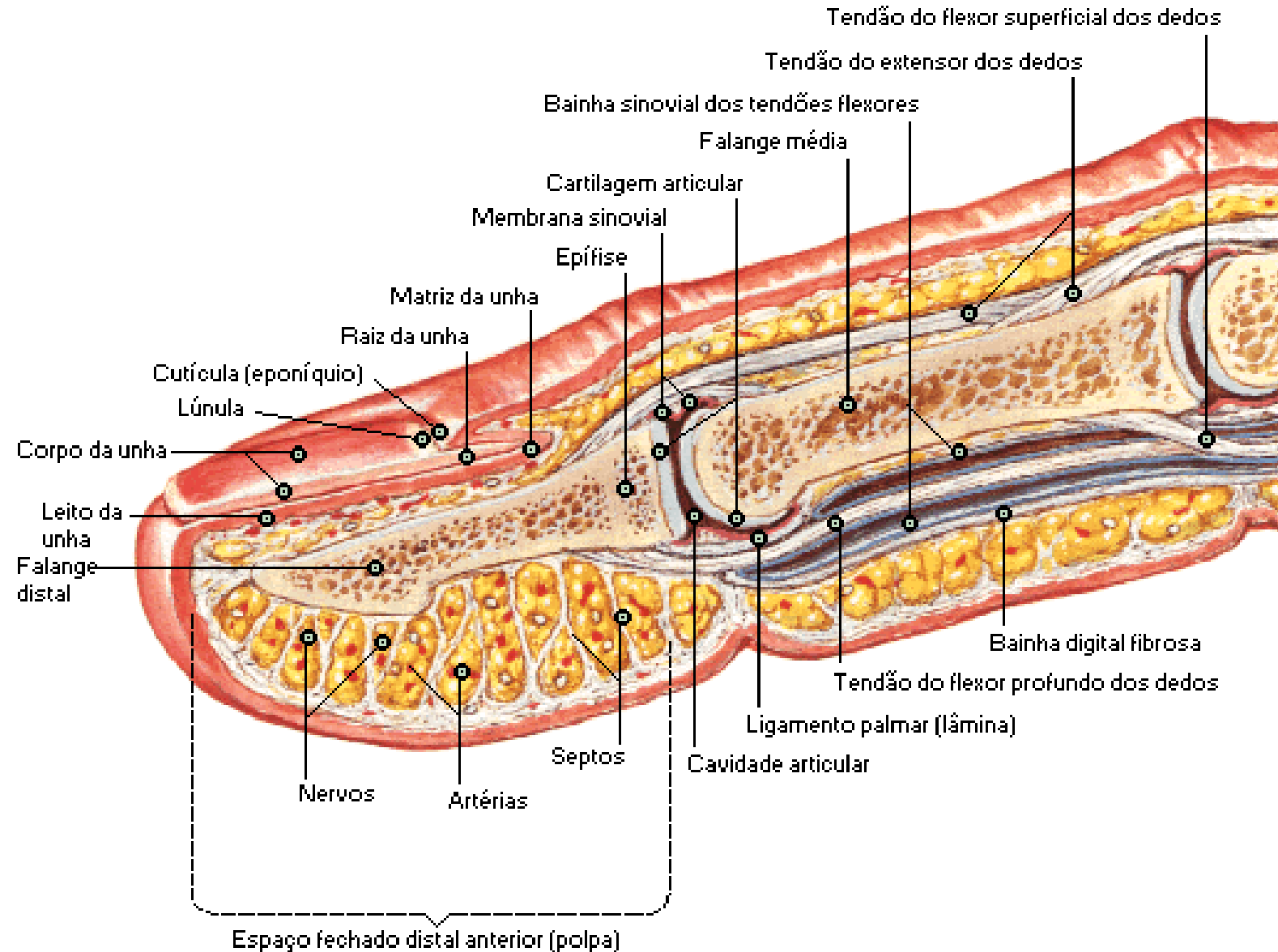
Tendões Extensores do Punho

Secção Transversal na Parte Proximal do Punho



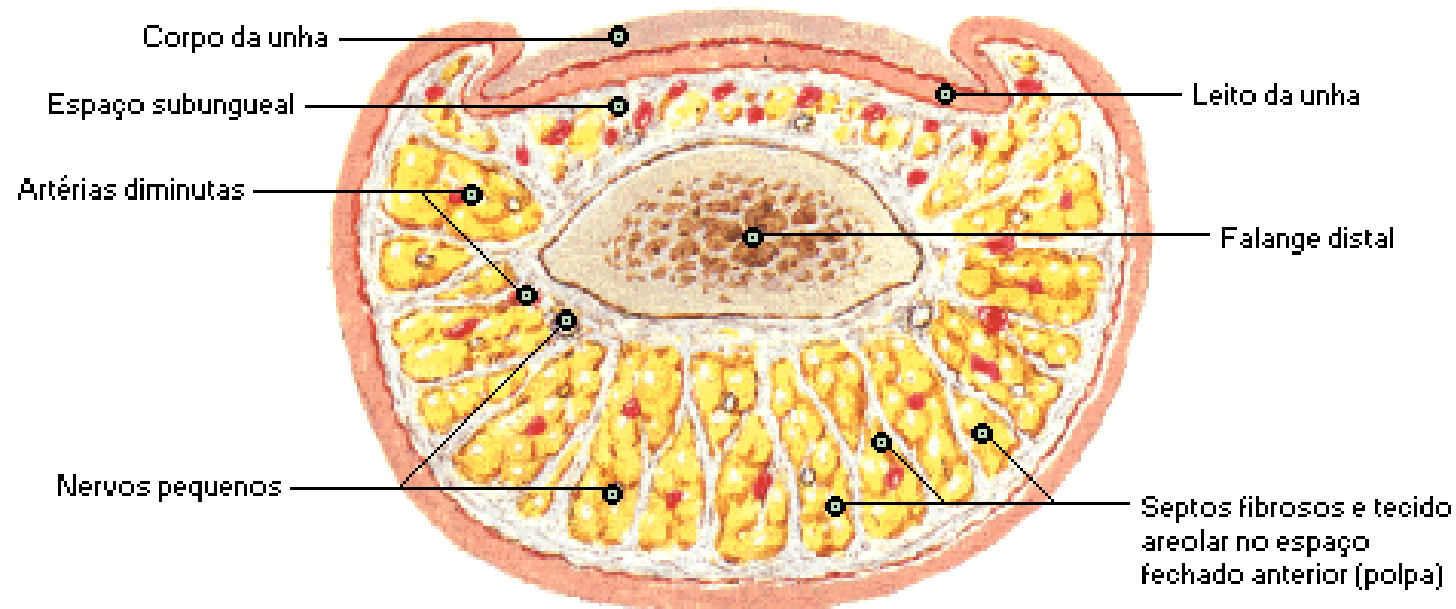
Dedos

Secção Sagital



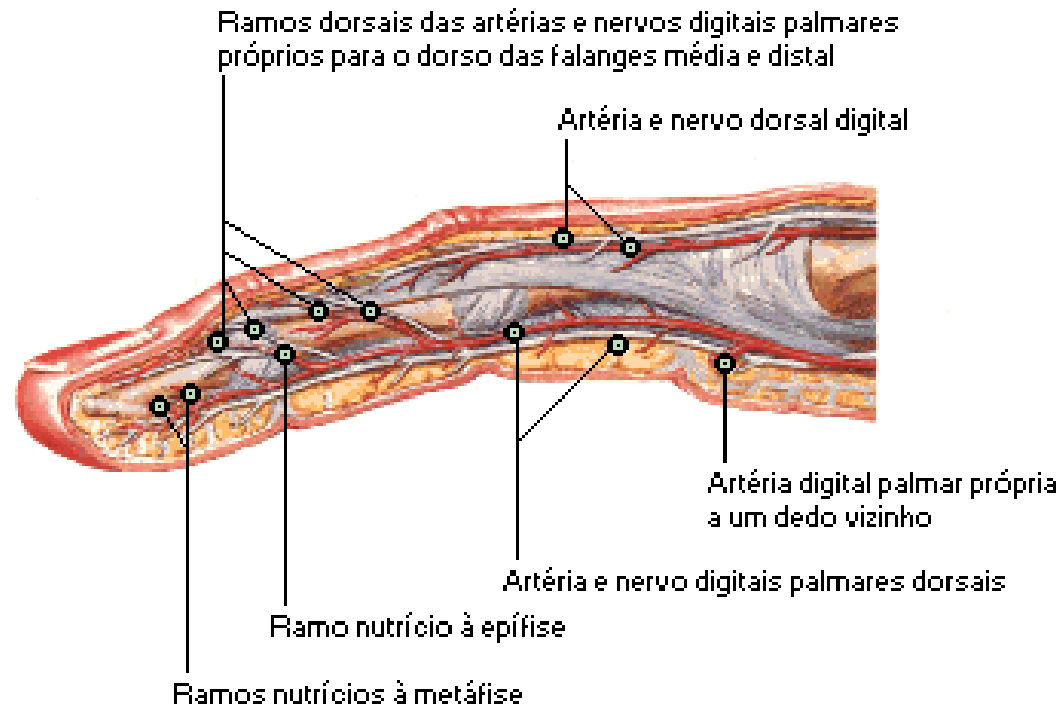
Dedos

Secção Transversal Através da Falange Distal



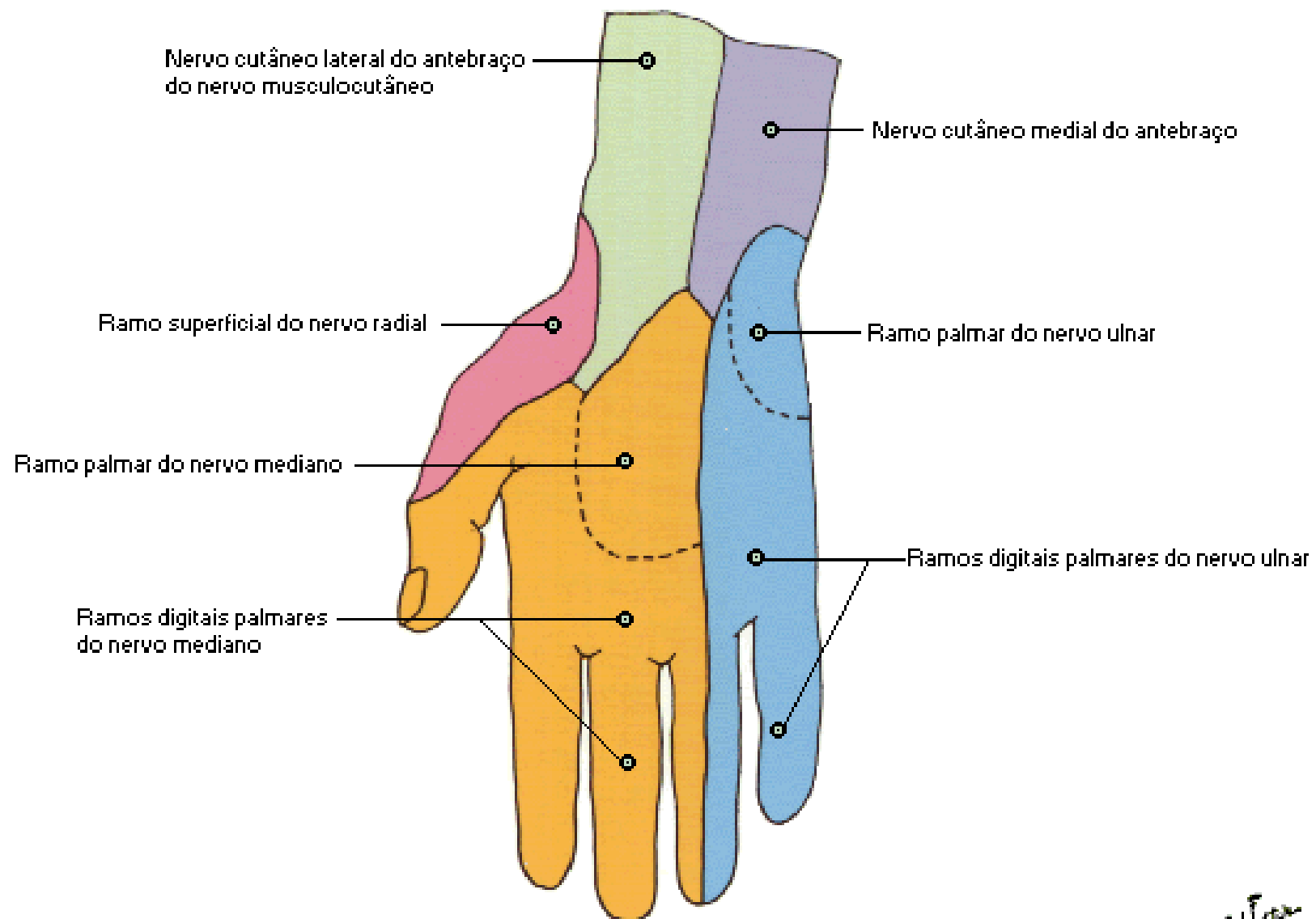
Dedos

Artérias e Nervos



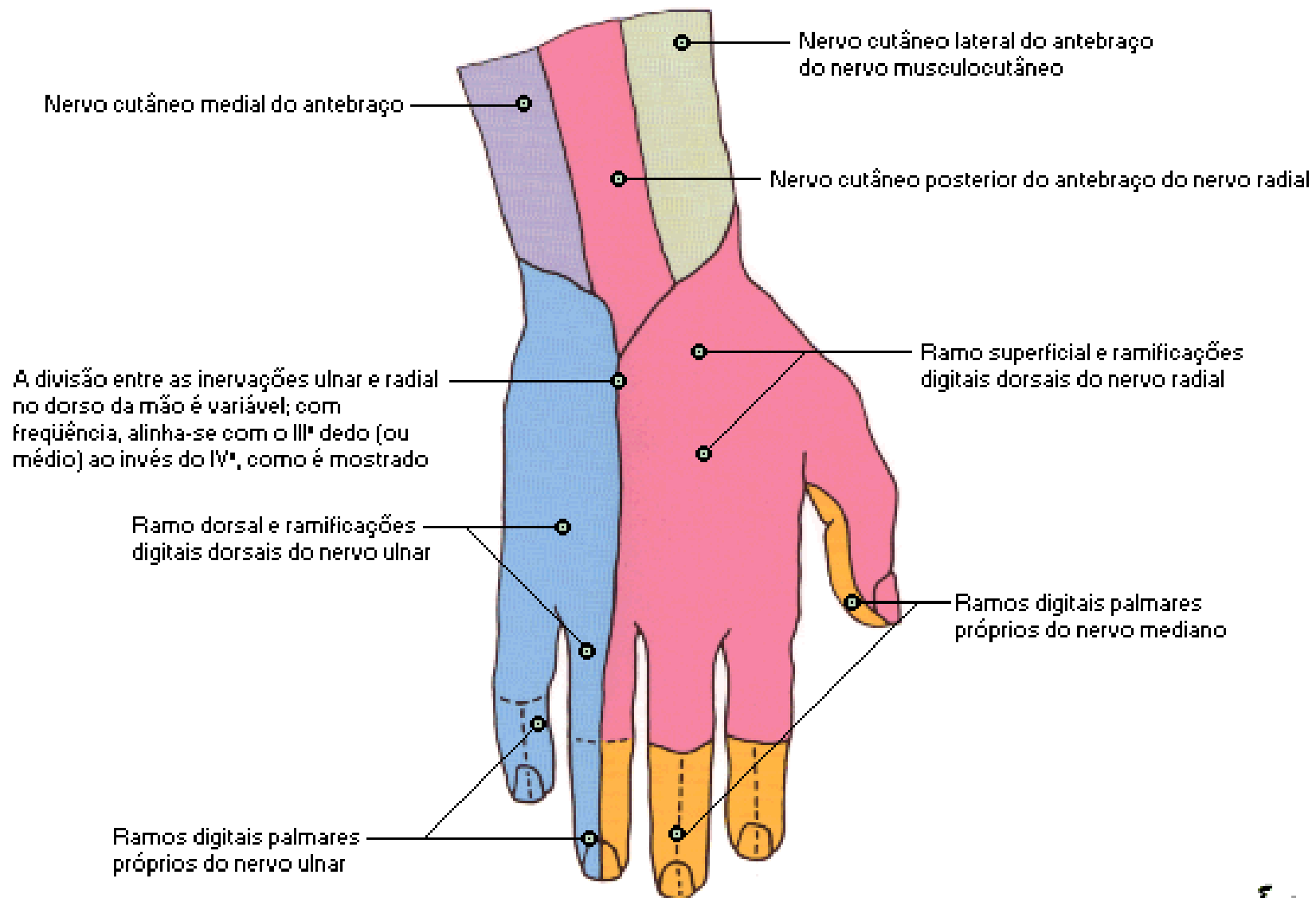
Nervos Cutâneos do Punho e Mão

Vista Anterior [Palmar]

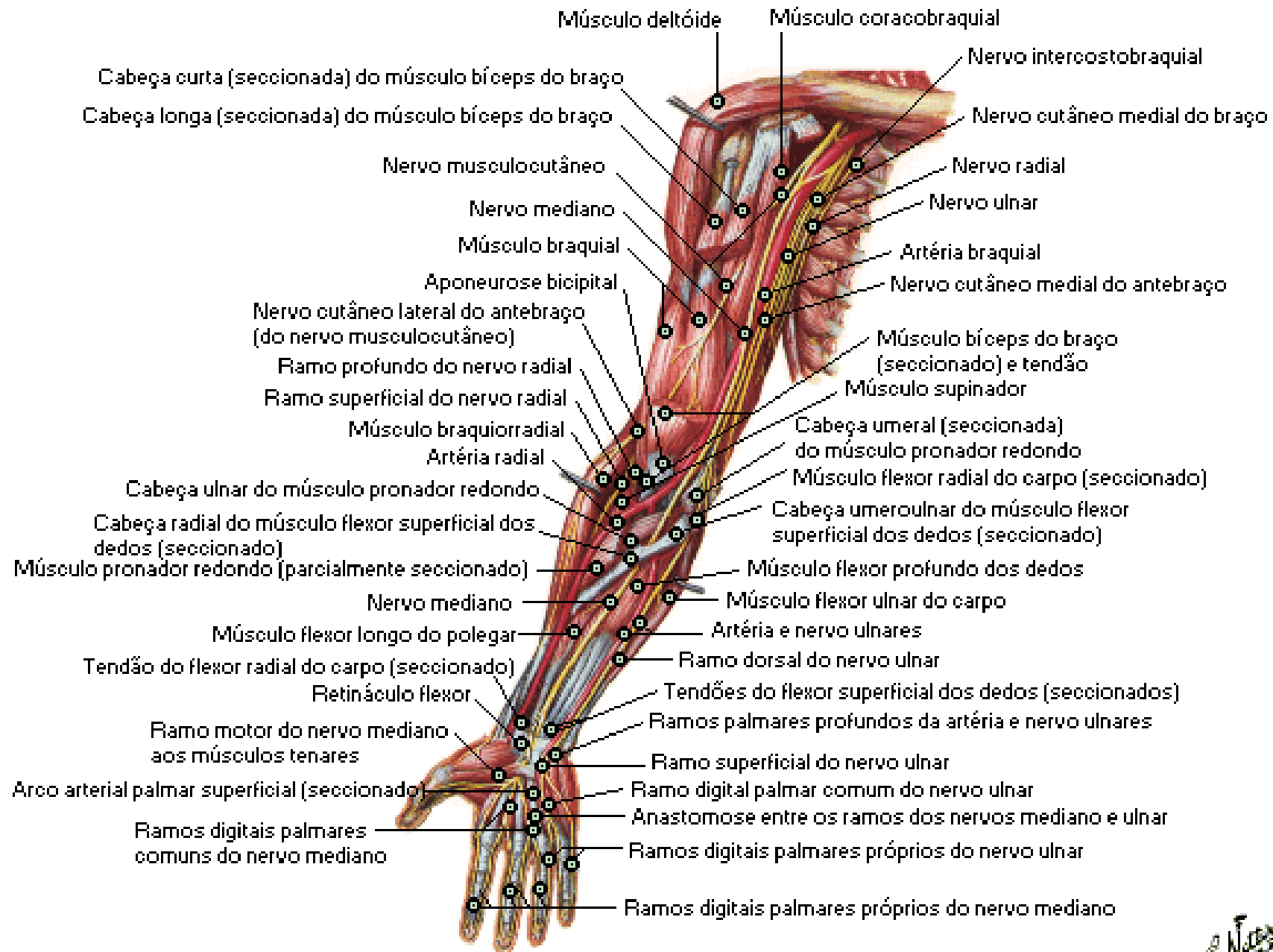


Nervos Cutâneos do Punho e Mão

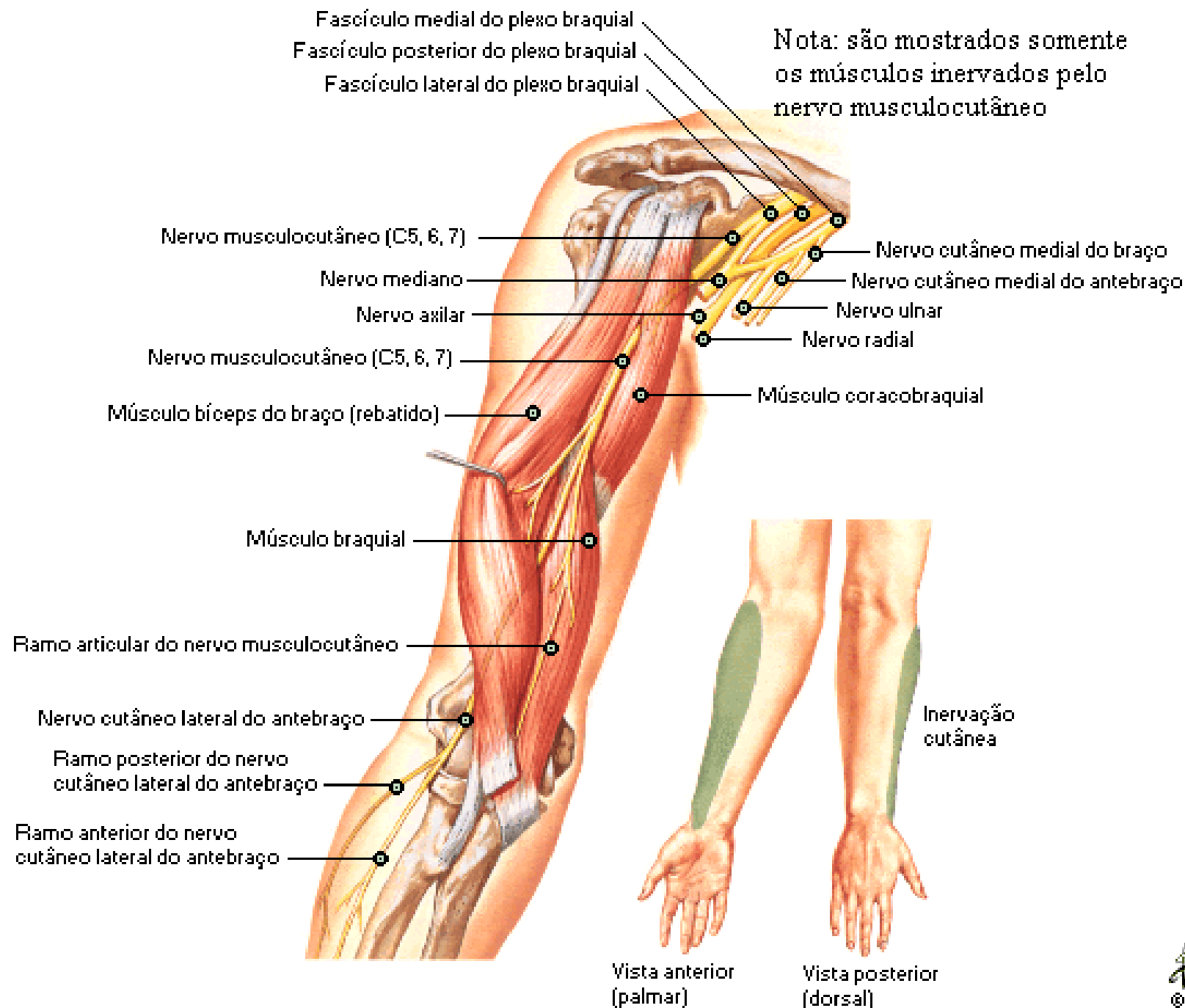
Vista Posterior [Dorsal]



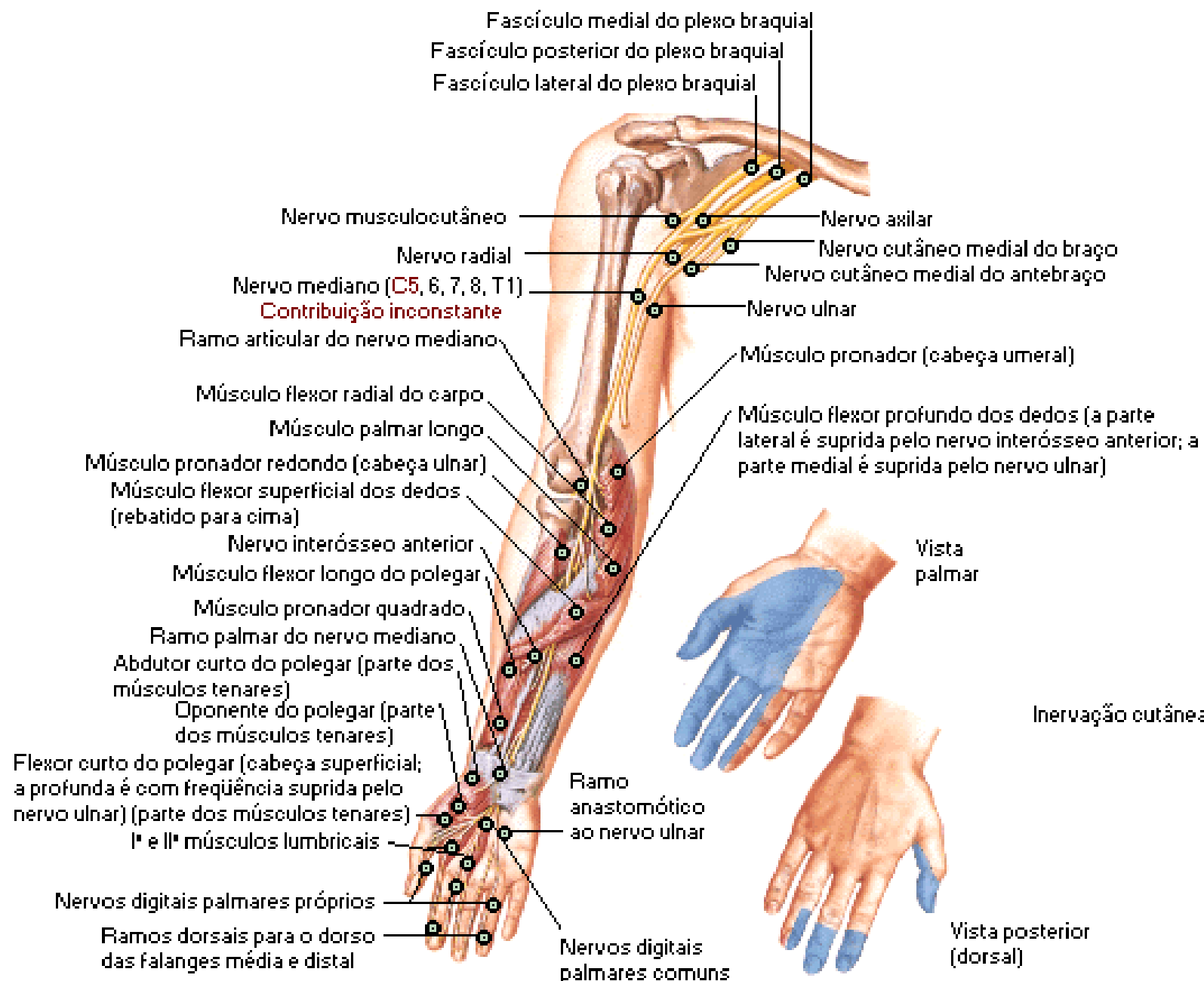
Artérias e Nervos do Membro Superior



Nervo Musculocutâneo

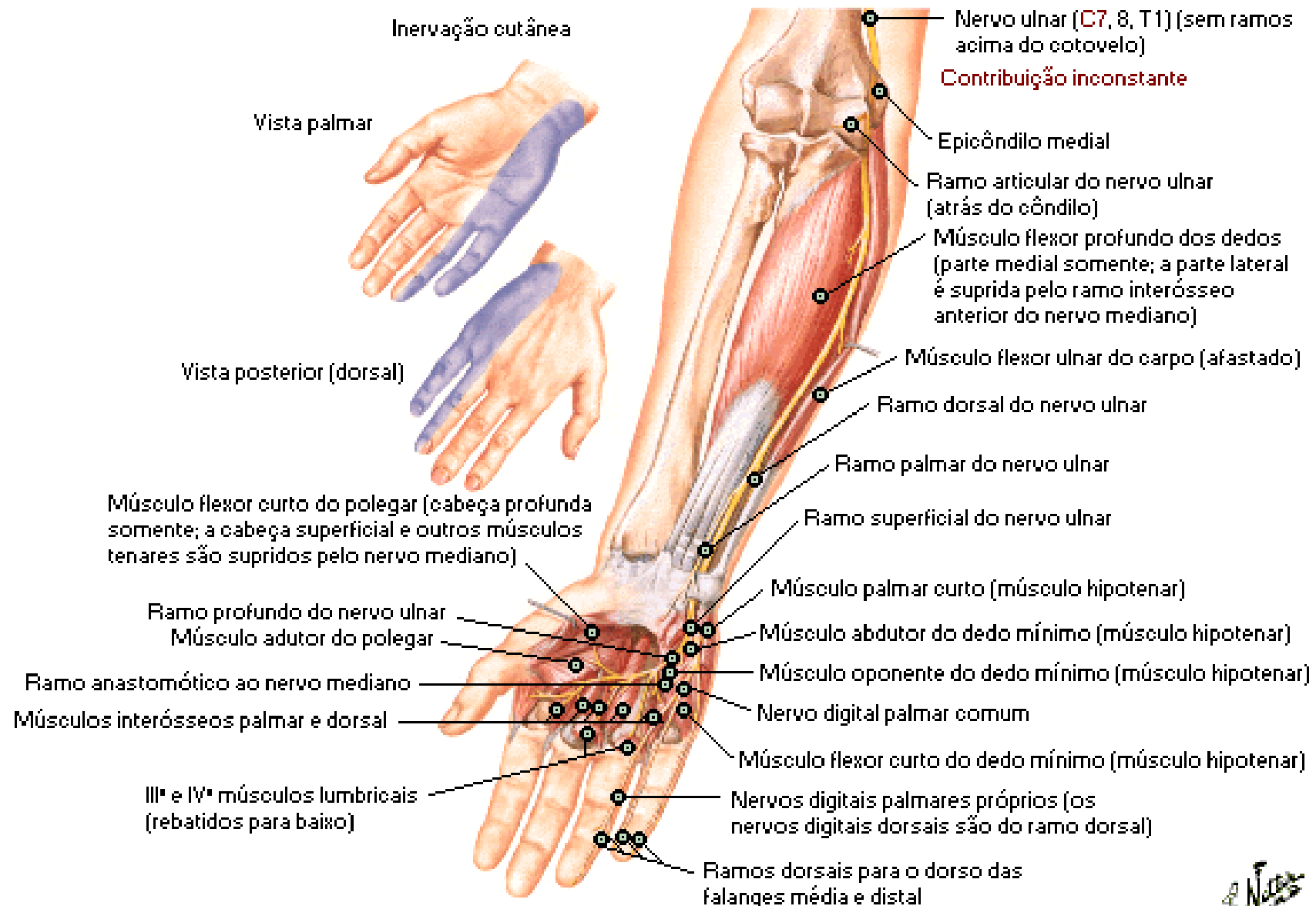


Nervo Mediano

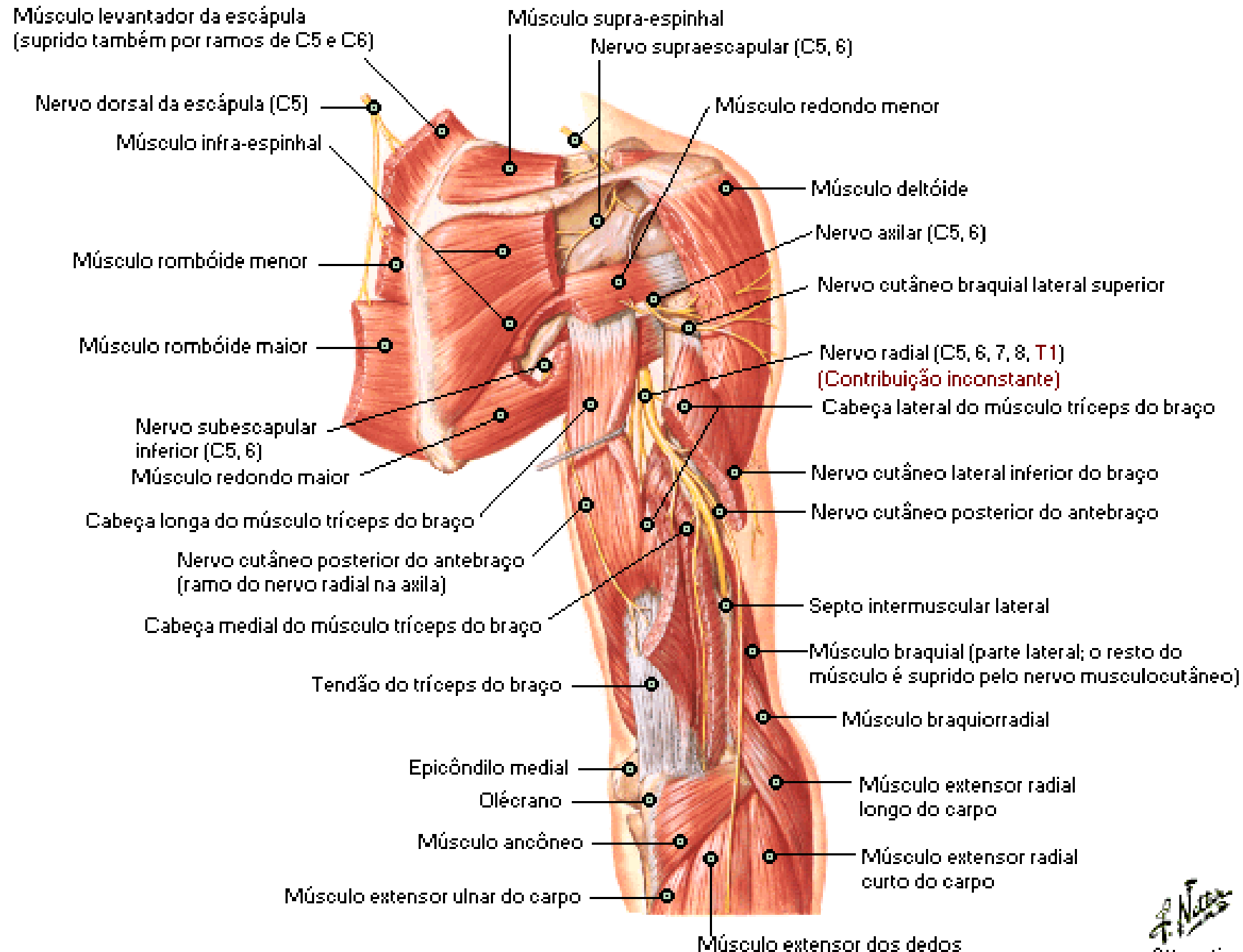


Nervo Ulnar

Nota: são mostrados somente os músculos inervados pelo nervo ulnar

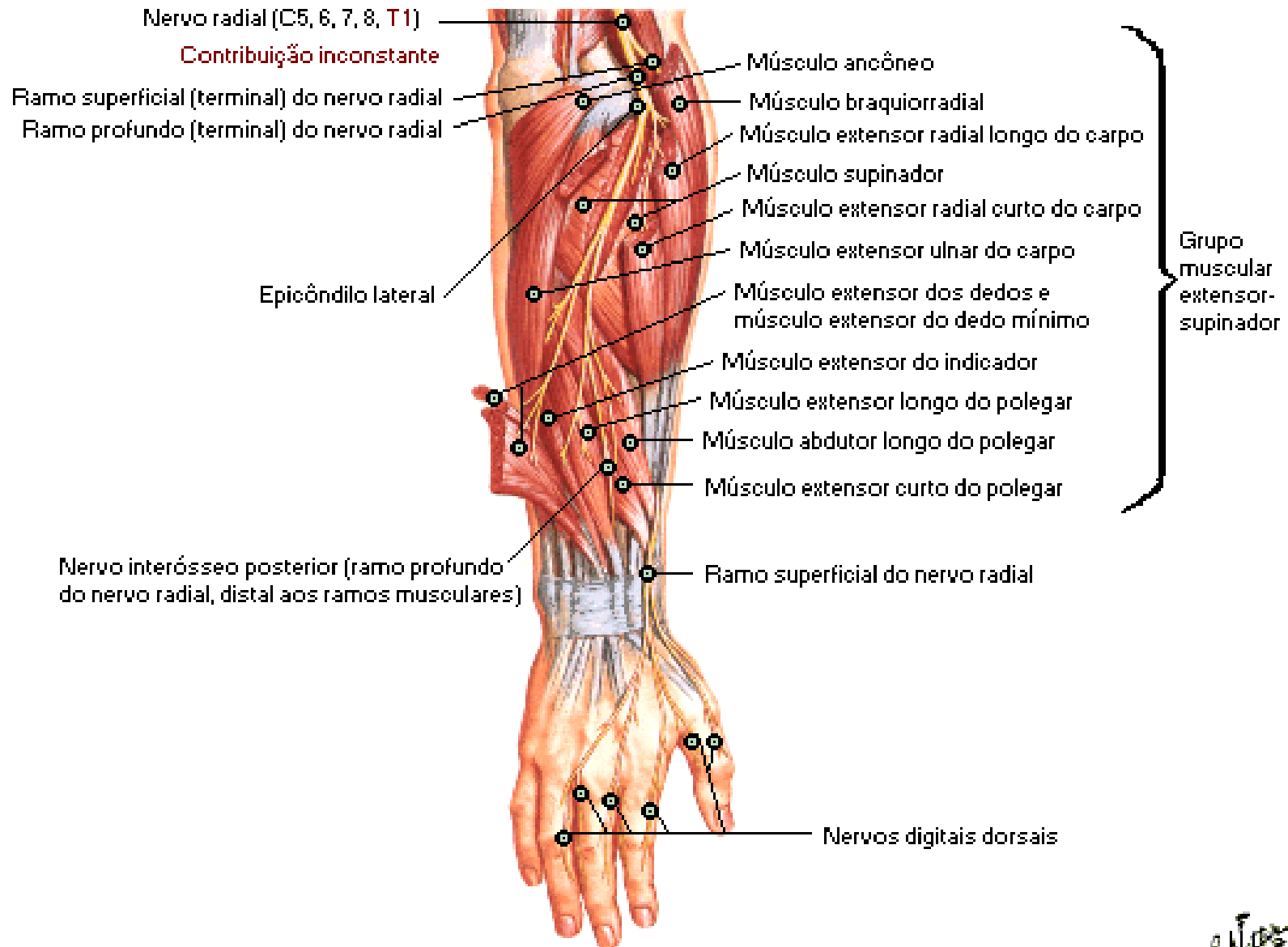


Nervo Radial no Braço e Nervos da Parte Posterior do Ombro



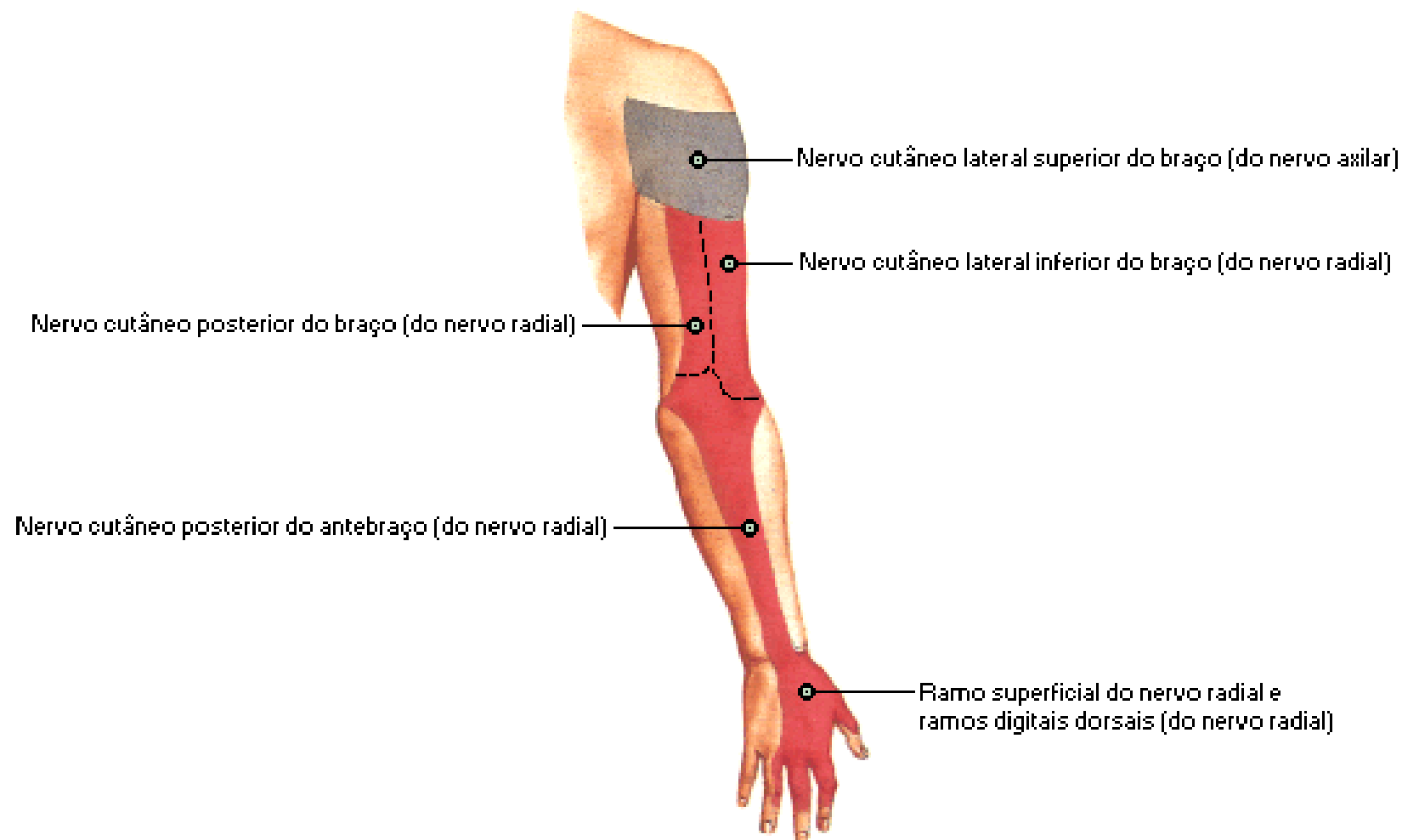
Nervo Radial no Antebraço

Vista Posterior



Nervos Radial e Axilar

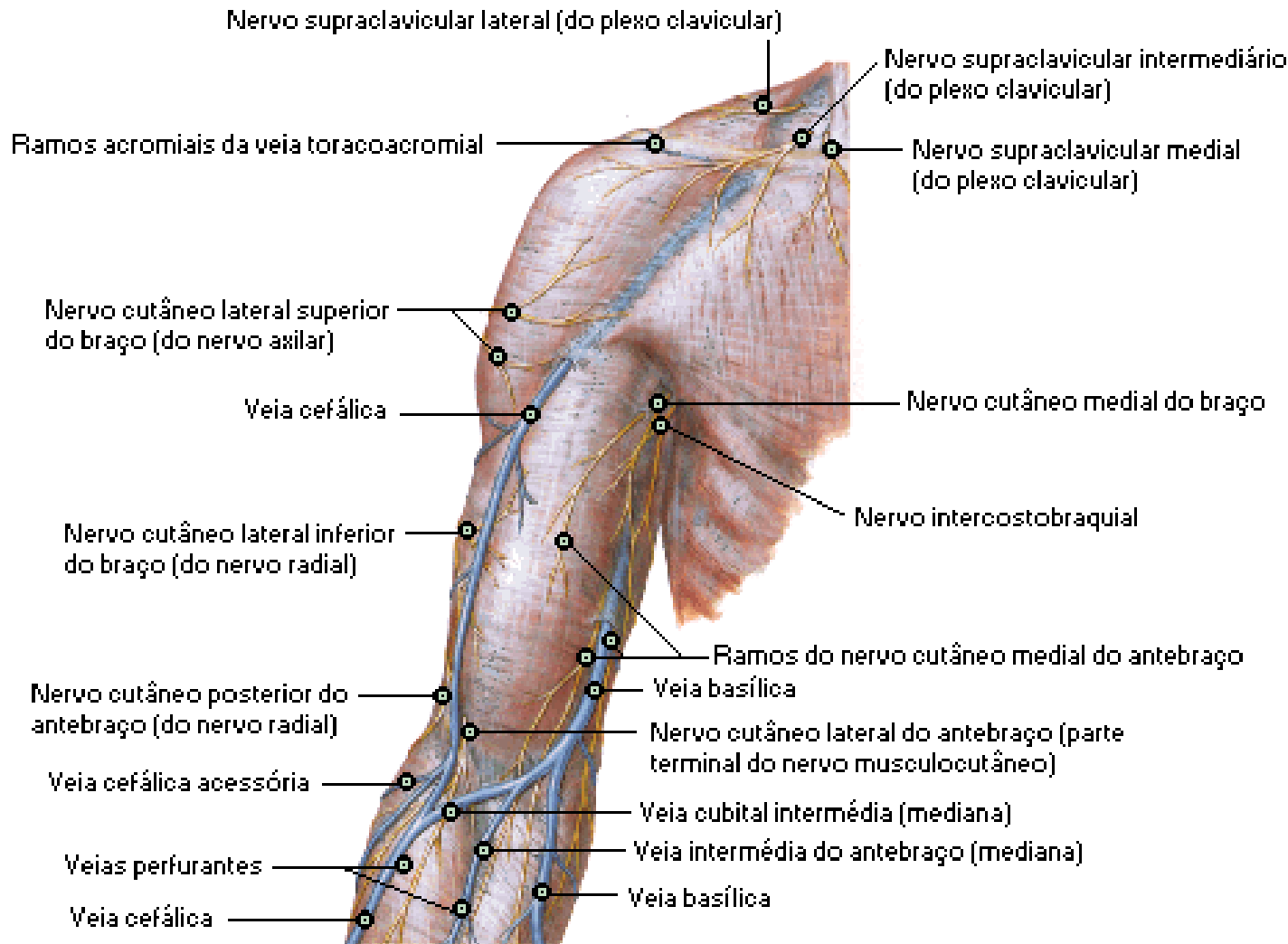
Inervação Cutânea



Vista posterior

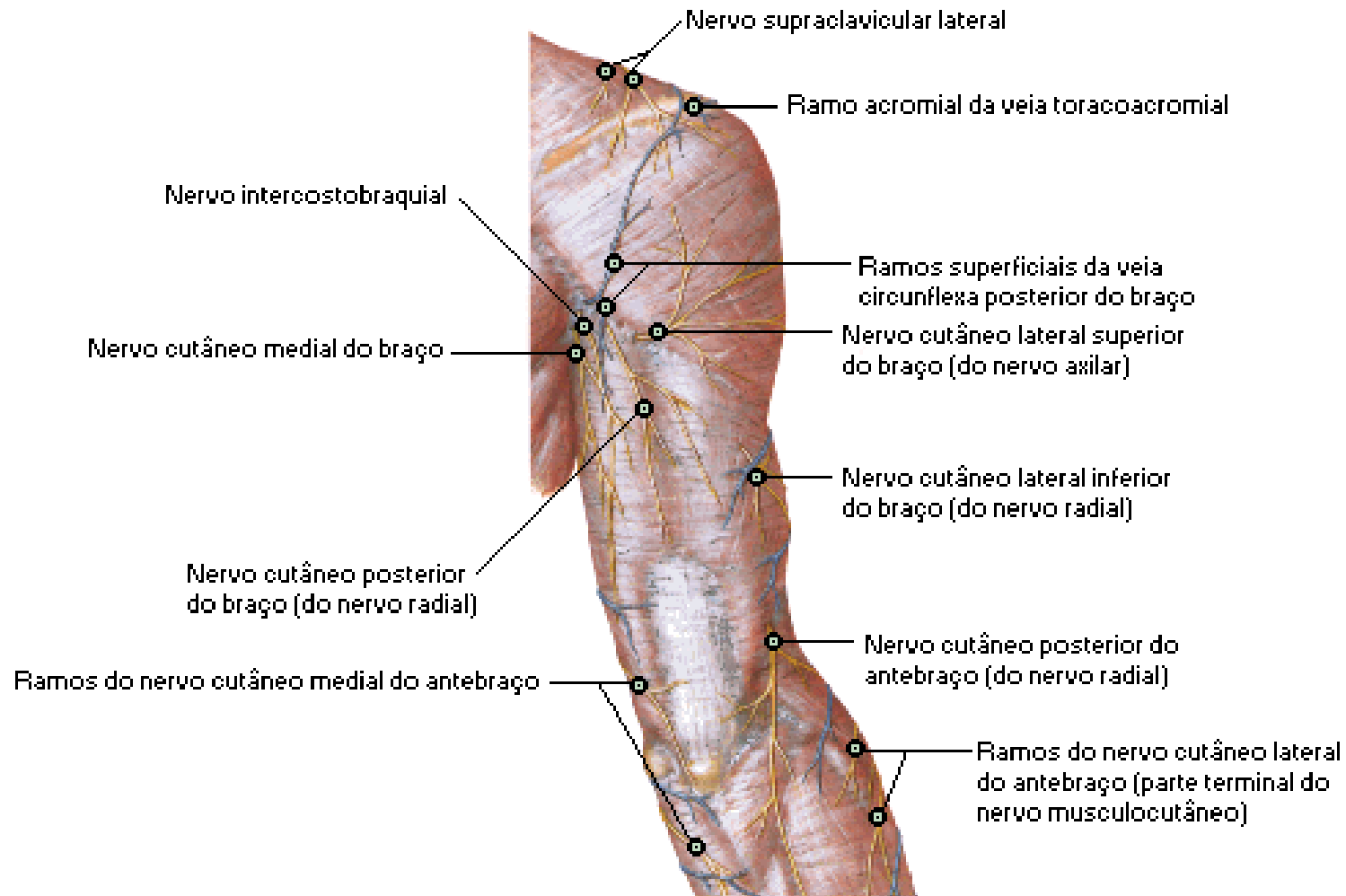
Nervos Cutâneos e Veias Superficiais do Ombro e Braço

Vista Anterior



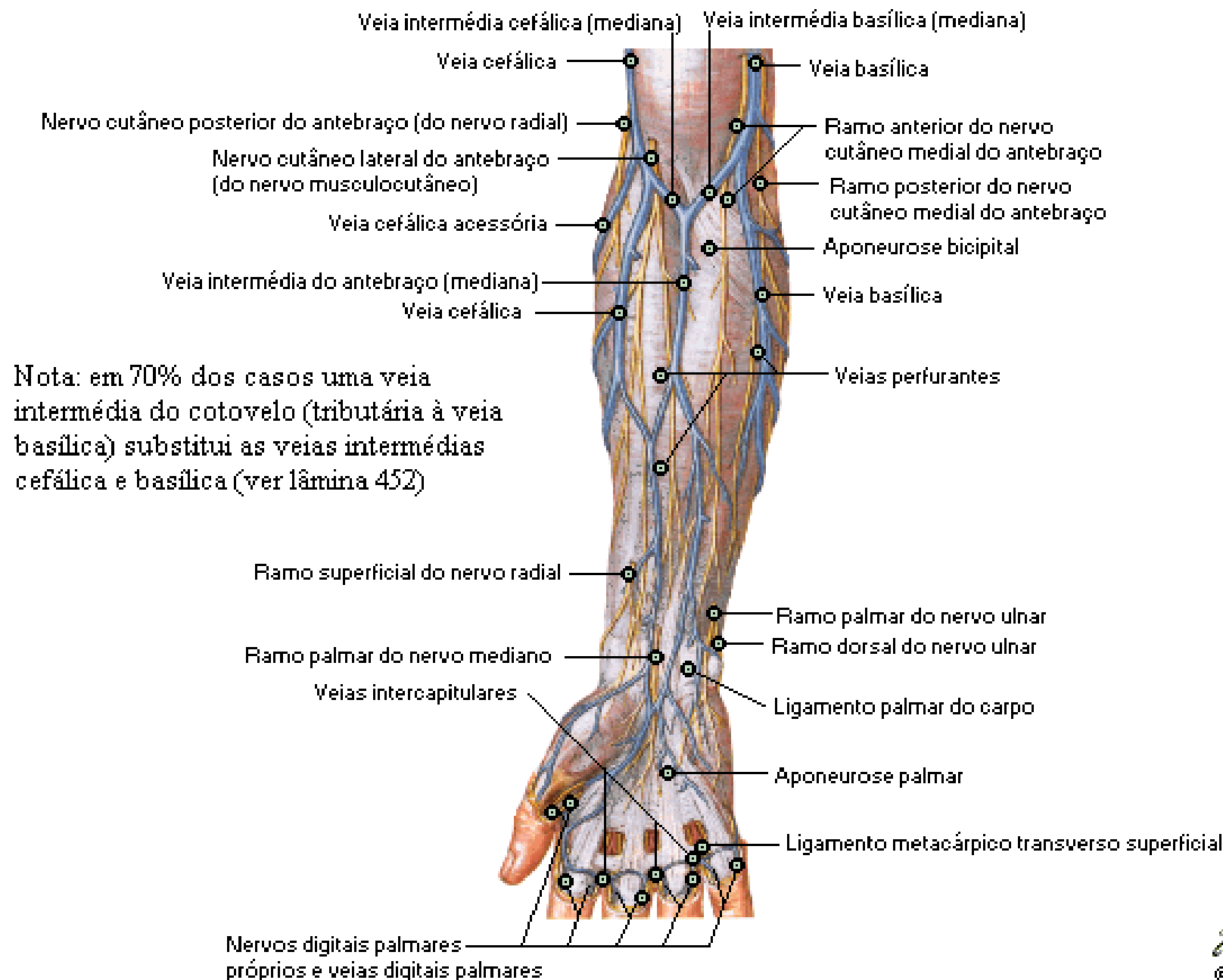
Nervos Cutâneos e Veias Superficiais do Ombro e Braço

Vista Posterior



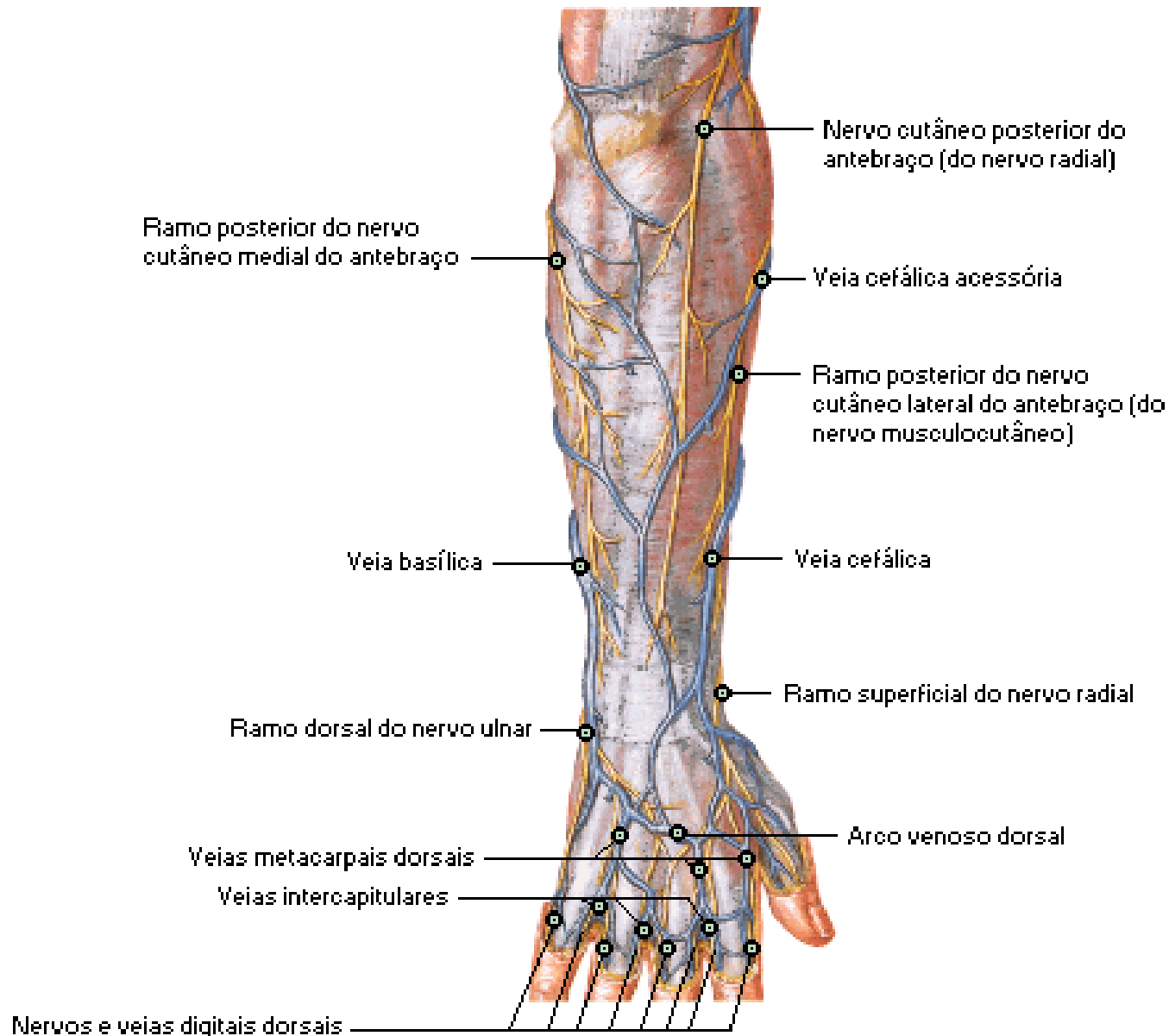
Nervos Cutâneos e Veias Superficiais do Antebraço

Vista Anterior [Palmar]



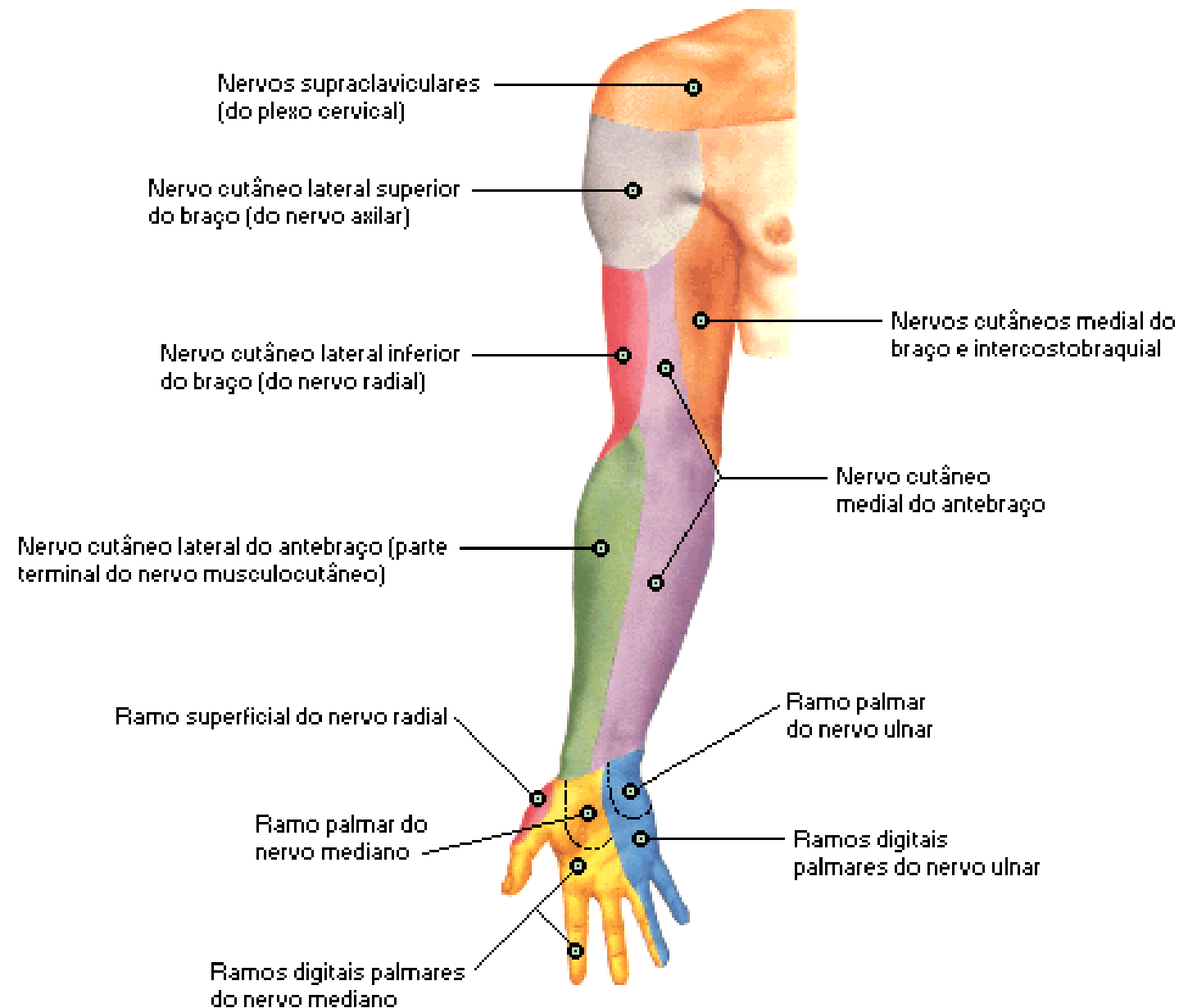
Nervos Cutâneos e Veias Superficiais do Antebraço

Vista Posterior [Dorsal]



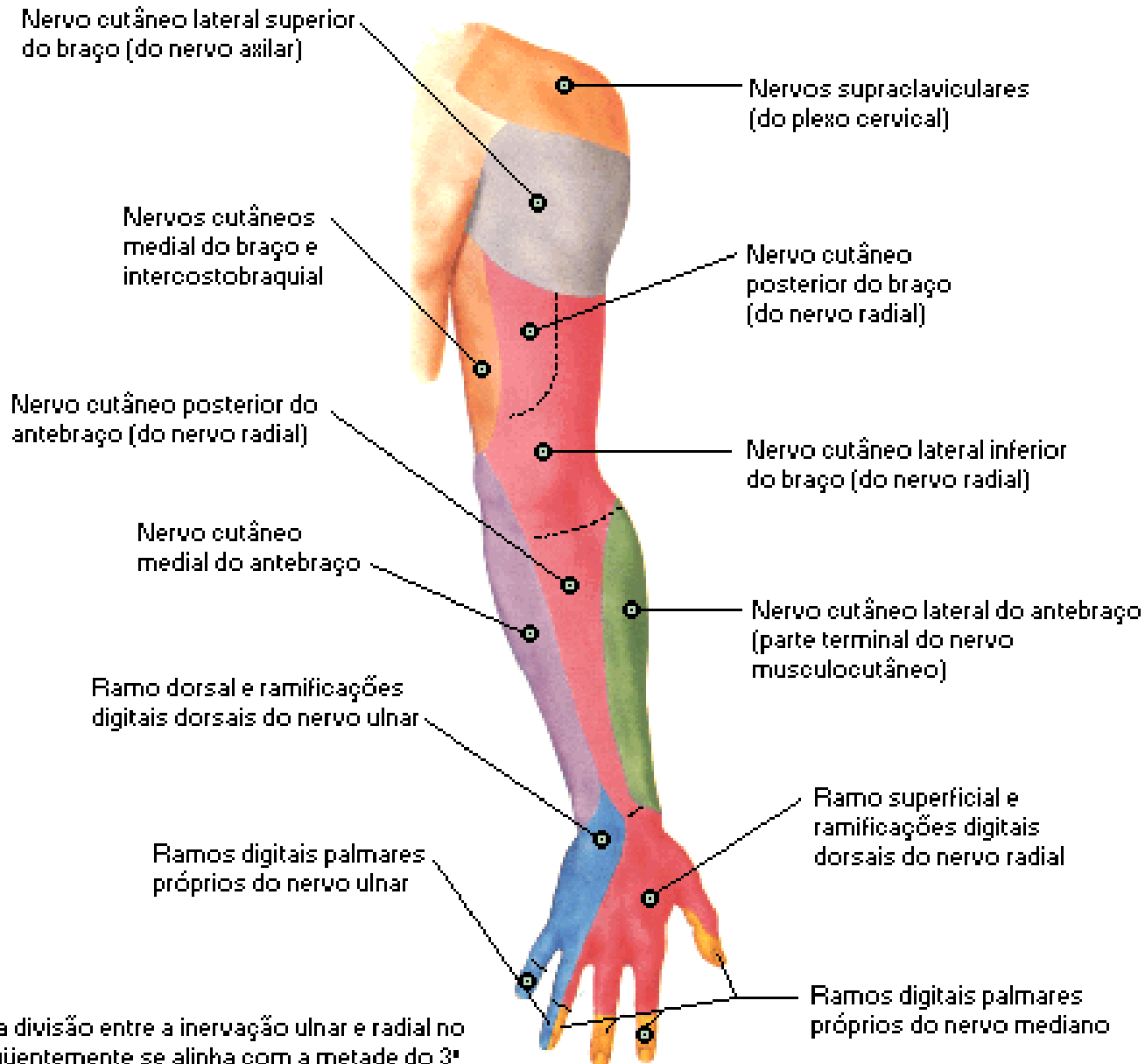
Inervação Cutânea do Membro Superior

Vista Anterior [Palmar]



Inervação Cutânea do Membro Superior

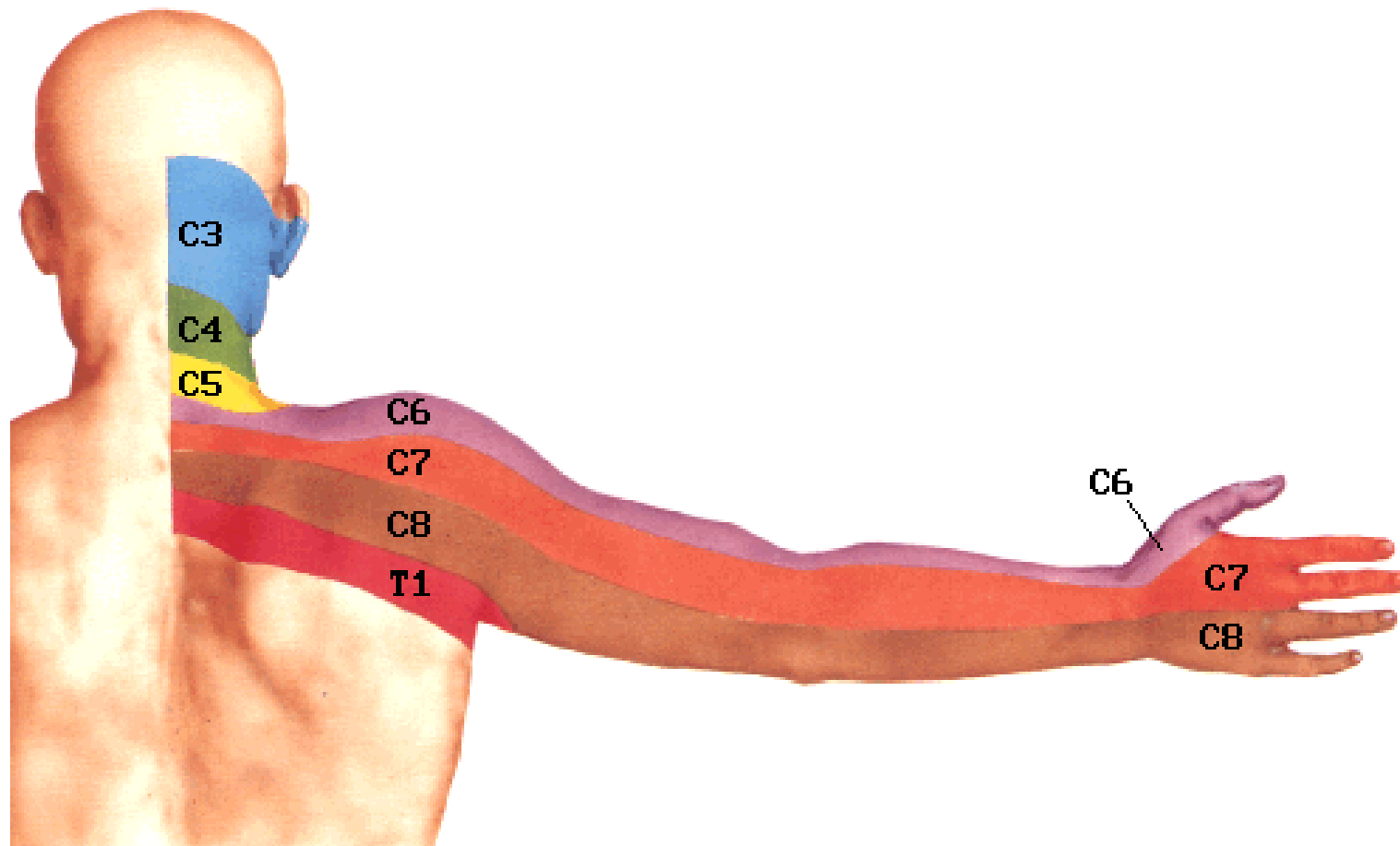
Vista Posterior [Dorsal]



Nota: há variação na divisão entre a inervação ulnar e radial no dorso da mão e frequentemente se alinha com a metade do 3º dedo ao invés do 4º dedo como é mostrado

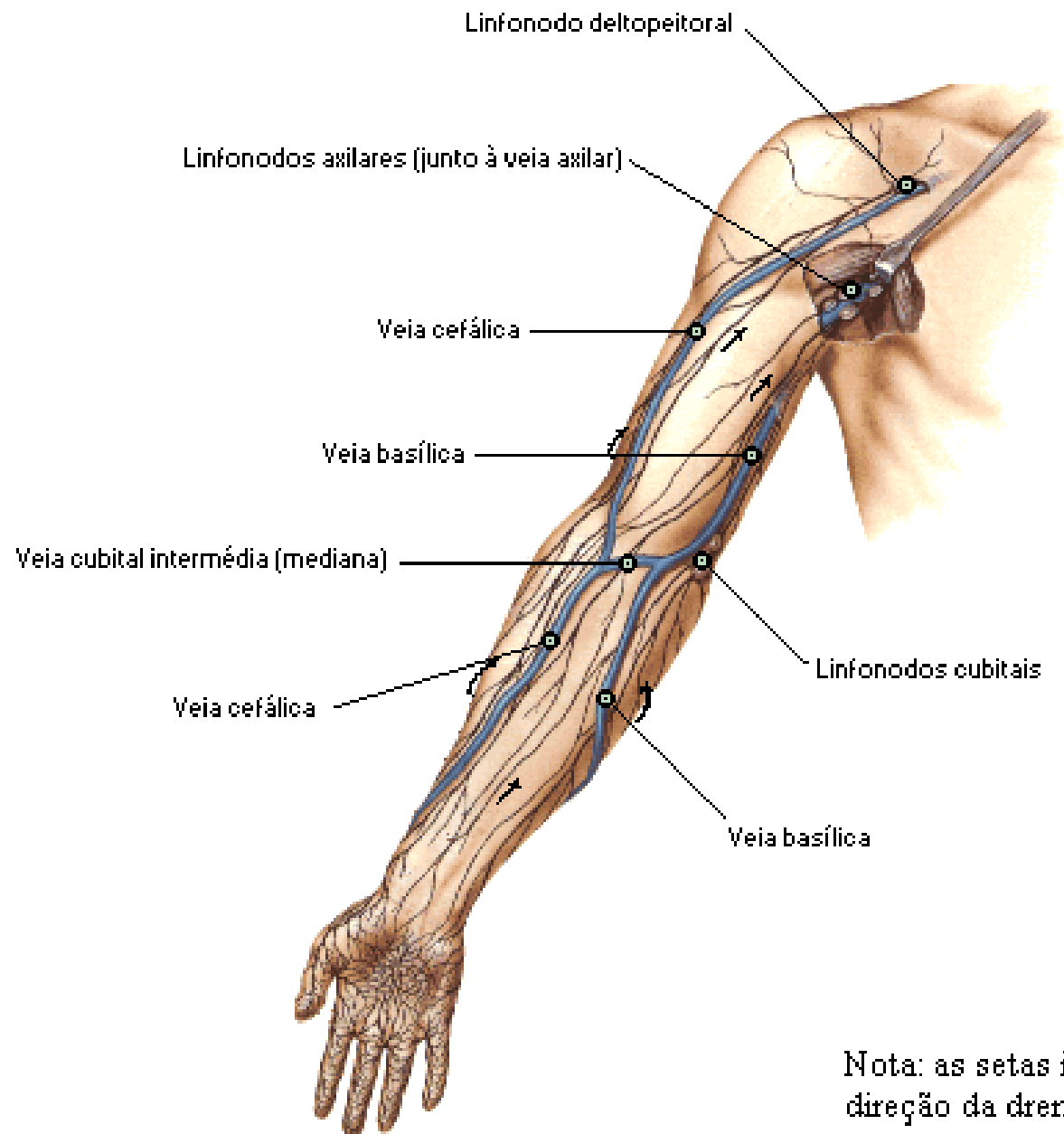
Dermátomos do Membro Superior

Vista Posterior



Nota: a demarcação esquemática dos dermatômeros é mostrada como segmentos distintos. Existe na realidade uma sobreposição considerável entre os dermatômeros adjacentes.

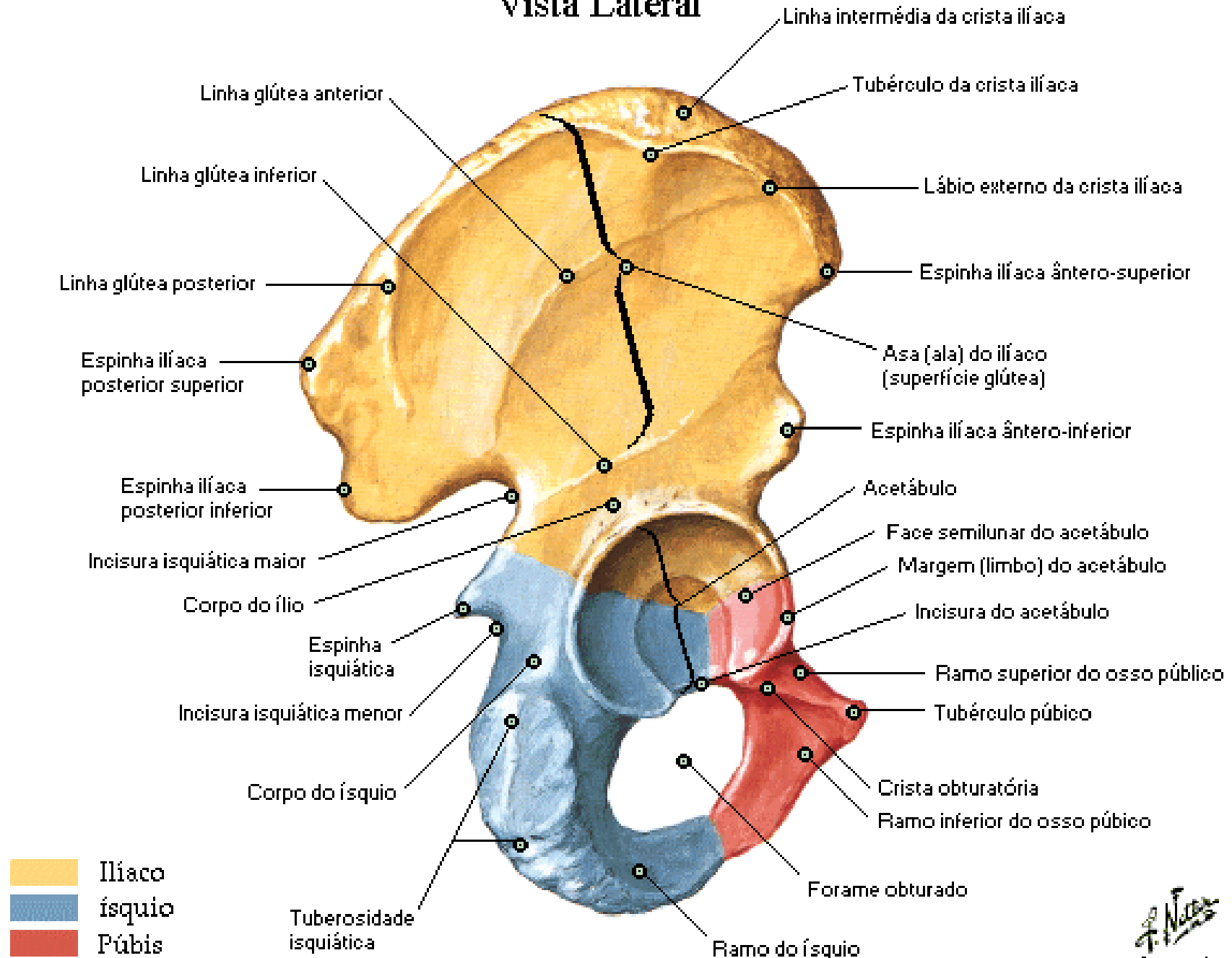
Vasos Linfáticos e Linfonodos do Membro Superior



Nota: as setas indicam a direção da drenagem

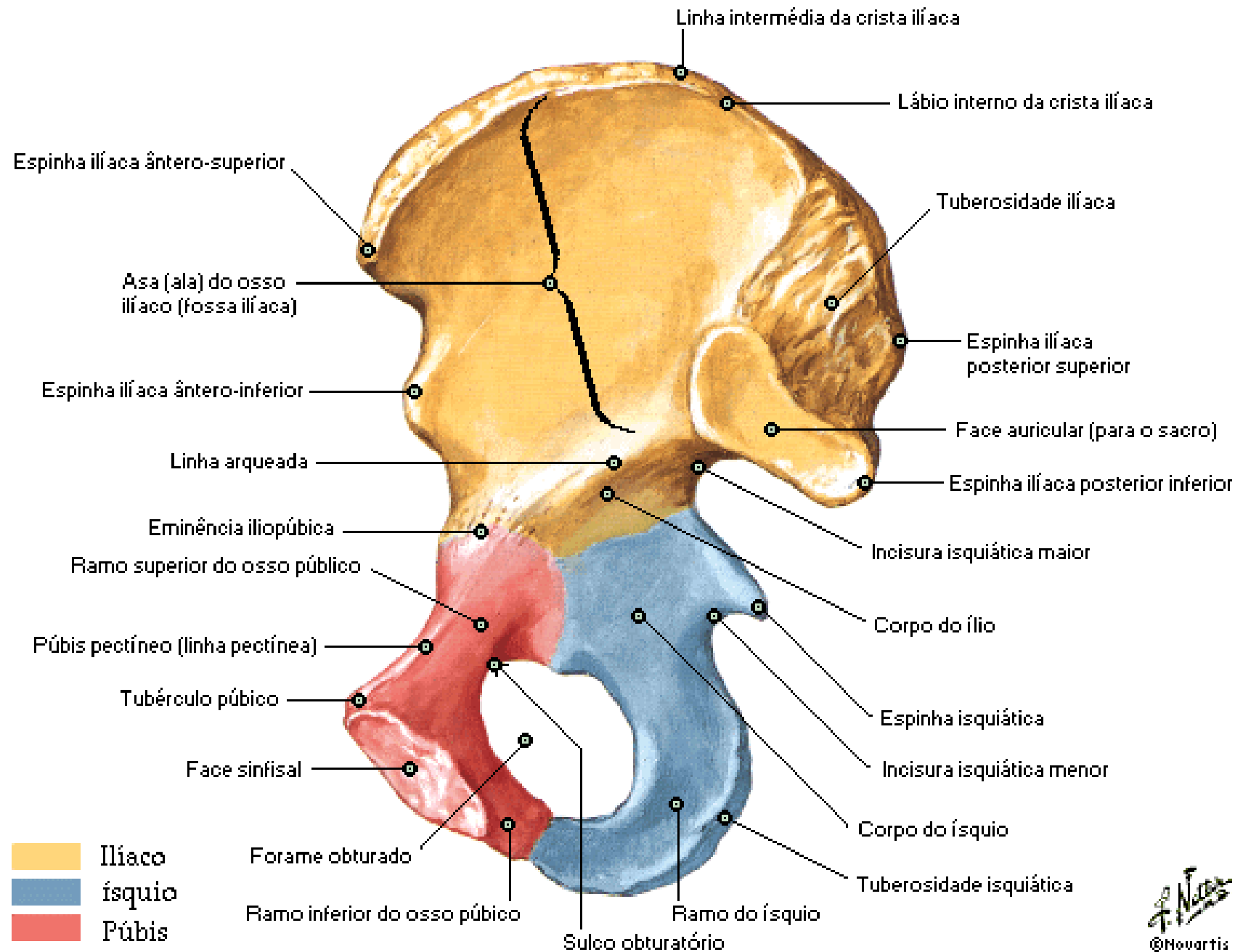
Ossos do Quadril

Vista Lateral



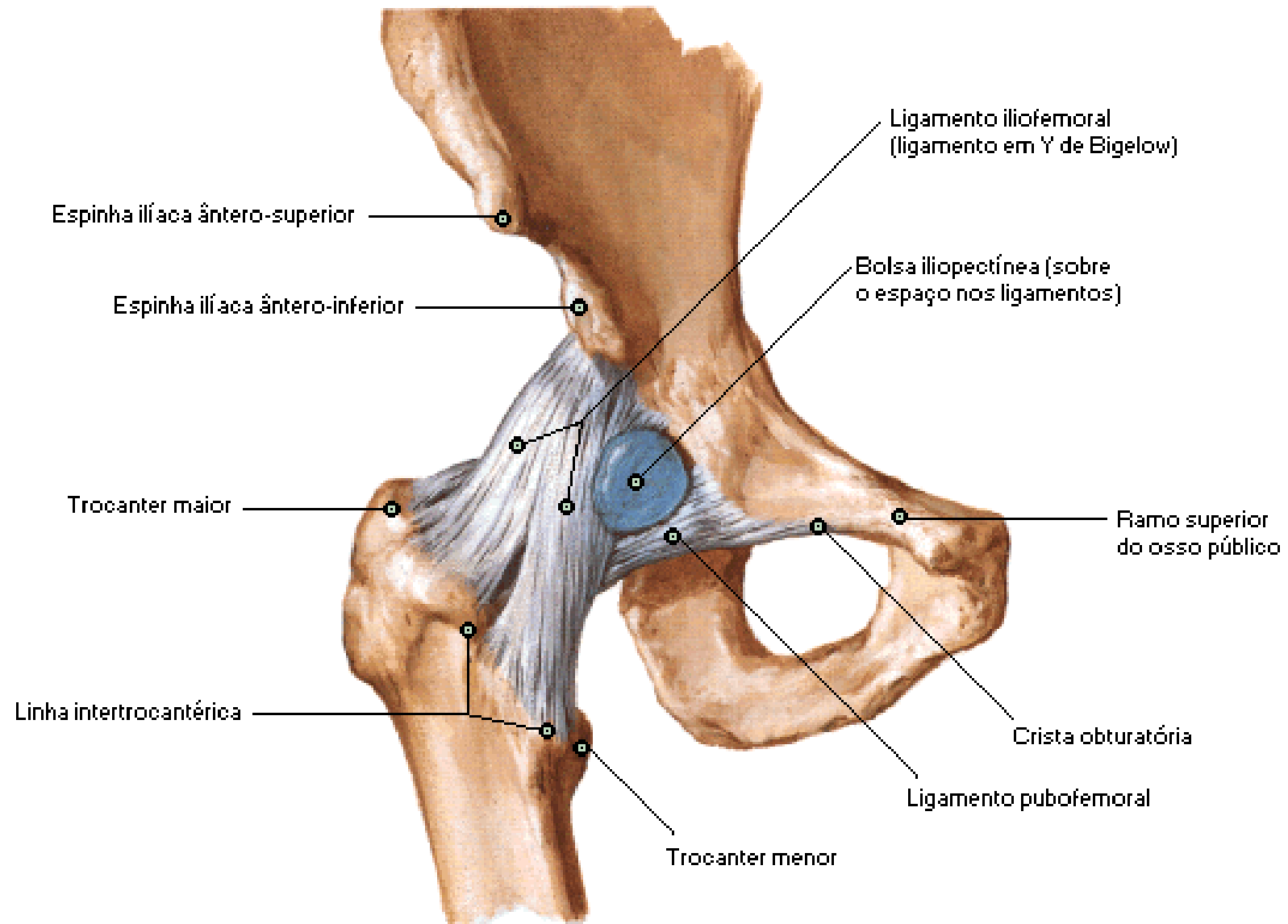
Osso do Quadril

Vista Medial



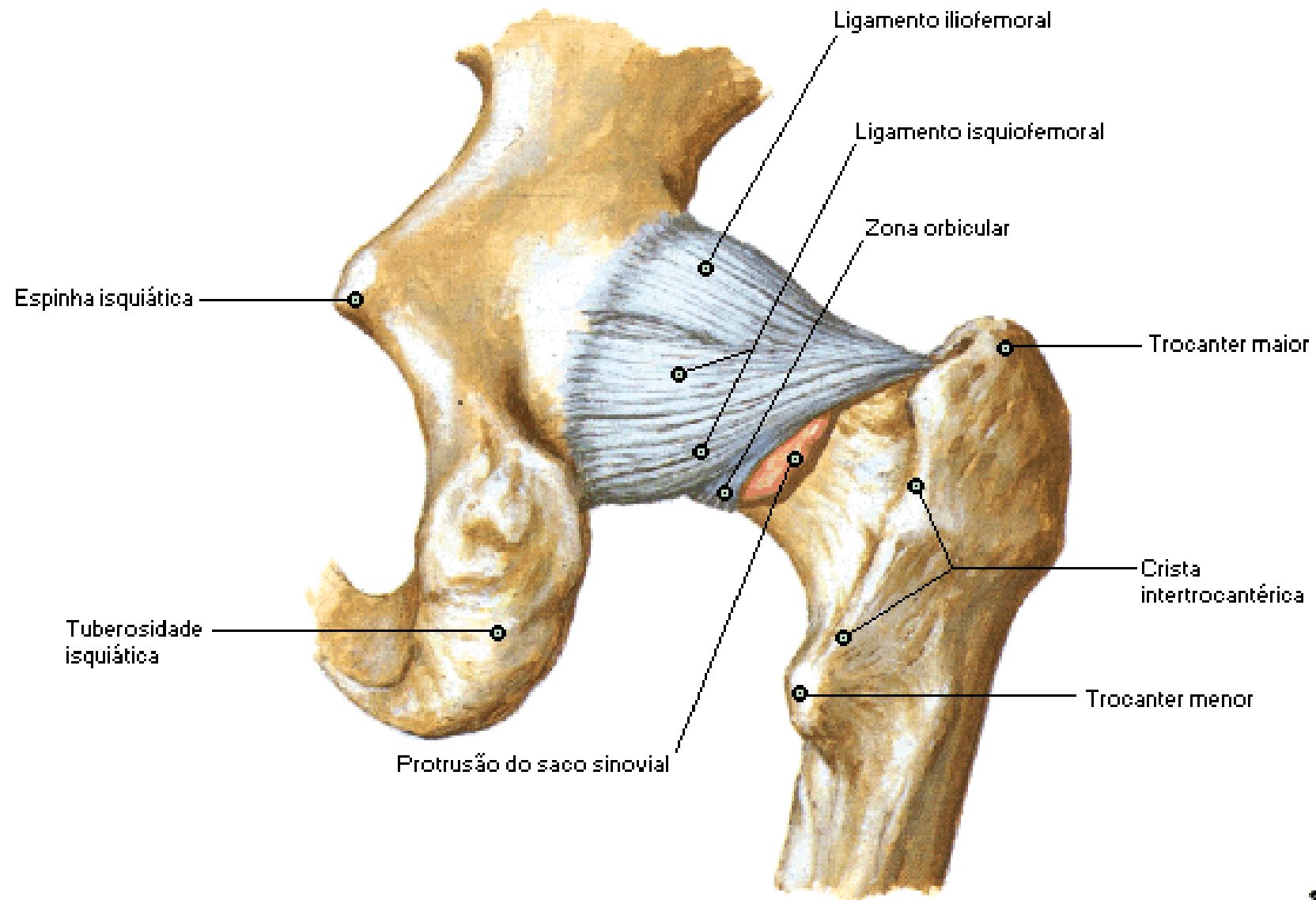
Articulação do Quadril

Vista Anterior



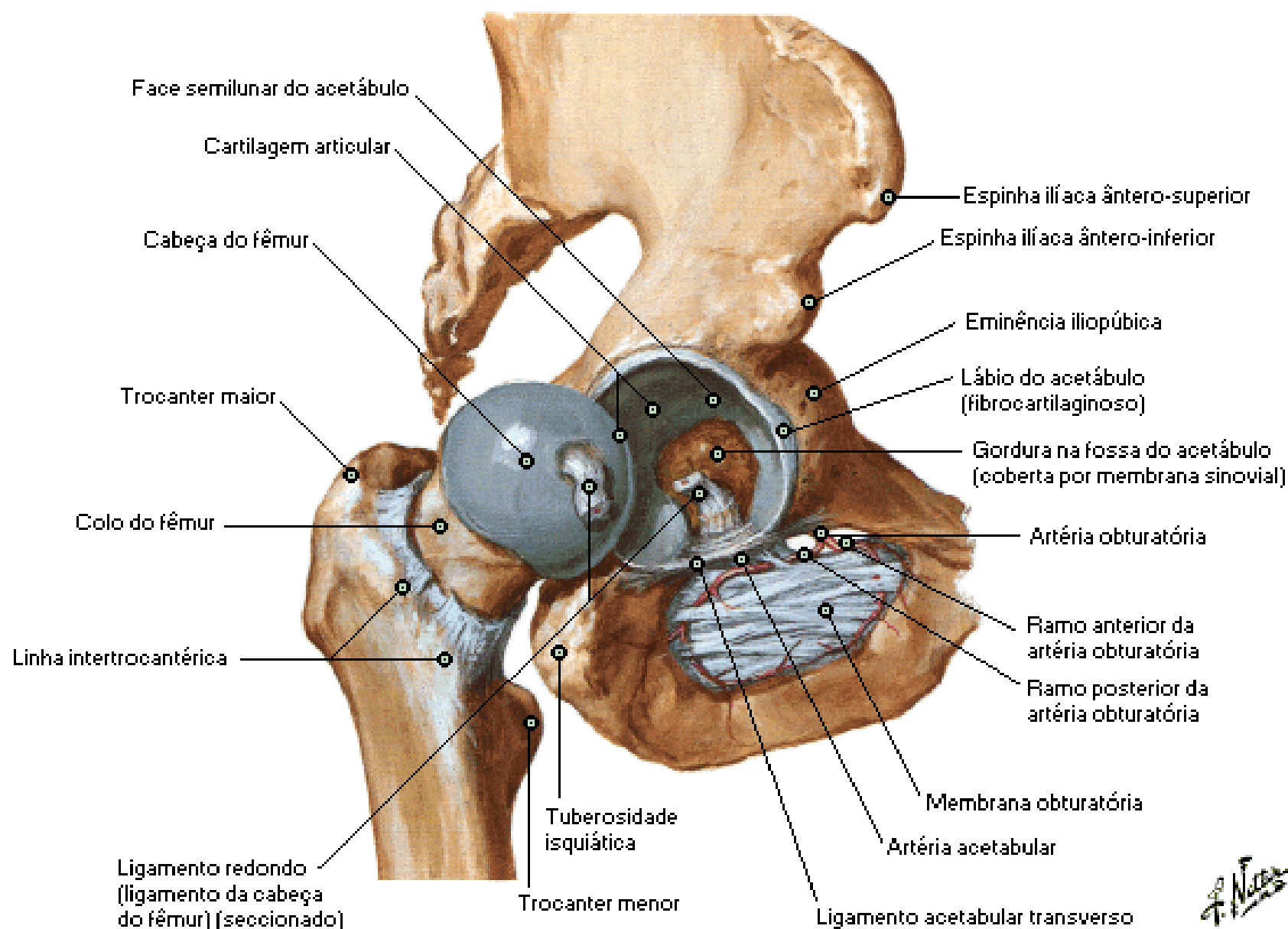
Articulação do Quadril

Vista Posterior



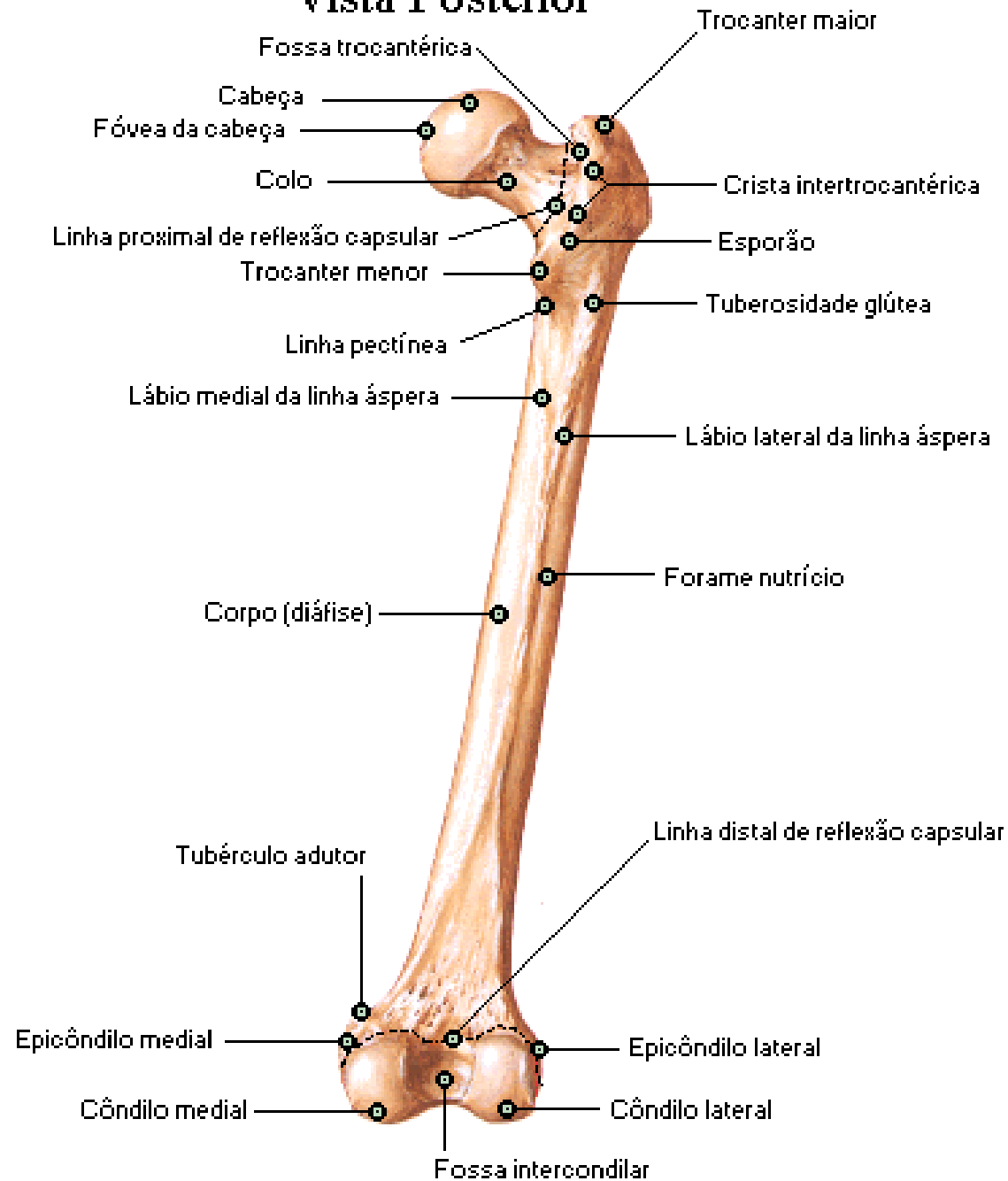
Articulação do Quadril

Vista Lateral



Fêmur

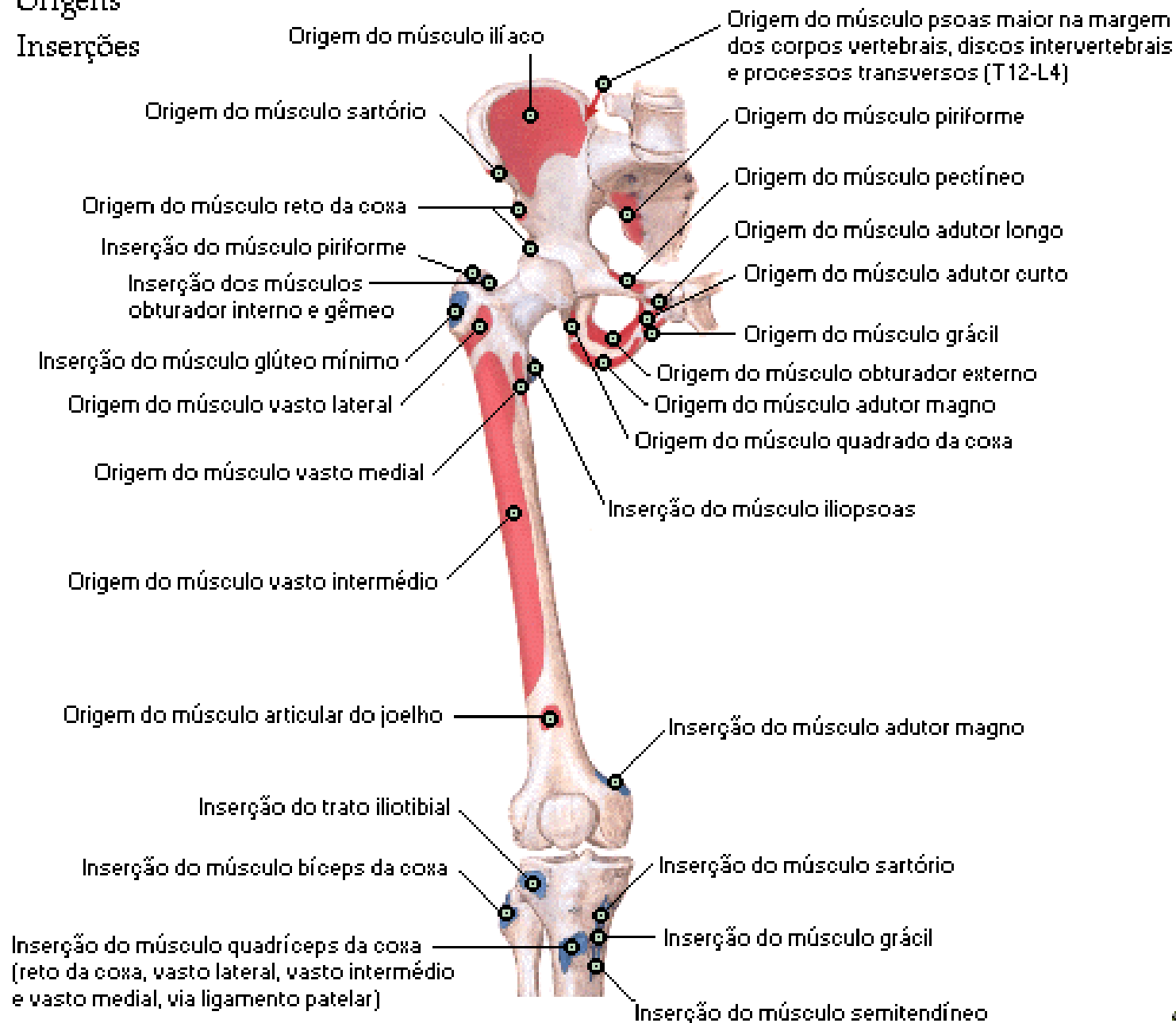
Vista Posterior



Inserções Ósseas dos Músculos do Quadril e Coxa

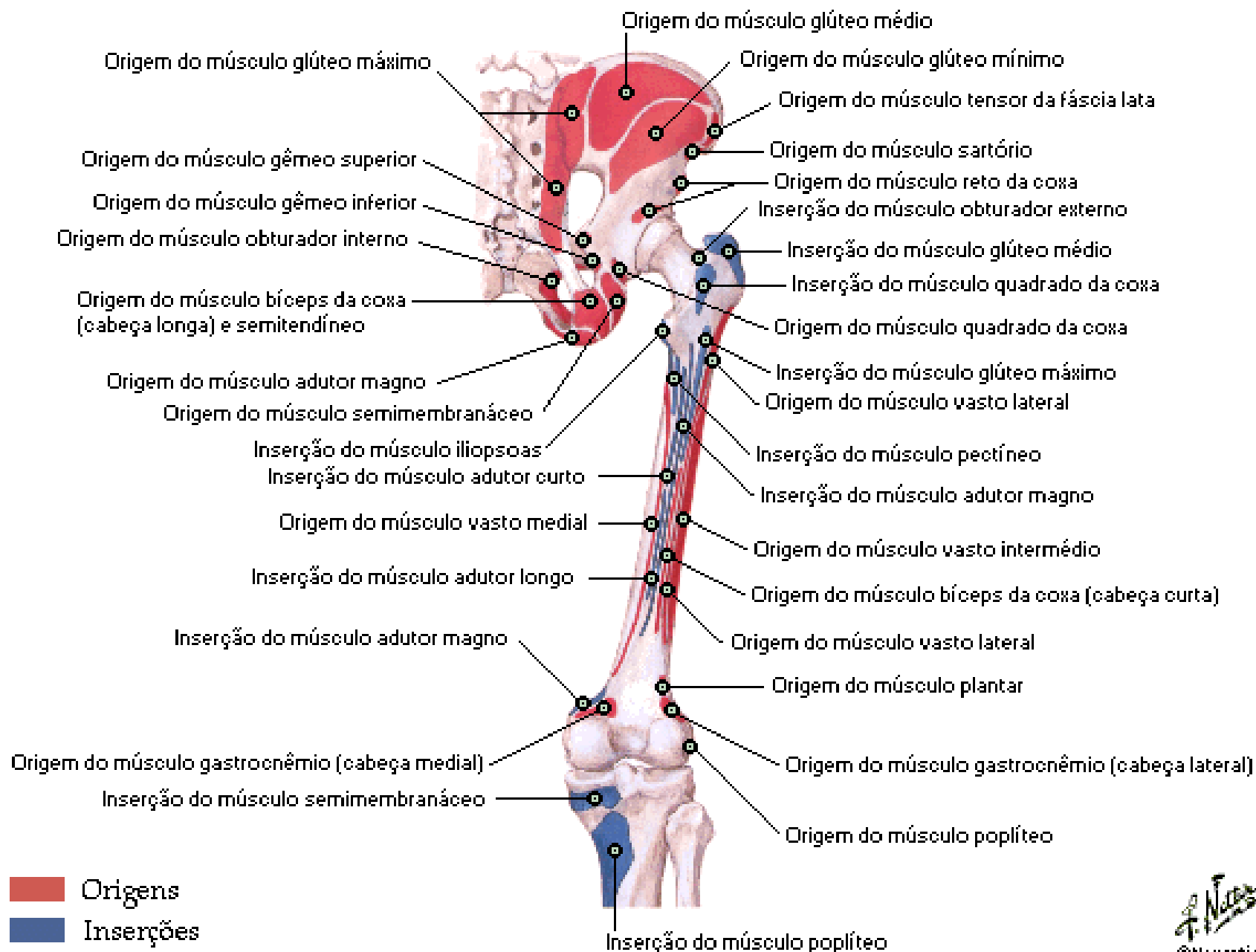
■ Origens
■ Inserções

Vista Anterior



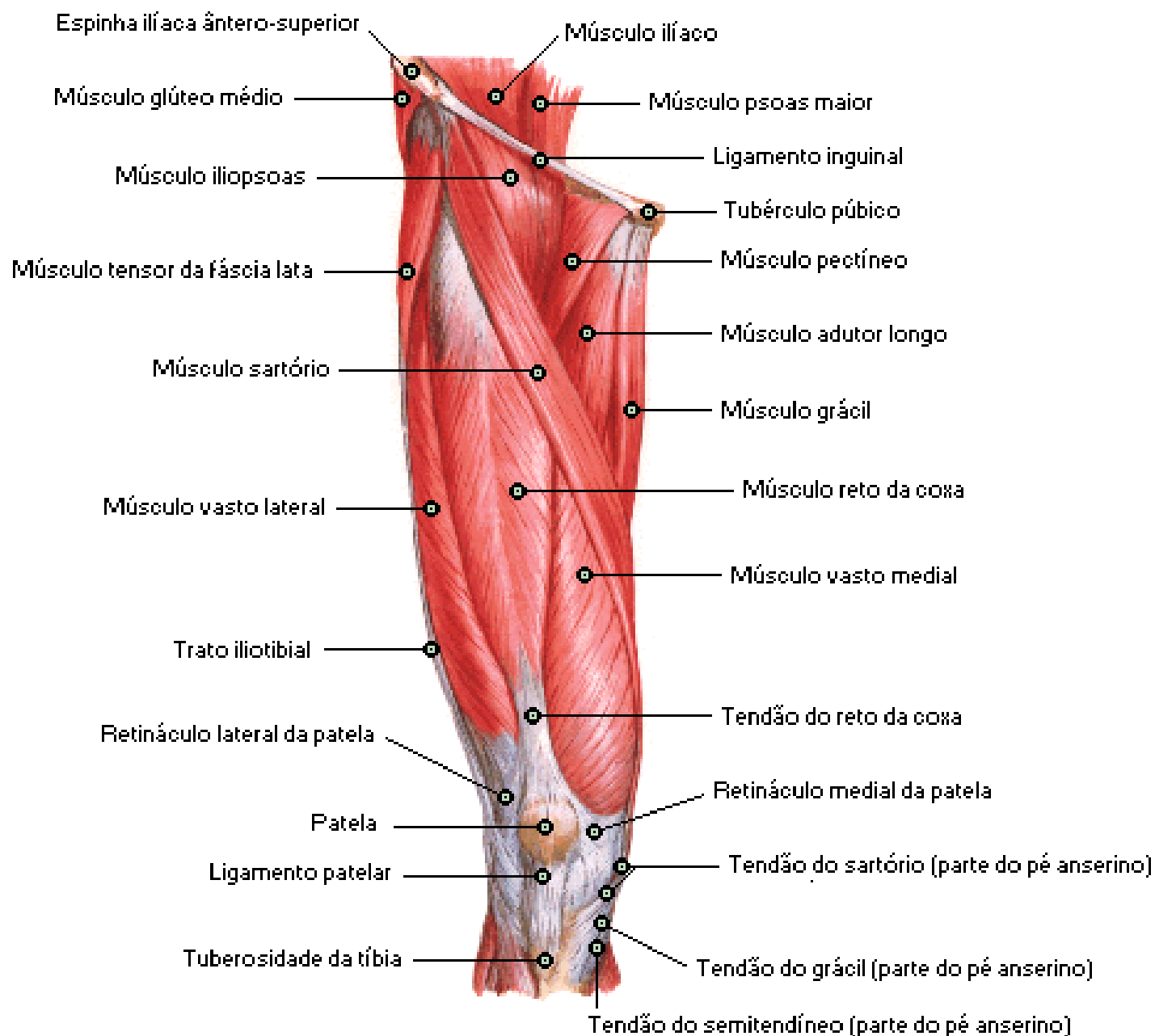
Inserções Ósseas dos Músculos do Quadril e Coxa

Vista Posterior



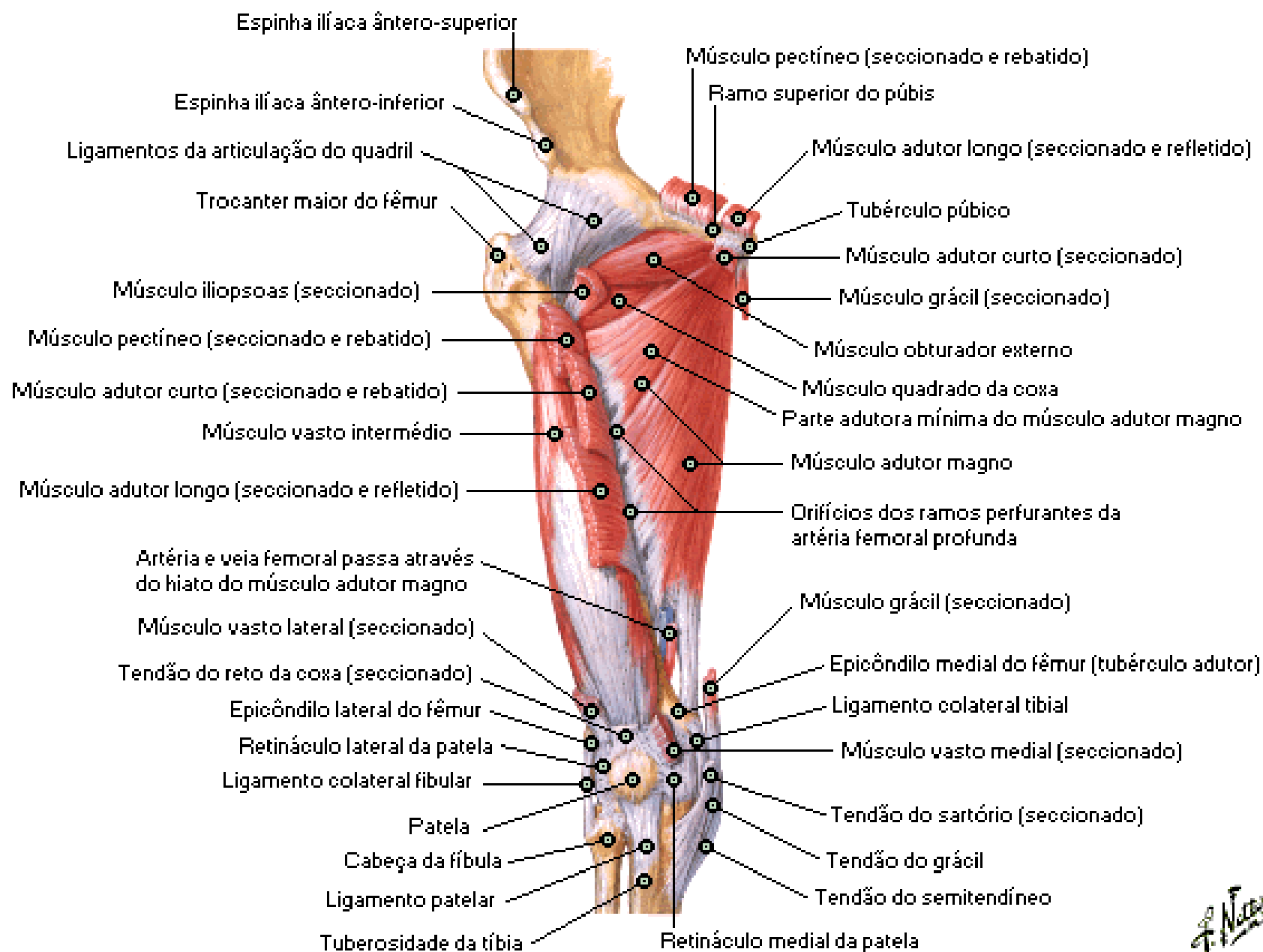
Músculos da Coxa

Vista Anterior - Dissecação Superficial



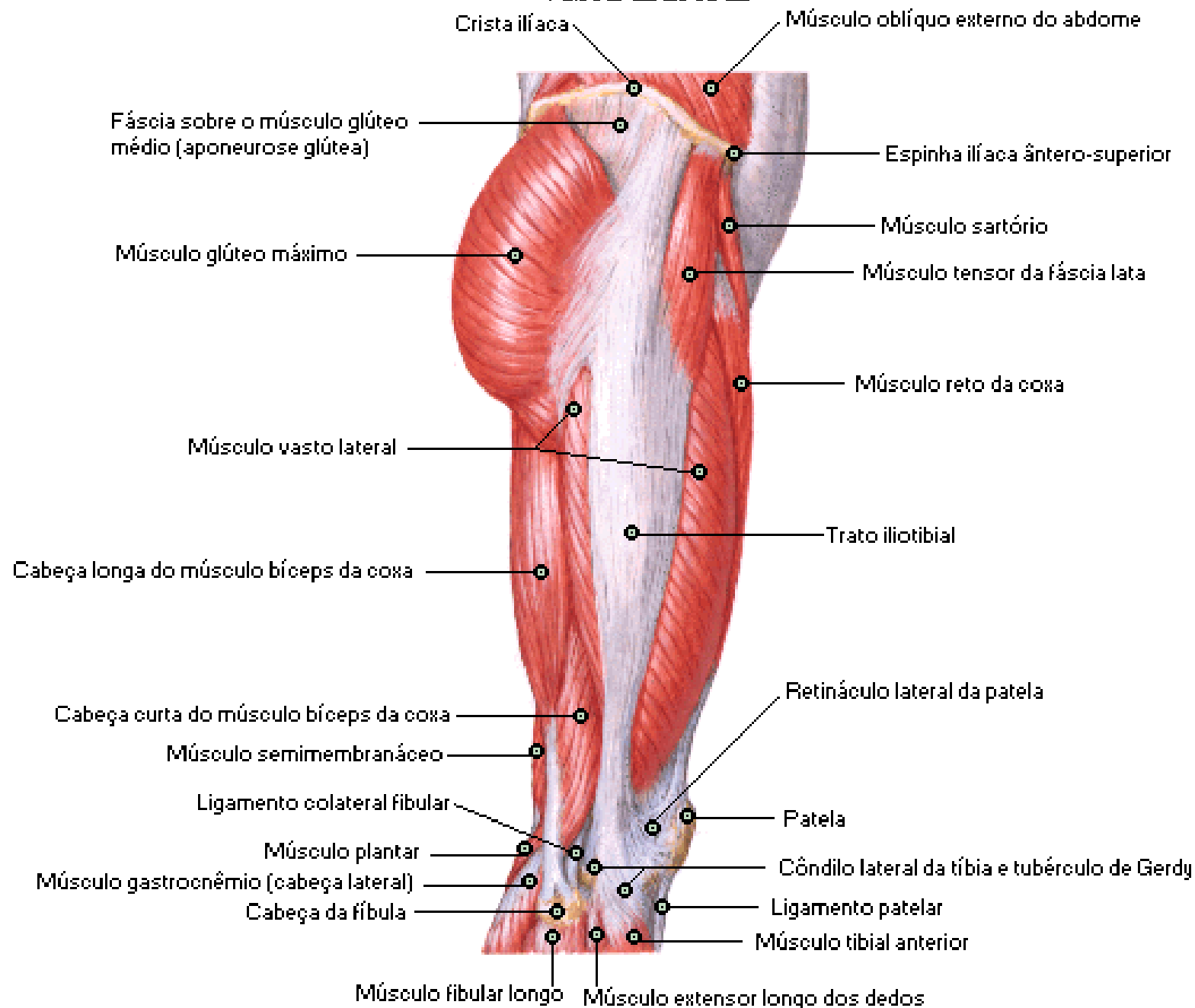
Músculos da Coxa

Vista Anterior - Dissecação Profunda



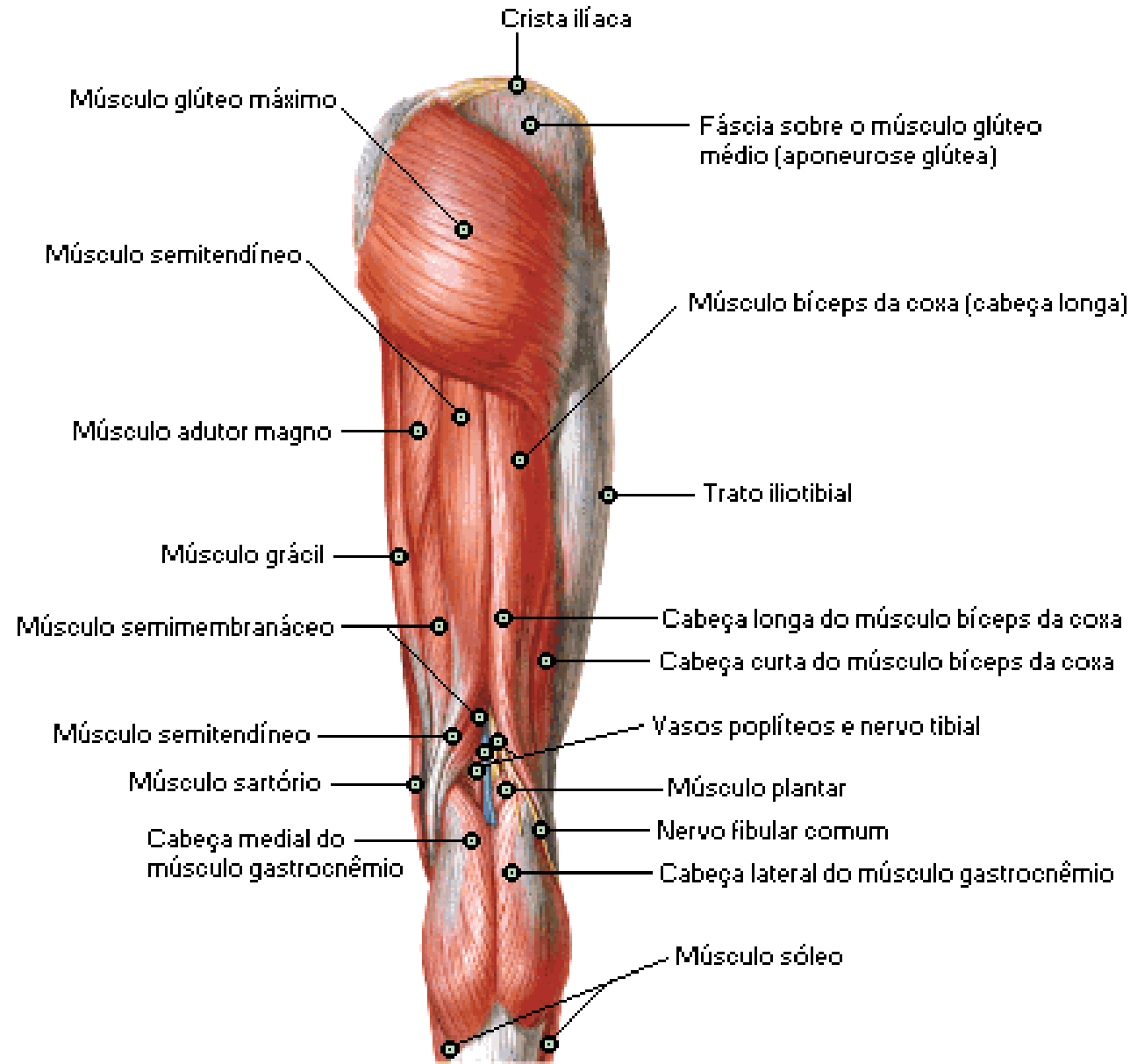
Músculos do Quadril e Coxa

Vista Lateral



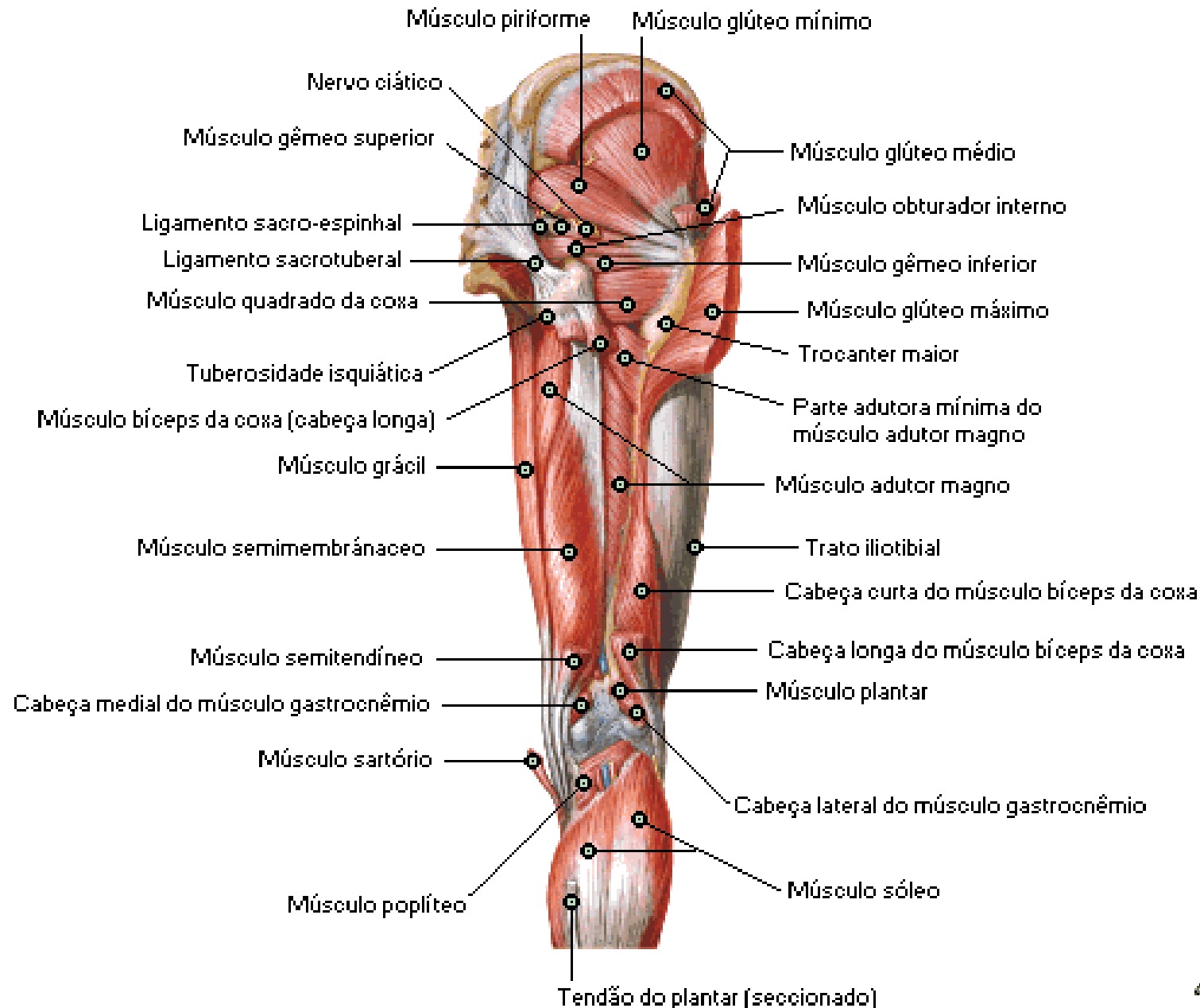
Músculos do Quadril e Coxa

Vista Posterior - Dissecação Superficial



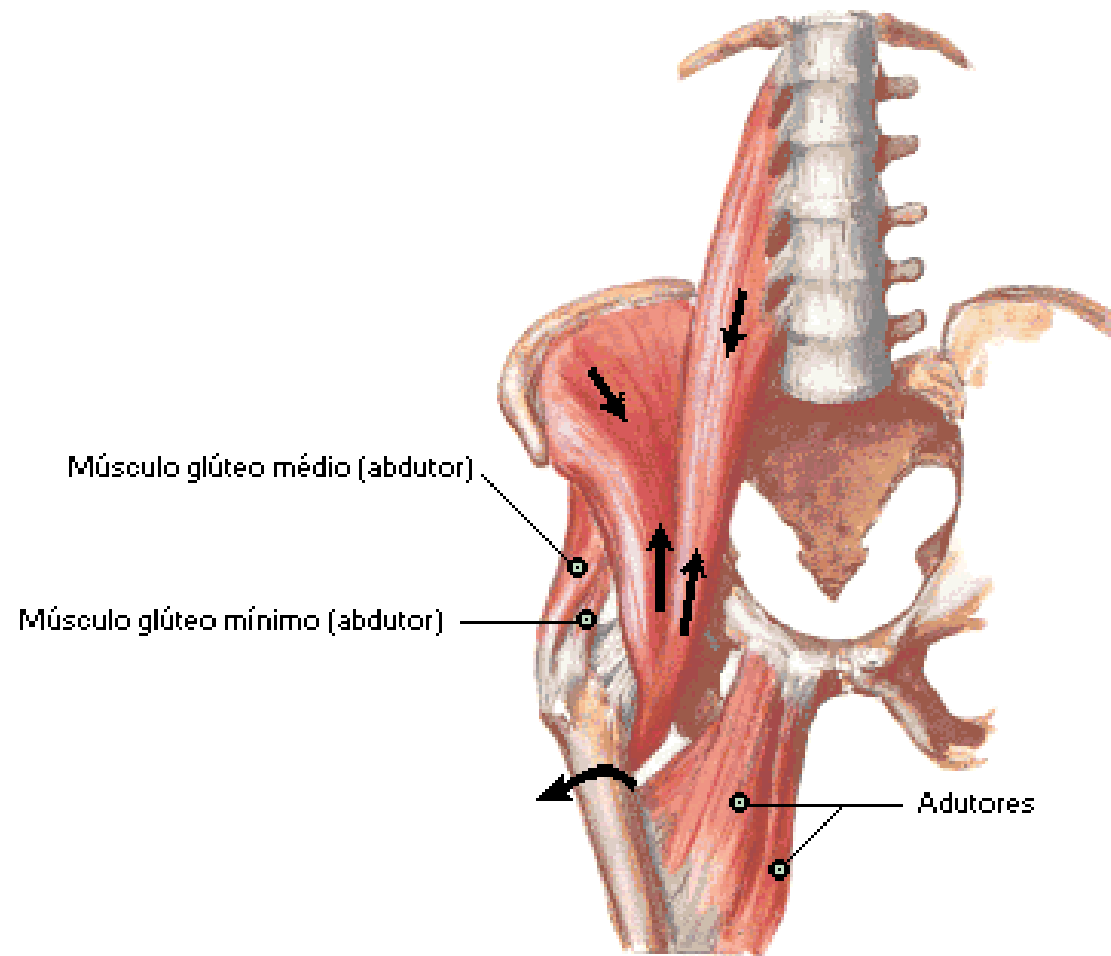
Músculos do Quadril e Coxa

Vista Posterior - Dissecação Profunda



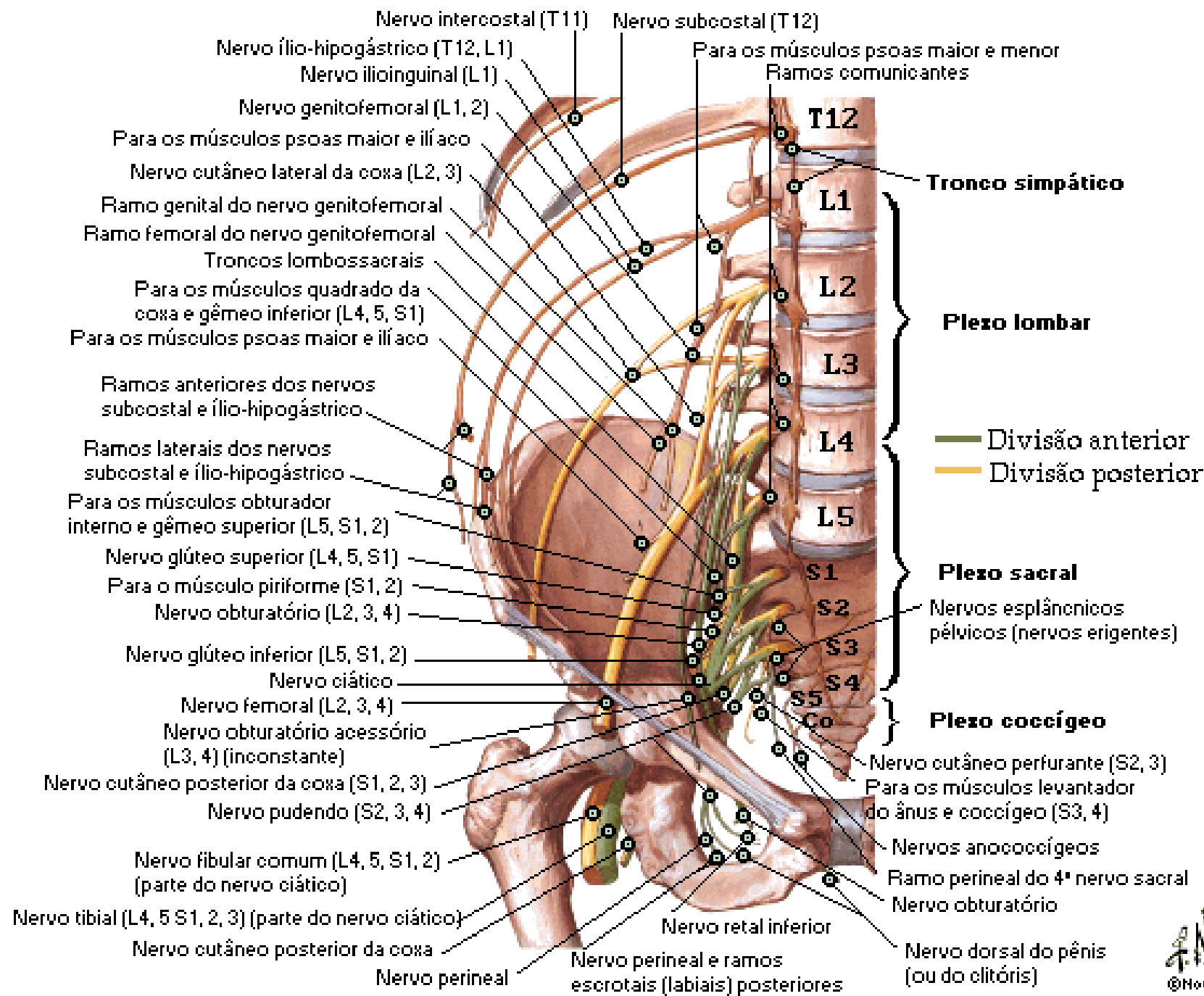
Músculos Psoas e Íliaco

Ação



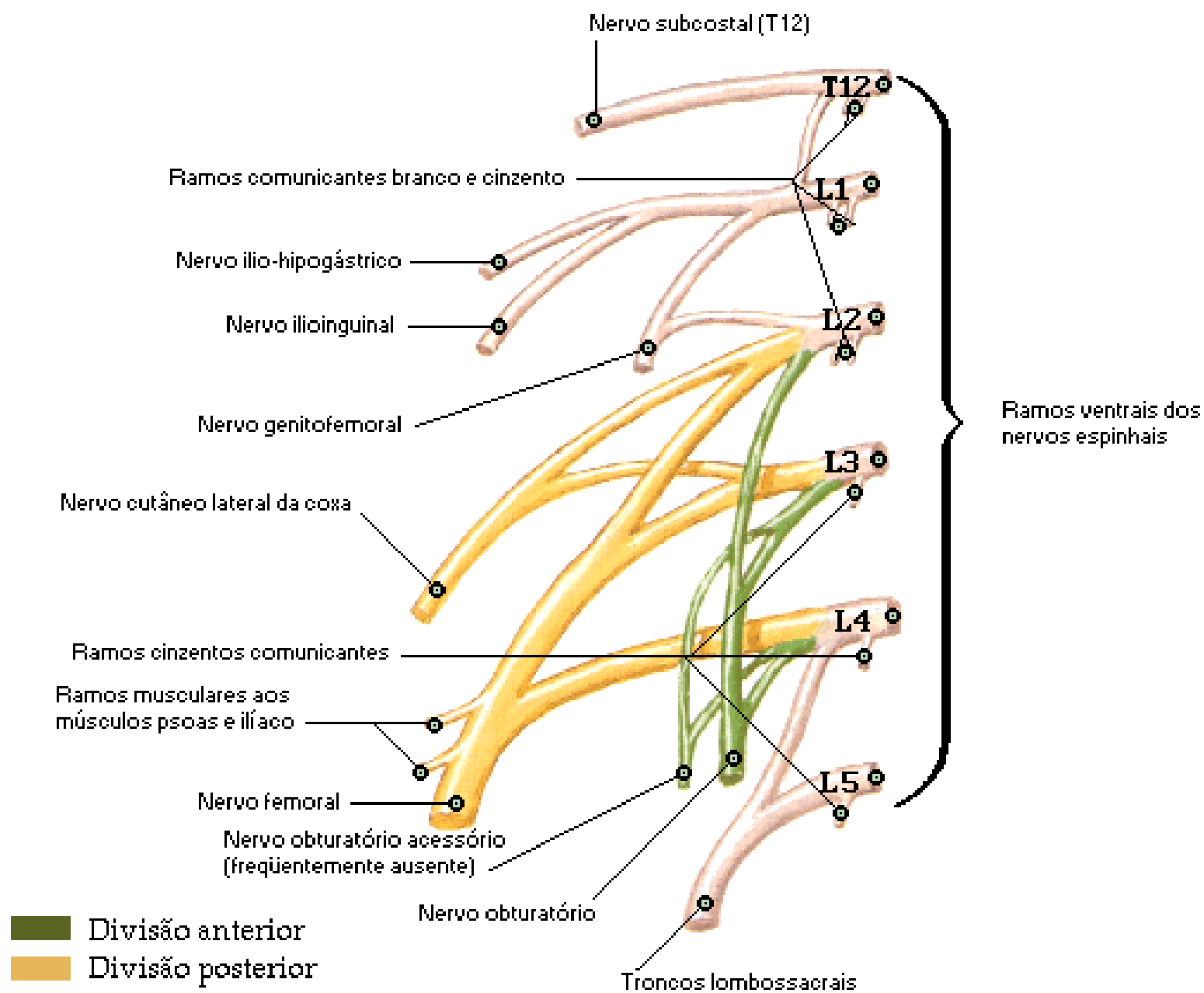
Nota: as setas indicam a direção de ação do músculo iliopsoas

Plexos Lombossacral e Coccígeo

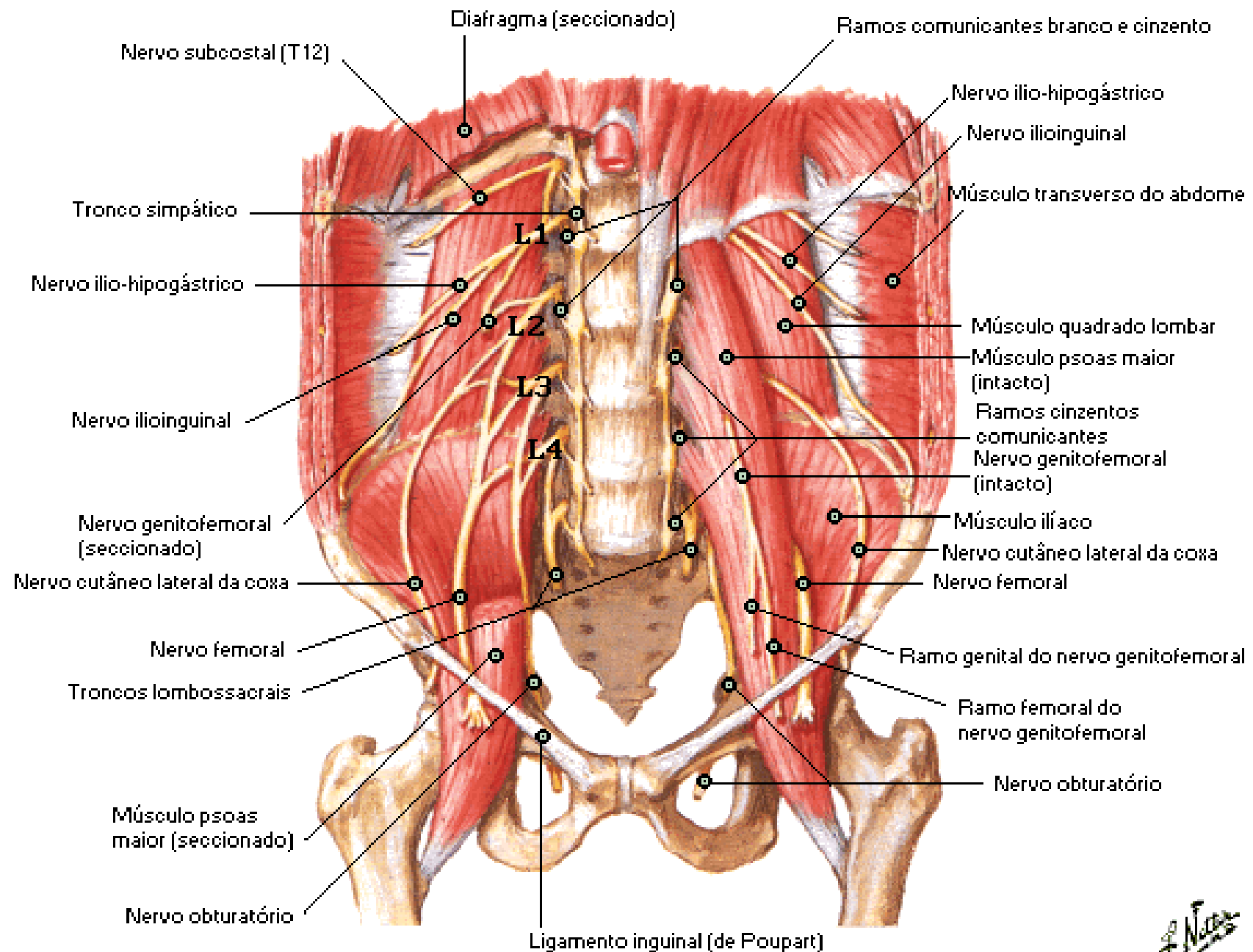


Plexo Lombor

Esquema

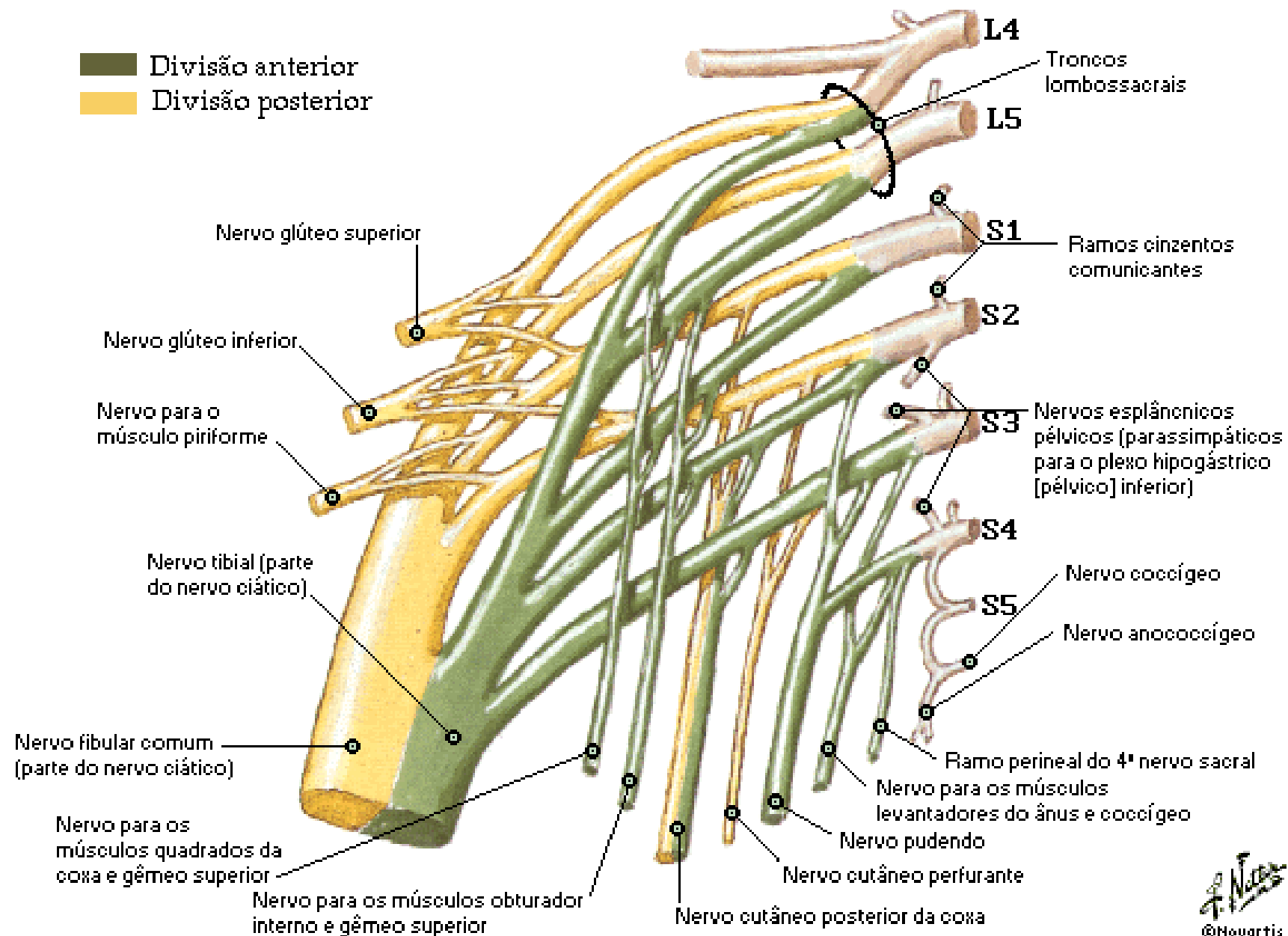


Plexo Lombor in Situ

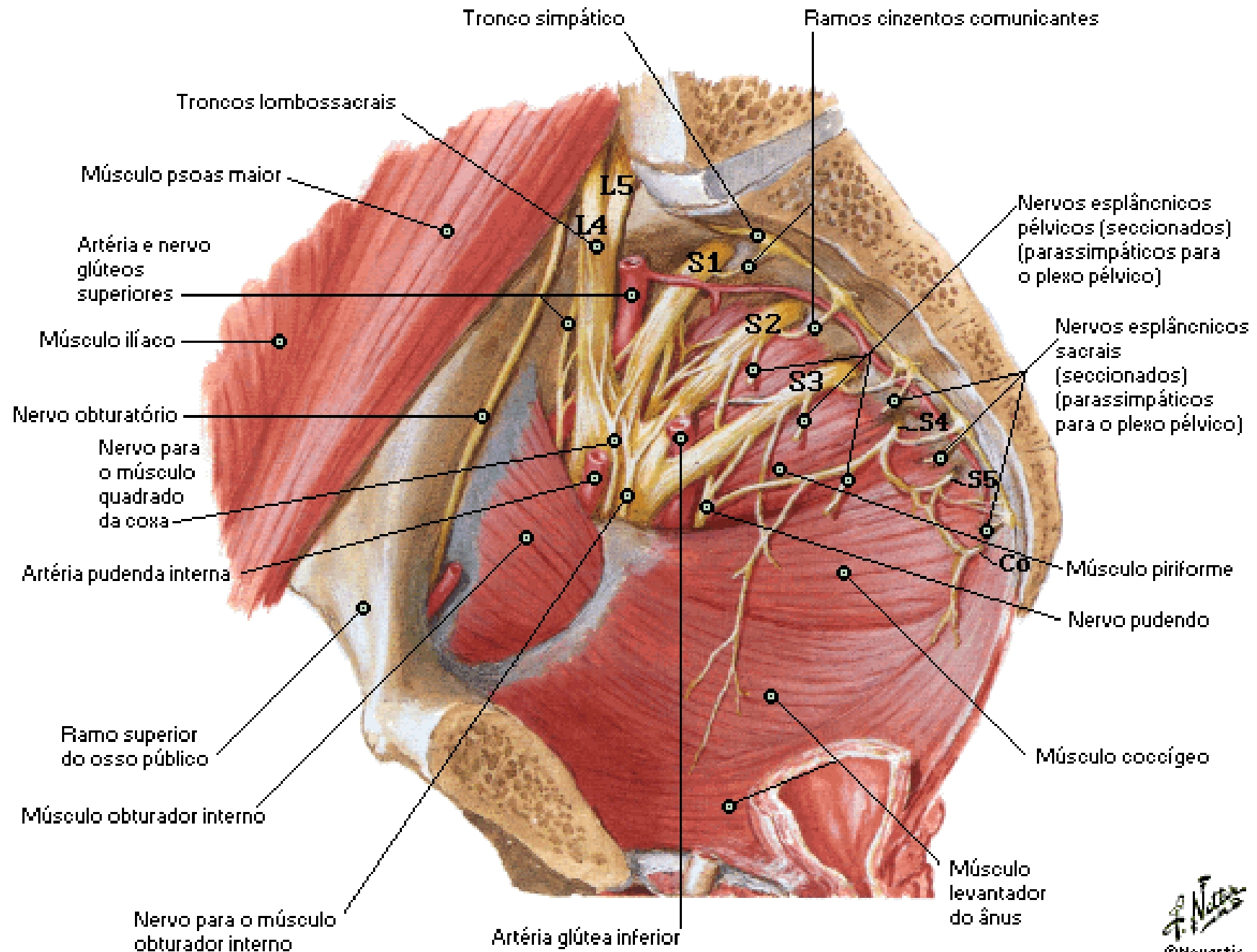


Plexos Sacral e Coccígeo

Esquema

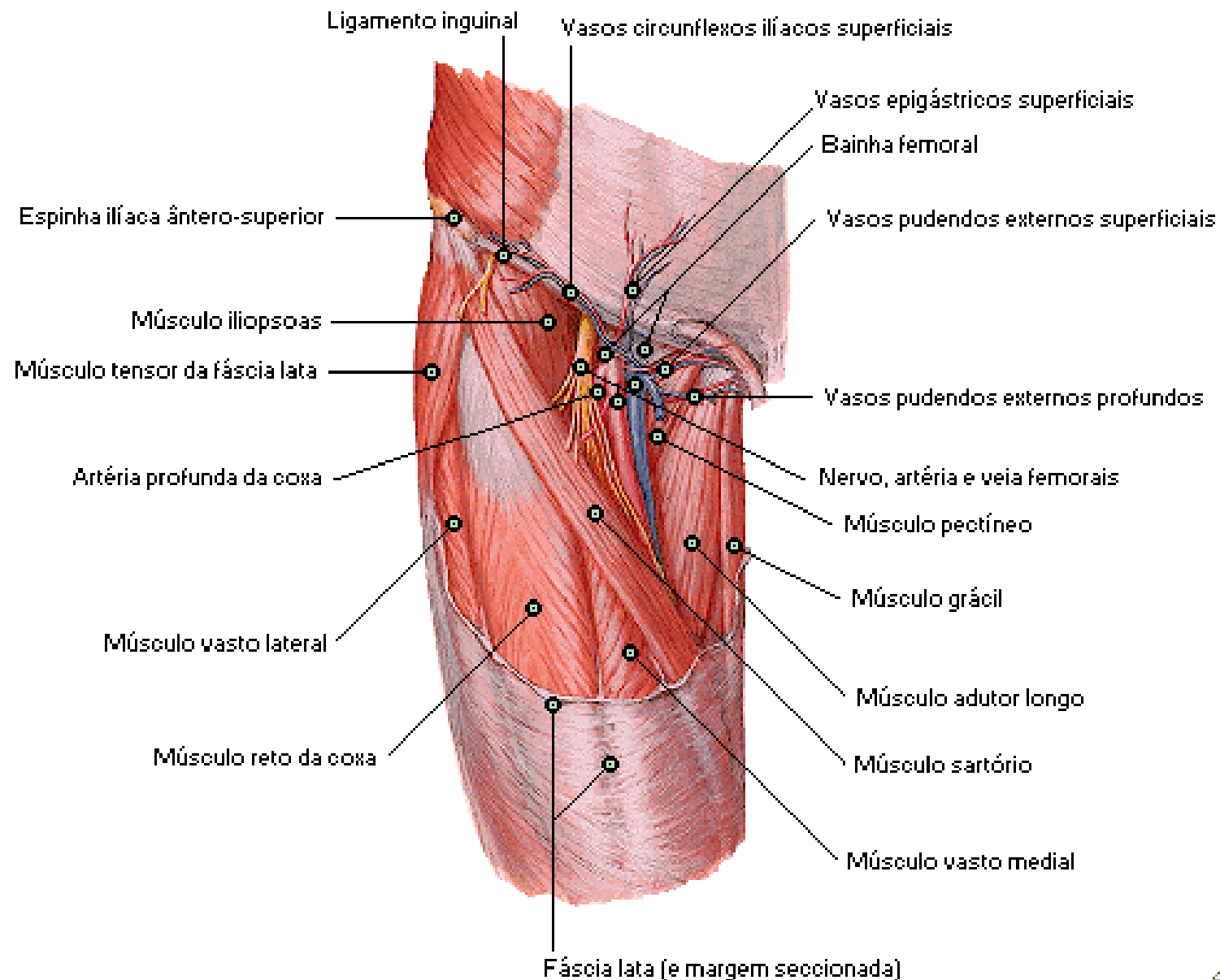


Plexos Sacral e Coccígeo in Situ



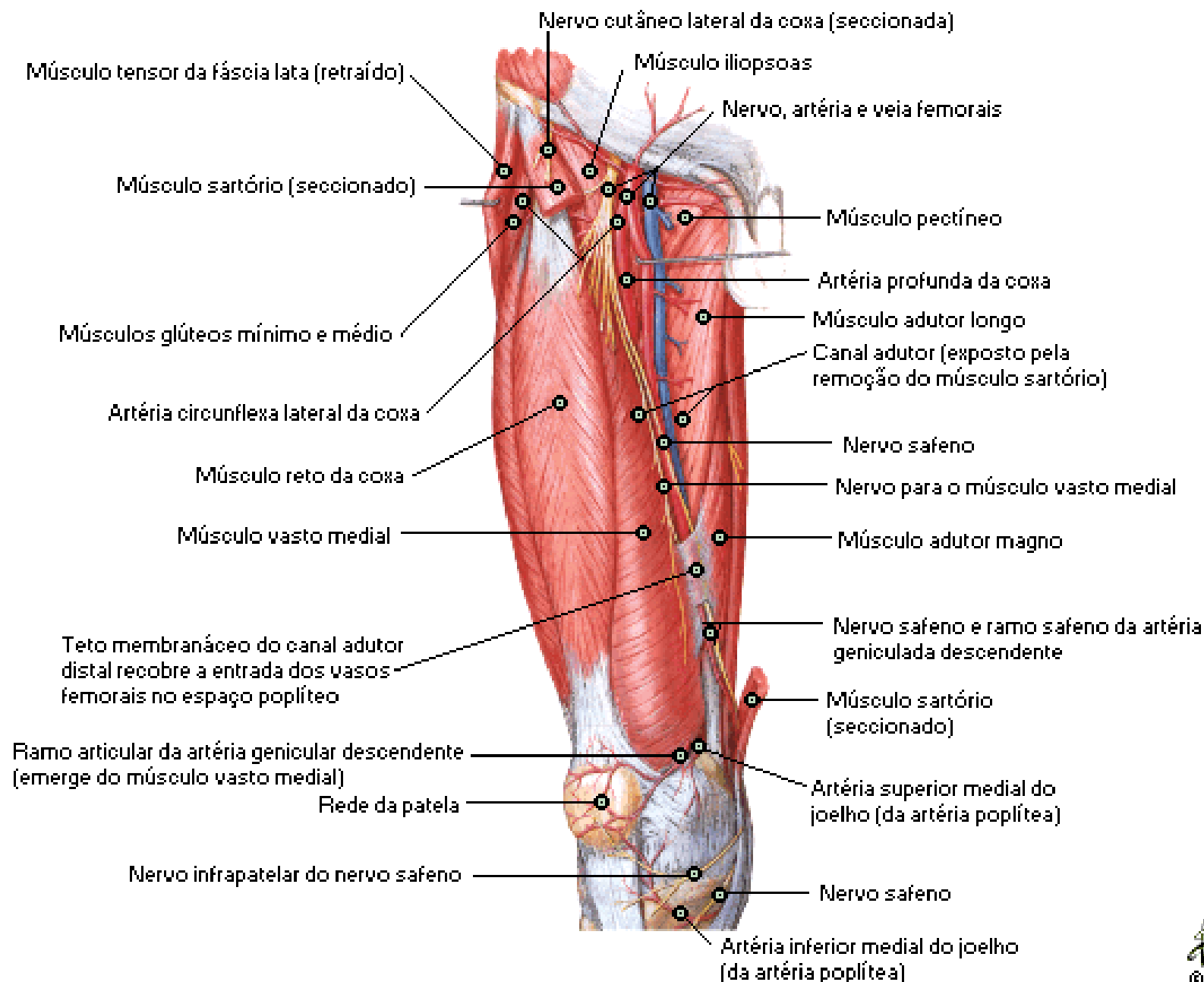
Artérias e Nervos da Coxa

Vista Anterior Superficial



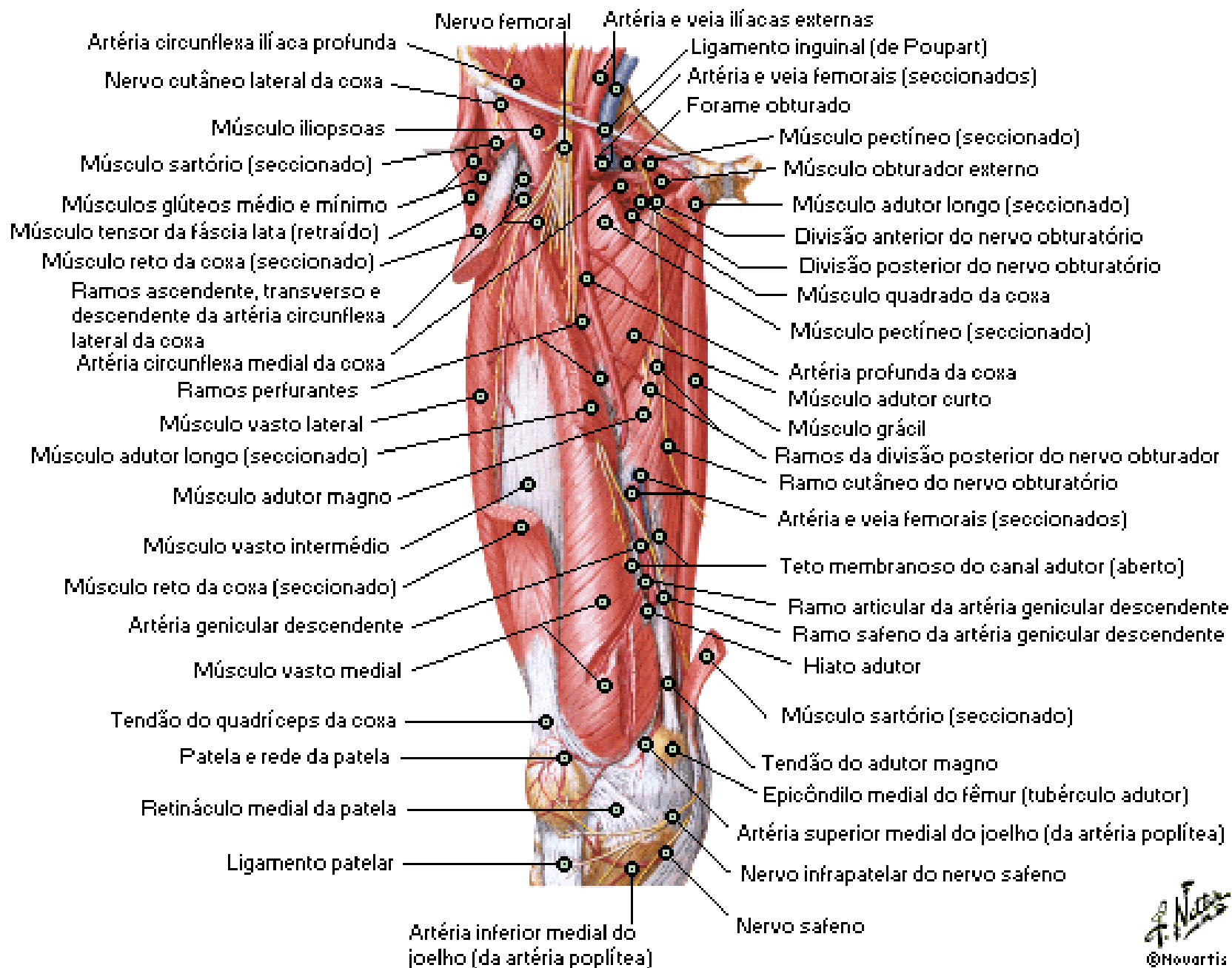
Artérias e Nervos da Coxa

Vista Anterior Profunda



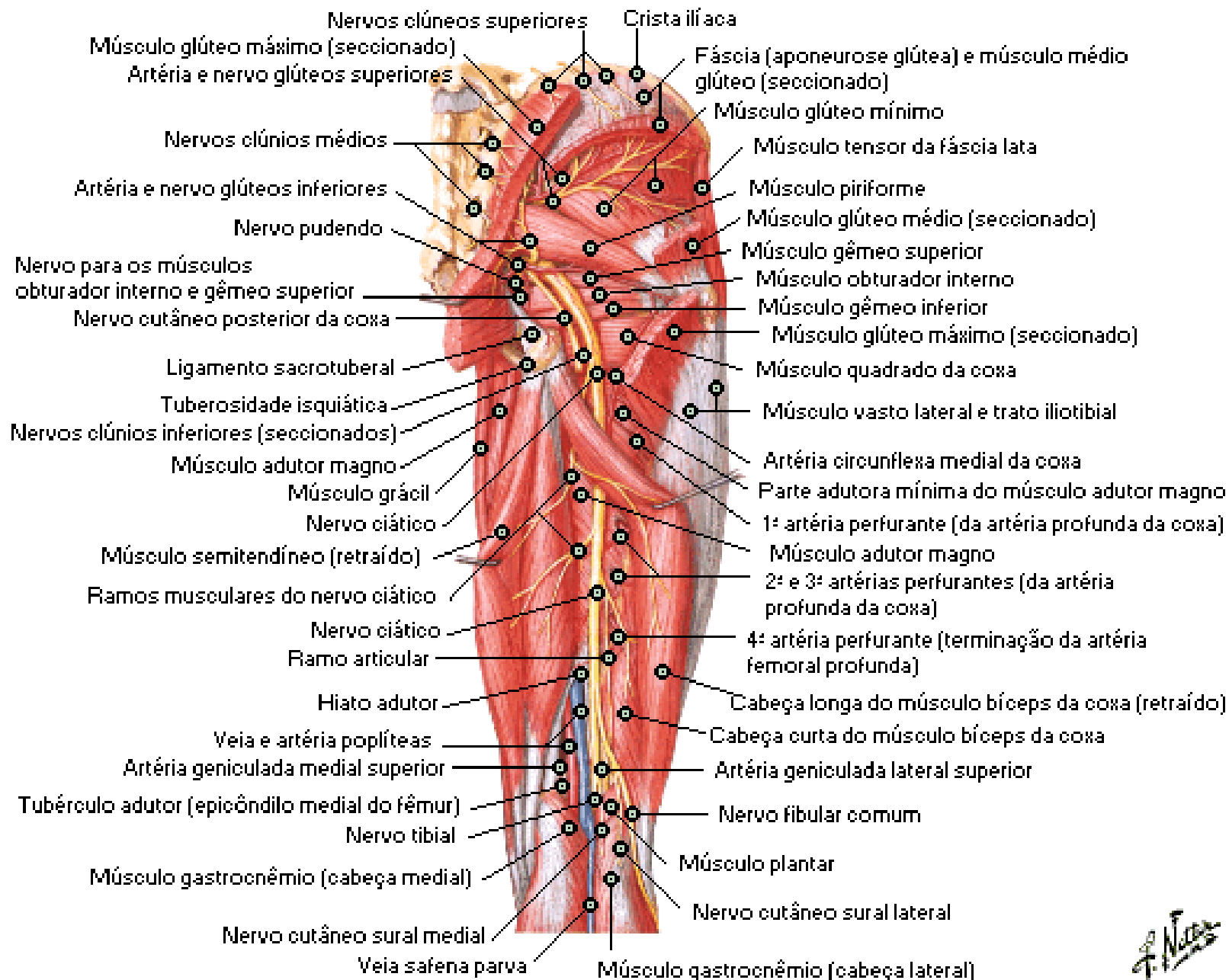
Artérias e Nervos da Coxa

Vista Anterior Profunda

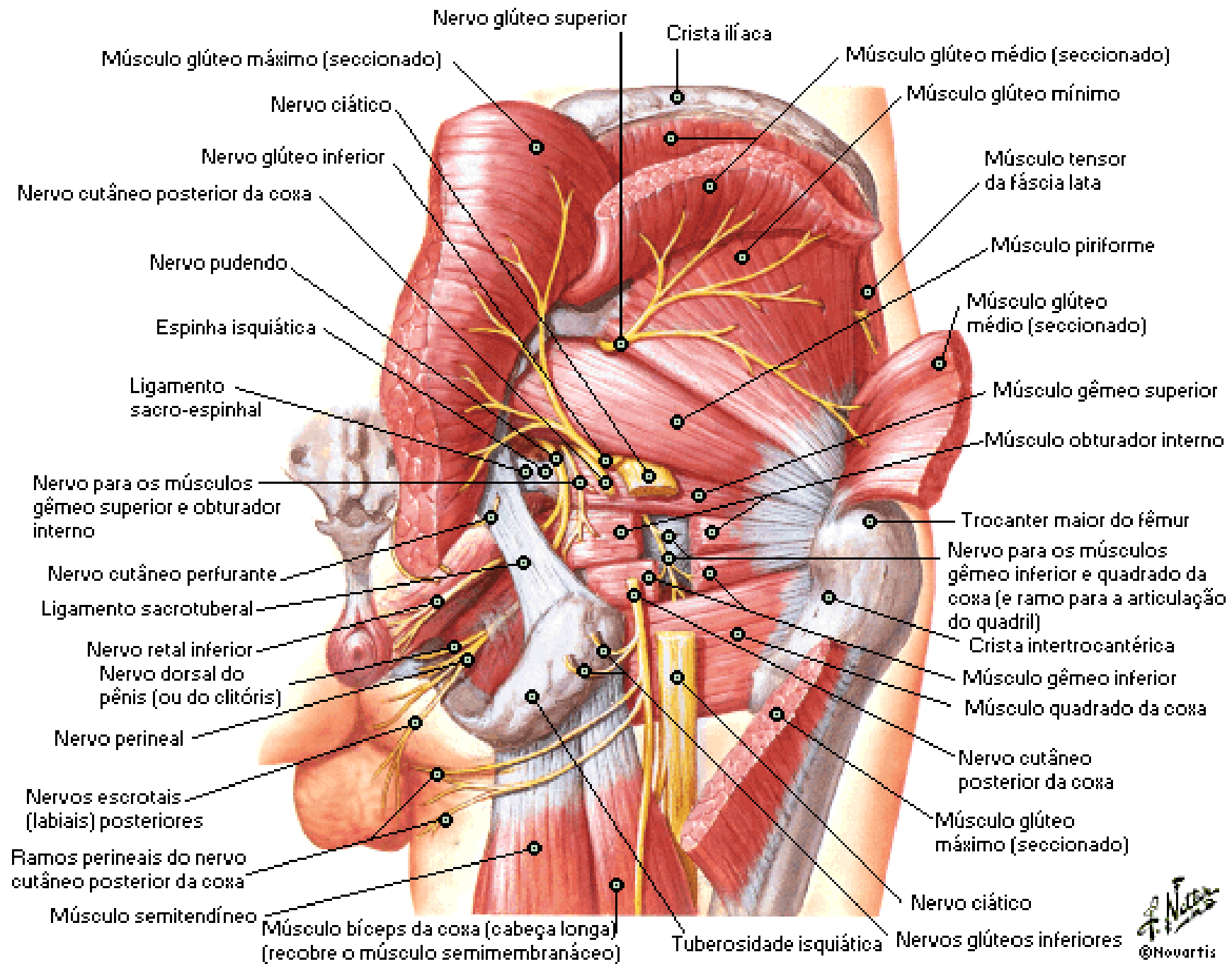


Artérias e Nervos da Coxa

Vista Posterior

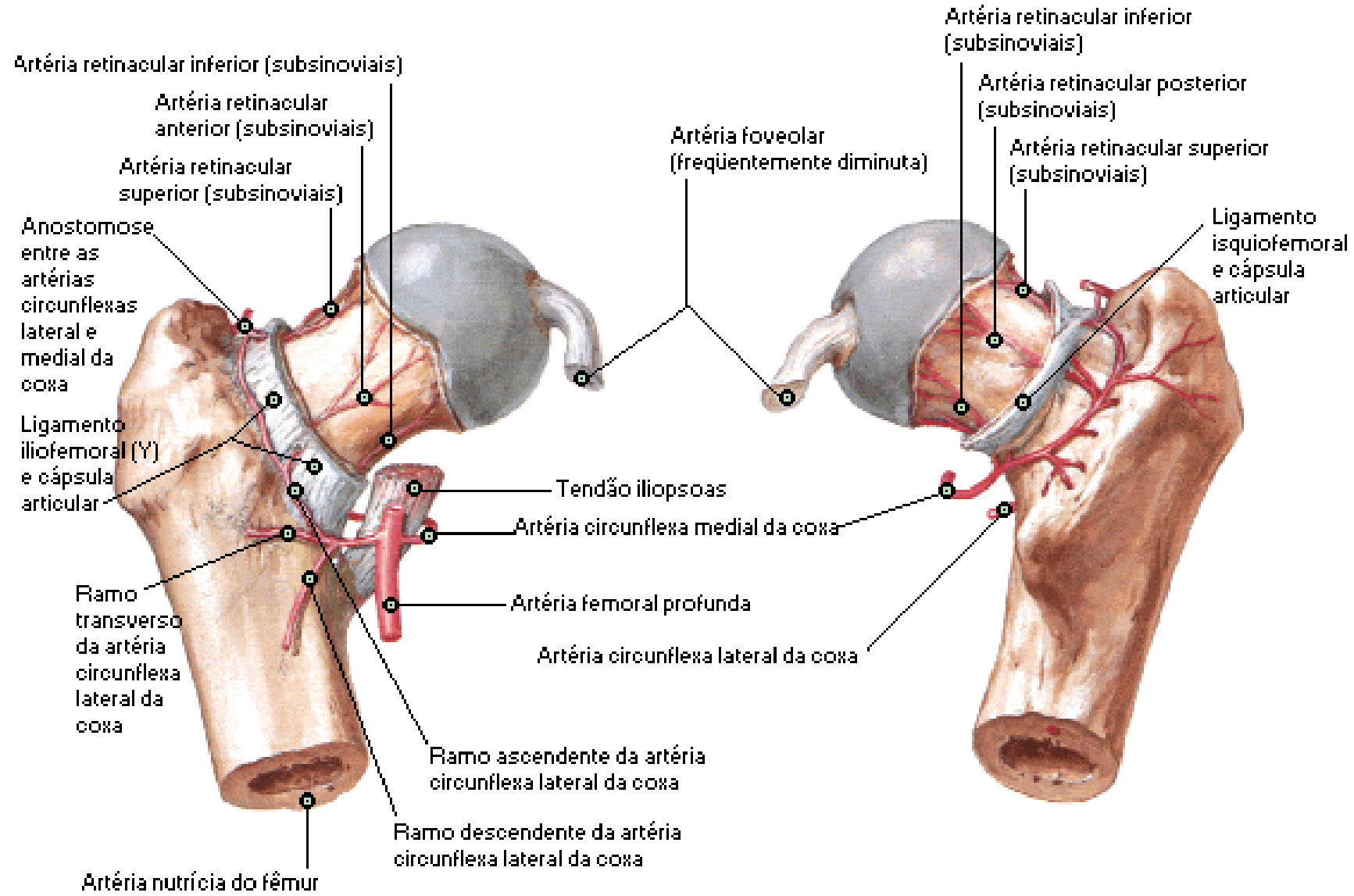


Nervos do Quadril e Região Glútea



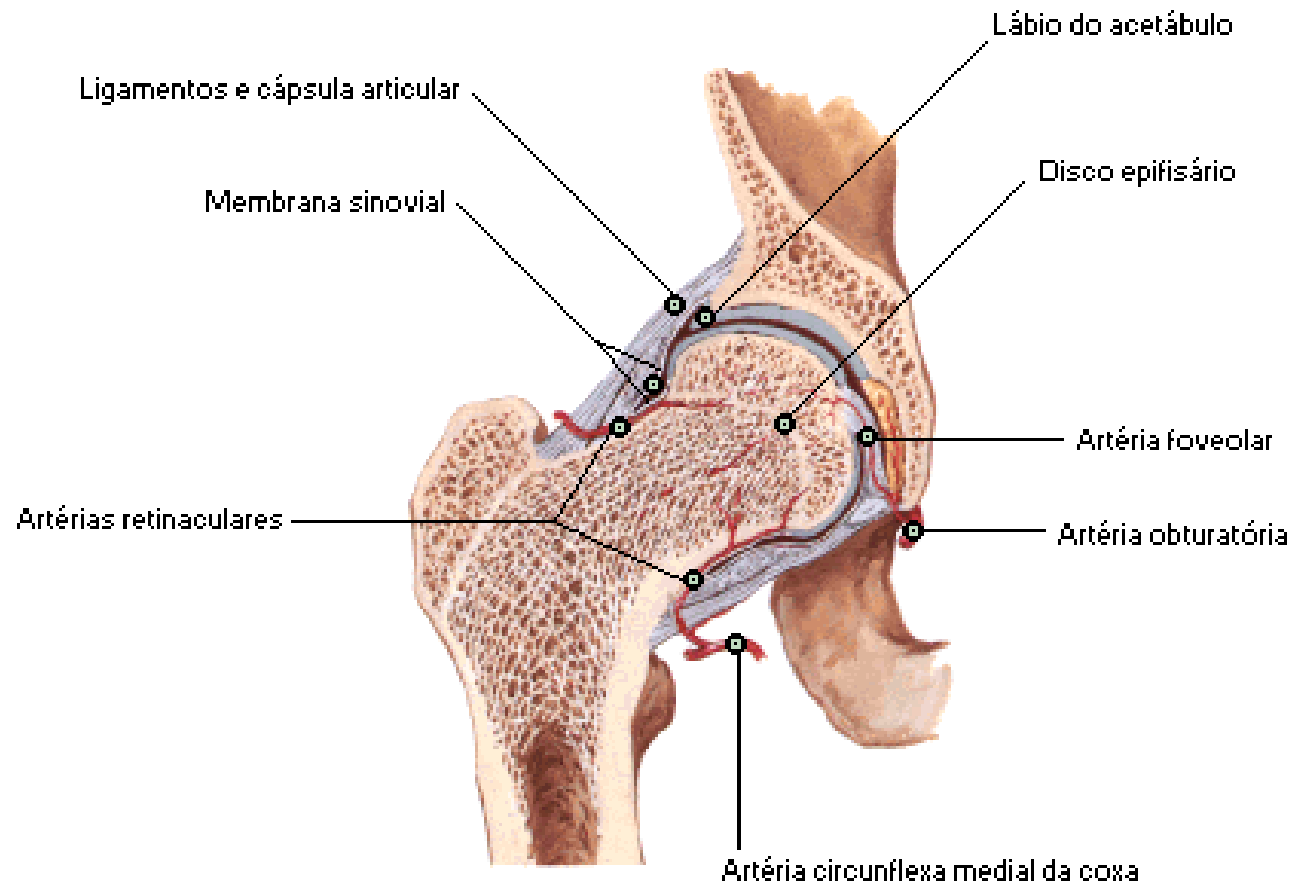
Artérias da Cabeça e Colo do Fêmur

Vistas Anterior e Posterior



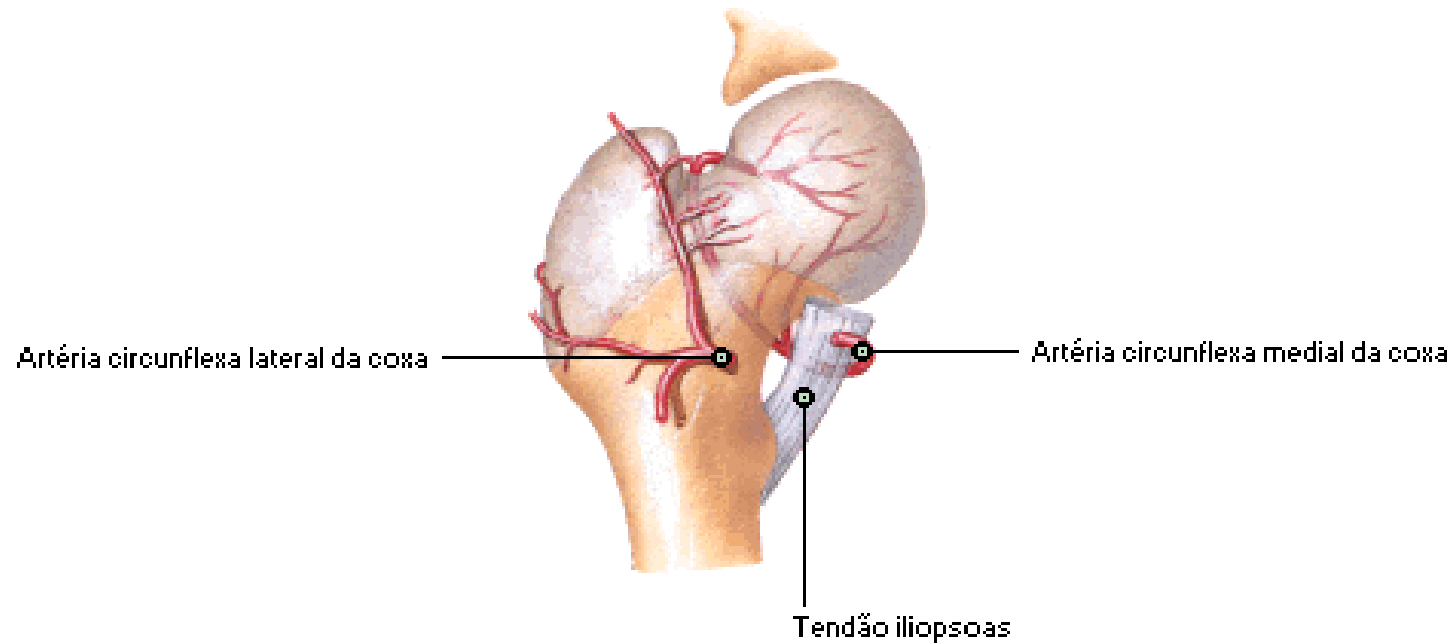
Artérias da Cabeça e Colo do Fêmur

Secção Coronal



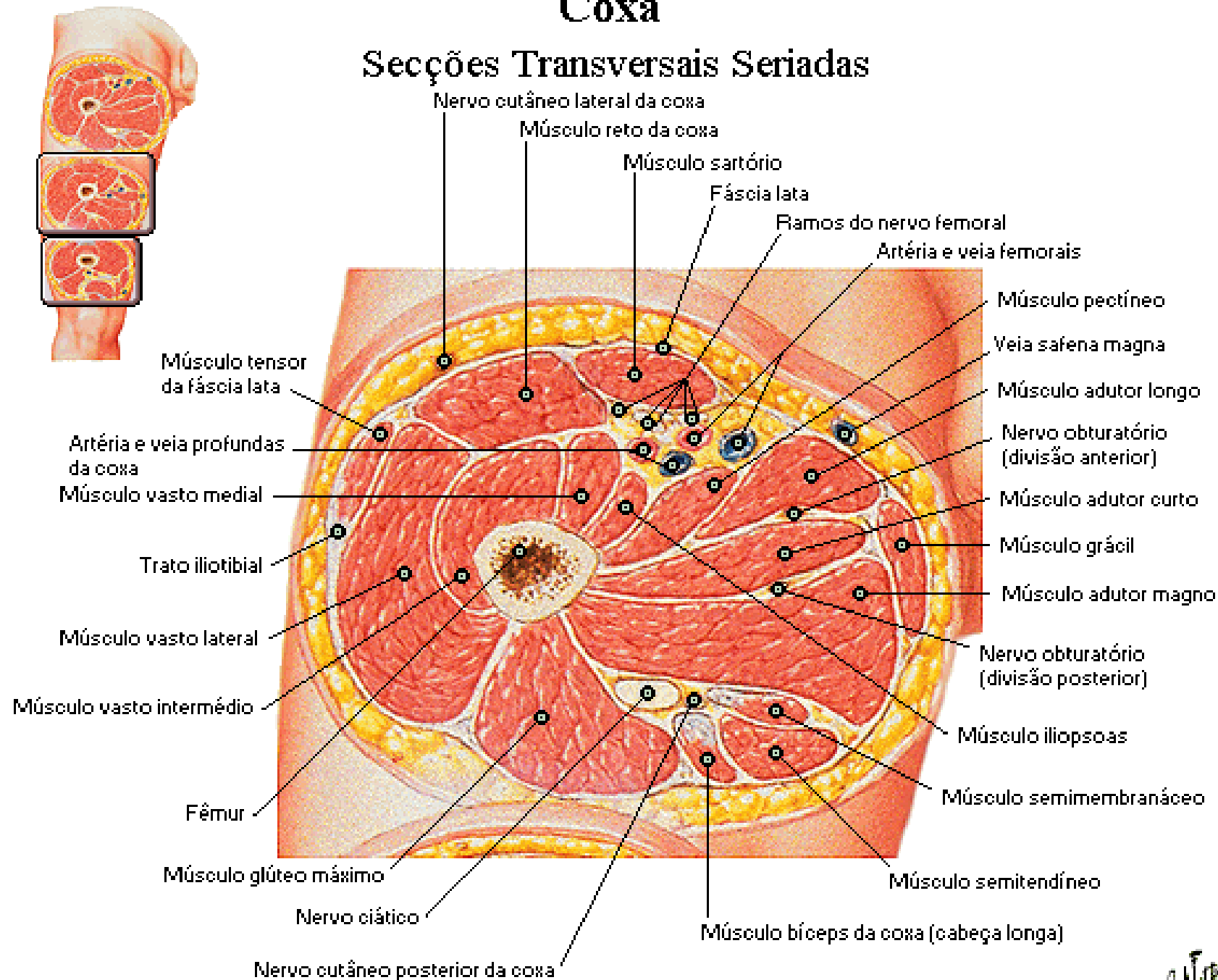
Artérias da Cabeça e Colo do Fêmur

Fêmur de uma Criança - Vista Anterior



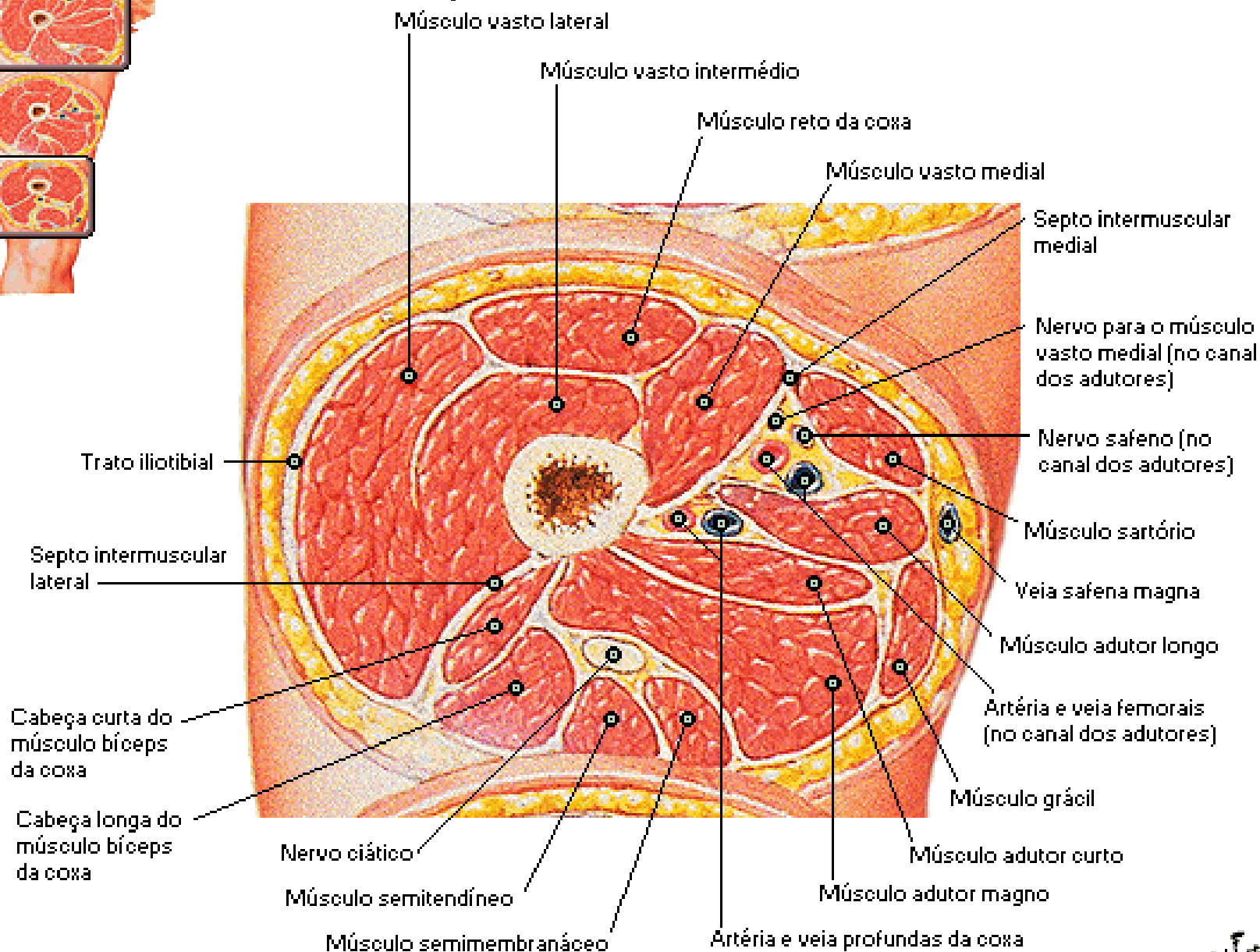
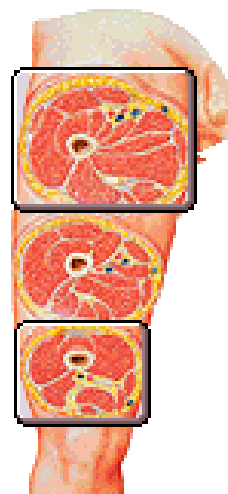
Coxa

Secções Transversais Seriadas



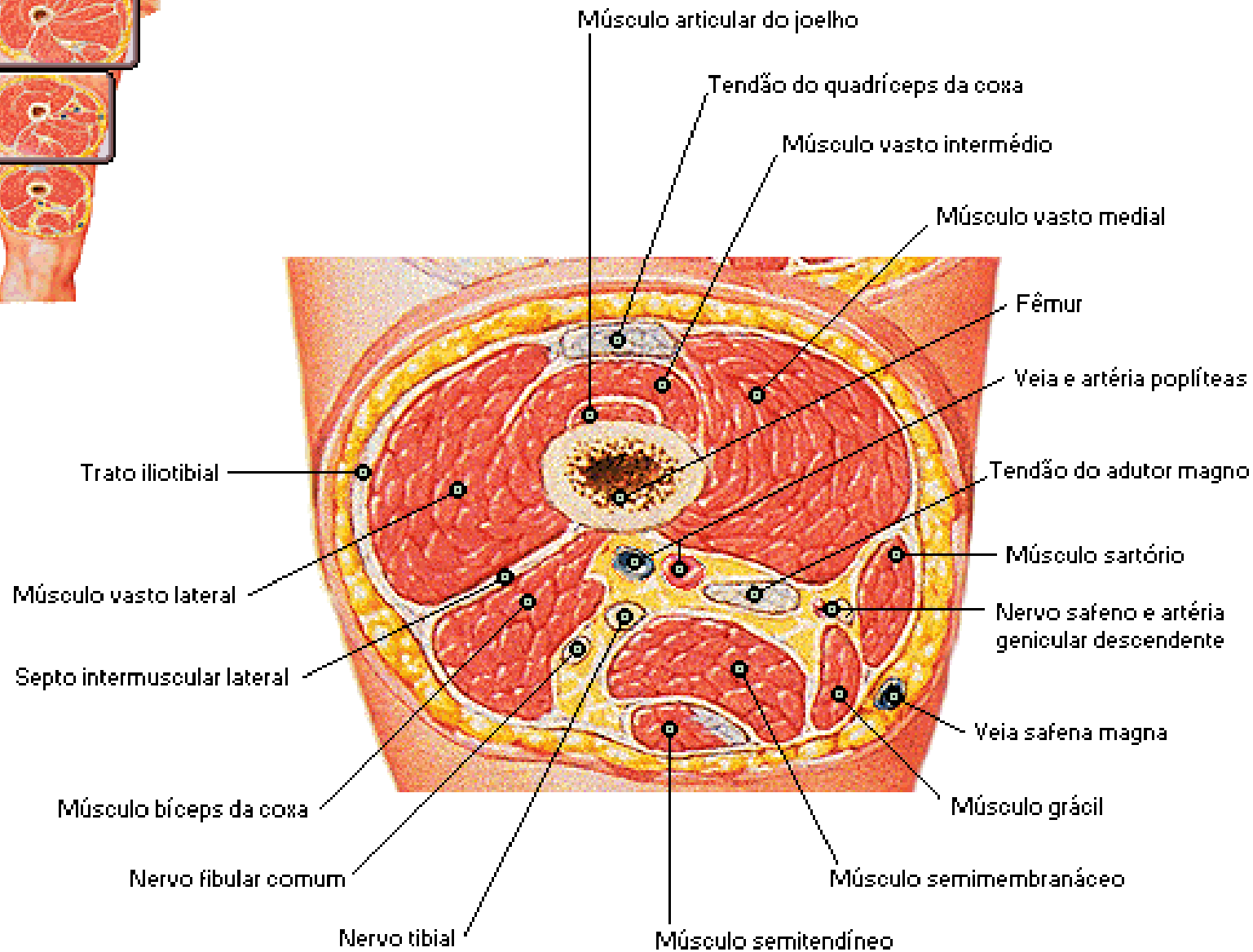
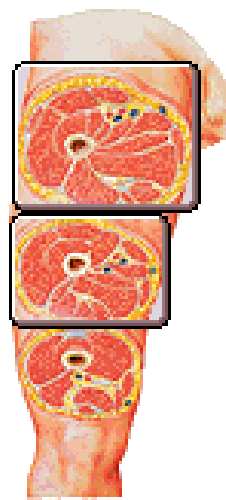
Coxa

Secção Transversal Média



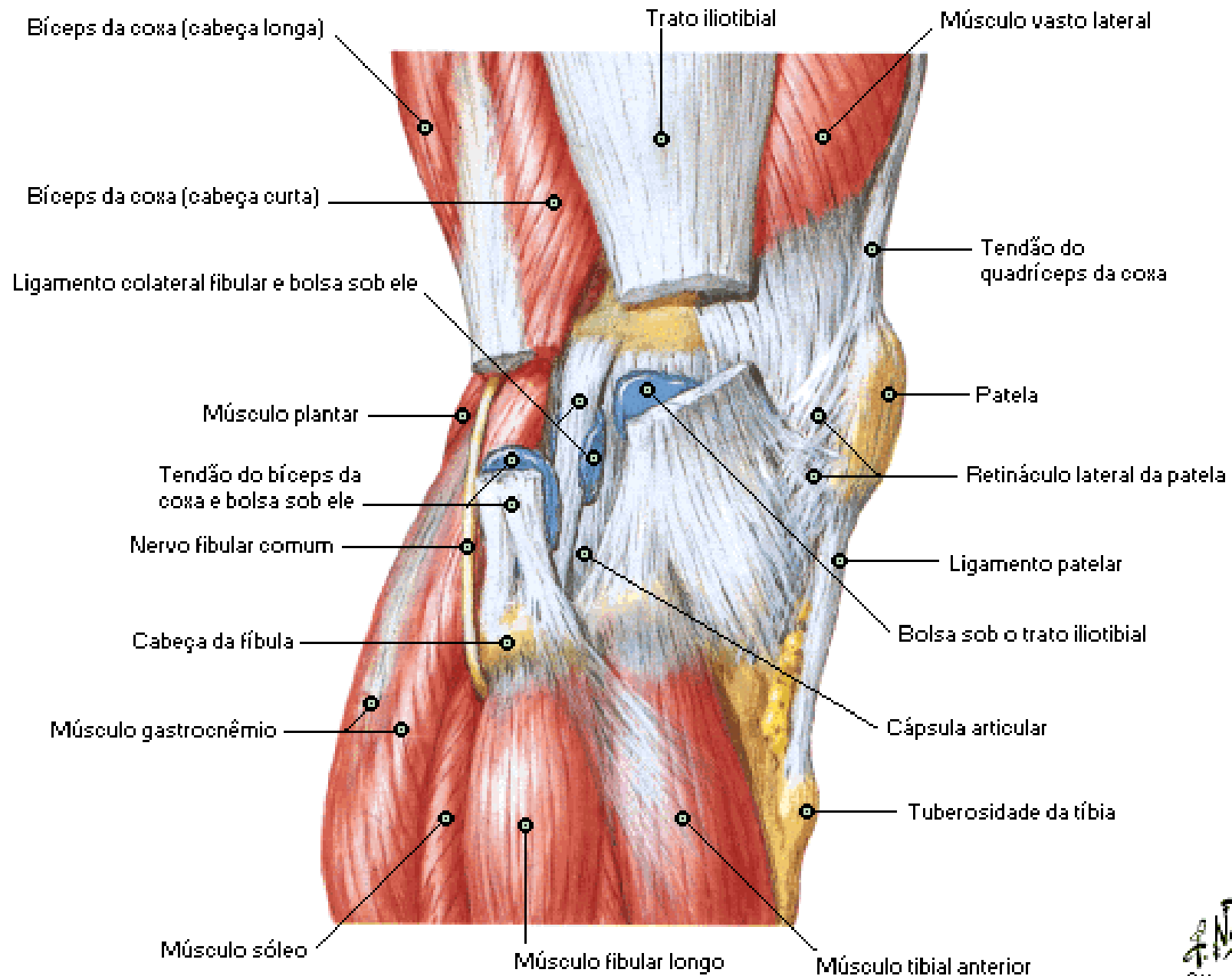
Coxa

Secção Transversal Distal



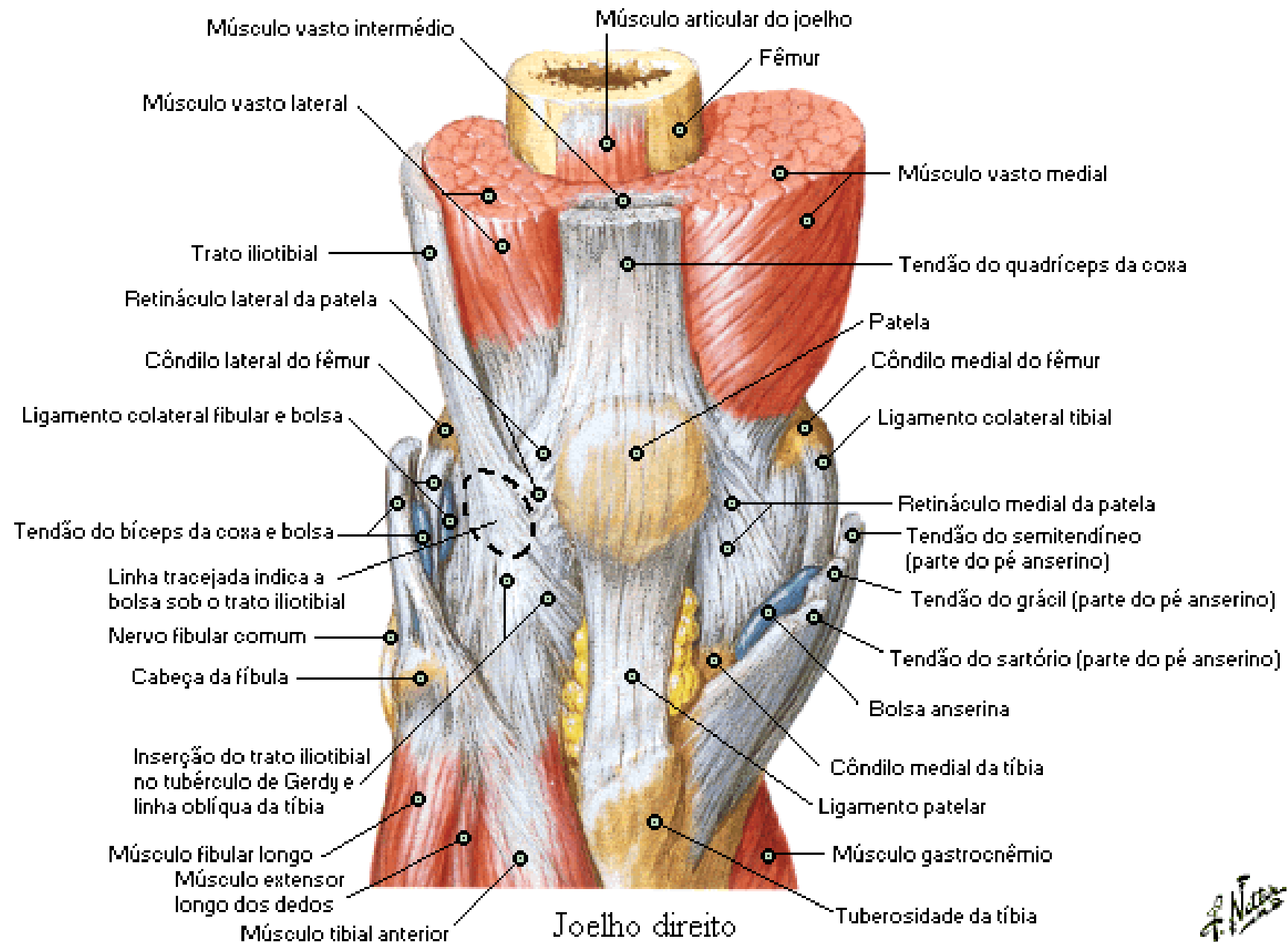
Joelho

Vista Lateral



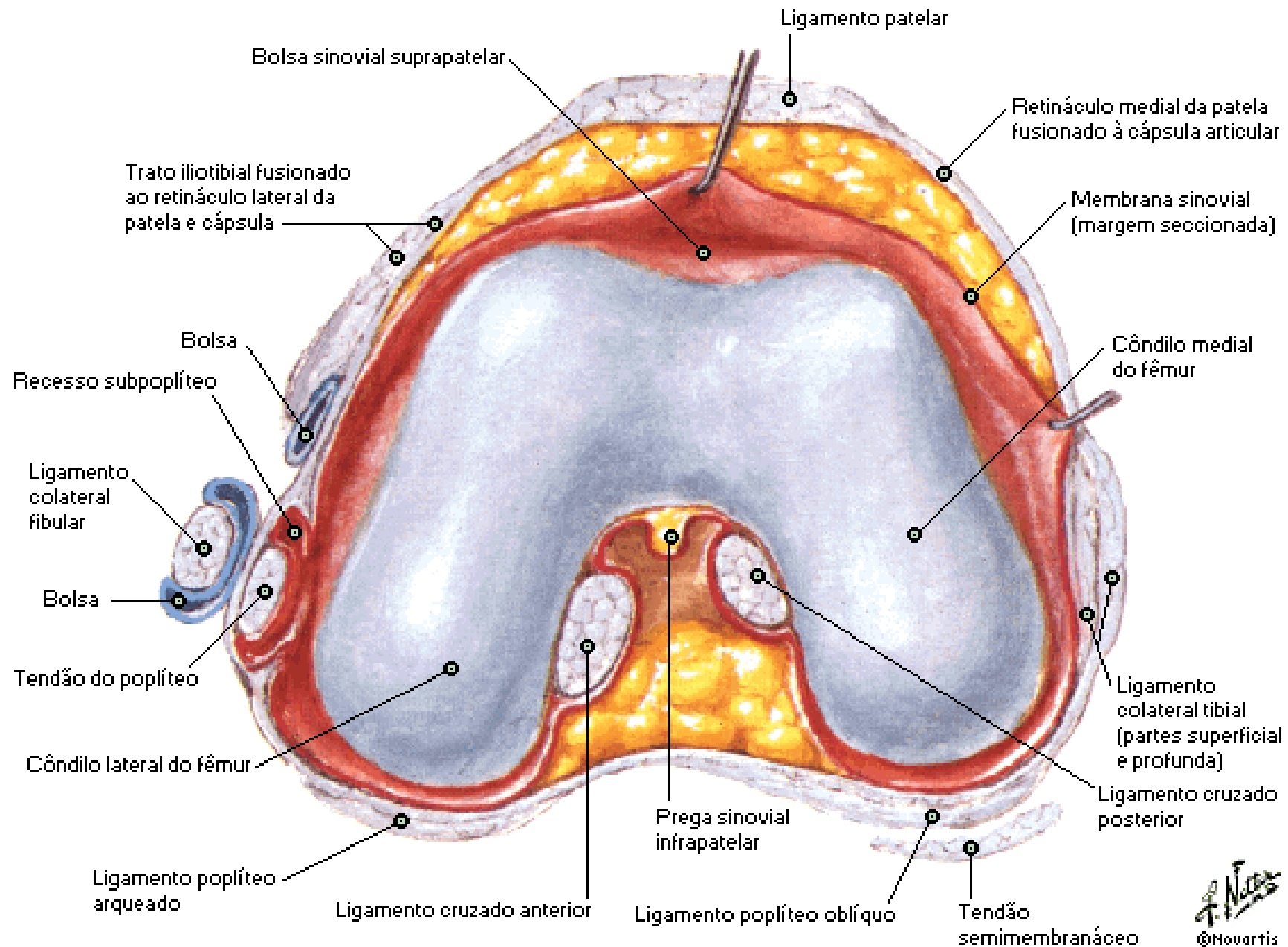
Joelho em Extensão

Vista Anterior



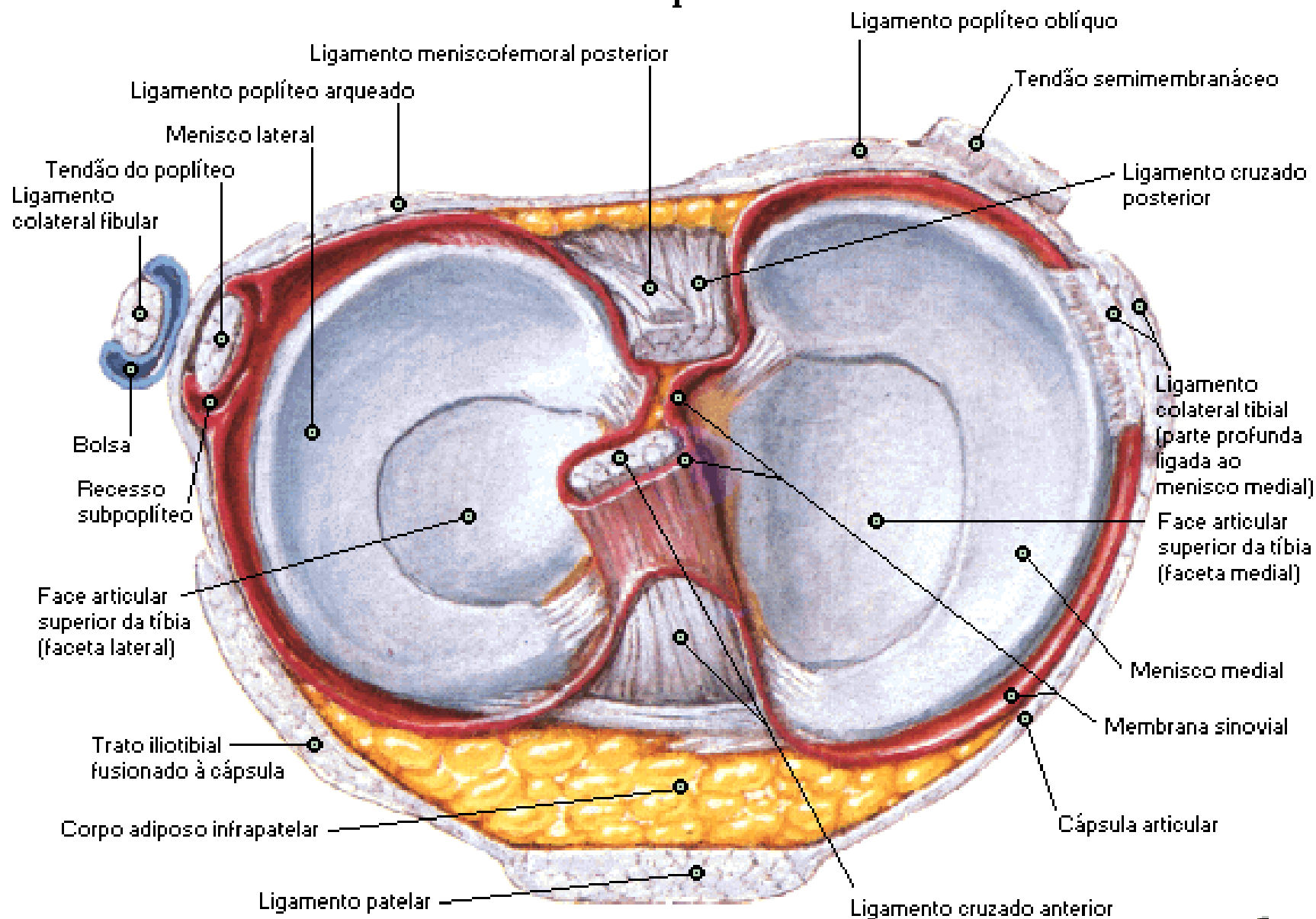
Joelho - Vista Interna

Vista Inferior



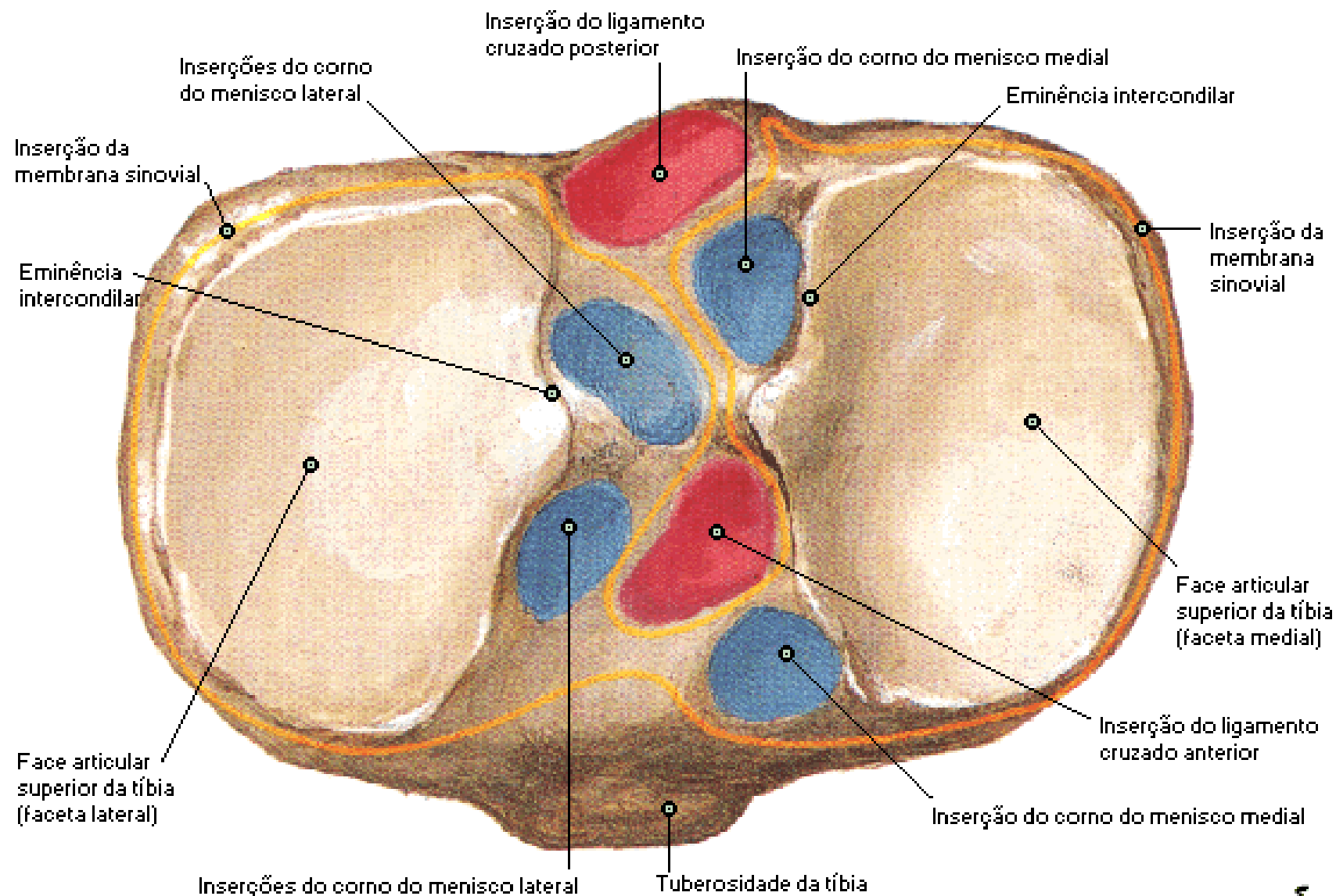
Joelho - Vista Interna

Vista Superior



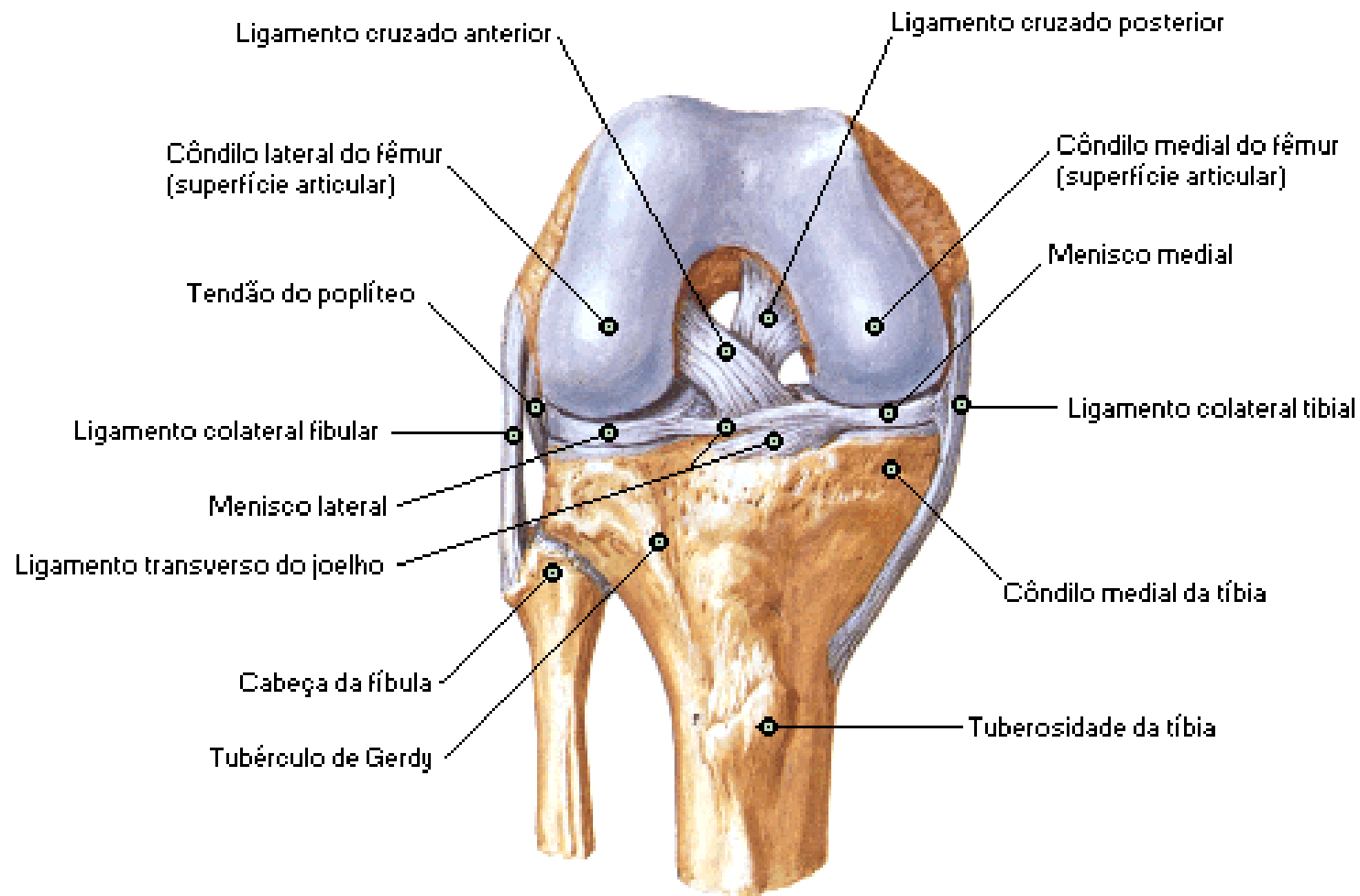
Joelho - Vista Interna

Vista Superior - Ligamentos e Cartilagem Removidos



Joelho - Ligamentos Cruzados e Colaterais

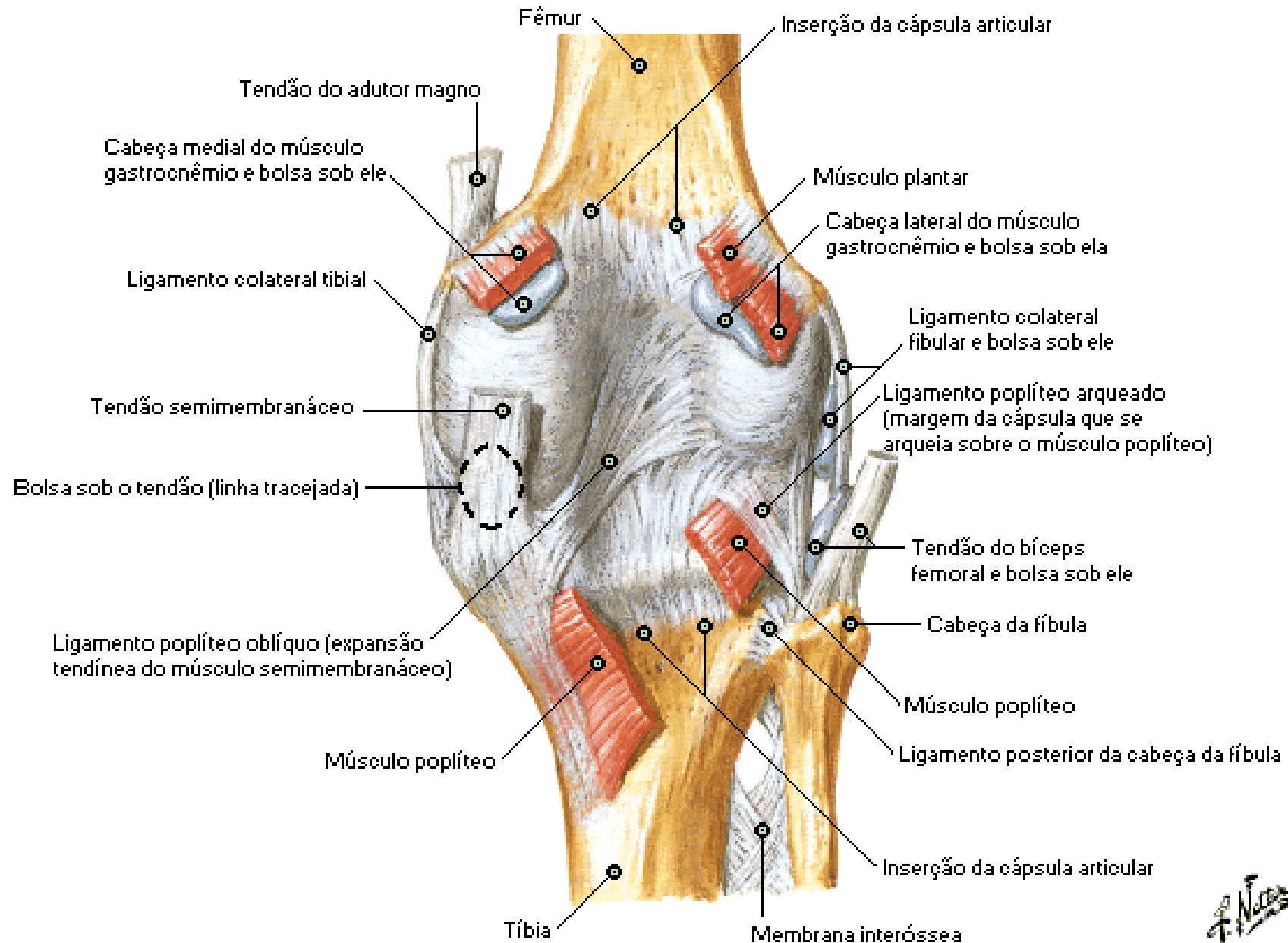
Joelho Direito em Flexão



Vista anterior

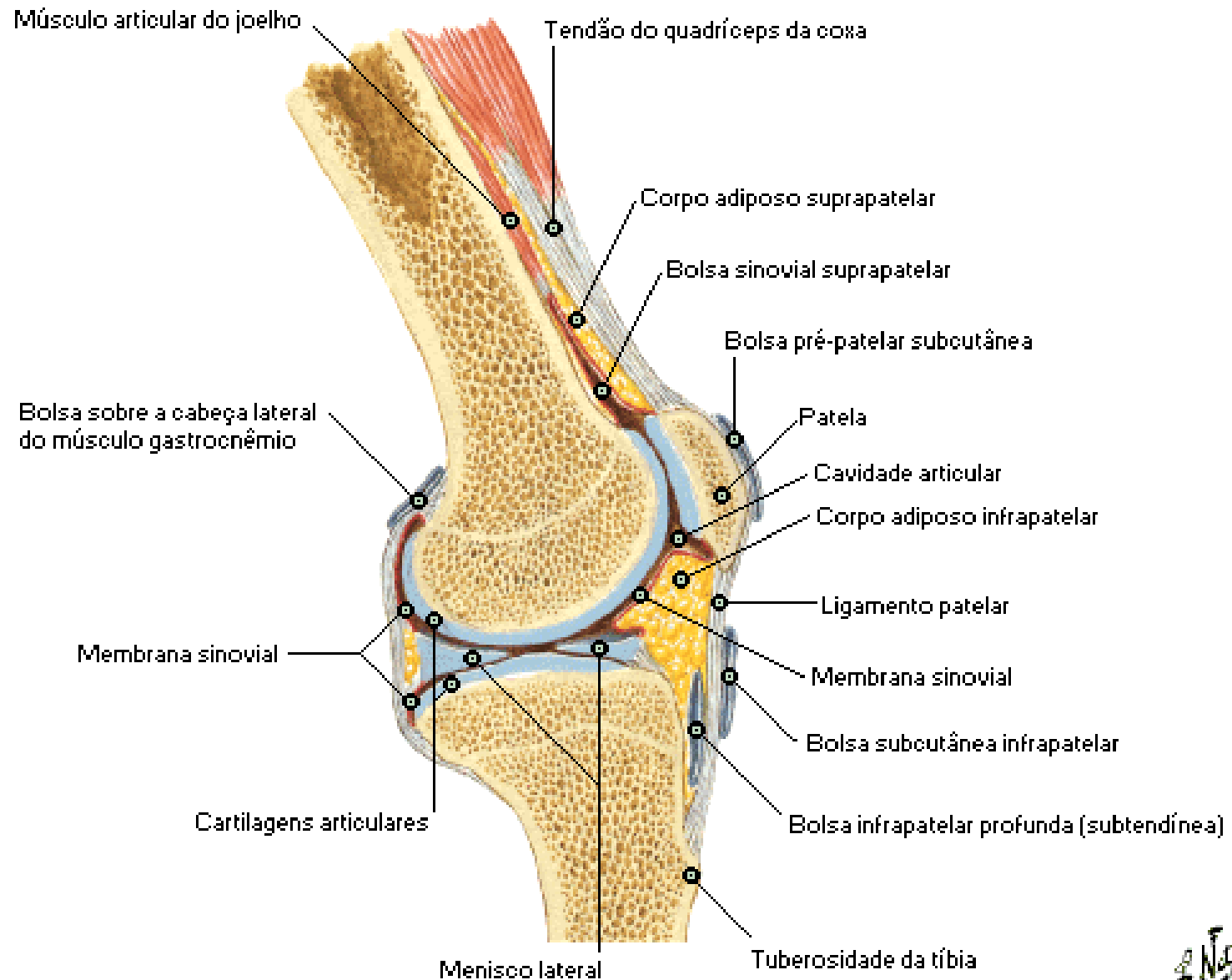
Joelho

Vista Posterior



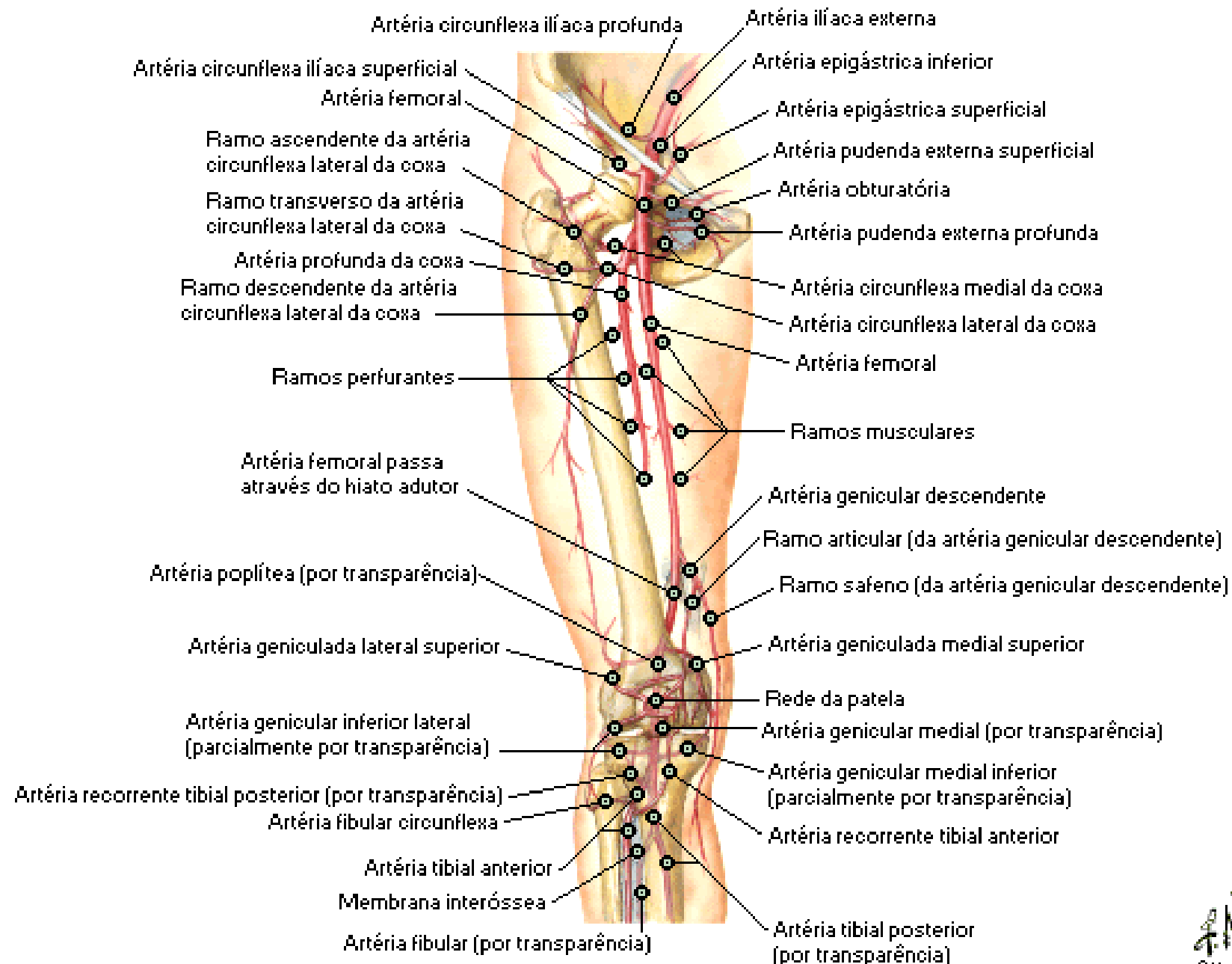
Joelho

Secção Parassagital



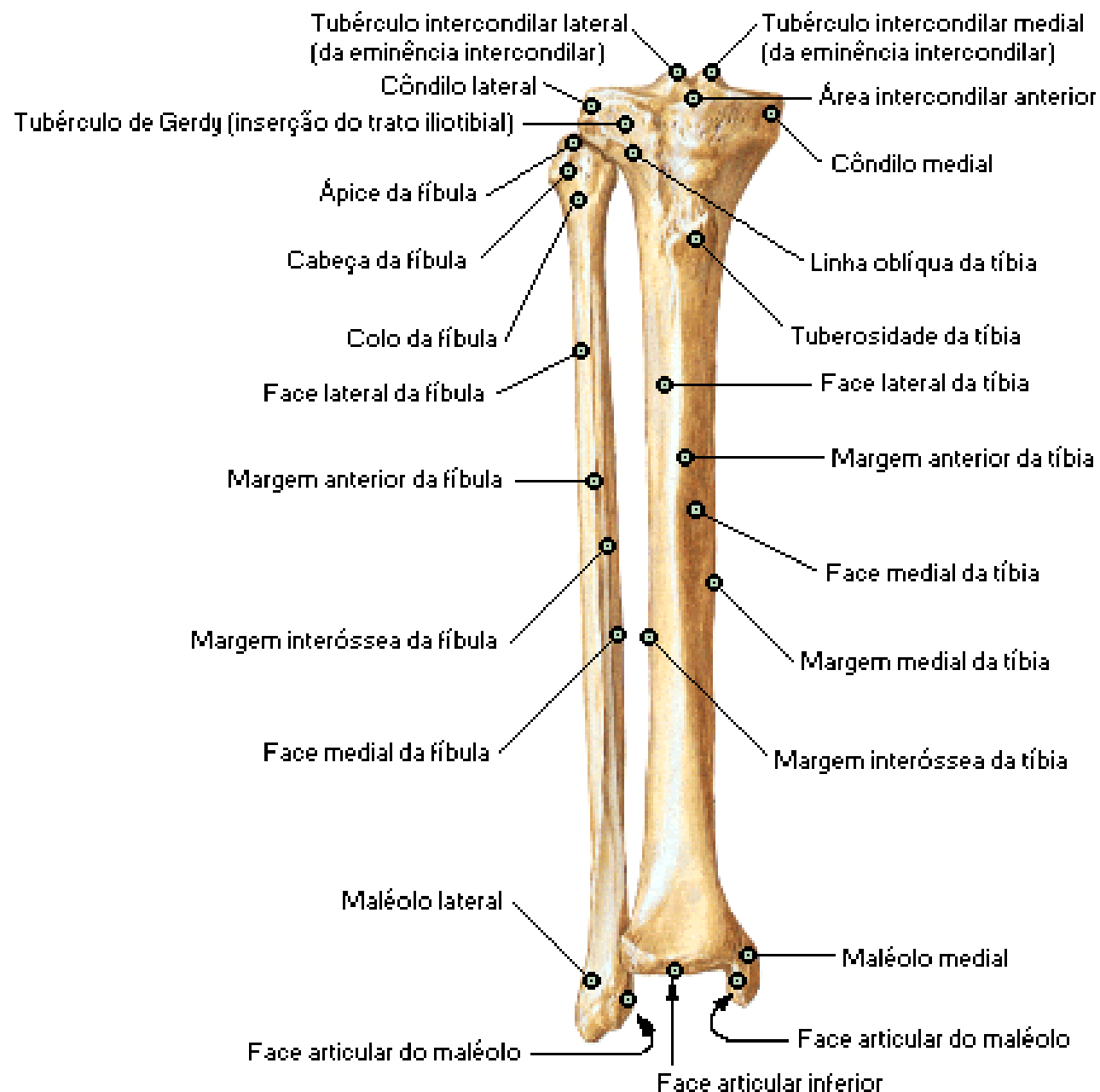
Artérias da Coxa e do Joelho

Esquema



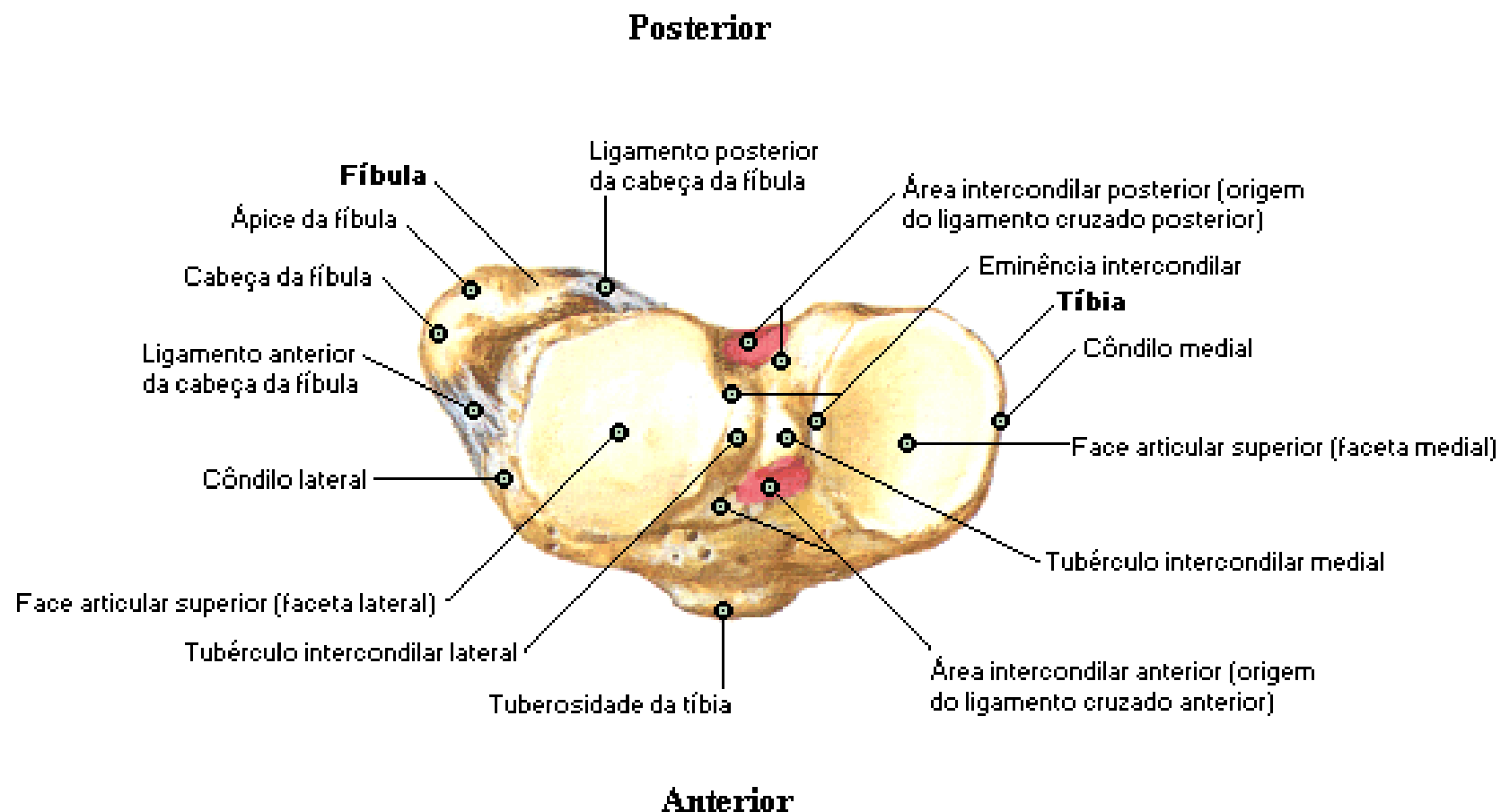
Tíbia e Fíbula da Perna Direita

Vista Anterior



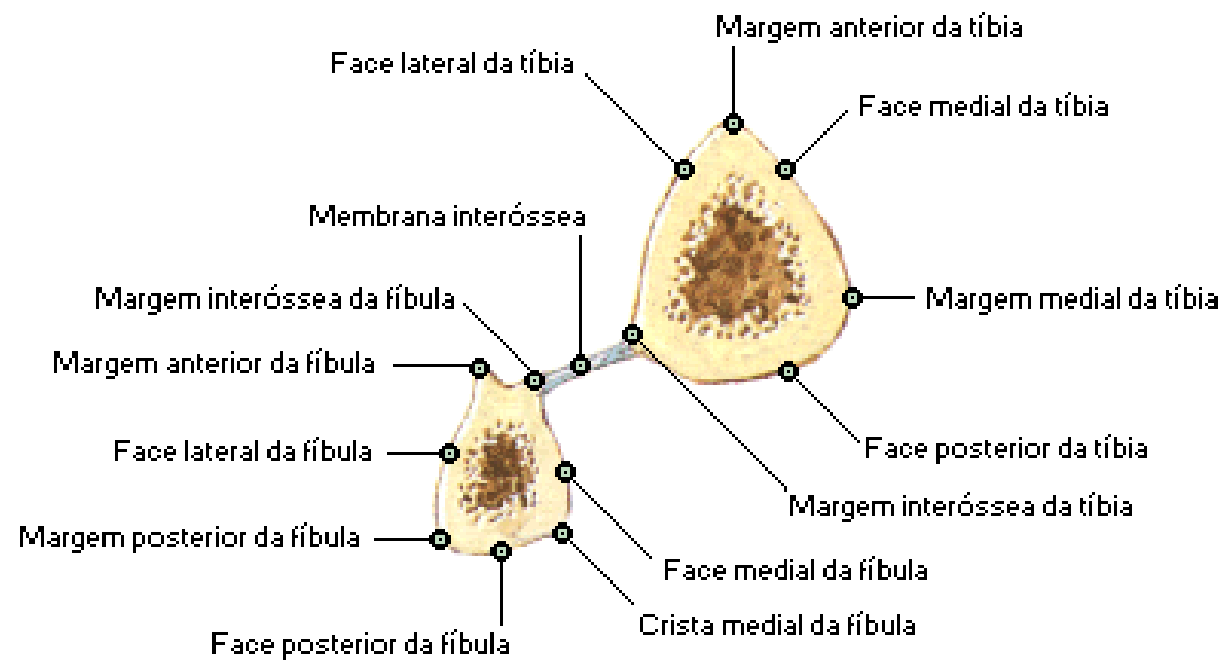
Tíbia e Fíbula da Perna Direita

Vista Superior



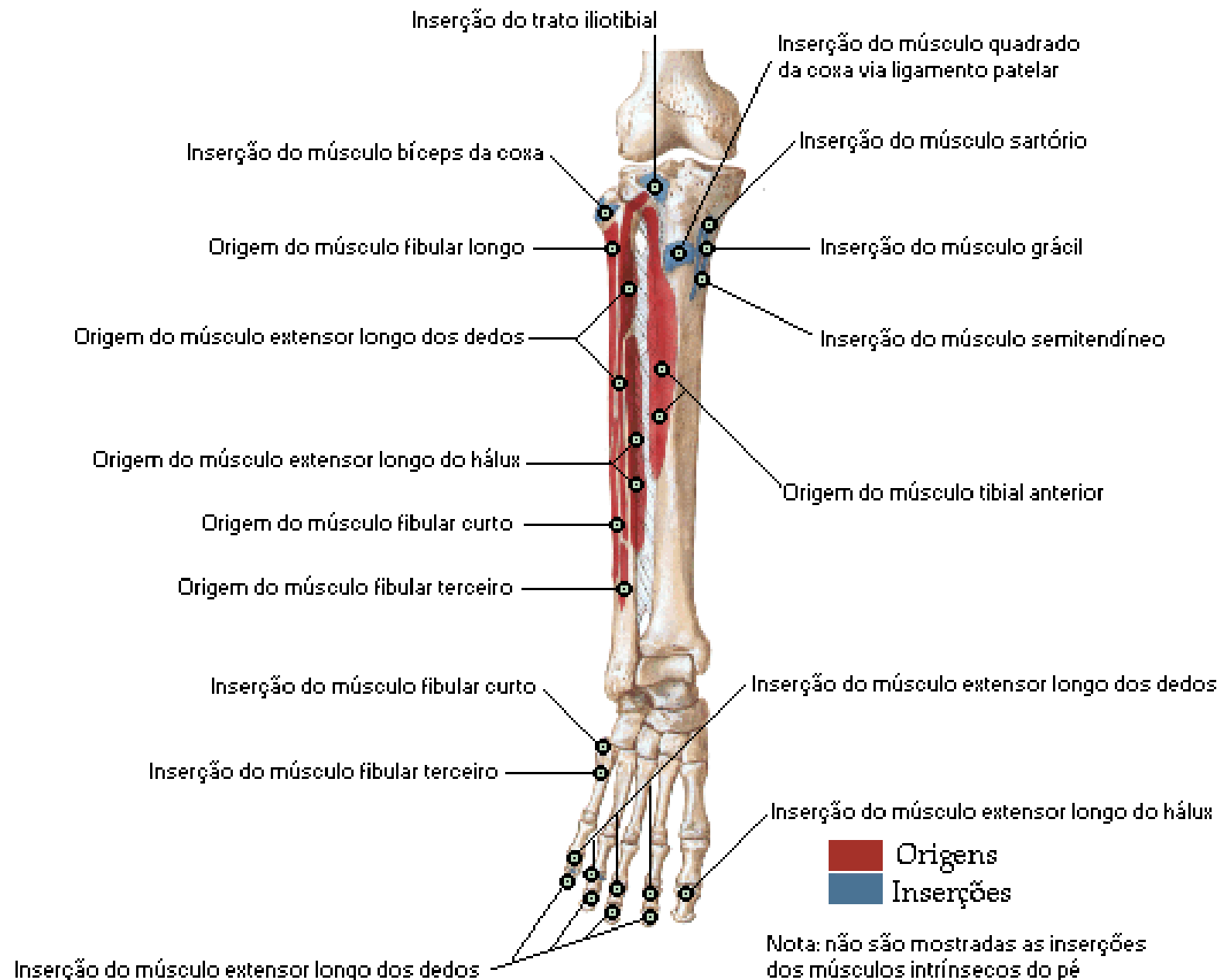
Tíbia e Fíbula da Perna Direita

Secção Transversal



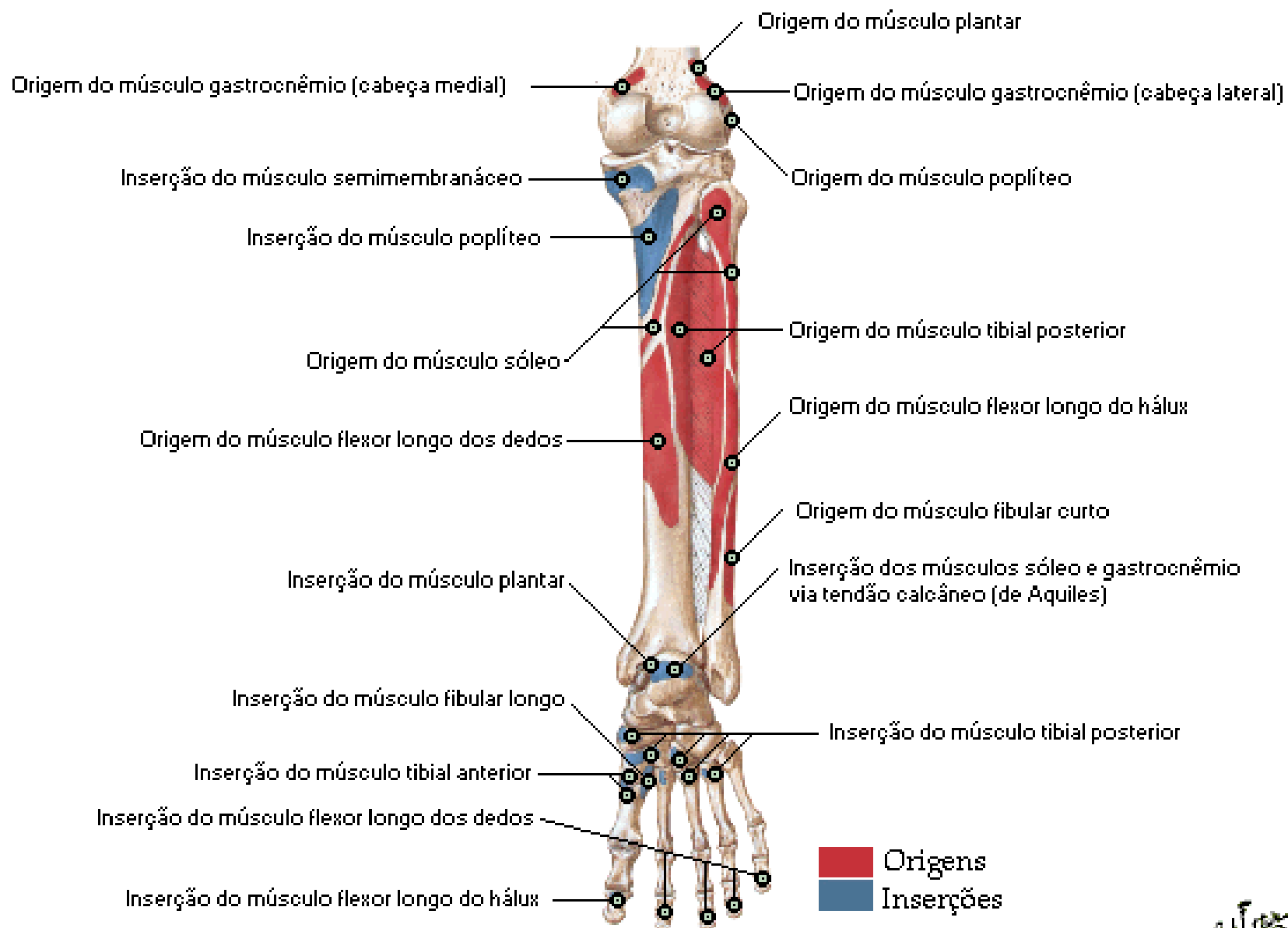
Inserções Ósseas dos Músculos da Perna

Vista Anterior



Inserções Ósseas dos Músculos da Perna

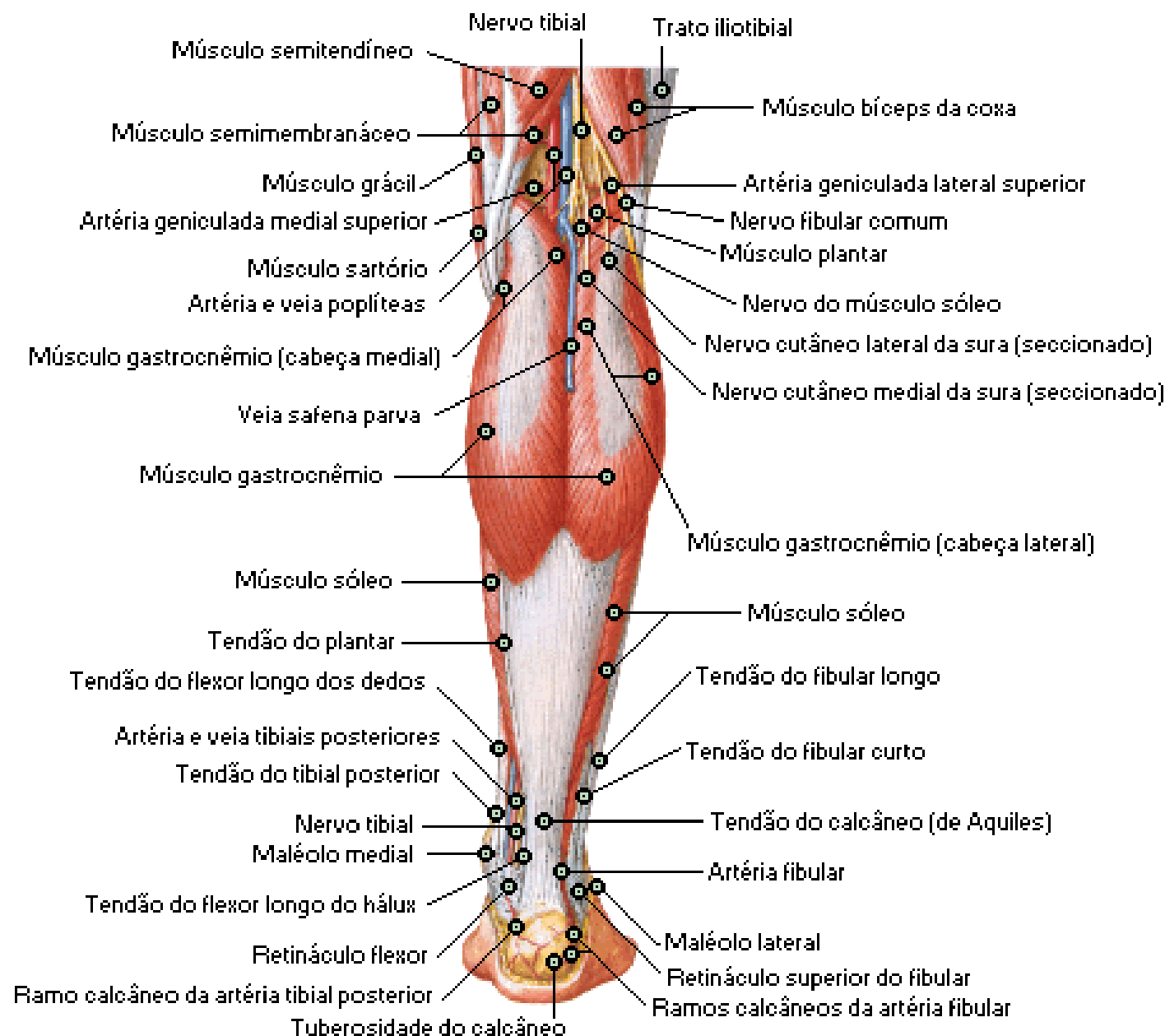
Vista Posterior



Nota: não são mostradas as inserções dos músculos intrínsecos do pé

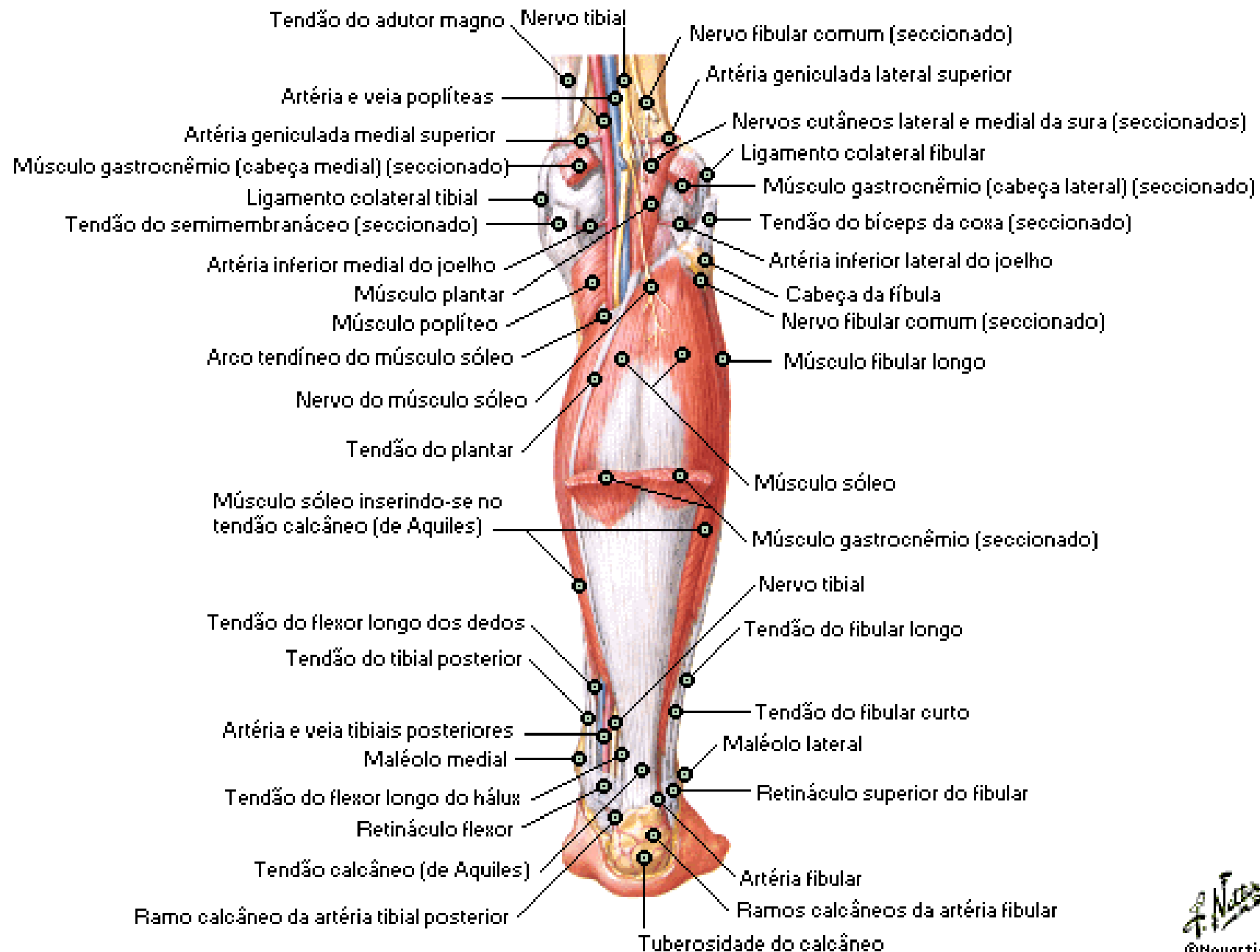
Músculos da Perna [Dissecação Superficial]

Vista Posterior



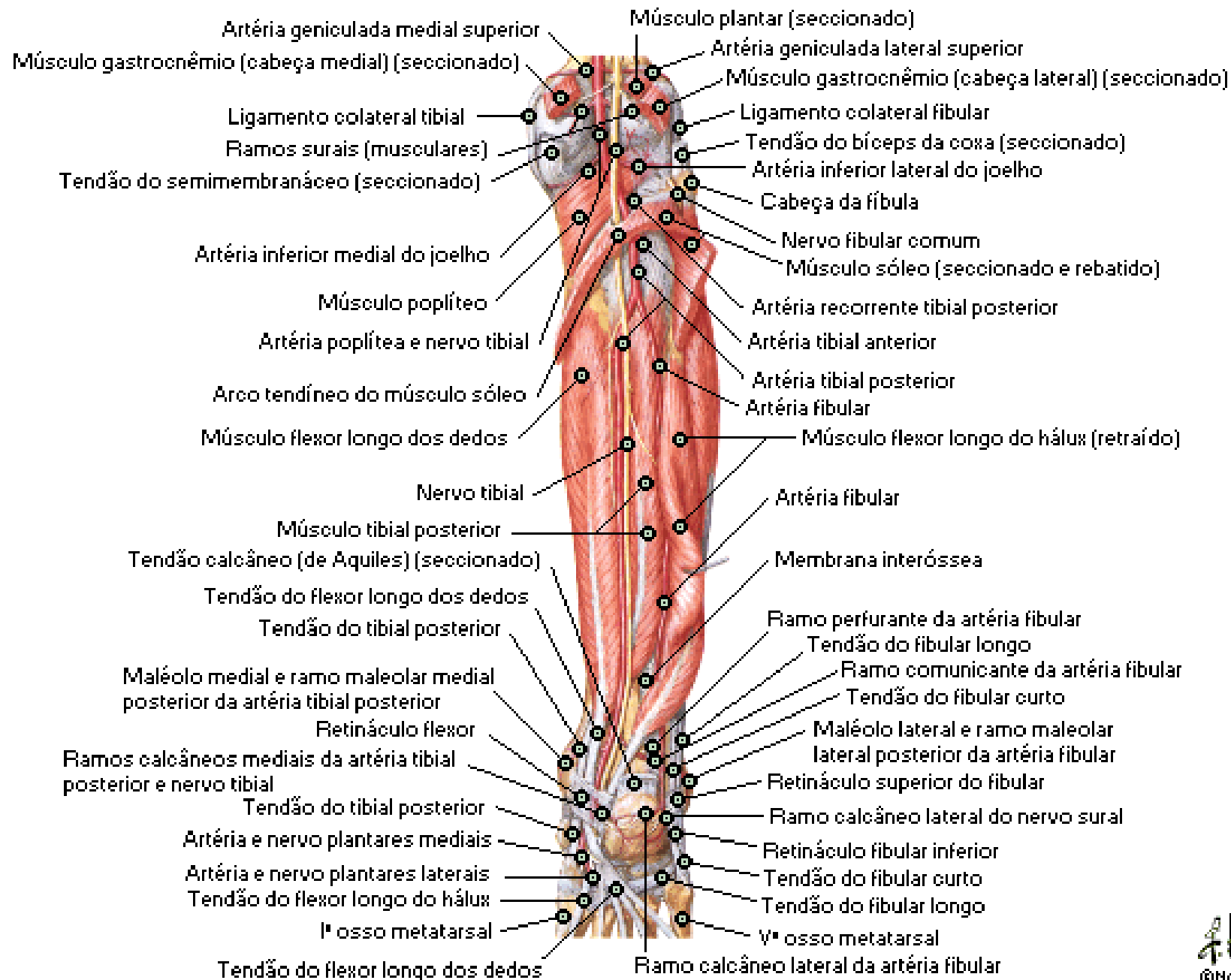
Músculos da Perna [Dissecação Intermediária]

Vista Posterior



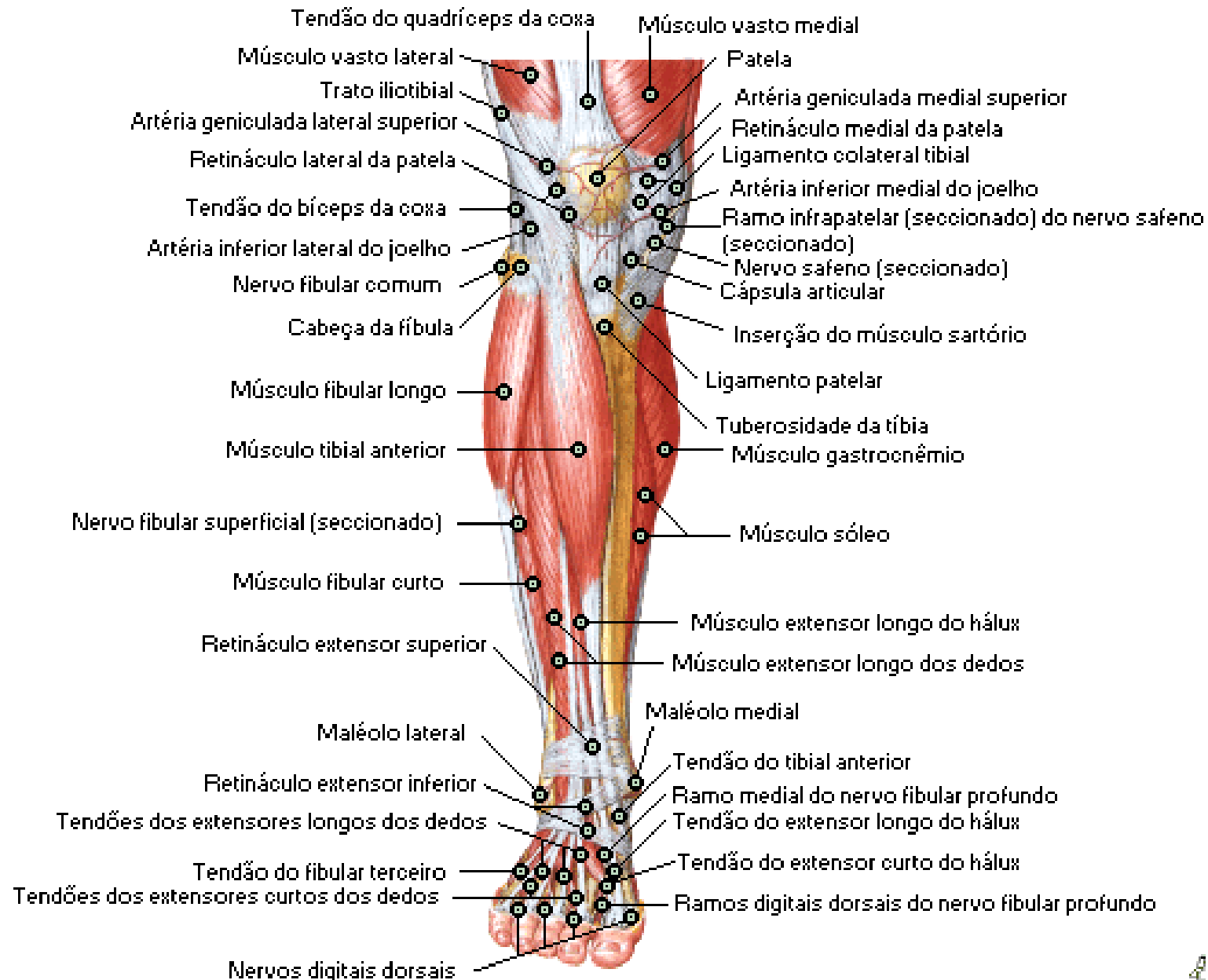
Músculos da Perna [Dissecação Profunda]

Vista Posterior



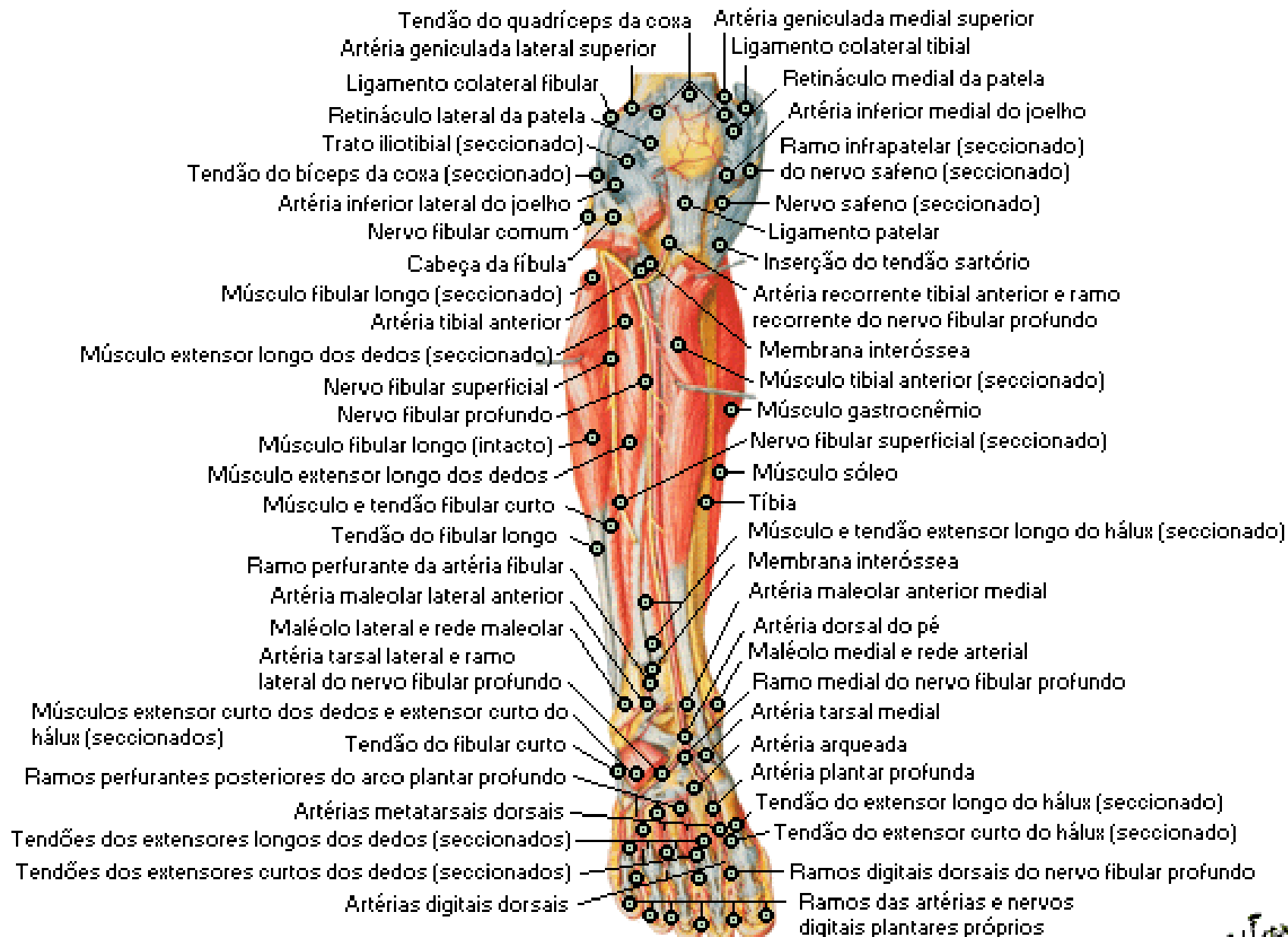Músculos da Perna [Dissecação Superficial]

Vista Anterior



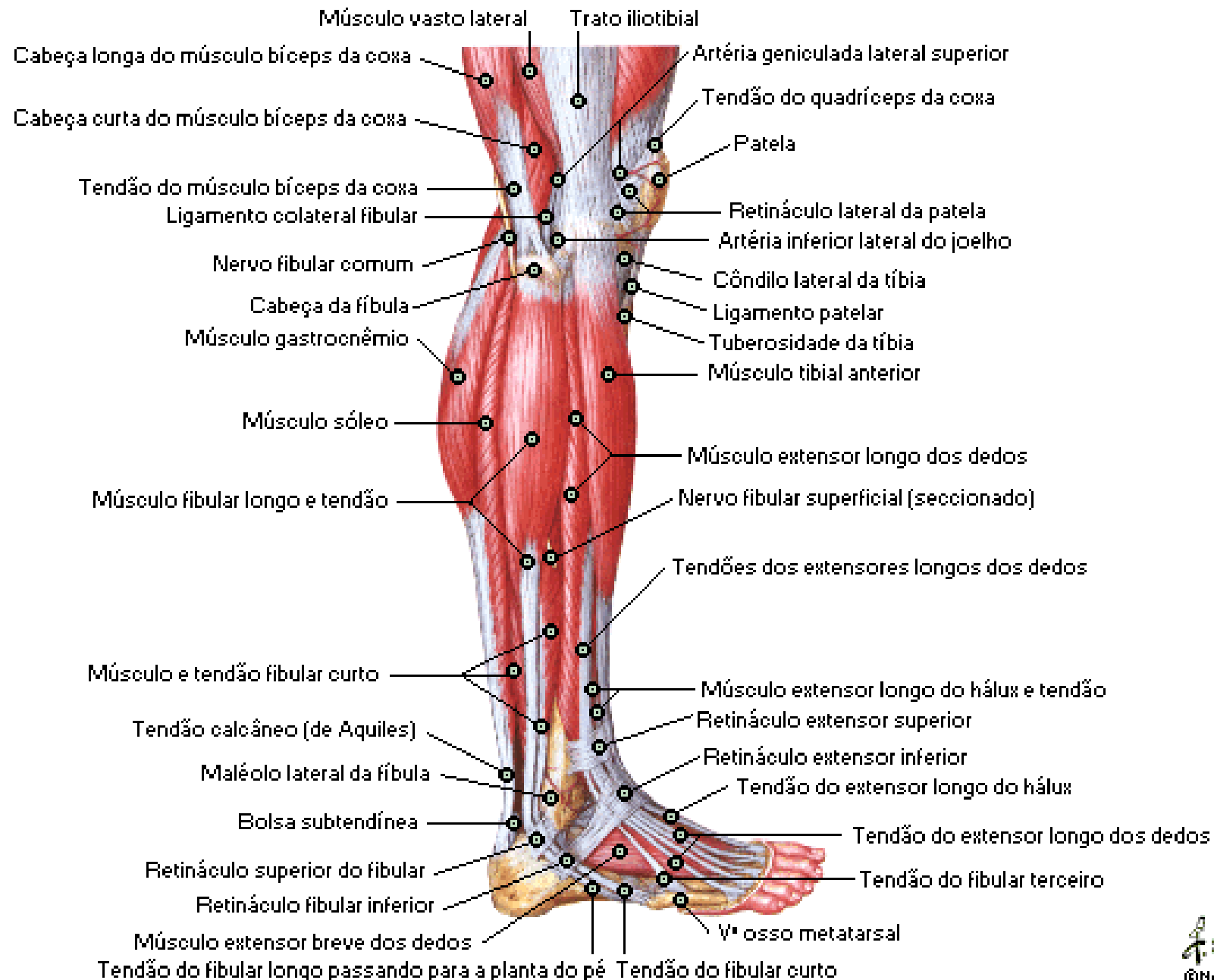Músculos da Perna [Dissecação Profunda]

Vista Anterior



Músculos da Perna

Vista Lateral



Perna

Secções Transversais e Compartimentos Fasciais

Compartimento anterior

Músculos extensores
Tíbia anterior
Extensor longo dos dedos
Extensor longo do hálux
Fibular terceiro
Artéria tibial anterior e veias
Nervo fibular profundo

Fáscia crural

Membrana interóssea

Tíbia

Compartimento posterior profundo

Músculos flexores profundos
Flexor longo dos dedos
Tibial posterior
Flexor longo do hálux
Poplíteo
Artéria tibial posterior e veias
Nervo tibial
Artéria fibular e veias

Septo intermuscular anterior

Compartimento lateral

Músculo fibular longo
Músculo fibular curto
Nervo fibular superficial

Septo intermuscular posterior

Fíbula

Fáscia crural

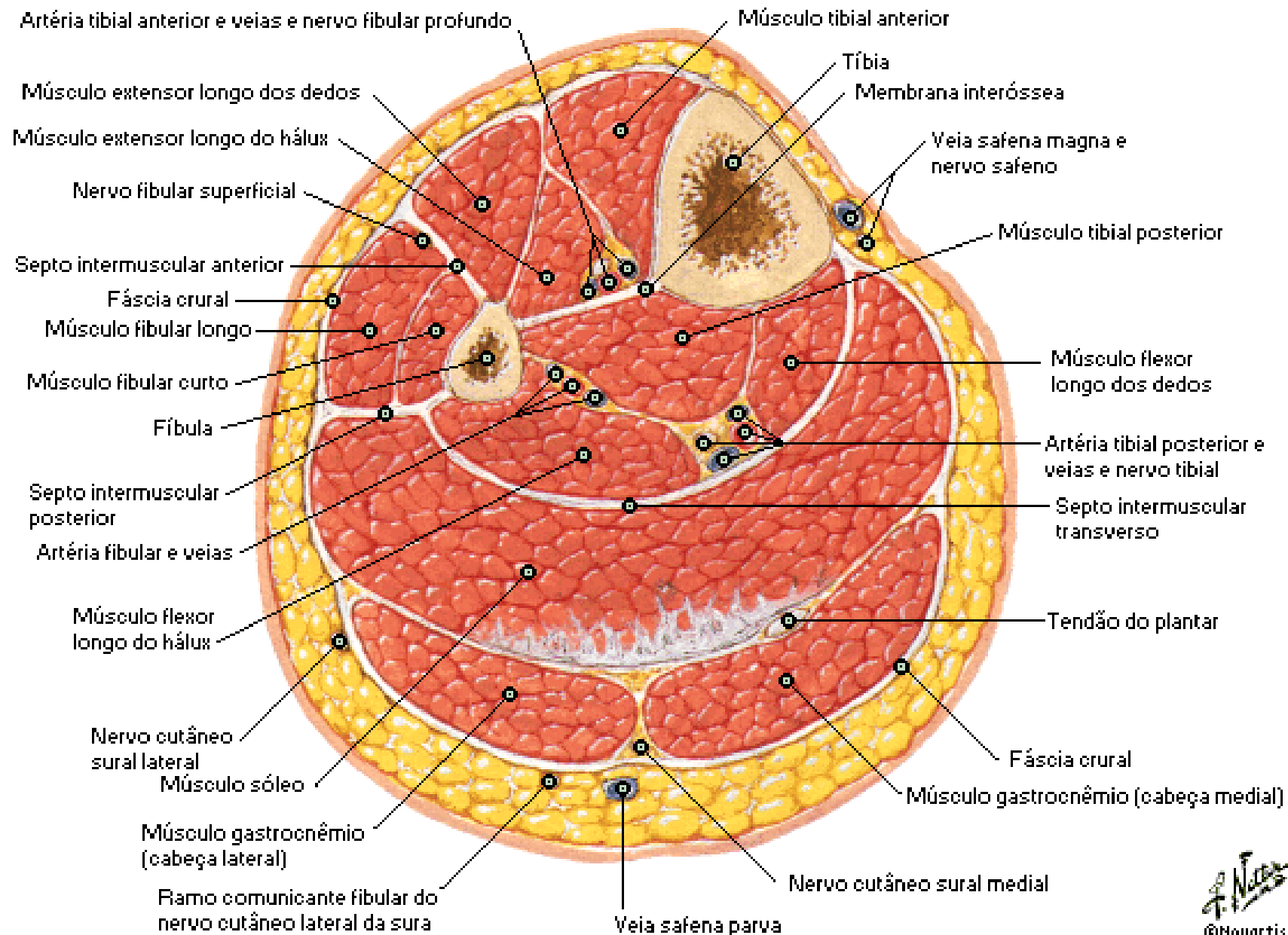
Septo intermuscular transverso

Compartimento posterior superficial

Músculos flexores superficiais
Sóleo
Gastrocnêmio
Plantar (tendão)

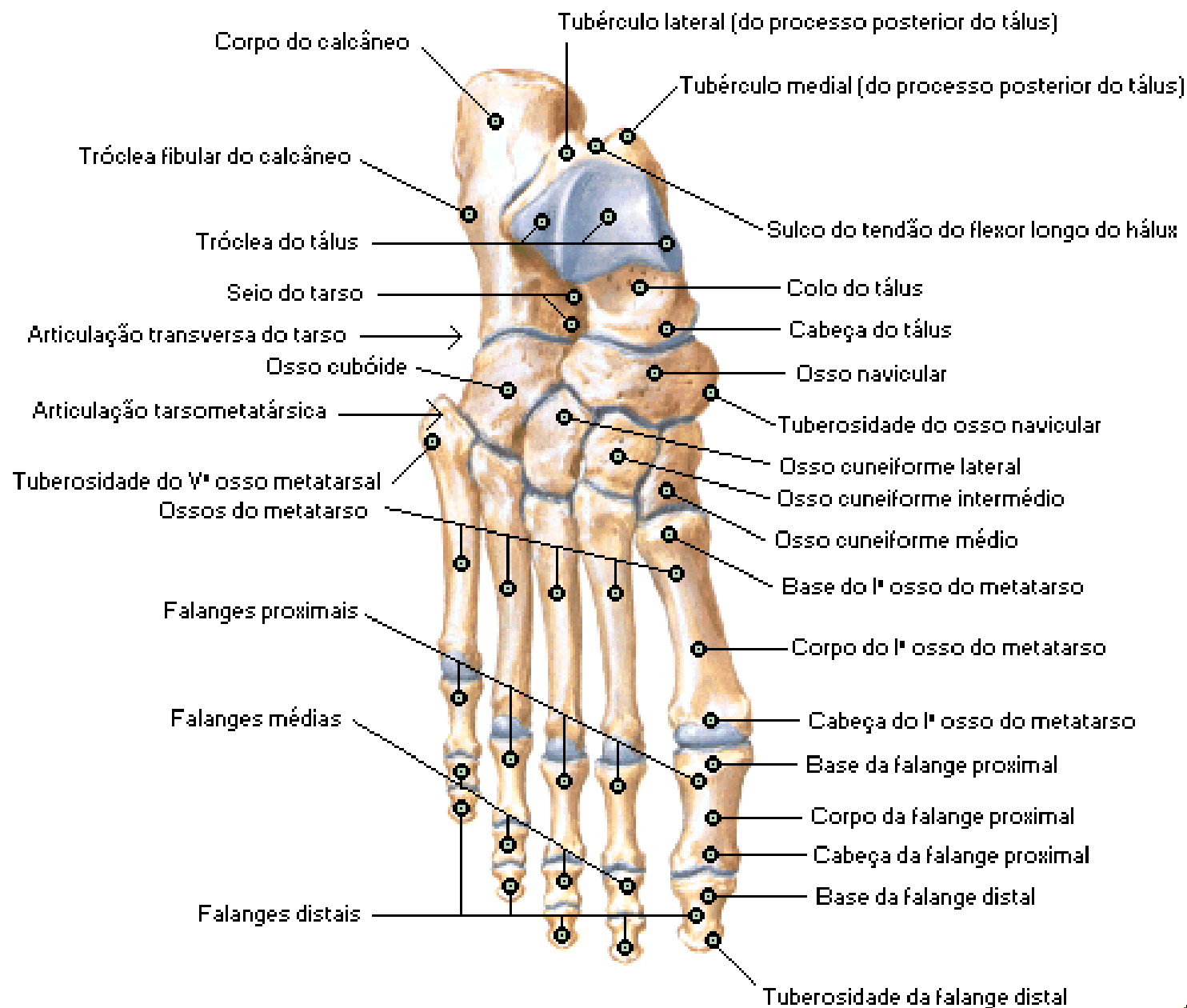
Perna

Secção Transversal Acima da Metade da Perna Esquerda



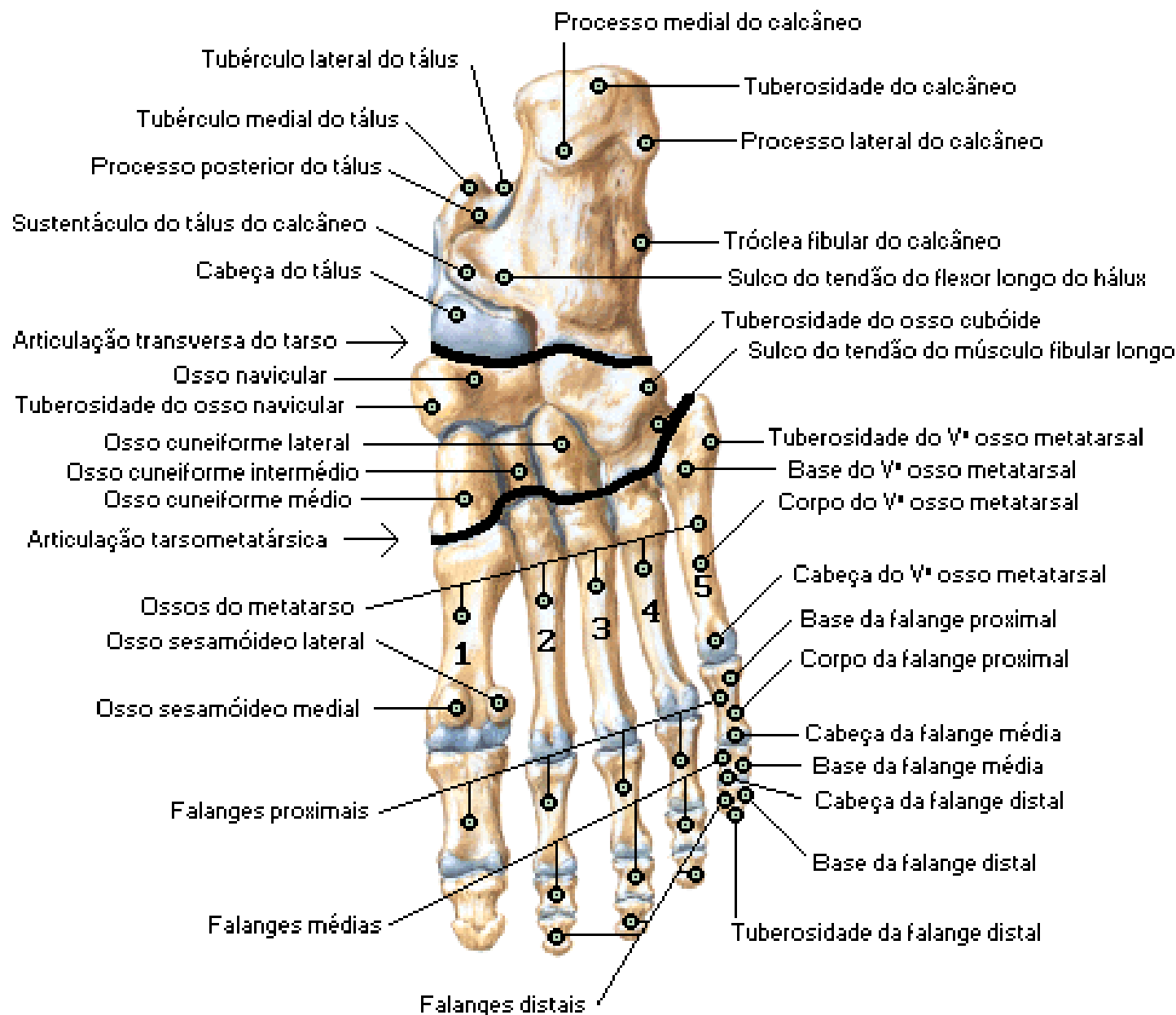
Ossos do Pé

Vista Dorsal



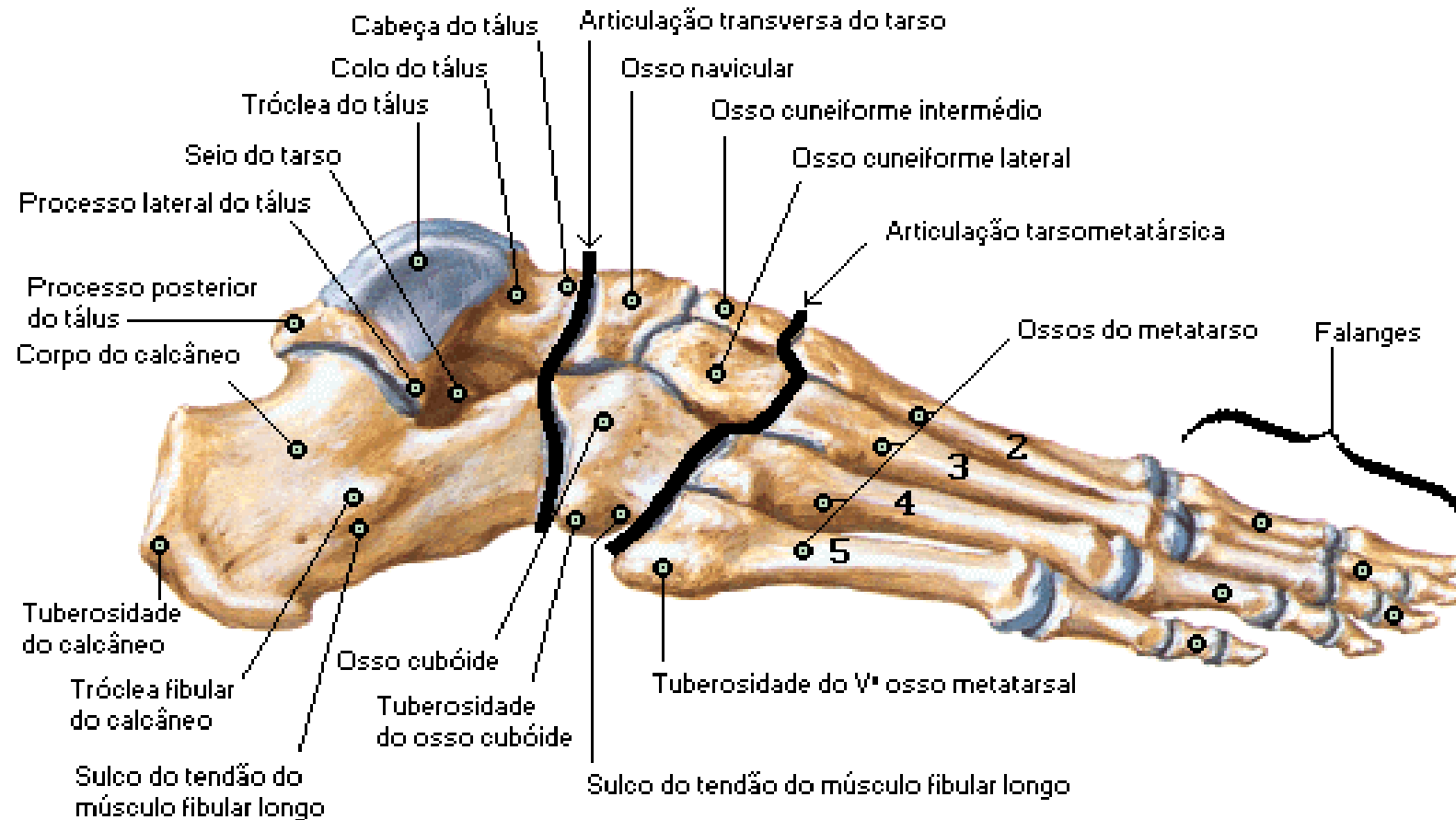
Ossos do Pé

Vista Plantar



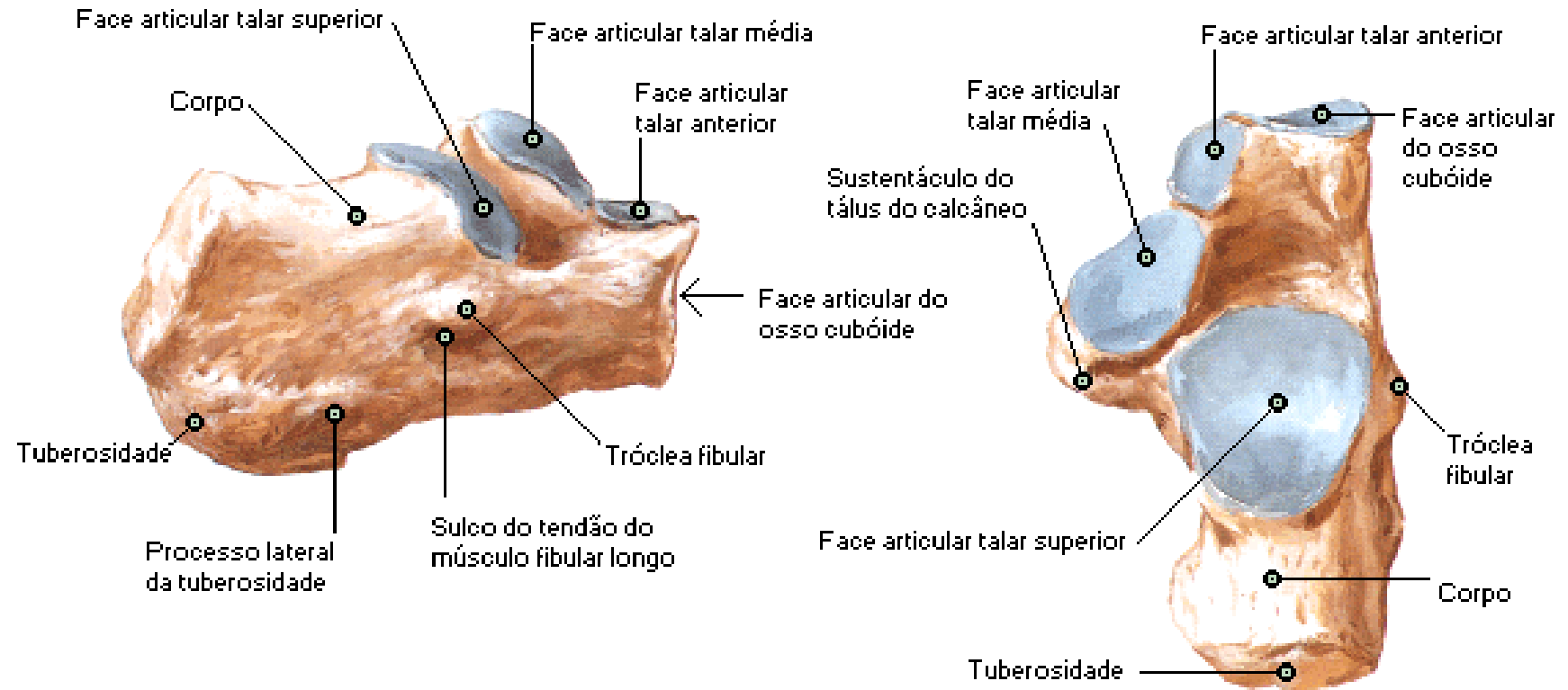
Ossos do Pé

Vista Lateral



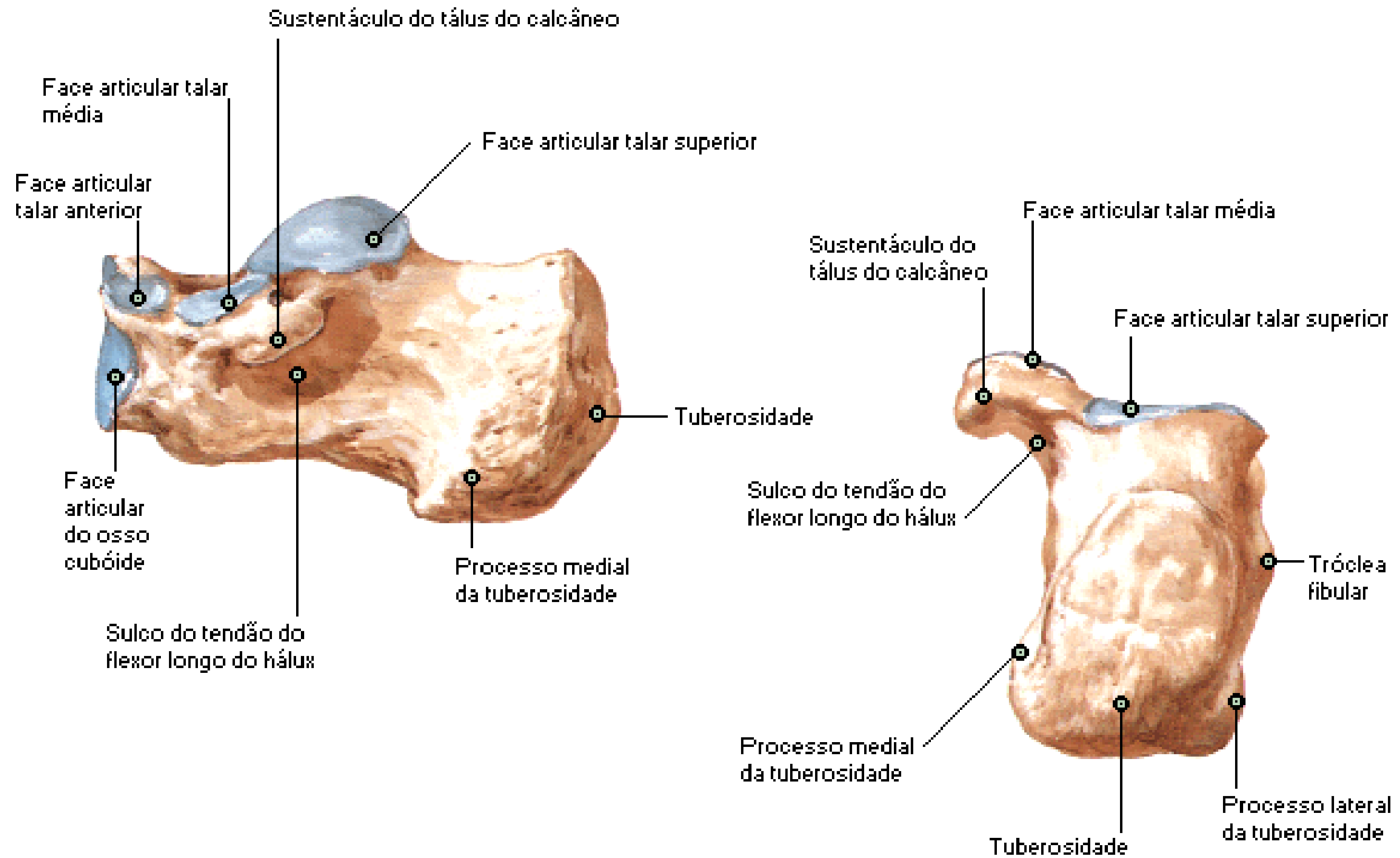
Calcâneo do Pé Direito

Vistas Lateral e Superior



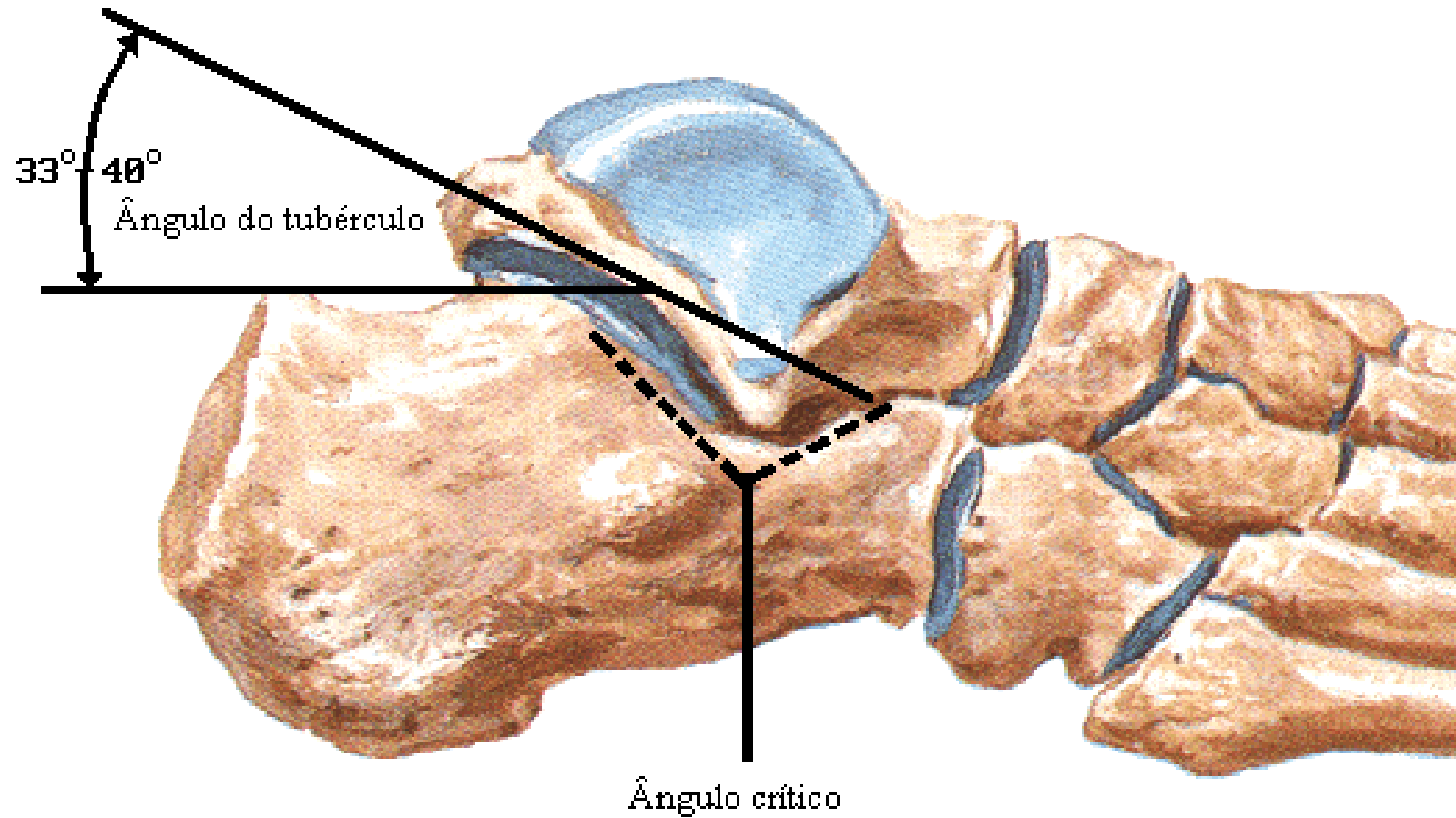
Calcâneo do Pé Direito

Vistas Medial e Posterior



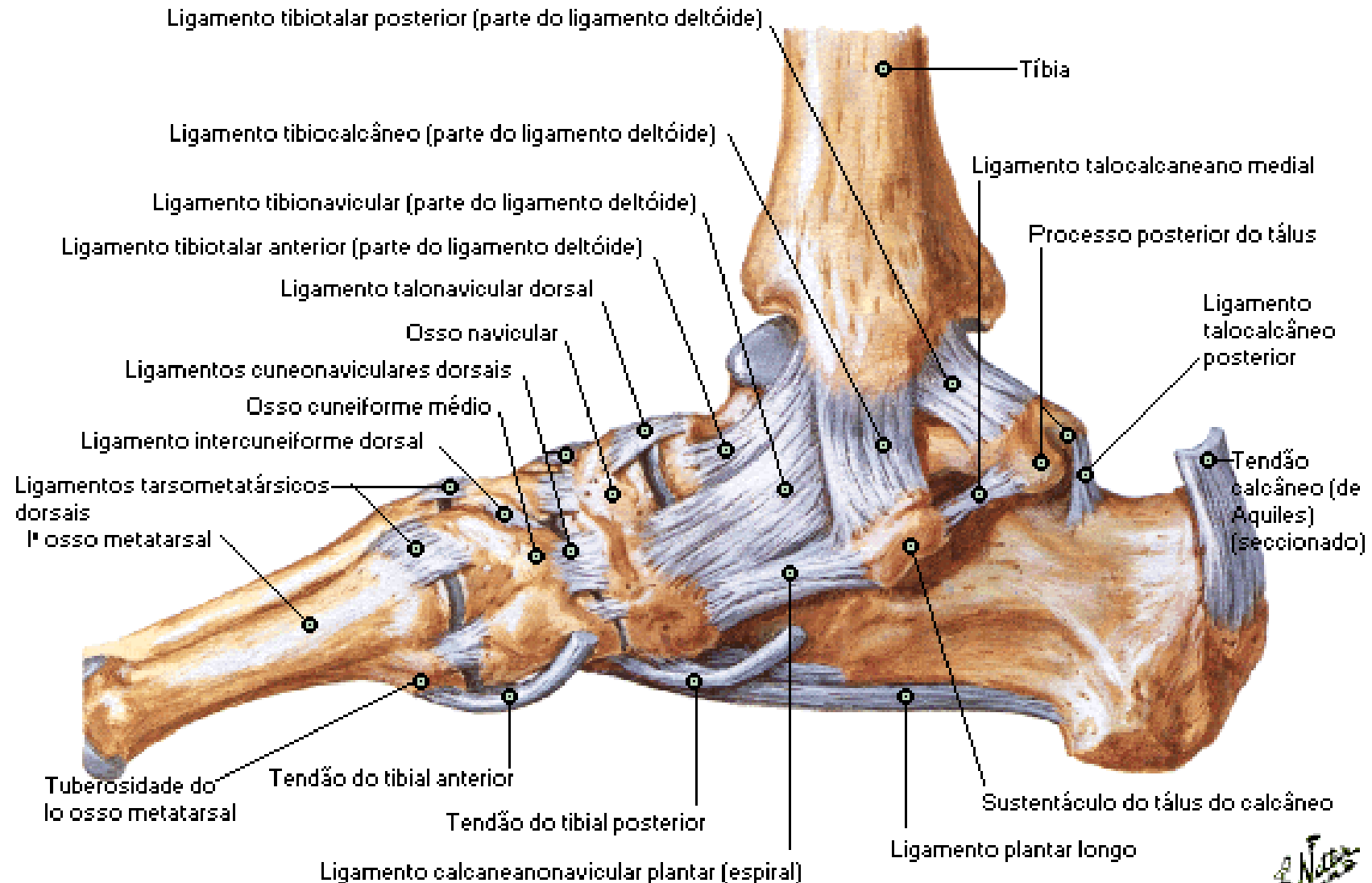
Calcâneo do Pé Direito

Relações Funcionais do Calcâneo



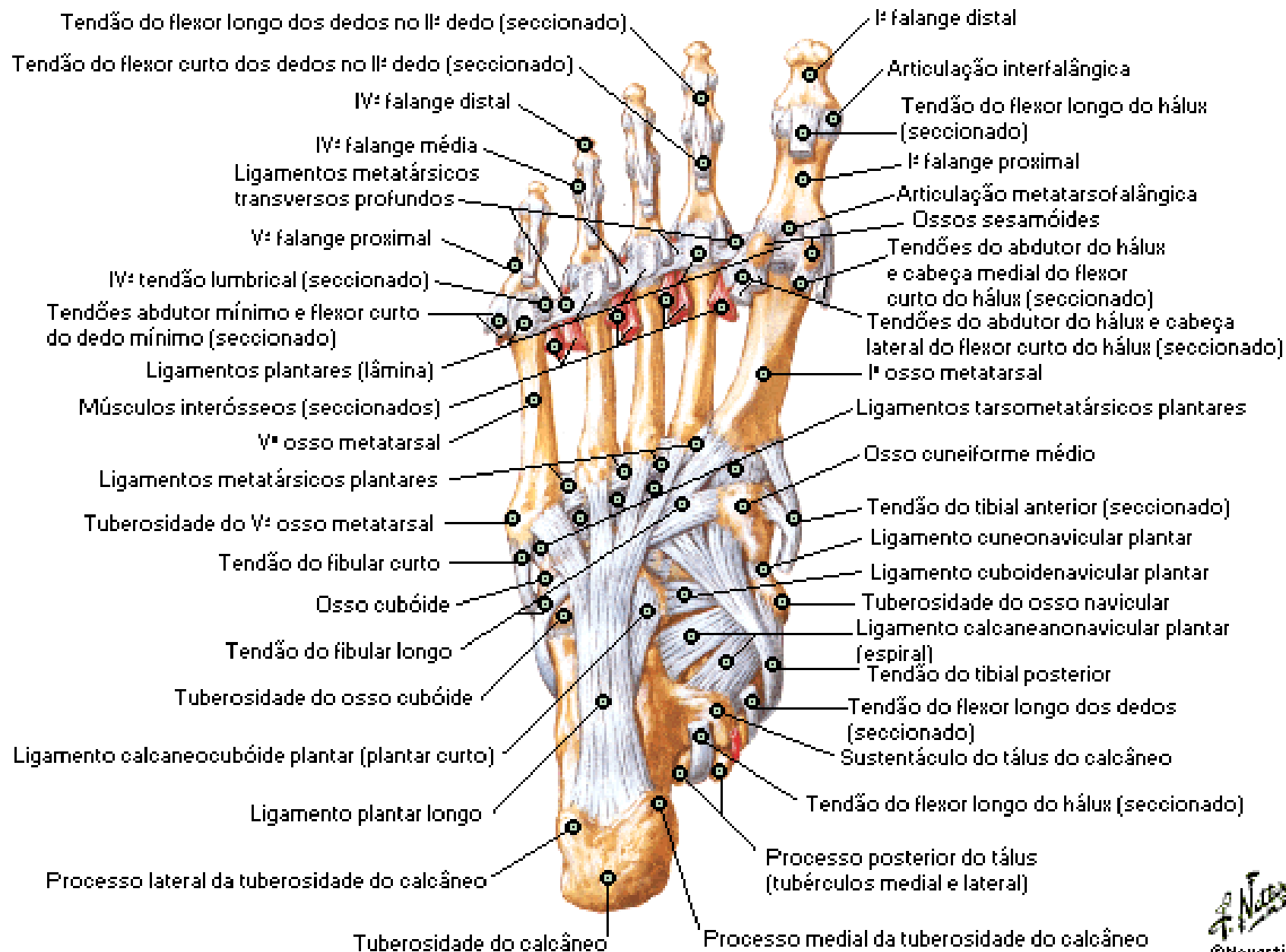
Ligamentos e Tendões do Tornozelo Direito

Vista Medial



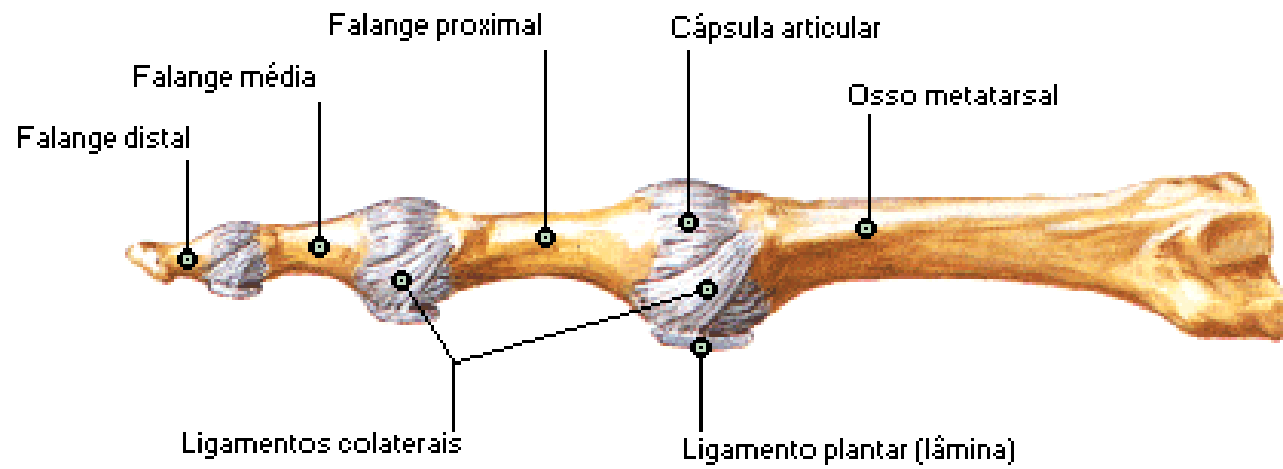
Ligamentos e Tendões do Pé

Vista Plantar



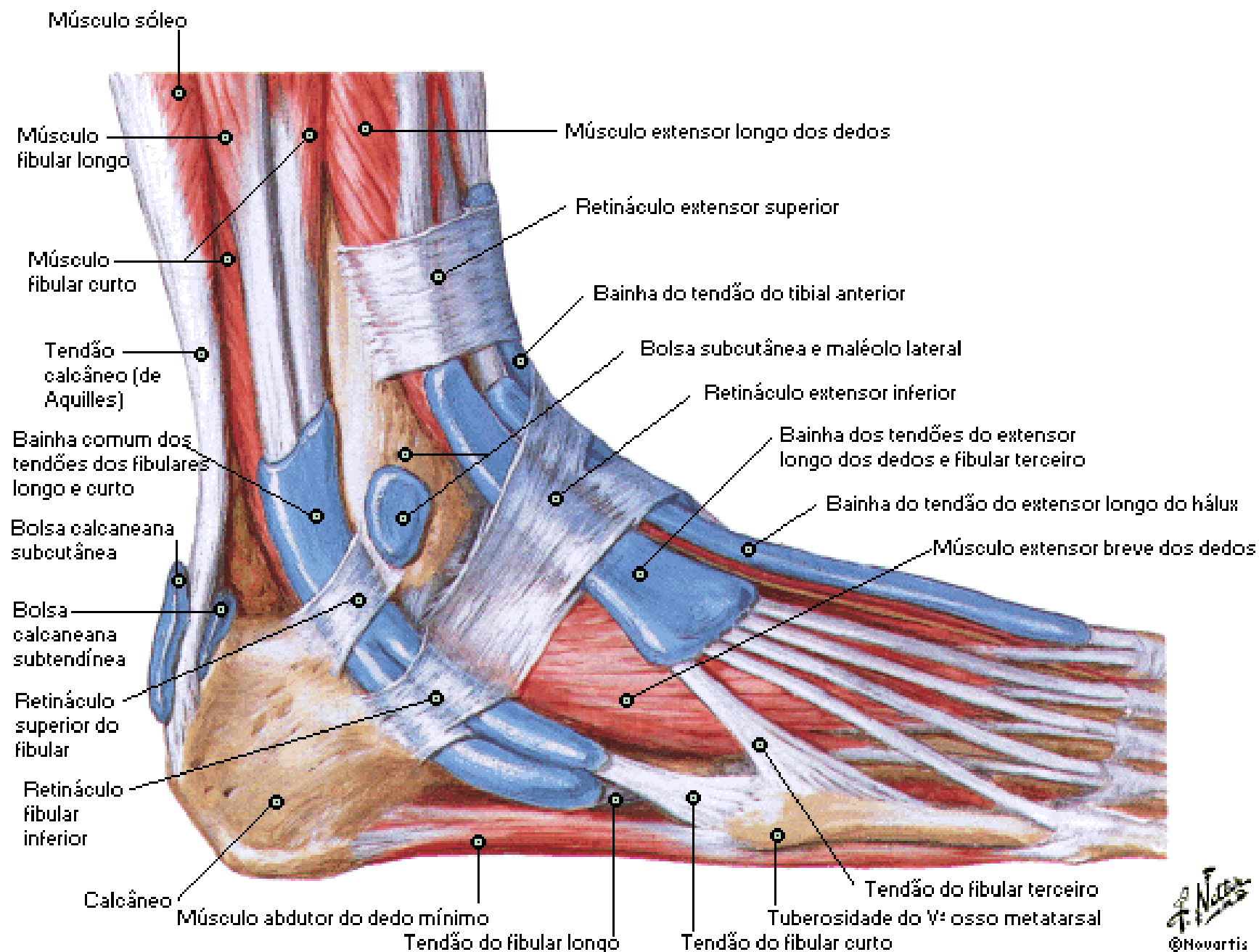
Articulações Metatarsofalângicas e Interfalângicas

Vista Lateral



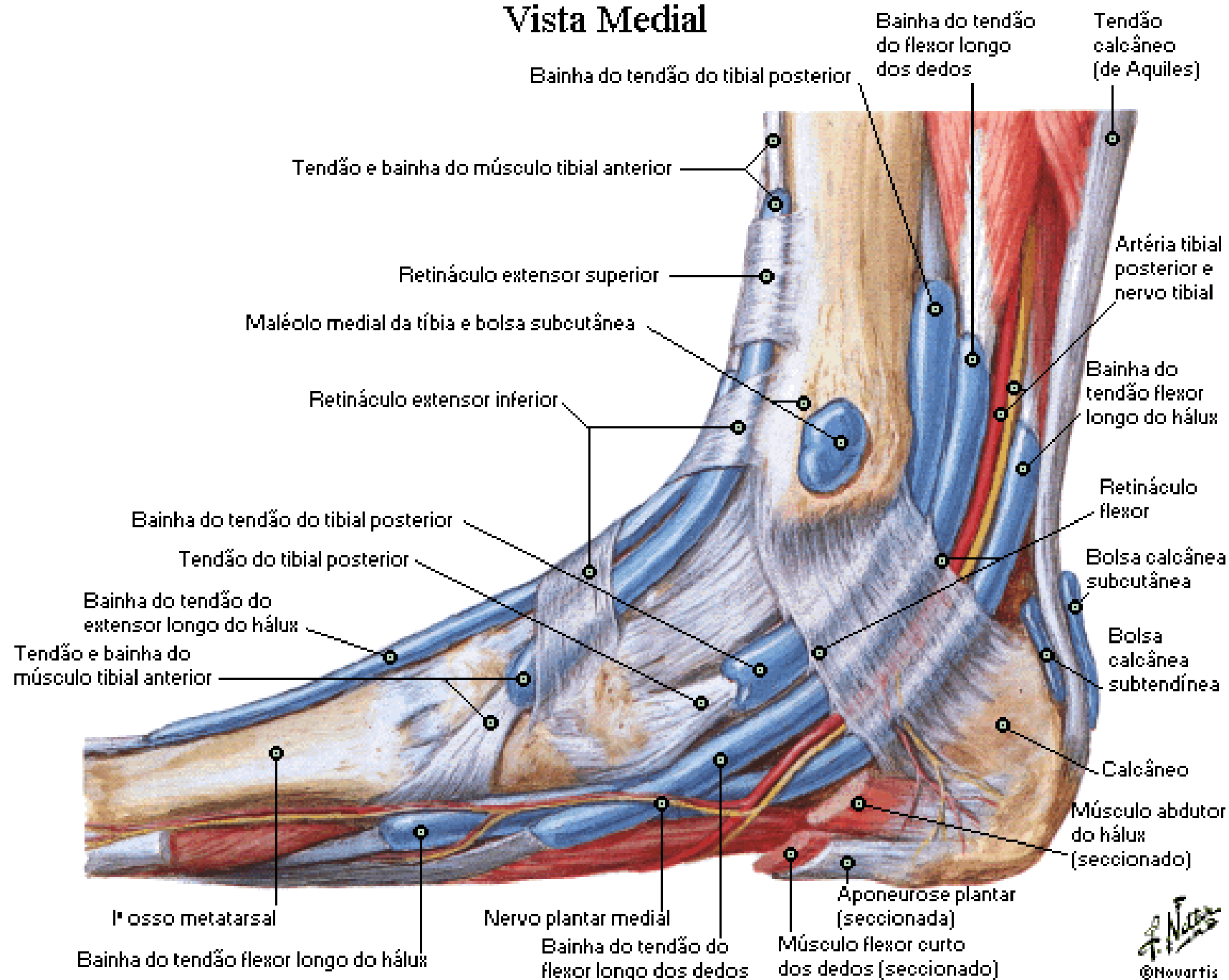
Bainhas Tendíneas do Tornozelo

Vista Lateral



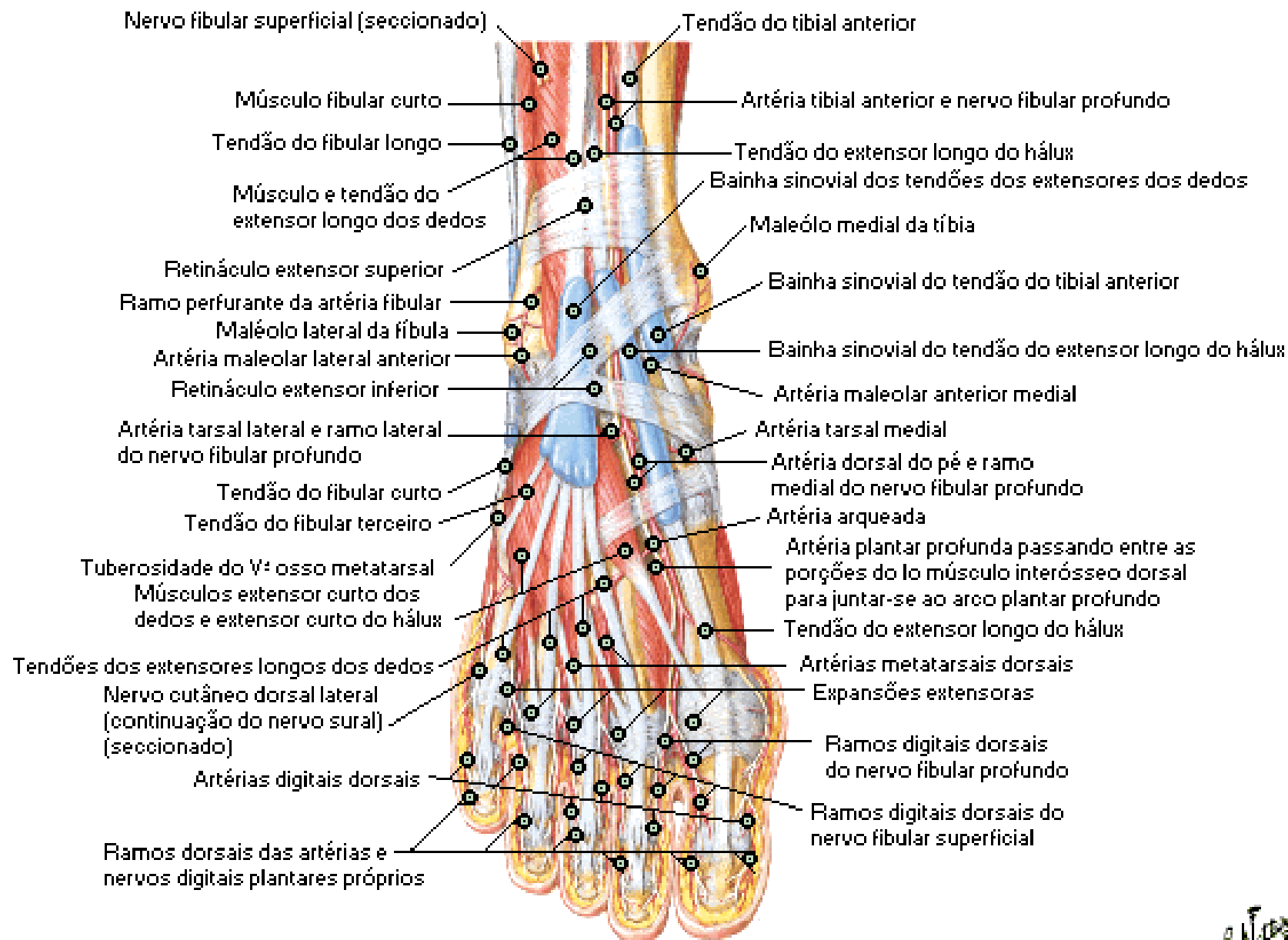
Bainhas Tendíneas do Tornozelo

Vista Medial



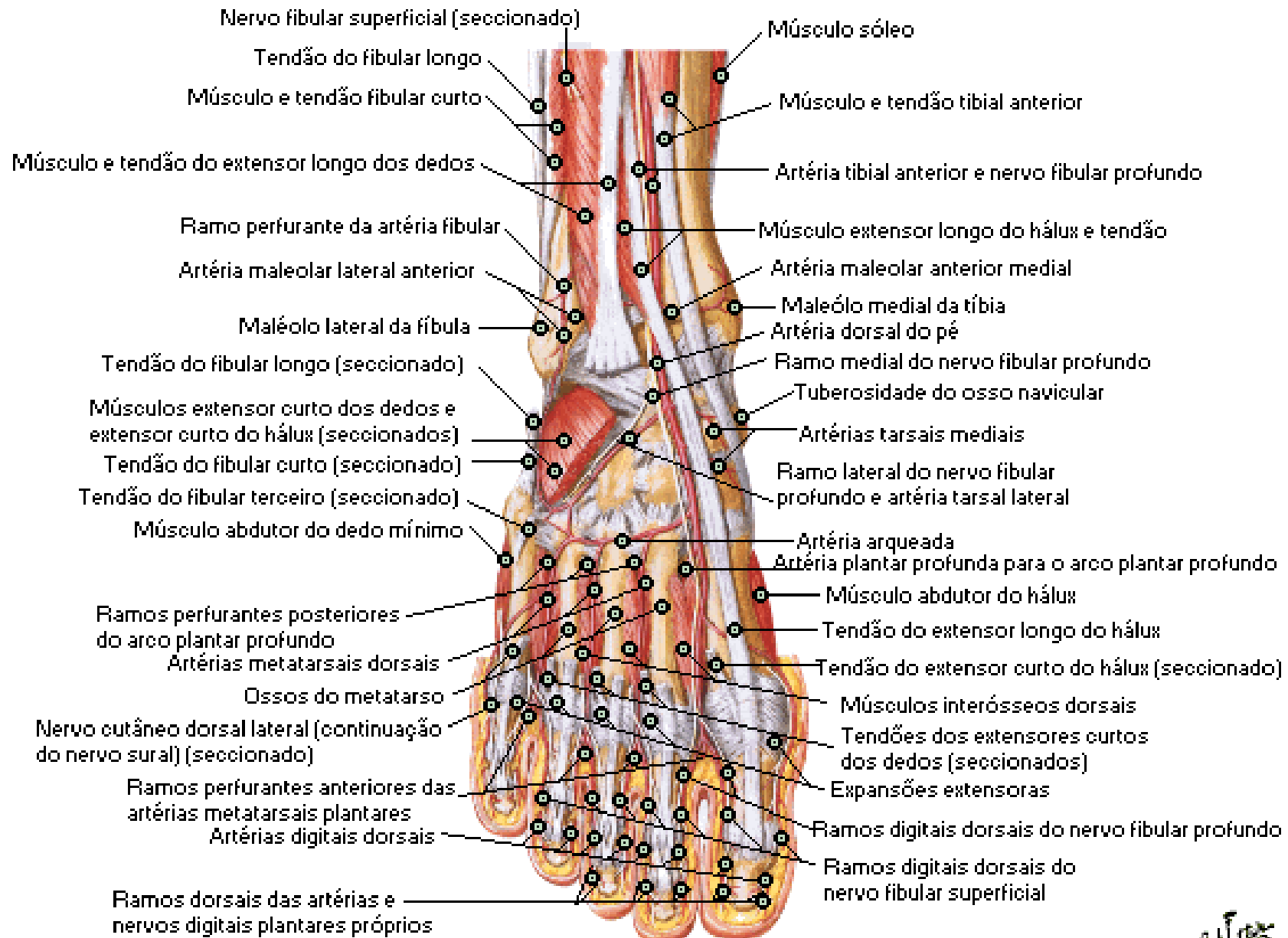
Músculos do Dorso do Pé

Dissecação Superficial



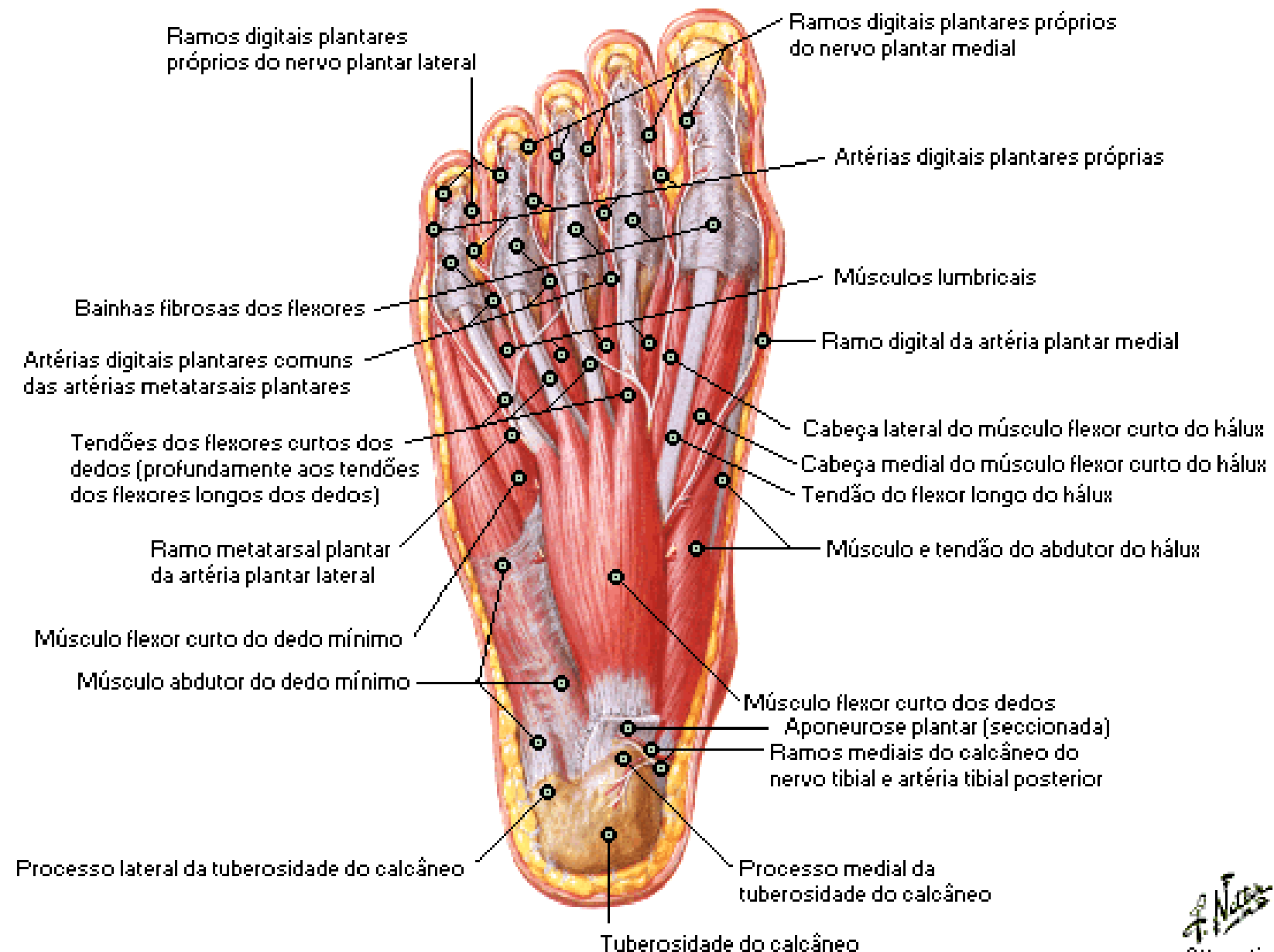
Dorso do Pé

Dissecação Profunda



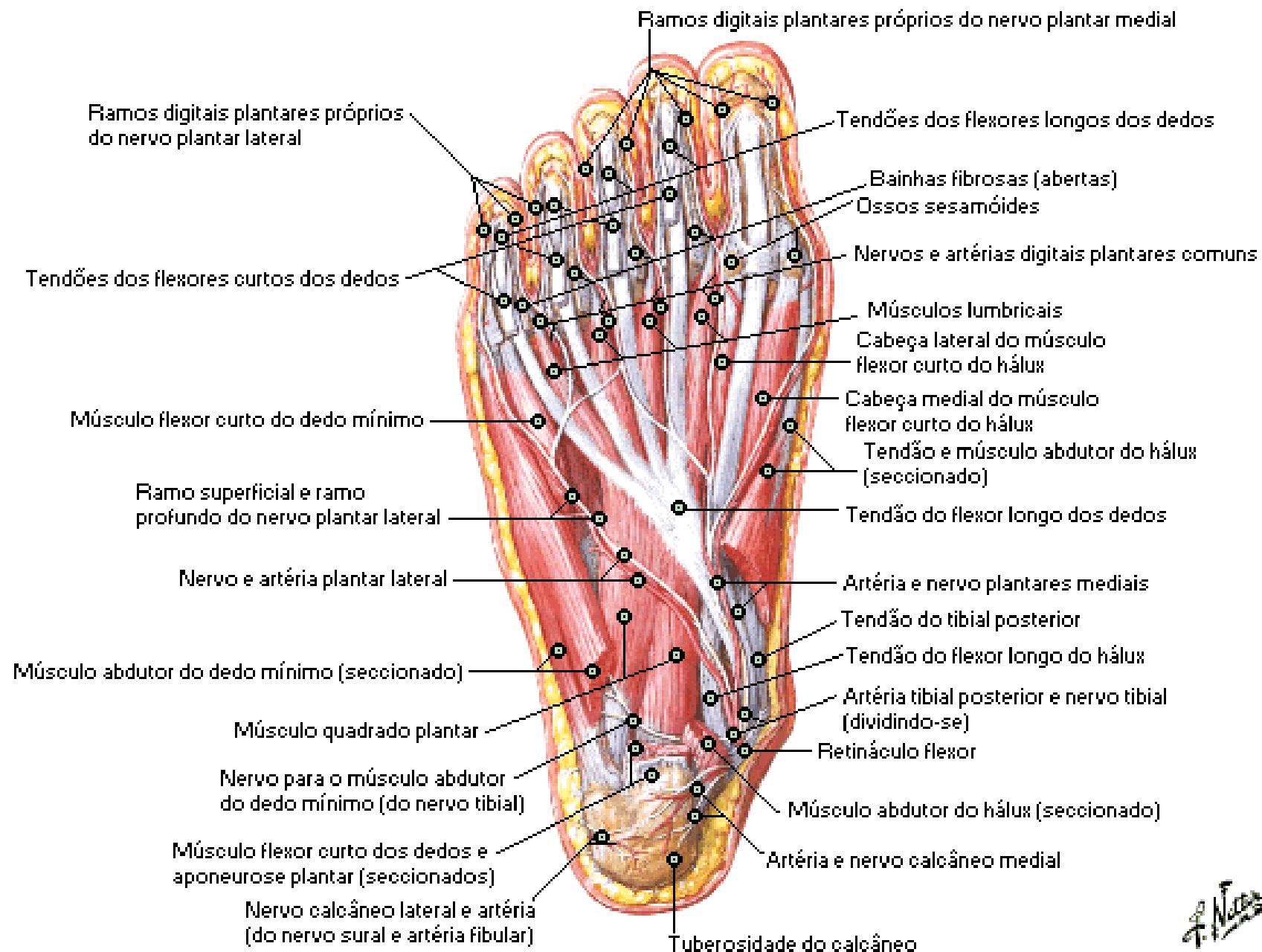
Músculos da Planta do Pé

Primeira Camada



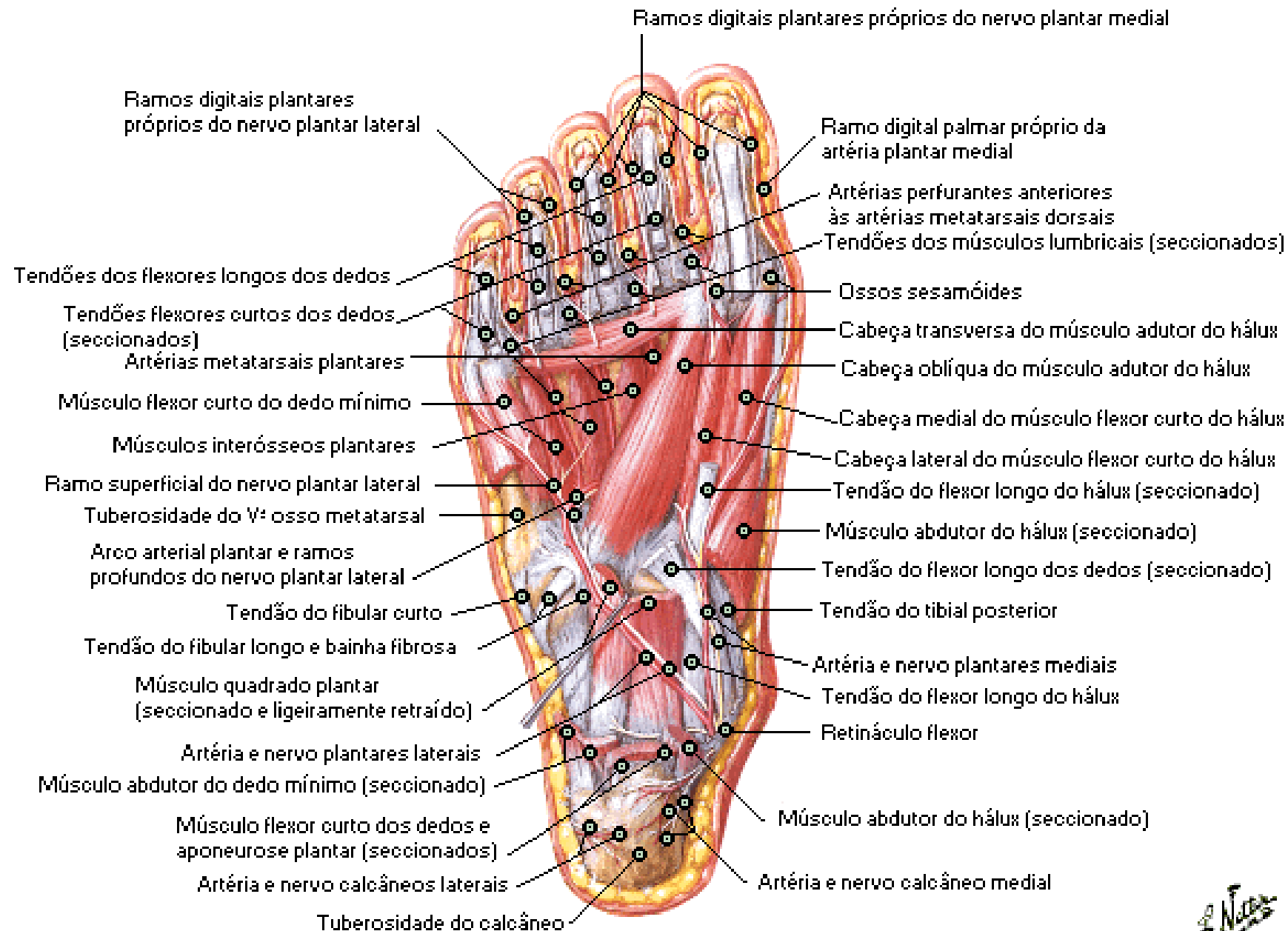
Músculos da Planta do Pé

Segunda Camada



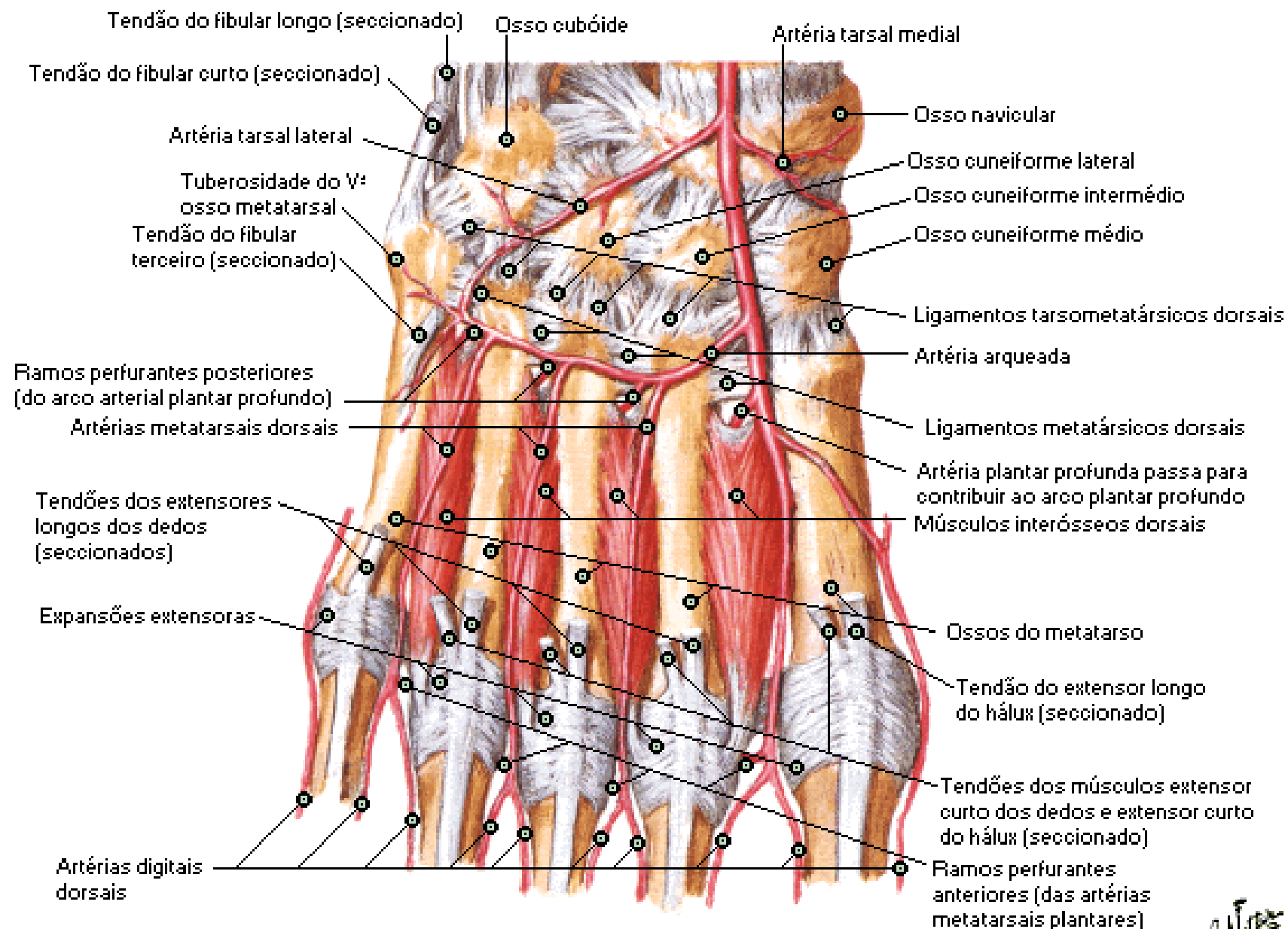
Músculos da Planta do Pé

Terceira Camada



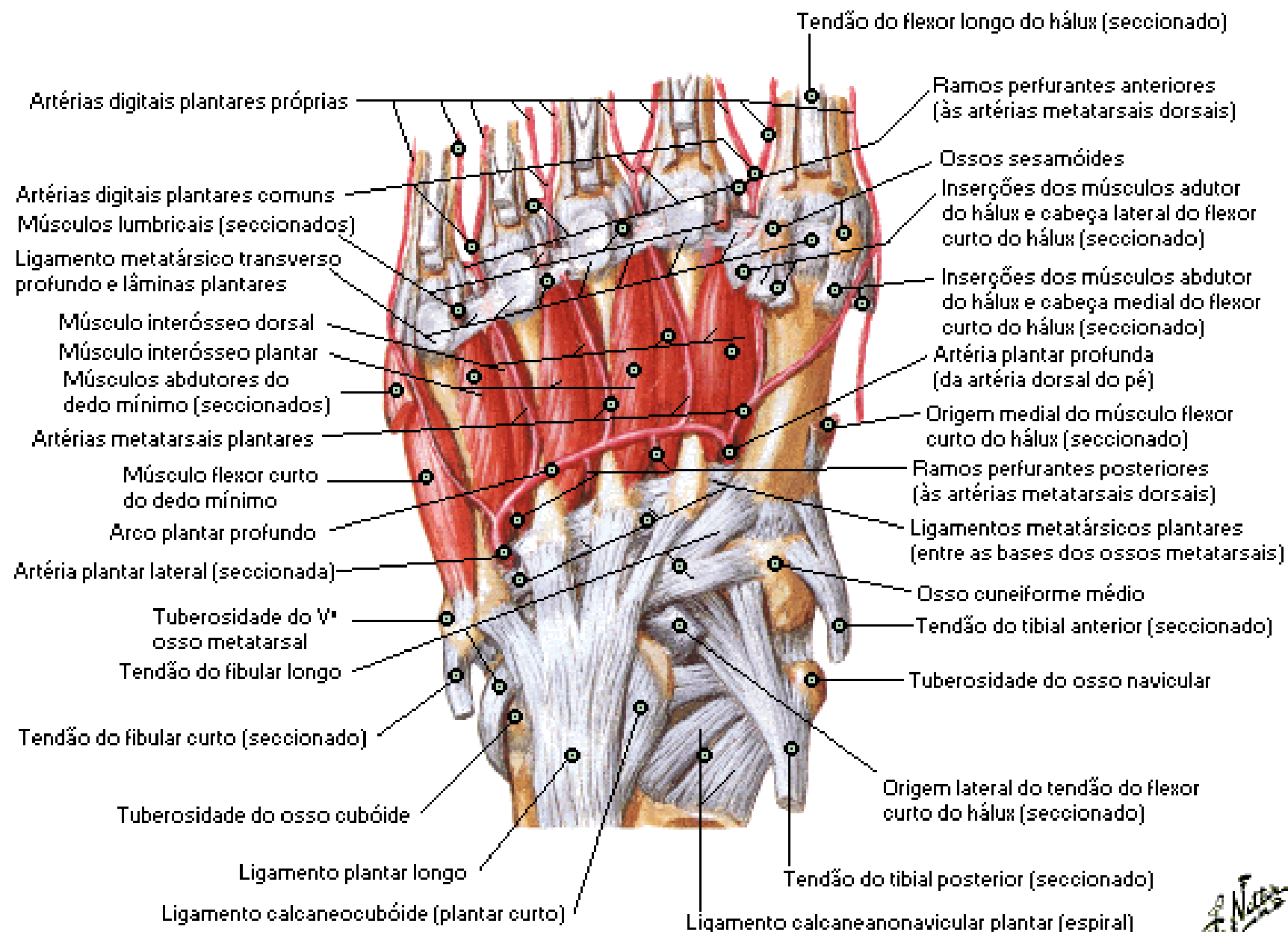
Músculos Interósseos e Artérias Profundas do Pé

Vista Dorsal



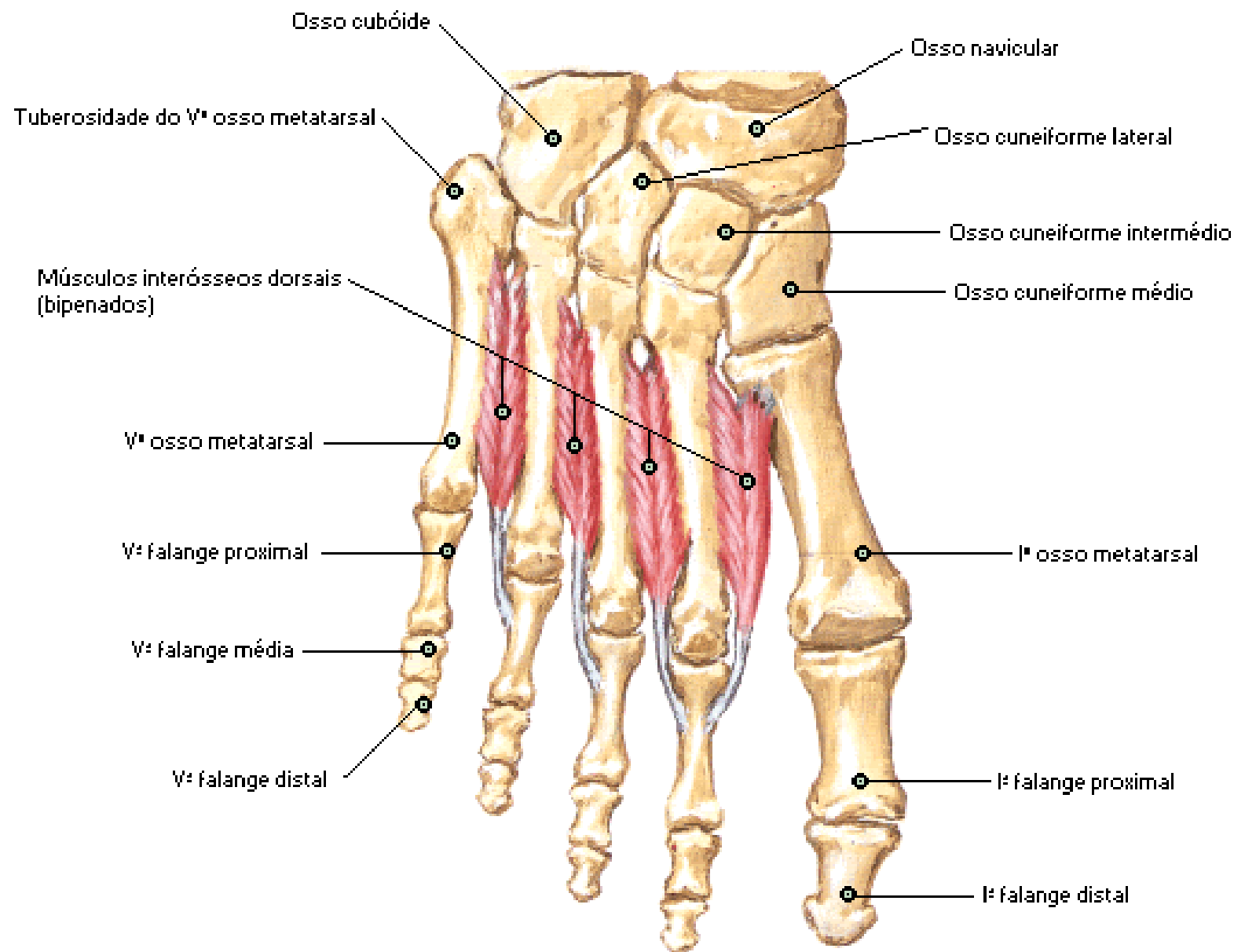
Músculos Interósseos e Artérias Profundas do Pé

Vista Plantar



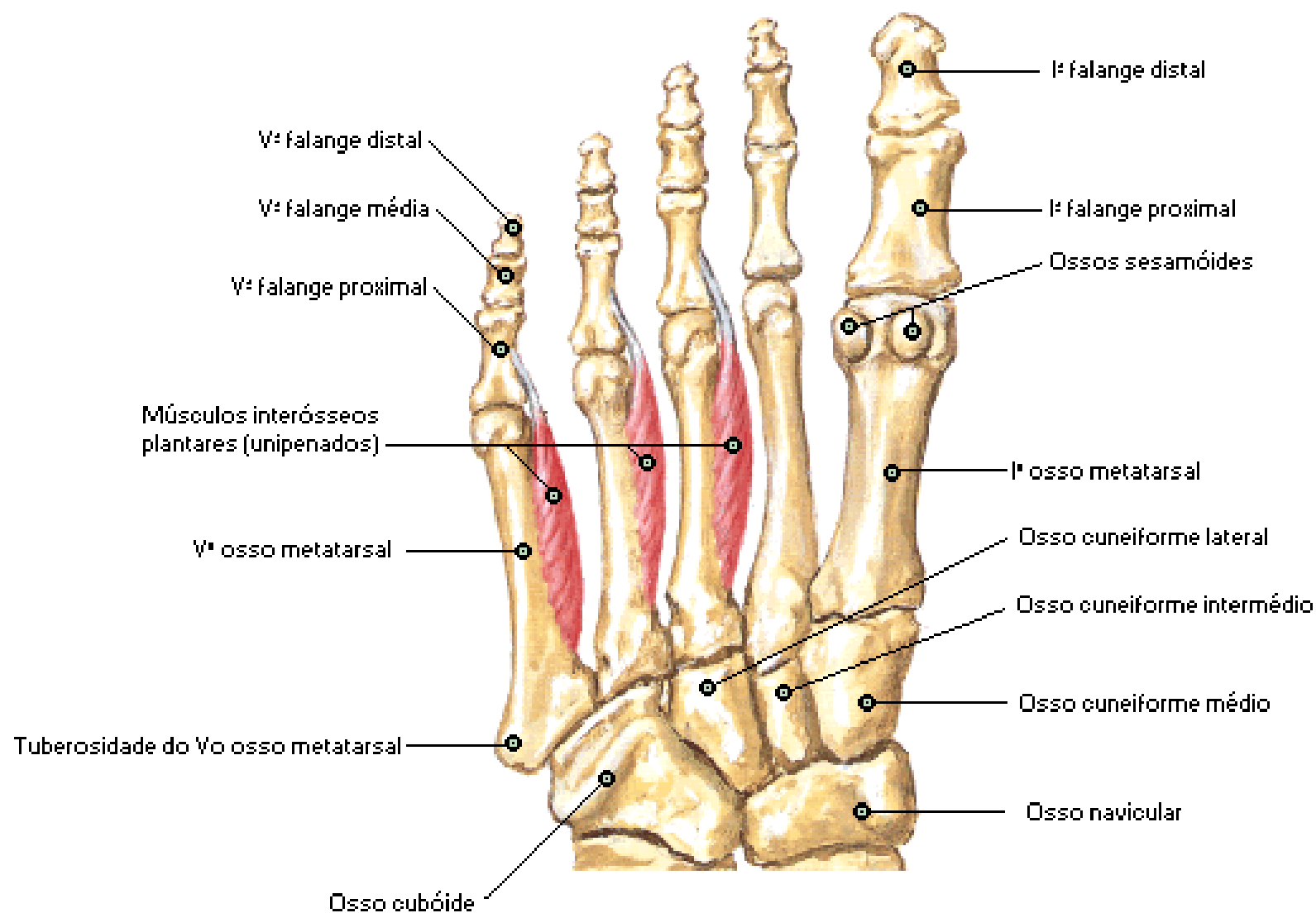
Músculos Interósseos do Pé

Vista Dorsal



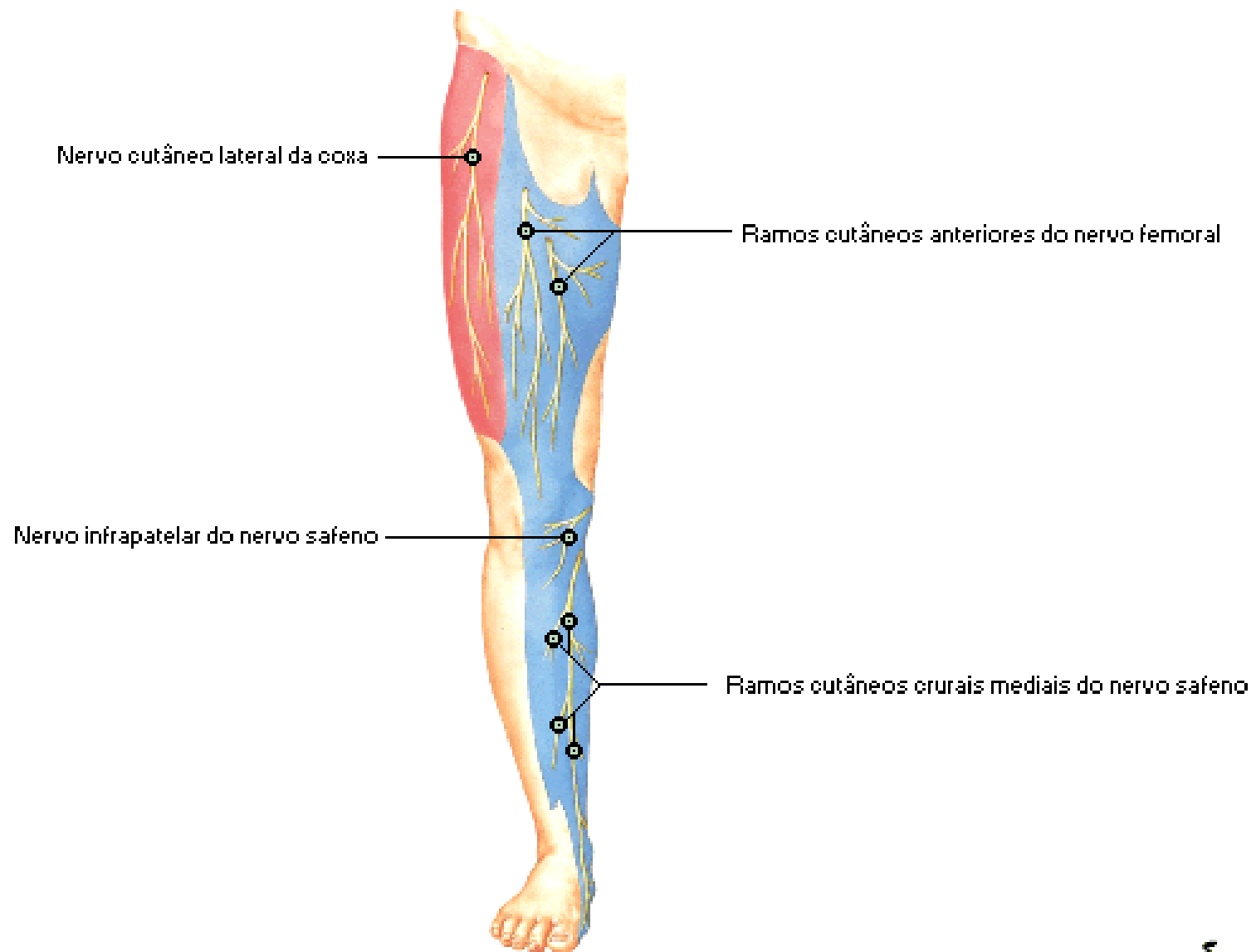
Músculos Interósseos Plantares

Vista Plantar

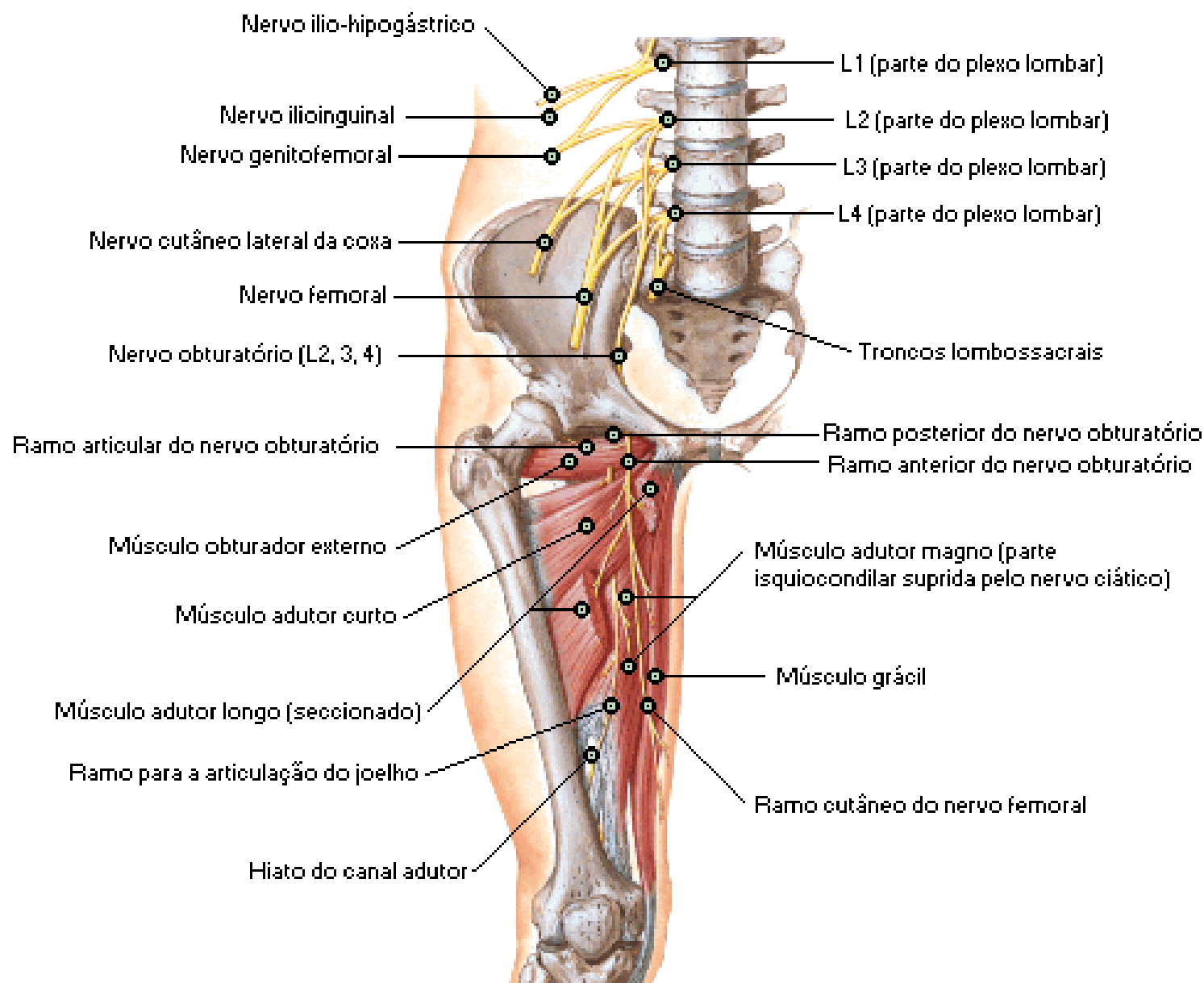


Nervo Femoral e Nervo Cutâneo Lateral da Coxa

Inervação Cutânea



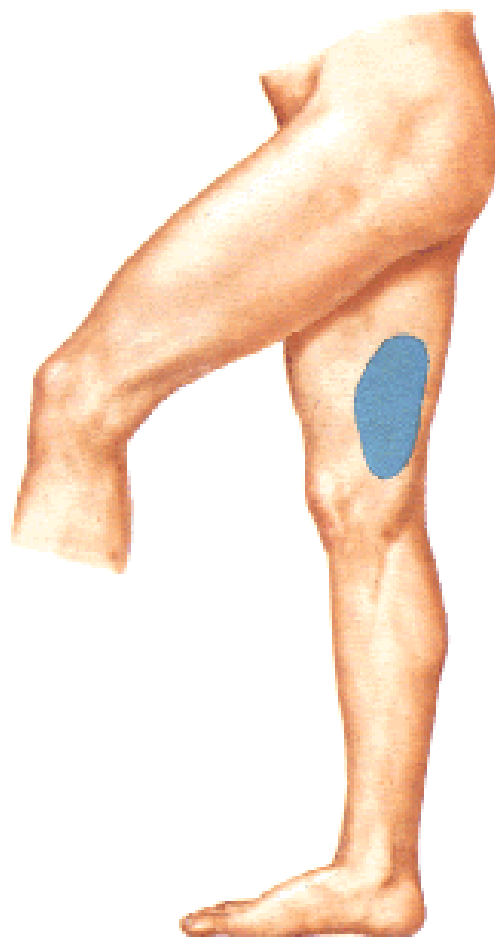
Nervo Obturatório



Nota: são mostrados somente os músculos inervados pelo nervo obturatório

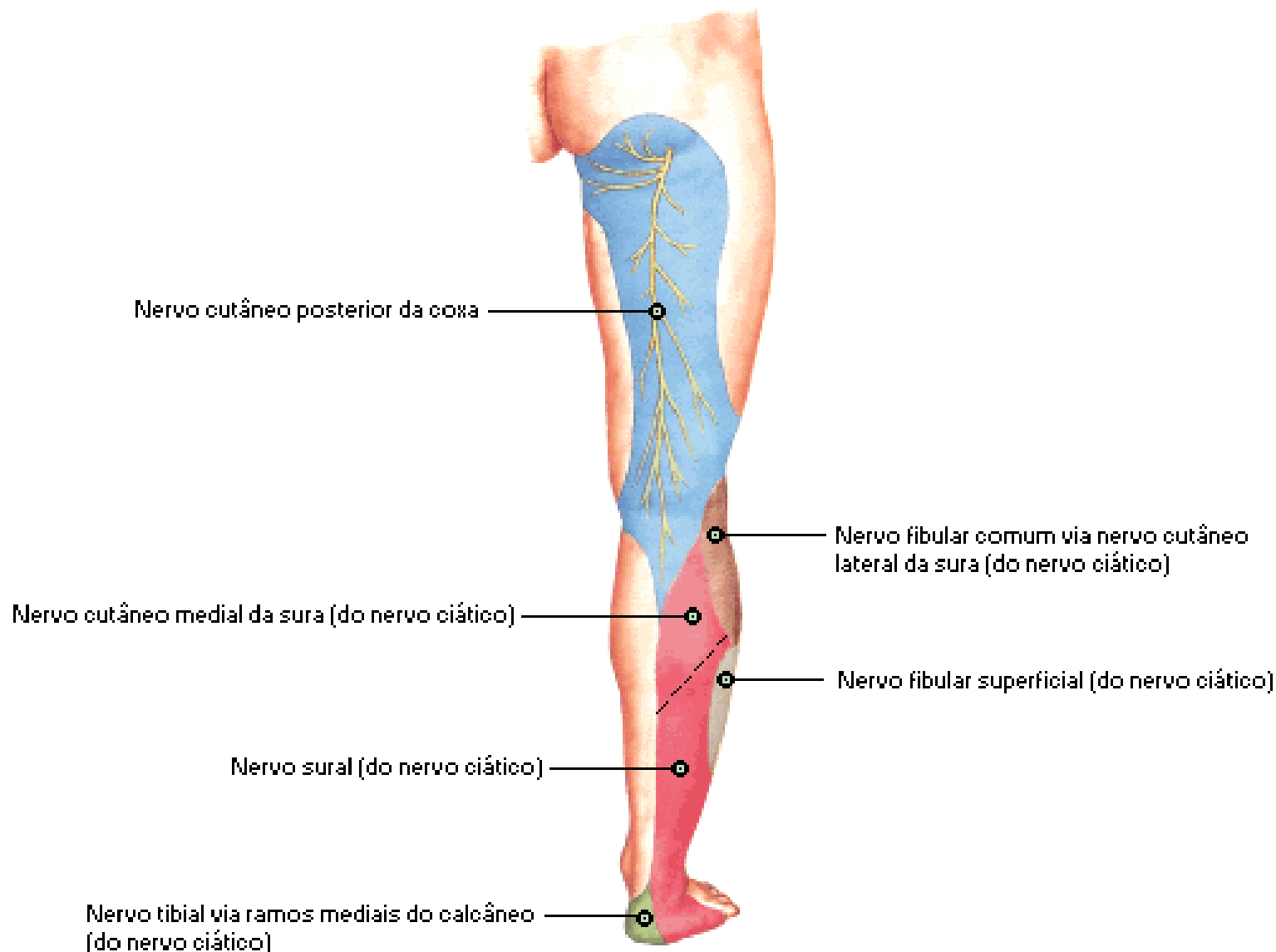
Nervo Obturatório

Inervação Cutânea

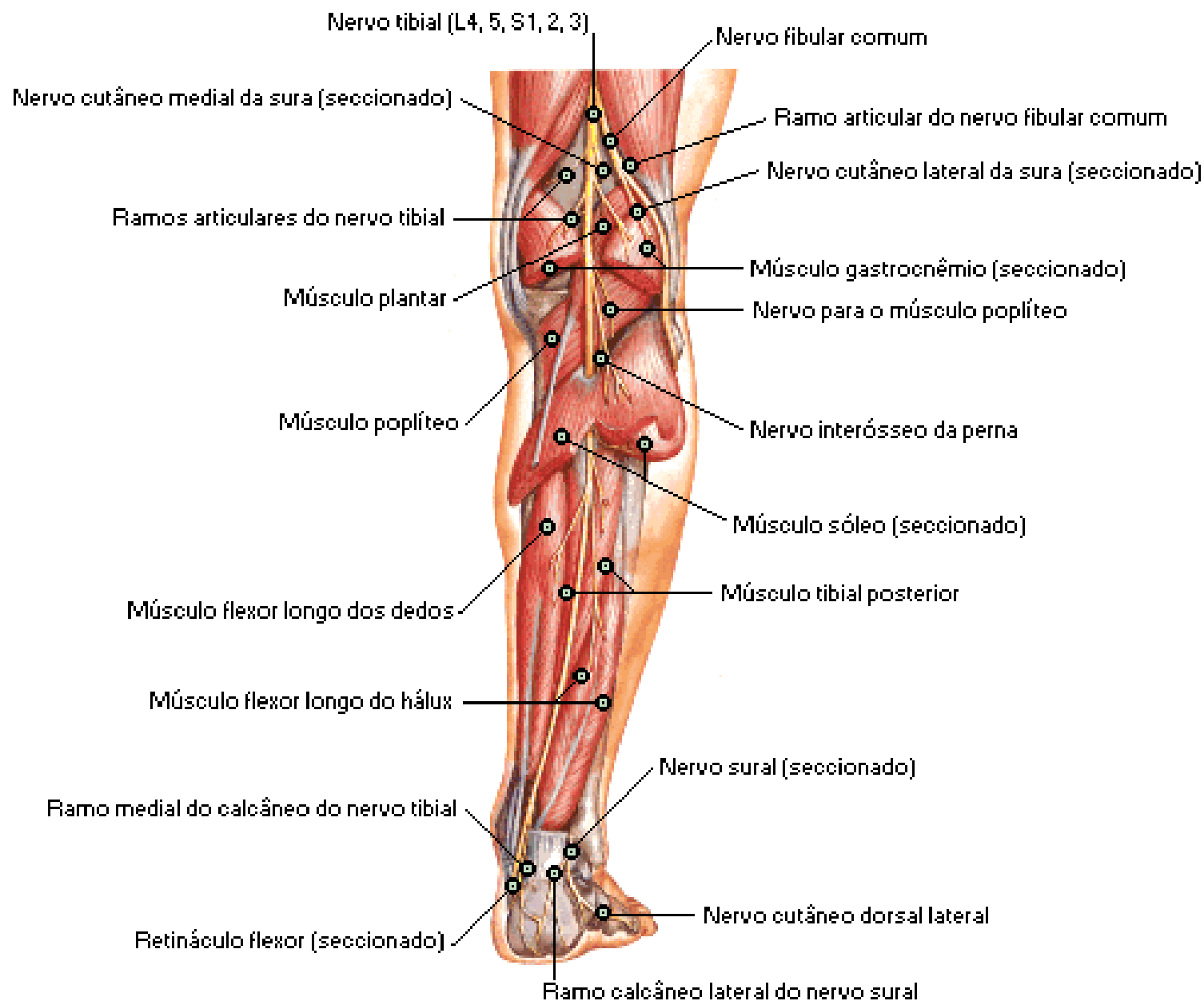


Nervo Ciático e Nervo Cutâneo Posterior da Coxa

Inervação Cutânea

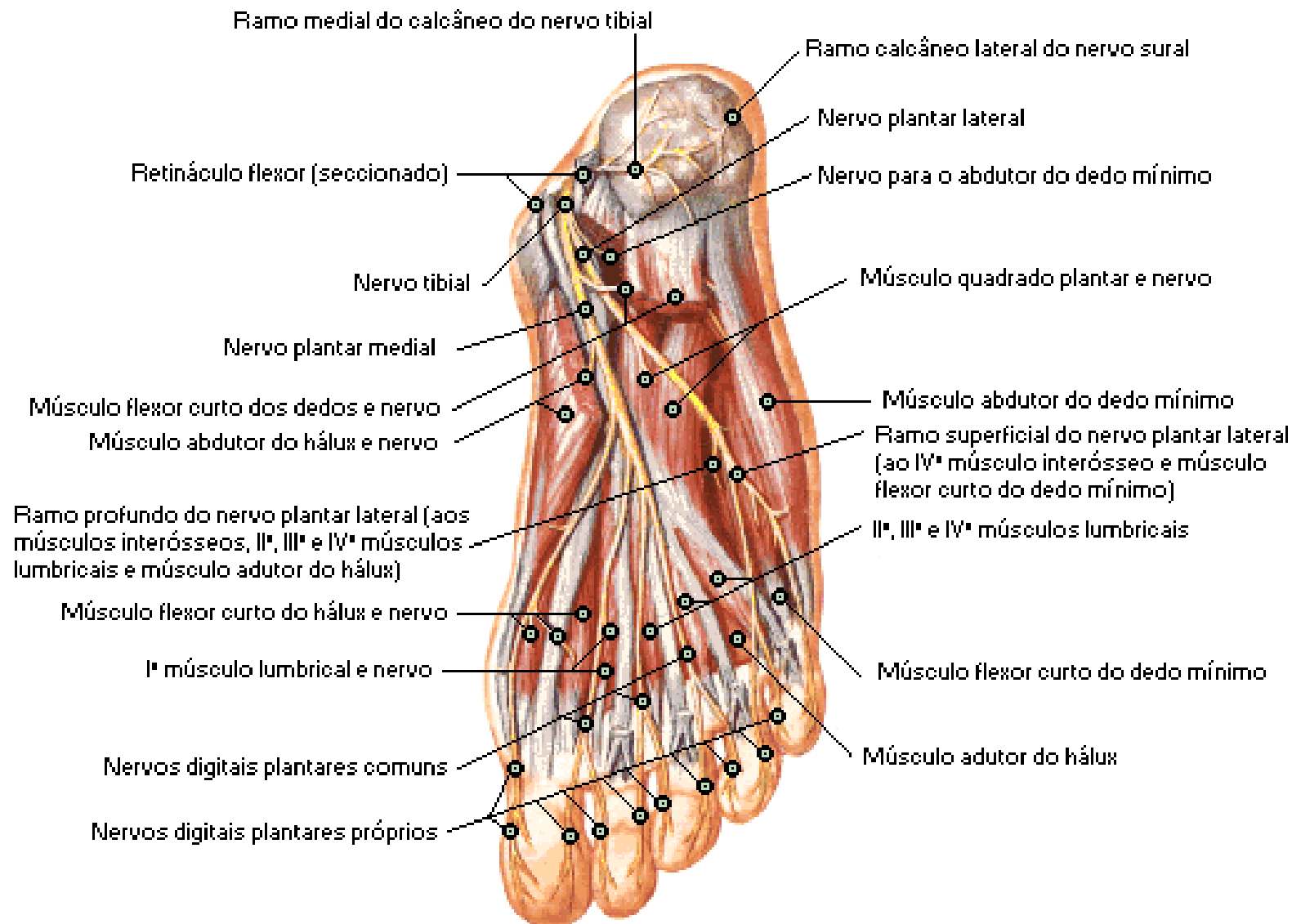


Nervo Tibial



Nervo Tibial

Vista Plantar



Nota: ramos articulares não são mostrados

Nervo Tibial

Inervação Cutânea da Planta do Pé

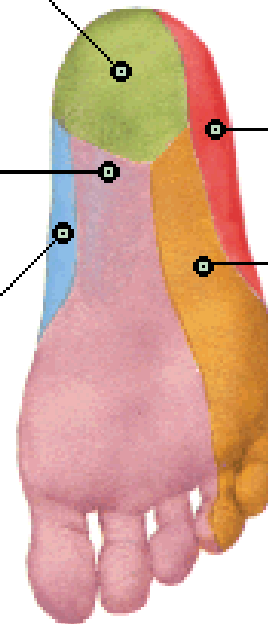
Ramos mediais (S1, 2) do calcâneo do nervo tibial

Nervo plantar medial (L4, 5) do nervo tibial

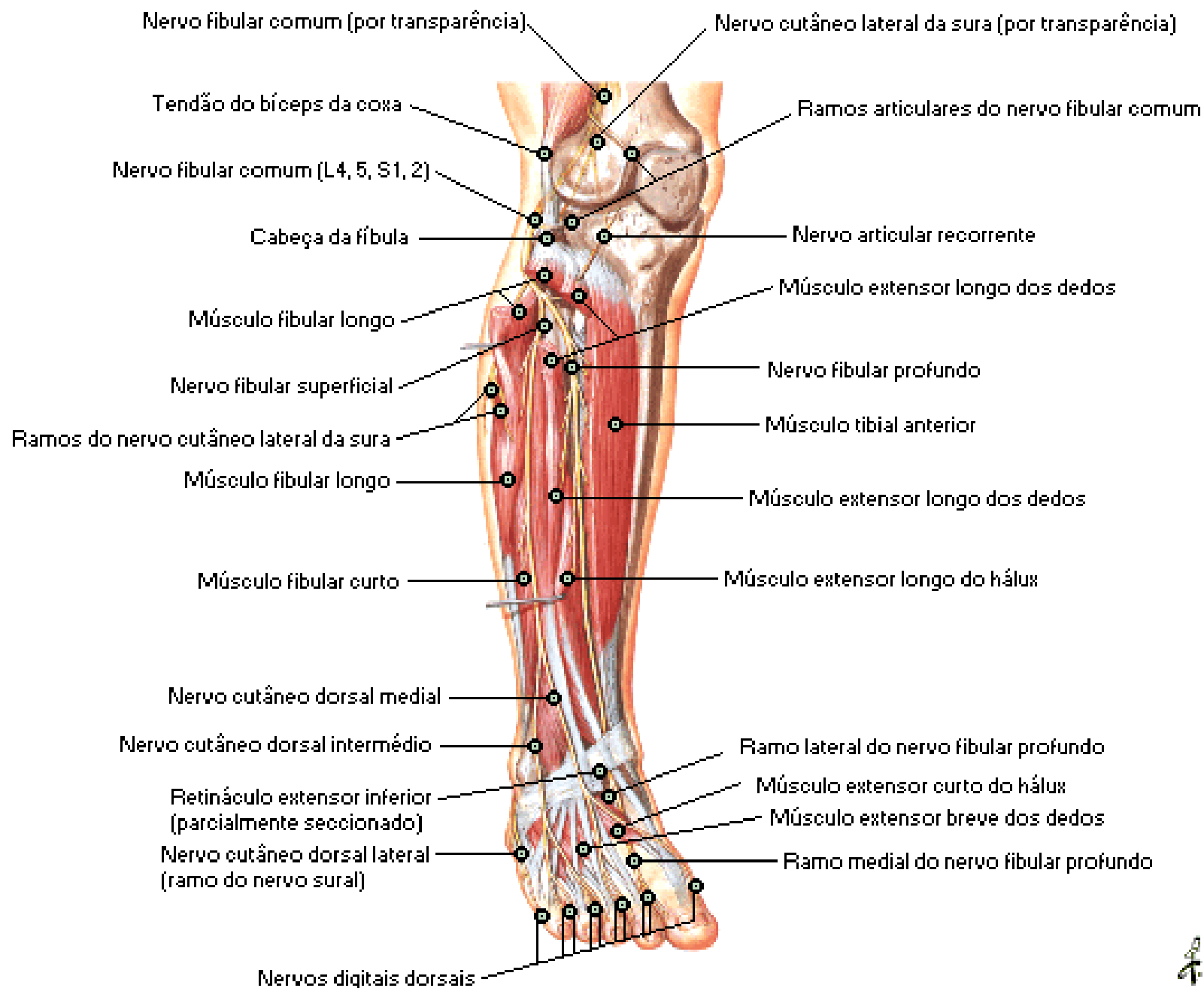
Nervo safeno (L3, 4)

Nervo sural (S1, 2) via ramos lateral do calcâneo e cutâneo dorsal lateral

Nervo plantar lateral (S1, 2) do nervo tibial

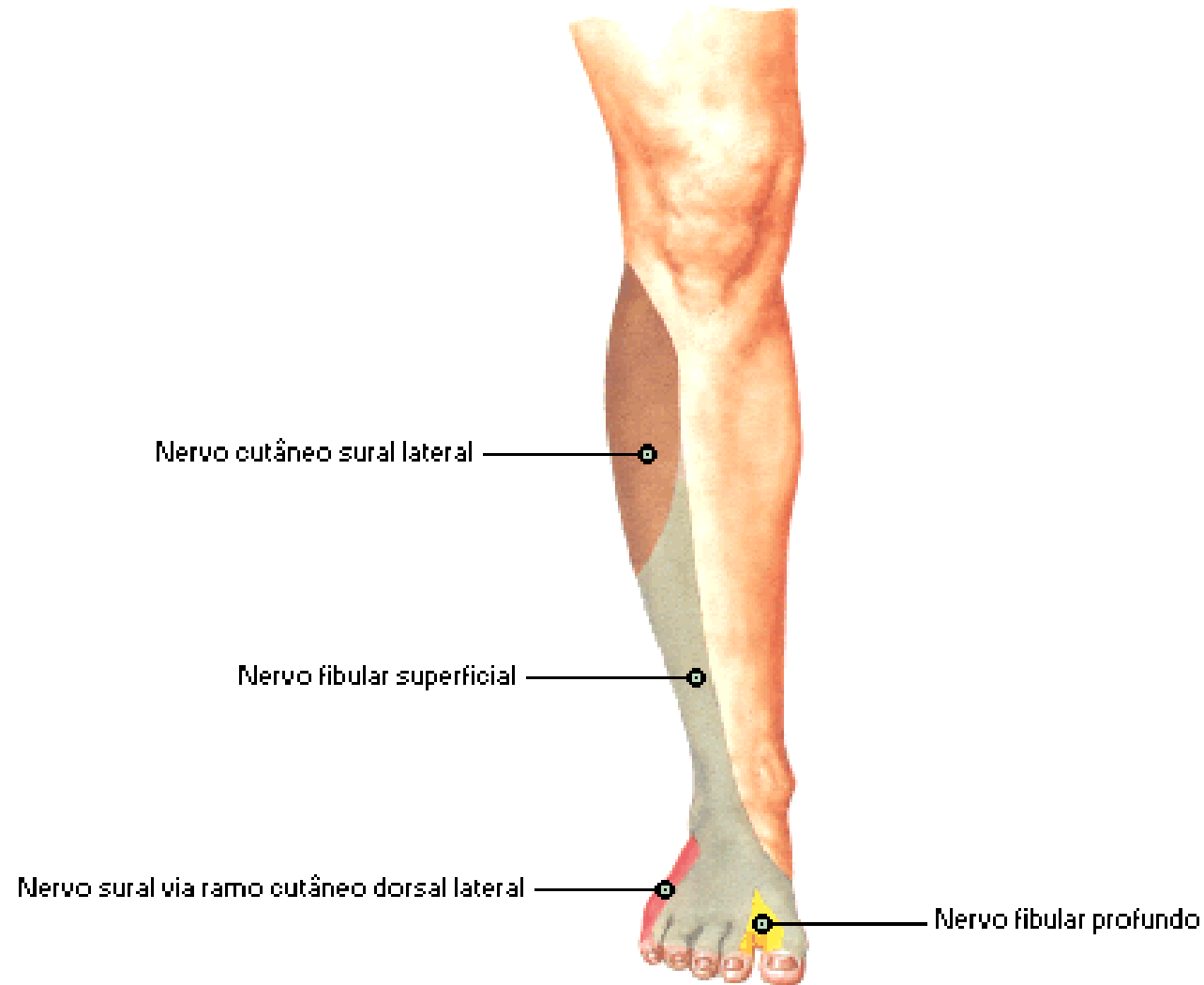


Nervo Fibular Comum



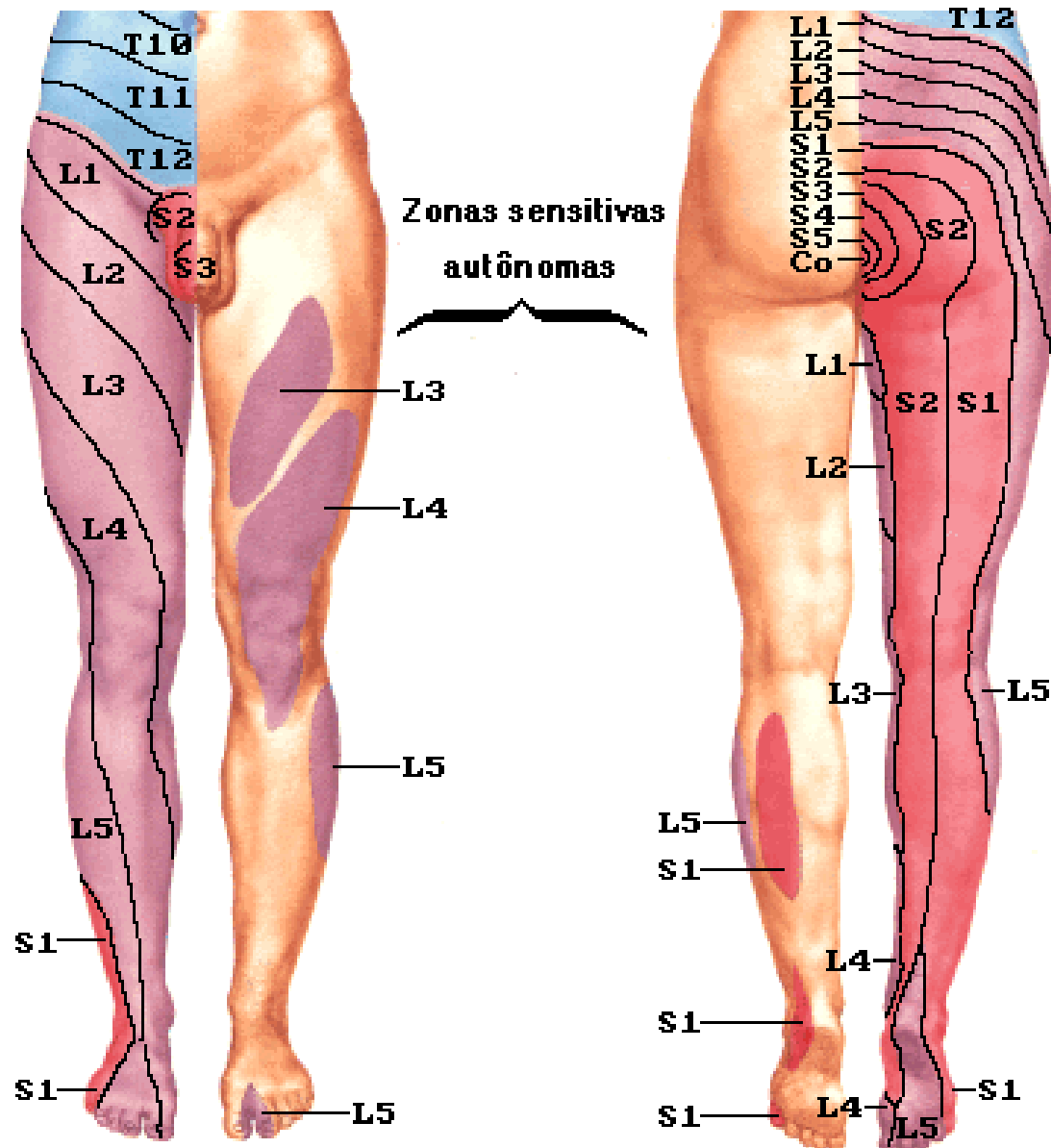
Nervo Fibular Comum

Inervação Cutânea

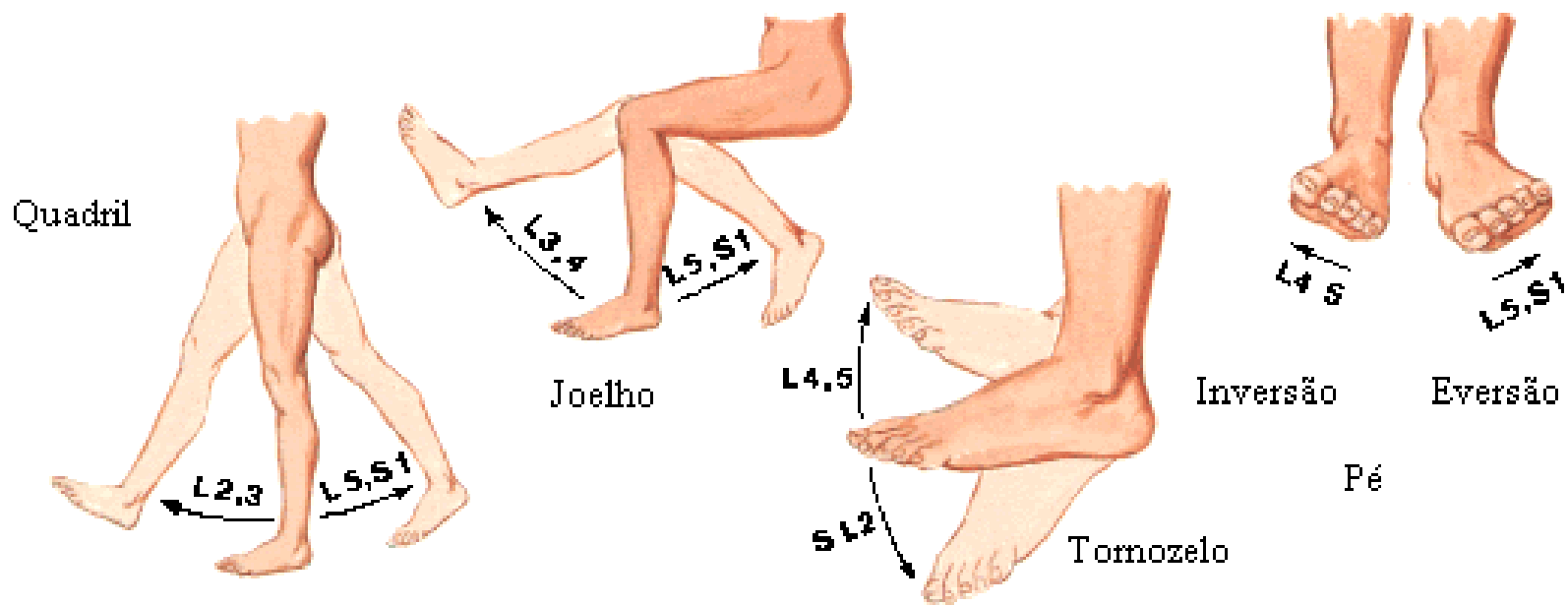


Dermátomos do Membro Inferior

Vistas Anterior e Posterior

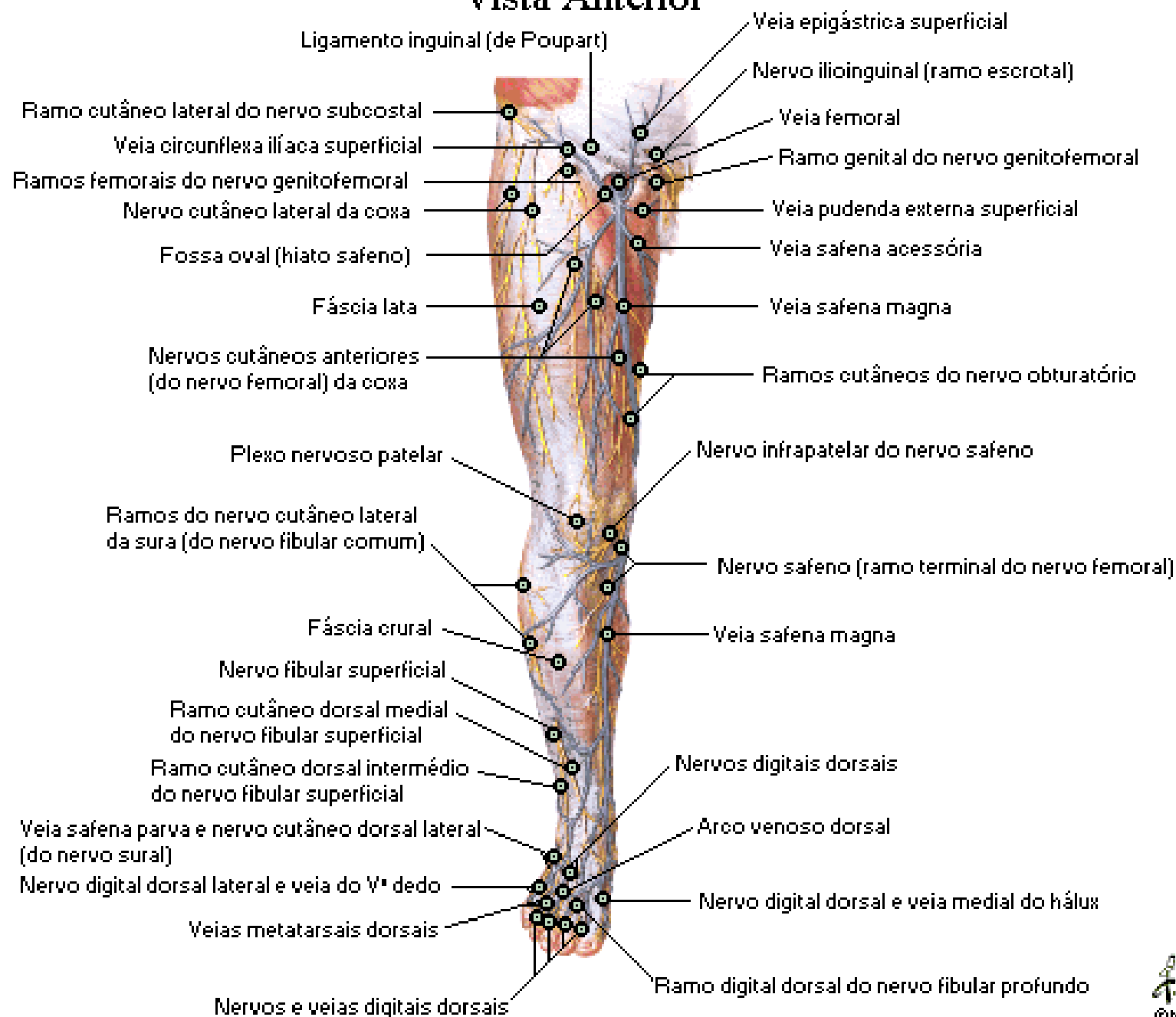


Inervação Segmentar dos Movimentos do Membro Inferior



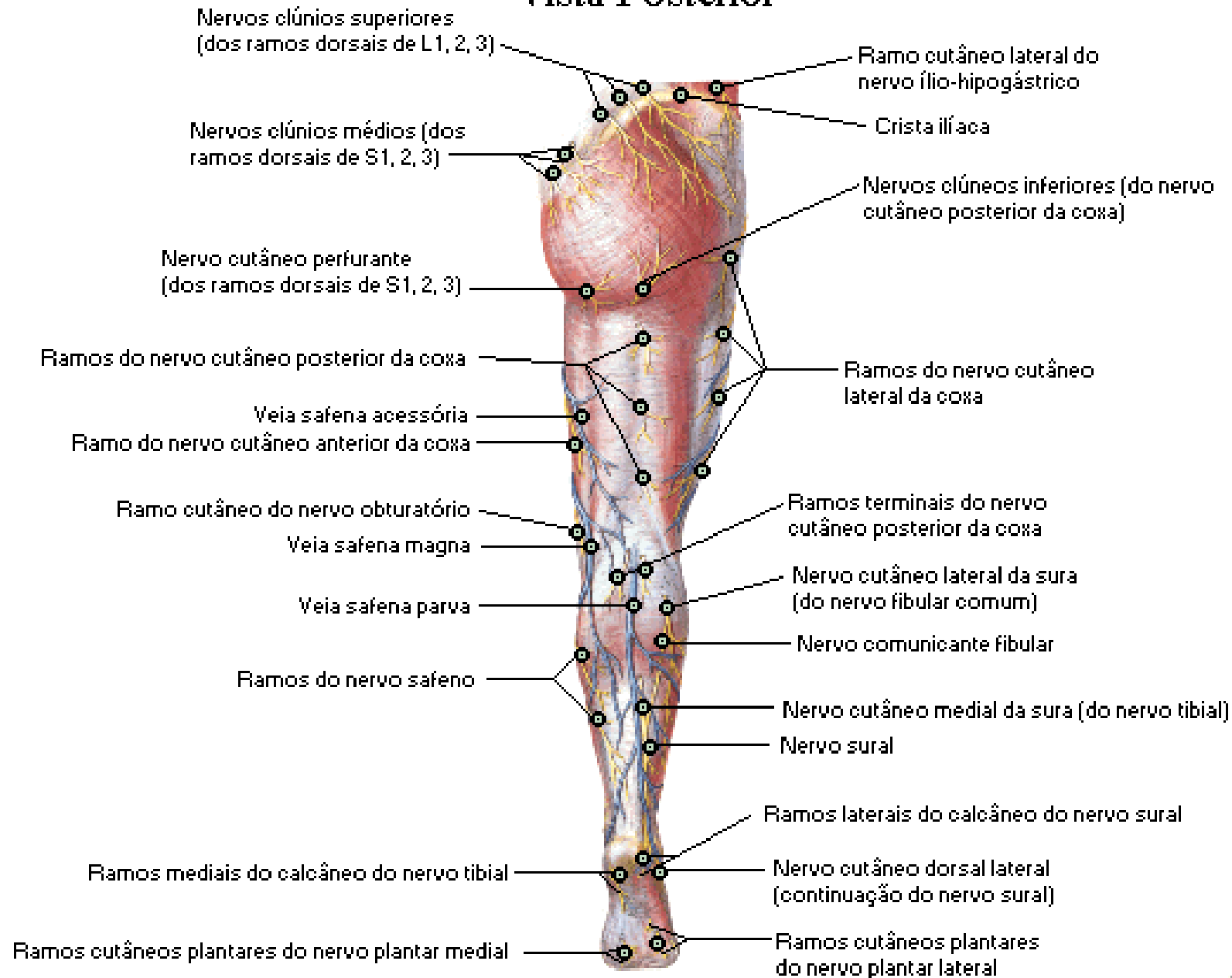
Nervos e Veias Superficiais do Membro Inferior

Vista Anterior



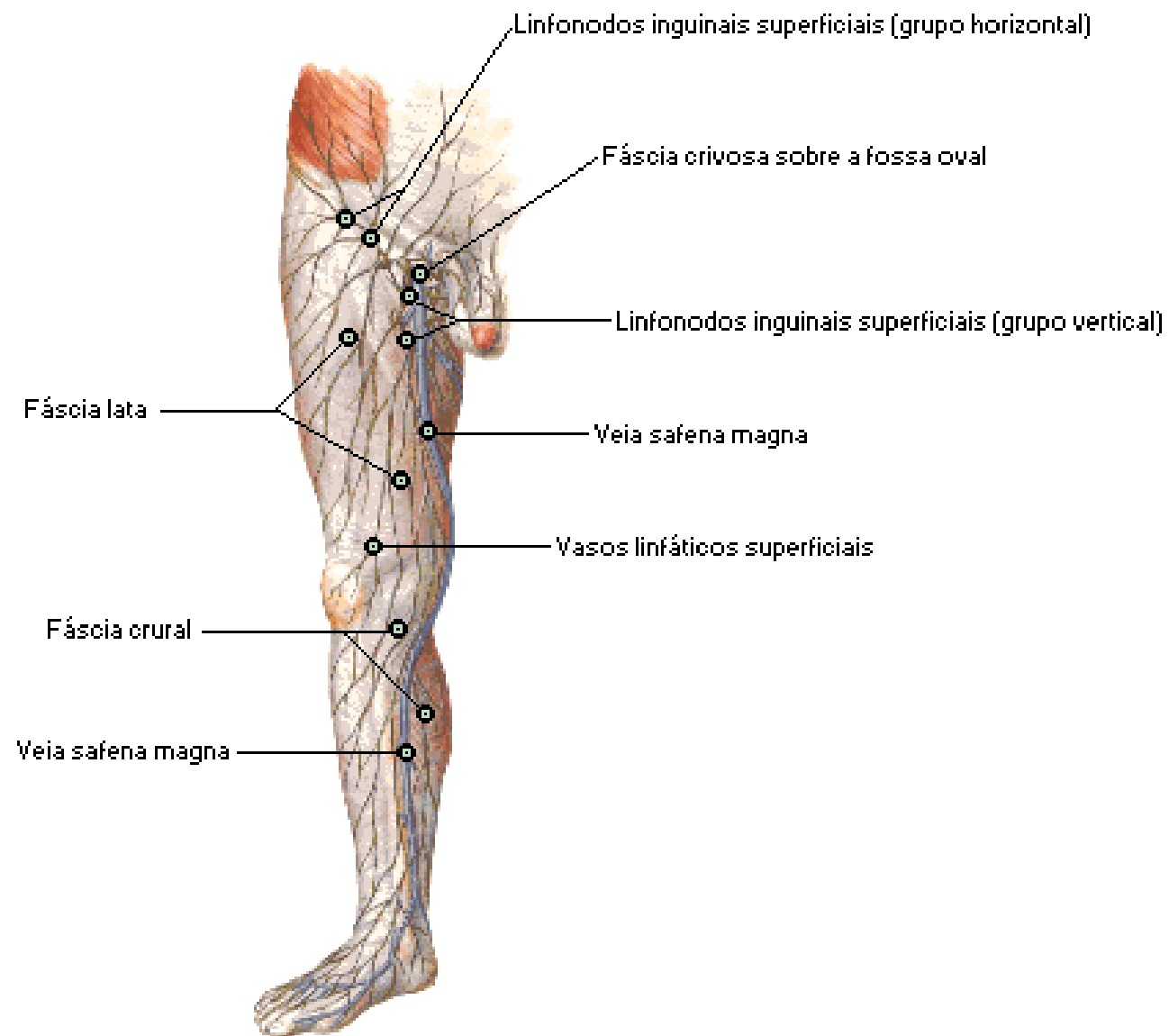
Nervos e Veias Superficiais do Membro Inferior

Vista Posterior



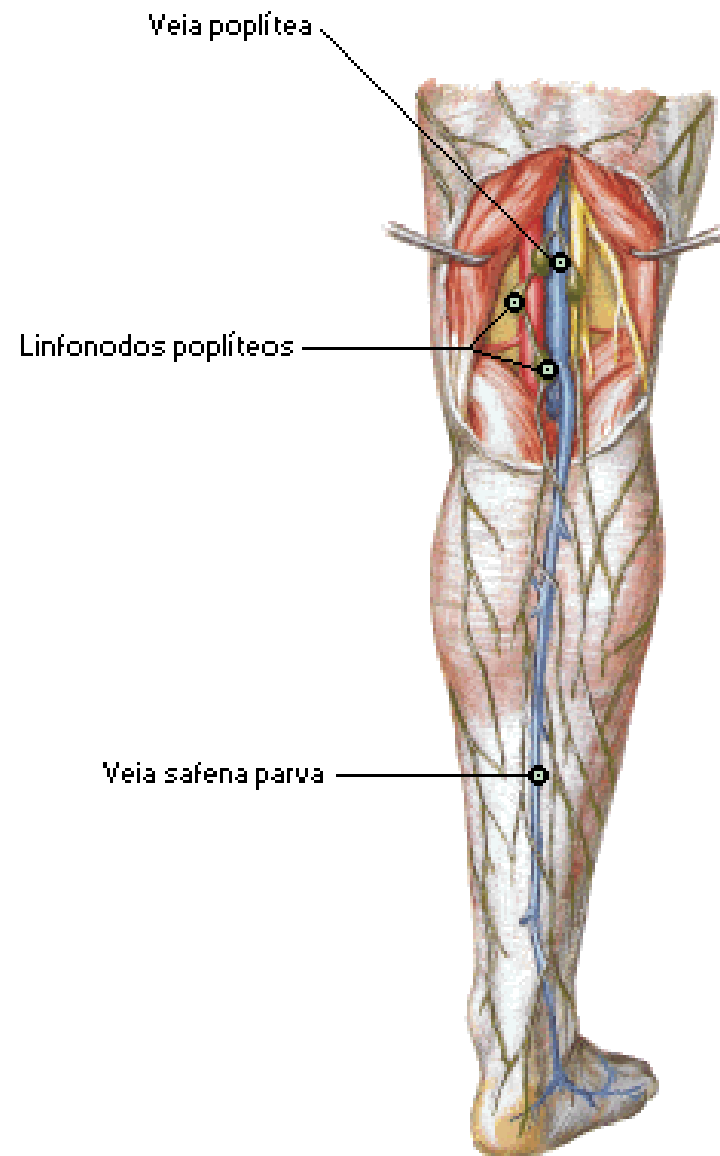
Vasos Linfáticos e Linfonodos do Membro Inferior

Vista Anterior



Vasos Linfáticos e Linfonodos do Membro Inferior

Vista Posterior



Vasos Linfáticos e Linfonodos do Membro Inferior

Região Inguinal

